



Textbook of EAR, NOSE & THROAT DISEASES

TWELFTH EDITION

Mohammad Maqbool
Suhail Maqbool

JAYPEE

Foreword
Suresh C Sharma

Contents

Section 1: EAR

1. Development of the Ear **3**

Development of the External and Middle Ear 3; Development of the Inner Ear 4; Development of the Bony Labyrinth 4

2. Anatomy of the Ear **6**

External Ear 6; Middle Ear Cleft 8; Inner Ear 11; Average Physical Data of the Ear 14; Inner Ear 14

3. Physiology of the Ear **16**

Physiology of Hearing 16; Physiology of the Vestibular System 18; Distortion in the Ear 19

4. History Taking with Symptomatology of Ear Diseases **20**

Deafness 20

5. Examination of the Ear **22**

Methods of Examination of the Ear 22; Evaluation of Ear Disease 23; Functional Examination of Ear 24; Radiological Examination of the Ear 27; Contrast Radiography 28; Nuclear Magnetic Resonance 28; Examination of the Vestibular Apparatus 28; Craniocorpography 32

6. Congenital Diseases of the External and Middle Ear **33**

Anomalies of the Pinna 33; Anomalies of the External Auditory Canal 34; Anomalies of the Middle Ear 34

7. Diseases of the External Ear **35**

Perichondritis 35; Hematoma of the Auricle 35; Frostbite of the Pinna 35; Pseudocyst Pinna 36; Otitis Externa 36; Otomycosis 37; Malignant Otitis External 37; Keratosis Obturans (Canal Wall Cholesteatoma) 37; Foreign Bodies in the External Auditory Canal 37; Impacted Wax in the External Canal 38; Bullous Myringitis 38; Traumatic Perforations of the Tympanic Membrane 38

8. Diseases of the Eustachian Tube **39**

Acute Salpingitis (Acute Tubal Catarrh) 39; Chronic Salpingitis 39

9. Acute Suppurative Otitis Media and Acute Mastoiditis **40**

Acute Suppurative Otitis Media 40; Myringotomy 43

10. Chronic Suppurative Otitis Media **45**

Rafiq Ahmad Pampori

Tubotympanic Type (Safe Type) 45; Atticoantral Disease (Unsafe Type) 48; Tuberculous Otitis Media 49

11. Complications of Chronic Suppurative Otitis Media **50**
Labyrinthitis 50; Otogenic Intracranial Infection 51; Extradural Abscess 51; Sinus Thrombophlebitis 51; Otitic Hydrocephalus 52; Otogenic Brain Abscesses 52

12. Nonsuppurative Otitis Media and Otitic Barotrauma **54**
Nonsuppurative Otitis Media 54; Acute Otitic Barotrauma 55

13. Adhesive Otitis Media **56**
Etiology 56; Pathology 56; Clinical Features 56; Treatment 56; Tympanosclerosis 56

14. Mastoid and Middle Ear Surgery **58**
Incisions for Exposure of Middle Ear Cleft 58; Surgical Procedures for the Discharging Ear 58; Tympanoplasty 60

15. Otosclerosis **62**
Etiology 62; Pathology of Otosclerosis 62; Types of Otosclerosis 62; Clinical Features 63; Physical Findings 63; Differential Diagnosis of Otosclerosis 63; Treatment 64; Stapedectomy 64; Cochlear Otosclerosis 65; Malignant Otosclerosis 65

16. Tumors of the Ear **66**
Tumors of the External Ear 66; Tumors of the Middle Ear 67; Tumors of the Inner Ear 69

17. Otological Aspects of Facial Paralysis **71**
Facial Paralysis 71; Otological Aspects of Facial Paralysis 71; Bell's Palsy 73; Hemifacial Spasm 74; Important Points 74

18. Ménière's Disease and Other Common Disorders of the Inner Ear **75**
Ménière's Disease 75; Vertigo 77; Vestibular Neuronitis 77; Benign Paroxysmal Positional Vertigo 77

19. Ototoxicity **78**
Clinical Features of Ototoxicity 78; Prevention and Treatment of Ototoxicity 79

20. Tinnitus **80**
Tinnitus Aurium 80

21. Deafness **82**
Rafiq Ahmad Pampori
Classification 82; Deaf-Mute 84; Acoustic Trauma 85; Presbycusis (Senile Deafness) 85; Sudden Deafness 85; Psychogenic Deafness 86

22. Hearing Aids and Cochlear Implant **88**
Hearing Aids 88; Cochlear Implant 89

23. Principles of Audiometry **94**
Acoustics 94; Audiometry 95

MCQs on Ear **101**

Section 2: NOSE

24. Development and Anatomy of the Nose and Paranasal Sinuses **107**
Development 107; Anatomy 108; Paranasal Sinuses 110; Blood Supply of the Nasal Cavity 110; Nerve Supply of the Nose 111; Lymphatic Drainage of Nose and Paranasal Sinuses 111

25. Physiology of the Nose and Paranasal Sinuses **112**
Olfactometry (Odor Measurement) 112; Disturbances of Olfaction 113; Functions of the Paranasal Sinuses 113; Multifarious Functions of Nose 113

26. Common Symptoms of Nasal and Paranasal Sinus Diseases **114**
Nasal Discharge 114; Nasal Obstruction 114; Facial Pain and Headache 114; Epistaxis 114; Disorders of Olfaction 114; Postnasal Drip 115; Speech Defect 115; Symptoms due to Extension of the Disease to the Adjacent Regions 115; Sneezing 115; Snoring 115; Sleep Apnea 115

27. Examination of the Nose, Paranasal Sinuses and Nasopharynx **117**
Inspection and Palpation 117; Anterior Rhinoscopy 117; Posterior Rhinoscopy 118; Rhinomanometry 119; Digital Palpation of the Nasopharynx 119; Nasopharyngoscopy 119; Transillumination of the Sinuses 119; Sinoscopy 119; Radiological Examination of the Nose and Paranasal Sinuses 119; CT Scan of the Nose, Paranasal Sinuses and Nasopharynx 120; Angiography 120

28. Congenital Diseases of the Nose **121**
Choanal Atresia 121; Dermoid Cysts of the Nose 122; Nasal Glioma 123; Encephalocele 123

29. Diseases of the External Nose **124**
Furunculosis of the Nose 124; Cavernous Sinus Thrombosis 124; Vestibulitis 125; Erysipelas 125; Acne Rosacea 125; Lupus Erythematosus 125; Herpes Simplex 125; Herpes Zoster 125; Rhinophyma 125; Neoplasms of the External Nose 126

30. Bony Injuries of the Face **127**
Fracture of the Nasal Bones 127; Fractures of the Maxilla 128; Fractures of the Malar-Zygomatic Complex 128; Blow-out Fracture of the Orbit 128; Cerebrospinal Rhinorrhea 129

31. Foreign Bodies in the Nose **130**
Inanimate Foreign Bodies 130; Animate Foreign Bodies 130; Rhinolith 131

32. Epistaxis **132**
Abdullah Terkawi, Saleh F AlDhahri
Applied Anatomy 132; Examination 133; Treatment 134

33. Diseases of the Nasal Septum **135**
Deviated Nasal Septum 135; Submucous Resection of Septum 136; Septoplasty 137; Septorhinoplasty 138; Septal Hematoma 139; Septal Abscess 139; Perforation of the Nasal Septum 139

34. Acute Rhinitis **141**
Etiology 141; Pathology 141; Nasal Diphtheria 141; Other Causes of Rhinorrhea 142

35. Chronic Rhinitis **143**
Chronic Hypertrophic Rhinitis 143; Rhinitis Caseosa (Nasal Cholesteatoma) 143; Atrophic Rhinitis (Ozena) 143; Anthrax 144; Xeroderma Pigmentosa 145; Granulomatous Lesions of Nose 145; Lupus Vulgaris of Nose 145; Tuberculosis of the Nose 146; Syphilis of the Nose 146; Leprosy 146; Rhinosporidiosis 146; Rhinoscleroma 147; Midline Nasal Granulomas 147

36. Nasal Allergy, Vasomotor Rhinitis and Nasal Polyposis **149**
Nasal Allergy 149; Vasomotor Rhinitis 150; Nasal Polyposis 150

37. Rhinosinusitis **154**
Imtiaz Majid Qazi
Acute Rhinosinusitis 154; Chronic Rhinosinusitis 156; Cysts in the Maxillary Region 165

38. Tumors of the Nose and Paranasal Sinuses **168**
Tumors of the Nasal Cavity 168; Tumors of the Paranasal Sinuses 170

39. Headache **175**
Classification of Headache 175

40. Facial Neuralgia (Pain in the Face) **177**

MCQs on Nose **179**

Section 3: THROAT

41. Oral Cavity and Pharynx **187**
Anatomy and Physiology of the Pharynx 187; Soft Palate 188; Physiology of the Pharynx 189; Deglutition 189

42. Common Symptoms of Oropharyngeal Diseases and the Method of Examination **191**
Common Symptoms of Oropharyngeal Diseases 191; Method of Examination of the Oral Cavity and Pharynx 192

43. Common Diseases of the Buccal Cavity **193**
Stomatitis 193; Cysts of Mouth 195; Carcinoma of the Tongue 196; Ludwig's Angina 196; Tumors of the Oral Cavity 196; Ameloblastoma (Adamantinoma) 198

44. Evaluation and Management of the Patient with a Neck Mass **199**
Khalid H Al-Qahtani
Anatomical Considerations 199; Branchial Apparatus and its Abnormalities 199; Neck Masses 203; Management of Metastatic Cervical Nodes 203; Diagnostic Work-up 203; Tumors of the Parapharyngeal Space 204; Salivary Gland Tumors 204; Neurogenic Tumors 205; Other Neurogenic Tumors 206; Hemangioma 206; Teratoma 208

45. Salivary Glands **209**
General Epidemiology 209; Parotid Gland 209; Submandibular Glands 213; Sialography 213

46. Pharyngitis **214**

Acute Pharyngitis 214; Membranous Pharyngitis 214; Chronic Pharyngitis 215; Keratosis Pharynges 215; Specific Infections of the Pharynx 216; Stenosis of the Pharynx 216

47. Tonsillitis **217**

Acute Tonsillitis 217; Chronic Tonsillitis 218; Acute Lingual Tonsillitis 218; Chronic Lingual Tonsillitis 218; Tonsillectomy 218; Peritonsillar Abscess (Quinsy, Paratonsillar Abscess) 220

48. Adenoids **222**

Clinical Features 222; Complications of Adenoids 222; Treatment 222

49. Pharyngeal Abscess **224**

Retropharyngeal Space 224; Parapharyngeal Space 224; Acute Retropharyngeal Abscess 224; Chronic Retropharyngeal Abscess 225; Parapharyngeal Abscess 225

50. Tumors of the Pharynx **226**

Tumors of the Nasopharynx 226; Nasopharyngeal Angiofibroma 226; Tumors of the Oropharynx 228; Tumors of the Hypopharynx 229; Plummer-Vinson or Paterson-Brown-Kelly Syndrome 231

51. Miscellaneous Conditions of the Throat **232**

Globus Hystericus (Globus Pharynges) 232; Palatal and Pharyngeal Palsy 232; Pharyngeal Spasm 232; Pharyngeal Pouch 233; Trismus (Lock Jaw) 233; Cleft Palate 233; Elongated Styloid Process (Stylalgia) 234

52. Development of Larynx and Tracheobronchial Tree **235**

Development of Larynx and Tracheobronchial Tree 235; Larynx 235; Tracheobronchial Tree 238

53. Physiology of the Larynx **240**

Phonation 240

54. Common Symptoms of Laryngeal Diseases **241**

Changes of Voice 241; Stridor and Dyspnea 241; Weak Cry 241; Cough 241; Dysphagia and Odynophagia 241

55. Examination of the Larynx **242**

External Palpation 242; Indirect Laryngoscopy 242; Direct Laryngoscopy 243; Stroboscopy 245; Radiography of the Larynx 245; Fiberoptic Laryngoscopy 245; Examination of the Larynx Under Microscope (Microlaryngoscopy) 246

56. Stridor **247**

Laryngomalacia 247; Acute Laryngotracheobronchitis 248; Acute Epiglottitis (Acute Obstructive Supraglottic Laryngitis) 249; Diphtheria 249

57. Acute Laryngitis **251**

Predisposing Factors 251; Pathology 251; Clinical Features 251; Treatment 251; Acute Laryngitis in Children 251

58. Chronic Laryngitis **253**

Pathology 253; Clinical Features 253; Reinke's Edema 253; Vocal Nodules 253; Vocal Cord Polyp 254; Contact Ulcer 254; Hyperkeratosis and Leukoplakia 255; Atrophic Laryngitis 255; Tuberculosis of the Larynx 255; Laryngeal Lupus 255

59. Laryngeal Trauma **256**

Pathology 256; Clinical Features 256; Treatment 256; Laryngeal Stenosis 256

60. Laryngocele **257**

Types 257; Symptoms 257

61. Edema of the Larynx **258**

Etiology 258; Angioneurotic Edema (Quincke's Edema) 258; Airway Obstruction in Children and Adults 259; Laryngeal Spasms 260

62. Foreign Body in the Larynx and Tracheobronchial Tree **261**

Foreign Bodies in the Larynx 261; Foreign Bodies in the Trachea 261; Foreign Bodies in the Bronchus 261

63. Laryngeal Paralysis **263**

Etiology of Laryngeal Paralysis 263; Laryngeal Paralysis in Association with other Cranial Nerve Dysfunction 264; Cricoarytenoid Joint Arthritis 265; Fixed and Paralyzed Cord 265

64. Tracheostomy **266**

Anatomical Relations of Trachea 266

65. Disorders of Voice **270**

Functional Aphonia 270; Dysphonia Plicae Ventricularis (Ventricular Band Voice) 270; Myasthenia of the Larynx (Phonasthenia) 270; Mogiphonia 270; Puberphonia (Mutational False to Voice) 270

66. Tumors of the Larynx **272**

Benign Tumors of the Larynx 272; Malignant Tumors of the Larynx 273; Partial CO_2 Laser Cordectomy 276; Total Cordectomy 276; Hemilaryngectomy 276; Extended Partial Laryngectomies 276; Organ Preservation Therapy 277; Alaryngeal Communication 277; Phonosurgery 277

67. Block Dissection of the Neck **282**

Radical Neck Dissection 282; Modified Radical Dissection 282; Selective Neck Dissection 282; Extended Radical Neck Dissection 282

68. Thyroid **285**

Saleh F AlDhahri

Enlargement of Thyroid Gland 285; Nodular Goiter 285; Retrosternal Goiter 285; Hashimoto's Thyroiditis 286; Thyroid Neoplasms 286; Treatment Policy 288

69. Bronchoscopy **289**

Indications 289; Contraindications for Bronchoscopy 289

70. Esophagus **291**

Surgical Anatomy 291; Investigations for an Esophageal Disease 291

71. Common Esophageal Diseases in ENT Practice **293**
Congenital Abnormalities of the Esophagus 293; Injuries to the Esophagus 293; Benign Strictures of the Esophagus 294; Esophagiectasia (Cardiospasm) 294; Foreign Bodies in the Upper Food Passages 295; Neoplasms of the Esophagus 296

72. Esophagoscopy **299**

73. Laser Surgery in ENT **300**
Khalid H Al-Qahtani
Principles of Laser Surgery 300; Advantages of Laser Use in Laryngeal Cancer Surgery 301

74. Principles of Radiotherapy **303**
Abdullah S AlAmro
Radiobiology 303

75. Chemotherapy for Head and Neck Cancer **308**
Roles in Management of Head and Neck Cancer 308; Chemo Agents Commonly Used 308

76. Syndromes in Otorhinolaryngology **309**
Syndrome in ENT 309

77. Otolaryngologic Concerns in the Syndromal Child **323**
Airway 323; Hearing Loss 323; Speech Disorders 324; Down Syndrome 324; Velocardiofacial Syndrome 324; Branchio-otorenal Syndrome 325; Treacher Collins Syndrome 326; Apert and Crouzon Syndromes 326; Pierre-Robin Sequence 327; Charge Association 327

78. Head and Neck Cancer Staging **329**
Rules of the AJCC-UICC System 329; Future of Staging Strengths of the Current System 331; Biologic Markers 331; The Future 331

79. Histopathology of Common Head and Neck Lesions **332**
Bilal A Raja
Thyroid Lesions 332; Ear Lesions 333; Salivary Gland Lesions 335; Laryngeal Lesions 337; Oral Lesions 338

80. Common ENT Instruments **339**

MCQs on Throat and Larynx **347**

Index *353*

Chapter

5

Examination of the Ear

Methods of Examination of the Ear

The auricle, external auditory canal and the postaural region are thoroughly inspected for the shape and size of the auricle, color changes in the skin, swelling, ulcer or a previous operative scar.

The lesions of the pinna may be congenital, traumatic, inflammatory or neoplastic. The infection to auricle or external canal may spread from scalp and the skin lesions may be eczematous. The auricle stands out prominently and the postauricular groove gets obliterated in furunculosis. The auricle is displaced downwards and outwards in mastoiditis with subperiosteal abscess.

The movements of the auricle and tragus are tender in otitis externa (furunculosis)—Tragus sign.

The mastoid region is examined for edema, abscess or postaural fistula as occurs in mastoiditis. Mastoid tenderness is elicited at the tip and at the cymba concha for the antrum which indicates an underlying infection. Edema at the site of exit of the mastoid emmissory vein (Griesinger's sign) occurs in lateral sinus thrombosis.

OTOSCOPY

The inside of the external auditory canal is examined conveniently using a head mirror, light source and an ear speculum. The examination may also be done by using a battery or electric otoscope. This gives some magnification and is useful in examining children and infants, and for bedside examination of patients, but any manipulation with an instrument while using the otoscope is impossible.

For a proper view of the inside of the canal, the pinna is gently pulled backwards and upwards in adults and downwards and outwards in infants to straighten the canal. A proper sized speculum is used to inspect the canal. Swelling due to a furuncle may be visible in the cartilaginous canal. Wax or debris may be filling the canal which is removed for deeper examination. Sagging of the posterosuperior canal wall occurs in mastoiditis.

The nature of ear discharge is noted and the discharge is cleaned by a cotton tipped applicator.

The ear canal is examined for edema, redness or granulations. A polypoidal mass may be seen in the canal due to chronic suppurative otitis media, glomus jugulare and malignancy. A deeper look into the canal shows the tympanic membrane or its remnants.

The tympanic membrane appears as a grayish white, translucent membrane set obliquely inside the canal. The important landmarks on the membrane are as follows:

1. The short process of the malleus appears as a small projection in the upper anterior part of the pars tensa. This landmark is least obliterated in disease.
2. The anterior and posterior malleolar folds radiate forwards and backwards from this projection separating the pars flaccida above from the pars tensa below.
3. The short process is followed down to note the handle of the malleus which is directed downwards and backwards, ending at the umbo.
4. From the umbo a cone of light is seen radiating anteroinferiorly.
5. Sometimes the long process of the incus may be seen through the posterior part of the pars tensa, below the posterior malleolar fold.

The pars tensa of the membrane is arbitrarily divided into four quadrants by two imaginary lines. A vertical line passes down along the handle of malleus and a horizontal line intersects it at the umbo, dividing the pars tensa into anterosuperior, anteroinferior, posteroinferior and posterosuperior quadrants. Abnormalities of the membrane are noted with respect to the quadrant involved.

1. *Integrity:* The membrane may be intact or perforated. The site of perforation and its shape are noted. A perforation of the pars tensa may be central or marginal. A central perforation may be small or large, but the intact rim of membrane is seen around the margins of the perforation. A perforation is called marginal if no rim or annulus is seen around or on side of the margin of the perforation.

JAYPEE BROTHERS

A marginal perforation is an indication of an unsafe disease. A perforation in the pars flaccida or attic perforation indicates an underlying cholesteatoma.

2. *Color changes in the tympanic membrane:* The tympanic membrane normally appears as a grayish white membrane. A congested membrane with prominent blood vessels is seen in the early stage of acute otitis media while a dull lustreless membrane is seen in secretory otitis media. A blue discoloration of the membrane occurs in hemotympanum and the flamingo pink reflex is seen in otosclerosis (Schwartze's sign).
3. *Position of the membrane:* Normally the position of the membrane is maintained by the pressure of air column on its either side. A bulging congested drum is seen in exudative stage of acute otitis media. A retracted membrane may occur in aero-otitis, serous otitis media, and adhesive otitis media. The retracted membrane appears dull, lustreless, with absent or distorted cone of light and has a reduced mobility. The handle of the malleus appears more horizontal and the short process more prominent.
4. *Mobility of the membrane:* The mobility of the membrane is tested by the Valsalva's method and by siegalization. The hypermobile areas of the membrane indicate scarring of the membrane. Restricted mobility is due to adhesive otitis media or fluid in the middle ear cavity.

EXAMINATION WITH SIEGEL'S SPECULUM

This speculum consists of a 10 diopter lens and a side tube connected with a rubber bulb. An air tight system is produced in the canal and pressure is increased in the bulb. The speculum is helpful for the following reasons.

1. It gives a magnified view of the membrane.
2. It is helpful to assess the mobility of the membrane.
3. The speculum is used to elicit the fistula sign.
4. By varying the pressure, discharge through the perforation can be sucked out as well as medication can be put into the middle ear.



Fig. 5.1: Examination under the microscope

EXAMINATION UNDER MICROSCOPE

For better and detailed examination of the middle ear cleft, examination under a microscope is of great help to the otologist (**Fig. 5.1**). It is done as an OPD procedure.

Examination of Ear with an Operating Microscope

In modern otological clinics a microscope is essential to inspect all quadrants of the drum adequately. Pus and debris may be aspirated and disease in the attic, margin or center of the tympanic membrane confirmed (**Fig. 5.2**).

Evaluation of Ear Disease

FISTULA TEST

Erosion of the bony part of the vestibule (usually the lateral semicircular canal) by trauma or by an ear disease exposes the membranous labyrinth to the external pressure changes. If the labyrinth is functioning, its stimulation will lead to a subjective feeling of vertigo and vomiting and may be associated with nystagmus. The presence of the erosion (fistula) can be demonstrated by the following ways:

1. Alternately compressing and releasing the tragus against the external meatus. This alters the pressure in the canal and stimulates the labyrinth.
2. By moving the polyp or granulations in the ear by a cotton tipped applicator.
3. By increasing and decreasing the pressure in the canal with a Siegel's speculum.

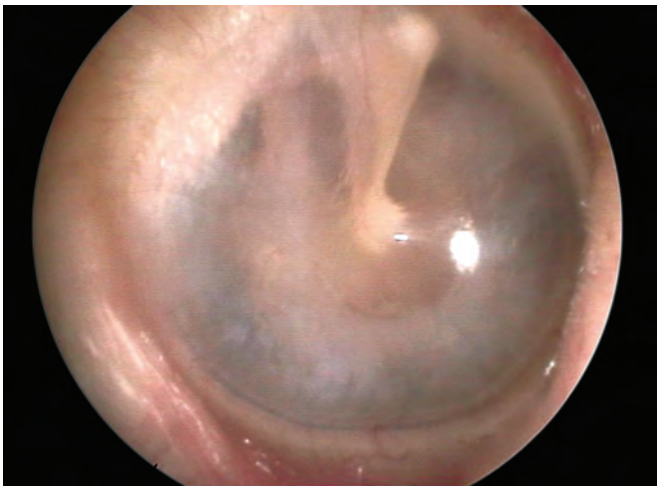

Fig. 5.2: Otoscopic view of normal tympanic membrane

JAYPEE BROTHERS

The subjective feeling of giddiness, nausea or vomiting with or without nystagmus indicates a *positive fistula sign* which indicates that there is a fistula in the labyrinth, and that the labyrinth is still functioning.

The fistula sign may be false-negative or false-positive.

False-negative fistula sign: This means that there is a fistula in the labyrinth but the fistula test is negative. This occurs in a dead labyrinth.

False-positive fistula sign: This means that there is no fistula in the labyrinth but the fistula test is positive. This occurs in congenital syphilis due to the deformed hypermobile footplate and is called Hennebert's sign. It may also occur after stapedectomy.

EUSTACHIAN TUBE PATENCY

The patency of the eustachian tube can be demonstrated by various tests. However, a patent eustachian tube is not necessarily an index of normal function of the tube.

The nasopharynx is examined by a posterior rhinoscopy or by a nasopharyngoscope.

Valsalva's Test

The patient is asked to close the mouth and pinch the nostrils and then to blow out, thus increasing the pressure in the nasopharynx. This opens up the eustachian tube and allows air to pass into the middle ear cavity. The outward movement of the tympanic membrane is seen through the ear speculum. The test is useful to know the mobility of the membrane as well as the patency of the eustachian tube. This test may normally be negative.

Politzerization

The tip of the nozzle of the Politzer's rubber bag is placed in one nostril and the other nostril closed over it by fingers. The patient is given some water to swallow. At the movement of swallowing, the air in the bag is compressed. The air thus enters the eustachian tube as it opens up on swallowing. The outward movement of the tympanic membrane indicates a patent eustachian tube.

Eustachian Catheterization

An eustachian catheter of a proper size is passed through the nose into nasopharynx. The tip of the catheter is turned into the eustachian orifice and air is blown down the catheter into the eustachian tube. The movement of the tympanic membrane is observed through the canal or the passage of the air through the tube is heard by an auscultation tube, one end of which is placed in the patient's ear and the other end in the examiner's ear. The sound heard by the examiner indicates the passage of air through the eustachian tube.

Method

The nasal cavity is anesthetized by the local use of 4 percent lignocaine spray, the eustachian catheter is passed along the floor of the nasal cavity without touching it, the tip of catheter pointing downwards till the catheter reaches the posterior wall of nasopharynx. The catheter is brought forwards gently till the tip hooks against the posterior edge of the soft palate. Now the tip of catheter is rotated by 90° outwards which approximates it with the pharyngeal end of the eustachian tube. The ring on the proximal end of the catheter indicates the direction of the tip of the catheter. A Politzer's bag nozzle is attached to the proximal end of catheter and is squeezed to allow the air to be blown into the eustachian tube through the catheter. If the tip of the catheter is rotated through 180° towards the other side of the nasopharynx the patency of the eustachian tube of the other side can be assessed. After the process is over, the catheter is brought back to the position as it was passed into the nasal cavity and withdrawn gradually from the nasal cavity without touching its sides and floor.

Functional Examination of Ear

The tests of hearing are intended to measure the ability to hear sounds (quantitative) and to test and compare the efficiency of the conductive and perceptive parts of the auditory apparatus (qualitative).

Qualitative testing is done by tuning forks and pure tone audiometer and quantitative by speech (live or recorded) and pure tone audiometer.

All tests should be carried out in a quiet room. In quiet places, normal distance at which speech of conversational level can be heard is about 20 feet, whereas the whispered voice (using residual air) should be understood at 12 feet. But most rooms do not allow more than a 12 feet range, so it is customary to consider 12 feet for both speech and whisper as the normal standard.

VOCAL INDEX

It is the relation between hearing loss for speech and whispered voice.

In conductive deafness the index is small and there is little difference between the two.

In perceptive deafness in which loss is mainly confined to high tones, there may be considerable discrepancy between the hearing for speech and whisper, so the vocal index is high.

THRESHOLD FOR SPEECH

In a person with normal hearing this threshold is zero but in a person with moderate degree of hearing loss it may be 40-45 dB.

SPEECH AUDIOMETER

A trained speaker speaks into a microphone certain words which are transmitted to the listener through a pair of head

JAYPEE BROTHERS

phones. Adjustments are made on the attenuator, which is so adjusted that when the dial is at zero at least 50 percent of the test material is heard.

PURE TONE AUDIOMETER

It is used to determine the threshold of hearing for pure tones within a selected band of frequencies. The tones are electrically produced and can be varied both in frequency and intensity. The range of frequencies available may be fixed at octave or half octave intervals between 64 and 8,192 cycles/sec (if Helmoltz scale is used) or there may be continued sweep between 0 and 10,000 cycles/sec.

Intensity can be varied, usually in 5 dB steps from 0 to 100 dB and the intensity dial is so calibrated that at zero for each selected frequency a person with normal hearing can just hear the test tone.

As sound at a level of 60 dB or more can be heard in the untested ear, it is advisable to use a masking apparatus. Masking is essential when there is considerable difference in the hearing acuity between the two ears, and when testing by bone conduction to get correct results.

The value of the pure tone audiometer test depends upon the following:

i. Accuracy of the audiometer.
ii. The way in which the test is carried out.
iii. Intelligence of the patient.

Each ear should be tested separately for all frequencies (usually 7) with masking of untested ear when necessary. For bone conduction, masking of the untested ear is essential. Only four tones are tested (256-2,048 cycles/sec).

The various hearing tests are described below.

VOICE TESTS

Speech tests though less accurate are simple and easily understandable to the patient. The conversational and whispered voice tests are conducted in reasonably quiet surroundings. The material for speech tests may be spondee words or numbers. Spondee words are bisyllabic words having an equal stress on both syllables like arm-chair, toothbrush, mousetrap, cough-drop, etc. Whispered voice is used at the end of normal expiration and is thus easily standardized than conversational voice.

Method: Each ear is tested separately. The other ear being masked by the finger on tragus or rubbing the nontest ear with a piece of paper. The distance at which the patient can hear the conversational and whisper voice in a reasonably quiet surrounding are noted. The distance is reduced for whisper voice in high frequency loss than for conversational voice. In conductive deafness there is little difference in distance at which each can be heard.

TUNING FORK TESTS

Tuning forks provide a simple, easy and reliable method of testing the hearing. A set of 256, 512, 1024, double vibration forks is commonly used. The following tests are commonly in use:

i. Rinne's test
ii. Weber's test
iii. Absolute bone conduction test.

Rinne's Test

The fork is struck gently on the elbow, knee cap, hypothenar eminence or a rubber pad and held in such a way so that the prongs vibrate against the ear in line with the external canal at a distance of about 1 inch (**Fig. 5.3**). The air conduction of the sound is compared with bone conduction. To test the bone conduction, the foot piece of the fork is placed on the mastoid. The patient is asked to indicate which of the two is louder or where he hears for the longer time.

Interpretation

1. Normally air conduction is better than bone conduction, which is called Rinne's positive. In patients with sensorineural deafness, both air and bone conduction of sound are diminished but air conduction is still better than bone conduction. This is called Reduced Rinne's positive.
2. Rinne's negative means that bone conduction of the sound is better than air conduction and signifies conductive deafness.
3. Sometimes air conduction of sound equals bone conduction and indicates mild conductive deafness.
4. At times, the test may be false-negative. A patient with severe unilateral sensorineural loss may indicate that he hears the bone conducted sound in the affected ear (test ear) with poor or no response to the air conduction, therefore, indicating negative Rinne's test. But in reality, this is false as he is hearing this bone conducted sound



Fig. 5.3: Rinne's test

JAYPEE BROTHERS

across the skull through the normal ear. In these cases, the test is repeated by masking the normal ear while testing the affected ear. Barany's noise box can be used for masking the ear.

The results of the Rinne's test are given in **Table 5.1**.

Weber's Test

A vibrating tuning fork is held either on the vertex, root of nose or on the upper incisor teeth (**Fig. 5.4**). The patient may hear the sound equally on both the sides, in the center of the head, or the sound may be lateralized to one side.

Interpretation

1. When the sound is heard in the center of the head or equally on both sides it is called Weber's centralized and is found in normal persons or may occur in patients having bilateral, symmetrical conductive hearing loss.
2. If the sound is heard louder on one side than the other, then it is called Weber's lateralized to that particular side. Weber's test gets lateralized to the deaf ear in conductive deafness and towards the normal ear in sensorineural deafness.

Absolute Bone Conduction (ABC) Test

This compares the absolute bone conduction of the patient with that of the examiner. The hearing of the examiner is considered to be normal. The vibrating fork is held on the mastoid of the patient, closing the external meatus firmly with the tragus, the patient is asked to signal when he no longer hears the sound (**Fig. 5.5**). The fork is then transferred by the examiner to his own mastoid closing the external meatus. The absolute bone conduction of the patient is thus compared with that of the examiner.

Interpretation

1. If the examiner still hears the vibration of the fork, when the patient has stopped hearing it, then the absolute bone conduction of the patient is said to be reduced. This is found in perceptive deafness.
2. If the examiner also does not hear the sound of the fork when the patient has stopped hearing it, then absolute bone conduction is regarded as normal.
3. The test is absolute and thus it cannot get prolonged.



Fig. 5.4: Weber's test



Fig. 5.5: Absolute bone conduction test

Table 5.1: Results of Rinne's test

Tuning for results	Nomenclature	Interpretation
1. AC > BC	R+	Normal
2. AC > BC (both reduced)	R+ (reduced)	Perceptive deafness
3. AC = BC	R=	Slight conductive deafness
4. AC only, No BC	R+ infinitely	Severe perceptive deafness
5. BC > AC	R–	Conductive deafness
6. BC only, other ear masked	R– infinitely	Very severe conductive deafness
7. BC only, other ear left Unmasked	R–(False) False negative Rinne	Very severe or total perceptive deafness

JAYPEE BROTHERS

Schwaback's Test

The test is performed to determine the state of bone conduction in presence of air conduction. This test is conducted like the absolute bone conduction test but without occluding the external auditory canal.

Radiological Examination of the Ear

Plain X-rays of the temporal bone help in determining the extent of middle ear and mastoid disease, the condition of the ossicles and the extent of pneumatization. The following views are of common use (**Figs 5.6A to D**):

Towne's view: The patient's head lies in contact with the film and the direction of the beam is 25-35° fronto-occipital (**Figs 5.7 and 5.8**).

It demonstrates both the mastoids on same film providing a contrast with the normal side. The following points are noted:

i. Degree of pneumatization or sclerosis.
ii. Mastoid antrum and air cells.
iii. Semicircular canals (superior and lateral) may appear in the film.
iv. Internal auditory meatus.
v. Ossicles like malleus and incus.

Haziness or destruction of bony partitions, cavity formation or erosion should be noted and compared with the other side.

Lateral oblique view: The patient's head is placed in a lateral position. The ray is directed 30-35° caudally. Each side is taken separately. It is useful in providing information regarding the following:

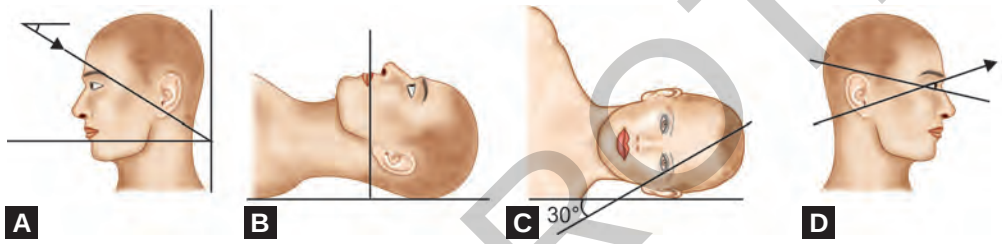

Figs 5.6A to D: Different view of X-ray for diseases of the ear: (A) Towne's (Fronto-occipital); (B) Submento-vertical view; (C) Stockholm-B view (Lateral-oblique); (D) Stenvers view (Oblique-posterior anterior)



Fig. 5.7: Towne's view

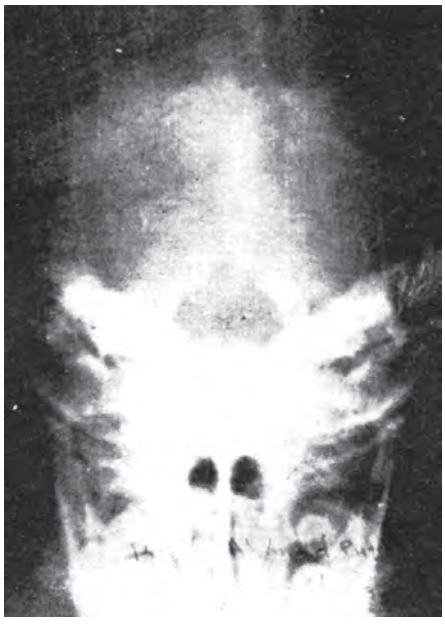

Fig. 5.8: X-ray of the skull, Towne's view showing sclerotic mastoids with bilateral cavities (cholesteatoma)

JAYPEE BROTHERS

i. Relationship of the sinus plate to the air cells and thus helps in determination of the posterior extent of the pneumatization.
ii. Superiorly the dural plate, the floor of the middle fossa is visible.
iii. Aditus, attic and antrum are demonstrated.

The external auditory canal and tympanic cavity are obscured by the bony labyrinth.

Stenver's projection: This is an oblique view of the skull, taken separately for each side at an angle of 12.5°. The view is taken mainly to demonstrate following structures:

i. The upper border of petrous bone
ii. The internal auditory meatus
iii. The superior semicircular canal
iv. Ossicles like malleus and incus.

Transorbital view of the petrous apex: This view demonstrates both petrosa on the same film and is commonly taken to visualize the internal auditory meati. A difference of 1 mm or more is significant.

Owen's projection: This is an oblique view which demonstrates the attic, aditus, and antrum. The ossicles are shown clearly within the external auditory canal.

X-ray base of the skull: The submentovertical view may be required to study the mastoids, auditory canals, petrousapex, bony eustachian tube and carotid canal.

CT SCAN

Computerized axial tomography (CAT) is the most accurate noninvasive neurodiagnostic test available. This test was invented by Hounsfield who received the Nobel prize for physics in 1979. The scanner has a diagnostic accuracy of 98 percent and the great advantage is that it is noninvasive and the radiation involved is only one-third of the dose for a single lateral skull radiograph.

The CAT scanner is capable of producing pictures in a wider range of densities than the conventional X-ray procedures. It clearly pin-points pathology like tumors, intracranial bleeding, infarcts, cysts, abscesses, hydrocephalus, aneurysms and various eye and ear, nose, throat (ENT) lesions. Vascular structures can also be seen following the injection of an iodized contrast material in the patient.

Advantages of CT Scanning

1. It provides a speedy and accurate diagnosis.
2. Pin-pointing of the pathological spots facilitates in accurate surgery.
3. It eliminates the need for painful and risky investigations and exploratory surgery.

Contrast Radiography

Radiographic examination after instillation of a radio-opaque dye may be done for eustachian salpingography and to demonstrate the lesions of the internal auditory meatus.

The dye may be put either through the nasopharyngeal orifice of the tube to demonstrate the block in the tube or alternatively, it may be injected into the middle ear through a tympanic membrane perforation if it is present, or a fine needle is used to put the dye into the middle ear.

Dye injected into the middle ear determines the patency of the tube as well as helps in assessing eustachian tube function by tympanic cavity clearance study.

In 8th nerve tumors the internal auditory meatus study is done by injecting the contrast material through a cisternal puncture.

Nuclear Magnetic Resonance

Nuclear magnetic resonance (NMR) or magnetic resonance imaging (MRI) is now used in advanced centers as a noninvasive scanning procedure and is superior to CT scan in some ways. It is based on the magnetic processes of the atomic nuclei. The nuclei are aligned in a strong magnetic field and a radiofrequency pulse applied. After this pulse is removed, the nuclei return to their original orientation emitting a radiofrequency signal. The image is created by specially encoding the emitted radiofrequency signal.

ADVANTAGES OF MRI

1. It is a noninvasive procedure and is safe even when used repeatedly and even in pregnancy.
2. The sagittal, coronal and even oblique sections can be taken to find the exact extent and location of the tumor.
3. Fractures are better visualized.
4. Tumors are better differentiated from muscles and blood vessels than by CT scanning.
5. Arteries and veins can be differentiated.

DISADVANTAGES OF MRI

1. The cost is very high and thus a limitation.
2. Small calcifications may be missed.
3. There is lack of bone details.
4. Patients with any metallic foreign body, e.g. pacemakers, metallic prosthesis, aneurysm clips cannot be imaged and these may have to be removed, as they may sometimes act as sharp, lethal missiles.

Examination of the Vestibular Apparatus

While examining the vestibular system a detailed neurological check-up including that of the cranial nerves is done for proper assessment of the lesion.

JAYPEE BROTHERS

CRANIAL NERVES

The 5th cranial nerve is tested by eliciting the corneal reflex. The cornea is touched with a cotton wisp and normal brisk closure of the eyes occurs. This reflex may be diminished or absent in cerebellopontine angle tumors.

The 7th cranial nerve is frequently involved by the cholesteatoma, malignancy of ear or acoustic neuroma and is tested to determine the site of lesion.

NYSTAGMUS

Nystagmus is the rhythmic oscillatory movement of the eyes and has two components, slow and quick.

Nystagmus can be of the following types:

1. Central, with other signs of intracranial disease.
2. Ocular, with signs of ocular disease.
3. Vestibular, with vertigo and some loss of hearing.

It can also be classified as follows:

First degree nystagmus: Present only when patient looks in the direction of the quick component.

Second degree nystagmus: Also present when the patient looks straight in front.

Third degree nystagmus: If still present when the patient looks in the direction of the slow component.

Under anesthesia, the quick component is eliminated and only the slow or vestibular movement takes place and results in conjugate deviation.

In labyrinthine nystagmus there is a slow component of vestibular origin and a quick component which is of cerebral origin. Each labyrinth tries to deviate the eyes slowly to the opposite side due to its tonic activity and thus normally the effect is neutralized so that the eyes remain in midline. When one utricle is stimulated due to disease or caloric stimulation, the eyes get deviated slowly to the opposite side. When the cerebral cortex becomes aware of this deviation, it brings in effect the correcting reflex, thus bringing the eyes quickly back to the original position. The reverse occurs when the labyrinth is hypoactive or dead, i.e. the quick component to the opposite side and slow component to the affected side.

The vestibular nystagmus is fine, always horizontal and does not last for more than six weeks.

Central nystagmus (due to involvement of the central connections) may be horizontal, vertical or rotatory, is coarse and lasts for a longer time.

How to look for nystagmus: The patient is placed in good light and the examiner faces the patient. The patient's head is kept steady and he is asked to follow the direction of the finger tip of the examiner, which is moved across the field of vision in various directions. The jerking of eyes appears at the extreme range of vision in normal individuals and should not be mistaken for labyrinthine nystagmus.

If the labyrinth is irritated on one side, spontaneous nystagmus occurs towards that side and when the labyrinth is destroyed, the nystagmus occurs towards the opposite side.

The function of the vestibular system may be evaluated by stimulating the labyrinth and noting the change in its response. Induced nystagmus may be produced by the following tests:

i. Caloric test
ii. Rotation test
iii. Optokinetic test.

The Caloric Test

In this test the labyrinth is stimulated by the changes in temperature. This is done by irrigating the external auditory canal with hot and cold water.

Commonly the lateral semicircular canal is tested. The patient lies supine on the table. The head end of the table is inclined 30° forwards. This is done because the anterior end of the horizontal semicircular canal is about 30° higher than its posterior end. In this position, the horizontal canal thus assumes a vertical plane for easy stimulation.

Cold caloric test: About 5 cc of ice cold water is injected into the external auditory canal. This cools down the surrounding bone and the temperature variation is transmitted to the labyrinth. Convection currents are set-up in the endolymph and thus the labyrinth is stimulated. Nystagmus occurs and its duration nystagmus is compared on both sides. Normally the nystagmus persists for about two minutes. This is a simple test but is less informative.

Bithermal caloric test (differential caloric test) or Fitzgerald and Hallpike test: This test is done by irrigating the external auditory canal with water having a temperature 7° above body temperature (44°C) and 7° below body temperature (30°C). The canal is irrigated by the water at these temperatures for 40 seconds.

The onset and duration of the nystagmus with each stimulation is graphically recorded (calorigram—**Figs 5.9A to D**). An interval of about 5 minutes should be allowed between the tests. Cold stimulation produces nystagmus towards the opposite side and hot stimulation produces nystagmus towards the same side. The duration of nystagmus is measured on both sides. If nystagmus persists for less than the average time, it is called canal paresis (hypoactive). Sometimes caloric responses are enhanced in one particular direction (directional preponderance). This is due to the loss of tonus elements and commonly occurs towards the normal ear.

Nystagmus may be observed unaided or with the help of Frenzel's glasses worn by the patient to prevent optic fixation and provide magnification of the eye movements. Thus low intensity nystagmus, which may not be visible to the naked eye, becomes obvious.

JAYPEE BROTHERS

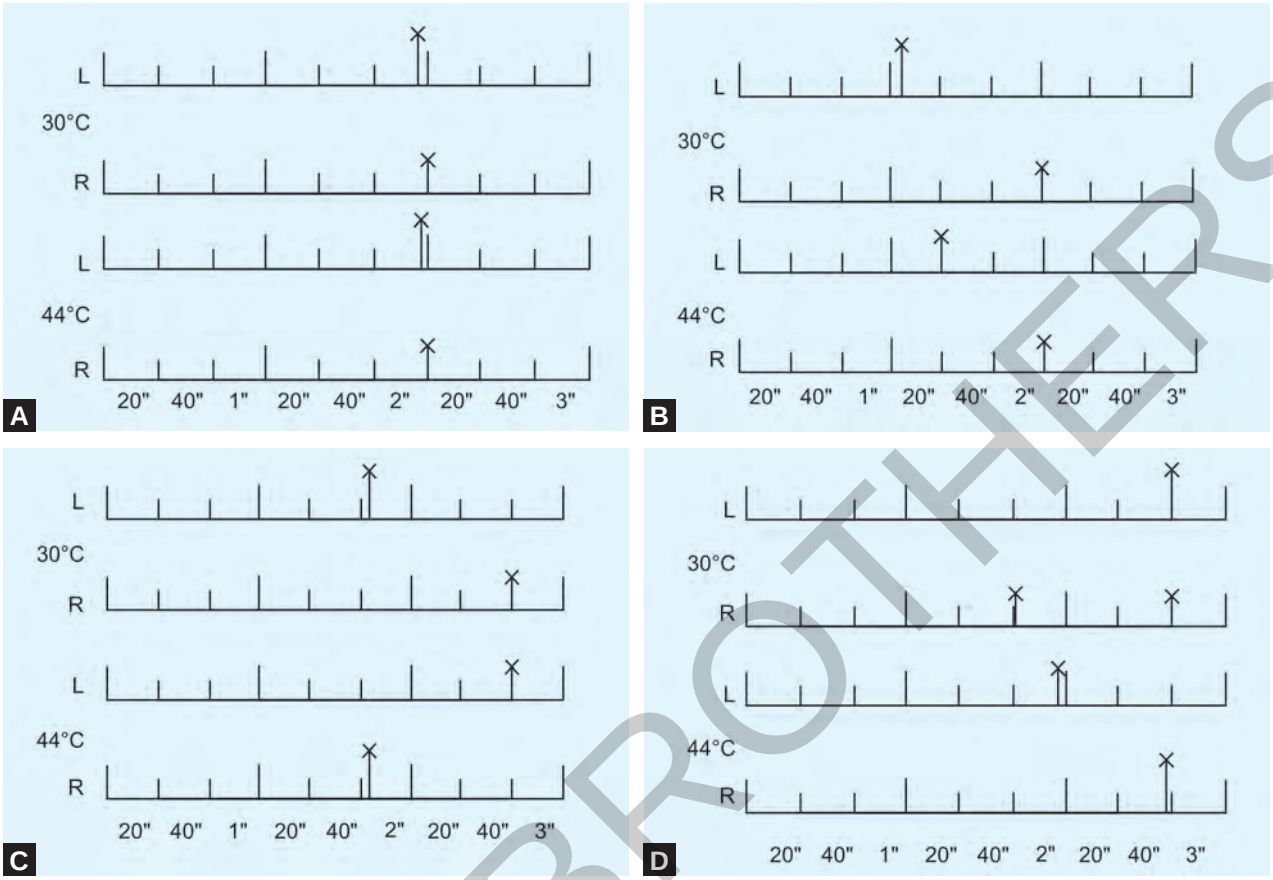

Figs 5.9A to D: Calorigram: (A) Normal; (B) Left canal paresis; (C) Left directional preponderance; (D) Right directional preponderance

Caloric test with Dundas-Grant apparatus: In patients with perforation of the tympanic membrane water cannot be injected into the external canal. In such patients the Dundas-Grant metallic coil is used. Ethyl chloride is sprayed over the coil and air is passed by pressing the attached rubber bulb. As the air passes through the coil, it gets cooled and enters the ear, thus producing cold caloric responses in the ear.

Rotation Test

The patient is placed on a revolving Barany's chair which is rotated at the rate of ten revolutions per second. The chair is then suddenly stopped and the postrotational nystagmus noted. Both labyrinths are stimulated at the same time, hence, the test is not of much significance.

Optokinetic Test

A white rotating drum with black vertical lines is used. The drum rotates on a horizontal plane. The patient is seated at a distance of 3 feet from the drum. The drum rotates to one side and then to the other. The patient follows the vertical lines on the drum to either side. The drum is stopped and eyes are examined for nystagmus. A normal person has nystagmus of both sides. In central vestibular lesions, the nystagmus of one side is suppressed.

ELECTRONYSTAGMOGRAPHY

It is an extremely useful method for recording the eye movements. The apparatus is shown in **Figure 5.10**. The corneoretinal potential method utilizes the electric potential between the cornea and retina. An electric field exists between the cornea (electrically-positive) and the retina (electrically-negative). Electronystagmography (ENG) detects movements of these electric fields and records them onto a continuous tracing. The electrodes are placed lateral to each eye and on the forehead between the eyes. The main advantage of ENG is that some patients reveal nystagmus which is not readily visible on naked eye examination. ENG recordings also allow for quantification and the provision of a permanent record of the nystagmus (**Fig. 5.11**). Characteristic tracings are seen in peripheral and central vestibular disorders, congenital nystagmus and cerebellar disorders. This technique allows the recording of nystagmus with the eyes closed or open. It provides a base line

JAYPEE BROTHERS



Fig. 5.10: Three-channel electronystagmograph machine

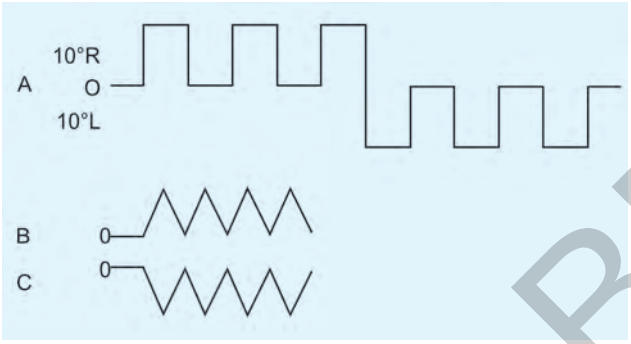

Fig. 5.11: Typical electronystagmographic records: (A) Calibration record; (B) Nystagmus towards right; (C) Nystagmus towards left

record and subsequent changes are compared with this tracing. It also allows the evaluation of other parameters of nystagmus in terms of duration, intensity, velocity and latency of onset.

The special advantage of electronystagmography in determining the qualitative and quantitative changes of nystagmus is made use of in the following tests as well:

1. *Rotation tests:* Rotation activity is grossly diminished by ototoxic drugs like streptomycin, neomycin, etc. when frequency and amplitude of nystagmus are both affected, while gross asymmetry of the reaction is seen in vestibular neuronitis. Normal frequency but reduced amplitude on the rotation testing is seen in Ménière's disease.
2. *Optokinetic tests:* Marked asymmetry of nystagmus on optokinetic tests usually suggests a central lesion of the vestibulo-optic system.
3. *Eye tracking tests:* In this test eye movements in response to a visual pendular simulus are recorded which normally produces a sinusoidal curve. A nonsinusoidal curve is always due to central lesions while sinusoidal with superimposed nystagmic movements can occur in peripheral lesions.

Positional Test

Positional nystagmus can be induced by placing the patient's head in different positions. The procedure is explained to the patient.

Nystagmus is looked for after asking the patient to lie down and sit up with the head turned 90° to the right, to the left and backwards. The patient is taken backwards for about 10 seconds, if the nystagmus appears, the position is maintained for 30 seconds. Observation is made concerning the latent period, direction, duration and fatiguability. Fine, horizontal, fatiguable nystagmus occurs in vestibular lesions and benign positional vertigo. Rotatory or horizontorotatory nystagmus which is nonfatiguable is seen in central lesions.

Romberg's test

This test is conducted by asking the patient to stand upright with the heels together. The patient may be asked to close the eyes. The patient falls towards the direction of the slow component of peripheral labyrinthine nystagmus. In case of the central lesion the patient swings or fall towards the direction of the quick component.

Past Pointing

The patient has a sensation of objects turning away from him which, he voluntarily attempts to compensate by touching a fixed object. This effect is due to presence of vertigo.

Cupulometry

It is a rotation test to assess the vestibular function by utilizing minimal stimuli. It was devised by Jongkees and coworkers in 1952. A special turning chair is used in which the patient sits with his feet free of the floor and his head immediately above the axis of his rotation in the upright position, inclined 30° forwards to bring the two lateral semicircular canals in the horizontal plane.

Subthreshold acceleration is given to the turning chair and maintained till every reaction has ceased. It is then suddenly stopped. This is repeated at different velocities. The duration of after-sensation and after-nystagmus are recorded on a logarithm scale. The record is called cupulogram.

The test is based on the fact that the cupulae of the semicircular canals respond to the angular acceleration, i.e. the increasing speed of rotation. Angular acceleration which when maintained for 20 sec is sufficient to evoke a just recordable nystagmus is known as threshold. Normal threshold for nystagmus without optic fixation is 0.15°/sec^2 and with optic fixation, it is 1°/sec^2.

JAYPEE BROTHERS

Craniocorpography

Craniocorpography provides a rapid graphical recording of the combined results of the Romberg and the Unterberger tests for the pathological discrimination of the spinal vestibular system. The basis of craniocorpography is the Unterberger test, established as the most sensitive method for accurate clinical studies of the spinal vestibular system. Unterberger gave special consideration to the rotation of the human body in the slow phase of the nystagmus after a caloric stimulation.

In the craniocorpograph test, which does not last more than sixty seconds, the patient remains with his eyes closed and walks on the spot for 80 to 100 steps. The craniocorpograph test considers walking deviation and lateral balance of the patient and provides more explicit information allowing better discrimination between central and vestibular peripheric perturbations or a combination of both.

Rapidity of the craniocorpograph test makes it useful for group screening, examination of children, industrial medical checkups, legal medicine, driving test, etc.

JAYPEE BROTHERS

Textbook of
EAR, NOSE & THROAT DISEASES

Salient Features

- Thoroughly revised and updated edition
- A complete inclusion of all the aspects of ENT disease
- Five new chapters are added
- Multiple Choice Questions (MCQs) are given at the end of each section
- A comprehensive guide for the undergraduates and a quick reference guide for postgraduates and general practitioners.



Mohammad Maqbool MBBS DLO MS FICS completed his MBBS in 1958 from Mahatma Gandhi Memorial (MGM) Medical College, Indore, Madhya Pradesh, India, and did his residency first in Eye and ENT, and then in General Surgery till 1960. In 1965, he completed his Diploma in Otorhinolaryngology (DLO), and in 1967, he completed his MS in ENT from King George's Medical College, Lucknow, Uttar Pradesh, India, with merit. In 1969, he attained his Diploma in Medical Audiology (DMA) from Christian Medical College, Vellore, Tamil Nadu, India. He joined the ENT Department of Government Medical College, Srinagar, Jammu and Kashmir, India, as an Assistant Professor, where he worked zealously to make the department an independent and full-fledged postgraduate department, and, thereafter, he established the first Hearing and Speech Center and Neurotology Clinic in Shri Maharaja Hari Singh (SMHS) Hospital, Srinagar, Jammu and Kashmir, India, in 1970.

In 1973, he received his Fellowship of the International College of Surgeons (FICS), and was promoted to the post of Professor and Head, Department of ENT, while also working as Chief Consultant of Otorhinolaryngology and Chief of Speech and Hearing Rehabilitation Center to Government Medical College and associated hospitals. In 1975, he was awarded the WHO Fellowship after visiting London, USA and Canada.

He is the author of *Textbook of Ear, Nose and Throat Diseases, Multiple Choice Question Booklet for Otorhinolaryngology, Booklet on Syndromes in Otorhinolaryngology*. He has published over sixty-five papers in many reputed foreign and Indian medical journals, and pamphlets in various languages on guidance to parents and teachers as to how one must treat deaf, mute, and hard of hearing children.

Dr Maqbool has been awarded with honors—Best Thesis Award by University of Lucknow (1966); Visiting Fellowship by Indian Council of Medical Research, New Delhi, India (1969 and again in 1970); WHO Fellowship (1975); Best Teacher Award by Medical Fraternity of Government Medical College, Srinagar, Jammu and Kashmir, India (2000); Teacher of the Millennium, University of Kashmir, Jammu and Kashmir, India (2000); Award of Appreciation North-West Zone by Association of Otorhinolaryngologists of India (2004); and Real Hero Award in Health and Disability Category by CNN-IBN/Reliance Industries Limited (2011).



Suhail Maqbool MBBS MS completed his MBBS from Government Medical College, Srinagar, Jammu and Kashmir, India, in 1985. He has had a distinguished undergraduate career, obtaining gold and silver medals in academics. He completed his Masters in ENT surgery from Postgraduate Institute of Medical Education and Research, Chandigarh, India, in 1990. He worked as Registrar in Shri Maharaja Hari Singh (SMHS) Hospital and moved to Kingdom of Saudi Arabia in 1994. He worked in the King Saud University Hospitals till 2006. He then joined the King Fahad Medical City, Riyadh, Kingdom of Saudi Arabia, as an Assistant Consultant and is also associated with the King Saud University for Health Sciences as a tutor-guide for undergraduate otorhinolaryngology teaching. He has published 26 case reports and 15 papers in various international journals and is currently involved in three prospective studies aimed at im proving the outcome of patients following Neck, Thyroid and Ear Surgery.

Shelving
Recommendation
OTORHINOLARYNGOLOGY

ISBN 978-93-5090-495-4

9 789350 904954

Available at all medical book stores
or buy directly from Jaypee Brothers through online shopping
at www.jaypeebrothers.com

JAYPEE BROTHERS
Medical Publishers (P) Ltd.
www.jaypeebrothers.com