SINGLE PORT LAPAROSCOPIC SURGERY IN GYNECOLOGY





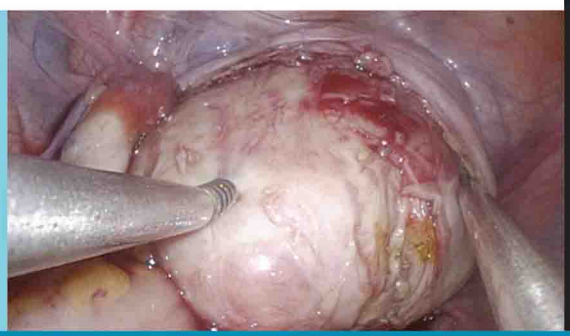



INCLUDES INTERACTIVE DVD-ROMs

B Ramesh
Madhuri Vidyashankar
Pooja Sharma Dimri

Foreword
Paul PG

JAYPEE

Contents

Section 1: Basic Principles, Instruments and Techniques

Chapter 1. Evolution of Laparoendoscopic Single-Site Surgery in Gynecology 3

Single-Incision Laparoscopic Tubal Ligation 3

Evolution 4
Hysterectomy, Supracervical Hysterectomy with Adnexectomy 4; Adnexal Procedures 4; Other Procedures 4

Nomenclature 5
Lesscar Terminology 5; Technical Clinical Issues 6; Skills Training 6; Web-Based Secure Database Registry 6; Collaboration with Other Surgical Societies 6

Chapter 2. Indications of Laparoendoscopic Single-Site Surgery 9

Indications of Laparoendoscopic Single-Site Surgery in Gynecology 9

Contraindications of Laparoendoscopic Single-Site Surgery in Gynecology 10

Chapter 3. Abdominal Access in LESS 11

Umbilicus—The Site of Entry 11
Use of Operative Laparoscope in Single-Port Laparoscopy 11; The Single-Incision but Multi-Port Technique (Curcillo and King Technique) 12; Use of a Specialized Multichannel Access Device 14

Operative Procedure: Access in LESS 14
Entry 14; Important Considerations 14; Closure 16

Chapter 4. Instruments and Ports 19

Access Ports 19

TriPort and QuadPort Access System 19
Component Parts 19; Deployment 19; Advantages 20; Drawbacks of TriPort and QuadPort Devices 20; QuadPort 20

X-Cone 20

GelPort and GelPoint System 22
Component Parts 22; Deployment 22

SILS Port 23
Advantages 23; Drawbacks 23

SSL Port 23
Advantages 24

TransEnterix Spider 25
Component Parts 25

Wound Retractor and Glove 25
Deployment 25; Advantages of Glove and Wound Retractor 25; Disadvantages 26

Instruments 27

Use of Various Instruments in LESS 27
Standard (Straight) Laparoscopic Instruments 27; Use of 1.9 mm Needle Instruments 27; Curved Instruments 28; Wristed Instruments (Articulated) 28; Instruments for Hemostasis 30

Future Trends—'Smart Instruments' 31

Chapter 5. Optics for Laparoendoscopic Single-Site Surgery 33

Laparoscope 33

Optics Options for LESS 34
Conventional Laparoscopes 34; Modified Laparoscopes 35; Endo Eye 35; Stryker–IDEAL EYES-HD-Articulating Laparoscope 35

Chapter 6. Suturing Techniques in LESS 38

Technical Complexity of Suturing in LESS 38; Principles of Laparoscopic Suturing 38; Instrumentation for Suturing 39

Steps of Suturing 39
Intracorporeal Knotting Technique 41; Extracorporeal Knotting Technique for LESS 43; Review of Literature 43

Continuous Suturing with Barbed Suture 44

Endostitch Device/SILS Stitch Device 46

SILS Stitch Articulating Suturing Device 48

Chapter 7. Specimen Retrieval 50

Through the Umbilical Access Port using Claw Forceps 51; Colpotomy 51; Endobag 51; Transumbilical Mechanical Morcellation 53; Electromechanical Morcellation with a Power Morcellator 53; Transcervical Morcellation (of Uterus in Supracervical Hysterectomy) 56

Chapter 8. Benefits of LESS 59

Pain 59
Cosmesis 60
Reduction in Trocar Site Complications—Hernia, Vascular and Soft Tissue Injuries 61

Chapter 9. Technical Challenges and Limitations of LESS 64

Loss of Triangulation 64
Solution 64

Instrument Crowding 64
Solution 64

Reduced Vision 65
Solution 65

Learning Curve 65
Solution 65

Patient-Related Limitations 65
Solution 65

Chapter 10. Skill Training **66**

Simulators in Laparoscopic Surgery 67
Virtual Reality Simulator Training 67; The 'Video' or 'Box' Trainer 68; Physical Simulation 69

Section 2: LESS in Gynecology

Chapter 11. LESS in Adnexal Surgery **73**

Adnexal procedures that can be performed by Single-port Laparoscopy 73; Indications for Laparoscopic Management of Benign Adnexal Pathology 73; Preoperative Evaluation 74; Relative Contraindications 74; Access Port 74; Optics 74; Instruments 74; Operative Procedure 74

Oophorectomy/Salpingo-oophorectomy 75

Ovarian Cystectomy 75

Review of Literature 77
LESS-Assisted Extracorporeal Cystectomy 77; Isobaric Extracorporeal Cystectomy without Pneumoperitoneum 79; Extracorporeal Cystectomy in Pregnancy 79; Learning Curve for Ovarian Surgery in LESS 79

Chapter 12. Laparoendoscopic Single-Site Surgery for Ectopic Pregnancy **82**

Sites of Ectopic Pregnancy 82; Laparoscopy for Management of Ectopic Pregnancy 82; Selection of Patients for Surgical Management in Ectopic Pregnancy 82; Salpingectomy or Salpingostomy? 83; Laparoendoscopic Single-Site Salpingectomy 83; Surgical Technique 83; Laparoendoscopic Single-Site Salpingostomy 86; Reports of LESS in Ectopic Surgery 86

Chapter 13. Laparoendoscopic Single-Site Myomectomy **89**

Indications for Single-Port Laparoscopic Myomectomy 89; Relative Contraindications 89; Preoperative Patient Counseling 89; Preoperative Assessment and Planning 90; Selection of Access Port for LESS Myomectomy 90; Optics for Single-Port Laparoscopic Myomectomy 90; Instruments for Suturing 90; Operative Procedure 90; Myoma Morcellation Techniques 95; Difficulties Associated with Single Incision Laparoscopic Myomectomy 96; Complications of LESS Myomectomy 98

Chapter 14. LESS Hysterectomy **100**

Patient Selection 100

Patient Counseling 100

Pre-operative Preparation 101
Access 101
Port and Instrument Selection 101
Instrument Selection 101; Laparoscopes 102

Types of Hysterectomy 102
LESS-LAVH 102
LESS-TLH 103
Steps of LESS-TLH 103; The Upper Pedicle 103; Development of Bladder Flap 105; The Uterine Pedicles 105; Cardinal-Uterosacral Ligament Complex 106; Opening of the Vault 106; Specimen Retrieval 106; Vault Closure 109

Special Situations 109
LESS-TLH for Previous LSCS 109; LESS-TLH for Large Uterus 109; LESS-SCH (Supracervical Hysterectomy) 110

Comparison with 4 Port Conventional TLH/LAVH 110
Complications 110
Complications of Laparoscopy 110

Learning Curve 111

Chapter 15. LESS in Gynecological Oncology 114

Minimally Invasive Surgery in Gynecologic Malignancy 114

Endometrial Cancer 114
Advantages of Laparoscopy over Laparotomy 114

Ovarian Cancer 115
Concerns about Laparoscopy in Ovarian Cancer 115; Advantages of Laparoscopy over Laparotomy 115

Cervical Cancer 115
Advantages of Laparoscopy over Laparotomy 115

Laparoendoscopic Single-Site Surgery in Gynecologic Malignancy—Review of Literature 116
Advantages of LESS in Oncosurgery 116; Contraindications for LESS in Oncosurgery 116; Disadvantages of LESS in Oncosurgery 116

Chapter 16. Laparoendoscopic Single-Site Abdominal Sacrocolpopexy for Vaginal Vault Prolapse 119

Principle of Repair 120; Preoperative Evaluation 120; Surgical Procedure 120

Complications 123
Bleeding 123; Injuries to Ureter and Bladder 123; Injuries to the Bowel 123

Chapter 17. LESS Concomitant Procedures 126

Concomitant Gynecological and Surgical Procedures 127; Limitations 127; Review of Literature 127; Future of Concurrent Surgery in LESS 131

Chapter 18. Vaginal Route Single-Site Surgery (Transvaginal NOTES) 133

Advantages of Vaginal Route 133; Disadvantages of Vaginal Route 134; Contraindications 135; Technical Difficulties 135; Procedure 135; The Transdouglas Endoscopic Device (TED) 136; Application of NOTES in Gynecology 136

Chapter 19. Complications of Laparoendoscopic Single-Site Surgery 138

Classification of Complications 138
Complications Specific to the Procedure Performed 138; Complications Specific to a Laparoscopic Approach 138; Incidence of Complications 138

Complications Specific to LESS 139
Access-Related Factors 139; Intraoperative Factors 139; Postoperative Complications 141

Electrosurgical Complications in LESS 143
Risk Factors 144; Mechanisms of Electrosurgical Injury 144; Prevention of Electrosurgical Injury 145; Active Electrode Monitoring System 146;

Section 3: Recent Advances in LESS

Chapter 20. Robotic-Assisted Laparoendoscopic Single-Site Surgery in Gynecology (R-LESS) 153

Abdominal Access 153; Selection of Access Port for Robotic LESS 153; Advantages of Robotics in Single-Site Surgery 154; Limitations of Robotic Single-Site Surgery and New Innovations 155

Chapter 21. Newer Trends and Future 157

Laparoscopic Camera Holders 157
Magnetic Anchoring and Guidance System 158

Access Port 159
Hybrid Notes 159
Robots in Laparoscopic Surgery 159
Oasis 160
Computer-Assisted Surgery 160

LESS: Our Experience—Tips and Tricks for Beginners 163

Access—The Incision in the umbilicus 163
Tips and Tricks 163

Access—Insertion of the Access Port 164
Tips and Tricks 164

Choice of Access Port 164
Tips and Tricks 165

Closure of the Incision 165
Tips and Tricks 165

Vision and Optics 165
Tips and Tricks 166

Instrument Manipulation and Triangulation 166
Tips and Tricks 166

Suturing 166
Tips and Tricks 167

Hemostasis 167
Tips and Tricks 167

Tissue Retrieval 167

Specific Situations 167
LESS Total Laparoscopic Hysterectomy 167; LESS Myomectomy 167

Learning Curve 168

Complications 168

Index *171*

CHAPTER

3

Abdominal Access in LESS

Access through a single incision differentiates laparoendoscopic single-site surgery from traditional multiport surgery. It is an important facet of LESS, as it should not only allow the telescope and various hand instruments through a single small incision, but also facilitate the movement of instruments for effective performance of surgery.

UMBILICUS–THE SITE OF ENTRY

Umbilicus is the site of choice as both pelvis and abdomen is accessible through it. Good cosmesis is another advantage as umbilicus being a natural cicatrix, conceals the scar if proper reconstruction is done. Entry into the peritoneal cavity can be obtained through a vertical umbilical skin incision or an inverted Omega circumumbilical incision.

There are 3 approaches to performing laparoscopic surgery via a single incision.[1]

1. **Operative laparoscope:** This approach has been widely used by gynecologists to perform tubal sterilization. The operative laparoscope (Laprocator) has a side channel along the shaft of the instrument, which allows passage of a ring applicator to perform banding, or instrument for coagulation of the fallopian tubes.
2. **Single skin incision with multiple fascial incision:** With this approach, multiple 5 to 10 mm trocars are inserted next to each other for access to the abdominal cavity. Small bridges are cut between the fascial incisions to enable organ retrieval.[2,3]
3. **Specialized access ports:** These are commercially available devices with multiple channels to access the abdominal cavity. The ports have been described in Chapter 4.

1. Use of Operative Laparoscope in Single-Port Laparoscopy [Figs1A, 1B (i & ii)]

Similar to single-port surgery, other techniques have been developed to reduce the invasiveness of laparoscopic surgeries and increase the cosmetic appeal like the two-port surgery and NOTES (Natural orifice trans luminal endoscopic surgery). The two port and laparoscopic assisted techniques utilize an operative laparoscope through one port while an accessory port assists in retraction and dissection of tissues and helps in triangulation.[4] The use of single-port laparoscopy to detort the ovary and treat ovarian cysts, while sparing the ovarian tissue itself, has been described in the literature.[5-7] These methods have been shown to be feasible, safe, effective and provide minimal post-operative pain and bleeding with improved cosmesis. Limitations of this technique are common to other procedures involving the operative laparoscope. Depth perception is a challenge when using the original "operating laparoscopes" because the laparoscope and the operating instrument are aligned in the same plane.[8] There are fewer degrees of freedom between the instruments, inside and outside the abdominal cavity, which limits the surgeon's movements. These problems of the operating laparoscope can be alleviated to some extent by use of intrauterine manipulator to change the position of the uterus, use of a 30-degree angled laparoscope to allow better

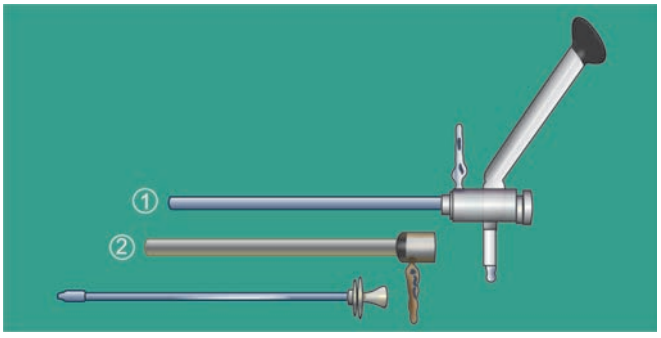

Figure 1A

Operative laparoscope: The Frazee operative laparoscope (KARL STORZ, Tuttlingen, Germany) is a 8 mm straight-viewing Hopkins laparoscope, 30 cm length, with a 5 mm working channel.





Figures 1B (i& ii)

Laparocator (for laparoscopic tubal ligation with Fallope rings): (i) Laparocator channel (Operative laparoscope) with offset eyepiece and operating channel. The ring applicator for application of fallope channel rings is seen with prongs at the distal end. (top). (ii) The ring applicator has been inserted through the operating channel. [*Courtesy:* Dr Sharda Patra Assoc Prof (Deptt of Obstetrics & Gynecology, Lady Hardinge Medical College, New Delhi)].

visualization and to perform surgery with a combination of standard and long instruments.[7] Last, but not the least, the operating laparoscope has only one side channel for instrumentation which limits the type of procedures that can be performed by this method. In comparison, the specialised multiple access ports available for single-port laparoscopic surgery contain three to four 5 mm channels, which make more complex procedures feasible.

2. The Single-Incision but Multi-Port Technique (Curcillo and King Technique) [Figs 2 (A-E)] and 2 F(i-viii)

The transumbilical technique for cholecystectomy, without additional incisions, was described first by Navarre et al. in 1997 and later Piskun et al. in 1999[9,10], but failed to gain popularity due to lack of proper instrumentation. This was further refined and popularized by Curcillo and King in 2007 and published subsequently with their original technique of entry.[11,12] In their technique, a skin incision at the umbilicus, allows a flap of the umbilicus to be raised, allowing for three to four separate sheath incisions at distances of 2 to 3 cm from each other in the 'Mickey Mouse' configuration. This makes it possible to insert three or even four low profile trocars, which can permit one optic and two working instruments and the possibility of an additional grasping instrument as well. Low profile and short trocars further reduce the clashing of the instruments close to the abdominal wall.[13] These fascial defects are placed at a short distance from each other. If angulation is used to enter these fascial defects, better maneuverability and maintenance of pneumoperitoneum is ensured. The disadvantage with this method is loss of pneumoperitoeum and that the defects left behind (swiss cheese appearance) may not allow proper approximation and may lead to fascial weakening.

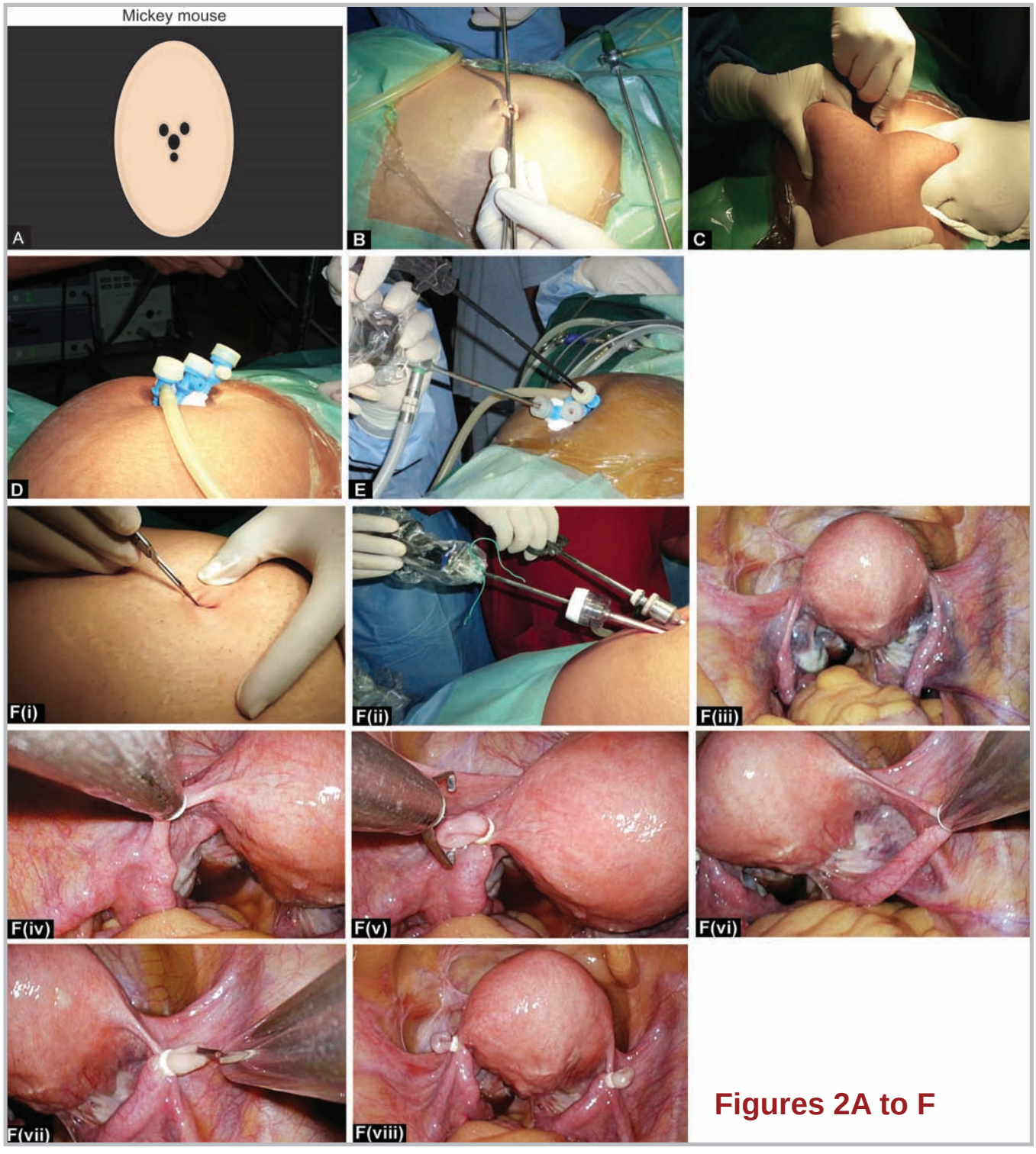

Curcillo & King method. Single skin with multiple fascial incisions: (A). Diagrammatic representation; (B). Incision is planned at the umbilicus; (C) First 5 mm trocar inserted through the fascia; (D) Three 5 mm trocars through different fascial but single skin incision; (E) Salpingectomy being performed. 5 mm telescope and grasper inserted through two trocars; (F) Laparoscopic tubal ligation with Fallope rings. Two trocars have been inserted through a single skin incision in the umbilicus with two fascial incisions: (i) Incision for access; (ii) Endoeye and Ring applicator seen through two trocars in the same incision. (iii to viii) Laparoscopic view of tubal ligation with Fallope rings using ring applicator.

3. Use of a Specialized Multichannel Access Device

The third and widely used technique is use of specially designed multichannel devices. These are commercially available devices, which can be inserted through a single opening in the umbilicus. These ports have 3 to 4 openings, which permit the placement of 3 or 4 instruments. One of the earliest multichannel devices was the R-Port (Advanced Surgical Concepts, Wicklow, United Kingdom). It was just a single-gel interphase that could be perforated many times to get the instruments in. But there was a problem of loss of pneumoperitoneum with this. Now a wide variety of access devices are available. These new access devices permitted the surgeon to insert more than two instruments and an optic, with trocars as in the GelPort and the SILS™ port and without as in the R-Port™, through the same port. [14-17] The articulating or angulated instruments can be inserted through these devices along with an optic to overcome problems of loss of triangulation[18,19] [Fig. 3]. The access device is inserted through an incision between 20–25 mm depending on the port and the organ to be accessed.[20] For details of various access ports refer Ch-4.



Figure 3

Instruments and telescope (5 mm 30° long) through Covidien SILS port

OPERATIVE PROCEDURE: ACCESS IN LESS

Entry [Figs 4A to N]

After administrating anesthesia and routine preparation of the patient, the right-handed surgeon stands on left side of the patient. The umbilicus is cleaned with Betadine solution.

Preventive local anesthesia: A dilute 10-20 mL solution of local anesthetic (0.5% bupivacaine with epinephrine) is administered topically in the peritoneum before skin incision is made. It is known as Preemptive anesthesia. It is known to reduce postoperative pain intensity and requirement of analgesic in patients treated with local anesthetic before surgery as compared to local anesthetic administered postoperatively.[21,22] Transmission of pain signals evoked by tissue damage leads to sensitization of the peripheral and central pain pathways. Pre-emptive analgesia reduces this sensitization. Owing to this 'protective' effect on the nociceptive system, pre-emptive analgesia is more effective than a similar analgesic treatment initiated after surgery.[23] Hence it is preferable to prevent or 'pre-empt' the neurophysiological and biochemical consequences of a noxious input to the CNS rather than to begin treatment when these consequences are already established.[24]

The abdominal entry through the umbilicus is made with open Hasson technique. It should be remembered that the size of the skin incision is independent of the fascial incisions. Since cosmesis postoperatively is an important factor for consideration, all efforts should be made to avoid the disfigurement of the umbilicus. Especially for female patients, as in gynecological procedures, it is expected that any disfigurement of the umbilicus will negate all benefits of single access surgery and can lead to patient dissatisfaction.

Important Considerations

- Proper preoperative preparation of the umbilicus. Patients are instructed to clean the umbilicus thoroughly before reporting to the hospital. Preoperative prepping by ward nurse includes cleaning with soap solution and betadine.
- Skin incision should mimic natural creases- either a curved infra umbilical incision also known as 'Omega'-type incision or a 'J'–shaped or 'hockey stick incision' can be given.[25] The shape of the incision will depend on the size and configuration of the umbilical crater.



Figures 4A to N

Procedure for single incision access using SILS port (Covidien). (A) Local anesthetic instillation; (B) Making vertical incision. The margins of the umbilicus are held with Allis forceps; (C) Subcutaneous sharp dissection; (D) Blunt dissection and palpation of rectus sheath; (E) Extension of the fascial incision with a long artery forceps; (F) Access has been obtained into the peritoneal cavity; (G) Stay sutures at the margins of the rectus sheath; (H) SILS port(Covidien) being held with artery forceps for insertion; (I to K) Steps on insertion of Covidien port into the incision; (L) Access port fully inserted; (M) Insertion of 5 mm trocars; (N) SILS port with three 5 mm trocars.

- No part of the incision should lie outside the umbilical crater.[25]
- Umbilical stalk should not be cut; instead the fascia can be entered at the base where the stalk is attached.[25]

Use of the circumumbilical inverted Omega incision allows for placement of multiple trocars through separate fascial incisions through umbilicus or multichannel access ports, provides a site for specimen removal, and potentially enhances cosmesis in this patient population.The choice to use a vertical or a inverted omega incision rests with the surgeon. After making the incision, the dissection is done up to the rectus sheath by using blunt dissection. The rectus sheath is held with artery forceps and lifted and a small nick is given with scissors. Once the fascial defect is created, it can be extended by using a blunt artery forceps and stretching it both horizontally and vertically. It is a good practice to hold the rectus sheath with stay sutures before putting in the access port. This helps as a guide to the sheath when the fascial closure is done. The stay sutures are removed when the fascia is being closed. The access port is then inserted into the incision.

CLOSURE [Fig 5(A-C)]

At the conclusion of each case, the fascia and underlying peritoneum are isolated and closed with delayed absorbable suture in a running fashion with 0-Vicryl suture (Ethicon, Somerville, NJ). If the umbilical stalk is cut, it is identified and reattached to the fascia with an anchoring stitch by use of 0-Vicryl suture, and the skin is closed with subcuticular absorbable sutures with 3-0 monocryl. The fascia can also be closed with interrupted, 'Figure-of-8' delayed absorbable sutures.[26] In a retrospective study conducted by Kevin Stepp et al ,there were no significant differences in intraoperative or postoperative complications, wound complications, postoperative antibiotic use, or 6 week patient satisfaction between the 2 incision types.[27]

Review of literature; The method for access was described by Rivas et al in their case series on single incision laparoscopic cholecystectomy.[28] The umbilicus was everted by pulling the deepest point of the umbilical scar (inner ring) out of its inward position. A 1.5 to 2 cm transumbilical incision then was performed in a vertical fashion without extension of this incision beyond the outer limits of the umbilical folds. By incising the rectus sheath, direct access into the abdomen was obtained. Through this opening, a low-profile, 5 mm trocar was placed under direct vision without the need for an introducer or previous pneumoperitoneum. Only for cases in which the entry site into the abdomen is not readily identified after the stalk had been incised, is pneumoperitoneum obtained with the use of a Veress needle.[26]

In Curcillo and King method,[11,12] after adequate pneumoperitoneum has been obtained, a second 5 mm port is placed through the same skin incision, but approximately 5 mm above the first port. Only if needed is an additional 5 mm trocar placed inferiorly or laterally through the same skin incision but at a different fascial site. The use of three different fascial incisions could lead to loss of pnemoperitoneum which can be avoided by not making such openings too near each other (should be at least 2 mm apart).

Therefore, abdominal access through a single incision in the umbilicus defines Laparoendoscopic single-site



Figures 5A to C

Closure. (A and B) Closure of the incision; (C) Scar after closure

surgery. The type of incision and ports depends on the procedure, skill and comfort of the patient. The surgeon should be careful about maintaining the integrity of the umbilicus during access and closure. If these principles are followed, excellent cosmetic benefit and satisfaction can be provided to the patient without compromising on the operative procedure.

KEY POINTS

- Access though a single incision defines Laparoendoscopic Single-site Surgery
- Site of Access is the Umbilicus
- Anatomical configuration of the umbilicus should be maintained during incision and closure
- Type of incision depends on shape & size of umbilicus and Surgeon's preference
- Local infilteration of anesthetic preoperatively provides enhanced postoperative pain relief.

REFERENCES

1. Shitanshu Uppal, Michael Frumovitz, Pedro Escobar, and Pedro T. Ramirez. Laparoendoscopic Single-site Surgery in Gynecology: Review of Literature and Available Technology, Journal of Minimally Invasive Gynecology. 2011:18. 12–23.
2. Podolsky ER, Curcillo PG II. Single-port access (SPA) surgery: a 24-month experience. J Gastrointest Surg. 2010; 14:759-67.
3. Tacchino R, Greco F, Matera D. Single-incision laparoscopic cholecystectomy: surgery without a visible scar. Surg Endosc. 2009; 23: 896–99.
4. Arjun Khosla, Todd A Ponsky. Use of operative laparoscope in single-port laparoscopy. A forgotten tool, Journal of Minimal Access Surgery. 2011;7(1): 116-20.
5. Li YT, Kuon LC, Lee PN. et al. Laparoscopic detorsion of twisted ovary. J Chin Med Assoc. 2005 Dec; 68(12): 595-98.Source.
6. Kosumi T, Kubota A, Usui N, et al. Laparoscopic ovarian cystectomy using a single umbilical puncture method. Surg Laparosc Endosc Percutan Tech. 2001 Feb; 11(1): 63-57.
7. Fagotti A, Fanfani F, Marocco F, et al. Laparoendoscopic single-site surgery (LESS) for ovarian cyst enucleation: Report of first 3 cases. Fertil Steril. 2009;92: 1168;e1113-166.
8. Mohamed A. Bedaiwy, Pedro F. Escobar, Jay Pinkerton, William Hurd, Laparoendoscopic Single-Site Salpingectomy in Isthmic and Ampullary Ectopic Pregnancy: Preliminary Report and Technique. Journal of Minimally Invasive Gynecology (2011) 18, 230–233.
9. Navarra G, Pozza E, Occhionorelli S, et al. One-wound laparoscopic cholecystectomy. Br J Surg. 1997; 84:695.
10. Piskun G, Rajpal S. Transumbilical laparoscopic cholecystectomy utilizes no incisions outside the umbilicus. J Laparoendosc Adv Surg Tech A. 1999; 9:361–4.
11. Castellucci SA, Curcillo PG, Ginsberg PC, et al. Single-port access adrenalectomy. J Endourol. 2008; 22:1573–576.
12. Podolsky ER, Rottman SJ, Poblete H, et al. Single-port access (SPA) cholecystectomy: A completely transumbilical approach. J Laparoendosc Adv Surg Tech A.2009; 19:219–22.
13. Raman JD, Bensalah K, Bagrodia A, et al. Laboratory and clinical development of single keyhole umbilical nephrectomy. Urology. 2007; 70:1039–42.
14. Rane A, Kommu S, Eddy B, et al. Rao P. Clinical Evaluation of a novel laparoscopic port (R-Port) and evolution of the single laparoscopic port procedure (SLiPP) J Endourol. 2007; 21:A22–23.
15. Rane A, Rao P. Single-port-access nephrectomy and other laparoscopic urologic procedures using a novel laparoscopic port (R-port) Urology. 2008; 72:260–63.
16. Rao PP, Bhagwat SM, Rane A. The feasibility of single-port laparoscopic cholecystectomy: A pilot study of 20 cases. HPB (Oxford). 2008; 10:336–40.
17. Kaouk JH, Haber GP, Goel RK, Desai MM, Aron M, Rackley RR et al Single-port laparoscopic surgery in urology: Initial experience. Urology. 2008;71:3–63
18. Raman JD, Bensalah K, Bagrodia A, et al. Laboratory and clinical development of single keyhole umbilical nephrectomy. Urology. 2007;70:1039–42.
19. Raman JD, Cadeddu JA, Rao P, et al. Single-incision laparoscopic surgery: Initial urological experience and comparison with natural-orifice transluminal endoscopic surgery. BJU Int. 2008; 101:1493–496.

20. Prashanth P Rao, Pradeep P Rao, Sonali Bhagwat. Single-incision laparoscopic surgery - current status and controversies J Minim Access Surg. 2011 Jan-Mar; 7(1): 6–16.
21. Pasqualucci A, de Angelis V, Contardo R, et al. Preemptive analgesia: intraperitoneal local anesthetic in laparoscopic cholecystectomy. A randomized, double blind, placebo-controlled study. Anesthesiology. 1996 Jul; 85(1): 11-20.
22. Ke RW, Portera SG, Bagous W, et al. A randomized, double-blinded trial of preemptive analgesia in laparoscopy. Obstet Gynecol. 1998 Dec; 92(6): 972-75.
23. J. B. Dahl and S. Moiniche http://bmb.oxfordjournals.org/ 16 British Medical Bulletin 2004; 71.
24. Woolf CJ, Chong MS (1993) Preemptive analgesia-treating postoperative pain by preventing the establishment of central sensitization. Anesth Analg, 77, 362–379.
25. Craig Sobolewski, Patrick P Yeung Jr, Stuart Hart. Laparoendoscopic single-site surgery in Gynaecology. Obstet Gynecol Clin N Am 38(2011) 741-745.
26. Camille C. Gunderson, Jason Knight, Jessica Ybanez-Morano, Carol Ritter, Pedro F. Escobar, Okechukwu Ibeanu, Francis C. Grumbine, Mohamed A. Bedaiwy, William W. Hurd, and Amanda Nickles Fader. The Risk of Umbilical Hernia and Other Complications with Laparoendoscopic Single-Site Surgery. Journal of Minimally Invasive Gynecology (2012) 19, 40–45.
27. Kane S, Stepp KJ. Circumumbilical (Omega) Incision Use in Laparoendoscopic Single-site (LESS) Gynecologic Surgery, Journal of Minimally Invasive Gynecology. 18 (2011) S132–S155.
28. Homero Rivas, Esteban Varela, Daniel Scott. Single-incision laparoscopic cholecystectomy: initial evaluation of a large series of patients. Surg Endosc (2010) 24:1403–1412.

SINGLE PORT LAPAROSCOPIC SURGERY IN GYNECOLOGY

Salient Features

- First elaborative book on Laparoendoscopic Single-Site Surgery (LESS) in gynecology
- A complete reference guide for gynecologic laparoscopic surgeons who plan to venture into the field of Single-Port Laparoscopic Surgeries
- Organized into 3 sections with a separate section on 'our experience'
- Exhaustive description of access, ports, instruments and techniques related to Single-Port Surgeries
- Describes surgical procedures in detail for complete understanding of the reader
- Comprehensive description of benefits, limitations and complications
- Informative chapter on skill training
- A number of pictures, illustrations and tables to simplify and explain the surgical procedures in LESS
- Includes interactive DVD-ROM of live single-incision access laparoscopic surgeries.



B Ramesh MD DGO FCPS FICOG is a renowned Gynecologic Endoscopic Surgeon and Director at Dr Ramesh Hospital, Bengaluru, Karnataka, India. He is the pioneer in Single-Incision Laparoscopic Surgery (SILS) technique in Gynecologic Laparoscopy in India and has demonstrated the technique of Single-Port Laparoscopic Surgery in many workshops all over the country. His special interests, apart from gynecological endoscopy, are urogynecology and infertility. He has performed several thousand laparoscopic surgeries all over India and has trained more than 1000 gynecologists in operative laparoscopy from India and abroad. He was the first one to start structured fellowship courses in Minimally Invasive Surgery in Gynecology in India. He has received many awards for his contribution to the field of medicine. He believes in holistic medical and surgical approach to the patient. His passion and dedication to his work has been a source of inspiration to many aspiring gynecologic laparoscopic surgeons.



Madhuri Vidyashankar MS DNB (OBG) has done fellowship in Gynecological Endoscopy at Dr Ramesh Hospital, Bengaluru, Karnataka, India and now works as a Consultant Gynecologic Endoscopic Surgeon; a very good clinician and surgeon. She has worked on LESS surgeries for a long time and contributed immensely in the development of this technique. She is also very caring and compassionate towards the patients.



Pooja Sharma Dimri MD DNB (OBG) is an alumnus of Lady Hardinge Medical College, New Delhi, India. She has done fellowship in Gynecological Endoscopy at Dr Ramesh Hospital, Bengaluru, Karnataka, India and presently works as a Consultant Gynecologic Endoscopic Surgeon. Apart from being an efficient surgeon, she is actively involved in academics and research. She is excellent in scientific writing. She has also done a lot of work in the field of different techniques of morcellation of fibroids.

Shelving Recommendations
LAPAROSCOPIC SURGERY
GYNECOLOGY

ISBN 978-93-5090-638-5
9 789350 906385

Available at all medical book stores
or buy directly from Jaypee Brothers through online shopping
at www.jaypeebrothers.com

JAYPEE BROTHERS
Medical Publishers (P) Ltd.
www.jaypeebrothers.com