almology books, visit our website **www.jaypeebrothers.com,** for detailed information on ophthalmology books

LACRIMAL DRAINAGE SURGERY

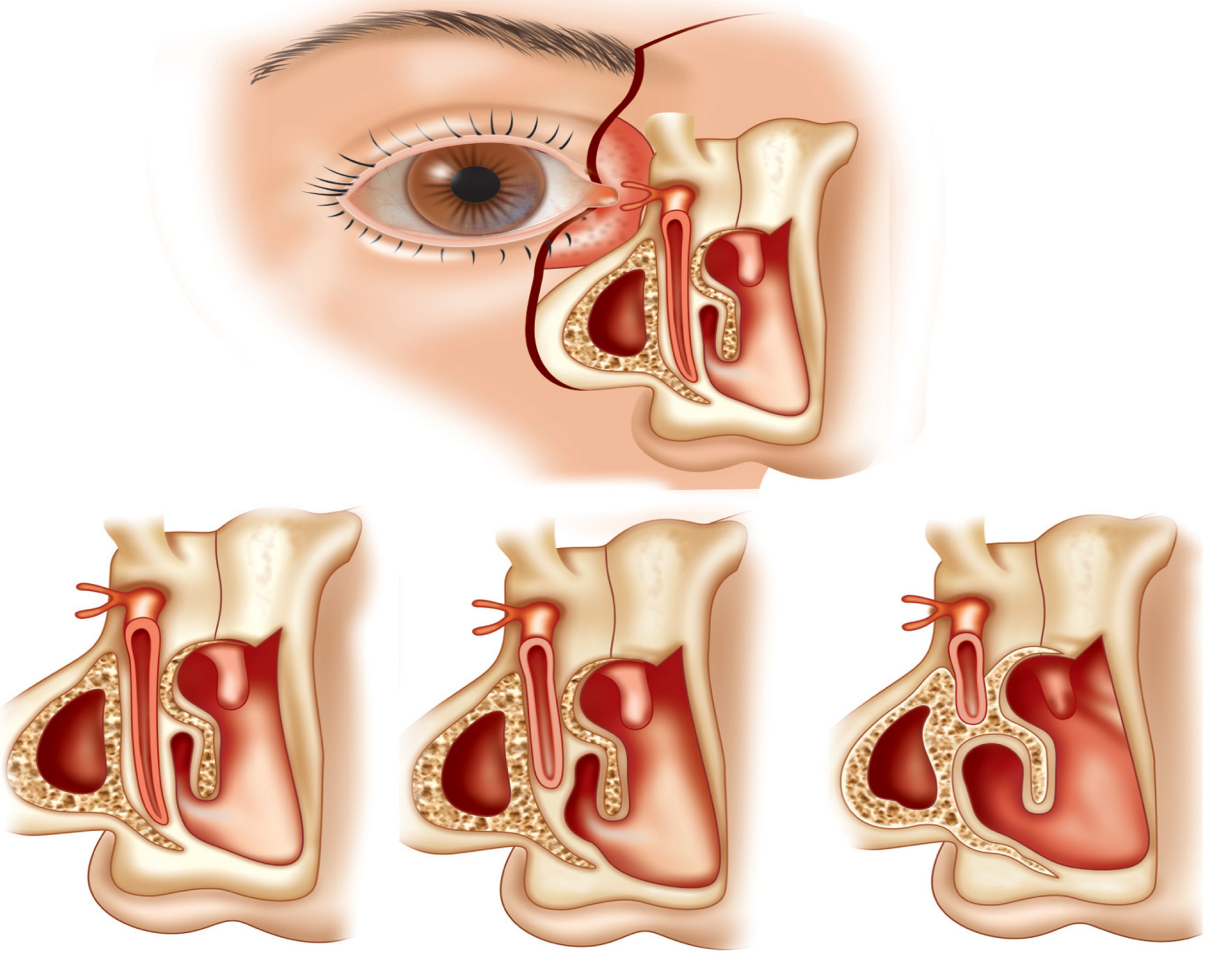

Suresh D Isloor

JAYPEE

Contents

1. Milestones in Lacrimal Drainage Surgery **1**

Suresh D Isloor

- Historical Background *1*

2. Surgical Anatomy of the Lacrimal Excretory System and Lateral Wall of the Nose **3**

Suresh D Isloor

- Lacrimal Fossa *5*
- Lateral Nasal Wall *7*

3. Physiology of the Lacrimal System **10**

Suresh D Isloor

4. Symptoms and Evaluation of Tearing Patient **12**

Suresh D Isloor

- Epiphora Grading *12*
- Clinical History *13*
- Lavage *15*

5. Imaging in Lacrimal Drainage System **17**

Lakshmi Mahesh

- Conventional Radiography (X-ray) and Dacryocystography *17*
- Ultrasound *19*
- Nuclear Medicine Dacryoscintigraphy *19*
- Computed Tomography/Computed Tomography Dacryocystography *20*
- Magnetic Resonance Imaging *21*

6. Evaluation and Management of Congenital Dacryostenosis **23**

Suresh D Isloor

- Natural History *23*
- Intubation *27*
- Indications *28*
- Postoperative Care and Complications *29*

7. External, Conventional or Percutaneous Dacryocystorhinostomy **30**

Suresh D Isloor

- Indications for Surgery *30*
- Contraindications *31*

- Anesthesia *31*
- Lacrimal SAC *35*
- Silicone (Silastic) Intubation *36*
- Postoperative Care *36*

8. Endoscopic Endonasal Approach to the Lower Lacrimal Drainage System 37

P Thulasi Das, Harini T Das, V Venkatraman

- Indications *37*
- Evaluation of Patients with Epiphora *37*
- Endoscopic Surgery of Lower Lacrimal Drainage System *38*

9. Combined Transcanalicular Endonasal Diode Laser Dacryocystorhinostomy 42

Suresh D Isloor

- Postoperative *45*

10. Conjunctivodacryocystorhinostomy 46

Mohammad Javed Ali, Roshmi Gupta, Santosh G Honavar

- Indications *46*
- Contraindications *46*
- Equipment Required *46*
- Preparation *47*
- Procedure *47*
- Postoperative Care *49*
- Success Rates and Complications *50*

11. Centurion Syndrome and its Management 51

Shivayogi R Kusagur

- Anatomy and Function of Medial Canthal Tendon *51*

12. Smart Lacrimal Probe 55

Mihir Kothari

13. Diode Laser Machines Used in Transcanalicular Laser DCR 58

Suresh D Isloor

14. Instruments Used in External, Endonasal, Laser DCR 62

Suresh D Isloor

15. Endonasal Endoscopic Dacryocystorhinostomy 72

Deviprasad D

- Indications *72*
- Contraindications *72*

- Advantages Over External Dacryocystorhinostomy *73*
- Preoperative Considerations *73*
- Equipment and Instruments *74*
- Anesthesia *75*
- Surgical Technique *75*
- Postoperative Care *77*
- Complications *78*

16. Minimal Invasive Lacrimal Surgeries: Balloon Dacryoplasty 79

Mohammad Javed Ali, Milind N Naik, Santosh G Honavar

- Balloon Dacryoplasty in Children *80*
- Balloon Dacryoplasty in Adults *82*
- Nine Millimeter Primary Endoscopic Balloon *83*
- Balloon-Assisted Revision Dacryocystorhinostomy *84*

17. Amniotocele and Fistula, Dacryocystitis and Tumors (Neoplastic) 86

Suresh D Isloor

- Amniotocele *86*
- Lacrimal Fistula *86*
- Treatment *87*
- Dacryocystitis *87*
- Tumors (Neoplastic) *87*
- Traumatic *88*
- Iatrogenic *88*

Index *89*

3 Physiology of the Lacrimal System

Suresh D Isloor

INTRODUCTION

Symptoms of lacrimal drainage disorders affect ocular function, ocular health and social functions. Basic knowledge of the whole lacrimal system is essential to understand the physiology of tear flow—ocular surface cornea and conjunctiva, lacrimal gland and accessory lacrimal glands, nasolacrimal system, puncta, canaliculi, lacrimal sac and nasolacrimal duct and nasal cavity.

Hyperlacrimation (excessive tear production) may be caused by reflex lacrimation and direct stimulation of lacrimal gland. Epiphora (decreased tear outflow) may be caused by disorders of lacrimal outflow system, puncta, canaliculi, lacrimal sac, lacrimal pump, nasolacrimal duct and valve of Hasner at the lower end of the nasolacrimal duct into the nasal cavity.

Most common sites of blockage are: nasal orifice of the duct, common canalicular duct and junction between sac and nasolacrimal duct.

Causes of Epiphora

- Punctal abnormalities
- Punctal stenosis
- Punctal ectropion
- Punctal agenesis: congenital
- Lacrimal pump dysfunction
- Eyelid laxity
- Eyelid retraction
- Weakness of orbicularis oculi
- Canalicular stenosis
- Trauma
- Herpetic disease
- Canaliculitis
- Topical medications
- Radiation
- Nasolacrimal duct obstruction
- Involution
- Traumatic
- Neoplastic
- Nasal pathology
- Allergy
- Nasal infection-sinusitis
- Neoplastic-polyps
- Deviated nasal septum.

Lacrimal Secretory System

Main lacrimal gland is situated in the lacrimal fossa, superolateral region of the orbit. The gland measures 20 × 12 × 5 mm and is divided by the lateral horn of levator aponeurosis into larger orbital lobe, and lesser palpebral lobe. The orbital lobe lies posterior to the orbital septum and preaponeurotic fat and anterior to the levator aponeurosis.

Lacrimal gland produces water, proteins, peptides, glycopeptides and mucin. Two to six secretory ducts from the orbital lobe of the lacrimal gland pass through the palpebral lobe or along the fibrous capsule, joining with the ducts from the palpebral lobe to form six to twelve tubules and empty into superolateral conjunctival fornix 4–5 mm above tarsus. The gland is composed of numerous acini that drain into larger tubules and ducts. The acini are made up of basal myoepithelial cell layer with inner columnar secretary cells. Contraction of myoepithelial cells helps to force secretions into the tubules and drainage ducts.

Accessory lacrimal glands of Krause 20–40 are located in the superior and inferior conjunctival fornices. Glands of Wolfring are located in the palpebral conjunctiva along the superior tarsal border in upper eyelid and are responsible for aqueous tear secretion.

Lacrimal Functional Unit

Cornea possesses the richest sensory innervation of the body to detect noxious stimuli. The lacrimal branch of ophthalmic division of the trigeminal nerve carries the sensory stimuli (parasympathetic) from the lacrimal gland. Different classes of noxious stimuli (mechanical injuries, heat, extreme cold, irritant chemicals) activate the sensory fibers of the ocular surface to different degree, unpleasant sensations of distinct quality.

Tear film is secreted reflexively by the "lacrimal functional unit" which is composed of ocular surface tissues, cornea and conjunctiva, goblets cells and meibomian glands, the lacrimal

JAYPEE BROTHERS

glands and their interconnecting sensory and autonomic innervation. This reflex secretion is initiated by subconscious stimulation of highly innervated ocular surface epithelia. The nasolacrimal ducts are also integrated in this reflex arc.

Mechanism of Tear Drainage

Drainage of lacrimal (tear) fluid involves a number of mechanisms. The action of lacrimal part of orbicularis oculi muscle is the most important factor in draining the fluid into the lacrimal sac.

In the middle of the eyelid structure is the palpebral part of the orbicularis muscle. Fiber bundles of the muscle overlap with one another like roof tiles. Orbicularis action is triggered by facial nerve leading to time shifted lid closure from temporally to nasally, moving the tears to medial canthal region—lacrimal lake.

Epithelial secretions, the surrounding cavernous body, and the connective tissue fibers are most important factors in draining tear fluid from the lacrimal sac into the nose.

The lacrimal sac and nasolacrimal duct are surrounded by vascular plexus. Closure and opening of the lacrimal drainage passage is caused by the swelling and shrinkage of the cavernous body which regulates the tear flow. Cavernous body is densely innervated. Epiphora related to emotions such as sorrow or happiness occurs not only by increased tear secretions from lacrimal gland but by closure of lacrimal passage. Pharmacologically, this can be influenced, [decongestant drops (**Figure 3.1**)].

Physical Factors

- Evaporation, capillary action, gravity and respiration
- Lacrimal pump mechanism
- Opening and closing of lumen of the lacrimal passage facilitated by swelling and shrinkage of cavernous body
- Absorption of tear fluid occurs through the lining epithelium of lacrimal sac and nasolacrimal duct and is transported into the surrounding cavernous body, which is subject to autonomic control and regulates tear outflow. These vessels of cavernous body are connected to the blood vessels of the outer eye and could act as a feedback signal for tear fluid production.

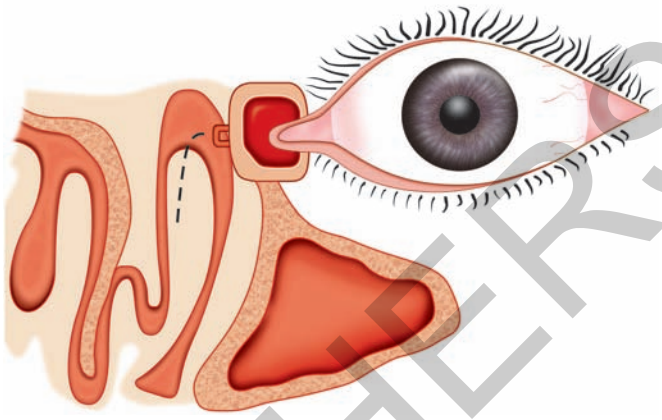

Figure 3.1: Tear drainage

Lacrimal Pump Theory of Jones

Contraction of the pretarsal orbicularis muscle fibers during eyelid closure compresses and shortens the lateral part of the canaliculi forcing tears through the medial portion of canaliculi into the lacrimal sac. Simultaneous contraction of the deep head of the preseptal orbicularis muscle expands the lacrimal sac, creating negative pressure within the lacrimal sac that draws the tears into the sac from the canaliculi. Between every blink reflex tears flow lateral to medial canthal region "lacrimal lake". Recent studies indicate that a positive pressure mechanism is responsible for the lacrimal pump mechanism during eyelid closure. Flow of tears from canaliculi to the sac is an active process while the flow of tears into the nasolacrimal duct is a passive process.

Wall of the lacrimal sac is composed of collagen, elastic, and reticular fiber bundles arranged in a helical pattern. These fibers encircling the sac may result in the sac being "wrung out" contribute biomechanically to tear outflow during blinking.

JAYPEE BROTHERS

r detailed information on ophthalmology books, visit our website **www.jaypeebrothers.com,** for detailed inform

LACRIMAL DRAINAGE SURGERY

Salient Features

- Step-by-step instructions on how to perform state-of-the-art surgical techniques on lacrimal drainage.
- Characterize the surgical anatomy of the lacrimal system including surgical anatomy of the lateral wall of the nose, pathophysiology, and diagnostics including CT and MRI.
- Essential reference for Eye and ENT surgeons, who need a refresher on surgical procedures as well as postgraduates seeking guidance on the latest advancement in lacrimal drainage surgery.
- Offers in-depth, step-by-step descriptions of the clinical management of lacrimal disorders.
- Comprises external and endonasal dacryocystorhinostomy (including flap technique), conjunctivo-rhinostomy and latest procedures such as transcanalicular nasal endoscopic-assisted diode-laser dacryocystorhinostomy (DCR) and balloon-assisted dacryoplasty.
- Useful for both novice and experienced surgeons, who deal with dacryocystorhinostomy and also for the postgraduate students in updating their knowledge on the subject.



Suresh D Isloor DO DLO FIAMS completed his graduation in Medicine from Maharaja Sayajirao University at the Medical College Baroda, Vadodara, Gujarat, India, in the year 1961 and obtained his Postgraduate Diploma in Otolaryngology in 1963 and Ophthalmology in 1964. He is a lifetime member and Ex-President of Karnataka Ophthalmic Society, Karnataka, India. Having the advantages of the dual specialty, he has done the research work on use of cornea in tympanoplasty, atrophic rhinitis (nasal obturator) and dacryocystorhinostomy. He started the first private nursing home in 1964 in Shimoga, Karnataka, India. He was awarded the prestigious Dr Srinivas Rao Memorial Oration Award in the year 2010, at Udupi during Karnataka Ophthalmic Society.

Available at all medical book stores
or buy directly from Jaypee Brothers through online shopping
at www.jaypeebrothers.com

JAYPEE BROTHERS
Medical Publishers (P) Ltd.
www.jaypeebrothers.com

Shelving Recommendation
OPHTHALMOLOGY
OTORHINOLARYNGOLOGY

ISBN 978-93-5090-650-7