ental books, visit our website www.jaypeebrothers.com, for detailed information of dental books, visit our website www.jaypeebrothers.com, for detailed information of dental books, visit our website www.jaypeebrothers.co

THIRD EDITION

Textbook of
ORAL MEDICINE





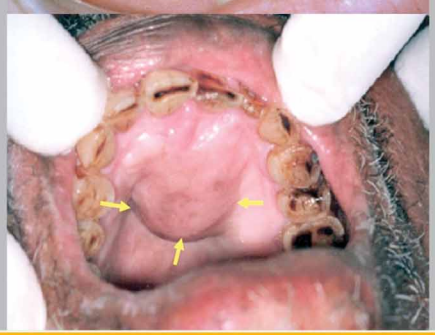

Pramod John R

Foreword
MS Valiathan

JAYPEE

Contents

Chapter 1: History Taking and Clinical Examination **1**
Diagnosis 3
Recording of History and Clinical Examination 4
Medical Risk Assessment of the Dental Patient 4
Principles of Clinical Examination 16

Chapter 2: Terminology in Oral Medicine **18**
General Terms 18
Clinical Terms 19
Histological Terms 28

Chapter 3: Maxillofacial Imaging **30**
Imaging Modalities 30

Chapter 4: Structure of the Oral Mucous Membrane **39**
Gingiva 39
Buccal and Labial Mucosa 40
Tongue 40
Floor of the Mouth 43
Retromolar Trigone 43
Hard Palate 44
Soft Palate 45
Tonsillar Area 45
Oropharynx 46
Histology of Oral Mucosa 46
Stomatitis 48

Chapter 5: Oral Microbial Flora **51**
Factors Influencing Growth of Microorganisms 52
Factors Influencing the Isolation and Identification of Oral Flora 53
Genera of Oral Bacteria 53
Gram-positive Rod-shaped Bacteria 54
Gram-negative Anaerobic Rod-shaped Bacteria 55
Facultative Gram-negative Rods 56
Fungi 56
Protozoa 57
Viruses 57

Chapter 6: Saliva **60**
Functions of Saliva 61
Composition 62
Sialorrhea (Increased Saliva Flow) 62
Xerostomia (Dry Mouth) 63

Chapter 7: Developmental Disorders Affecting the Jaws, Teeth, Lips, Oral Mucosa, and Tongue **66**
Developmental Disorders Affecting the Jaws 67
Developmental Disorders Affecting the Teeth 77
Disorders During Morphodifferentiation of Tooth Germs 80
Developmental Disorders Affecting the Lips 97
Developmental Disorders Affecting the Oral Mucosa 100
Developmental Disorders Affecting the Tongue 108

Chapter 8: Lymphatic Drainage of the Head and Neck Region Differential Diagnosis of Cervical Lymphadenopathy **116**
Location of Lymph Nodes 117
Examination of the Lymph Nodes 119
Causes of Cervical Lymph Nodes Enlargement 120

Chapter 9: Age Changes in the Oral Cavity **123**
Age Changes Affecting Structures in the Oral Cavity 123

Chapter 10: Halitosis **129**
Classification 129
Mechanism of Production of Halitosis 131
Measurement of Halitosis 131
Management 132

Chapter 11: Diseases of the Teeth and Supporting Tissues, Gingival Enlargement, and Desquamative Gingival Lesions **133**
Dental Caries 134
Internal and External Resorption of the Teeth 141
Discoloration of Teeth 143
Gingivitis 144
Periodontitis 145
Gingival Enlargement 148
Desquamative Gingival Lesions 152

Chapter 12: Diseases of the Pulp and the Periapical Region **155**
Diseases of the Pulp 155
Diseases of the Periapical Region 158

Chapter 13: Cysts of the Jaws **165**
Cysts in the Jaws 166

Chapter 14: Infections of the Oral Cavity 176
Bacterial Infections 176
Viral Infections 195
Fungal Infections 200

Chapter 15: Ulcerative Lesions of the Oral Cavity 208
Classification 208
Infections 211
Acute Multiple Lesions 211
Recurrent Oral Ulcers 211
Chronic Multiple Ulcers 216
Ulcers Secondary to Other Factors 216

Chapter 16: Vesiculobullous Lesions 218
Vesiculobullous Lesions due to Viral Infections 218
Autoimmune Diseases 218
Drug Eruptions 225

Chapter 17: Immunologic Diseases 226
Allergy 227
Serum Sickness 227
Generalized Anaphylaxis 227
Primary Immune Deficiencies 228
Secondary Immune Deficiencies 228
Connective Tissue Diseases 228

Chapter 18: Red and White Lesions of the Oral Mucosa 231
Classification of Red and White Lesions 231
Normal Variations 232
Non-keratotic White Lesions 233
Keratotic Lesions without Premalignant Potential 234
Hereditary Keratotic Lesions 236

Chapter 19: Oral Premalignant Lesions and Conditions 237
Leukoplakia 238
Erythroplakia 241
Palatal Changes Associated with Reverse Smoking 241
Oral Submucous Fibrosis 242
Lichen Planus 244
Syphilis 246
Sideropenic Dysphagia 246
Discoid Lupus Erythematosus 246
Dyskeratosis Congenita 247

Chapter 20: Oral Cancer and Principles of Radiotherapy **249**
Etiology of Oral Cancer 250
Mechanism of Carcinogenesis 250
TNM Classification and Staging of Oral Cancer 251
Investigations 251
Histopathology 251
Treatment of Oral Cancer 252
Oral Malignant Lesions Other than Oral Squamous Cell Carcinoma 254
Principles of Radiotherapy 258

Chapter 21: Benign Tumors and Tumor-like Lesions **261**
Tumor-like Lesions 261
Benign Tumors 263
Neurogenic Tumors 265
Benign Non-odontogenic Tumors 267
Vascular Tumors 267
Other Tumors 269
Glandular Lesions 270

Chapter 22: Odontogenic Tumors **272**
Epithelial Tumors 273
Mesenchymal Tumors 276
Mixed Tumors (Ectodermal-Mesodermal Tumors) 279

Chapter 23: Salivary Gland Disorders **282**
Functional Disorders 283
Developmental Disorders 283
Obstructive Disorders 283
Inflammatory and Infectious Diseases 286
Immunological Disorders 287
Neoplastic Diseases 291
Asymptomatic Enlargement 294
Miscellaneous Conditions 294
Evaluation of Salivary Glands 294

Chapter 24: Diseases of the Bone **297**
Diseases of the Bone 297
Malignant Non-odontogenic Tumors 301

Chapter 25: Nutritional Deficiencies and Metabolic Disorders **305**
Carbohydrates and Disturbances of Carbohydrate Metabolism 306
Fats and Disturbances of Lipid Metabolism 306
Proteins and Disturbances of Protein Metabolism 308
Water 309

Minerals and Trace Elements 309
Vitamins 310

Chapter 26: Disorders of the Endocrine System 313
Pituitary Gland 313
Thyroid Gland 314
Pancreas 315
Parathyroid Gland 316
Adrenal Gland 317
Pregnancy 317

Chapter 27: Pigmented Lesions of the Oral Mucosa 319
Endogenous Pigmentation 320
Exogenous Pigmentation 321
Miscellaneous Conditions 322

Chapter 28: Disorders of the Temporomandibular Joint and Trismus 324
Classification of Disorders of the TMJ 325
Examination of the Articulatory System 325
Etiology of TMJ Disorders 328
Degenerative Joint Disease 329
Rheumatoid Arthritis 329
Developmental Defects 330
Trismus 331

Chapter 29: Facial Pain 334
Classification of Orofacial Pain 335
Pain Arising from Teeth and Supporting Structures 335
Pain Arising from Neighboring Structures 336
Referred Pain from Remote Structures 337
Neuralgias 337
Vascular Pain 340
Muscular Pain 343
Psychogenic Pain 343
Glossodynia and Glossopyrosis 344

Chapter 30: Diseases of the Maxillary Sinus 345
Examination of the Sinus 346
Classification 347
Inflammatory Changes 348
Cysts of the Maxillary Sinus 349
Tumors 350
Trauma 351
Other Osseous Pathoses 352

Chapter 31: Blood Disorders **354**
Disorders of the Red Blood Cells 354
Disorders of the White Blood Cells 359
Leukemia 361
Lymphomas 363

Chapter 32: Hemorrhagic Disorders **366**
Normal Clotting Mechanism 366
Factors Responsible for Clotting Mechanism 368
Hemorrhagic Diseases 369

Chapter 33: Medical Problems in Dentistry **374**
Diseases of the Cardiovascular System 375
Diseases of the Respiratory Tract 384
Diseases of the Gastrointestinal Tract 388
Diseases of the Liver 389
Renal Diseases 391

Chapter 34: Acquired Immunodeficiency Syndrome **393**
Risk Group 394
Etiology 394
Immunopathogenesis 394
Clinical Manifestations 395
Classification of Oral Lesions Associated with HIV Infection 397
Diagnosis 398
Laboratory Investigations in the Detection of HIV Infection 398
Treatment 399
Prevention 400
Dental Considerations 401
Precautions to be Taken While Treating Patients with HIV Infection 401

Chapter 35: Hepatitis B **402**
Modes of Transmission 403
Laboratory Investigations 403
Serology of Hepatitis B 403
Precautions to be Taken While Treating HBV-infected Patients 405

Chapter 36: Corticosteroid Therapy in Dental Practice **406**
Action of Corticosteroids 407
Contraindications 407
Reactions Associated with Corticosteroid Therapy 407
Adverse Effects 407
Methods of Administration 407

Various Corticosteroid Preparations Available 409
Dental Considerations 409

Chapter 37: Laboratory Investigations in Dentistry **410**
Types of Laboratory Investigations 411

Chapter 38: Emergencies in Dental Practice **430**
ASA Physical Status Classification System 432
Unconsciousness 432
Vasodepressor Syncope 433
Postural Hypotension 434
Acute Adrenal Insufficiency 435
Airway Obstruction 436
Hyperventilation 437
Asthma 438
Heart Failure and Acute Pulmonary Edema 439
Cerebrovascular Accident 440
Seizures 441
Allergy 442
Chest Pain 443
Cardiac Arrest 443

Bibliography 445
Index 447

CHAPTER 4

Structure of the Oral Mucous Membrane

- Introduction
- Gingiva
- Buccal and Labial Mucosa
- Tongue
- Floor of the Mouth
- Retromolar Trigone
- Hard Palate
- Soft Palate
- Tonsillar Area
- Oropharynx
- Histology of Oral Mucosa
- Stomatitis

"Love all serve all
Help ever, hurt never
The hands that serve are better than the lips that pray."
—Sathya Sai Baba

INTRODUCTION

Mucous membrane is the lining of a body cavity that opens to the outside of the body. The oral mucous membrane can be divided into different areas based on functional and histological differences, such as the gingiva, buccal mucosa, labial mucosa, floor of the mouth, tongue, hard palate, and soft palate. The gingiva and the hard palate are lined by keratinized epithelium, the tongue is lined by specialized epithelium, and the other areas are lined by non-keratinized epithelium.

GINGIVA

Gingiva or "gums" covers the alveolar bone and is adherent to the periosteum of the alveolar bone and covers the roots of the teeth extending beyond the alveolar crest. The interproximal spaces between the teeth are also covered by gingiva. Gingiva is anatomically divided into three areas. The marginal gingiva or free gingival margin surrounds the teeth at the cervical region.

A potential space is present coronal to the marginal gingiva which is called the sulcus or gingival crevice. It has a depth of 1–2 mm. The part of the gingiva adherent to the bone is called the attached gingiva. Attached gingiva is stippled due to the connective tissue core projecting into the epithelium.

Beyond the gingiva, there is alveolar mucosa which covers the alveolar bone. The junction between the marginal gingiva and the attached gingiva is the mucogingival junction.

JAYPEE BROTHERS

BUCCAL AND LABIAL MUCOSA

The buccal mucosa and labial mucosa line the inner aspect of the cheeks and lips and are freely movable, covering the underlying loose connective tissues and adipose tissues as well as the musculature. The cheeks are thus musculomembranous structures and are limited superiorly and inferiorly by the upper and lower vestibule, anteriorly by the labial commissure and posteriorly by the retromolar trigone and the intermaxillary commissure.

The inner surface of both the upper and lower lips are attached to the corresponding gingiva by means of a fold of mucous membrane called frenum (labial frenum) (Fig. 4-1). The upper labial frenum is larger than the lower labial frenum.

The retrocommissural region is located between the labial commissure and the opening of Stenson's duct (opening of the parotid duct). It is located opposite to the second maxillary molar. The opening of the parotid duct is guarded by a soft tissue flap which is known as the parotid papilla. Anteriorly the buccal mucosa merges with the labial mucosa.

A horizontal and slightly elevated streak or line may be seen extending from the corners of the mouth and running posteriorly. This line corresponds to the level of occlusion between the upper and lower teeth. This line is called ***linea alba buccalis*** (Fig. 4-2). It corresponds to the line of occlusion where the upper and lower teeth meet. It is not a pathology and is considered on a normal variation.



Fig. 4-1 Labial frenum (upper).



Fig. 4-2 Linea alba buccalis.

The buccinator muscle forms the muscular framework of the check and is also a muscle of facial expression. It is covered by the buccal pad of fat. The buccal pad of fat is more prominent in infants and may be due to the suckling. The buccal pad of fat also smoothes the cheek contour by filling the depression and the anterior border of the masseter.

The masseter muscle covers the buccinator muscle. The other muscles contributing in the formation of cheek are the zygomaticus, risorius, and platysma.

Lips show a mucocutaneous junction which separates the mucosal and skin surfaces at the vermilion border.

TONGUE

The tongue is a muscular organ and helps in taste sensation, speech, mastcation, and swallowing. It is completely covered by a mucous membrane. It occupies most of the oral cavity and oropharynx. The tongue has a complex innervation by five cranial nerves (Fig. 4-3).

The tongue also plays an erotic role in sexual activity. In the newborn and infants, the tongue forms an important organ in the sensory perception and in the emotional satiation.

The tongue has three surfaces, the tip, body, and base. The tip is the highly mobile, pointed

JAYPEE BROTHERS

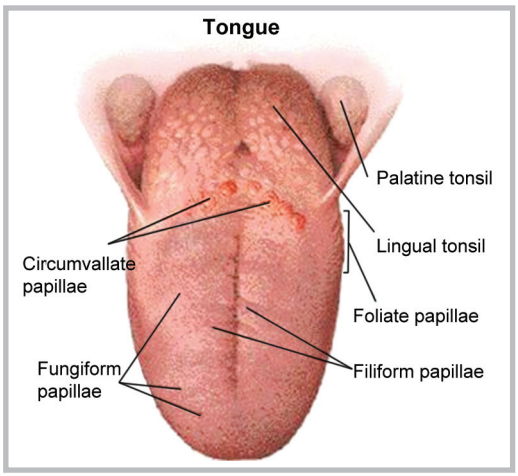

Fig. 4-3 Anatomy of tongue.

anterior part of the tongue. Posterior to the tip there is body of the tongue which has a dorsal (superior) and ventral (inferior) surfaces.

The median sulcus of the tongue separates the body into left and right halves. The terminal sulcus or groove is V-shaped and separates the anterior two third of the tongue (or the body) and base (or the root) of the tongue. The base of the tongue contains the lingual tonsils or the innermost part of the Waldeyer's ring.

The tongue has four intrinsic and four extrinsic muscles. The muscles in each side of the tongue are separated by a fibrous lingual septum. Extrinsic muscles originate outside the tongue and are inserted within it, whereas, the intrinsic muscles originate within the substance of the tongue. The muscles are unable to act in isolation.

The shape of the tongue is mainly altered by the intrinsic muscles and the position of the tongue is altered by the extrinsic muscles. The intrinsic muscles also help in forming the bulk of the tongue.

The following are the intrinsic muscles of the tongue:

Intrinsic Muscles

- Superior longitudinal
- Inferior longitudinal
- Transverse
- Vertical.

Extrinsic Muscles

- Genioglossus
- Hyoglossus
- Styloglossus
- Palatoglossus.

The dorsal surface of the tongue is roughened due to the presence of lingual papillae. These are projections of lamina propria covered with epithelium. The lingual papillae are: (a) filiform papillae, (b) fungiform papillae, (c) circumvallate papillae (vallate papillae), and (d) foliate papillae.

Filiform Papillae

Filiform papillae are small and punctate in appearance They are also thin and long. They are the most abundant papillae. These papillae are not involved in the taste perception.

Fungiform Papillae

Fungiform papillae are seen scattered in between the filiform papillae and they appear more reddish in color. They are mushroom-shaped and are dispersed most abundantly along the tip and lateral surfaces of the tongue. There are about 200-300 fungiform papillae.

Circumvallate Papillae

Circumvallate papillae are arranged in a 'V'-shaped configuration anterior to the sulcus terminalis, at the junction between the anterior two-thirds, and posterior one-third of the tongue. They are about 8–10 in number. Because of their prominence and larger size, they may be mistaken for pathology (Fig. 4-4).

Foliate Papillae

The foliate papillae are small folds of mucosa located along the lateral surface of the tongue.

JAYPEE BROTHERS



Fig. 4-4 Circumvallate papillae.



Fig. 4-5 Foliate papillae.

They are red, irregularly shaped masses present on the lateral aspect of the tongue (Fig. 4-5).

The circumvallate, foliate, and fungiform papillae contain taste buds which help in the taste perception. The vallate papillae contain about 250 taste buds, the foliate papillae about 1,000 and the fungiform papillae about 1,600 tastebuds.

The mucosa of the ventral surface of the tongue merges with the mucosa of the floor of the mouth. A fold of mucous membrane, the lingual frenum, runs from the ventral surface of the tongue to the floor of the mouth.

Taste Buds

Taste buds are present in the lingual papillae as well as in the mucosa of the soft palate and pharynx. A taste bud is made up of taste cells and

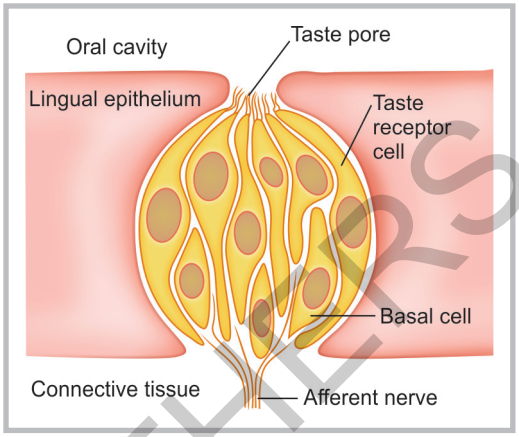

Fig. 4-6 Structure of a taste bud.

supporting cells (sustentacular cells) (Fig. 4-6). The supporting cells surround an opening directed towards the epithelial surface called the inner taste pore. The taste pore communicates with an opening on the squamous epithelial layer called the outer taste pore.

Each taste bud contains 5–20 taste cells. Taste cells are thin columnar cells and the supporting cells are wider. Nerve fibers enter the taste buds and form a network of branches running between taste cells and supporting cells. All the taste buds can perceive the five types of taste, namely, sweet salt, bitter, sour, and umami (***umami*** is a new type of taste) (Fig. 4-7). Each taste bud consists of taste receptor, basal cells and edge cells.

When a taste molecule binds to a taste receptor, it undergoes depolarization leading to an influx of Ca^{++}. This results in release of a neurotransmitter, the nature of which is not known. The neural pathway is dependent on the location of the taste bud that was stimulated.

The chorda tympani branch of the facial nerve (VII cranial nerve) helps in the taste perception from the anterior two-thirds of the tongue, whereas the lingual-tonsillar branch of the glossopharyngeal nerve (cranial nerve IX) relays the taste information from the posterior one third of the tongue.

JAYPEE BROTHERS

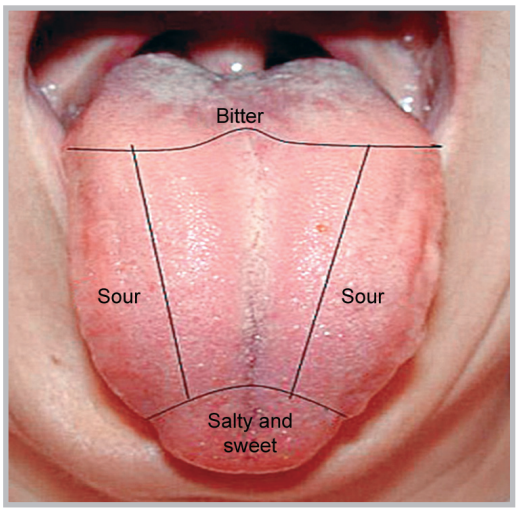

Fig. 4-7 Taste areas.

FLOOR OF THE MOUTH

Floor of the mouth is located beneath the tongue and it forms the inferior limit of the oral cavity (Fig. 4-8). Floor of the mouth is lined by a thin epithelium. It covers the mylohyoid and geniohyoid muscles. Anteriorly it merges with lingual portion of the gingiva.



Fig. 4-8 Floor of the mouth.

There is a 'V'-shaped ridge in the floor of the mouth and at the summit is a thin strip of tissues called the lingual frenulum or frenum. On the V-shaped ridge, there are openings of the ducts of the submandibular (***Wharton's duct***) and sublingual salivary glands that are located close to each other. Sublingual papillae or caruncles or folds are located on both the sides of the frenulum.

The excretory duct of the submandibular salivary gland runs in the floor of the mouth along the medial border of the sublingual salivary gland to pierce the surface of the mouth at the paramedian sublingual caruncle. The sublingual salivary glands have multiple small ducts that drain directly into the mouth. The tongue is attached to the floor of the mouth by means of a soft tissue fold which is known as the lingual frenulum.

The anterior third of the tongue is usually free or it is partially attached to the floor of the mouth by the lingual frenulum. There is a spectrum ranging from fusion of the tongue to the floor of the mouth (***ankyloglossia***) to a lingual frenulum that is short or anchored toward the tip of the tongue (***tongue tie***).

RETROMOLAR TRIGONE

The retromolar trigone is a small triangular-shaped area of the oral cavity. It is the area of the mucosa that lies behind the third molar tooth and covering the ramus of the mandible (ascending ramus) (Fig. 4-9). It is continuous with the maxillary tuberosity. The pterygomandibular raphae, under the mucosa of the retromolar trigone connects the pterygoid process of the sphenoid bone with the mylohyoid ridge of the mandible. On this raphae, the buccinators muscle and superior pharyngeal constrictor muscle are attached. Location wise, the retromolar trigone is located at the junction of the oropharynx, nasopharynx, buccal space, floor of the mouth, and parapharyngeal space.

The base of the triangle is posterior to the last molar tooth, the apex is continuous with the

JAYPEE BROTHERS



Fig. 4-9 Retromolar trigone.

maxillary tuberosity behind the maxillary third molar tooth. The retromolar trigone is bounded laterally by the gingival sulcus and medially by the anterior tonsillar pillar.

The retromolar trigone is frequently involved by the lateral extension of oropharyngeal malignancies.

HARD PALATE

Hard palate is horseshoe-shaped and separates the nasal cavity and the oral cavity into two separate compartments (Fig. 4-10). It is basically a thin horizontal bony plate located in the roof of the mouth. It also spans the arch formed by the upper teeth. The hard palate is concave in shape and mostly occupied by the tongue in rest. The palate is divided into the primary and secondary palates.

The primary palate is separated from the secondary palate by a small depression behind the central incisors which is called the incisive fossa where the incisive foramen opens.

The anterior two-thirds of the hard palate is formed by the incisive bone or premaxilla and the palatine process of the maxilla. The horizontal plates of the palatine bone forms the



Fig. 4-10 Hard palate.

posterior third. The secondary palate presents an elevated suture line in the midline which is called the median palatine raphae or mid-palatine raphae or palatine raphae.

Anterior part of the hard palate contains rugae. Rugae are irregular ridges in the mucous membrane and it facilitates retention of the food bolus and movement of food bolus towards the pharynx. The hard palate continues posteriorly into the mouth as a fleshy part which is known as the soft palate. The basic functions of the hard palate may be food intake and speech. The palatal mucosa covers the underlying connective tissue and is firmly adherent on the underlying bone.

Numerous mucous glands are present below the palatal mucosa and opening on the surface as small dots. In the anterior region of the hard palate many folds of firm tissue are seen which are called the rugae.

The palate has four anatomic regions. These are the following:

- Gingival region adjacent to the teeth
- Palatine raphae extending from the incisive papilla posteriorly, along the midline
- Anterolateral fatty zone
- Postero-lateral glandular zone.

Some of the commonest disorders that can affect the hard palate are the following:

- Developmental disorders, such as cleft palate

JAYPEE BROTHERS

- Torus palatines
- Cysts and tumors
- Stomatitis nicotina palatinae
- Smoker's palate
- Palatal changes associated with reverse smoking
- Leukoplakia
- Pemphigus
- Oral candidiasis (denture stomatitis)
- Palatal papillary hyperplasia
- Perforation of palate as it occurs in syphilis
- Viral infections, such as measles.

SOFT PALATE

The soft palate is also known as the velum or muscular palate. The anterior surface of the soft palate is concave when relaxed. It is present posterior to the hard palate. It is movable as it does not contain bone. It consists of muscle fibers and connective tissue sheathed in mucous membrane. It closes the nasal passage (nasal cavity) and airway (nasal part of the pharynx) during swallowing.

The mobility and support to the soft palate is provided by the muscular and connective tissue content. During the act of sneezing, it protects the nasal passage by diverting a portion of the excreted substance to the mouth. It is possible for the soft palate to retract and elevate during speech to separate the oral cavity from the nasal cavity to produce the oral speech sounds. If this separation is incomplete, air escapes through the nose, resulting in nasal quality of the speech.

More posteriorly as a continuation of the soft palate in the midline there is uvula. Laterally, there are two bilateral processes called the palatoglossal and palatopharyngeal arches or pillars. The palatoglossal arch connects the soft palate to the tongue and the palatopharyngeal arch connects the soft palate to the pharynx. It hangs from the end of the soft palate. The fauces are space between the cavity of the mouth and the oropharynx. They are bounded superiorly by the soft palate, inferiorly by the root of the tongue, and laterally by the pillars of the fauces (Fig. 4-11).

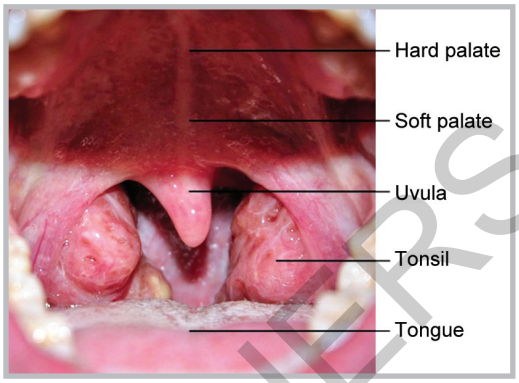

Fig. 4-11 Structures in the roof of the mouth.

The following are the muscles of the soft palate:

- Tensor veli palatine
- Palatoglossal
- Palatopharyngeal
- Levator veli palatine
- Musculus uvulae.

Levator veli palatine and tensor veli palatine are involved in elevating the soft palate during swallowing.

Some of the pathological lesions that can affect the soft palate are the following:

Mucosal Lesions

- Pemphigus vulgaris
- Herpangina
- Stomatitis
- Streptococcal pharyngitis
- Petechiae.

Muscular Conditions

- Cleft palate
- Cleft uvula.

TONSILLAR AREA

Palatine tonsils are present bilaterally within the glossopalatine arch and pharyngopalatine arch. The areas between these two arches are called fauces. These arches are also called as anterior

JAYPEE BROTHERS



Fig. 4-12 Tonsillar area.



Fig. 4-13 Oropharynx.

and posterior pillars of fauces, respectively. The palatine tonsils are ovoid mass of lymphoid tissue located in the oropharynx between the anterior and posterior pillars (Fig. 4-12).

The tonsils have a protective function as it prevents the entry of pathogens through the nasal and oral route. The crypts on the surface of the tonsils serve to increase the surface area and increase the efficiency of protection against the microorganisms or pathogens. They also form a part of ***Waldeyer's ring*** or lymphatic ring.

Waldeyer's lymphatic ring consists of lymphoid tissue present in the neck (Waldeyer's outer ring) and pharynx (Waldeyer's inner ring or tonsillar ring).

The Waldeyer's outer ring is composed of various lymph nodes in the neck, mostly the cervical lymph nodes, such as the occipital, posterior auricular, preauricular, parotid, facial, submandibular, submental, superficial cervical, and anterior cervical.

Waldeyer's inner ring is in the nasopharynx and oropharynx. It consists of the adenoids (nasopharyngeal tonsil), tubal tonsil, palatine tonsil, and lingual tonsil.

OROPHARYNX

Oropharynx or the oral part of the pharynx lies between the nasopharynx and laryngeal pharynx and extends from the soft palate to the level of the hyoid bone (Fig. 4-13). It is also sometimes referred to as the mesopharynx. It opens anteriorly through isthmus faucium into the mouth. In its lateral wall, between the two palatine arches, the palatine tonsil is present.

The anterior wall of oropharynx is constituted by the base of the tongue and the epiglottic vallecula; the lateral wall is formed by the tonsil, tonsillar fossa, and tonsillar or faucial pillars; the superior wall consists of the inferior surface of the soft palate and the uvula.

There are aggregations of lymphoid tissue within the mucosa.

HISTOLOGY OF ORAL MUCOSA

Keratinizing or Orthokeratinizing Epithelium

Keratinizing or orthokeratinizing epithelium which lines the masticatory mucosa has four cell layers (Fig. 4-14). These are the following:

- Stratum basale
- Stratum spinosum
- Stratum granulosum
- Stratum corneum.

A single cell originating in the basal layer is at times part of each cell layer and keratinization takes place as it reaches the surface. The basal cell layer is capable of mitosis. Hence the basal cell layer and parabasal cell layer are collectively called as stratum germinativum. The adjacent

JAYPEE BROTHERS

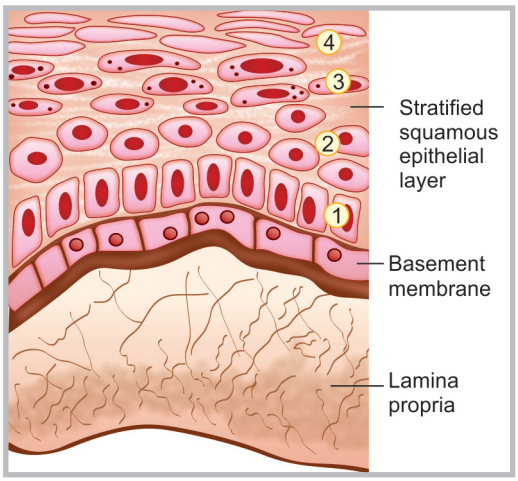

Fig. 4-14 Structure of keratinized oral mucosa. 1. Stratum basale; 2. Stratum spinosum; 3. Stratum granulosum; 4. Stratum corneum.

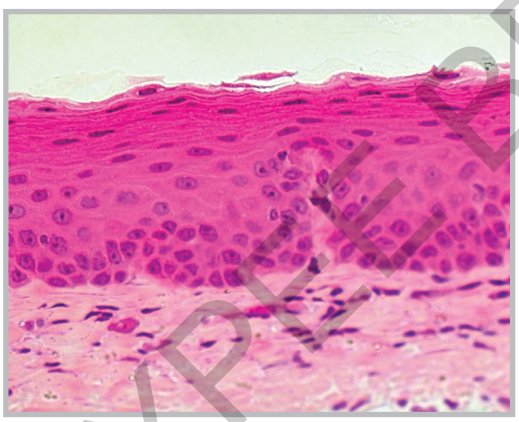

Fig. 4-15 Histology of keratinizing epithelium.

basal cells are united by desmosomes. The spinous cells (stratum spinosum) are irregularly polyhedral and are larger. The adjacent cells are united together by desmosomes with tonofilament bundles (Fig. 4-15).

The space between the cells contains glycoprotein, glycosaminoglycans, and fibronectin. The cells are capable of protein synthesis. The cells in the stratum granulosum are flatter and wider and contain keratohyaline granules. The nuclei exhibit varying degrees of degeneration and pyknosis. The tonofilaments are more and are densely organized. Stratum corneum contains keratinized squame which are flatter and larger in size, devoid of nuclei, ribosomes, and mitochondria.

Cells of the stratum corneum are made up of densely packed filaments derived from tonofilaments and coated by a protein (filaggrin) of the keratohyaline granules. Cells of the parakeratinized epithelium exhibit presence of nuclear remnants which have pyknotic and condensed nuclei.

Non-keratinizing Epithelium

The non-keratinizing epithelium has three layers (Fig. 4-16). These are the following:

- Stratum basale
- Stratum intermedium
- Stratum superficiale.

The cells of the basal layer are similar to that of keratinized epithelium, but the cells of the stratum intermedium are bigger than the cells of the stratum spinosum. The cells do not have obvious intercellular spaces and are attached by desmosomes. The cells approximate closely. The surface layer of the cells are nucleated. The thickness of the epithelium is variable, In the buccal mucosa, the epithelium is relatively thick, whereas in the floor of the mouth it is quite thin (Fig. 4-17).

The basal and the suprabasal layers of the oral mucosa contain Langerhans cells, Merkel cells,

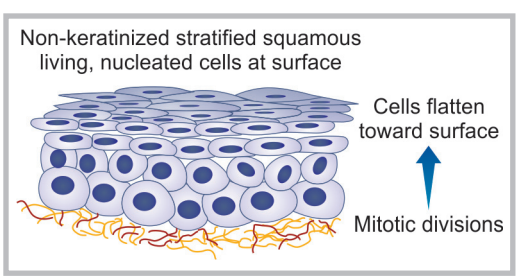

Fig. 4-16 Structure of non-keratized stratified squamous epithelium.

JAYPEE BROTHERS

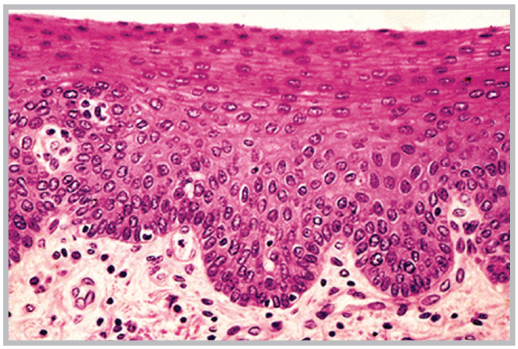

Fig. 4-17 Histology of non-keratinizing epithelium.

and melanocytes. The Langerhans cells are concerned with immunity, the Merkel cells are associated with intraepithelial nerve endings, and the melanocytes are associated with the synthesis of melanin.

Lamina Propria

Lamina propria is the connective tissue component of the epithelium that is present beneath the epithelial layer. It has two parts, the papillary and reticular zones.

Though the reticular portion is always present, the papillary zone may be absent in areas, such as the alveolar mucosa where it may be absent or short. As there is corrugation and interlocking at the junction of the epithelium and connective tissue, exchange of materials is facilitated. The lamina propria may be attached to the periosteum or it may be present over the submucosa.

The underlying connective tissue is separated from the epithelium by a basement membrane. Histologically, the lamina propria is similar in structure and composition to that of the dermis of the skin. However, the interface between the mucosal epithelium and the connective tissue in case of non-keratinizing epithelium is fairly flat compared to the skin or masticatory mucosa. In the keratinizing epithelium, the epithelial ridges and connective tissue papillae are long and numerous. It may be related to the need to withstand the abrasive forces during mastication. Apart from keratinized epithelium and complex epithelial-connective tissue junction, the lamina propria of masticatory mucosa is often directly attached to the periosteum of the underlying alveolar bone or the palatal bone (in case of maxilla). Hence, submucosa is absent. This structure is called as mucoperiosteum. In the posterolateral region of the hard palate, however, there is submucosa containing adipose tissue and numerous minor salivary glands.

The common cell type in lamina propria is the fibroblast. Other cell types are macrophages and mast cells. In case of inflammation, neutrophils, lymphocytes, and plasma cells may also be seen.

Type I collagen is the predominant fiber component of the extracellular matrix in the epithelium. Both type III collagen and elastic fibers are found in the lamina propria and submucosa.

Submucosa

Submucosa is made up of varying amounts of connective tissue. The thickness of the connective tissue differs based on the mobility of the mucous membrane. It helps in attaching the epithelium to the underlying structures. This layer contains glands, blood vessels nerves, and adipose tissue. Submucosa may not be consistently present.

STOMATITIS

Stomatitis refers to the inflammation of the oral mucous lining or oral mucosa of the mouth, which may involve the buccal mucosa, gingiva, tongue, labial mucosa, and roof or floor of the mouth. The literal meaning of the word "stomatitis" is inflammation of the mouth (Fig. 4-18). The inflammation can be caused by certain factors of local origin as well by certain factors of systemic origin.

JAYPEE BROTHERS



Fig. 4-18 Stomatitis.

Etiology

- Poor oral hygiene
- Ill-fitting dentures
- Burns due to intake of hot beverages
- Certain medications
- Allergic reactions
- Nutritional deficiencies
- Dental restorative materials
- Infections due to bacteria, viruses, fungi, etc. Poorly fitted oral appliances
- Cheek biting
- Sharp margins of the teeth
- Chronic mouth breathing can cause dryness of the mouth tissues, which in turn can lead to irritation
- Diseases, such as herpetic infections, recurrent aphthous stomatitis, gonorrhea, measles, leukemia, and HIV infections
- Vitamin C and B complex deficiency can present with stomatitis
- Inflammatory bowel disease
- Behçet's syndrome which is an inflammatory multisystem disorder of unknown cause.
- Generalized or contact stomatitis can result from excessive use of alcohol, spices, hot food, or tobacco products
- Sensitivity to mouthwashes, toothpastes, and lipstick can cause irritation of the lining of the mouth
- Exposure to heavy metals, such as mercury, lead, or bismuth can also cause stomatitis
- Thrush, a fungal infection caused by *Candida albicans*, is a type of stomatitis.

Stomatitis is an inflammation of the lining of any of the soft-tissue structures of the mouth. Stomatitis is usually a painful condition, associated with redness, swelling, and occasional bleeding from the affected area. Halitosis or bad breath may also accompany the condition. Stomatitis can affect all age groups.

Diagnosis

History is important in identifying the etiological factor, such as dietary deficiency, a systemic disease, or contact with materials causing an allergic reaction.

Blood tests may be done to determine if any infection is present. Scrapings of the lining of the mouth may be sent to the laboratory for microscopic evaluation, or cultures of the mouth may be done to determine if an infectious agent may be the cause of the problem.

Treatment

The treatment of stomatitis is based on the problem causing it. Therefore, elimination of the etiological factor is very important. Local cleansing and maintenance of good oral hygiene are fundamental. Rough and crunchy foods must be avoided. Using soft brushes minimize trauma to the oral mucosa. Excessive intake of spicy food must be avoided.

Local factors, such as ill-fitting dental appliances or sharp teeth must be corrected. Systemic problems, if any, must be treated.

Aphthous stomatitis can be treated with tetracycline antibiotics or corticosteroids. Valacyclovir has been shown to be effective in treating stomatitis caused by herpesviruses.

Patients may also be given topical anesthetics (usually a 2% lidocaine gel) to relieve pain and a protective paste (Orabase) or a coating agent like Kaopectate to protect eroded areas from further irritation from dentures, orthodontic appliances, or teeth.

JAYPEE BROTHERS

Researchers in Brazil have reported that an extract made from the leaves of *Trichilia glabra*, a plant found in South America, is effective in controlling viruses that cause stomatitis.

SELF-ASSESSMENT TEST

1. Write a note on gingival in health.
2. Which are the papillae present on the tongue?
3. Describe the histology of keratinizing or orthokeratinizing epithelium.
4. Describe the histology of non-keratnizing epithelium.
5. What is lamina propria?

JAYPEE BROTHERS

r detailed information of dental books, visit our website www.jaypeebrothers.com, for detailed information of dental books, visit our website www.jaypeebrothers.com, for detailed information of dental books, visit our website

Textbook of
ORAL MEDICINE

Textbook of Oral Medicine is the third edition of the original title *Handbook of Oral Medicine*. The book has been updated with all the latest information available and is up-to-date in all respects. Numerous color pictures have been added so as to provide a better idea of the clinical presentation of the oral diseases. Newer and scientifically accepted classifications and terminologies have been used. The book will be of immense help to undergraduate and postgraduate students of dentistry as well as medical students. The simple style of explaining the text and point-wise presentation of information will greatly enhance the learning experience. This would boost the photographic memory to grasp and retain the content to effectively reproduce the same in the written and oral examinations.

Pramod John R is a Senior Professor of oral medicine and radiology and has done his graduation and postgraduation from the prestigious College of Dental Surgery, Manipal, Karnataka, India. After his postgraduation, he continued to serve as faculty in the Manipal and Mangalore campuses of the College of Dental Surgery for a long time. After serving as Professor and Head in the Department of Oral Medicine and Radiology in Mahatma Gandhi Postgraduate Institute of Dental Sciences, Puducherry, he joined Amrita School of Dentistry (a constituent institution of Amrita Vishwa Vidyapeetham University) as Professor and Head in the Department of Oral Medicine and Radiology. He is still serving in the same institution. He is an accomplished academician having many years of undergraduate and postgraduate teaching experience. He serves as an undergraduate and postgraduate examiner of various universities. He is also invited as a guest speaker in many scientific meetings and conferences. He was also served as an Editor of *Journal of Indian Dental Association*.

Shelving Recommendations
DENTISTRY, MEDICINE

ISBN 978-93-5090-850-1
9 789350 908501

Available at all medical book stores or buy directly from Jaypee Brothers through online shopping at www.jaypeebrothers.com

JAYPEE BROTHERS
Medical Publishers (P) Ltd.
www.jaypeebrothers.com