com, for detailed information on nursing books, visit our website www.jaypeebrothers.com, for detailed information on nursing books



Textbook of GYNECOLOGY for Nurses

Anupama Tamrakar

Foreword
Khagendra Bhattarai

JAYPEE

Contents

1. Anatomy and Physiology of Female Reproductive Organs 1
External Genitalia 1
Internal Genital Organs 3
Menstruation 13
Pelvic Floor 15
Anatomy of Other Organs Related to Gynecology 18

2. Examination of a Gynecological Patient 30
History Taking 30
Examination of Patient 32
General and Systemic Examination 32
Gynecological Examination 33
Other Diagnostic Tests 37
Liquid-based Cytology 43
Imaging Technologies in Gynecology 49
Culdocentesis 55
Breast Examination 61
Laser in Gynecology 64

3. Development of Genital Organs and Gonads 66
Development of External Genital Organs 66
Development of Internal Genital Organs 67

4. Congenital Malformations of Female Genital Organs 74
Development of Reproductive Organs (Embryology) 74
Uterine Malformations 74
Vaginal Abnormalities 81
Ectopic Ureter 88

5. Menopause 90
Age of Menopause 90
Overview 91
Causes of Menopause 91
Menopause Symptoms 92
Complication of Menopause 94
Diagnosis of Menopause 95
Prevention 95

Management 96
Treatment 96
Overall Management of Menopause and Abnormal Menopause 100
Nursing Management of the Women with Menopause and Abnormal Menopause 102

6. Disorders of Menstrual Cycles 104
Dysmenorrhea (Menstrual Cramps, Painful Menstruation) 104
Mittelschmerz Syndrome 109
Pelvic Congestion Syndrome 110
Premenstrual Syndrome 111
Amenorrhea 115
Nursing Management of a Patient with Menstrual Disorders 125

7. Abnormal Uterine Bleeding 129
Menorrhagia 129
Polymenorrhea (Frequent Periods) 134
Hypomenorrhea 136
Oligomenorrhea 137
Metrorrhagia 137
Dysfunctional Uterine Bleeding 138
Changes in the Uterus in Dysfunctional Uterine Bleeding 142
Changes in the Ovary in Dysfunctional Uterine Bleeding 143
Postmenopausal Bleeding 150

8. Displacement of the Uterus 154
Position of the Uterus 154
Retroverted Uterus 154
Uterine Inversion 158
Acute Inversion of Uterus 159
Chronic Inversion of Uterus 162
Nursing Management of Patient with Displacement of Uterus 163

9. Pelvic Organ Prolapse 165
Risk Factor 165
Types 166
Nursing Management of the Client with Pelvic Organ Prolapse 183

10. Genital Fistulae 186
Genitourinary Fistula 186
Vesicovaginal Fistula 186
Urethrovaginal Fistula 195

Ureterovaginal Fistula 196
Rectovaginal Fistula 197
Lifestyle and Home Remedies 202
Nursing Management 203

11. Pelvic Inflammatory Diseases 205
Incidence 205
Causative Organisms 205
Causes 206
Mode of Infection 206
Pathophysiology 206
Risk Factors 206
Clinical Features 207
Diagnosis 208
Laboratory Investigations 208
Prognosis 209
Complications 209
Prevention 209
Treatment 209
Patient Education to Prevent Reinfection 211
Chronic Pelvic Infection (Chronic PID) 211
Genital Tuberculosis 212
Tuberculosis of the Pelvis 214
Tuberculosis of the Fallopian Tubes 214
Tuberculosis of the Uterus 215
Tuberculosis of the Ovaries 216
Tuberculosis of the Cervix 216
Tuberculosis of Vulva and Vagina 217
Tuberculous Peritonitis 217

12. Infections of Pelvic Organs 225
Endometritis 225
Salpingitis 228
Oophoritis 232
Cervicitis 234
Pelvic Abscess 238
Parametritis 239
Vulvitis 240
Vaginitis 242
Bartholinitis 246

Treatment 248
Nursing Process 250

13. Sexually Transmitted Infections 253
Epidemiology 253
Consequences of Sexually Transmitted Infections 253
Sexually Transmitted Infections and its Outcome in Pregnancy 254
Common Sexually Transmitted Infections 254
Nursing Process 292

14. Infertility 297
Classification 297
Prevalence 298
Causes 298
Unexplained Infertility 305
Diagnosis of Infertility 306
Diagnosis in Male 306
Laboratory Investigations for Male 306
Diagnosis in Female 309
Laboratory Examinations for Female 309
Treatment of Infertility 313
Treatment of Male Infertility 314
Treatment in Female Infertility 315
Ovulatory Dysfunction 316
Treatment for Tubal Damage 321
Treatment for Endometriosis 322
Treatment of Uterine Problems 323
Treatment of Cervical Mucus Hostility 323
Treatment for Immunological Infertility 324
Immunotherapy 324
Treatment for Unexplained Infertility 325
Assisted Reproductive Technology 326
Artificial Insemination 326
Methods of Surgical Sperm Retrieval 329
In Vitro Fertilization and Embryo Transfer 330
Gamete Intrafallopian Transfer 335
Zygote Intrafallopian Transfer 336
Intracytoplasmic Sperm Injection 336
Embryo or Oocyte Donation 337
Surrogacy and Adoption 339

15. Benign Lesions of Genital Tract 342
Benign Vulvar Lesions 342
Non-neoplastic Epithelial Disorders 342
Inflammatory Diseases 342
Pigmentary Changes 345
Vulvar Ulcers 346
Benign Lesions of the Cervix 352
Benign Lesions of the Uterus 354
Benign Lesions of the Ovary 362

16. Endometriosis and Adenomyosis 373
Endometriosis 373
Adenomyosis 385

17. Genital Malignancy 389
Vulval Carcinoma 389
Bartholin's Gland Carcinoma 394
Vaginal Carcinoma 394
Cervical Cancer 397
Endometrial Carcinoma 401
Choriocarcinoma 404
Malignant Cancer 405
Ovarian Cancer 406
Fallopian Tube Carcinoma 410
Nursing Management of Genital Malignancy 413

18. Breast Disorders 414
Development of Breast 414
Anatomy of Breast 414
Anatomical Defects of the Breast 415
Mastalgia (Breast Pain) 416
Breast Lump 418
Galactorrhea 419
Drugs That Raise Prolactin 419
Benign Tumors in Breast 421
Breast Cancer 422
Nursing Process 427
Exercises After Breast Surgery 428

19. Genital Tract Injuries 437
Genital Injuries 437
Old Complete Perineal Tear 437

Coital Injuries 440
Rape Victims 440
Direct Trauma 441
Foreign Bodies 441
Instrumental Injuries 442

20. Urinary Problems in Gynecology 443
Urinary Incontinence 443
Types 445
Stress Incontinence 445
Urge Incontinence 449
Functional Incontinence 452
Overflow Incontinence 452
Stress and Urge Incontinence 453
Transient Incontinence 453
Nursing Process of a Patient with Urinary Incontinence 453
Voiding Disorders 453
Urinary Tract Infection 457
Frequent or Urgent Urination 460
Dysuria 461
Nursing Process (Patient with Lower UTI) 464
Urethral Caruncle 466

21. Intersex 469
Nomenclature 469
Classification 469
Examinations and Tests 479
Treatment 480

22. Contraception 482
Benefits of Contraception 482
Methods of Contraception 482
Temporary Methods 482
Parenteral Steroidal Contraceptives 502
Permanent Methods 509
Emergency Contraception 515

23. Radiotherapy, Chemotherapy, Immunotherapy and Gene Therapy in Gynecology 518
Radiotherapy 518
Chemotherapy 528

Immunotherapy 540
Genes 542

24. Hormonal Therapy in Gynecology 545
Estrogens 545
Antiestrogens 547
Progesterone 548
Antiprogesterone 549
Androgens (Testosterone/Antigonadotropins) 551
Antiandrogen 553
Gonadotropin-releasing Hormone 555

25. Gynecological Problems from Birth to Adolescence 559
Anatomy 559
Physiology 559
Gynecological Problems 559
Neonates, Toddlers and Infants 559
Premenarchal Disorders 561
Postmenarchal to Adolescence 566

26. Special Topics 570
Abnormal Vaginal Discharge 570
Pelvic Pain 574
Psychosexual Problems 578

27. Operative Gynecology 591
Preoperative Management 591
Day Care Surgery 594
Intraoperative Care 594
Postoperative Management 597
After Surgery: Discomforts and Complications 601
Gynecological Operations 602
Major Surgical Operations 607
Operations of the Ovary 614

Index 621

Chapter 4

Congenital Malformations of Female Genital Organs

DEVELOPMENT OF REPRODUCTIVE ORGANS (EMBRYOLOGY)

The uterus develops from the two paramesonephric ducts (müllerian ducts). The caudal two thirds of these ducts give rise to the uterus and the upper third become the fallopian tubes. The development of the uterus is divided into three stages:

1. Weeks 6 to 9: The appearance of müllerian ducts and their caudal midline fusion and connection with urogenital sinus.
2. Weeks 10 to 13: The upward fusion of the caudal parts of the müllerian ducts.
3. Weeks 14 to 18: The resorption of the medial septum initially separating the caudal parts of the müllerian ducts to form the uterovaginal channel, as the origin of both uterine cavity and superior two thirds of the vagina.

Two paired müllerian ducts ultimately develop into the structures of the female reproductive tract. The structures include the fallopian tubes, uterus, cervix and upper two thirds of the vagina. The ovaries and lower one third of the vagina have separate embryologic origins not derived from the müllerian system. The ovaries are derived from germ cells that migrate from the primitive yolk sac into the mesenchyme of the peritoneal cavity and subsequently develop into ova and supporting cells. The lower vagina arises from the sinovaginal bulb, which fuses with the müllerian-derived upper two-thirds to form the complete vagina.

Four Other Important Facts

1. As the superior two-thirds of the vagina have the same embryologic origin as the uterus, uterine malformations are often associated with upper vaginal malformations.
2. Genital anomalies are often associated with urinary tract anomalies (kidneys, urethra) due to close embryological interactions.
3. The independent ovarian and müllerian ducts development explains the, generally normal ovarian morphology and function in the cases of uterovaginal developmental anomalies.
4. The uterine malformations are usually not associated with chromosomal or sexual differentiation anomalies.

UTERINE MALFORMATIONS

A uterine malformation is the result of an abnormal development of the müllerian duct(s)

JAYPEE BROTHERS

during embryogenesis. Symptoms range from amenorrhea, infertility, recurrent pregnancy loss and pain, to normal functioning depending on the nature of the defect.

Prevalence

The prevalence of uterine malformation is estimated to be 6.7 percent in the general population, slightly higher (7.3%) in the infertility population and significantly higher in a population of women with a history of recurrent miscarriages (16%). These relatively frequent pathologies are often revealed at the time of the first sonographic examination in early pregnancy. The prevalence of the particular types of the uterine malformations is difficult to estimate. However, the septate uterus seems to be the most frequent anomaly accounting for 30% to 50% of all the cases, followed by the bicornuate uteruses and unicornuate uteruses respectively.

Complete formation and differentiation of the müllerian ducts into the segments of the female reproductive tract depend on completion of three phases of development as follows.

Organogenesis

One or both müllerian ducts may not develop fully between 6th and 9th week, resulting in abnormalities such as uterine agenesis or hypoplasia (bilateral) or unicornuate uterus (Fig. 4.1) (unilateral).

Fusion

The process during which the lower segments of the paired müllerian ducts fuse to form the uterus, cervix and upper vagina is termed lateral fusion. Failure of fusion between 10th and 13th week, results in anomalies such as bicornuate or didelphys uterus (Fig. 4.2). The term vertical fusion occasionally is used to refer to fusion of the ascending sinovaginal bulb with the descending müllerian system (i.e. fusion of the lower one third and upper two thirds of the vagina). Complete vertical fusion forms a normal patent vagina, while incomplete vertical fusion results in an imperforate hymen.

Septal Resorption

After the lower müllerian ducts fuse, a central septum is present, which subsequently must be resorbed to form a single uterine cavity and cervix. Failure of resorption between 14th and 18th week is the cause of septate uterus.

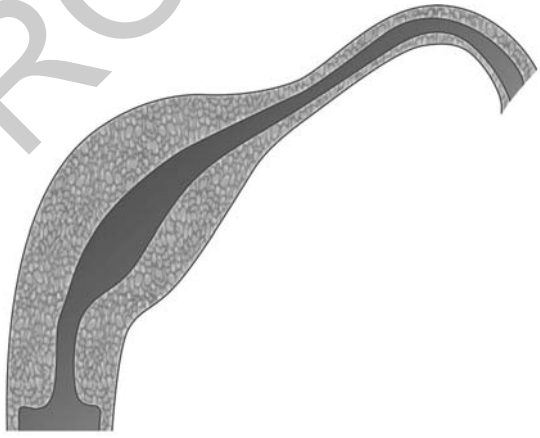

Fig. 4.1: Unicornuate uterus

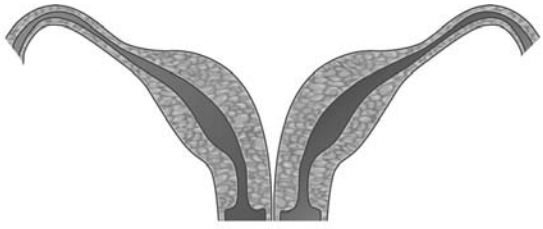

Fig. 4.2: Didelphys uterus

JAYPEE BROTHERS

Classification

Müllerian duct anomalies are categorized most commonly into seven classes, according to the American Fertility Society (AFS) classification scheme as follows.

Class I (Hypoplasia/Agenesis)

Hypoplasia includes entities such as uterine/cervical agenesis or hypoplasia. The most common form is the Mayer-Rokitansky-Kuster-Hauser syndrome, which is combined agenesis of the uterus, cervix and upper portion of the vagina. Patients have no reproductive potential aside from medical intervention in the form of *in vitro* fertilization of harvested ova and implantation in a host uterus.

Class II (Unicornuate Uterus)

A unicornuate uterus is the result of complete or almost complete arrest of development of one müllerian duct. If the arrest is incomplete, as in 90 percent of patients, a rudimentary horn with or without functioning endometrium is present. If the rudimentary horn is obstructed, it may come to surgical attention when presenting as an enlarging pelvic mass. If the contralateral healthy horn is almost fully developed, a full-term pregnancy is believed to be possible (see didelphys uterus).

Class III (Didelphys Uterus)

Didelphys uterus anomaly results from complete non-fusion of both müllerian ducts. The individual horns are fully developed and almost normal in size. Two cervices are inevitably present. A longitudinal or transverse vaginal septum may be noted as well. Didelphys uteri have the highest association with transverse vaginal septa, but septa also may be observed in other anomalies. Consider metroplasty; however, since each horn is almost a fully developed uterus, patients have been known to carry pregnancies to full term.

Class IV (Bicornuate Uterus)

A bicornuate uterus (Fig. 4.3) results from partial non-fusion of the müllerian ducts. The central myometrium may extend to the level of the internal cervical orifice of the uterus (os) (bicornuate unicollis) or external cervical os (bicornuate bicollis). The latter is distinguished from didelphys uterus, because it demonstrates some degree of fusion between the two horns, while in classic didelphys uterus, the two horns and cervices are separated completely. In addition, the horns of the bicornuate uteri are not fully developed; typically, they are smaller than those of didelphys uteri. Some patients are surgical candidates for metroplasty.

Class V (Septate Uterus)

A septate uterus (Fig. 4.4) results from failure of resorption of the septum between the two uterine horns. The septum can be partial or complete in which case it extends to the internal cervical os. Histologically, the septum may be composed of myometrium or fibrous tissue. The uterine fundus is typically convex,

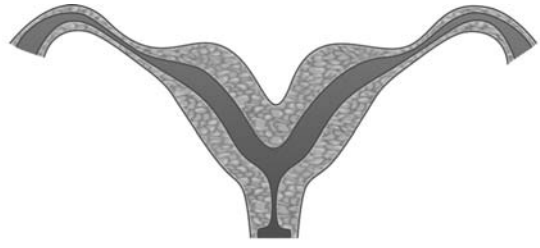

Fig. 4.3: Bicornuate uterus

JAYPEE BROTHERS

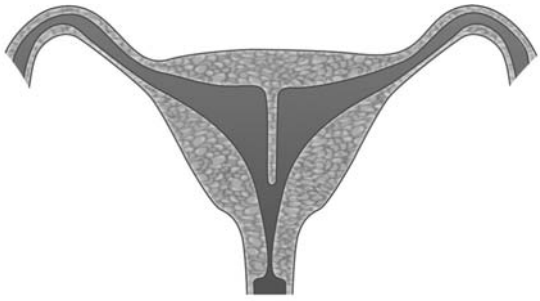

Fig. 4.4: Septate uterus

but may be flat or slightly concave (< 1 cm fundal cleft). Women with septate uterus have the highest incidence of reproductive complications. Differentiation between a septate and a bicornuate uterus is important, because septate uteri are treated by using transvaginal hysteroscopic resection of the septum, whereas if surgery is possible and/or indicated for the bicornuate uterus, an abdominal approach is required to perform metroplasty.

Class VI (Arcuate Uterus)

An arcuate uterus (Fig. 4.5) has a single uterine cavity with a convex or flat uterine fundus, the endometrial cavity, which demonstrates a small fundal cleft or impression (1.5 cm). The outer contour of the uterus is convex or flat. This form is often considered a normal variant, because it is not significantly associated with the increased risks of pregnancy loss and the complications found in other subtypes.

Class VII (Diethylstilbestrol-related Anomaly)

Several million women were treated with diethylstilbestrol (DES) (Fig. 4.6), an estrogen analogue prescribed to prevent miscarriage from 1945 to 1971. The drug was withdrawn once its teratogenic effects on the reproductive tracts of male and female fetuses were understood. The uterine anomaly is seen in the female offspring of as many as 15 percent of women exposed to DES during pregnancy. Female fetuses, which are affected, have a variety of abnormal findings that include uterine hypoplasia and a T-shaped uterine cavity. Patients may also have abnormal transverse ridges, hoods, stenosis of the cervix and adenosis of the vagina with increased risk of vaginal clear cell carcinoma. Imaging findings are pathognomonic for this anomaly.

Diagnosis

Once a müllerian anomaly is suggested based on evidence from the patient's history and physical examination, the clinician may opt for additional imaging workup. Imaging criteria for distinguishing forms of uterine anomalies are based on the configuration

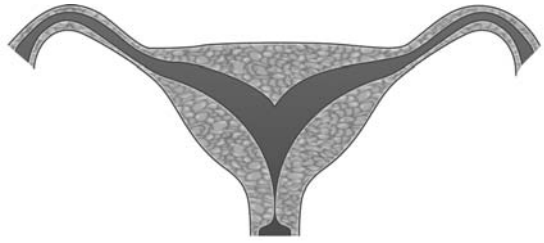

Fig. 4.5: Arcuate uterus

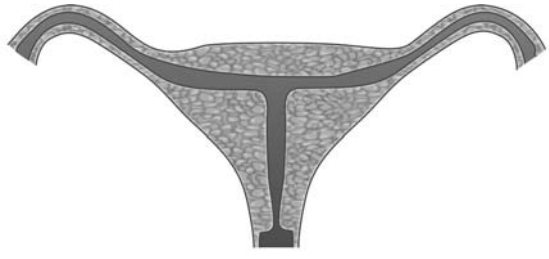

Fig. 4.6: Diethylstilbestrol-exposed uterus

JAYPEE BROTHERS

of the endometrial cavity—primarily on the configuration of the uterine fundus.

1. Typically, the first examination ordered is a pelvic ultrasound (US) with transabdominal and if feasible, transvaginal imaging specially, newer three-dimensional (3D) sonographic techniques offer relatively higher sensitivity and specificity.
2. Hysterosalpingography (HSG), performed under fluoroscopy allows evaluation of the uterine cavity and tubal patency.
3. Magnetic resonance imaging (MRI) is considered the criterion standard for imaging uterine anomalies. MRI provides high-resolution images of the uterine body, fundus and internal structure. In addition, it can help to evaluate the urinary tract for concomitant anomalies. Most types of uterine anomalies can be diagnosed confidently using pelvic MRI.

Clinical Features

Gynecological Impacts

- Infertility and dyspareunia are often seen in vaginal septum
- Dysmenorrhea in bicornuate uterus or due to cryptomenorrhea
- Menorrhagia may also occur in bicornuate uterus.

Obstetrical Impacts

The two facts are important to realize:

1. More than 50 percent of women with malformed uterus will stay completely asymptomatic from the obstetrical point of view.
2. Anatomical aspect and clinical outcomes can be different and influenced by other, not so striking, associated anomalies like anomalies of endometrium, vascularization, myometrial compliance, cervical competence and others.

Infertility: The prevalence of uterine malformations in the infertile patients is very variable according to all studies, but does not seem to be significantly different from the prevalence observed in the general population. The uterine malformations are not the only factor responsible for the infertility, but it should be taken into account that some of them can increase the risk of endometriosis.

Early abortions: All uterine malformations can be responsible for early abortions. The frequency of abortions is doubled compared to the women with normal uterus. The incidence of the miscarriages seems to be highest in the case of septate uterus, when the trophoblast invades the badly vascularized area of the septum with defective structure of the endometrium.

Ectopic pregnancies: The frequency of the ectopic pregnancies in cases of malformed uteri does not seem to be different from that found in the general population. Nevertheless, the place of ectopic gravidity is important prognostic factor. When not recognized early, the ectopic pregnancies localized in a rudimentary horn of the unicornuate uteri (type II A or II B) or asymmetrical septate uteri can lead to serious uterine ruptures.

Late abortions or premature birth: These complications are often secondary to premature rupture of the membranes or to a cervical incompetence and can be associated with all the types of uterine malformations. The rate of childbirth at term in cases of uterine malformations is only 50 percent. There is also a higher risk of late fetal losses and very premature childbirths.

Intrauterine growth restriction: The risk of intrauterine growth restriction (IUGR) appears to be increased in cases of uterine

JAYPEE BROTHERS

malformation. Some studies described 50 percent risk of IUGR in the case of unicornuate uterus and some authors found an increase rate of preeclampsia and placental abruption, probably as a consequence of abnormal placentation.

Anomaly of presentation: The risk of abnormal presentation (breech or transverse presentation) is higher in cases of uterine malformations due to mechanical factors that impede normal rotation of the fetus in the uterine cavity.

Management

Before Pregnancy

The management of the uterine malformations before pregnancy comprises the surgical treatment, if it is possible and necessary. Some of the malformations remain out of surgical capabilities (unicornuate uterus, didelphys uterus), but surgical procedures can prevent ectopic pregnancy. For example, in cases of the unicornuate uteri of the type II A or II B (excision of the rudimentary horn).

In the bicornuate uteruses type VI, hysteroplastic is theoretically possible in case of symptomatic malformation, but as this malformation is usually more complex, this procedure is done only seldom.

The septate uteri (type V) are the only uterine malformations, whose surgical treatment is relatively simple by hysteroscopic excision. This treatment is addressed to the symptomatic patients that had an obstetrical complication before. However, some authors recommend preventive treatment after the anomalies had been diagnosed. Hysteroscopic treatment can be proposed to patients with some types of the bicornuate uteri and arcuate uteri.

However, the two important facts must be taken into account in the surgical treatment of uterine malformations:

1. The restoration of normal cavity anatomy is not guarantee of a good obstetrical prognosis (abnormal uterine vascularization, compliance, etc.).
2. To the contrary with the generally accepted idea, the number of pregnancies does not improve obstetrical prognosis in women with untreated uterine malformations.

During Pregnancy

When the diagnosis of uterine malformation is made at the beginning of pregnancy, the treatment can be only preventive (setting at rest, sonographic monitoring of the fetal growth and the cervical competence). Cervical cerclage should be proposed only in the case of proved cervical incompetence observed in one third to one fourth of uterine malformations.

Abdominal metroplasty could be done either by excising the septum or by incising the septum. The success rate of abdominal metroplasty in terms of live birth is 5% to 75%. Nowadays, hysteroscopic metroplasty is done for this condition.

Abnormalities of the Fallopian Tubes

The fallopian tubes develop from the unpaired distal ends of the müllerian ducts and extend outward from the superolateral portion of the uterus. The fallopian tubes are between 10 and 14 cm long and normally end by curling around the ovary. Disease may be asymptomatic or may be linked to infertility. Congenital anomalies of the fallopian tube include accessory ostia, complete absence of

JAYPEE BROTHERS

the fallopian tube and a number of embryonic cystic remnants.

Abnormalities of the Ovaries

The congenital anomaly of the ovaries includes congenital absence of ovary and the developmental ovarian cyst. Accessory ovary (division of the original ovary into two) also comes under this condition. Rarely, supernumerary ovaries may be found in the broad ligament or elsewhere.

Wolffian Remnant Abnormalities

The outer end of the wolffian (Gartner's) duct may be pea sized, cystic and pedunculated, and attached to the outer end of the tube. Gartner's duct cysts are the remnants of the wolffian duct and they are rarely seen in adulthood. We present a case of a pregnant patient with a prolapsing vaginal mass. A diagnosis of Gartner's duct cyst was made after MRI was performed. The Gartner's duct cyst was drained when the patient went into labor, allowing vaginal delivery to be performed.

Paraovarian Cyst

Paraovarian cysts are not actually ovarian, they are usually located alongside the ovaries or on the fallopian tubes, but they are often hard to distinguish from the ovarian cysts. If they are small and do not cause any trouble, they are hard to notice, the only way to do so is with the transvaginal examination. They are often mistaken for ovarian cysts.

These cysts are not so common, but do appear. They make 10 percent of all the masses in the adnexal region (ovaries and tubes). These cysts represent remnants of the wolffian duct that lies parallell to the upper third of the vagina, uterus and fallopian tubes.

The cysts can grow to be very big and even extend to the upper abdomen. Their size and symptoms do not correspond to the hormonal cycle like other ovarian cysts do.

Paraovarian cysts may be troublesome, because they can tear, bleed, rupture and become infected.

Paraovarian cysts account for 10% to 20% of all adnexal masses and are relatively uncommon in children. They are more common in women 30 to 40 years of age. Paraovarian cysts arise not only from the tissues of the broad ligament, predominantly from mesothelium covering the peritoneum (mesothelial cysts) but also from paramesonephric (paramesonephric cysts or müllerian cysts) and rarely mesonephric remnants (mesonephric cysts or wolffian cysts).

They are usually, incidentally discovered during surgery and prophylactic excision is performed due to increased incidence of torsion, as well as their propensity to undergo rapid enlargement.

Types

- Paramesonephric cyst
- Hydatid cyst of Morgagni
- Wolffian cyst
- Kobelt cyst
- Cyst of the organ of Rosenmuller.

Paramesonephric cysts: The paramesonephric duct (or müllerian duct) forms the fallopian tube at about 9 weeks of gestation. Multiple invaginations near the ostium of the tube become the fimbriae. Any secondary invagination that does not connect may form a blind sac and this enlarges to form a paraovarian cyst.

JAYPEE BROTHERS

Complications

- Paraovarian cyst torsion (2%–16%)
- Hemorrhage
- Rupture
- Secondary infection
- Neoplastic transformation (2.9%)
  - Papillary serous cystadenoma
  - Endometrioid cystadenocarcinoma
  - Serous cystadenocarcinoma
  - Mucinous cystadenocarcinoma.

Torsion of the paraovarian cyst is 3 times more common in pregnant women likely related to rapid growth spurt.

VAGINAL ABNORMALITIES

The vaginal abnormalities include:

- Narrow introitus
- Septum
- Hymen abnormalities
- Agenesis
- Associated abnormalities.

Narrow Introitus

Narrow introitus condition is revealed after the marriage. The patient complains about dyspareunia. Treatment is done by manual stretching under general anesthesia or by perineoplasty.

Vaginal Septum

Transverse Vaginal Septum

Transverse vaginal septum (TVS) is formed when the tissue between the vaginal plate and the caudal aspect of the fused müllerian ducts fail to reabsorb. This anomaly divides the vagina into two segments, reducing its functional length. Most of these septa are located in the superior vagina at the putative junction between the vaginal plate and caudal aspect of the uterovaginal prolapse (UVP) (46%). The next most common locations are the midvagina, at a rate of 40 percent and the inferior vagina, at a rate of 14 percent.

The TVS is one of the most rare müllerian duct anomalies, with an approximate frequency of one case in 70,000 females. Unlike other müllerian duct anomalies, TVS is only occasionally associated with urologic defects. TVS has been associated with other structural anomalies, including imperforate anus, bicornuate uterus, coarctation of the aorta, atrial septal defect and malformation of the lumbar spine.

Diagnosis

Diagnosis of TVS in fetuses, neonates and infants:

1. TVS is rarely diagnosed in the neonate or infant, unless the obstruction causes a significant hydro/mucocolpos. Hydro/mucocolpos can be diagnosed *in utero* during third trimester with transabdominal sonography.
2. Abdominal ultrasonography of the pelvis can also detect hydro/mucocolpos.
3. MRI should also be performed to make a definitive diagnosis. MRI can also be useful to depict pelvic anatomy and determine the thickness of the vaginal septum.

Surgical management

Surgical management of TVS—fetuses, neonates and infants:

1. When third trimester ultrasonographic findings lead to the diagnosis, early delivery and drainage of the obstructed vagina and uterus are indicated when other organs are compromised.

JAYPEE BROTHERS

2. In infants, the vaginal septum is usually thin and can be corrected without extensive procedures. Surgical excision of the obstructed septum through a perineal approach is most efficacious. Bilateral incisions may be required to ensure complete removal.

Postoperative Management

Postoperative management—fetuses, neonates and infants.

Clinical follow-up is necessary because vaginal stenosis with subsequent accumulation of fluid may develop postoperatively. Vaginal reconstruction (vaginoplasty) may be required to allow satisfactory menstruation and coitus.

The stent is left in place for 4 to 6 months. Daily dilation for the next 2 to 4 months is required to ensure continued vaginal patency. It is often necessary to make lateral incisions along the sides of the stent during removal. Coitus can be initiated or if the patient is not sexually active, a silicone vaginal form is inserted lightly, until the constrictive phase of healing is complete. Routine postoperative care following vaginal surgery includes abstaining from intercourse for 1 month.

Longitudinal Septum (Double Vagina)

As the vagina is largely derived from the müllerian ducts, lack of fusion of the two ducts can lead to the formation of a vaginal duplication and lack of absorption of the wall between the two ducts will leave a residual septum, leading to a 'double vagina'. This condition may be associated with a uterus didelphys or a uterine septum. A person may not be aware of having a 'double vagina'. If necessary, the partition can be surgically corrected.

Diagnosis

Besides a physical examination, the physician will need imaging techniques to determine the character of the malformation: gynecologic ultrasonography, pelvic MRI or HSG. A hysterosalpingogram is not considered as useful due to the inability of the technique to evaluate the exterior contour of the uterus and distinguish between a bicornuate and septate uterus. In addition, laparoscopy and/or hysteroscopy may be indicated. In some patients, the vaginal development may be affected.

Treatment

Surgical intervention depends on the extent of the individual problem. With a didelphic uterus surgery is not usually recommended. A uterine septum can be resected in a simple outpatient procedure that combines laparoscopy and hysteroscopy. This procedure greatly decreases the rate of miscarriage for women with this anomaly.

Hymen Abnormality

Imperforate Hymen

When no hymenal opening is present, a membrane covers the area of the hymen and is called an imperforate hymen (Fig. 4.7). An imperforate hymen needs to be surgically corrected. Diagnosis is either in the newborn baby or at the time of menarche (the first period).

Frequency

Imperforate hymen is likely the most frequent obstructive anomaly of the female genital tract, but estimates of its frequency vary from one case per 1,000 population to one case per 10,000 population. Imperforate hymen

JAYPEE BROTHERS

usually occurs sporadically, but a handful of cases have been reported to be familial.

Etiology

Imperforate hymen and related genital tract anomalies result from abnormal or incomplete embryologic development.

Pathophysiology

By the 5th month of gestation, the canalization of the vagina is complete. The hymen itself is formed from the proliferation of the sinovaginal bulbs, becoming perforate before or shortly after birth. An imperforate hymen results when this 'sheet' of tissue fails to completely canalize. Varying degrees of perforation result in findings such as a cribriform or septate hymen.

The lining of the urethra and urinary bladder derives from endoderm and the urogenital sinus forms the urethra and vestibule in females. The ectoderm fuses with the endoderm to contribute to the patency and canalization of the genital tract. Defects in this process lead to fusion failures, imperforate and obstruction defects.

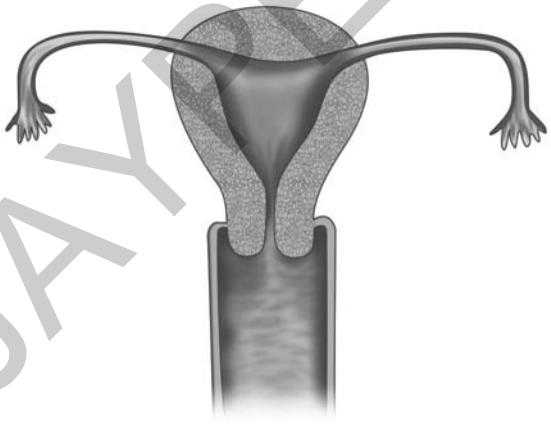

Fig. 4.7: Imperforate hymen

Familial occurrence

Dominant transmission (either sex-linked or autosomal) and sibships suggesting a recessive mode of inheritance may be possible in rare condition. The inheritance of müllerian defects likely is polygenic or multifactorial.

Anomalies of the female reproductive tract

Anomalies of the female reproductive tract can result from agenesis or hypoplasia, vertical fusion and/or canalization defects, lateral fusion and/or duplication abnormalities or failure of resorption, resulting in septa.

Clinical features

In the newborn period, there may be a bulge of the hymenal membrane due to normal mucus from the baby's vagina being unable to drain. The baby has mucus production due to mother's hormones, which are still circulating within the baby's bloodstream. Due to the blockage, the mucus cannot drain and a white bulge may appear at the location of the normal opening to the vagina.

Alternatively, an imperforate hymen may not be identified, until some point in childhood or at the time of a normal first menstrual period. A young woman with an imperforate hymen, which has not been surgically corrected, will not have a normal menstrual period as there is a blockage and the blood cannot come out of the vagina. This blockage may be associated with abdominal pain, back pain or difficulty with urination.

Diagnostic procedures

1. Careful physical examination combined with imaging is usually sufficient to establish the diagnosis.

JAYPEE BROTHERS

2. In certain circumstances related to the child's age and maturity, examination may need to be deferred, until it can be performed with the patient under anesthesia.

Imaging studies

1. Abdominal and pelvic ultrasonography and MRI are the cornerstones of imaging for uterovaginal anomalies.
2. Ultrasonography provides a reliable means for rapidly diagnosing hematocolpos or hematometrocolpos.
3. If a complex anomaly is suspected, MRI is necessary. In addition, transrectal ultrasonography may help in delineating complex anatomy.
4. MRI and sonography also aid in excluding associated congenital anomalies of the urinary tract.
5. Laparoscopy has been recommended to evacuate pelvic and intra-abdominal endometrial material generated because of retrograde menstruation. This procedure is speculated to reduce the potential for secondary endometriosis.

Management

Surgical therapy

Surgical intervention for imperforate hymen should require only one definitive procedure to evacuate the retained secretions and to ensure the maintenance of patency. Simple drainage of the material confined beyond the hymen is contraindicated, because it does not allow for adequate drainage of the thick fluid, it is not definitive and it increases the risk of infection (pyometra).

Two techniques are most commonly advocated for surgical therapy:

1. Simple incision and small excision of the membrane: Simple incision of the hymen may be associated with postoperative stenosis with strictures and it is not the method generally preferred at many centers. Use of an X-shaped incision ought to be the method of choice.
2. An elliptical excision of the membrane is performed close to the hymenal ring, followed by evacuation of the obstructed material. This technique is considered to be most effective in definitive treatment. Avoid compressing the uterus and fallopian tubes to speed evacuation of the trapped contents, after the hymen is incised.

Preoperative care

1. After the appropriate diagnostic studies are performed, an outpatient procedure to be done under general anesthesia is scheduled.
2. Distinguishing an imperforate hymen from a transverse vaginal septum is important, because the latter requires a relatively extensive procedure to reconstruct a functional vaginal tract and because it has implications in terms of reduced fertility.
3. The retained secretions are typically sterile unless previous manipulation (e.g. needle aspiration) has resulted in infection. Therefore, prophylactic antibiotics are not usually required.

Intraoperative details

The urethra should be identified first and a catheter can be placed if the patient has urinary obstructive symptoms. Various ways to make the incision have been discussed. The incision on the hymenal membrane can be made with a scalpel or with an electrocautery device. After the hymenal edges are

JAYPEE BROTHERS

inspected, the incision is completed and excess tissue can be resected further if needed. To prevent recurrence, absorbable suture is used. Local anesthetic can be injected into the edges of the hymen to achieve postoperative analgesia. As an alternative, lidocaine jelly can be applied topically.

Postoperative care

For postoperative analgesia, acetaminophen or non-steroidal anti-inflammatory drugs (NSAIDs), such as ibuprofen, are usually sufficient.

Follow-up: Postoperative follow-up is deferred for 6 to 8 weeks to allow the patient to re-establish a menstrual cycle. Findings on evaluation of the patient's menstrual cycle determine the need for further evaluation.

Complications: Incomplete drainage and failure of marsupialization may result in recurrent obstruction and potentially, an ascending pelvic infection. Although prophylactic antibiotics are not recommended, postoperative fever or abdominal pain must be evaluated and treated promptly. Potential complications include endometritis, salpingitis or tubo-ovarian abscess—any of which can affect subsequent fertility.

Microperforate Hymen

A microperforate hymen (Fig. 4.8) is essentially an imperforate hymen with a very small hole within it. The hole may be large enough for mucus and/or blood to come through the hymeneal opening, but instead of having a regular menstrual period lasting 4 to 7 days, the woman may have a period, which lasts longer. This is due to the fact that the blood cannot come out at a normal rate.

A microperforate hymen may resolve spontaneously and the opening may get larger as a child becomes older. A young woman, e.g. who has a microperforate hymen may attempt to insert a tampon and have pain or the inability to insert the tampon. If she attempts to have sexual intercourse, she may have pain and the excess hymenal tissue may tear. A surgical approach can be undertaken to resect the excess hymenal tissue.

Septate Hymen

A septate hymen (Fig. 4.9) refers to a band of extra hymenal tissue, running vertically in the area of the normal hymen. A hymenal septum may interfere with a woman's ability to insert a tampon or she may find that she can insert the tampon, but once it expands with blood, she cannot remove the tampon.

A hymenal septum does not have to be surgically removed and if a woman attempts to have sexual intercourse with a septate hymen, it will usually tear. This may be associated with some discomfort, pain or bleeding.

A simple surgical approach can be undertaken to remove the septate hymen, creating a normal hymenal orifice.

Vaginal Agenesis

Vaginal agenesis (agenesis means failure to develop or grow) is a congenital disorder of the reproductive system, which affects a relatively small proportion of women, some one in 5,000 to 7,000 or about 0.025 percent. It occurs when the vagina, the muscular canal connecting the cervix of the uterus to the vulva, stops developing during pregnancy. The condition encompasses females with a shorter than normal vagina, as well as those with no vagina.

Technically this condition is called the Mayer-Rokitansky-Küster-Hauser syndrome.

JAYPEE BROTHERS

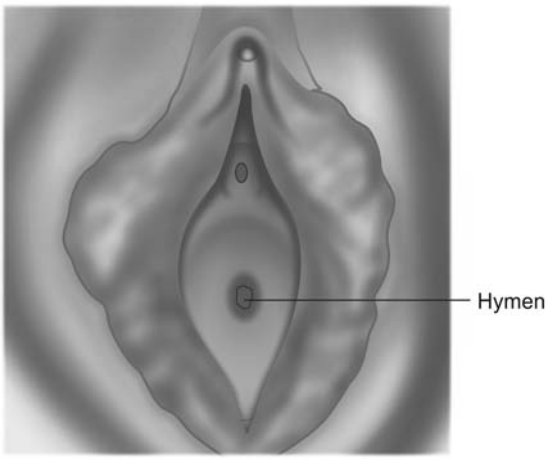

Fig. 4.8: Microperforate hymen

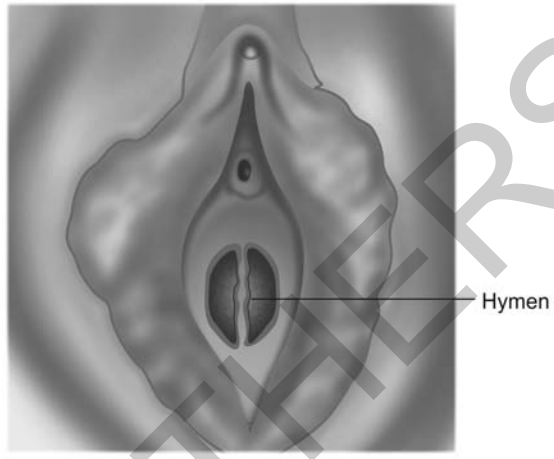

Fig. 4.9: Septate hymen

Typically sufferers have a short vagina of may be 3.5 cm or 1.5 inch in length, but there might be no vagina at all. 30 percent of patients with vaginal agenesis have kidney abnormalities. Approximately 12 percent of patients with vaginal agenesis have skeletal abnormalities that affect the spine, ribs or limbs.

Clinical Features

- Absent vagina
- Absence of menstrual period
- Absent uterus and other reproductive organs
- Kidney abnormalities
- Skeletal abnormalities
- Hearing loss.

Diagnosis

1. Since outward genitalia appear normal, vaginal agenesis is not usually diagnosed until puberty. Typically, an adolescent girl 15 to 18 years old, consults a pediatrician or gynecologist when her period does not start. The condition may also be discovered in infancy or childhood, while investigating kidney, skeletal or other abnormalities, such as the absence of an anal opening.
2. Ultrasound (US)—reveals if the uterus and ovaries are present and the presence and location of kidneys.
3. MRI—shows a more detailed picture of the reproductive tract and kidneys.

Treatment

Most young women are treated in their late teens or early 20s. Others may wait until they are older and sexually active. Treatment is not urgent, but it is usually necessary before sexual intercourse.

Self-dilation: Some patients can create a vagina without surgery, using self-dilation. In this treatment, the patient presses a small rod (dilator) against the skin or the small vagina for 15 to 20 minutes per day. This is often done after bathing, when skin is more pliable. Progressively larger dilators are used to expand the vagina. Several months may be required to obtain the desired result.

JAYPEE BROTHERS

Surgery (vaginoplasty): Two types of surgery (vaginoplasty) are used to create a functional vagina. These treatments are usually delayed, until the patient possesses the maturity to handle follow-up dilation.

Skin graft (McIndoe procedure): The McIndoe procedure is the most commonly performed vaginoplasty. The procedure uses a skin graft from the buttock (which leaves only a slight disfigurement). The surgeon makes an incision, where the vagina would normally develop and inserts the graft to create a vagina. A mold is placed in the newly formed vagina for 7 days. Following surgery, patients use a vaginal dilator, which is like a solid, large tampon. It is removed for urination, bowel movements or sexual intercourse. After a time, patients use the dilator only at night, and then rely on sexual intercourse and occasional dilation to maintain a functional vagina. The vagina will constrict if there is no subsequent dilation or intercourse.

Bowel vaginoplasty: In a bowel vaginoplasty, a portion of the sigmoid colon is diverted to an opening in the genital area, creating a new vagina. The remaining colon is then reconnected. Potential complications include bowel leakage at the attachment site and mucus drainage for up to 1 year after the surgery. Daily use of a vaginal dilator is not required with this surgery. Some women will experience a tightening of the new vagina, where it connects to the vulva. If this occurs, dilation is performed under anesthesia.

Vecchietti procedure: The Vecchietti procedure is a semi-surgical method that takes advantage of laparoscopy to accelerate dilation. An olive-shaped device, placed at the vaginal opening, is connected with sutures to a traction device on the lower abdomen. Under laparoscopic guidance, the traction device is tightened daily, gradually pulling the olive-shaped device inward to create a vagina. This takes approximately 1 week. The device is then removed and further manual dilation performed.

Counseling

Counseling is often useful for a patient to speak with a counselor about her condition. Psychologists at clinic can assist women, who have questions or experience difficulties managing the implications of vaginal agenesis. After treatment, patients with vaginal agenesis can have a normal sex life. Although it is not common, some patients with vaginal agenesis have a normal uterus and can bear children. Typically, vaginal agenesis patients have an undersized uterus and cannot become pregnant. However if their ovaries are healthy, which is often the case, affected women can have children by *in vitro* fertilization of their own eggs with the pregnancy carried by a surrogate mother.

Other Abnormalities

Labia Minora Abnormalities

The labial fusion may be due to developmental defect or inflammation.

Labia Majora Abnormalities

Includes the conditions like hyperplastic or hypoplastic labia and abnormal fusion in the adrenogenital syndrome.

JAYPEE BROTHERS

Clitoris Abnormalities

The clitorial hypertrophy may be present in associated with various intersex problems.

Perineum Abnormalities

Malformation of the perineum is rare. Imperforate anus, anal stenosis or fistula are the result of abnormal development of the urorectal septum. This may be due to the posterior development of septum.

ECTOPIC URETER

Ectopic ureter (Fig. 4.10) is an abnormally located terminal portion of the ureter. Instead of the ureter opening in the bladder, it opens in the urethra, vagina or uterus. The result is constant dribbling of urine.

Clinical Features

- Urine leaking or dribbling at times, but normal urination at other times
- Bladder infection is present in 64 percent of ectopic ureter patients
- Blood-tinged urine, if bladder infections are also present
- Frequent urination.

Diagnostic Testing Prior to Surgery

- Complete blood cell count
- Biochemical profile to make sure that the kidneys and other internal organs are healthy
- Urinalysis and urine culture to check for infection of the bladder and/or kidney
- Abdominal US to evaluate the structure of the kidneys, the ureters usually cannot be seen with US, unless they are dilated
- An excretory urogram involves giving the pet, a type of dye or contrast media through an intravenous catheter. The dye is excreted into the urine. As the dye passes through the ureters they may be seen with radiographs (X-rays)
- Computerized tomography (CT) scan is the best diagnostic tool used to diagnose ectopic ureters. This scan is performed, if the excretory urogram does not provide a definitive diagnosis.

Treatment

The moment of truth comes with surgical exploration with intent to correct the incontinence. The patient's urinary bladder will be opened and the ureteral openings located. Some ectopic ureters go to the bladder as they are supposed to, but instead of entering the bladder, simply course along the outside of the bladder to end elsewhere. During surgery, both ureters are identified and followed to their terminal points. One of the following surgical techniques will be used depending on where the ureters are going.

Neoureterostomy

Neoureterostomy procedure is used for ureters that attach to the bladder, but do not actually enter the bladder. Here, an opening

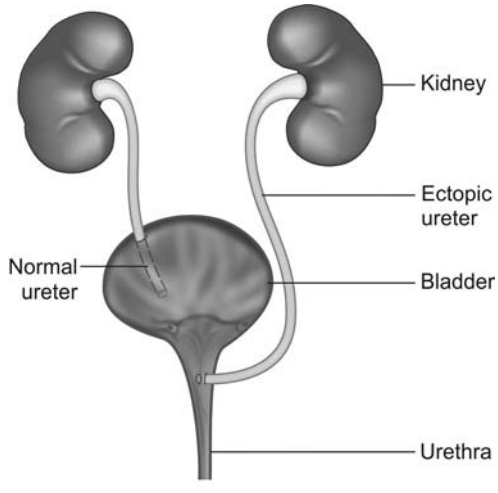

Fig. 4.10: Ectopic ureter

JAYPEE BROTHERS

into the bladder is made, where the ureter attaches, but has failed to penetrate. The part of the ureter beyond this opening is simply removed.

Neoureterocystostomy

Neoureterocystostomy technique is used for ureters that bypass the urinary bladder totally and connect elsewhere. A new opening in the urinary bladder is made, the ureter is pulled through, snipped short and sewed in place, being sure not to twist it.

Nephroureterectomy

Nephroureterectomy means 'removal of the kidney and ureter', a self-explanatory definition. If the kidney is so infected or diseased, as to be useless, it is just as well to remove the ureter and the entire kidney. One would not undertake this procedure, unless the other kidney was normal or near normal.

Complications

1. Most patients will have urinary straining and some discomfort after surgery. A urinary catheter is generally in place for a day or two after surgery, to prevent bladder distension during the first day of healing.
2. Incontinence is likely to continue to be present after surgery, but in 55 percent of dogs it was improved. Several studies have been done to determine the incidence of total incontinence resolution and depending on the study, 33% to 58% actually were free of their incontinence.

BIBLIOGRAPHY

1. Available from www.müllerianananomalies.blogspot.com
2. Congenital anomalies of vagina. [online]. Available from www.childrenshospital.org/.../mainpagesS2239P5subleve/11.html
3. Congenital uterine malformations: Müllerian duct abnormalities. [online]. Available from www.miscarriage.about.com/../congenital.htm [Accessed December 10, 2007].
4. Dutta DC. Textbook of Gynaecology, 5th edition. India: New Central Book Agency; 2008.
5. Ectopic ureters. [online]. Available from www.petplace.com
6. Female genital abnormalities. [online]. Available from www.patient.co.uk [Accessed October 3, 2008].
7. Lawrence SA, Richard SL. (2012). Müllerian duct anomalies. [online] Medscape website. Available from www.emedicine.medscape.com/article/
8. Padubidri VG, Daftary SN. In: Howkins, Bourne (Eds). Shaw's Textbook of Gynaecology, 14th edition. India: Elsevier India Private Limited; 2008.
9. Uterine Abnormalities. (2007). Müllerian duct abnormalities. [online]. Available from www.layyous.com/.../Müllerian eng. htm
10. Uterus, müllerian duct abnormalities: eMedicine Radiology. [online]. Available from www.emedicine.medscape.com/article/ [Accessed October, 2009].

JAYPEE BROTHERS

r detailed information on nursing books, visit our website www.jaypeebrothers.com, for detailed information on nursing books, visit ou

Textbook of GYNECOLOGY for Nurses

Gynecological disorders are the problems peculiar to women especially those of genital tract and breasts. There are several minor to major gynecological problems, which may occur during the reproductive life of a woman. Those disorders may create more psychological, physiological and social difficulties in their lives. Gynecological disorders are major causes of maternal morbidity and mortality.

Nurses are the members of a health team and often have a great responsibility in the preventive, promotive, curative and rehabilitative care of the women with gynecological problems. This *Textbook of Gynecology for Nurses* is a comprehensive clinical reference designed for use by the students and nurses of various levels in the hospitals and community settings. The textbook provides information regarding the gynecological disorders/problems, various diagnostic investigations and treatment modalities. Each disorder/problem is formatted consistently for access to vital information on–

- Disease
- Etiological factors and risk factors
- Clinical manifestations
- Assessment and diagnostic methods
- Prevention and its medical and surgical management
- Nursing management according to the nursing process and nursing care plans.

The textbook places special emphasis on home- and community-based nursing practice, patient education and application of nursing process, while providing care to the patients. In precise, this textbook has been compiled and written to provide contents that nurses need to know. I hope it will be a valuable guide that will help the nurses and the students in their education and practice.



Anupama Tamrakar MSc (N) completed MSc in Obstetrics and Gynecological Nursing from Rajiv Gandhi University of Health Sciences, Karnataka, India, in 2007. She is a pre-PhD candidate in Yenepoya University, Mangalore, Karnataka, India. She has about 6 years of teaching experience in undergraduate and postgraduate nursing programs. Also she has an experience of working as Program Coordinator of Department of Nursing, Pokhara University, Kaski, Nepal. She has worked in hospitals and non-government organization for around six years. Ms Anupama Tamrakar is a life–member of various professional organizations and voluntary organizations. Also participated and organized various health training programs, workshops and conferences. She has published some articles and conducted several research activities.

Available at all medical book stores
or buy directly from Jaypee Brothers through online shopping
at www.jaypeebrothers.com

JAYPEE BROTHERS
Medical Publishers (P) Ltd.
www.jaypeebrothers.com

ISBN 978-93-5090-861-7