hers.com, for detailed information of dental books, visit our website jaypeebrothers.com, for detailed information of dental books, visit our website jaypeebrothers.com, for detailed information of dental books, visit our website jaypeebrothers.com,

RAJIV M BORLE

Textbook of Oral & Maxillofacial Surgery

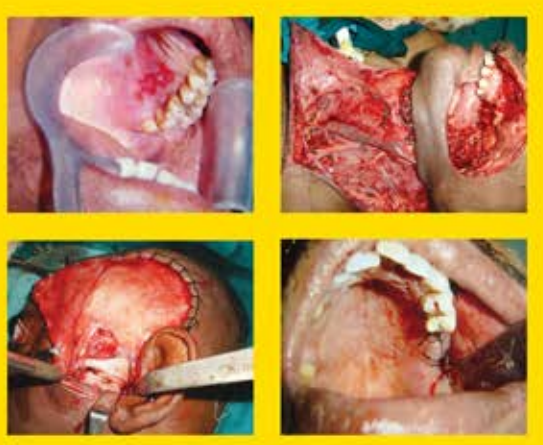

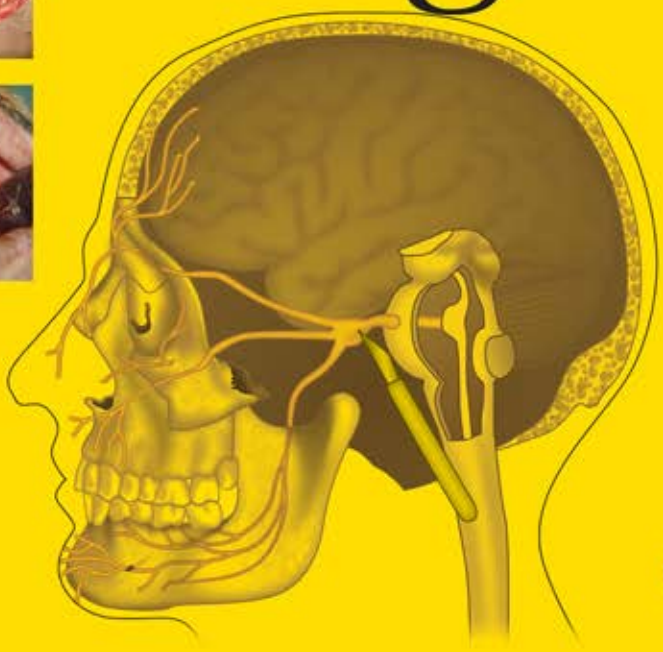

Foreword
GE Ghali

JAYPEE

Contents

Section 1: Principles of Surgery

1. Basic Principles of Surgery **3**

Borle Rajiv M, Rai Anshul, Yadav Abhilasha

- Asepsis and Sterilization *3*
- Aseptic Technique *3*
- Sterilization *3*
- Antiseptic Solutions *6*
- Care of Antiseptic Solution *11*
- Aseptic Technique *12*

2. Sutures **35**

Borle Rajiv M, Bora Smriti, Rai Anshul

- Historical Aspects *35*
- Properties of Sutures *35*
- Principles of Suture Selection *36*
- Types of Suture Material *37*
- Absorbable Synthetic Suture *37*
- Nonabsorbable Suture Material *41*
- Metal Suture and Clips *43*
- Armamentarium *44*
- Suturing Techniques *48*
- Ligatures *51*
- Suture Removal *51*

3. Incisions in Maxillofacial Surgery **54**

Borle Rajiv M, Rai Anshul

- Basic Principles of Incision Making *54*
- Incisions used in Oral and Maxillofacial Surgery *55*
- Commonly used Intraoral Incisions *55*
- Extraoral Incisions *58*

4. Fluid, Electrolyte Balance and Acid-base Equilibrium **71**

Borle Rajiv M, Agrawal Poonam

- Acid-base Balance *71*
- Fluid and Electrolyte Imbalance *73*
- Acid-base Homeostasis and Disorders *77*

JAYPEE BROTHERS

- General Principles of Water and Electrolyte Therapy *79*
- Fluid Management in Various Systemic Conditions *81*
- Parenteral and Enteral Nutrition *82*

5. Shock **85**

Borle Rajiv M

- Hypovolemic Shock (Oligemic Shock) *85*
- Septic Shock *89*
- Hypoglycemic Shock *91*
- Anaphylactic Shock *92*

6. Medical Emergencies in the Clinical Practice **97**

Borle Rajiv M, Angik Richa

- Predisposing Factors *98*
- Classification of Emergencies in Clinic *98*
- Vasovagal Shock/Syncope/Vasodepressor Syncope 99
- Postural Hypotension *102*
- Hypoglycemia *103*
- Hyperglycemia *105*
- Respiratory Tract Emergencies *106*
- Hypothyroidism *108*
- Hyperthyroidism—Thyrotoxicosis *109*
- Myocardial Infarction *111*
- Cardiac Arrest *111*
- Drug Related Emergencies *115*
- Surgical Emergencies *118*
- Aspiration of the Foreign Body *120*
- Maintenance of Emergency Kit in the Office *121*
- Emergency Drugs *122*

7. Management of Airway in Maxillofacial Surgery **131**

Borle Rajiv M

- Maintenance of Airway *132*

8. Biomedical Waste Management **145**

Borle Rajiv M, Sachdeva Sachin Dev

- Components of Biomedical Waste *145*
- Infectious Waste *146*
- Legal Aspects and Environmental Concerns *148*

Section 2: Neurological Disorders of Face and General Anesthesia

9. Neurological Disorders of the Face **153**

Borle Rajiv M, Rai Anshul

- Trigeminal Neuralgia (Tic Douloureux, Idiopathic Trigeminal Neuralgia) *153*
- Glossopharyngeal Neuralgia *157*
- Facial Nerve Paralysis *158*

JAYPEE BROTHERS

- Frey's Syndrome *162*
- Peripheral Nerve Injuries *162*
- Eagle's Syndrome *168*
- Cluster Headache *169*
- Temporal Arteritis *171*
- Migraine *172*

10. General Anesthesia **176**

Borle Rajiv M, Angik Richa

- Historical Aspects *176*
- Anesthesia after 1846 *176*
- Introduction of Intravenous Anesthetic Agents *176*
- Commonly Used Anesthetic Agents *176*
- Indications for General Anesthesia *180*
- Preanesthetic Preparation *180*
- Preanesthetic Medication *181*
- Phases of General Anesthesia *181*
- Stages of General Anesthesia *182*
- Preanesthetic Evaluation *182*
- Induction, Maintenance and Reversal of GA *183*
- Complications of General Anesthesia: Intra-anesthetic Problems *185*
- Venous Air Embolism *186*
- Postanesthetic Care *189*

Section 3: Dentoalveolar Surgeries

11. Exodontia **195**

Borle Rajiv M, Arora Aakash, Magarkar Shashwat D

- History *195*
- Definition of Exodontia *195*
- Applied Surgical Anatomy of Teeth and Jaw Bones *195*
- Indications for Extraction of Tooth *197*
- Contraindications for Extraction *197*
- Presurgical Assessment *199*
- Methods of Exodontia *200*
- Sequence of Procedures to be Undertaken during Extraction *200*
- Complications of Exodontia *212*

12. Management of Impacted Teeth **222**

Borle Rajiv M, Arora Aakash, Magarkar Shashwat D

- Theories of Impaction *222*
- Etiology *222*
- Impacted Mandibular Third Molars *222*
- Applied Surgical Anatomy *222*
- Classification of the Impacted Third Molar Impactions *223*
- Sequelae of the Impacted Third Molars *225*
- Evaluation of the Patient for the Third Molar Surgery *227*
- Surgical Procedure *231*

JAYPEE BROTHERS

- Odontectomy *233*
- Complications of Third Molar Surgery *237*
- Maxillary Canine Impactions *237*
- Diagnostic Aids *238*
- Classification *238*
- No Treatment *238*
- Impacted Maxillary Third Molar *239*
- Diagnosis *241*
- Treatment *241*
- No Treatment *241*

13. Preprosthetic Surgeries **245**

Borle Rajiv M, Bhoyar Anjali, Garg Ketan

- Scope of Preprosthetic Surgery *245*
- Anatomical and Physiological Considerations *245*
- Vestibuloplasty Procedures *249*
- Corrective Surgical Procedures *254*
- Hard Tissue Procedures *259*

Section 4: Maxillary Sinus

14. Diseases of Maxillary Sinus **275**

Borle Rajiv M, Arora Aakash, Nimonkar Pranali V

- Applied Surgical Anatomy *275*
- Age Changes in the Maxillary Sinus *275*
- Maxillary Sinusitis *276*
- Carcinoma of Maxillary Sinus *279*
- Oroantral Fistula *281*

Section 5: Salivary Glands Pathologies

15. Diseases of Salivary Glands **291**

Borle Rajiv M, Agni Nishit, Arora Aakash

- Embryological Development *291*
- Surgical Anatomy of Parotid Gland *292*
- Identification of the Facial Nerve *293*
- Surgical Anatomy of Submandibular Gland *293*
- Surgical Anatomy of Sublingual Gland *294*
- Diagnostic Aids *297*
- Etiology of Tumors *299*
- Common Salivary Gland Neoplasm *299*
- Approach to the Management of Salivary Gland Tumors *307*
- Radiotherapy and Chemotherapy in the Management of Salivary Gland Tumors *310*
- Cystic Conditions *311*
- Inflammatory Diseases *312*
- Salivary Fistula 316

JAYPEE BROTHERS

Section 6: Infections of Maxillofacial Region

16. Management of Periapical Infections 321
Borle Rajiv M, Garg Ketan
- Causes *321*
- Fate of the Periapical Infection *321*
- Pathogenesis of Periapical Lesions *322*
- Apicoectomy/Apisectomy *322*
- Anatomical Considerations *323*

17. Odontogenic Infections 329
Borle Rajiv M, Angik Richa
- Applied Surgical Anatomy *330*
- Local Barriers *330*
- Fascial Spaces *332*
- Spaces Around the Mandible *334*
- Spaces Around Maxilla *341*
- General Principles of Infection Management *349*
- Medicinal Treatment in Orofacial Infections *350*
- Selection of Anesthesia *351*
- Complications of Maxillofacial Infections *352*
- Fungal Infections of the Maxillofacial Area *357*

18. Osteomyelitis of the Facial Bones 362
Borle Rajiv M, Yadav Abhilasha, Arora Aakash
- Applied Surgical Anatomy *362*
- Pathophysiology of Osteomyelitis *362*
- Predisposing Factors *364*
- Etiology *364*
- Clinical Features *364*
- Radiological Features *366*
- Principles of Treatment of Osteomyelitis *367*
- Different Types of Osteomyelitis and their Clinical Presentations *373*
- Osteoradionecrosis *378*

Section 7: Maxillofacial Trauma

19. Management of Soft Tissue Injuries 387
Jajoo Suhas N, Yadav Abhilasha, Garg Rajat
- Definition of Wound *387*
- Examination and History *387*
- Types of Injury *388*
- Management of Soft Tissue Injuries *393*
- Wound Debridement *394*
- Injuries Require Special Consideration *399*

JAYPEE BROTHERS

20. Fractures of Mandible **402**

Borle Rajiv M, Arora Aakash, Yadav Abhilasha

- Applied Surgical Anatomy of Mandible *402*
- Classification of Fracture Mandible *402*
- Clinical Features of the Fracture *405*
- Examination of the Patient *407*
- Management of the Fracture 408
- General Supportive Treatment *409*
- Definitive Treatment *411*
- Pediatric Fractures *423*
- Geriatric Fractures 423
- Condylar Fractures *424*
- Fracture Healing *426*

21. Fractures of Middle Third of Facial Skeleton **434**

Borle Rajiv M, Arora Aakash, Bhola Nitin, Yadav Abhilasha

- Pathophysiology of Maxillofacial Injuries *434*
- Involvement of Various Structures during Middle Third Fractures *435*
- Classification of the Fractures of the Middle Third (Rowe and Williams) *438*
- Dentoalveolar Fracture *438*
- Fractures of Maxilla *439*
- Fractures of the Zygomatic Bone *449*
- Superior Orbital Fissure Syndrome *457*
- Fractures of the Zygomatic Arch *459*
- Orbital Fractures *460*
- Nasal Bone Fractures *463*
- Nasoethmoidal Fractures *467*
- Canthoplasty *471*
- Priorities in the Management of a Polytrauma Patient *473*

22. Facial Burns **477**

Jajoo Suhas N, Yadav Abhilasha, Garg Rajat

- Etiology *477*
- Evaluation *477*
- Facial Burn *485*

23. Medicolegal Aspects of Injury **488**

Anjankar AJ, Borle Rajiv M, Garg Rajat

- Types of Injuries *488*
- Grievous Injuries *488*
- Injuries Caused by Mechanical Violence *488*
- Differences between Suicidal Wounds and Homicidal Wounds *492*
- Age of Injury *492*
- Types of Weapon *492*

JAYPEE BROTHERS

Section 8: Facial Deformities

24. Introduction to Cleft Lip and Palate **497**
Jajoo Suhas N, Yadav Abhilasha, Garg Rajat
- Introduction *497*
- Historical Aspect *497*
- Epidemiology *498*
- Applied Surgical Anatomy *498*
- Formation of Palate *499*
- Etiology *501*
- Classification *502*
- Prenatal Diagnosis and Counseling of Parents *504*
- Management Protocols for the Patients with Cleft Lip and Palate *505*
- Surgical Procedures for Cleft Lip and Palate *511*
- Surgical Procedures for Cleft Lip Repair *511*
- Secondary Procedures *517*
- Palatal Fistula *521*
- Scar Revision of the Cleft Lip *522*
- Rhinoplasty *524*
- Objectives of Corrective Surgery *525*

25. Orthognathic Surgery **531**
Borle Rajiv M, Bhola Nitin, Vibhute Pawan J
- Historical Aspects *531*
- Classification of Facial Deformities *532*
- Patient Evaluation and Planning *532*
- Occlusal Evaluation and Model Analysis *533*
- Profile Assessment *533*
- Clinical Features *535*
- Cephalometric Analysis *536*
- Dental Relations *537*
- Posteroanterior Cephalometric Analysis *538*
- Soft Tissue Cephalometric Analysis *539*
- Operative Procedures *542*
- Complications of Orthognathic Surgery *559*
- Distraction Osteogenesis *562*
- Distraction Devices and Options *564*
- Extraoral Distractor *566*

Section 9: Temporomandibular Joint

26. Temporomandibular Joint Disorders **575**
Borle Rajiv M, Arora Aakash, Singh Divya
- Temporomandibular Joint Ankylosis *575*
- Other Temporomandibular Joint Disorders *585*
- Myofacial Pain Dysfunction Syndrome *590*

JAYPEE BROTHERS

Section 10: Neoplastic Conditions of Head, Neck and Face

27. Odontogenic and Nonodontogenic Cysts of the Maxillofacial Region **603**
Borle Rajiv M, Gadbail Amol, Singh Divya
- Odontogenic Cysts *603*
- Development of a Cyst *603*
- Classification of the Cyst of Oral Cavity *603*
- Etiopathogenesis *604*
- General Clinical Features of Odontogenic Cysts *604*
- Theories of Cyst Enlargement *605*
- Diagnosis of the Cyst *605*
- Treatment Modalities of the Cyst *606*
- Developmental Cysts of Odontogenic Origin *609*
- Odontogenic Cyst of Inflammatory Origin *617*
- Non-odontogenic Cysts *619*
- Cyst of Soft Tissue of Head, Neck and Face *621*
- Dermoid Cyst *624*
- Hydatid Cyst *627*

28. Odontogenic Tumors **630**
Borle Rajiv M, Singh Divya
- According to WHO *630*
- WHO Classification of Odontogenic Tumors *630*
- Ameloblastoma *631*
- Calcifying Epithelial Odontogenic Tumor *646*
- Squamous Odontogenic Tumors *649*
- Adenomatoid Odontogenic Tumor *650*
- Ameloblastic Fibroma *652*
- Odontogenic Fibroma *655*
- Benign Cementoblastoma *657*
- Myxoma (Odontogenic Myxoma, Fibromyxoma) *658*
- Odontoma *659*
- Malignant Odontogenic Tumors *663*

29. Potentially Malignant Disorders of the Oral Cavity **669**
Borle Rajiv M, Gadbail Amol
- Concept of Precancer *669*
- Potentially Malignant Disorders *669*
- Oral Submucous Fibrosis *681*
- Lichen Planus *685*

30. Oral Cancer **693**
Borle Rajiv M, Arora Aakash, Bhola Nitin
- Etiology *694*
- Pathogenesis *695*
- Carcinogenesis *695*
- Clinical Presentation of Oral Cancer *696*
- Primary Intraosseous Carcinoma *699*

JAYPEE BROTHERS

- Management of OSCC *710*
- Cachexia in Malignancy *732*
- Basal Cell Carcinoma *733*

Section 11: Important Tips for Postgraduate Students

31. Thesis Writing **745**

Gaidhane Abhay, Quazi Syed Zahiruddin

- Preparing Synopsis *745*
- Outline of the Study Protocol *745*
- Start with Research Question *746*
- A Poorly Framed Research Question *746*
- Hypothesis *747*
- Objectives *748*
- Planning the Research *748*
- Selecting the Suitable Study Design *748*
- Defining the Sampling Methodology and Calculating Sample Size (Random Error and Level of Significance and Power of Study) *752*
- Data Collection: Tools and Techniques (Methods) *755*
- Data Quality *756*
- Data Analysis and Basic Biostatistics Principles *756*
- Writing the Thesis/Dissertation Report *761*

32. Seminar and Journal Club Presentation **768**

Borle Rajiv M

- Seminar *769*
- Journal Club Presentation *772*

Section 12: Appendices

Commonly Prescribed Investigations in Surgical Practices, their Values and Interpretation **777**

Borle Rajiv M

- Appendix-I: Hematology *777*
- Appendix-II: Biochemical Investigations *780*
- Appendix-III: Coagulation *785*
- Appendix-IV: Arterial Gas Analysis *787*
- Appendix-V: Urine Examination *789*

Index **793**

JAYPEE BROTHERS

16 Management of Periapical Infections

Borle Rajiv M, Garg Ketan

The periapical infections are commonly seen in the clinical practice. The periapical infections result secondary to pulpal pathologies and the involved tooth is invariably non-vital and discolored. The exposure of the pulp to the external (oral) environments secondary to caries, attrition/abrasion leads to contamination and subsequently infection of the pulp (Box 16.1). Similarly, the thermal or chemical insult of the pulp also leads to inflammatory changes in the pulp. The pulp is enclosed in an inexpansile chamber (tooth) and inflammation and edema of the pulp leads to increased pressure within the chamber leading to its compression and ischemia. The pain of pulpitis is very severe and the involved tooth becomes to hot and cold. In fact, the hot and cold could be the aggravating and/or relieving factors for the pain in this condition. The mounting pressure within the pulp chamber compresses the periapical blood vessels and the lymphatics and the ischemic necrosis of the pulp takes place. The tooth which had pulpitis and was very painful and sensitive to hot and cold becomes less painful and insensitive owing to the necrosis of the pulp. The necrotic pulp serves as a good nidus for the microbial proliferation. The infection leads to liquefactive necrosis of the pulp and the necrotic, infected material escapes into the periapical area of the tooth leading to periapical infection. The mounting periapical pressure due to infection and inflammation causes extrusion of the tooth. The tooth has premature contact due to extrusion and patient feels pain during mastication. The tooth also becomes tender on vertical percussion and the mobility sets in due to lysis of periodontal fibers. The infection initially produces widening of lamina dura and mild periapical rarefaction on radiographs and endodontic therapy is good enough to drain and manage the periapical infection. However, the long standing periapical infection leads to changes like chronic periapical granuloma, periapical cyst and it may not be amenable to the endodontic treatment alone and to prevent recurrent episodes of infection and to remove the periapical pathological tissue completely, the endodontic treatment needs to be followed by the periapical surgery.

Box 16.1: The common causes of the pulpal pathologies

- Carious lesions leading to pulp exposure and infection.
- Regressive conditions like abrasion, attrition, erosion leading to pulp exposure.
- Fractures of the tooth involving the pulp.
- Dentoalveolar injuries which lead to luxation of the tooth and render it non vital which serves as a nidus for the infection.
- Extension of the periodontal infections to the periapical area.

CAUSES

The common causes of the pulpal pathologies are:

- Carious lesions leading to pulp exposure and infection.
- Regressive conditions like abrasion, attrition, erosion leading to pulp exposure.
- Fractures of the tooth involving the pulp.
- Dentoalveolar injuries which lead to luxation of the tooth and render it non-vital, which serves as a nidus for the infection.
- Extension of the periodontal infections to the periapical area.

FATE OF THE PERIAPICAL INFECTION

- Complete resolution, if the cause is treated.
- Transition to the chronic form leading to PA granuloma or cyst formation.
- Spread to adjoining bone.
- Extension in the adjacent soft-tissue spaces.

The periapical infection (abscess) can be drained through the root canal or through the socket of the tooth by extracting the offending tooth. This is very important in the management of the pain due to acute periapical infection/abscess. The common mistake done by the clinician is the attempt to treat the periapical infection by

JAYPEE BROTHERS

prescribing heavy doses of analgesics and antibiotics. The pain never gets relieved satisfactorily with medication as the cause of the pain is pressure and the decompression of the area will give lasting relief to the patients rather than the antibiotics and analgesics alone.

The history of the periapical surgeries also reveals the procedure called 'trephination' (creating the hole in the buccal cortical plate) to decompress the infection.[1] The infection should be promptly drained by opening the root canal and then the drugs should be prescribed. Endodontic therapy will lead to satisfactory remission of the infection. However, the chronic infections may not be treated by endodontic therapy alone. The periapical cyst, granuloma or the extension of the infection in soft tissue leading to a chronic cutaneous or gingival sinus may require further surgical intervention in the form of periapical curettage, apicoectomy and excision of cutaneous sinus along with the tract (Figs 16.1 to 16.3).



Fig. 16.1: Case of periapical abscess



Fig. 16.2: Radiological picture



Fig. 16.3: Peridontal abscess

PATHOGENESIS OF PERIAPICAL LESIONS

Fish[2] described the reaction of periradicular tissues to noxious products of tissue necrosis, bacterial products and antigenic agents from root canal by establishing experimental foci of infection in the jaws of guinea pigs by drilling openings in the bone and packing in wool fibers saturated with broth culture of microorganisms. Four well-defined zones of reaction were found:

Zone of Infection

This zone was found in the center of the lesion and characterized by polymorphonuclear leukocytes. The microorganisms not disposed off by polymorphonuclear leukocytes are found in Haversian canals.

Zone of Contamination

This zone is characterized by round cell infiltration around the central zone. Fish observed an area of cellular destruction by the toxins released from the central zone. The nature of the toxins however could not be established (tissue-breakdown products or exotoxins). Prevalence of lymphocytes was noted. Autolytic death of bone cells with empty lacunae is seen.

Zone of Irritation

This zone is characterized by macrophages and osteoclasts. Fish found irritation evidences further from the central lesion as the toxins became more diluted. In this zone, normal bone cells and osteoclasts just managed to survive in the presence of small, round cells. These osteoclasts activated the bone tissue, while the collagen framework was destroyed by macrophages. This opens up a gap in the bone around the center of the lesion; as trees are felled to isolate a forest fire, and this space is then subsequently filled with polymorphonuclear lymphocytes and until this has taken places a danger of widespread of necrosis remains. The histologic picture is of starting of reparative activity.

Zone of Stimulation

This zone is characterized by fibroblasts and osteoblasts. At the periphery, the toxin is mild enough to be stimulant according to Fish's observations. Fibroblasts lay down collagen fibers, which act like a wall of defense around the zone of irritation and act like a scaffold on which osteoblasts build new bone. This newly built bone is deposited in irregular fashion.

APICOECTOMY/ APISECTOMY

Apicoectomy is the surgical procedure done to resect the diseased apex of an infected root of a tooth. This term is often interchanged with the term apicoectomy. The history of this surgery dates back to late 18th century when a hole was drilled in the buccal cortex of the alveolar bone to drain the periapical abscess. The surgery is often done to eliminate the periapical pathology which can not be treated by endodontic

JAYPEE BROTHERS

Box 16.2: The indications for the periapical surgery or the apicoectomy

- Periapical cysts
- Periapical granulomas
- Over extended root canal fillings
- Dilacerated, calcified or curved root canals, which can not be adequately obturated by anterograde method and remain under filled.

Box 16.3: Indications for periradicular surgery (According to Europian Society of Endodontics 1994)[3]

- Obstructed canal with radiologic findings and/or clinical symptoms.
- Extruded material with radiologic findings and/or clinical symptoms.
- Failed root canal treatment when retreatment is inappropriate (isthmus tissue, persistent acute symptoms or flare-ups, risk of root fracture).
- Perforations with radiologic findings and/or clinical symptoms, and where it is impossible to treat from within the pulp cavity

Box 16.4: Contraindications for periradicular surgery (According to Europian Society of Endodontics 1994)[2]

- Local anatomical factors (e.g. inaccessible root end).
- Tooth with inadequate periodontal support.
- Nonrestorable tooth, without function (no antagonist, no pillar for removable or fixed prothesis).
- Uncooperative patient.
- Compromised medical history.

means alone. The indications and contraindications for the periapical surgery are summarized in Box 16.2 to 16.4.

Indications for the Periapical Surgery or the Apicoectomy

- Periapical cysts
- Periapical granulomas
- Over extended root canal fillings
- Dilacerated, calcified or curved root canals, which can not be adequately obturated by anterograde method and remain under filled.

Indications and Contraindications for Periradicular Surgery

Indications for Periradicular Surgery (According to Europian Society of Endodontics 1994)[3]

- Obstructed canal with radiologic findings and/or clinical symptoms.
- Extruded material with radiologic findings and/or clinical symptoms.
- Failed root canal treatment when retreatment is inappropriate (isthmus tissue, persistent acute symptoms or flare-ups, risk of root fracture).
- Perforations with radiologic findings and/or clinical symptoms and where it is impossible to treat from within the pulp cavity.

Contraindications for Periradicular Surgery (According to Europian Society of Endodontics 1994)[2]

- Local anatomical factors (e.g. inaccessible root end).
- Tooth with inadequate periodontal support.
- Nonrestorable tooth, tooth without function (no antagonist, no pillar for removable or fixed prosthesis).
- Uncooperative patient.
- Compromised medical history.

ANATOMICAL CONSIDERATIONS

The anatomical structures, which are to be considered while performing periapical procedures include:

- Maxillary sinus[4] (Fig. 16.4)
- Inferior alveolar neurovascular bundle and mental nerve as it emerges from the mental foramen[5]
- Facial artery
- Floor of the nose with anterior nasal spine

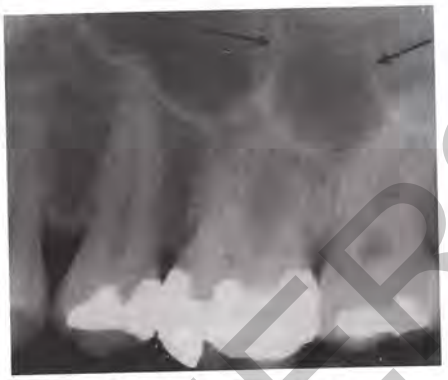

Fig. 16.4: Maxillary sinus

- Nasopalatine nerve and vessels
- Greater palatine neurovascular bundle
- Floor of the mouth.

Each of these should be kept in mind and taken into consideration, while performing surgery in the involved region so as to avoid damage to them.

The standard armamentarium required for the periapical surgery is shown in Box 16.5 and Figure 16.5.

Box 16.5: Instruments required

- Local anesthetic solution containing vasoconstrictor
- No. 3 BP handle with No. 15 Surgical blade
- Molt periosteal elevator
- Cawood-Minnesota retractor
- Standard dental high speed handpiece No. 6 round bur and No. 557 long fissure bur
- Mayo-Hegar needle holder
- Dean's surgical dissecting scissors
- Black silk or Vicryl suture (3 '0' or 4 '0') on cutting needle. The instruments required for periapical surgery are shown in the Figure 16.5.

Steps

- Soft tissue access via a mucoperiosteal flap
- Cortical ostectomy to approach the root apex
- Apical curettage
- Apicoectomy
- Retrofilling.

JAYPEE BROTHERS

Flap Designing

Basic principles to be followed, while reflecting the mucoperisteal flap. The flap should be wider at the base than the apex to ensure proper blood supply and drainage of the flap (Figs 16.6A and B, Fig. 16.7).

The incisions recommended for this procedure are[6,7]

- Degloving incision (Figs 16.8A and B)
- Submarginal flap (Figs 16.9A to C)
- Semilunar incision (Figs 16.10A and B)
- Trapezoid incision (Figs 16.11 and 16.12)
- Triangular incision (Figs 16.13A and B)
- Envelope incision (Figs 16.14A and B)
- Palatal flap for maxillary posteriors (rare) (Fig. 16.15).

Surgical Procedure

The routine patient preparation is done prior to the surgery. Good quality post root canal treatment (RCT) radiographs are obtained to assess the size of the lesion to facilitate proper planning and reflection of the mucoperiosteal flap. Under all aspectic precautions like part preparation, draping, etc. the procedure is usually carried out under the local anesthesia. The general anesthesia is indicated in extensive lesions and where the patient compliance is poor. After taking one of the above mentioned incisions suitable in the given case a full thickness mucoperiosteal flap is designed and reflected. Selection of the appropriate flap design should be based on the following principles:

- Incision should lie on healthy bone so that after closure the suture line lies on solid healthy bone, as incisions closed over a dead space tend to breakdown.
- Healing is initiated by epithelial migration across the suture line and this is four times faster in attached gingiva as compared to alveolar mucosa and this advantage should be taken by placing horizontal incision over the attached gingival.
- The horizontal incision should extend atleast one tooth on the either



Fig. 16.5: Instruments required for periapical surgery

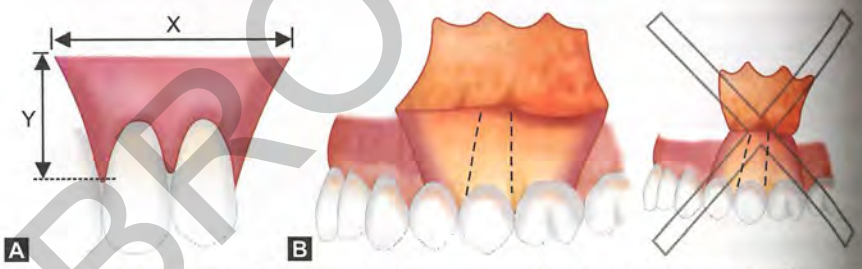

Figs 16.6A and B: Flap designing: (A) Dimensions of flap (x>y); (B) Correct and incorrect way of designing of flap



Fig. 16.7: Direction of blood supply in the anterior maxillary region

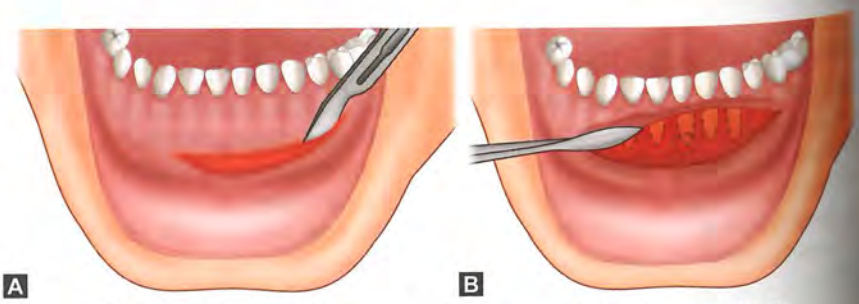

Figs 16.8A and B: Flap design for lower anteriors degloving incision

JAYPEE BROTHERS



Figs 16.9A to C: Luebke-ochsenbein (scalloped) submarginal flap

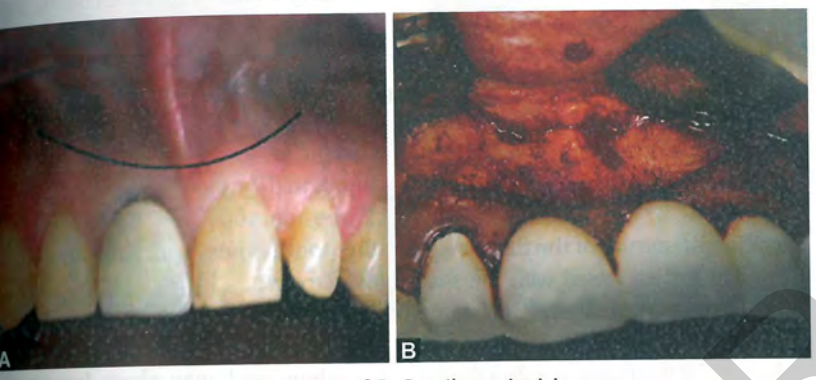

Figs 16.10A and B: Semilunar incision



Fig. 16.11: Trapezoid flap



g. 16.12: Triangular/trapezoidal flap for sterior mandible with release in the eral incisor-canine area to avoid damage the mental nerve and vessels

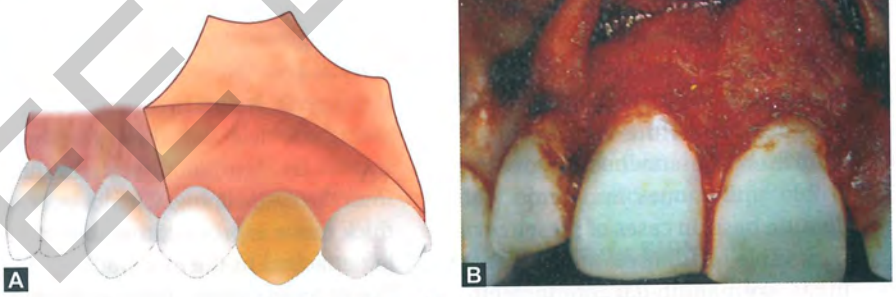

Figs 16.13A and B: Triangular incision





Figs 16.14A and B: Envelope flap

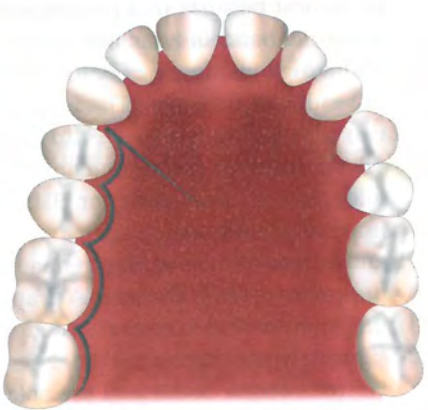

Fig. 16.15: Palatal flap design

JAYPEE BROTHERS

side of the tooth/teeth on which apicoectomy is to be performed.
- The flap must provide adequate access and visualization of the surgical site without tearing/bruising of the flap and damage to the adjacent structures.
- Retracting instrument of the flap must rest on healthy bone to avoid trauma so as provide healing with minimal inflammation, pain and subsequent scarring of tissues and subsequent carrying of the tissue.
- The primary blood supply for the free alveolar mucosa is derived from the supraperiosteal vasculature that runs parallel to the long axis of the tooth and any horizontal incision in this unattached mucosa will greatly compromise the blood supply of the flap, which will result in compromised healing. Therefore, only vertical release incisions should be made in the alveolar mucosa (*see* Fig. 16.7).
- The vertical release incision should be made at an obtuse angle to the horizontal one so as to have a flap with a broad base with respect to the apex.
- Horizontal incision is to be placed in the gingival sulcus in cases of severe periodontal disease.
- Fixed and removable prosthetic restorations if present should be considered with the incision being placed on the attached gingival in visible smile zones and under the denture base, in cases of presence of removable prostheses.
- In cases of mandibular anterior teeth, the sulcular incision is considered to be best because of a presence of a narrow band of attached gingival and a high incidence of dehiscence of vestibular incisions. The incision can also be placed in the lip 1 to 1.5 cm anterior to the mucobuccal fold, this incision goes for 2 mm into the orbicularis oris muscle and a myocutaneous flap is made, the periosteum is then incised and the superior flap is then elevated to expose the root apex.
- For mandibular molar and premolar regions sulcular incisions with anterior release in the lateral incisor-canine area are indicated. Never place the incision in the buccal mandibular vestibule. If additional access is required then a posterior release incision can be given.

Technique

- Horizontal incision is made first with a sharp, clean stroke avoiding multiple incisions.
- The vertical arm or arms are then added to it.
- Intactness of papilla should be maintained as it will serve as an anchoring point for sutures.
- The entire length of the incision should then be scored with a periosteal elevator to assure its completeness to the bone and avoid accidental tearing of the flap.
- The flap is then raised with the sharp end of the periosteal elevator starting with the horizontal incision and the blunt end is then used to reflect the flap.
- With the sulcular incision, the elevation is started at the incisal papilla farthest from the release incision.
- If two release incisions are used then flap reflection is started from the crestal gingival and taken to each vertical arm.
- If the cystic lesion is adherent to the mucoperiosteal flap then a scissors should be used to dissect the flap from the cystic lining. Often a layer of thick tissue is present, this should be left attached to the cyst wall and the free mucosa sharply dissected from it.

To access the palatal root of the maxillary molars a sulcular incision with a vertical release in the region of the canine is indicated. These areas require a large soft-tissue flap to provide adequate access through the dense palatal bone. The vertical releasing incision should extend just short of midline and be tapered posteriorly. It may involve the terminal branches of the greater palatine artery. The buccal cortical plate is exposed. If a sinus is present previously, then perforation in the cortex is noticed along with the gingival sinus tract. If the lesion is within the bone and has not perforated through the bone then the intact cortical plate is seen. If the cortical perforation is present, the same is widened with the help of the flat fissure bur to expose the periapical pathology. If the cortex is intact a post stamp incision is taken in the bone with a number 8 round bur and the holes are joined with the flat fissure bur and the intervening bone is removed to expose the periapical pathology and the apex of the involved tooth. The purpose of creating a window in the bone is to gain working access to the tooth being treated. The size of the bone window should be large enough to provide complete removal of the periapical pathology.

The root apex of the offending tooth should be located precisely to prevent injury to the apices of the adjacent teeth. Three methods may be used to locate the tooth apex and thus the area of ostectomy:

1. In most cases the cortical plate may be thin because of underlying pathology and may show fenestrations or fistulae. A periosteal elevator or curette is used to start the access window in such situations.
2. In cases of posterior teeth with thicker overlying bone root apices can be located by establishing working length of the tooth over a radiograph and then transposing the measurement with a file or curette. approximate site of root apex is located by this technique.
3. If still not located as in cases of mandible molars then it can be done by using a round bur to drill a hole into the buccal cortical plate as close to the estimated apex as possible. A medium sized gutta-percha point is then placed into the hole and a periapical X-ray is now taken to locate the apex accurately.

After the apex is located, the surgical window is prepared depending on the size of the pathology (Figs 16.16A and B) and all unsupported bone is removed since it has a poor vascular supply and fails to heal. The root apex is particularly difficult to locate in cases, where very small/absent periapical lesions are present.

JAYPEE BROTHERS

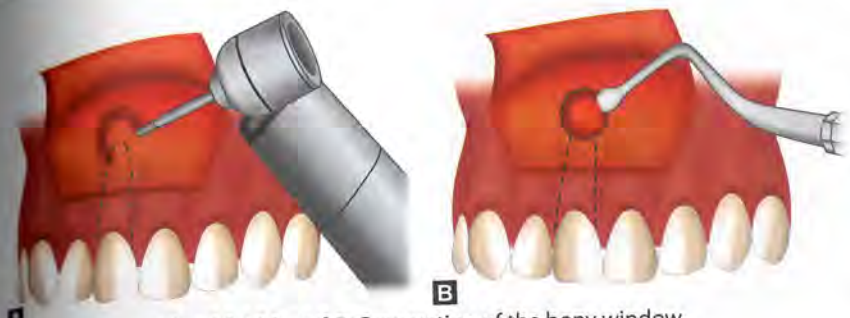

Figs 16.16A and B: Preparation of the bony window

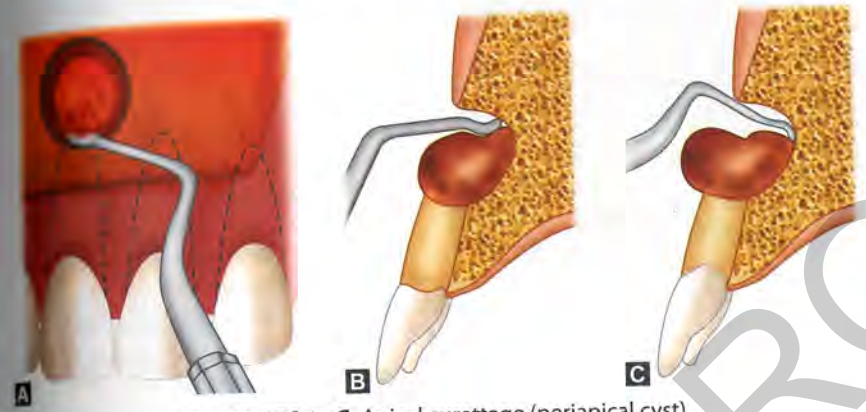

Figs 16.17A to C: Apical curettage (periapical cyst)

Apical Curettage

Two types of pathosis are associated with endodontically treated teeth (Figs 16.17A to C):

- Granulation tissue
- Radicular cyst

Granulation tissue is removed with curette (*see* Figs 16.16A and B). Complete removal is advised in cases of smaller radiographically confined lesions. In cases of large lesions, any communications with the nasal cavity, maxillary sinus, lingual plate defects, adjacent roots, inferior alveolar neurovascular bundle should be ruled out.

If no communications are present then complete removal of the lesion should be done.

A periapical cyst differs from granulation tissue in terms of tissue characteristics, organization and structure. The cysts are well-encapsulated structures and should be removed *in toto* as a single unit. After delineation of the bony soft-tissue border, a curette is used to gently disengage the sac from the bone by placing the sharp edge against the bone and convex surface against the cystic membrane to avoid perforation of the cystic lining (Figs 16.17A to C, 16.18A to D). On the other hand the granuloma is composed of fragile, friable tissue, which bleeds and fragments readily on instrumentation. It is often removed in piece meal. The stoppage of the bleeding from the bone should be taken as a sign of complete removal of the granuloma. The lining of the cyst also tends to fragment and bleed if it is grossly infected.

In cases of large lesions, which are close to the vital structures and are likely to result in large defects and damage to the adjacent vital structures, an alternative treatment plan comprising of elimination of the source of infection and creation of an effective periapical seal by endodontic therapy, preoperatively, then the residual cystic lining or granulation tissue will resolve and the magnitude of the periapical surgery will be reduced and morbid complications can also be avoided. All the tissue that are removed should be submitted to the pathologist for histopathological examination.

Apicoectomy

Purpose

To create an apical bevel permitting the operator to access the apex

The angle of bevel should be kept minimum to minimize leakage through dentinal tubules. The ideal angle of resection is flat (0°) cut since it minimizes apical leakage (Fig. 16.19).[8] The technical requirement for good surgical access to place a retrograde filling means that some bevel is necessary, which should be kept to the smallest angle possible.

Factors

The factors affecting inclination of bevel are[9]:

- Anatomy of the root.
- Surgical visibility and access to the site.
- Size of instrument used to prepare the root end for retrofilling.

The cut through the apex should bevel the root so that it gives a lateral/forward inclination toward the operator. This permits an adequate view of the apical foramen. The projecting Gutta-percha point should be identified while performing apicoectomy.

Retrograde Filling[10]

If the apical seal of the root canal filling is inadequate then the chances of microleakage and the recurrent infections are very high. To avoid these complications, apical seal can be achieved by doing the retrograde filling.

Wound Closure and Postoperative Care

- Wound should be thoroughly irrigated with sterile normal saline solution before closure.
- Closure should not be too tight.
- First suture after repositioning the flap in proper alignment is to be

JAYPEE BROTHERS

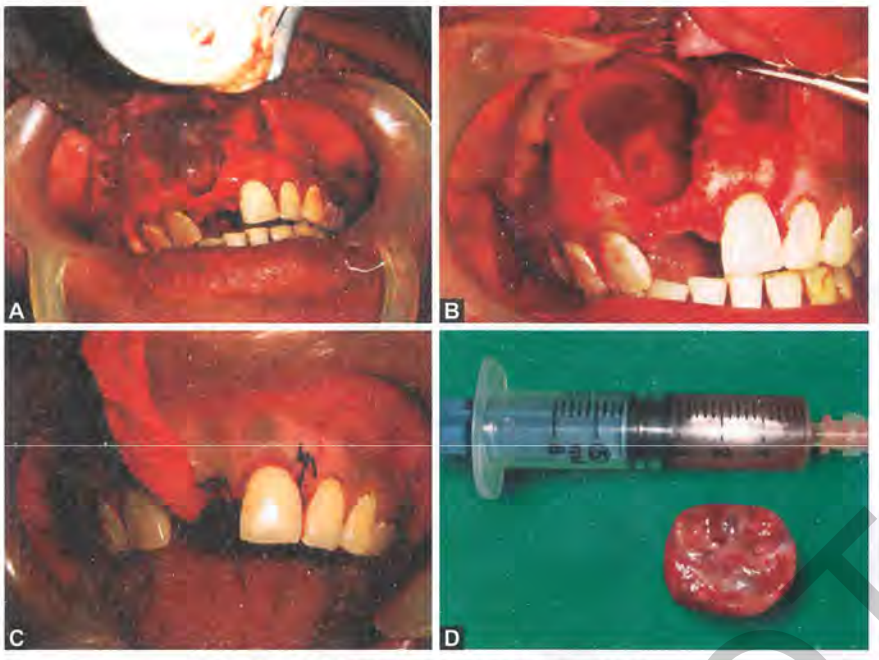

Figs 16.18A to D: Curettage of the cystic lining



Fig. 16.19: Direction of the bevel

placed at the point of convergence of the vertical and horizontal incisions. This is the positional suture, once this is done, then the vertical and lastly the horizontal incisions are closed.

- Periodontal sling or simple interrupted sutures can be placed.
- Some portion of the vertical incision can be left open to facilitate drainage of the collected hematoma/exudate.
- If the teeth are found to be mobile then they can be splinted using an arch bar for a period of 4 to 6 weeks till the healing has taken place.

Pain

The postoperative pain is managed by non-steroidal anti-inflammatory drugs (NSAID's) or any other suitable analgesic.

Antibiotics[11]

Generally not required, but depends on:

- Medical history.
- Length of time the wound was open.
- Surgical contamination.
- Clinical findings.

Usually the beta lactum group of antibiotics are adequate to provide good cover (e.g. penicillin, amoxicillin, ampicillin and cephalosporins).

Swelling

A mild to moderate postoperative swelling is expected and can be managed by use of icepacks and anti-inflammatory drugs. Routine use of steroids is not advocated for periapical procedures. Application of the cold packs in first 24 hours of surgery help in reducing the inflammatory edema by inducing vasoconstriction.

Suture Removal

Mucoperiosteal flap reattaches within 48 hours and incisions in the attached gingiva heal within 4 to 5 days. However, suture removal is done on 7th day depending upon clinical judgement and patient comfort.

REFERENCES

1. Brian M. Henry. Trephination for acute pain management. Journal of endodontics. 2003;29(2):144-6.
2. Fish EW. The physiology of dentine and its reaction to injury and disease. Br Dent J. 1928;49:593.
3. ESE/European Society of Endodontology: Consensus report of the European Society of Endodontology on quality guidelines for endodontic treatment. Int Endod J. 1994;27:115.
4. Garcia, et al. Periapical Surgery in Maxillary Premolars and Molars. J Oral Maxillofac Surg. 2008.
5. Martí, et al. Distance Between Periapical Lesion and Mandibular Canal as a Factor in Periapical Surgery in Mandibular Molars. J Oral Maxillofac Surg. 2008.
6. Gutmann JL, Harrison JW. Surgical Endodontics. 1994;123-299.
7. Vreeland DL, Tidwell E. Flap design for surgical endodontics. Oral Surg. 1982; 54:461-5.
8. Gagliani M, Taschieri S, Molinari R. Ultrasonic root-end preparation: influence of cutting angle on the apical seal. J. Endod. Baltimore, 1998. v.24, n.11, pp.726-30.
9. Hirsch JM, Ahlstrom U, Hendrikson PA, Periapical surgery. Int J Oral Surg. 1979;8:173-85.
10. Obón-Arroyave, SI, et al. *Ex vivo* microscopic assessment of factors affecting the quality of apical seal created by root-end fillings. Int. Endod. J. 2007; 40(8):590-602.
11. Baumgartner JG, Bakland LK, Sugita EI. Microbiology of endodontics and asepsis in endodontic practice. In John Ingle, Leif Bakland (Eds) Endodontics, 5th edn, BC Becker, London, Chapter 3, pp. 63-94.

JAYPEE BROTHERS

For detailed information of dental books, visit our website jaypeebrothers.com, for detailed information of dental books, visit our website jaypeebrothers.com, for detailed information of dental books, visit our website jaypeebrothers.com, for de

Textbook of Oral & Maxillofacial Surgery

"He who would climb the ladders, must begin at the bottom"

Salient Features

- Touches almost every aspect of oral and maxillofacial surgery and also gives an equal weightage to basic concepts like basic principles of surgery, fluid and electrolyte balance, parenteral therapy, shock and biomedical waste management.
- Compiles all the basic knowledge, evidenced-based information, explanations thereof and words of wisdom that the authors have gained from their long experience.
- Emphasis on basics and reasoning for better understanding.
- Comprehensive coverage of pathologies, craniofacial trauma, precancer and cancer, orthognathic surgery and distractions, cleft lip and palate, TMJ disorders, salivary gland pathologies, and maxillary sinus.
- Text enriched with illustrative clinical photographs, radiographic images, flow charts, text boxes and tables for better understanding.
- Helpful to the undergraduate and postgraduate students in the field of oral and maxillofacial surgery, otolaryngology, and plastic surgery.
- Evidence-based information, words of wisdom and practical tips for beginners.



Rajiv M Borle MDS FAOMSI is currently working as Professor, Department of Oral and Maxillofacial Surgery, Sharad Pawar Dental College and Hospital, a constituent unit of Datta Meghe Institute of Medical Sciences (Deemed University), Wardha, Maharashtra, India. He is the Director of Smile Train Inc. Project (a global charity for helping the people with cleft lip and palate deformities), Acharya Vinoba Bhave Rural Hospital, attached to the University. He is also Registrar of Datta Meghe Institute of Medical Sciences (Deemed University), Wardha, Maharashtra, India. He has completed his graduation and postgraduation from Government Dental College and Hospital, Nagpur, Maharashtra, India, and has outstanding academic track record. He has seven books to his credit and has published more than 100 papers in the national and international journals. He is a regular face in the national and international conferences pertaining to maxillofacial surgery, cleft lip and palate, otolaryngological and head, neck, face (HNF) oncology and has 94 key note addresses/guest lectures/orations to his credit. He has been the faculty for many national and international workshops and conferences. He has achieved many academic distinctions in his illustrious career. He is a popular teacher since last 30 years and has guided more than 50 postgraduate students and he is also a recognized PhD supervisor.

Shelving Recommendations
DENTISTRY, PLASTIC SURGERY, OTOLARYNGOLOGY

ISBN 978-93-5152-009-2
9 789351 520092

Available at all medical book stores or buy directly from Jaypee Brothers through online shopping at www.jaypeebrothers.com

JAYPEE BROTHERS
Medical Publishers (P) Ltd.
www.jaypeebrothers.com