ers.com, for detailed information of dermatology books, visit our website www.jaypeebrothers.com, for detailed information of dermatology bo

Advances in Pediatric Dermatology-2

Neonatal Dermatology





Guest Editor
Rashmi Sarkar

Series Editors
Arun C Inamadar
Aparna Palit

JAYPEE

Contents

1. Skin Care in Newborn **1**

Rashmi Sarkar, Khushbu Goel, Vijay K Garg

- Principles of Skin Care of the Newborn *1*
- Role of Vernix Caseosa *2*
- Bathing of Newborn *3*
- Cleansing Agents *4*
- Care of the Diaper Area *6*
- Care of the Scalp *6*
- Care of other Areas *7*
- Emollients for the Newborn *7*
- Use of Drugs and Topical Preparations *8*
- Use of Vehicles *9*
- Powders *9*
- Fat or Lipophilic Excipients *9*
- Emulsions *9*
- Care of Infants at High-risk of Atopic Dermatitis *9*

2. Neonatal Transient Benign Cutaneous Lesions: An Update **14**

Margarita Larralde, Paula Carolina Luna

- Transient Physiologic Changes *14*

3. Iatrogenic Cutaneous Injuries in Neonates **24**

Srikanta Basu, Kirtisudha Mishra

- Injuries due to Intravascular Access *25*
- Venepuncture and Heel Lance Injuries *27*
- Burn Injuries *27*
- Adhesive Tape Injuries *29*
- Pressure Injuries *30*

4. Hereditary Diseases in the Newborn: Ichthyosis and Ectodermal Dysplasias **34**

Flavia Reginatto, Tania Cestari

- Ichthyosis in the Newborn *34*
- Classification of Inherited Ichthyosis *34*
- Treatment of Ichthyosis *45*
- Ectodermal Dysplasias in the Newborn *46*

5. Epidermolysis Bullosa and Other Blistering Genodermatoses: An Update **51**

Sultan Al-Khenaizan, Luluah Al Mubarak

- Epidermolysis Bullosa *51*
- Diagnosis of Epidermolysis Bullosa *61*
- Other Blistering Genodermatosis *65*

6. Primary Immunodeficiencies **71**
Subhash Lokre, Ravi Hiremagalore
- Classification *71*
- Laboratory Diagnosis *74*
- Molecular Diagnosis *74*
- Primary Immune Deficiency Prevention *77*
- Primary Immune Deficiency in India—Our Scenario *79*

7. Neonatal Lupus Erythematosus: An Update **81**
Vishalaxi S Pandit, Aparna Palit, Arun C Inamadar
- Epidemiology *81*
- Etiopathogenesis *81*
- Genetic Background *82*
- Clinical Features *82*
- Diagnosis *84*
- Management, Course of the Disease and Prognosis *85*

8. Neonatal Erythroderma: An Approach to Diagnosis and Management **88**
Neela Bhuptani, Timir Y Mehta, Pratik Sheth
- Definition *88*
- Epidemiology *88*
- Etiological Classification *89*
- Etiopathogenesis *90*
- Clinical Features *93*
- Diagnosis and Differential Diagnosis *101*
- Prenatal Diagnosis *105*
- Treatment and Management *105*
- Prognosis *109*
- Follow-up *109*

9. Skin in Congenital Infections in a Newborn: An Update **110**
Archana Singal, Namrata Chhabra
- Viral Infections *110*
- Bacterial Infections *115*
- Fungal Infections *117*
- Protozoal Infections *118*

10. Lumps, Bumps and Hamartomas in the Newborn **121**
Magdalena Hernández, Antonio Torrelo
- Fibromatosis *121*
- Hamartomas and other Frequent Tumors *128*
- Calcinosis Cutis and ossification in the Skin *135*
- Malignant Tumors *136*

11. Vascular Tumors and Malformations **142**

Vikash Oza, Erin Mathes

- Vascular Tumors *142*
- Other Vascular Tumors *148*
- Vascular Malformations *150*

12. Neoplastic and Infiltrative Diseases in the Newborn: An Update **165**

Saumya Panda, Jayoti Nandi

- Vascular Tumors *165*
- Diagnosis *169*
- Immunohistochemistry *170*
- Neurofibromatosis *176*
- Basal Cell Nevus Syndrome *179*
- Histiocytosis *179*
- Cutaneous Mastocytosis *186*

13. Birth Marks of Clinical Significance **198**

Nilendu Sarma, Sayantani Chakraborty

- Hypopigmented Birth Marks *198*
- Hyperpigmentary Birth Marks *211*
- Flexural Pigmentation *215*
- Generalized Hyperpigmentation *217*
- Dyschromia *219*

14. Diaper Dermatitis **222**

Shilpa Garg, Rashmi Sarkar

- Skin of a Newborn *222*
- Etiology of Primary Irritant Diaper Dermatitis *222*
- Pathology *224*
- Incidence of Diaper Dermatitis *224*
- Clinical Features of Primary Irritant Diaper Dermatitis *225*
- Differential Diagnosis *227*
- Prevention *229*
- Treatment of Irritant Diaper Dermatitis *232*
- Prognosis *236*

Index *241*

CHAPTER

2 Neonatal Transient Benign Cutaneous Lesions: An Update

Margarita Larralde, Paula Carolina Luna

JAYPEE BROTHERS

❑ INTRODUCTION

Since birth, neonatal skin undergoes different changes in order to adapt from the aquatic and sterile uterine world, to the more dry, nonsterile, more aggressive extrauterine environment. For these reasons some patients develop lesions that are benign and transient and should be recognized in order to avoid unnecessary procedures. This chapter will address the more recent advances in these diseases.

❑ TRANSIENT PHYSIOLOGIC CHANGES

Vernix Caseosa

It is a white, greasy substance that covers the body of full-term newborns.[1] It is composed by proteins (10%), lipids (10%), and water (80%) together with corneocytes embedded in a hydrophobic matrix.[2] It is thought to have several functions: Intra utero it protects the epidermis from water exposure while facilitating epidermal cornification[2] and in the low humidity of extrauterine world it acts as a barrier to water loss, helps temperature regulation, and acts as an antimicrobial barrier.[3,4]

In full-term newborns, it may cover the entire skin surface or be only confined to body folds. Very low-birthweight infants of less than 28 weeks' gestation and less than 1000 g, have very immature and incompetent stratum corneum and also lack the protective mantle of vernix caseosa.[3]

Although traditional practice has been to wipe vernix caseosa of the newborn, retention of vernix caseosa following birth may lead to significantly higher skin hydration at 24 hours of life.[2,3]

Benign Transient Lesions

Sucking Blisters and Erosions

Flaccid bullae, vesicles or erosion resulting of sucking in utero, may be seldom seen at birth.[5] These lesions are usually single, fluid filled, measure 5–20 mm and are surrounded by normal appearing skin.[6] As they are due to the vigorous

and repetitive suction at one given spot, they are located over regions that are accesible, as the forearms, wrists, hands and fingers (specially thumb and index finger).[7]

They spontaneously resolve without sequelae, usually by 2 weeks of life.[4] These lesions may be confused with more serious diseases in the newborn, such as herpes simplex, bullous impetigo, bullous mastocytosis or epidermolysis bullosa. Some of the newborns may still show suction of the region postnatally,[6] helping to reach the diagnosis, when this does not happen, the characteristic morphology, focal presentation and failure to develop new lesions postnatally may allow correct diagnosis.[4]

Sebaceous Gland Hyperplasia

Sebaceous gland hyperplasia is a very frequent finding in the newborn period. These lesions appear in 40–50% of babies with the lowest incidence among Asians and the highest among African Americans.[8] The incidence also varies according to the gestational age being more frequent among full-term babies and less frequent (although still common) in preterm infants and show a 1:1 female/male ratio.[4]

They are usually present at birth as multiple, pinpoint, white-yellowish papules with no surrounding erythema,[6] at the opening of each pilosebaceous follicle in areas with prominent sebaceous glands, such as the nose, cheeks, upper lip and forehead.[4]

It is thought to result from the influences of androgens (both maternal and fetal) on the pilosebaceous follicle causing hypertrophy of the gland.

Histopathology reveals large sebaceous glands with prominent secretory cells surrounding the pilosebaceous follicles.[4]

Differential diagnosis includes: Milia (epidermal inclusion cysts), are often solitary or few, discrete, and whiter in color.[4] These lesions may appear together in approximately half of affected infants. Neonatal acne, miliaria crystallina and cephalic pustulosis might also be confused as sebaceous hyperplasia.

No treatment is necessary, for lesions tend to resolve in the first week of life.

Milia

Milia are small epidermal cysts commonly found on the newborns. These white-pearly, superficial, firm, 1–2 mm globular papules occur prominently on the nose, cheeks, chin and foreheads in 20–83% of term newborns.[9,10] These lesions can be divided into primary milia (when they occur spontaneously) or secondary milia (when they develop after the healing of another lesion). The number of papules can vary from a few to hundreds. Larger, solitary lesions can be seen on the foreskin, areolae, scrotum, and labia majora.[6] Lesions usually appear and disappear spontaneously during the first month. In some cases, milia may be more persistent.[11] Incision and expression of keratinous contents is rarely necessary.[5]

The origin of primary milia cysts is located in the pilosebaceous apparatus of vellus hair, and contains concentric layers of keratinized stratum corneum.[9]

JAYPEE BROTHERS

Secondary milium originates from epithelial structures such as sweat ducts, hair follicles, or sebaceous ducts. Numerous and persistent milia have been described as part of several genodermatosis **(Table 2.1)**.[4,11,12]

Other genodermatosis, such as Christ-Siemens-Touraine anhidrotic ectodermal dysplasia and Marie-Unna hypotrichosis have been reported to have pseudomilia, lesions that resemble milia clinically but not histologically.[4]

Erythema Toxicum Neonatorum (Toxic Erythema of the Newborn)

Erythema toxicum neonatorum (ETN) is a benign, very frequent and self-limited condition of the neonatal period. It´s incidence is not influenced by sex, race, ethnicity, or season, but seem to be related to the gestational age and weight at birth.[13] It is very common in term infants, but is rare in preterm babies and infants with less than 2,500 g birthweight.[4]

Lesions appear as multiple erythematous macules, papules, pustules or wheals that usually start at the second day of life (but they may begin at any time from birth to 2 weeks of age) **(Fig. 2.1)**. They can be found on any body surface, although palms and soles are rarely affected.

Pustules may develop in around 10% of the cases and in some instances vesicles may be seen occasionally before becoming pustular.[6] The lesions may wax and wain, with spontaneous resolution of individual lesions within hours to days. The lesions are asymptomatic and the baby is usually well.

The etiology of ETN remains unknown, and several theories have been proposed, and although no single organism has been isolated, several cytoquines have been implicated (IL-1 alfa y beta, IL-8, aquaporines y nitrico oxid synthetasa 1, 2 and 3) suggesting that ETN might be a cutaneous response to commensal microbes that penetrated into the skin of the newborn.[13]

Table 2.1: Genodermatoses with milia

Bazex-Dupré-Christol syndrome
Rombo syndrome
Brooke-Spiegler syndrome
Orofaciodigital syndrome type 1
Atrichia with papular lesions
Hereditary vitamin D-dependent rickets type IIA
Pachyonychia congenita type II
Basal cell nevus syndrome
Generalized basaloid follicular hamartomas syndrome
Basan´s syndrome (Familial milia and absent dermatoglyphics)
Familial profuse congenital milia
Nicolau-Balus syndrome Hypotrichosis with light-colored hair and facial milia Keratitis ichthyosis deafness (KID) syndrome Loeys-Dietz syndrome

JAYPEE BROTHERS

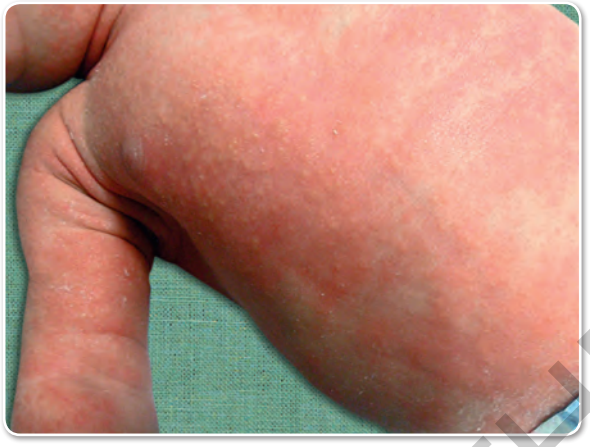

Fig. 2.1: Erythema toxicum neonatorum: erythematous coalescent plaques and papules over the abdomen

Wright stain of pustular contents will show more than 50% of eosinophils. Peripheral blood eosinophilia is seen in some cases. Histologic examination of the macules show a diffuse and perivascular accumulation of eosinophils in the upper dermis. Papular lesions are characterized by discrete hyperkeratosis and upper dermal eosinophils together with an accumulation of eosinophils and some neutrophils around the outer root sheath of hair follicles extending into the epidermis. In pustular lesions, intrafollicular subcorneal eosinophilic pustules are present.[4]

When ETN is typical, the diagnosis is straightfoward. In some cases it may need to be differentiated from other diseases such as transient neonatal pustular melanosis (TNPM), congenital candidiasis, miliaria, bacterial infections, Herpes simplex infection, incontinentia pigmenti, scabies, eosinophilic pustular folliculitis and eosinophilic pustulosis.

Parental reassurance is usually the only intervention needed, given the self-limited behavior of this disease.

Transient Neonatal Pustular Melanosis (Transient Neonatal Pustular Dermatosis)

Transient neonatal pustular melanosis is a benign condition of full-term neonates. It is considered to be very rare[5] and is more commonly seen in black infants.[14]

It is characterized by the presence of multiple pustules or vesicles measuring 1–5 mm over a normal-appearing skin. Lesions may be found in clusters or singly. New lesions cease to appear after birth and the vesicopustules break down, leaving a fine white collarette of scale. Days later the lesions resolve leaving hyperpigmented macules[4] **(Fig. 2.2)**.

Lesions may appear anywere in the skin including genitals, scalp, palms and soles.[15]

JAYPEE BROTHERS



Fig. 2.2: Pustules, white collarets scale and hyperpigmented macule coexisting in a full-term newborn

Its physiopathogenic mechanism is not completely understood, but several investigations have seen some kind of association with ETN, suggesting it might either be a variant of this entity or a precocious form.[6]

Wright staining of the pustules show neutrophils and occasional eosinophils. Histopathologic evaluation reveals neutrophilic, intracorneal or subcorneal, pustules.[15] The pigmented macules show increased basilar melanocytes.

Most important differential diagnosis includes ETN, bacterial, viral, and mycotic infections, miliaria and eosinophilic pustulosis.

Under some circumstanses a clear-cut differentiation between TNPM and erythema toxicum might be really imposible.

Given the benign and self-limited nature of this disease, no therapy is usually necessary.

Miliaria

Miliaria is a dermatosis caused by the extravasation of sweat into the skin due to the obstructions and rupture of the eccrine duct. It can happen at any age but is particularly frequent in neonates, specially in those born in warm climates, in nurseries without air-conditioning and in febrile infants.[4] The most supperficial type (with the obstruction located at the stratum corneum) is known as miliaria crystallina (sudamina), it appears as fragile, pinpoint, clear, superficial vesicles over a non-inflammatory skin. It is more common in the first week of life, with some reports of congenital lesions.[16] Lesions tend to develop mainly on the forehead and upper trunk.

Miliaria rubra (prickly heat, or "heat rash") is due to a deeper obstruction (intraepidermal) with leakage around the ducts that results into secondary local inflammation. Lesions are erythematous with nonfollicular papules, pustules and vesicles. It tends to affect the face, neck, and trunk. It usually

JAYPEE BROTHERS

occurs during the second week of life. Althought it is usually benign, several cases associated with salt-depletion crises in severe autosomal recessive type 1 hypoaldosteronism, have been reported.[14,17]

The deepest type of miliaria, miliaria profunda, is extremely rare in neonates.

As lesions tend to resolve spontaneously the most important intervention is to teach the caregivers to minimize overheating of the infant. Cool baths and air-conditioning are useful.[4]

Neonatal Cephalic Pustulosis

Acneiform eruptions can be seen in up to 20% of newborns. Most of these eruptions, that were in the past considered altogther under the term "neonatal acne", are actually what today is known as neonatal cephalic pustulosis (NCP).

Neonatal cephalic pustulosis is a benign, transient papulopustular eruption that affects mainly the face (cheeks, chin, eyelids and forehead), scalp,[18] and the upper chest. The spectrum of lesions is quite variable, ranging from few erythematous papules **(Fig. 2.3)**, to more extensive, coalescent pustules **(Fig. 2.4)**. Comedones are typically absent, for if they are present the dermatosis consider to be true neonatal acne. This eruption is never congenital and tends to start aroud the fith day of life.[4]

Neonatal cephalic pustulosis has been attributed to *Malassezia furfur* or *M. sympodialis* yeasts.[19] As this microorganism can be found in 50% of newborns at birth and 80% at 7 days of life, other factors that may influence the development of this pustulosis are to be investigated.[4] In most patients diagnosis is clinical, the absence of comedones distinguishes this entity from true neonatal acne. If needed KOH preparation and culture of the pustule can be of help.

Most patients do not require treatment although in more profuse and persistent eruptions caregivers will demand a solution. Topical antifungal (azolic based) may clear the eruption in few days.[4]



Fig. 2.3: Benign cephalic pustulosis with subtle erythematous papules

JAYPEE BROTHERS



Fig. 2.4: Benign cephalic pustulosis with extensive coalescent pustules over

Neonatal Acne (Acne Neonatorum)

True neonatal acne is rare, and is defined as acne that is present, or occurs shortly after birth.[4] In the past this term has been used to describe also what today is known as neonatal cephalic pustulosis, but true neonatal acne is characterized by the presence of at least some comedones[18] **(Fig. 2.5)**, still today there is controversy, and some authors consider true neonatal acne a benign cephalic pustulosis to be to two ends of the same spectrum.[19] It usually develops at few weeks of life and is manifested mainly by multiple open or closed comedones as well as erythematous papules and pustules. Nodules and cystic lesions might also be present and might lead to scaring.[4] Lesions are usually localized over the cheeks and forehead and tend to resolve spontaneously towards the first month of age.

Although the pathogenic mechanism remains unknown, in the past it has been attributed to maternal androgens, and recently it has been suggested that



Fig. 2.5: Neonatal acne. Multiple comedones in the face of a 1-month-old baby

JAYPEE BROTHERS

it might be due to an increase in dehydroepiandrosterone (DHEA) production causing enlargement and, in some cases, hyperactivity of the fetal adrenal gland.[18]

As it is usually self-limited, only in the few instances when lesions are very severe, they last more than few months or the neonate shows other alterations (growth, maturation) an endocrinologic workup to rule out disorders such as adrenal cortical hyperplasia, virilizing tumor or other disorders is needed.[18]

No treatment is usually needed. If necessary, therapies such as benzoyl peroxide, erythromycin, clindamycin or even a low potency topical retinoid could be tried.[18-20]

Oral Lesions

Epstein's Pearls

Epstein's pearls (or palatal cysts) are thought to be the counterpart of facial milia but along the median palatal raphe instead of the face.[11] Lesions are usually multiple and small, (less than a millimeter), but single bigger lesions have also been described. Epstein's pearls are common, with an incidence of 60–88.1% of newborn infants.[4] They have been described in up to 92% of Japanese newborns. In a study describing lesions in 1,000 consecutive births in spain, they found a higher frequency of palatal cysts in full-term Caucasian female newborns with high weight at birth.[9] Longer gestation has also been associated with this finding.[12]

These lesions are epidermal inclusion cysts formed during the fusion of the soft and hard palates, and contain desquamated keratin within their lumens. As most lesions break spontaneously within the first few weeks to months of life no therapy is indicated.[4]

Bohn's Nodules

Bohn's nodules are multiple, small cystic structures found along the lingual or buccal surfaces of the alveolar ridges and the lateral palate.[4] The overall appearance is similar to the Bohn nodule, but the location and etiology makes this a distinct entity.

These lesions are less common than palate cysts, with an incidence of less than 20%.[9,21]

A descriptive study found that development of gingival cysts were associated with female sex, high birthweight, greater gestational age, and more than two previous pregnancies.[9]

Bohn's nodules are thought to develop from epithelial remnants of salivary gland tissue or from remnants of the dental lamina.[4] As spontaneous involution or shedding is the rule, therapy is unnecessary.

Natal And Neonatal Teeth

Teeth tend to start their normal eruption around the sixth month of life. In some rare cases teeth might be seen during the neonatal period.[22] When teeth are present since birth, they are known as natal teeth. Neonatal teeth, are those that erupt during the first month of life.[4]

JAYPEE BROTHERS

The incidence of natal and neonatal teeth ranges from 1:1000 to 1:30000 depending on the study[23] with natal teeth occuring three times more often than neonatal teeth.[4] The most common location for natal teeth is at the sites of the central mandibular incisors (85%), followed by the maxillary incisors (11%) mandible molars or canines (3%) or maxillar canines or molars (1%).[4] Teeth can appear alone or in pairs.

These teeth are poorly developed, small and cone-shaped and usually have a yellowish-brown or whitish opaque color with hypoplastic enamel or dentin.

Several syndromes have been associated with natal/neonatal teeth **(Table 2.2)** and they also seem to be more frequent in patients with cleft lip **(Fig. 2.6)**.[23]

An X-ray should be perfomed in order to differentiate deciduous teeth from supernumerary teeth. Supernumerary teeth are extraneous teeth, with no root, which should be extracted, as they may interfere with normal tooth eruption, may cause trauma, such as Riga Fede ulcer or may be aspirated. Treatment of natal teeth is dependent upon morphology, amount of root development, and mobility. If the tooth is only minimally loose, it will tend to stabilize over time and can be left in place. Problematic teeth should be extracted to prevent complications.[4]

Table 2.2: Syndromes with neonatal teeth

Ellis-van Creveld
Hallermann-Steriff
Pachyonychia congenita
Pallister Hall
Wiedemann-Rautenstrauch
Hypomyelinating leukoencephalopathy 4H syndrome/ADDH
X-linked Opitz (G/BBB) syndrome.
Down's syndrome
Congenital hypothyroidism



Fig. 2.6: Cleft lip and cleft palate with a neonatal teeth

JAYPEE BROTHERS

❑ REFERENCES

1. Afsar FS. Physiological skin conditions of preterm and term neonates. Clin Exp Dermatol. 2010;35(4):346-50.
2. Visscher MO, Utturkar R, Pickens WL, LaRuffa AA, Robinson M. Neonatal skin maturation--vernix caseosa and free amino acids. Pediatr Dermatol. 2011;28(2):122-32.
3. Singh G, Archana G. Unravelling the mystery of vernix caseosa. Indian J Dermatol. 2008;53(2):54-6.
4. Eichenfield L, Lee P, Larralde M, Luna P. Neonatal skin and skin disorders. In: Schachner AL, Hansen RC (Eds). Pediatric Dermatology, 3rd edition. China: Elsevier Ltd; 2011. pp. 299-373.
5. Tarang G, Anupam V. Incidence of vesicobullous and erosive disorders of neonates. J Dermatol Case Rep. 2011;5(4):58-63.
6. Lucky AW. Transient benign cutaneous lesions in the newborn. In: Eichenfield LF, Frieden I, Esterly N (Eds). Neonatal Dermatology, 2nd edition. China: Saunders Elsevier; 2008. pp. 85-97.
7. Monteagudo B, Labandeira J, León-Muiños E, Caraballeira I, Acevedo A, Suarez-Amor O, et al. Neonatal sucking blisters: prevalence and differential diagnosis. An Pediatr (Barc). 2011;74(1):62-4.
8. Kanada KN, Merin MR, Munden A. A prospective study of cutaneous findings in newborns in the United States: correlation with race, ethnicity, and gestational status using updated classification and nomenclature. J Pediatr. 2012;161:240-5.
9. Monteagudo B, Labandeira J, Cabanillas M, Acevedo A, León-Muiños E, Toribio J. Prevalence of milia and palatal and gingival cysts in Spanish newborns. Pediatr Dermatol. 2012;29(3):301-5.
10. Gupta P, Faridi MM, Batra M. Physiological skin manifestations in twins: association with maternal and neonatal factors. Pediatr Dermatol. 2011;28(4):387-92.
11. Berk DR, Bayliss SJ. Milia: a review and classification. J Am Acad Dermatol. 2008;59(6):1050-63.
12. Luna PC, Larralde M. Profuse congenital familial milia with absent dermatoglyphics (Basan's Syndrome): description of a new family. Pediatr Dermatol. 2012;29(4):527-9.
13. Morgan AJ, Steen CJ, Schwartz RA, Janniger CK. Erythema toxicum neonatorum revisited. Cutis. 2009;83(1):13-6.
14. Agusti-Mejias A, Messeguer F, Febrer I, Alegre V. Transient neonatal pustular melanosis. Actas Dermosifiliogr. 2013;104:84-5.
15. Chia PS, Leung C, Hsu YL, et al. An infant with transient neonatal pustular melanosis presenting as pustules. Pediatr Neonatol. 2010;51(6):356-8.
16. Babu TA, Sharmila V. Congenital miliaria crystallina in a term neonate born to a mother with chorioamnionitis. Pediatr Dermatol. 2012;29(3):306-7.
17. Onal H, Adal E, Ersen A, Onal Z, Keskindemirci G. Miliaria rubra and thrombocytosis in pseudohypoaldosteronism: case report. Platelets. 2012;23(8):645-7.
18. Friedlander SF, Baldwin HE, Mancini AJ, Yan AC, Eichenfield LF. The acne continuum: an age-based approach to therapy. Semin Cutan Med Surg. 2011;30(3 Suppl):S6-11.
19. Mancini AJ, Baldwin HE, Eichenfield LF, Friedlander SF, Yan AC. Acne life cycle: the spectrum of pediatric disease. Semin Cutan Med Surg. 2011;30(3 Suppl):S2-5.
20. Antoniou C, Dessinioti C, Stratigos AJ, Katsambas AD. Clinical and therapeutic approach to childhood acne: an update. Pediatr Dermatol. 2009;26(4):373-80.
21. da Silva CM, Ramos MM, Carrara CF, Dalben G. Oral characteristics of newborns.J Dent Child (Chic). 2008;75(1):4-6.
22. Gupta P, Faridi MM, Batra M. Physiological skin manifestations in twins: association with maternal and neonatal factors. Pediatr Dermatol. 2011;28(4):387-92.
23. Basavanthappa NN, Kagathur U, Basavanthappa RN, Suryaprakash S. Natal and neonatal teeth: a retrospective study of 15 cases. Eur J Dent. 2011;5:168-72.

JAYPEE BROTHERS

detailed information of dermatology books, visit our website www.jaypeebrothers.com, for detailed information of dermatology books, visit our

Advances in Pediatric Dermatology-2

Neonatal Dermatology

Salient Features

- A first time monograph on Neonatal Dermatology from Asia
- Common and unusual entities in neonatal period written by experts from India and around the globe
- A beautifully illustrated must-have book for dermatology and pediatric consultants, practitioners and students
- An uncared subspecialty made interesting for dermatologists and pediatricians
- Differential diagnosis and management made simple for the neonatal dermatological conditions.



Rashmi Sarkar MD MNAMS is Professor of Dermatology at Maulana Azad Medical College and Associated Lok Nayak Hospital, New Delhi, India. She has done her MD in Dermatology from PGI, Chandigarh, India. Her special interests are in Pigmentary Disorders and Pediatric Dermatology. She has done Visiting Fellowship in Pediatric Dermatology in Pediatric Dermatology Division, Dermatology Department, University of California, San Francisco, USA. She was the Founder Editor of Asian Pigment Bulletin (APB); is Associate Editor of Journal of Cutaneous and Aesthetic Surgery (JCAS); on the Editorial Board of Indian Journal of Dermatology, Venereology and Leprology (IJDVL), Indian Journal of Pediatric Dermatology (IJPD), ISRN Dermatology, and Editorial Advisory Board of Indian Journal of Dermatology (IJD) besides being a reviewer for 11 Journals. She has 95 publications in peer-reviewed international and national journals and 30 chapters in textbooks of dermatology and pediatrics. She has edited 2 textbooks in dermatology. She is National Honorary Secretary of Indian Association of Dermatologists, Venereologists and Leprologists (2014–2016), Chief Founder and Honorary Secretary of Pigmentary Disorders Society (PDS) and Founding President of Joint Women's Dermatologic Society—Indian Women's Dermatologic Society. She is the recipient of several prestigious awards and honors including Maria Duran Fellowship from International Society of Dermatology, Member Making a Difference Award from American Academy of Dermatology and Career and Community Development Award from Women's Dermatologic Society and other International Travel Awards from ISD, WCD and AAD. Dr Rashmi has been an invited speaker in international and national conferences like Annual AAD, World Congress of Dermatology, World Congress of Pediatric Dermatology, ASPCR, IPCC, Dermacon, Dermazone, and ISPD conferences. She is International Representative, Board of Directors, Women's Dermatologic Society (WDS), Board of Directors in Skin of Color Society (SOCS), Member of International Mentorship Committee of International Society of Dermatology (ISD), Chair of Women's Committee of International Federation of Pigment Cell Research Societies (IFPCS) and International Affairs Committee of WDS, Council Member of Asian Society of Pigment Cell Research.



Arun C Inamadar MD DVD is Professor and Head, Department of Dermatology, Shri BM Patil Medical College, Hospital and Research Center, BLDE University, Bijapur, Karnataka, India. He is a dedicated academician with more than 130 published articles in indexed and non-indexed journals and has contributed more than 18 chapters in various textbooks and edited 4 books in Dermatology. He has presented papers and delivered guest talks in several national and international meets. He has travelled length and breadth of India and many overseas countries to deliver guest talks. He has served the national body of Indian Association of Dermatologists, Venereologists and Leprologists (IADVL) as Vice-President and Chairperson of IADVL Academy of Dermatology. He is the member of membership committee of European Academy of Dermatology and Venereology (EADV). He is member of ISD, AAD and ESPD. His areas of interest are pediatric dermatology (viz. genodermatology), clinical dermatology and critical care in dermatology.



Aparna Palit MD is Professor, Department of Dermatology, Shri BM Patil Medical College, Hospital and Research Center, BLDE University, Bijapur, Karnataka, India. She has 75 published articles in indexed journals and has contributed more than 15 chapters in various textbooks and co-edited 3 books in Dermatology. She has presented papers and delivered guest talks in several national and international meets. Her interest in medical writing is exemplary. Her areas of interest are pediatric dermatology, atopic dermatitis and leprosy.

Shelving Recommendations
PEDIATRICS
DERMATOLOGY

ISBN 978-93-5152-117-4



Available at all medical book stores
or buy directly from Jaypee Brothers through online shopping
at www.jaypeebrothers.com

JAYPEE BROTHERS
Medical Publishers (P) Ltd.
www.jaypeebrothers.com