led information of cardiology books, visit our website www.jaypeebrothers.com, for detailed information of cardiology books, visit our website www.jaypeebrothers.com

Transesophageal Echocardiography of the Tricuspid & Pulmonary Valves

Includes DVD-ROM

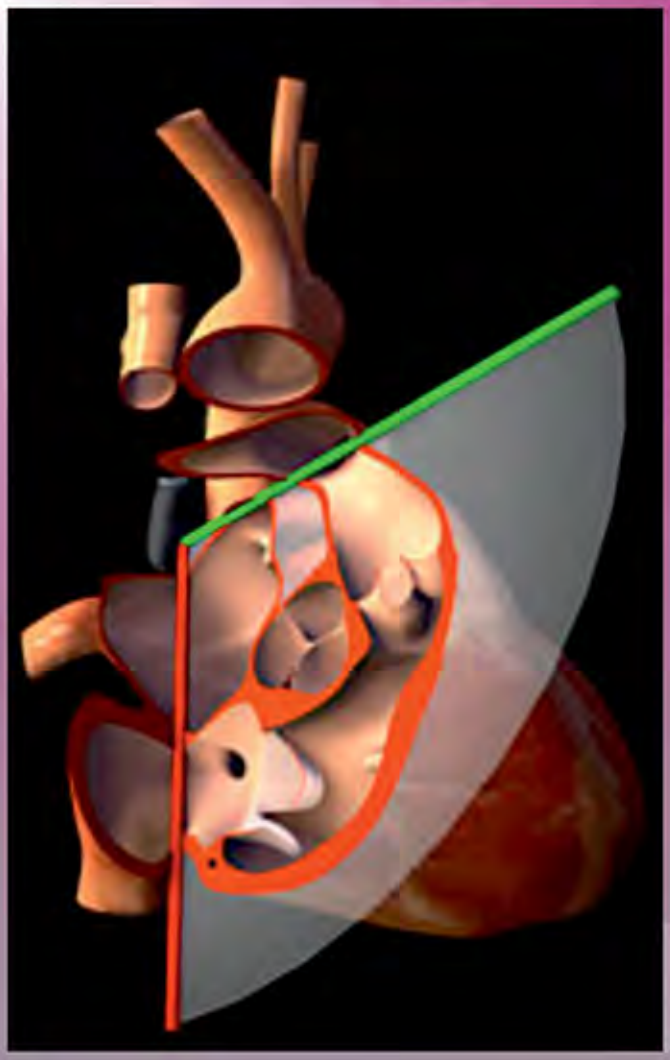

Editor

Poonam Malhotra Kapoor

Section Editors

Yatin Mehta
Muralidhar Kanchi
Rajiv Juneja

Under the Aegis of SCA—Delhi and NCR

Forewords
Navin C Nanda
Balram Airan

JAYPEE

Contents

SECTION I: TRANSESOPHAGEAL ECHOCARDIOGRAPHY OF TRICUSPID VALVE

Section editor: Yatin Mehta

1. **Anatomy of Tricuspid and Pulmonary Valves** 3
Poonam Malhotra Kapoor, Ajay Jha

Anatomy of the Tricuspid Valve 3; Chordae 6; Pulmonic Valve Anatomy 14; Anatomy of the Right Heart 16; Physiology of the Right Heart 16; Application of Tricuspid Valve and Pulmonary Anatomy 20; Right Ventricular Diastolic Function 27

2. **Transesophageal Echocardiography Views of Tricuspid and Pulmonary Valves** 29
Murali Chakarvarthy, Poonam Malhotra Kapoor, SN Das

Mid-esophageal Four-Chamber View 34; Mid-esophageal Mitral Commissural View 36; Mid-esophageal Ascending Aorta: Short Axis View 37; Mid-esophageal Ascending Aorta Long Axis View 39; Mid-esophageal Right Pulmonary Vein View 40; Mid-esophageal Aortic Valve Short Axis View 41; Mid-esophageal Right Ventricular Inflow-outflow View 42; Mid-esophageal Modified Bicaval View 43; Upper-esophageal Right and Left Pulmonary Veins View 44; Transgastric Basal Short Axis View 45; Transgastric Mid Papillary Short Axis View 47; Transgastric Apical Short Axis View 48; Transgastric Right Ventricular Basal View 49; Transgastric Right Inflow-outflow View 50; Deep Transgastric 5-Chamber View 51; Transgastric Right Ventricular Inflow View 52; Upper-esophageal Aortic Arch: Short Axis View 53; Transesophageal Echocardiography Views to Assess Pulmonary Valve 54; ASE/SCA 2013 Guidelines for Tricuspid Valve 3D TEE 55; Pulmonary Valve 3D TEE 57

3. **Doppler Examination Across Tricuspid and Pulmonary Valves** 61
Poonam Malhotra Kapoor, Sameer Taneja, Mahesh Vakamudi

Estimation of Intracardiac Pressures 64; Shunt Fractions 67

4. **Tricuspid Regurgitation** 71
Poonam Malhotra Kapoor, Dharmesh Aggarwal

Severity of Tricuspid Regurgitation 73; Etiology of Tricuspid Regurgitation 76; Functional Tricuspid Regurgitation 78; Pathogenesis of Tricuspid Regurgitation in Mitral Valve Disease 81; Leaflet Tethering of Functional Tricuspid Regurgitation 83; TEE Views of Tricuspid Regurgitation 86; Tricuspid Regurgitation due to Infective Endocarditis 88; Miscellaneous Etiologies 90; Intraoperative Post-cardiopulmonary Bypass Laminar Tricuspid Regurgitation 90; Atrioventricular Canal Defect Causing Tricuspid Regurgitation 93; Tricuspid Regurgitation with TOF 93; Double Chambered Right Ventricle 95; Chronic Constrictive Pericarditis 97; Tricuspid Regurgitation due to Ebstein's Anomaly 102; Absent Pulmonary Valve 105; 2D Echocardiography 108;

Color Flow Doppler 108; Continuous Wave Doppler for Tricuspid Valve 111; Pulse Wave Doppler 113; Measurement of the Vena Contracta 115; Moderate Tricuspid Regurgitation during Mitral Valve Surgery 117; Endocardial Lead Induced Tricuspid Regurgitation 119; Tricuspid Valve Anatomy on Real Time 3D Echocardiography 120; Traumatic Tricuspid Regurgitation on 3D TEE 124; Usefulness of Live 3D Echocardiography in Tricuspid Regurgitation 124; Tricuspid Regurgitation 3D Color Flow Doppler 126

5. Tricuspid Stenosis **133**
Poonam Malhotra Kapoor, Arindam Choudhury, Manju Mani

Etiology of Tricuspid Stenosis 133; Rheumatic in Tricuspid Stenosis 134; Carcinoid in Tricuspid Stenosis 135; Eosinophilic in Tricuspid Stenosis 135; Live 3D Echocardiography in Carcinoid Disease 137; Metabolic and others Abnormalities in Tricuspid Stenosis 137; Pacemaker Lead-induced Severe Tricuspid Valve Stenosis 137; Infective Endocarditis in Prosthetic Tricuspid Valve 138; Other Miscellaneous Etiology of Tricuspid Valve 138; Pathophysiology of Tricuspid Valve 139; Sequelae of Tricuspid Stenosis 141; Anatomic Presentation of Tricuspid Stenosis 142; How to Grade Tricuspid Stenosis? 142; Approaches to Three-dimensional Imaging of the Tricuspid Valve Stenosis 146; Percutaneous Transcatheter Valve-in-valve Implantation in Stenosed Tricuspid Valve Bioprosthesis 146

SECTION II: TRANSESOPHAGEAL ECHOCARDIOGRAPHY OF PULMONARY VALVE

Section editor: Muralidhar Kanchi

6. Pulmonary Stenosis **153**
Poonam Malhotra Kapoor, Sarvesh Pal Singh

Anatomy of Pulmonary Valve 153; Valve Anatomy 154; What is Pulmonary Stenosis? Pathophysiology of Pulmonary Stenosis 154; Physiology of Pulmonary Stenosis 156; Infundibular Pulmonary Stenosis 160; Pulmonary Artery and Vein Stenosis 161; Why is Pulmonary Stenosis a Concern? 161; Color Wave and Pulse Wave Doppler and Pressure Gradients Across the Pulmonary Stenosis 162; Pressure Gradient Across the Pulmonary Stenosis 166; Severity Definitions of Pulmonary Stenosis 169

7. Pulmonary Regurgitation **183**
Poonam Malhotra Kapoor, Suruchi Hasija

Etiology of Pulmonic Regurgitation 184; Etiology and Mechanisms of Pulmonary Regurgitation 185; Other Etiologies of Pulmonary Regurgitation 185; Pulmonary Regurgitation in Tetralogy of Fallot 186; Pathophysiology of Pulmonary Regurgitation 186; Clinical Presentation of Pulmonary Regurgitation 188; Investigations for Pulmonary Regurgitation 189; 2-Dimensional Echocardiography and M-Mode 191; Color Flow Doppler 191; Continuous-wave Doppler and Pulse Wave Doppler 192; Vena Contracta Width 193; Flow Convergence Method 194; Pulsed Doppler 194; Regurgitant Volume and Fraction 194; 3-Dimensional TEE of Pulmonary Regurgitation 196; Role of Exercise Echocardiography 198; Integrating Indices of Severity 198; Assessment of Pulmonary Regurgitation Severity 199; Severity of the Pulmonary Regurgitation 199

8. Pulmonary Artery Hypertension **203**
Poonam Malhotra Kapoor, Vishwas Malik, Usha Kiran

Causes of Pulmonary Hypertension 204; Clinical Features of Pulmonary Hypertension 204; Echo Assessment of Pulmonary Hypertension 205; Pulmonary Artery Systolic Pressure Measurement on TEE 205; TR V_{max} for Pulmonary Artery Hypertension Diagnosis 209; Pulmonary Artery Diastolic Pressure 211; Associated Features 212; Sample Report as a Summary of Pulmonary Arterial Hypertension Echo Measurement 212

9. Ebstein's Anomaly **215**
Navin C Nanda, Poonam Malhotra Kapoor, Arun Subramaniam

Anatomy of Ebstein's Anomaly 215; Clinical Presentation in Ebstein's Anomaly 216; Congenital Abnormalities of Tricuspid Valve: Ebstein's Anomaly 217; Jugular Venous Pressure in Ebstein Anomaly 220; Cathlab of Ebstein's Anomaly 220; Electrocardiogram in Ebstein's Anomaly 221; Echocardiography of Ebstein's Anomaly 221; Management of Ebstein's Anomaly 222; Three-dimensional Transesophageal Echocardiographic (TEE) of Ebstein's Anomaly 223

10. Cardiac Masses Across Tricuspid and Pulmonary Valves **229**
Ramchandran Gopinath, Poonam Malhotra Kapoor, Suruchi Ladha

Tumors 230; Myxoma 230; Thrombus 234; Vegetations 235; Endocarditis 235; Abscesses 237; Bioprosthetic Valve Endocarditis 239

11. Miscellaneous Lesions Affecting Tricuspid and Pulmonary Valves **243**
Poonam Malhotra Kapoor, Kalpana Irpachi

Transesophageal Echocardiography in Carcinoid Disease Affecting the Heart 243; Other Inflammatory Valvulopathies 246; Tricuspid Valve Replacement 253; Ebstein's Anomaly and the Right Heart 258

SECTION III: MULTIPLE CHOICE QUESTIONS
Section editor: Rajiv Juneja

12. Multiple Choice Questions **263**
Poonam Malhotra Kapoor, BS Sethi

True and False Questions 277

Index *283*

2 Transesophageal Echocardiography Views of Tricuspid and Pulmonary Valves

Murali Chakarvarthy, Poonam Malhotra Kapoor, SN Das

JAYPEE BROTHERS

- Mid-Esophageal Four-Chamber View
- Mid-Esophageal Mitral Commissural View
- Mid-Esophageal Ascending Aorta: Short Axis View
- Mid-Esophageal Ascending Aorta: Long Axis View
- Mid-Esophageal Right Pulmonary Vein View
- Mid-Esophageal Aortic Valve Short Axis View
- Mid-Esophageal Right Ventricular Inflow-Outflow View
- Mid-Esophageal Modified Bicaval View
- Upper-Esophageal Right and Left Pulmonary Veins View
- Transgastric Basal Short Axis View
- Transgastric Mid Papillary Short Axis View
- Transgastric Apical Short Axis View
- Transgastric Right Ventricular Basal View
- Transgastric Right Inflow-Outflow View
- Deep Transgastric 5–Chamber View
- Transgastric Right Ventricular Inflow View
- Upper-Esophageal Aortic Arch: Short Axis View
- Transesophageal Echocardiography Views to Assess Pulmonary Valve
- ASE/SCA 2013 Guidelines for Tricuspid Valve 3D TEE
- Pulmonary Valve 3D TEE

INTRODUCTION

Transesophageal echocardiography (TEE) has the unique advantage of portability and the ability to obtain high-resolution images of the abnormal cardiovascular anatomy, function and is relatively easy to perform with a low risk of complications.

Transesophageal echocardiography use has become an integral part in the care of cardiac surgical patients. This is evolving to be used in other subspecialties. The purpose of this article is to introduce the novice echocardiographer to a stepwise approach in image orientation and acquisition.

The American Society of Echocardiography (ASE) and the SCA have suggested a set of standard views and the nomenclature for those views **(Figs 1A to T)**. This nomenclature should be followed whenever possible to minimize confusion. Generally, a combination of these views allows for a complete diagnostic examination. However, deviation from these standard views may be necessary to obtain images appropriate to the individual patient **(Table 1)**. It is beneficial

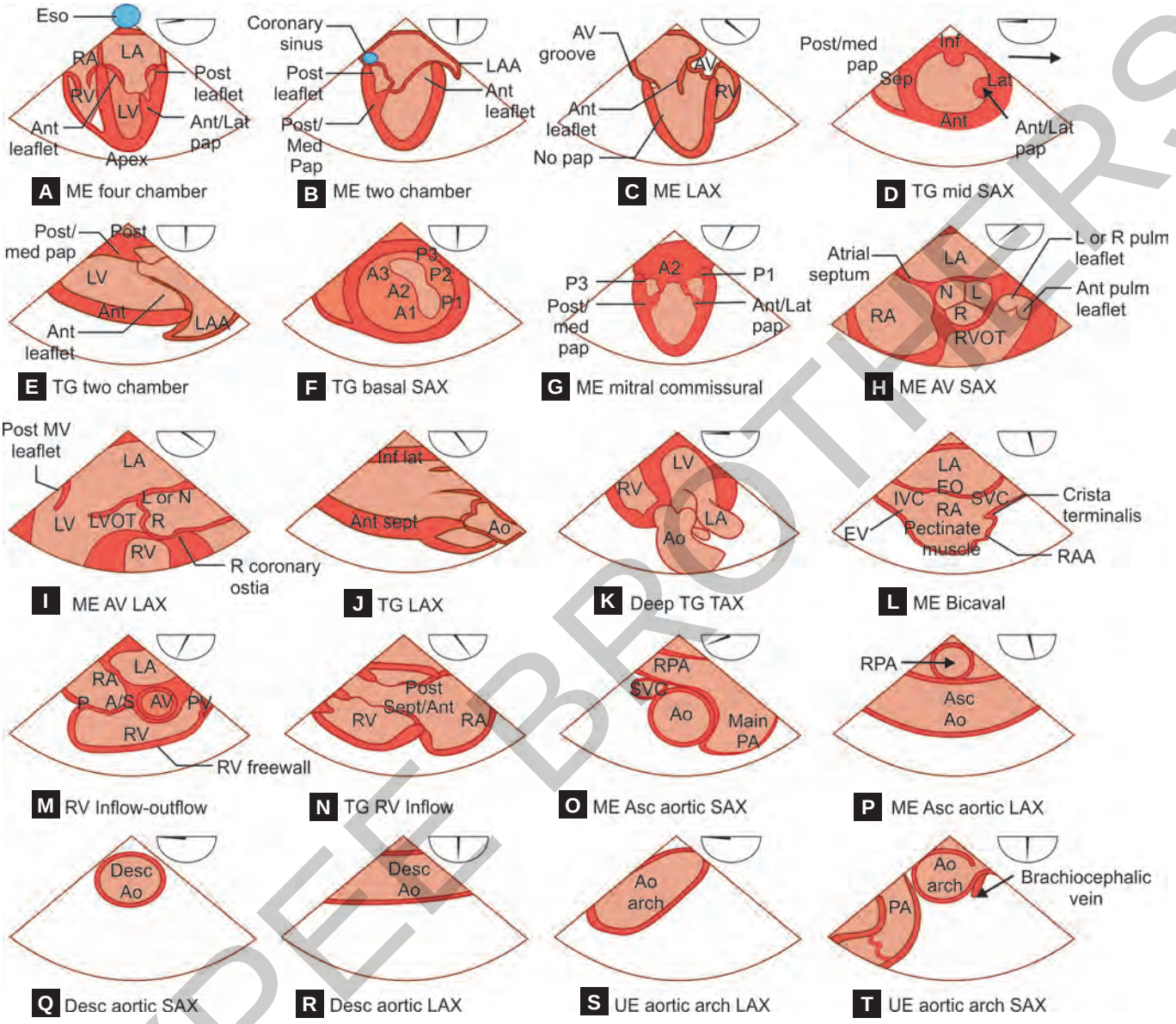

Figures 1A to T

The following is a suggestion for how to perform a focused 20-view TEE exam. There are many ways to do the exam, and ultimately the order of the exam depends on the preference of the examiner and the specific conditions of the patient. After you become familiar with the views, you can devise an order that works for you. Doing the exam in a similar fashion every time will ensure that you examine all 20 views and cover all the basics of the TEE exam for every patient. A basic 20 view exam can easily be expanded to the full ASE/SCA views with more experience (*Source*: ASE/SCA "Guidelines for performing a comprehensive intraoperative multiple TEE examination" Shanewise, et al. 1999)

to be flexible about the order in which the views are obtained to allow focusing on a specific clinical question in a timely manner. Each echocardiographer should develop a systematic order for routine diagnostic TEE. This not only allows for increased speed and efficiency but also ensures that an important finding will not be missed simply because a view was forgotten.

JAYPEE BROTHERS

TEE Views for TV and PV (Figs 2A to I)

Table 1: List of focused views for tricuspid and pulmonary valve

- Mid-esophageal 4-chamber view
- Mid-esophageal mitral commissural view
- Mid-esophageal ascending aorta long axis view
- Mid-esophageal ascending aorta short axis view
- Mid-esophageal right pulmonary vein view
- Mid-esophageal aortic valve short axis view
- Mid-esophageal right ventricular inflow-outflow view
- Mid-esophageal modified bicaval TV view
- Upper esophageal right and left pulmonary veins view
- Transgastric basal short axis view
- Transgastric mid papillary short axis view
- Transgastric apical short axis view
- Transgastric right ventricular basal view
- Transgastric right inflow-outflow view
- Deep transgastric 5-chamber view
- Transgastric right ventricular inflow view
- Upper esophageal aortic arch short axis view

Probe Manipulation

Once in the esophagus, the transducer should be gently guided and the operator should never apply undue force.

There are 4 probe manipulations for optimal image acquisition. The probe manipulation described here is made with reference to the operator standing at the patient's head and looking towards the patient's feet.

1. *Advance, withdraw:* Pushing or pulling the tip of the TEE probe.
2. *Turn to right, turn to left (also referred to as clockwise and anticlockwise):* Rotating the anterior aspect of the TEE probe to the right or left of the patient.
3. *Anteflex, retroflex:* Anteflex is flexing the tip of the TEE probe anteriorly by turning the large control wheel clockwise. Retroflex is flexing the tip of the TEE probe posteriorly by turning the large wheel anticlockwise.
4. *Flex to right, flex to left:* Flexing the tip of the TEE probe with the small control wheel to the patient's right or left. The probe flexion to the right and left may not be necessary and should be avoided to minimize trauma to the esophagus **(Figs 4A to D)**.

- **The same has been revised in 2013. Eleven basic views should be followed by an echocardiographer and of these 9 ME and UE views (Figs 2A to I) and 8 TG views (Figs 3A to H) are important for detailed evaluation of tricuspid and pulmonary valve.**

JAYPEE BROTHERS

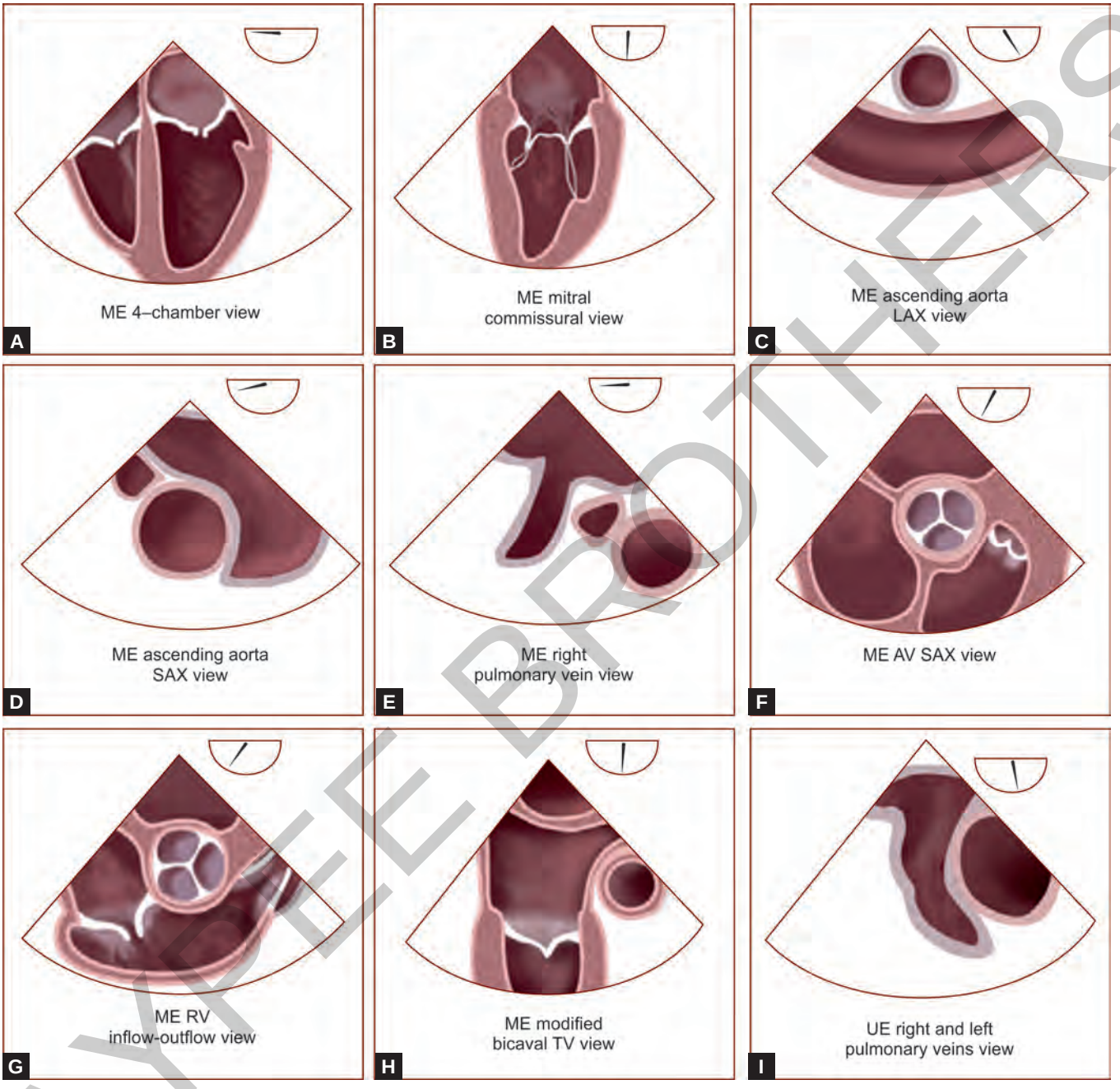

Figures 2A to I

Nine mid-esophageal views on TEE for quick assessment of tricuspid and pulmonary valve

JAYPEE BROTHERS

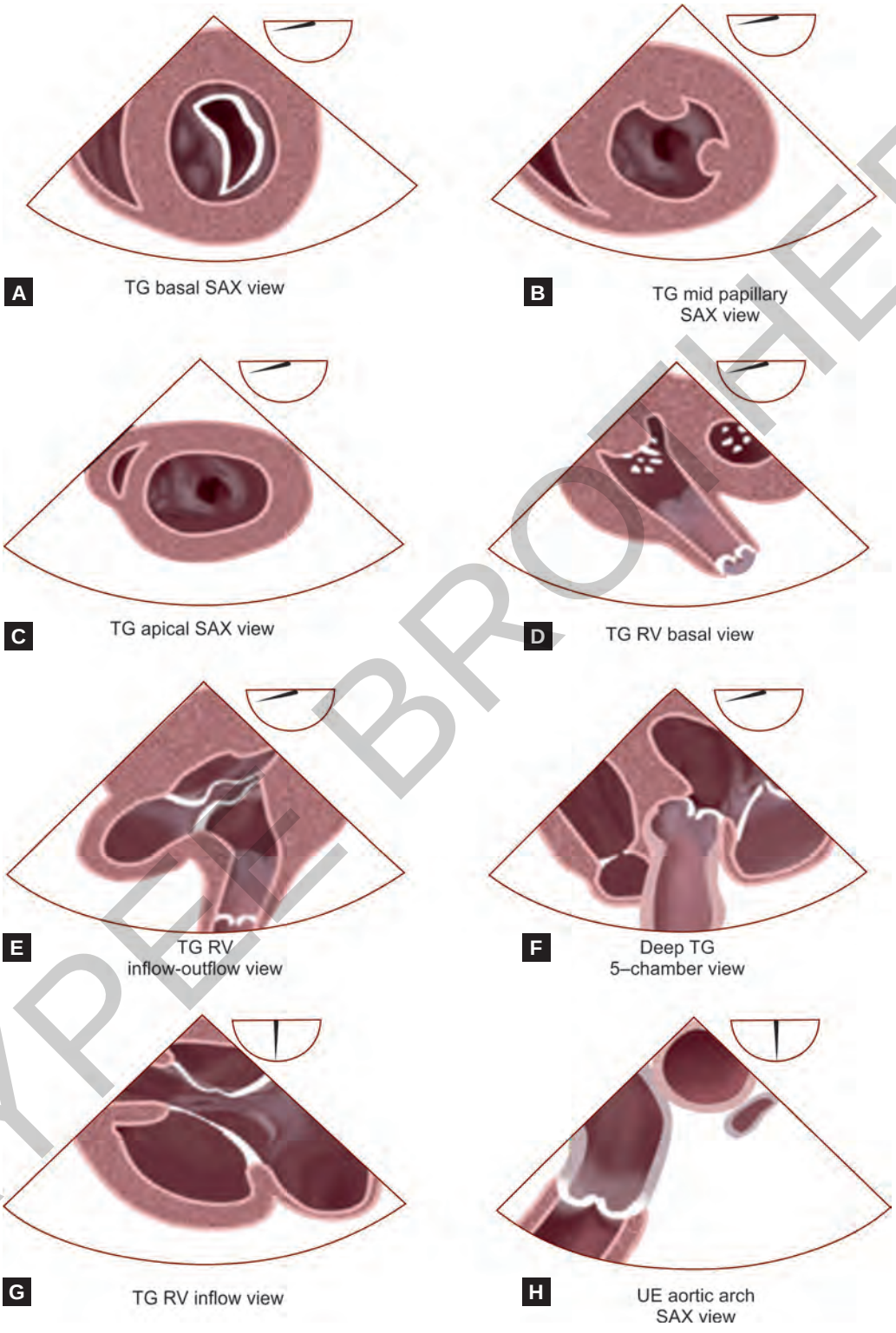

Figures 3A to H

Eight transgastric views on TEE for quick assessment of tricuspid and pulmonary valve

JAYPEE BROTHERS

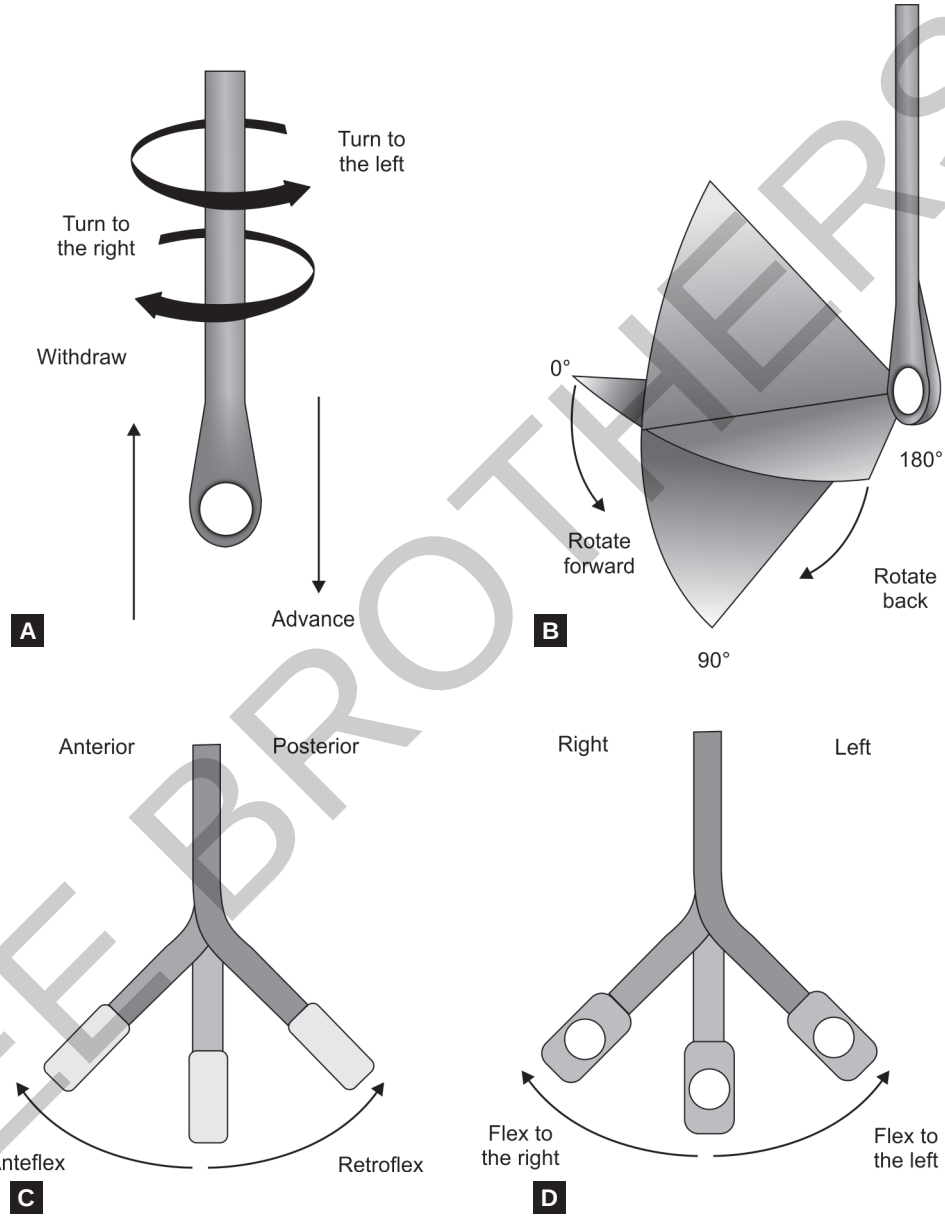

Figures 4A to D

Terminology of TEE probe manipulation

MID-ESOPHAGEAL FOUR-CHAMBER VIEW (FIGS 5A to E)

Multiplane Angle Range

- 0 to 20°
- *Sector depth:* ~ 12 to 14 cm

Anatomy Imaged

- Left ventricle and atrium
- Right ventricle and atrium

JAYPEE BROTHERS

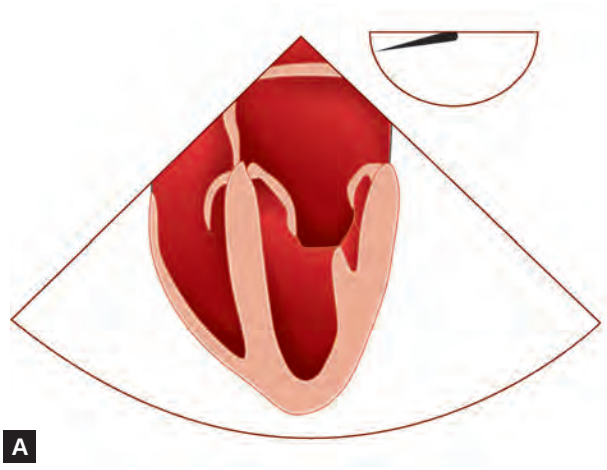

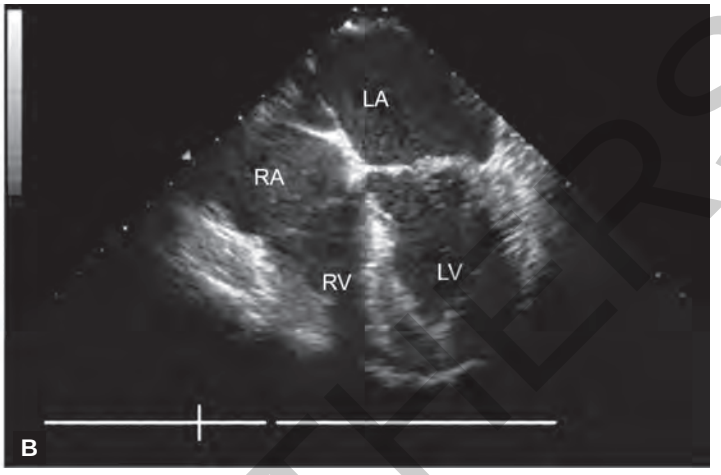

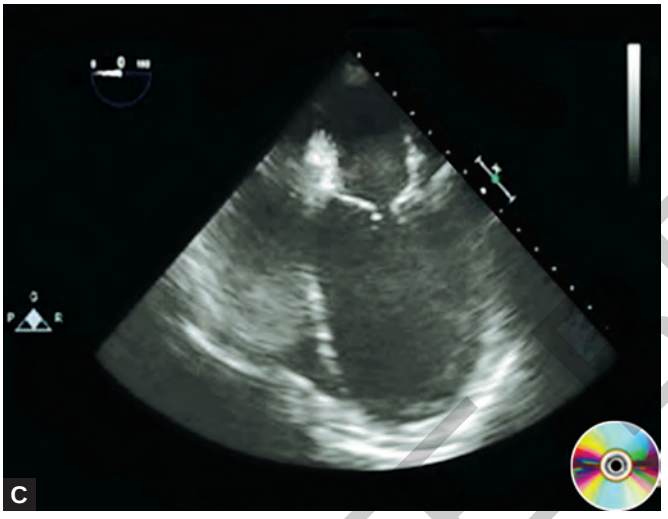

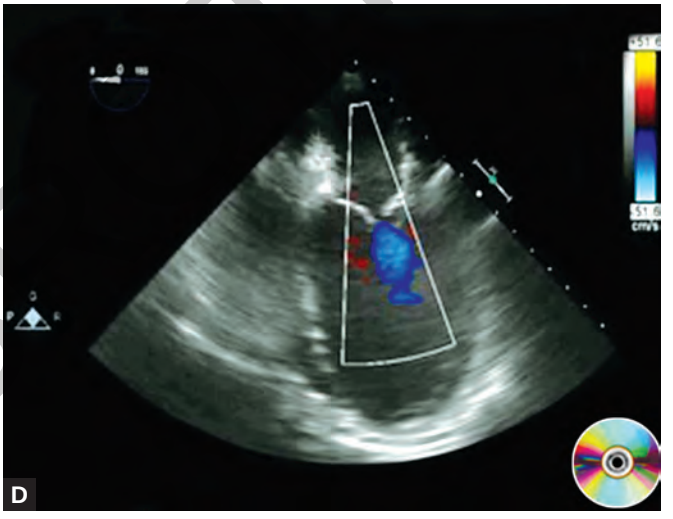

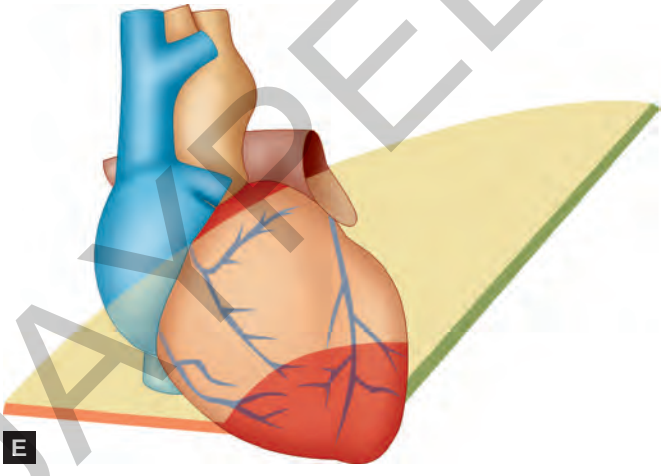

Figures 5A to E (VIDEOS 1 and 2)

ME four chamber view

JAYPEE BROTHERS

- Mitral and tricuspid valves
- Interatrial and interventricle septa
- *Left pulmonary veins:* Slight probe withdrawal and turning to left
- *Right pulmonary veins:* Slight probe withdrawal and turning to right
- *Coronary sinus:* Slight probe advancement and turn to right.

Clinical Utility

- *Ventricle function:* Global and regional
- *Intracardiac chamber masses:* Thrombus, tumor, air; foreign bodies
- *Mitral and tricuspid valve evaluation:* Pathology, pathophysiology
- Congenital or acquired interatrial and ventral septal defects
- Hypertrophic obstructive cardiomyopathy evaluation
- Ventricular diastolic evaluation via transmitral and pulmonary vein Doppler flow profile analysis
- *Pericardial evaluation:* Pericarditis; pericardial effusion
- *Coronary sinus evaluation:* Coronary sinus catheter placement; dilation secondary to persistent left superior vena cava

MID-ESOPHAGEAL MITRAL COMMISSURAL VIEW (FIGS 6A TO D)

Multiplane Angle Range

- 60 to 70°
- *Sector depth*: ~ 12 cm

Anatomy Imaged

- Left ventricle and atrium
- Mitral valve

Clinical Utility

- *Left ventricle function:* Global and regional
- *Left ventricle and atrial masses:* Thrombus, tumor, air; foreign bodies
- *Mitral valve evaluation:* Pathology, pathophysiology
- Ventricular diastolic evaluation via transmitral Doppler flow profile analysis.

JAYPEE BROTHERS

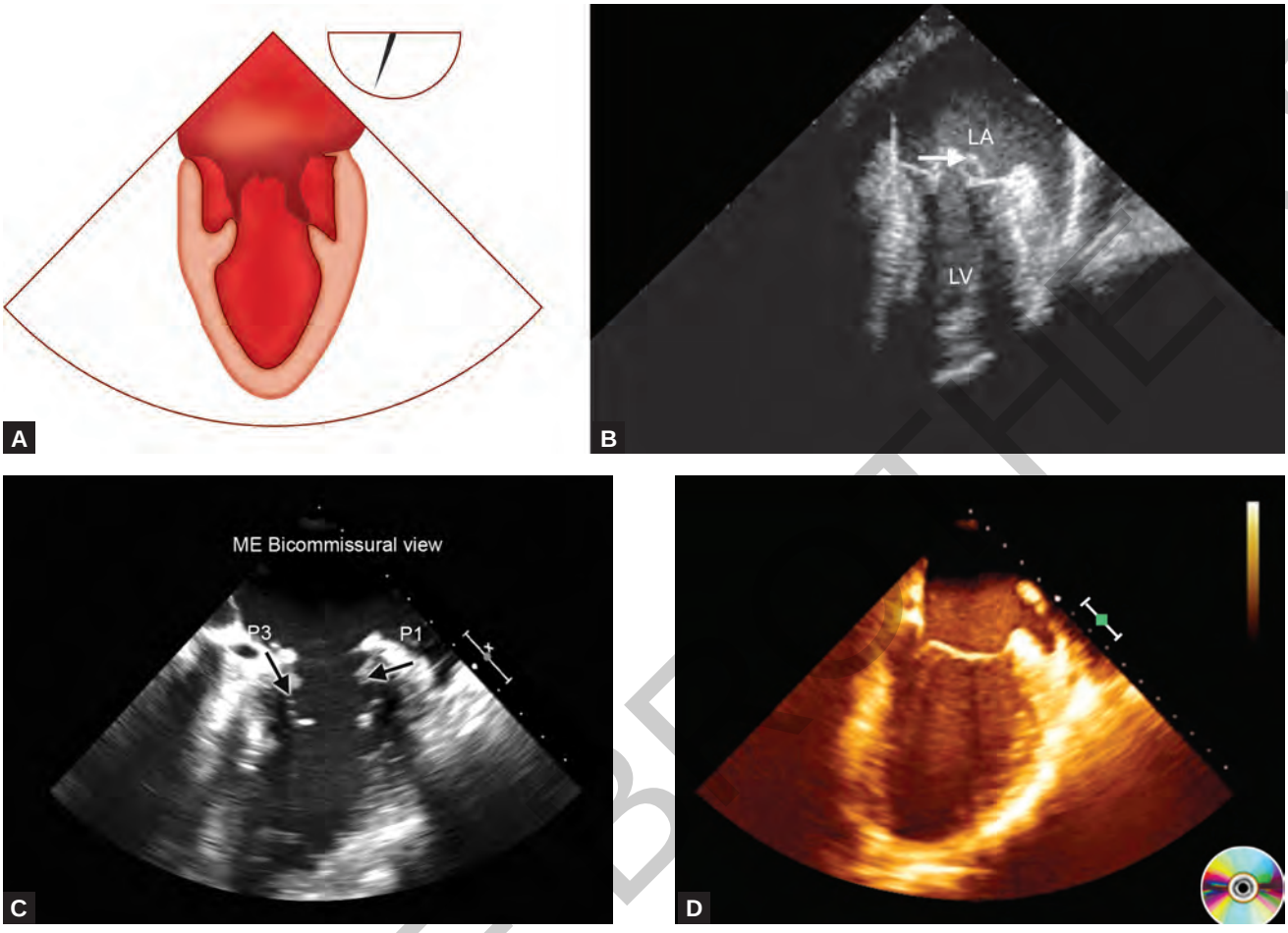

Figures 6A to D (VIDEO 3)

ME bicommissural view

MID-ESOPHAGEAL ASCENDING AORTA: SHORT AXIS VIEW (FIGS 7A TO C)

Multiplane Angle Range

- 0 to 60°
- *Sector depth:* ~ 12 cm.

Anatomy Imaged

- Ascending aorta
- Superior vena cava (short axis)

JAYPEE BROTHERS

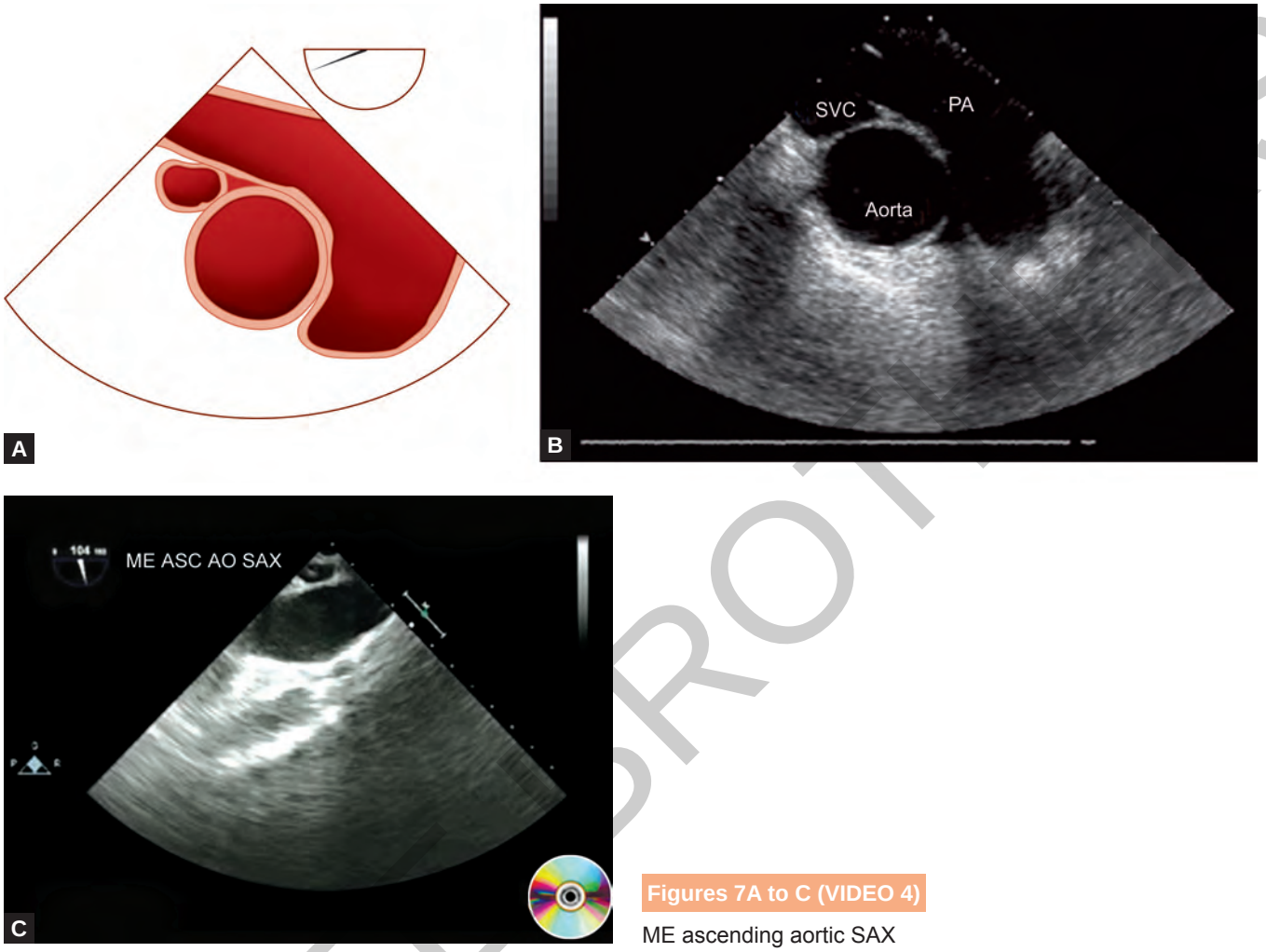

Figures 7A to C (VIDEO 4)
ME ascending aortic SAX

- Main pulmonary artery
- Right pulmonary artery
- Left pulmonary artery (turn probe tip to left)
- Pulmonic valve.

Clinical Utility

- *Ascending aorta pathology:* Atherosclerosis, aneurysms, and dissections
- *Pulmonic valve:* Pathology; pathophysiology
- Pulmonary embolus/thrombus evaluation
- *Superior vena cava pathology:* Thrombus, sinus venosus atrial septal defect
- Pulmonary artery catheter placement.

JAYPEE BROTHERS

MID-ESOPHAGEAL ASCENDING AORTA: LONG AXIS VIEW (FIGS 8A TO C)

Multiplane Angle Range

- 100 to 150°
- *Sector depth*: ~ 12 cm

Anatomy Imaged

- Ascending aorta
- Right pulmonary artery

Clinical Utility

- *Ascending aorta pathology:* Atherosclerosis, aneurysms, and dissections
- Anterograde cardioplegia delivery evaluation

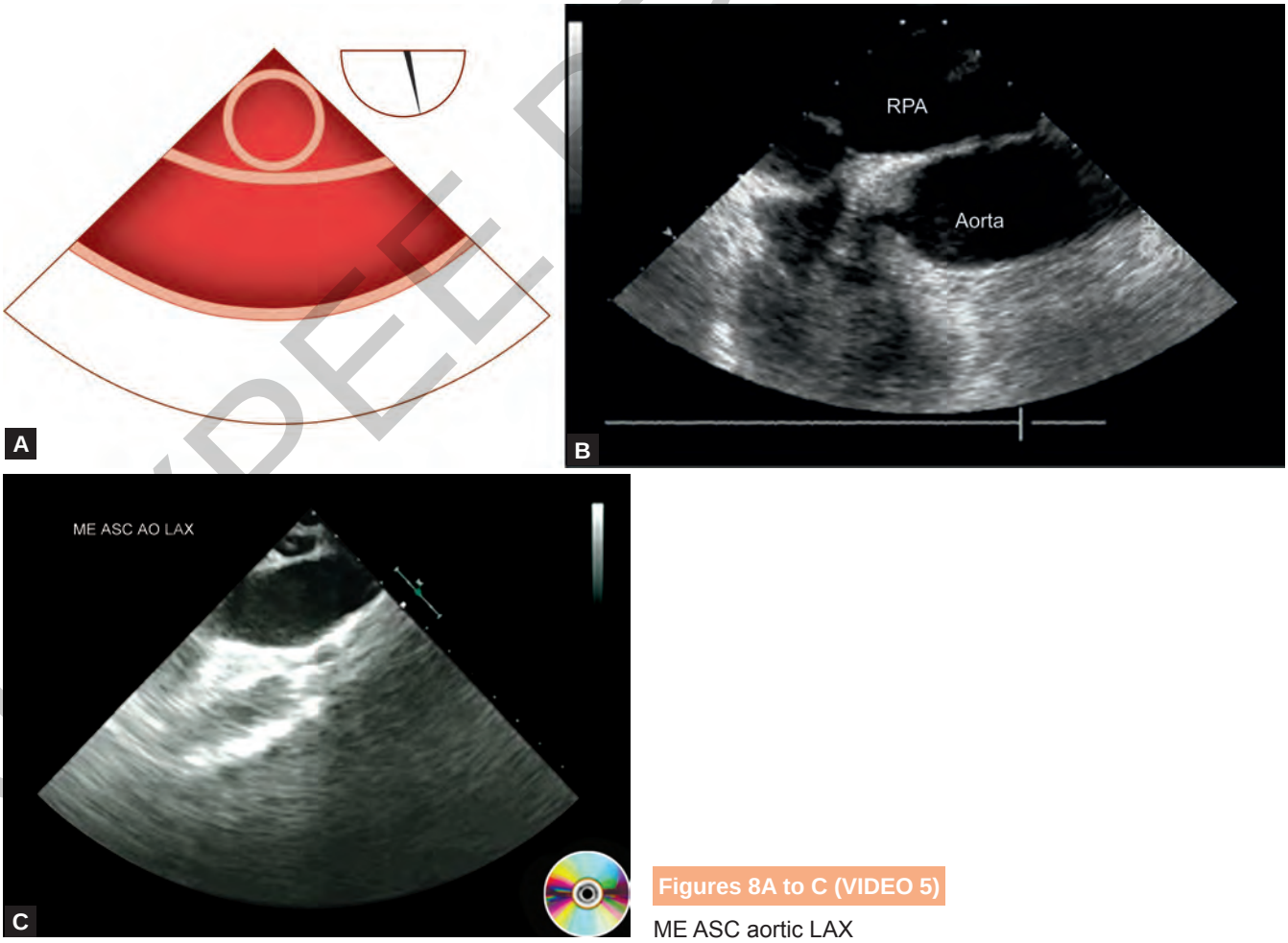

Figures 8A to C (VIDEO 5)
ME ASC aortic LAX

JAYPEE BROTHERS

- Pulmonary embolus/thrombus
- Probe tip depth (from lips) upper esophageal (20–25 cm)

MID-ESOPHAGEAL RIGHT PULMONARY VEIN VIEW (FIGS 9A AND B)

Transducer Angle

- 0 to 30°
- Upper esophageal

Anatomy Imaged

- Mid-ascending aorta
- Superior vena cava
- Right pulmonary veins

In addition to the right pulmonary veins:

- The superior vena cava (SAX view) and ascending aorta (SAX view) are also imaged.
- The right pulmonary veins can also be imaged from the 90 to 110 view by first obtaining a ME bicaval view and turning the probe to the right (clockwise).
- This orthogonal image is the ME right pulmonary vein view.
- Note that the left pulmonary veins may be imaged by turning the probe to the left (counterclockwise) just beyond the left atrial appendage.

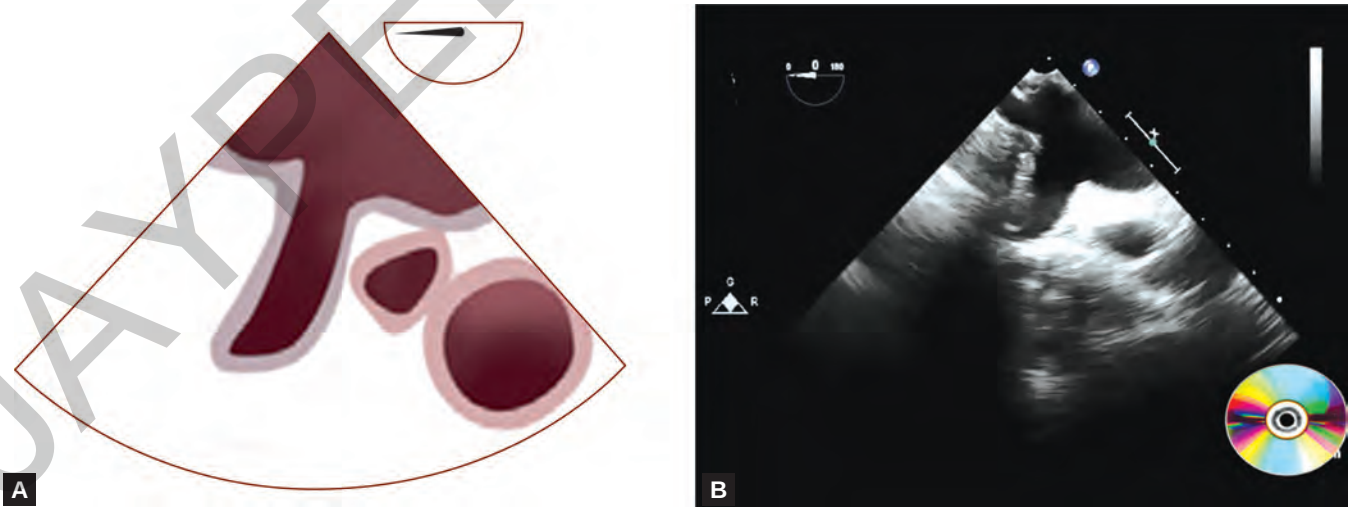

Figures 9A and B (VIDEO 6)

ME right pulmonary vein view

JAYPEE BROTHERS

or detailed information of cardiology books, visit our website www.jaypeebrothers.com, for detailed information of cardiology books, visit our website www.jaypeebrothe

Transesophageal Echocardiography of the Tricuspid & Pulmonary Valves

Salient Features

- A comprehensive and an easy-to-read book on *Transesophageal Echocardiography of the Tricuspid and Pulmonary Valves* for the first time as a separate subject for a textbook
- Includes detailed TEE images and videos on recent upcoming topics like Anatomy of Tricuspid and Pulmonary Valves, TEE Views, Doppler Examinations, Tricuspid Regurgitation, Tricuspid Stenosis, Pulmonary Stenosis, Ebstein's Anomaly, and Pulmonary Artery Hypertension
- TEE images and videos on a DVD on the subject from all perspectives of understanding, teaching and taking examinations
- Contains a section on MCQs which will help master the subject
- Helpful for examiners and examinees especially the cardiac topics in all medical branches
- A useful guide for intensivists, cardiac anesthetists, cardiologists, pediatricians and surgeons—as it deals with an easy and basic approach to TEE for the right ventricle "the neglected heart".



Poonam Malhotra Kapoor MD DNB MNAMS FIACTA FTEE FISCU is currently working as a Professor, Department of Cardiac Anesthesia, Cardiothoracic and Neurosciences Center, All India Institute of Medical Sciences (AIIMS), New Delhi, India. She is the co-editor of Annals of Cardiac Anesthesia; and Coordinator and Office-in-Charge, Indian Association of Cardiovascular Thoracic Anesthesiologists (IACTA) Education and Research Cell, which conducts Fellowship examinations in transesophageal echocardiogram (TEE) and cardiac examination. She is also the Examiner of DM, IGNOU, DNB Cardiac Anesthesia and Delhi University. She is the Founder Secretary, Society of Cardiac Anesthesia, New Delhi and National Capital Region (NCR), India. She is author of the bestseller books on *Manual of ECMO* and *2100 MCQs in Cardiac Anesthesia—Anesthesia Review*.

JAYPEE BROTHERS

Shelving Recommendation
CARDIOLOGY

ISBN 978-93-5152-129-7

Available at all medical book stores
or buy directly from Jaypee Brothers through online shopping
at www.jaypeebrothers.com

JAYPEE BROTHERS
Medical Publishers (P) Ltd.
www.jaypeebrothers.com