website www.jaypeebrothers.com, for detailed information on orthopedics books, visit our website www.jaypeebrothers.com

Interventional Spine Procedures

A Case-Based Approach



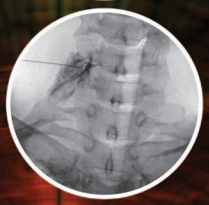

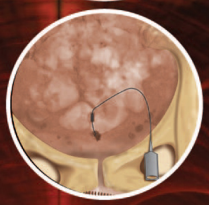

Editors

Jeremy Simon

Mitchell Freedman

Michael J Mehnert

Alexander R Vaccaro

JAYPEE

Contents

Introduction *xxiii*

1. Basic Principles of Fluoroscopically-guided Procedures **1**

Jeremy Simon

- Sterile Preparation 1
- Needle-Driving 2
- Fluoroscopy 2
- Contrast 4
- Anticoagulants 4

2. Lumbar Disc Herniation with Radiculopathy: Selective Spinal Nerve Injection **8**

Lisa Marino, Jeremy Simon

- Chief Complaint 8
- History of Presenting Illness 8
- Past Medical/Surgical History 9
- Review of Systems 9
- Family History 9
- Social History 9
- Current Medications 9
- Allergies 9
- Physical Examination 9
- Imaging Studies 10
- Electrodiagnostic Studies 10
- Diagnosis 10
- Treatment 10

3. Lumbar Disc Herniation with Radiculopathy: Lumbar Transforaminal Epidural Steroid Injection **17**

Natacha Falcon, Jeremy Simon

- Chief Complaint 17
- History of Present Illness 17
- Review of Systems 17

- Past Medical History 18
- Surgical History 18
- Medications 18
- Allergies 18
- Family History 18
- Social History 18
- Physical Examination 18
- Imaging 19
- Diagnosis 19
- Noninterventional Treatment Options 20
- Interventional Options 20
- Patient Discussion 21
- Plan 21

4. Lumbar Spinal Stenosis with Radiculopathy 25

Michael Molter, Jeremy Simon

- Chief Complaint 25
- History of Present Illness 25
- Past Medical History 26
- Past Surgical History 26
- Review of Systems 26
- Family History 26
- Social History 27
- Medications 27
- Allergies 27
- Physical Examination 27
- Diagnosis 28
- Treatment Options 29
- Complications/Pitfalls 32

5. Coccygodynia 37

Michael J Mehnert, Ferheen Shamim, Patrick M Foye

- Chief Complaint 37
- History of Present Illness 37
- Past Medical/Surgical History 38
- Review of Systems 38
- Family History 38
- Social History 38
- Current Medications 38

- Allergies 38
- Physical Examination 38
- Imaging 39
- Diagnosis 39
- Differential Diagnosis 40
- Coccygodynia 40
- Treatment Options 41
- Interventional Options 41
- Plan 42
- Procedure 42
- Concerns, Pitfalls and Tips 44

6. Lumbar Facet Syndrome 50

Jeremy Simon, Kelly Williams

- Chief Complaint 50
- History of Present Illness 50
- Past Medical History 51
- Past Surgical History 51
- Review of Systems 51
- Family History 51
- Social History 51
- Current Medications 51
- Allergies 51
- Physical Examination 51
- Imaging 52
- Diagnosis 53
- Treatment Options 53
- Interventional Options 54
- Sample Procedure Notes 57

7. Sacroiliac Joint Pain 61

Ari Greis, Melissa Guanche

- Chief Complaint 61
- History of Present Illness 61
- Past Medical History 61
- Past Surgical History 62
- Review of Systems 62
- Family History 62
- Social History 62

- Current Medications 62
- Allergies 62
- Physical Examination 62
- Imaging 63
- Diagnosis 64
- Treatment Options 66
- Interventional Options 66

8. Cervical Disc Herniation with Radiculopathy 71

Theodore Conliffe, Jeremy Simon, Zachary Broyer

- Chief Complaint 71
- History of Present Illness 71
- Past Medical History 72
- Past Surgical History 72
- Family History 72
- Medications 72
- Allergies 73
- Social History 73
- Review of Systems 73
- Physical Examination 73
- Imaging Studies 74
- Diagnosis 74
- Treatment Options 74
- Indications 75
- Discussion 76
- Clinical Outcome 77

9. Cervical Disc Herniation without Radiculopathy 79

Gautam Kothari, Jeremy Simon

- Chief Complaint 79
- History of Present Illness 79
- Past Medical/Surgical History 80
- Family History 80
- Social History 80
- Medications 81
- Allergies 81
- Review of Systems 81
- Physical Examination 81
- Imaging 82
- Diagnosis 84

- Treatment Options 84
- Interventional Options 84

10. Cervical Facet Syndrome 88

Matthew McAuliffe, Jeremy Simon

- Chief Complaint 88
- History of Present Illness 88
- Past Medical History/Past Surgical History 89
- Review of Systems 89
- Family History 90
- Social History 90
- Current Medications 90
- Allergies 90
- Physical Examination 90
- Imaging 91
- Diagnosis 91

11. Hip Pain 100

Anupam Sinha, Madhuri Dholakia

- Chief Complaint 100
- History of Present Illness 100
- Past Medical History/Past Surgical History 100
- Review of Systems 100
- Family History 101
- Social History 101
- Current Medications 101
- Allergies 101
- Physical Examination 101
- Imaging 102
- Diagnosis 102

12. Complex Regional Pain Syndrome—Lower Extremity 105

Jeremy Simon, Matthew McAuliffe

- Chief Complaint 105
- History of Present Illness 106
- Treatments to Date 106
- Past Medical History 106
- Past Surgical History 106
- Review of Systems 106

- Family History 107
- Social History 107
- Current Medications 107
- Allergies 107
- Physical Examination 107
- Imaging 108
- Diagnosis 108
- Treatment Options 110
- Plan 112
- Sample Dictation 112

13. Complex Regional Pain Syndrome—Upper Limb 115

Michael J Mehnert, Jeremy Simon, Matthew McAuliffe

- Chief Complaint 115
- History of Present Illness 115
- Treatments to Date 116
- Past Medical History 117
- Past Surgical History 117
- Review of Systems 117
- Family History 117
- Social History 117
- Current Medications 117
- Allergies 117
- Physical Examination 117
- Imaging 118
- Diagnosis 118
- Treatment Options 119
- Plan 121
- Procedure Note 121
- Indications 121
- Preoperative Diagnosis 121
- Postoperative Diagnosis 121
- Procedure Performed 121

14. Dural Puncture Headache 125

Jeremy Simon

- Chief Complaint 125
- History of Present Illness 125

- Past Medical History 125
- Past Surgical History 126
- Review of Systems 126
- Family History 126
- Social History 126
- Current Medications 126
- Allergies 126
- Physical Examination 126
- Imaging 127
- Diagnosis 127
- Discussion 127
- Treatment 127

15. Adverse Reactions to Medications 132

Jeremy Simon

- Chief Complaint 132
- History of Present Illness 132
- Past Medical History 132
- Past Surgical History 132
- Review of Systems 133
- Family History 133
- Social History 133
- Current Medications 133
- Allergies 133
- Physical Examination 133
- Imaging 134
- Diagnosis 134
- Additional Diagnosis 135
- Discussion 136

16. Discogenic Low Back Pain/Lumbar Disc Herniation without Radiculopathy 139

Jeremy Simon, Zachary Broyer, Theodore Conliffe

- Chief Complaint 139
- History of Present Illness 139
- Past Medical History 140
- Past Surgical History 140
- Review of Systems 140
- Family History 140

- Social History 140
- Current Medications 141
- Allergies 141
- Physical Examination 141
- Imaging 141
- Diagnosis 142
- Discussion 144
- Treatment Options 147

17. Thoracic Facet Pain 152

Michael J Mehnert, Jesse A Sally, Gary P Chimes

- Chief Complaint 152
- History of Present Illness 152
- Past Medical History 153
- Past Surgical History 153
- Review of Systems 153
- Family History 153
- Social History 154
- Current Medications 154
- Allergies 154
- Physical Examination 154
- Imaging 155
- Diagnosis 155
- Differential Diagnosis 155
- Treatment Options 156

18. Thoracic Disc Herniation 172

Arjang Abbasi, Shounuck I Patel, Gautam Malhotra

- Chief Complaint 172
- History of Present Illness 173
- Past Medical History 174
- Allergies 174
- Family History 174
- Social History 175
- Medication History 175
- Review of Systems 175
- Physical Examination 176
- Assessment with Differential Diagnosis 177
- Background 178

- Indications for Injection 179
- Treatment Alternatives 179
- Contraindications 179
- Thoracic Transforaminal Epidural Steroid Injection 179
- Equipment and Medications 180
- Technique: Oblique Subpedicular Transforaminal Approach 180
- Other Techniques 183
- Complications 184
- Evidence to Support the Procedure 186

Index *189*

Lumbar Disc Herniation with Radiculopathy: Selective Spinal Nerve Injection

2

Lisa Marino, Jeremy Simon

JAYPEE BROTHERS

CHIEF COMPLAINT

The patient complains about lower back pain and left thigh pain.

HISTORY OF PRESENTING ILLNESS

A 47-year-old right-handed male presents for consultation with complaints of left-sided low back and buttock pain that radiates into the posterolateral thigh with associated numbness into all five toes of the left foot on plantar and dorsal aspects. He describes his pain as a constant burning type rated at a 9/10 on the numeric pain scale. The pain began 4 months ago after playing 18 holes of golf and became progressively worse. The symptoms are aggravated with standing, walking and lying down. He gets some relief with sitting and medications. He denies fevers, chills, and/or night sweats. There are no associated bowel or bladder symptoms, progressive weakness, saddle anesthesia or night-time pain.

Treatment has consisted of physical therapy for 6 weeks, two fluoroscopically-guided transforaminal epidural injections, hydrocodone and celecoxib. The physical therapy offered no relief of pain. *He underwent two L5 transforaminal epidural injections and received 2–10 days of subsequent pain relief, after which the symptoms returned to baseline.* The pain was interfering with the patient's sleep and ability to work as an elevator repairman. He had a lumbar microdiscectomy at L5-S1 10 years prior with complete resolution of his left lower extremity radicular symptoms until the aforementioned episode. He was referred to a spinal interventionalist by the spine surgeon for a series of diagnostic selective nerve root injections to determine if surgery would be indicated.

PAST MEDICAL/SURGICAL HISTORY

Lumbar microdiscectomy L5-S1 10 years prior

REVIEW OF SYSTEMS

Otherwise negative

FAMILY HISTORY

Mother alive and healthy, father deceased from head and neck cancer.

SOCIAL HISTORY

No alcohol, tobacco or illicit drug history. He is married, with two children. Employed fulltime in elevator repair and construction, no workmen's compensation claims.

CURRENT MEDICATIONS

Celecoxib 200 mg daily, Hydrocodone/apap 10/325 one to two tablets daily to bid prn pain.

ALLERGIES

None

PHYSICAL EXAMINATION

Height: 6'7", Weight: 275 lbs, Pulse: 84/min, Blood Pressure (BP): 132/88 mm Hg. The patient was pleasant, conversant, well developed, oriented and in no acute distress. Affect and mood were normal. Rapid alternating movement was unremarkable. The patient demonstrated no overt pain behavior and was fully cooperative with the examination. Inspection and palpation did not identify significant misalignment, atrophy or asymmetry in the head, neck, thoracolumbar spine and lower limbs. There was no evidence of dislocation or fracture in the neck, back, and either lower limb. The pelvis was level without evidence of significant scoliosis. The patient had an *antalgic gait favoring left lower extremity weight bearing*. Toe and heel walk were intact. *Lumbar flexion, extension, rotation and side bending range of motion were diminished in all planes by 50% secondary to pain*. Bilateral hip and knee range of motion was grossly functional and symmetric. Strength testing was 5/5 in the hip flexors, extensors, knee flexors, extensors, dorsiflexors, everters, inverters and extensor hallucis longus (EHL) as well

JAYPEE BROTHERS

as grossly in the neck, spine and pelvis. Sensation to light touch and distal pulses were within normal limits in the lower limbs. The trunk and lower limbs were without evidence of lymphadenopathy, edema or rash. Muscle stretch reflexes were 2+ and symmetric in the knees and ankles without upper motor neuron signs. *Straight leg raise test was negative, but reproduced left thigh pain*.

IMAGING STUDIES

Radiographs of the lumbar spine were reviewed. There were posterior-anterior, lateral, flexion and extension views. Five normal appearing lumbar vertebrae were present without evidence of fracture, spondylolysis or spondylolisthesis. *There was evidence of decreased disc height at the L3-4, L4-5 and L5-S1 levels and evidence of a left hemilaminotomy.*

Magnetic resonance imaging (MRI) of the lumbar spine showed moderate degenerative changes at the L3-4 and L4-5. L5-S1 disc was significantly degenerated. A disc bulge was present at all three lower lumbar levels with lateral recess stenosis at L3-4 and L4-5. L5-S1 had severe bilateral foraminal stenosis with evidence of a hemilaminotomy.

ELECTRODIAGNOSTIC STUDIES

Electromyography (EMG)/Nerve conduction studies (NCS) of the bilateral lower extremities were normal.

DIAGNOSIS

Lumbar radiculopathy

TREATMENT

The patient presented to the clinic with several conservative treatments producing unsuccessful outcomes including medication management, physical therapy and therapeutic spinal interventions. Certainly, in the absence of neurological dysfunction, conservative measures should be tried before surgical intervention. Nonetheless, the patient was significantly limited by pain and was interested in pursuing definitive treatment. Subsequent to surgical consultation, it was determined that if further testing confirmed an L5 radiculopathy surgery would be indicated.

The patient presented with severe left-sided buttock and thigh pain associated with foot numbness. There were several diagnoses that could be the cause of his symptoms including lumbar radiculopathy, sacroiliac joint dysfunction, hamstring tendonitis, lumbar internal disc disruption

JAYPEE BROTHERS

syndrome with somatic referral and piriformis syndrome, among others. Although symptoms associated with standing and walking are expected with radiculopathy from spinal stenosis, the patient's pain radiated only into a portion of the L5 dermatome, not the classic area below the knee, making the diagnosis of L5 radiculopathy indeterminate.

The physical examination offered little evidence of lumbar radiculopathy. The patient had no dural root tension signs, myotomal weakness or dermatomal patterns of sensory disturbance that is often seen with lumbar radiculopathy.

The normal NCS/EMG was not supportive for ruling in the presence of acute radiculopathy. Electrodiagnostic evidence of radiculopathy can often be absent, with test sensitivity ranging from 49% to 92%.[1] Therefore, the patient's normal study did not exclude a lumbar radiculopathy as a source of his pain. Even if the NCS/EMG showed evidence of a chronic lumbar radiculopathy, it would not be useful given his previous history of lumbar surgery for left-sided lumbar radiculopathy.

The imaging studies showed three lower lumbar discs with abnormalities and varying degrees of lateral recess and foraminal stenosis; any of which could contribute to the patient's symptoms.

The short-term pain relief from the L5 transforaminal injection did not definitively indicate that the L5 nerve root was the pain generator. The L5 transforaminal injection was performed with both steroid and lidocaine and subsequent pain relief could have been a systemic steroid response.

Lumbar internal disc disruption syndrome was a consideration as a source of the patient's pain; therefore lumbar discography could have been an alternate diagnostic procedure. However, the use of discography for accurately pinpointing a pain generator is a controversial topic. In a study by Berg et al. discography was shown to influence surgical decision making in up to 72% of cases, thus supporting its use.[2] Opposing arguments report a best-case positive predicted value for provocative discography to be 50–60%, meaning that a positive discogram does not necessarily correlate with effective pain relief after fusion of the proposed painful disc.[3] Additionally, modern discography methods have been shown to accelerate the degenerative changes of the disc on imaging studies.[4]

In this case, lumbar radiculopathy was the leading differential diagnosis for the patient, however further diagnostic information was desired by the surgeon. Lumbar disc herniation with radiculopathy. Selective nerve root injections in conjunction with a pain diary would help to clarify the presence of an L5 radiculopathy since the other studies and physical examination was equivocal.

Diagnostic selective nerve injections have been used since the 1970s to determine sources of pain and have been shown to provide a sensitivity of 90–95%.[5,6] False positives can occur but can be minimized with appropriate injection technique.[6,7] A diagnostic selective nerve root injection was

JAYPEE BROTHERS

recommended in this case because less invasive testing was unable to accurately pinpoint the pain generator of the abnormal radicular pattern. The surgeon requested an L3, L4 and L5 diagnostic selective nerve root injection for confirmation of the suspected diagnosis of L5 radiculopathy. A positive diagnostic injection would change treatment, since the patient would be a surgical candidate if pain was relieved with the test injection.

Given the patient's pain distribution into the posterior thigh, an S1 selective nerve block could also be considered. In this case, the selective nerve root injections were requested to determine if surgical intervention would be of benefit. The L3, L4 and L5 nerve roots had the most compressive pathology on MRI making them a potential for decompressive surgical intervention and therefore were the only nerves selected for targeted diagnostic injections.

Diagnostic injections should be performed one nerve level per visit. The patient should complete a pre- and post-injection standard pain drawing and a numeric pain rating scale. The injection should be performed with fluoroscopic guidance and contrast dye confirmation of nerve outline. The spinal nerve and the dorsal root ganglion are the desired target.

In this case, informed consent was obtained and risks of the procedure were reviewed with the patient which include, but were not limited to infection, allergic reaction, nerve damage, paralysis, epidural hematoma, syncope, headache, respiratory or cardiac arrest, worsening pain and scar formation.

Vital signs were monitored prior to, during, and after the procedure.

The patient was placed in the prone position on the fluoroscopy table. The C-arm was rotated to a slightly oblique and ipsilateral position. The lumbar area was prepped and draped in the usual sterile fashion. Next, the L5 neuroforamen was identified under fluoroscopic guidance. A small skin wheel was raised over the insertion site with local anesthetic. Using a sterile technique, a 22-gauge, 3.5-inch spinal needle was inserted into the skin. Under intermittent fluoroscopic guidance, the needle was advanced towards the foramen in the oblique position aiming for the uppermost aspect of the superior articular process and just inferior to the pedicle. Once the needle entered the muscle adjacent to the spine, the C-arm was rotated to the anterior-posterior view. The needle was then advanced into "the safe triangle",[8] inferior to the 6 o'clock position of the pedicle and superolateral to the exiting spinal nerve. The borders of "the safe triangle" are the horizontal base of the pedicle, the traversing nerve as the hypotenuse, and the posterolateral border of the vertebral body. The needle position was checked in the anterior-posterior and lateral positions.

Extension tubing was then attached to the spinal needle and under live fluoroscopy 1–2 milliliters of contrast dye was injected to verify spinal nerve and dorsal root ganglion outline. The injection of contrast medium should be slow, about 1 mL per 20 seconds; this was done to determine the volume

JAYPEE BROTHERS

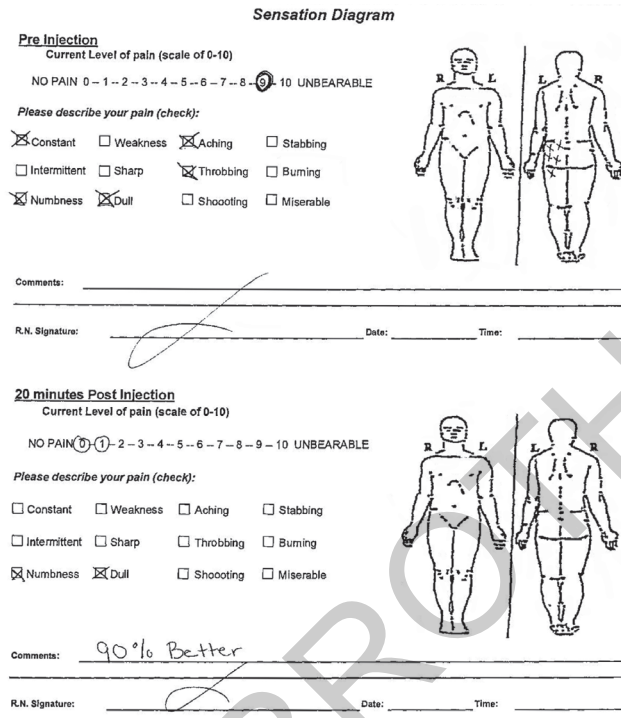

Fig. 2.1: Pain diagram pre-selective spinal nerve and post-selective spinal nerve injection performed for the left L5 spinal nerve. Note the patient reports 90% relief of his typical pain

needed to outline the targeted nerve. The volume needed of contrast dye to outline the nerve should be the same volume used for the local anesthetic. The contrast should flow along the surface of the nerve outlining the dorsal root ganglion and the nerve root sleeve. Medially the dye should curve up around the pedicle and laterally should outline the nerve. No vascular uptake, subarachnoid flow, or epidural spread to adjacent levels should be noted on live fluoroscopic views.

After aspiration was negative for return of blood or cerebrospinal fluid, 0.5 mL of 0.25% Bupivacaine was injected. The needle was then removed intact. The area was cleansed and a band-aid was applied to the injection site.

Twenty minutes after the injection, the patient completed the post-injection pain drawing and numeric pain scale.

The same procedure was repeated at the L4 and L3 nerve levels at one-week intervals. Each time the patient filled out a pre- and post-injection pain assessment.

The patient had 90% pain relief after the L5 selective nerve root injection (Fig. 2.1) and no pain relief after the L4 and L3 nerve injections (Fig. 2.2).

JAYPEE BROTHERS

Any pain relief over 80% would have been considered a positive diagnostic injection.[9] The patient was given a copy of the three pre- and post-injection pain diagrams for the surgeon. The diagnostic selective nerve injections were useful in diagnosing an atypical L5 radiculopathy (Fig. 2.3). The surgeon was confident in the responses of the diagnostic injections and went on to perform an anterior and posterior L5-S1 interbody fusion. Postoperatively, the patient had 90% relief of his symptoms and resumed his previous functional level.

It is important to note that while the diagnostic injections can more accurately pinpoint the pain generator when conventional methods fail, they cannot predict surgical outcomes. Additionally, false positives can occur if the procedure is not carried out correctly. Improper spread of the anesthetic to other nerve root levels or around the sinuvertebral nerve can anesthetize nontargeted potential pain generators.[10] A proper contrast dye flow pattern and small volume of anesthetic (less than half a milliliter) can reduce some of these concerns.[11]

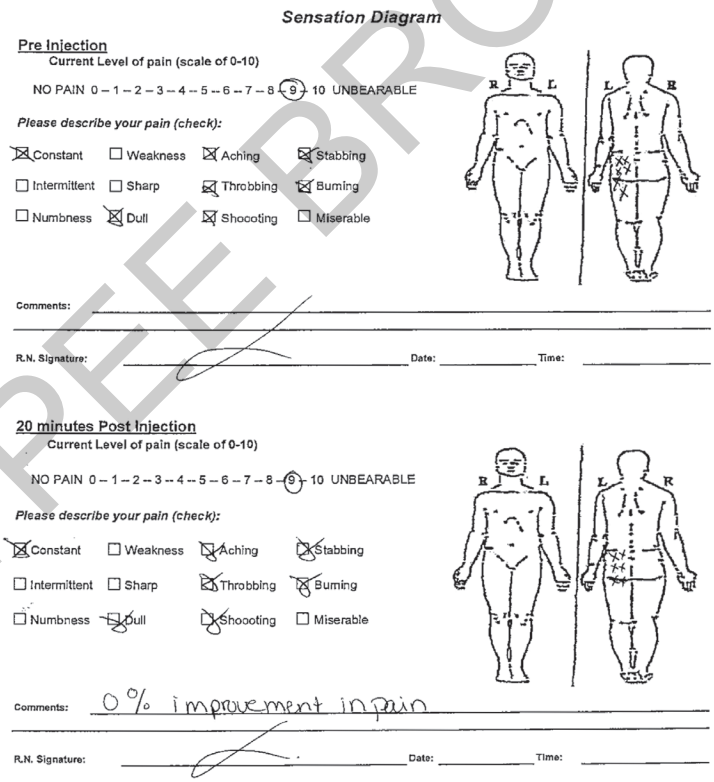

Fig. 2.2: Pain diagram pre-selective spinal nerve injection and post-selective spinal nerve injection performed for the left L3 and L4 spinal nerves. Note that the patient reports 0% relief of his typical pain

JAYPEE BROTHERS

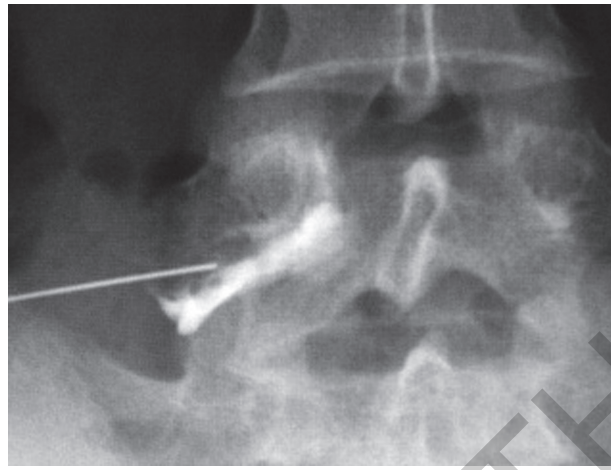

Fig. 2.3: Left L5 selective spinal nerve injection. Note the contrast along the spinal nerve, but not extending past the medial border of the L5 pedicle

SUMMARY

Selective nerve root injections can be a useful tool for diagnosing an atypical presentation of radicular pain. The indication for such a procedure includes an atypical radicular pattern with equivocal findings on physical examination and diagnostic studies. This intervention should be considered only when the resulting diagnostic information would impact the treatment intervention.

REFERENCES

1. Dillingham TR. Electrodiagnostic approach to patients with suspected radiculopathy. Physical Medicine and Rehabilitation Clinics of North America. 2002;13:567-88.
2. Berg S, Isberg B, Josephson A, et al. The impact of discography on the surgical decision in patients with chronic low back pain. The Spine Journal: Official Journal of the North American Spine Society. 2012;12:283-91.
3. Carragee EJ, Lincoln T, Parmar VS, et al. A gold standard evaluation of the "discogenic pain" diagnosis as determined by provocative discography. Spine. 2006;31:2115-23.
4. Carragee EJ, Don AS, Hurwitz EL, et al. 2009 ISSLS Prize Winner: Does discography cause accelerated progression of degeneration changes in the lumbar disc: a ten-year matched cohort study. Spine. 2009;34:2338-45.
5. Krempen JF, Smith BS. Nerve-root injection: a method for evaluating the etiology of sciatica. The Journal of Bone and Joint Surgery American volume. 1974;56:1435-44.
6. Huston CW, Slipman CW. Diagnostic selective nerve root blocks: indications and usefulness. Physical Medicine and Rehabilitation Clinics of North America. 2002;13:545-65.

JAYPEE BROTHERS

7. Slipman CW, Issac Z. The role of diagnostic selective nerve root blocks in the management of spinal pain. Pain Physician. 2001;4:214-26.
8. Bogduk N, Aprill CN, Derby R. Epidural spinal injections. St. Louis: Mosby; 1995.
9. Derby R, Kine G, Saal JA, et al. Response to steroid and duration of radicular pain as predictors of surgical outcome. Spine. 1992;17:S176-83.
10. Bogduk N, Tynan W, Wilson AS. The nerve supply to the human lumbar intervertebral discs. Journal of Anatomy. 1981;132:39-56.
11. Furman MB, Lee TS, Mehta A, et al. Contrast flow selectivity during transforaminal lumbosacral epidural steroid injections. Pain Physician. 2008; 11:855-61.

JAYPEE BROTHERS

r detailed information on orthopedics books, visit our website **www.jaypeebrothers.com**, for detailed information on orthoped

Interventional SPINE Procedures
A Case-Based Approach

This is a case-based approach to understanding, diagnosing and treating commonly encountered spine conditions in clinical practice. The book is also useful as an educational tool for allied health professionals, medical students, residents and fellows interested in painful spinal conditions. It may be used for teaching in the outpatient clinic and a Socratic approach with an attending and student is encouraged.

Each case is presented with a pain diagram, a history and physical examination. Appropriate testing is also ordered and treatment options discussed. As the text is an interventional approach, a procedure indicated for the patient's presentation is then ordered and performed. A discussion of the technique and rationale is also discussed. This is also meant to create a conversation and possibly disagreement as a practitioner's treatment paradigms may differ.



Jeremy Simon MD is a clinical instructor at the Rothman Institute in Media, Pennsylvania and Thomas Jefferson University Hospital. He is board certified in Physical Medicine and Rehabilitation and Pain Medicine. He is a reviewer for 3 peer-reviewed journals, has won resident teaching awards and is on the residency committee for the Rehabilitation Medicine Program at Thomas Jefferson University. He has published several articles, chapters, and given many lectures on interventional pain topics.



Mitchell Freedman DO is a graduate of LaSalle College and the Philadelphia College of Osteopathic Medicine. He participated in an internship at Delaware Valley Medical Center and was a resident in Physical Medicine and Rehabilitation at Thomas Jefferson University Hospital. He has board certifications in Physical Medicine and Rehabilitation via AAPM & R and AOCPMR and is also board certified in Pain Management and Electromyography. He is currently the Medical Director of Physical Medicine and Rehabilitation at the "Rothman Institute" and he is an Associate Professor in Physical Medicine and Rehabilitation at Thomas Jefferson University Hospital. He functions as the Chief Editor for Knowledge NOW in the American Academy of Physical Medicine and Rehabilitation in the areas of Pain and Neuromuscular medicine. He is a member of the Internal Review board at Thomas Jefferson University. In addition, he has authored multiple chapters and articles and received awards from the AAPM & R, Thomas Jefferson University and the residents in Physical Medicine and Rehabilitation at Thomas Jefferson University.



Michael J Mehnert MD is a board-certified physical medicine and rehabilitation specialist and has a subspecialty certification in Sports Medicine. He is a Clinical Instructor of Rehabilitation Medicine at Thomas Jefferson Medical College, Department of Physical Medicine and Rehabilitation. He is a published physician with works addressing spine injuries and epidural steroid injections. He has trained at the Kessler Institute for Rehabilitation in New Jersey, USA and has also completed fellowship training in spinal injection procedures and sports/occupational medicine.



Alexander R Vaccaro MD PhD is a Vice Chairman and Professor of Orthopedics and Neurosurgery at Thomas Jefferson University in Philadelphia, Pennsylvania, USA. He is past President of the American Spinal Cord Injury Association and was the recipient of the Leon Wiltse award given for excellence in leadership and clinical research for spine care by the North American Spine Society (NASS). He has over 540 peer-reviewed and 195 non-peer-reviewed publications. He has published over 300 book chapters and is the editor of over 44 textbooks and co-editor of OKU-Spine I and editor of OKU-8.

Shelving Recommendations

PHYSICAL MEDICINE AND REHABILITATION

PAIN MANAGEMENT

ORTHOPEDICS

ISBN 978-93-5152-169-3

9 789351 521693

Available at all medical book stores or buy directly from Jaypee Brothers through online shopping at www.jaypeebrothers.com

JAYPEE BROTHERS
Medical Publishers (P) Ltd.
www.jaypeebrothers.com

Join us on facebook.com/jaypeebrothers