website www.jaypeebrothers.com, for detailed information on radiology books, visit our website www.jaypeebrothers.com





Interpretation of CHEST X-RAY

An Illustrated Companion





G Balachandran

Contents

1. Introduction **1**
General Introduction 1
Basic Radiography 2
Basic Principles of Chest X-ray Interpretation 9

2. Normal Chest X-Ray **12**
Normal Structures Seen in Chest X-ray—A Brief Description 12
Introduction 12
The Lungs and Fissures 12
Some Useful Signs in Chest X-ray Interpretation 22

3. Lung Opacity and Lung Lucency **29**
Lung Opacity 29
Introduction 29
Unilateral Lung Opacity 30
Lobar Collapse Series 37
Collapse/Atelectasis 37
Collapse of Individual Lobes 43
Hilum Based Opacity 57
Bilateral Lung Opacity 60
Lung Lucency 64
Lung Lucency—Unilateral Involving Whole Lung 64
Lung Lucency—Unilateral Involving Part of Lung 65
Bullous Emphysema 70
Bronchiectasis 70
Lung Lucency—Bilateral COPD 72

4. Diseases of the Heart **75**
Criteria for a Normal Heart in Chest X-ray 75
Method of Measuring CTR in Chest X-ray 76
How to Read X-ray Chest in Cardiology? 79
Cardiac Shape—A Guide to Congenital Heart Disease 84
Cardiac Situs—A Guide to CHD 87
Coarctation of Aorta 88
Patent Ductus Arteriosus (PDA) 89
Ventricular Septal Defect (VSD) 90
Atrial Septal Defect (ASD) 91
Primary Pulmonary Hypertension 92
Bicuspid Aortic Valve 93
Mitral Regurgitation 95
Rheumatic Mitral Stenosis 96
Left Atrial Enlargement 98

Pericardial Effusion 98
Calcific Pericarditis 99
Dilated Cardiomyopathy 100
Congestive Heart Failure—CHF/CCF 101
Pulmonary Edema 102
Aortic Aneurysm 103

5. Miscellaneous Lesions **105**
Rib Fracture 105
Cervical Rib 106
Complete Eventration of the Right Hemidiaphragm 106
Diaphragm Rupture 108
Diaphragmatic Hernia in a Child 110
Gas Under Diaphragm 111
Chilaiditi Syndrome 112

Index ***117***

CHAPTER

2

Normal Chest X-ray

Chapter Outline

- Introduction
- The Lungs and Fissures
- Some Useful Signs in Chest X-ray Interpretation

NORMAL STRUCTURES SEEN IN CHEST X-RAY—A BRIEF DESCRIPTION

❑ INTRODUCTION

In the following pages an overview of all thoracic structures is given, emphasizing only the radiological anatomy. Each important structure is shown by chest X-rays and corresponding line diagrams. Later key points for chest X-ray interpretation is given.

There are two tables, one (Table 2.1) showing the normal structures seen in chest X-ray and the normal variants in other (Table 2.2) shows common abnormalities that are seen in common lung pathologies.

❑ THE LUNGS AND FISSURES

Since most of the lung consists of air, which is essentially transparent to X-rays (radiolucent) the only structures which are visible in normal lungs are the blood vessels, the interlobar fissures and the walls of some larger bronchi seen end on. Thus, the lungs are radiolucent, in both sides with traces of gray linear marking which are blood vessels (Fig. 2.1).

The right lung is divided into three lobes by means of two fissures: oblique and horizontal.

The oblique fissure runs from a position anterior on the diaphragm in a posterior direction superiorly towards the apex of the lung around thoracic vertebra T4 posterior, splitting the lung into an anterior, superior section (the upper and middle lobes) and a posterior, inferior section (the lower lobe). It is better seen in lateral projection.

The horizontal fissure runs from the anterior wall of the lung to the hilum, horizontally, dividing the upper section of the right lung into an upper lobe and a middle lobe. On the PA

Table 2.1 Normal finding and normal variants (some examples)

Structure	*Normal finding*	*Normal variants*
Trachea	Central, midline, cervical spinous processes seen through the tracheal air column	Displaced to right by unfolded aorta
Heart	Normal CTR = 0.5 2/3 of heart lies to the left of midline 1/3 of heart lies to the right of midline	1. Assessment of heart size Difficult in AP view, obese persons 2. Geometric enlargement on AP 3. Apparent enlargement on expiration 4. Depressed sternum displaces heart
Hilum	Left 1cm above right, symmetrical, concave	Obscured partly by heart
Lung zones	Both sides show, symmetric Similar radiographic density	Rotation and absence of breast shadow will produce differences in density
Fissures	Horizontal fissure at 6th rib right side only Oblique fissure not seen	Accessory fissures, e.g. azygos in right side
Diaphragm	Smooth outline convex upwards Sharply defined costophrenic and cardiophrenic angles Right dome 2 cm above left, normally	Elevation of left dome is often due to stomach gas Frequent hump on right dome in the elderly Fat pad in obese people
Bone thoracic cage	Level of rib correspond to the depth of respiration, lower in inspiration and higher in expiration	Cervical rib and minor rib anomalies, like synostosis are common
Soft tissue	Breast in young and nipples in old age women seen sharply	Plaits, hair, artefacts

Table 2.2 Abnormal chest X-ray findings (some examples)

	Structure	*Normal finding*	*Abnormal finding—example only*
1.	Trachea	Central	Pulled by collapse, fibrosis other lung volume reducing pathologies Pushed by massive pleural pathologies like effusion, pneumothorax
2.	Heart	Normal CTR = 0.5 Overall T diameter >16 cm 2/3 of heart lies left of midline	Increased CTR, e.g. Endocardial pathology VHD Myocardial pathology DCM Pericardial pathology effusion
3.	Hilum	Left 1 cm above right	Pulled by fibrosis, collapse Enlarged by lymphadenopathy
4.	Lung fields	Similar radiographic density	Increased density by mass consolidation, collapse, decreased density by air trapping, bullae, etc
5.	Fissures	Horizontal fissure at 6th rib right	Pulled by fibrosis, collapse
6.	Diaphragm	Smooth outline convex upwards Sharply define costophrenic angles Shadow at the level of 6th rib Right dome 2 cm above left	Pulled by fibrosis, collapse Abnormally elevated by paralysis, hepatomegaly, etc. Flatted by emphysema
7.	Thoracic cage	Calcification in costal cartilage is insignificant	Volume increases in COPD Volume decreases in collapse
8.	Soft tissue shadows	Breast and nipples	Air in SC plane

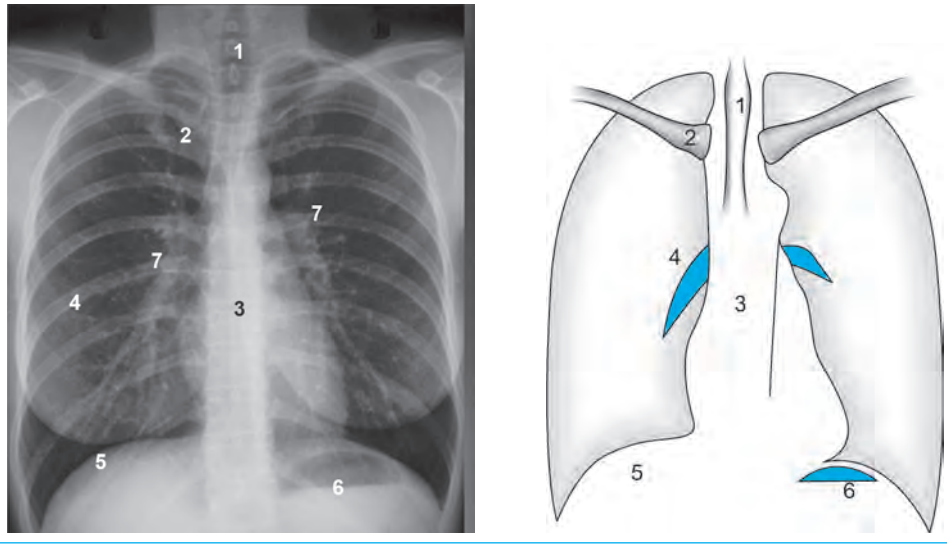

Fig. 2.1: Normal chest X-ray in erect PA view in an adult female patient

1. Trachea is straight, in midline, spinous process seen throw it, indicating no patient rotation
2. Clavicles both medial ends are equidistant from midline, indicating no patient rotation
3. Thoracic spine well seen behind the heart shadow, indicating overpenetration
4. Note the uniform blackiness in both lung zones, indicating normal aeration in both lungs
5. Note the level of diaphragm is at tenth posterior rib, indicating deep inspiration
6. Note the air/fluid level in stomach below left dome, indicating erect patient posture
7. Right and left hilum made up of normal pulmonary vessel and bronchi

film, only the horizontal fissure is visible running from the right hilum to the region of the sixth rib in the axillary line (Fig. 2.2A).

The left lung is divided into two lobes, an upper and a lower, by an oblique fissure (Fig. 2.2B) similar to the right lung. The lingula, or remnant of the middle lobe on the left, is considered to form part of the upper lobe.

The chest X-ray is a 2D projection of a 3D thoracic structures. There is considerable overlapping of lung lobes. Therefore, all the thoracic structures are summated together in a chest X-ray film. There is only a representation of all the lobes in frontal projection (Fig. 2.3). In practice the lung is divided into three zones—upper, middle and lower (Fig. 2.4) by drawing two horizontal imaginary lines—upper one passes through second rib anteriorly and the lower one through the fourth rib anteriorly, in each side. In practice the lungs are divided into zones; upper, middle, and lower zones.

- Upper; from the apex to 2nd costal cartilage
- Middle; between 2nd and 4th costal cartilage
- Lower; between 4th and 6th costal cartilage

Look for equal radiolucency (or blackness due to air filling) between the left and the right lungs zones. Look for any discrete or generalized gray/white shadows (described as opacity/patchy shadows).

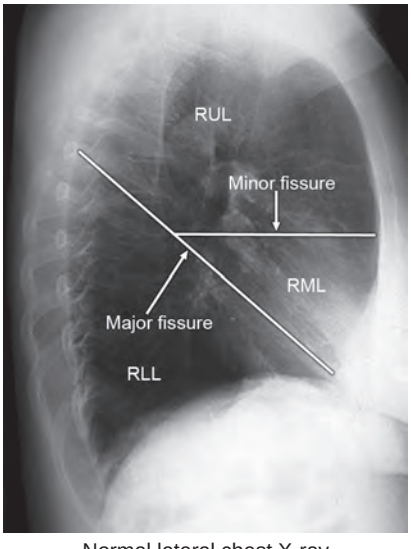

Normal lateral chest X-ray
(MIF) Minor (horizontal) fissure
(MAF) Major (oblique) fissure

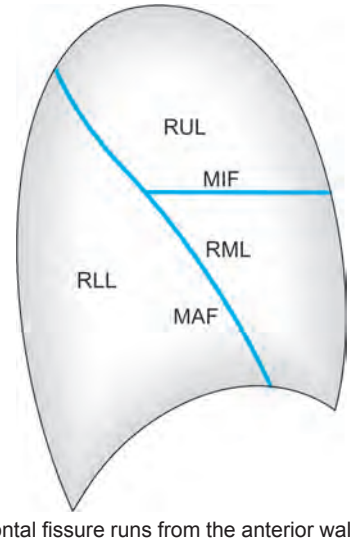

The horizontal fissure runs from the anterior wall of the lung to the hilum, horizontally, dividing the upper section of the right lung into an upper lobe and a middle lobe. On the PA film, only the horizontal fissure is visible running from the right hilum to the region of the sixth rib in the axillary line.

Fig. 2.2A: Chest right lateral view to show both the fissures

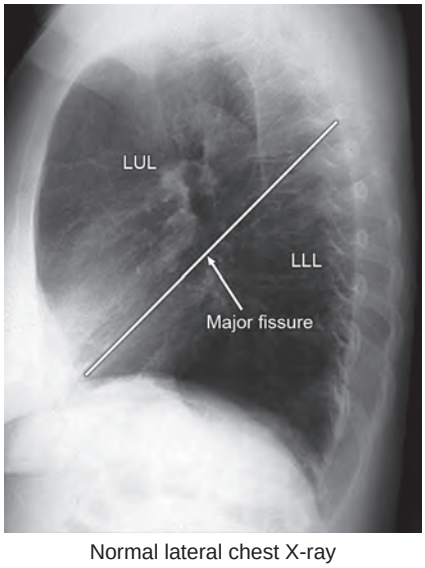

Normal lateral chest X-ray
(MAF) Major (oblique) fissure

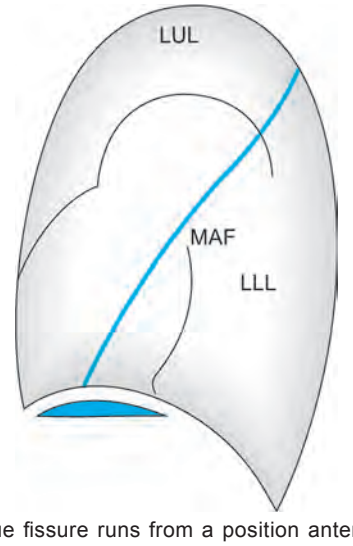

The oblique fissure runs from a position anterior on the diaphragm in a posterior direction superiorly towards the apex of the lung around T4 posteriorly, splitting the lung into an anterior, superior section (the upper lobe) and a posterior, inferior section (the lower lobe)

Fig. 2.2B: Chest left lateral view to show oblique fissure

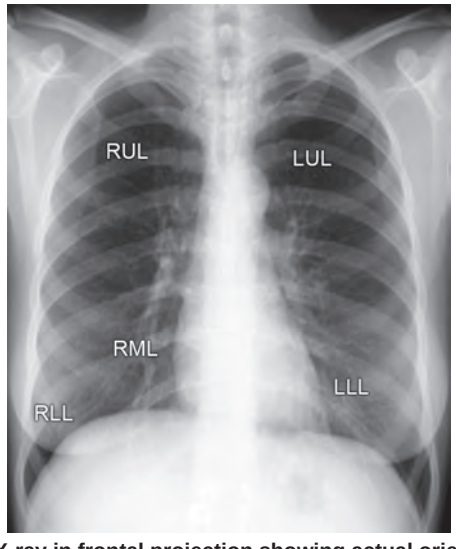

Chest X-ray in frontal projection showing actual orientation of various lung lobes.
There is considerable overlap of various lobes.
The horizintal fissure separates RUL from RML.
The oblique fissure in right side separates RML from RLL.
The oblique fissure in left side separates LUL from LLL.

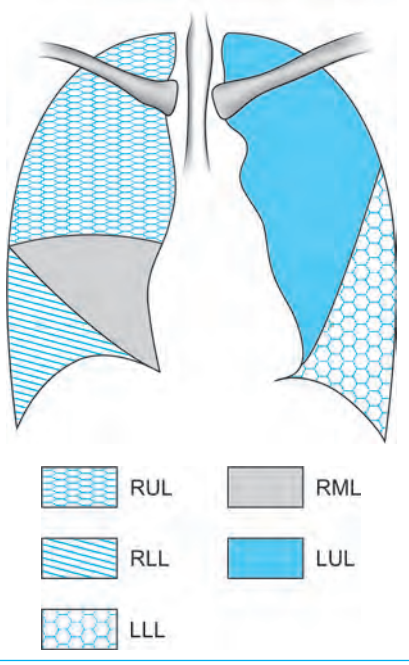

Fig. 2.3: Chest X-ray to show the overlapping lobes in frontal projection

The bronchi, pulmonary artery and lymphatics form the hilum of each lung (Fig. 2.1). The left hilum is usually smaller and higher in position than the right hilum. The pulmonary arteries and veins are lighter and air is black, as it is radiolucent. Both hila should be normally concave, similar size, shape and density.

Pleural Covering

Depending upon the site enveloping the lungs the pleura is named as diaphragmatic, mediastinal, costal, and apical pleurae. There are two layers of pleura: the parietal pleura and the visceral pleura. The parietal pleura lines the thoracic cage and the visceral pleura surrounds the lung. Both of these layers come together to form reflections which separate the individual lobes. These pleural reflections are known as fissures. On the right there is an oblique and horizontal fissure; the right upperlobe sits above the horizontal fissure (HF), the right lower lobe behind the oblique fissure (OF) and the middle lobe between the two. On the left, an oblique fissure separates the upper and lower lobes.

Ribs

Both anterior (to the sternum) and posterior (to the spinal vertebrae) attachments of the ribs are visible on the chest radiograph. It is important to be clear on differentiating the two.

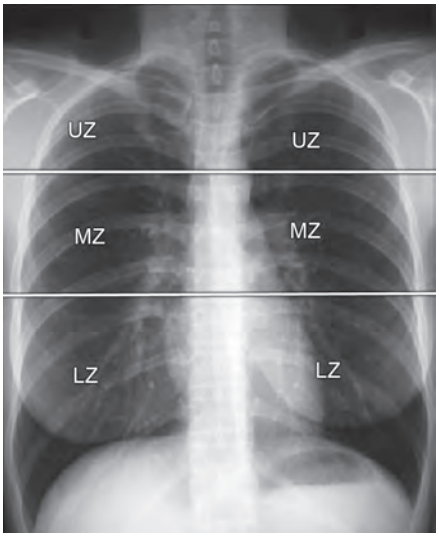

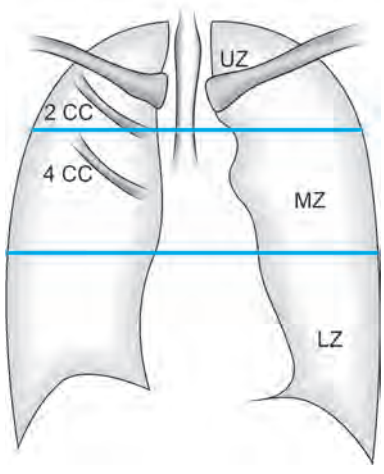

Radiological (Arbitrary) lung zones
UZ-upper zone—above second costal cartilage anteriorly
MZ-mid zone—between second and fourth costal cartilage anteriorly
LZ-lower zone—below fourth costal cartilage anteriorly

Fig. 2.4: Chest X-ray to show the various arbitrary zones

The posterior ribs lie horizontally, whereas the anterior ribs slope inferiorly joining the costochondral cartilages, which are of lower density than bone, are therefore relatively radiolucent, and so appear darker than bone (Fig. 2.5).

Diaphragm

The diaphragm is considered in two halves (left and right "hemidiaphragms") though anatomically there is only one diaphragm. Diaphragm is normally rounded and dome shaped. The right hemidiaphragm is higher than the left, on full inspiration by 2–3 cm. The pleurae near the corners of the thorax and cardiac shadow form the costophrenic and cardiophrenic recesses respectively (Fig. 2.6).

Heart

An overview of cardiac structures is shown in Figure 2.7. The heart lies in the middle mediastinum in midline. The width of the heart should be no more than half the width of the chest. This is the normal cardiothoracic ratio (CTR) (Fig. 2.8). About a third of the heart should be to the right and two thirds to the left of center. *Note:* the heart looks larger on an AP film and thus you cannot comment on the presence or absence of cardiomegaly on an AP film.
Site: Is it located on the right or left?
Size: Is it less than half the transthoracic diameter? (i.e. is the largest diameter of the heart less than half the largest diameter of the thorax)

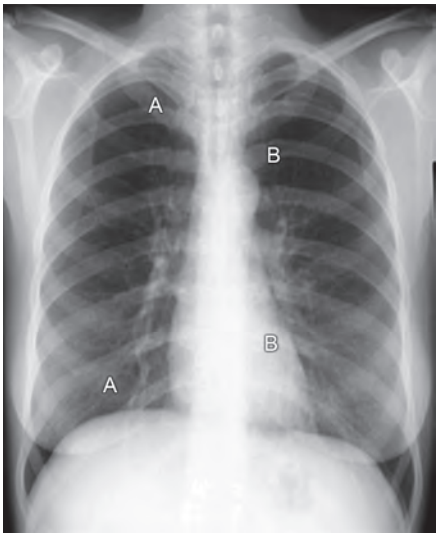

A-Anterior end of first rib and sixth rib-right side
B-Posterior end of fifth rib and ninth ribs in left side.
Each rib has its posterior end higher up and anterior end lower down
Frontal view showing the oblique orientation of the ribs. The anterior portions are slanted downward and the posterior portions are slanted upward. The costal cartilages (not shown) connect the anterior ribs to the sternum

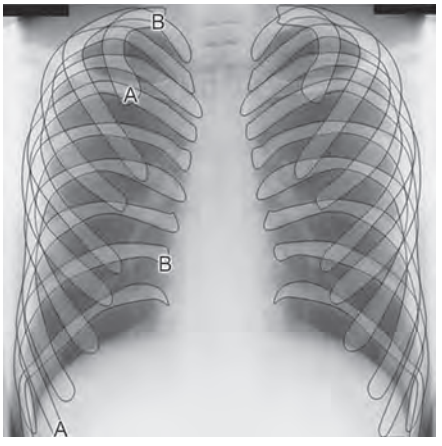

Bony skeleton to show rib cage
A-Anterior end of first rib and eighth rib-right side
B-Posterior end of first rib and ninth ribs in right side
Each rib has its posterior end higher up and anterior end lower down
C-Clavicle

Fig. 2.5: A chest X-ray—adult female—erect PA view to show orientation of ribs

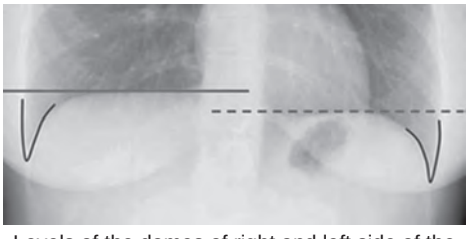

Levels of the domes of right and left side of the diaphragm
Note the sharply outlined right and left costophrenic angles

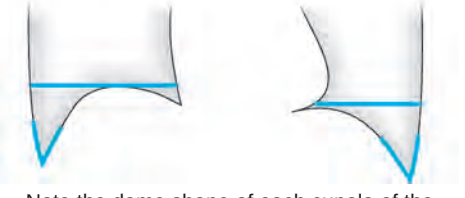

Note the dome shape of each cupola of the diaphragm
Normally right dome is at a higher level, approximately 2–3 cm

Fig. 2.6: X-ray lower chest to show the diaphragm and its recess

Shape: Is it ovoid with the apex pointing to the left?
Shadows: Any change in density?
Borders: Is it clear or well-defined?

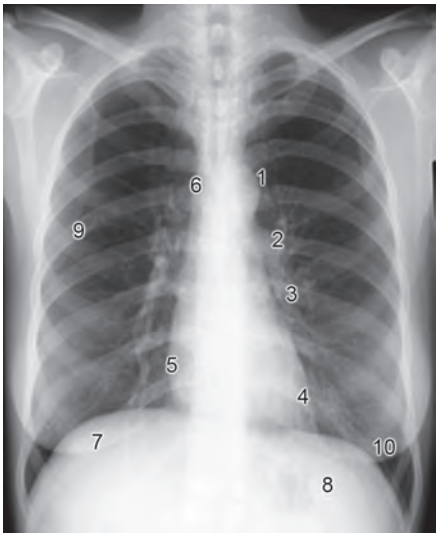

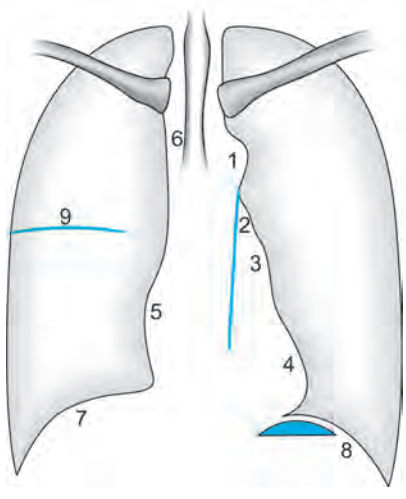

1. Aortic arch
2. Pulmonary trunk
3. Left atrial appendage
4. Left ventricle
5. Right atrium
6. Superior vena cava
7. Right hemidiaphragm
8. Left hemidiaphragm (note gastric air/fluid level)
9. Horizontal fissure
10. Left breast shadow.

Fig. 2.7: Normal chest X-ray in erect PA view in an adult female patient to show cardiac structures

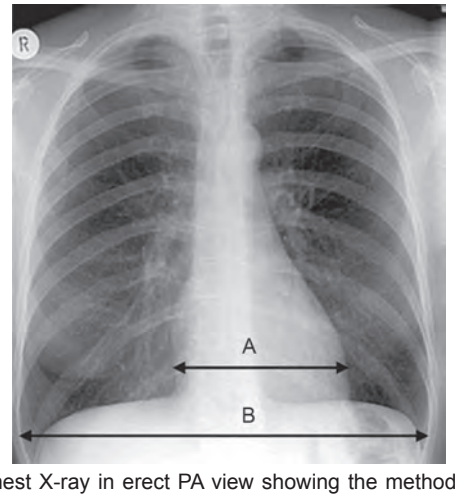

Chest X-ray in erect PA view showing the method of measuring the cardiothoracic ratio (CTR)

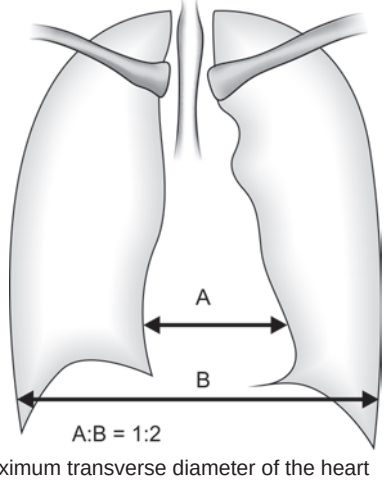

A. Maximum transverse diameter of the heart
B. Maximum transverse diameter of the chest
Normally the CTR (A/B) is 1:2

Fig. 2.8: Chest X-ray to show CTR measurement

The right border is only the right atrium alone and above it is the border of the superior vena cava (Fig. 2.9). The right ventricle is anterior and so does not have a border on the PA chest X-ray film. The left atrium is the posterior most chamber and not normally seen in PA chest X-ray filmThe left border of the heart is formed by (from above downwards) aortic knob, pulmonary artery, left atrial appendage and thin strip of left ventricle (Fig. 2.10).

Key Points for Interpretation

Trachea/Bronchi/Alveoli

a. Is the trachea in midline or deviated
b. Carina (where trachea divides into right and left bronchus) should be visible with slightly blacker outline over the lung fields themselves.
   Check the carinal angle. Normally it is acute.
c. Hila: Pulmonary arteries and veins. Left hilum appears smaller and higher than the right hilum
d. Check expansion of lungs, see all the lobes, both lungs should be symmetrically black.
   Is there are any opacity—linear/segmental/mass-like, etc. Is there any air bronchogram?
e. Look for the fissures—horizontal, oblique, their course, any shift.

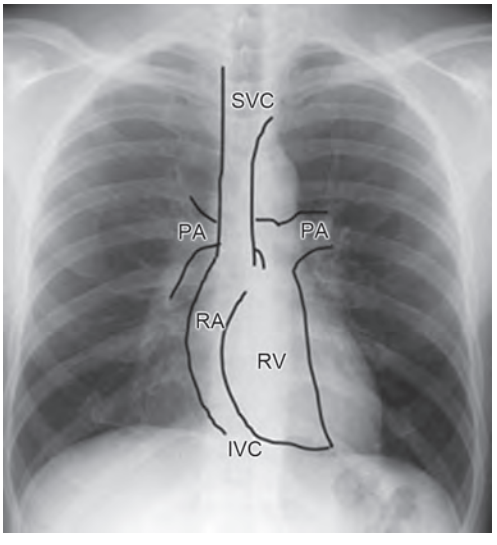

Normal chest X-ray PA, erect view
To show right heart border, position of RA, RV, PA in frontal projection

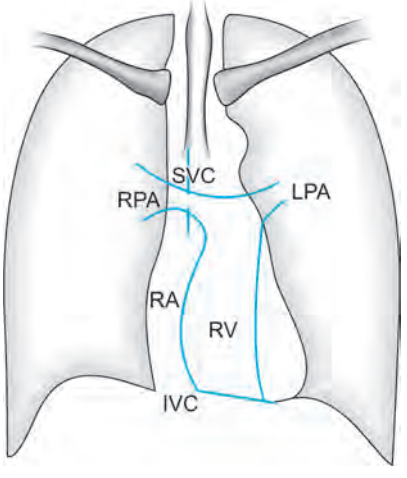

SVC-Superior vena cava
RPA-right pulmonary artery
LPA-left pulmonary artery
RA-right atrium
RV-right ventricle
IVC-inferior vena cava

Fig. 2.9: Chest X-ray with right heart structures lined out

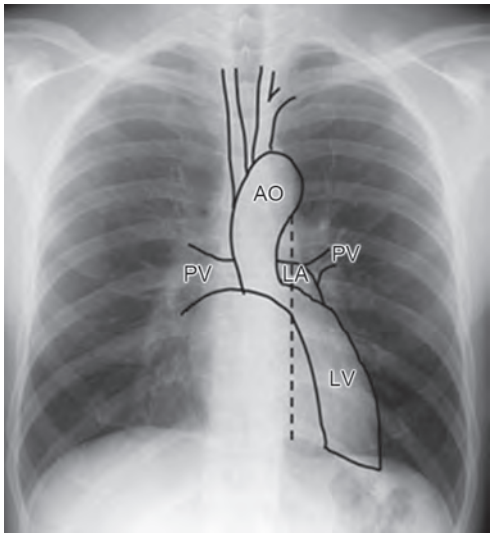

Normal chest X-ray PA, erect view.
To show left heart border, position of LA, LV, aorta, pulmonary veins in frontal projection

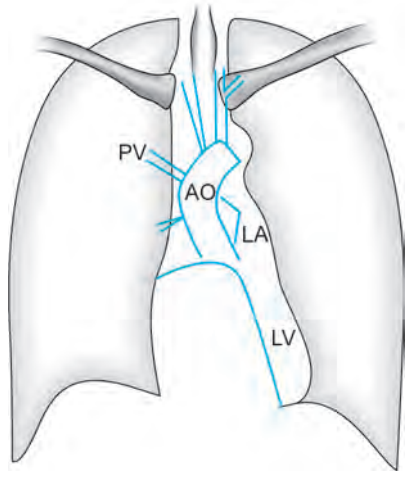

LA-left atrium
LV-left ventricle
AO-aorta
PV-Pulmonary veins

Fig. 2.10: Chest X-ray with left heart structures lined out

Heart and Great Vessels

a. Check size—CTR, cardiac apex.
b. Look at the cardiac site, shape, size, borders.
c. Look for any specific chamber enlargement.
d. Unclear right border suggest middle lobe consolidation.
e. Unclear left border suggest lingular lobe consolidation.
f. Check aortic arch, pulmonary artery for size, site, shape.
g. Check the pulmonary vascularity, is it increased/decreased; is it arterial/venous. Are they pruned?

Mediastinum

a. Check for mediastina size, shifts, density.
b. Check for borders—any mass/abnormal increase of structutes.

Diaphragm

a. Look for the level, shape, any tenting, flattening.
b. Look for sharp costophrenic and cardiophrenic recesses, whiteness immediately above the diaphragm indicates pleural effusion or consolidation. The presence of fluid will produce a meniscus (Meniscus sign) or a concave upper border.

c. Is the diaphragm below the anterior end of the 6th rib on the right? If so, this indicates hyperinflation.
d. Normal diaphragm elevations occur with obesity, pregnancy, pain, bowel obstruction.
e. Flatten diaphragms are indicative of emphysema.
f. Unilateral diaphragm changes are indicative of abdominal organ distention or paralysis.
g. Check sub-diaphragmatic region for abnormal air collection.

Bone Structures

a. Shape of the thorax – emphysema, polio, scoliosis?
b. Is the entire thorax visible? 9–10 posterior ribs should be visible in deep inspiration.
c. Look at and compare the bony structures paying attention to site, size, shape, shadows and borders: (clavicles, ribs, scapulae, thoracic vertebrae, and humerrus).
d. Any rib fractures? Erosion/notching/callus formation, altered density—osteoporosis, osteosclerosis.
e. Signs of surgery—rib resection, any extra rib.
f. Midline sternotomy sutures.
g. Intercostal spaces: Width and angle, wide or narrow?

Soft Tissues

a. Check neck and axilla for surgical emphysema, hemotomas, tumors.
b. Large breast tissue may obscure lung field to some extent, any e/o mastectomy.

Others

Look for any tubes (drainage, endotracheal, etc), pacemakers, catheters, artificial valve, etc.

A, B, C'S of Chest X-ray Interpretation

A- Airways—trachea, bronchi, alveoli
B- Bone cage—ribs, thoracic vertebrae other bones seen—clavicle, scapula
Blood vessels—aorta, pulmonary artery
C- Cardiac structures—CTR, chambers, borders
D- Diaphragm domes, costophrenic and cardiphrenic angles
E- Extrathoracic structures—chest wall, breast, sub-diaphragmatic, supraclavicular region
F- Fissures—oblique, horizontal
G- Gastric air bubble, great vessels—aorta, pulmonary artery
H- Hilum

❑ SOME USEFUL SIGNS IN CHEST X-RAY INTERPRETATION

Silhouette Sign

The normal silhouette (outline) of heart borders, diaphragm, etc. can be well seen because of the contrast that exists naturally between the "white" cardiac structures and "black" adjacent lung tissue.

The silhouette sign is the absence of depiction of an anatomic soft-tissue border. It is caused by consolidation and/or atelectasis of the adjacent lung, by a large mass, or by contiguous pleural fluid. The silhouette sign results from the juxtaposition of structures of similar radiographic density. The sign actually refers to the absence of a silhouette. This phenomenon, called the silhouette sign, is used not only to identify normal chest structures but also diagnose and localize lung diseases. Further the silhouette sign may be used to distinguish anterior from posterior structures on a chest radiograph.

For example, a silhouette sign would be expected in an area of consolidation in the right middle lobe of the lung because this lobe borders the right sides of the right atrium and the mediastinum. Because both the area of consolidation and the heart are water densities (white), the right border of the right atrium cannot be distinguished from the border of the right middle lobe of the lung. That is the right heart border is obscured, if the adjacent lung (right middle lobe) is consolidated (Fig. 2.11).

Uses of Silhouette Sign

1. Helps in localization of disease either in lungs or mediastinum in a chest X-ray, e.g. if a lesion is close to right heart border and obscures this right heart border, then the lesion is only in the right middle lobe of the lungs.

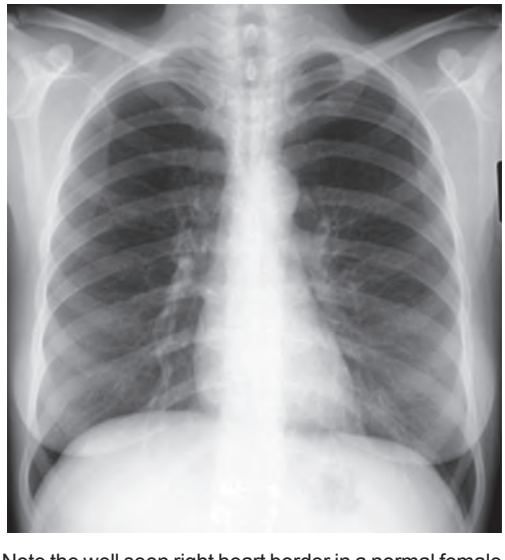

Note the well seen right heart border in a normal female. The white right heart border is well seen with the black density in right middle lobe region. Normally the right middle lobe (RML) is adjacent to right heart margin and does not reach diaphragm.



Note the right heart border is obscured in RML consolidation.
This is positive silhouette sign.
The loss of right heart border silhouette has helped in localizing the lung pathology to middle lobe.
Hence if the right heart margin is indistinct with a sharp diaphragm the lesion has to be in the RML.

Fig. 2.11: Chest X-ray showing application of silhouette sign in right middle lobe consolidation

or detailed information on radiology books, visit our website www.jaypeebrothers.com, for detailed information on radiology

Interpretation of CHEST X-RAY

An Illustrated Companion

Salient Features

- Over 100 chest X-rays are discussed
- Each X-ray is accompanied by a line diagram to highlight important features
- Several useful tables are included
- Several radiographic signs are well illustrated
- Over 100 chest topics, including basic radiography, is covered
- Covers the entire gamut of chest X-rays from lungs to heart
- Chest X-rays are discussed in a unique way, taking into account only the appearance of diseases
- Text is simple, easy-to-follow, and lucid style with well laid-out chapters
- Finds itself with almost every medical student, medical practitioner and all medical colleges
- No such book is found in national or global market
- This is a one-stop book for any chest ailment
- A handy reference book for day-to-day use.



G Balachandran MD DNB DMRD is an Associate Professor, Department of Radiology, Sri Manakula Vinayakar Medical College and Hospital, Puducherry, India and is a highly qualified Consultant Radiologist with over 30 years of experience in teaching radiology. He has already published two books, which were well accepted by medical students. He is a postgraduate teacher of radiology and guided several postgraduate theses. He was an academic registrar in a superspecialty postgraduate institute. He has presented papers in reputed international radiology journals such as American Journal of Neuroradiology (AJNR) and has published over 500 cases in international radiology forum such as EURORAD, MyPACS.net, Radiopaedia.org, Radiolopolis, AuntMinnie, etc. He is a very popular teacher among students.

Shelving Recommendation
RADIOLOGY

Available at all medical book stores or buy directly from Jaypee Brothers through online shopping at www.jaypeebrothers.com

JAYPEE BROTHERS
Medical Publishers (P) Ltd.
www.jaypeebrothers.com

ISBN 978-93-5152-172-3