Visit our website www.jaypeebrothers.com, for detailed information on obstetrics & gynecology books, visit our website www.jaypeebrothers.com

A Practical Guide to First Trimester of PREGNANCY



Mala Arora
Alok Sharma

Foreword
Hema Divakar

JAYPEE

Contents

Contributors *xi*
Foreword *xv*
Preface *xvii*
Acknowledgments *xix*

1. **Physiological Changes** **1**
   Suvarna S Khadilkar, Deepali Patil
2. **Dating and Chorionicity** **6**
   Jayprakash Shah, Parth Shah
3. **The Booking Visit** **14**
   Bhaskar Pal, Seetha Ramamurthy (Pal)
4. **Diet Counseling** **21**
   Kanthi Bansal
5. **Nausea and Vomiting** **32**
   Anupam Gupta
6. **Hyperemesis Gravidarum** **38**
   S Shantha Kumari, D Vidyadhari
7. **First Trimester Screening** **44**
   Anita Kaul
8. **Invasive Procedures** **52**
   Prashant Acharya, Ashini Acharya
9. **Vaccination** **60**
   Sangeeta Tejpuria
10. **Supportive Drug Use** **68**
    Sunita Tandulwadkar, Bhavana Mittal, Pooja Lodha
11. **Prescription Writing** **74**
    Ashis K Mukhopadhyay, Sagnika Dash

12. **Effect of Tobacco, Substance Misuse and Alcohol Abuse** 86
Shashi Prateek, Ananya Banerjee, Deepali Dhingra

13. **Travel Guidelines** 93
Pratap Kumar, Alok Sharma

14. **Role of Exercise and Bed Rest** 98
Maninder Ahuja

15. **Pain Abdomen** 106
Nalini Mahajan, Shivani Singh

16. **Ectopic Pregnancy** 113
Ameet Patki, Alok Sharma

17. **Gestational Trophoblastic Disease** 123
Harshad Parasnis

18. **HIV Positive Mother** 131
Sarita Agarwal

19. **TORCH Infection** 138
Subhash C Biswas, Ram P Dey

20. **Medical Disorders** 144
Sujata Misra, Sudhanshu Nanda

21. **Vaginal Discharge** 152
Roza Olyai

22. **Breast Diseases** 156
Madhuri Patel, Rahul Chauhan

23. **Associated Gynecological Conditions** 164
Rajat Ray, Yogita Dogra

24. **Recurrent First Trimester Pregnancy Loss** 171
Mala Arora, Ritu Joshi

25. ***In Vitro* Fertilization Conception** 178
Bharati Dhorepatil, Arati Rapol

26. **Twin Pregnancy** 183
Krishna Kavita Ramavath

27. **Surgery and Anesthesia** 190
Suchitra N Pandit, Deepali P Kale

28. **Laparoscopic Surgery** 206
Punita Bhardawaj

29. Sexual Behavior **225**
Asmita M Rathore, Reena Rani

30. Vaginal Bleeding **230**
Sadhana Gupta

31. Sepsis **239**
Neela Mukhopadhaya, Kusum G Kapoor, Pragya M Choudhary

32. Termination of Pregnancy **246**
Kiran Kurtkoti

33. Medico Legal Aspects Termination of Pregancy **252**
MC Patel

Annexures: Practical Tips for Ultrasound ***257***
Ajay V Valia

Index 305

Dating and Chorionicity

2
CHAPTER

Jayprakash Shah, Parth Shah

INTRODUCTION

Sonography is an indispensable tool for early pregnancy assessment. Its initial use was for gestational age assessment, i.e., dating.[1] Dating during early pregnancy has the advantage that at this time embryo does not reflect biological variations. Factors, such as race, geographical distribution, and nutrition do not affect its size significantly. Early pregnancy scan will also define the number of gestational sacs in multiple pregnancy and their chorionicity and amnionicity. During the 11–14 weeks scan, one can predict dating with almost equal accuracy, at the same time, we can assess fetal structure, chromosomal markers, and rule out major gross malformation. In some cases, we can predict early growth problems. At the same time, one can define chorionicity and amnionicity in multiple pregnancy with almost equal accuracy.

In obstetrics, many decisions require accurate gestational age for:

- Deciding the timing of invasive procedures like chorion villous sampling and amniocentesis
- Biochemical screening like double marker between 9 weeks and 12 weeks and triple marker at 16 weeks
- Deciding about medical termination of pregnancy
- Induction of labor in intrauterine growth restriction and sick fetuses for better outcome of neonate.

TERMINOLOGY

- *Menstrual age*: It is calculated from last menstrual period
- *Conception age*: It is calculated from day of conception
- *Gestational age*: Conception age +14 days. Gestational age is currently used in place of menstrual age.

Early pregnancy scan gives the best chance to date the pregnancy accurately. The best time to date pregnancy is between 6 weeks and 9 weeks by crown-rump length (CRL),[2] and best chorionicity and amnionicity can be defined at 8 weeks of pregnancy.

DATING OF EARLY PREGNANCY

Gestational Sac

Gestational sac is visible earliest from 4 weeks and 3–4 days. It is nothing but the chorionic sac with thick echogenic (>2 mm) border produced by the developing chorionic villi. It is eccentric and embedded completely in decidua—

intradecidual sign (Fig. 1). As it grows, it distorts the endometrial cavity. Toward the side of uterine cavity, it is covered by two layers of decidua, i.e., decidua capsularis and parietalis, separated by endometrial cavity—*double decidual sign* (Fig. 2). Gestational sac grows at a rate of 1.1 mm/day up to 8 weeks of pregnancy. It is filled by slightly echogenic fluid called chorionic fluid. Gestational sac should be measured from inner to inner border, i.e., only the anechoic area, excluding the trophoblast. It is to be measured in three dimensions, two transverse, and one vertical to get the average mean sac diameter (MSD). Many studies have been published using confirmed conception age as in *in vitro* fertilization pregnancies. These studies have confirmed that gestational sac is very accurate in gestational age assessment with variability of ±2 days. MSD when measured, gives the gestational age in days by a simple formula—MSD in mm +30 = gestational age in days. One can tabulate gestational age from gestational sac measurement. All machines are now equipped with these tables.

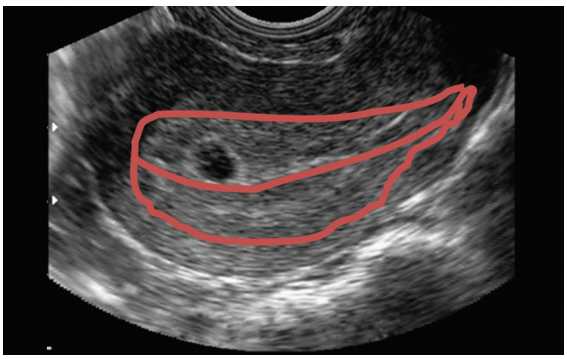

FIGURE 1 Intradecidual sign.

Rules for Gestational Sac Measurement

- Largest sac diameter in longitudinal sagittal and transverse planes should be selected (Fig. 3)
- Inner to inner (anechoic area) to be measured excluding trophoblast
- Two transverse and one vertical measurement, and mean of all three is to be taken
- Accuracy is ±2 days
- Once embryo is visible, it loses its accuracy, and now it is time to switch to CRL for gestational age assessment.

Crown-rump Length

Crown-rump length is crown to rump length but in practice it is maximum length measurement of the embryo (Fig. 4). Embryo is visible from 5 weeks 5 days (CRL 2 mm) just at the periphery of the yolk sac, because at this stage there is no yolk stalk. As soon as the embryo is visible, cardiac activity is visible, but it may not appear in few cases till the embryo size is 5 mm. Measurement of CRL gives the most accurate gestational age

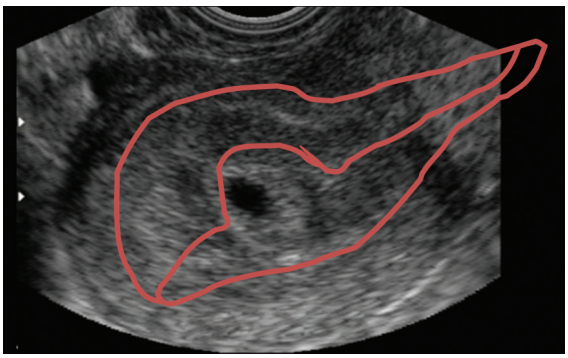

FIGURE 2 Double decidual sign.

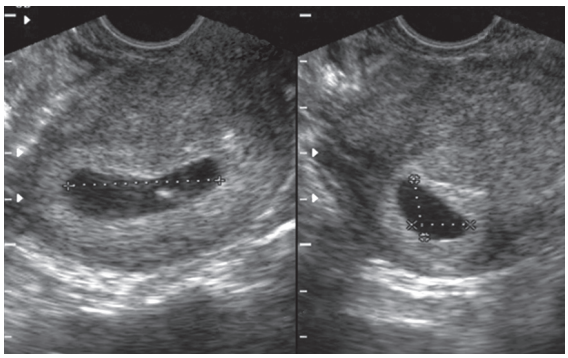

FIGURE 3 Gestational sac measurement in three planes.

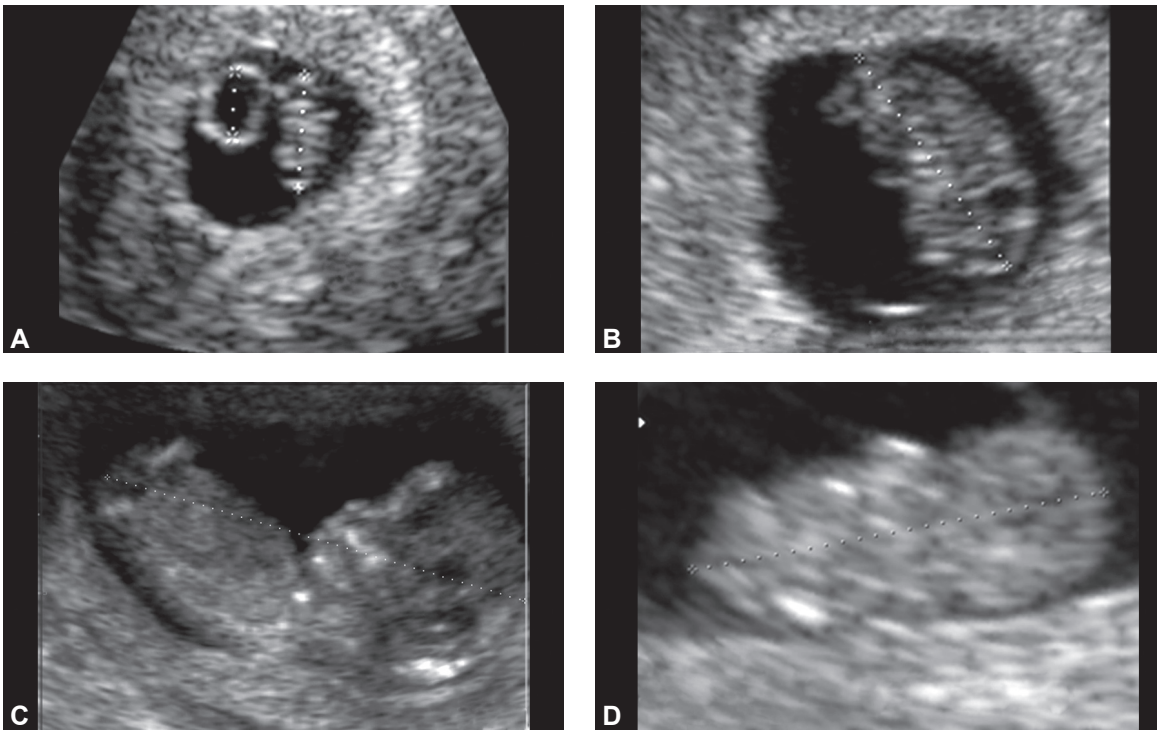

FIGURE 4 Measurement of crown-rump length.

±3–5 days.[3] All the data and studies that have been published unanimously agree upon the accuracy of the CRL for gestational age assessment from 7 weeks to 15 weeks gestation. Transition period of 13–15 weeks is considered best to switch over to other biometry like biparietal diameter.

Rules for Crown-rump Length Measurement

- The embryo shall be with spine towards the probe or away from probe so that the neutral position can be judged accurately. Chin not touching the chest in late early pregnancy. Limbs shall not be visible confirming exact sagittal plane
- Mid sagittal section of embryo—bladder visible and no limb visible in full length
- Maximum length of embryo to be measured.

In a study by MacGregor et al.[4] accuracy of CRL was found to be low with increasing gestational age—toward end of first trimester, probably reflecting the early biological variability. It was observed from various studies that overall accuracy of CRL gestational age has a ±8% variability, i.e., at CRL 11 weeks—gestational age is 11 weeks ±8%, i.e., 11 weeks ±9.5 days.

Biparietal Diameter

With the availability of high resolution machines equipped with transvaginal probe, many studies have been published on assessment of gestational age by other biometric parameters like biparietal diameter (BPD), femur length (FL), and abdominal circumference (AC). Although, BPD, FL, and AC are reasonably accurate, they do not have an upper edge compared to CRL. It is difficult to measure other biometry compared to CRL with accuracy before 13 weeks of pregnancy, although data on BPD are published

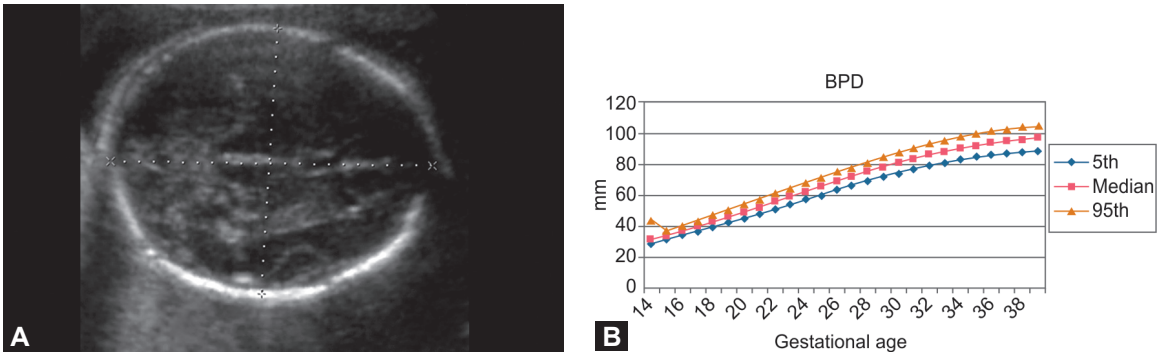

FIGURE 5 Measurement of biparietal diameter (BPD).

from seventh weeks onward. However, after 13 weeks—transition from first trimester to second trimester, it becomes important to switch over to other biometry.[5] Measurement of BPD is most accurate after 14 weeks of pregnancy (Fig. 5).

CHORIONICITY

All multifetal pregnancies are at high risk. It's risk depends on the chorionicity. Chorion is nothing but the developing placenta and when the fetuses in a multifetal pregnancy share the placenta, it means that they share their circulation as well. When circulation is shared among fetuses, one of them may get more blood supply at the cost of other due to arterio-arterial (A-A), arterio-venous (A-V), or veno-venous (V-V) connections. Both fetuses are be at risk. Complications associated with of monochorionicity include twin-to-twin transfusion syndrome (TTTS), acardiac twin, cord entanglement, conjoined twins, parasitic twins, and fetus *in fetu*, which has a direct impact on the outcome of pregnancy. Table 1 shows the outcome of pregnancy based on chorionicity.

Chorionicity and amnionicity are depicted in figure 6. The frequency and perinatal mortality rates are shown in table 1. Figure 7 graphically depicts the higher mortality rate in monochorionic twins.

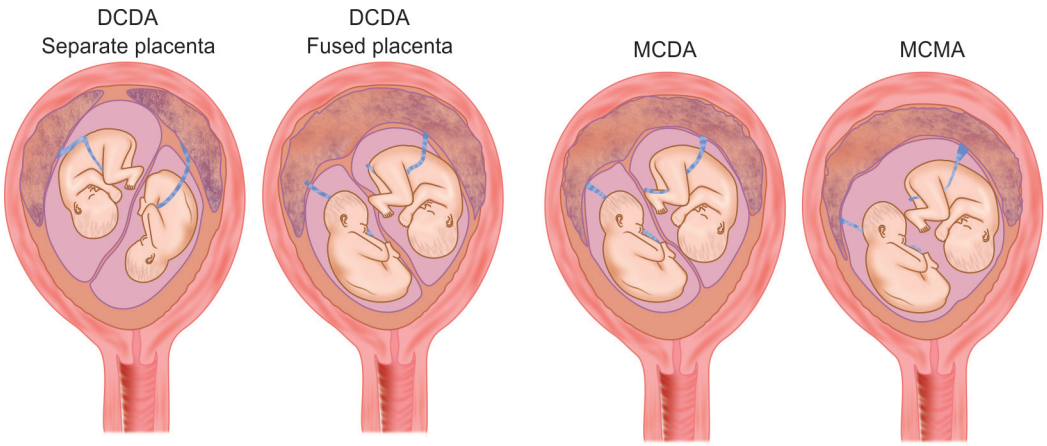

DCDA, dichorionic- diamniotic; MCDA, monochorionic- diamniotic, MCMA, monochorionic-monoamniotic.

FIGURE 6 Chorionicity and amnionicity.

TABLE 1: **Frequency and perinatal mortality with different chorionicity**

	Dichorionic- diamniotic separate placenta (%)	*Dichorionic- diamniotic fused placenta (%)*	*Monochorionic- diamniotic (%)*	*Monochorionic- monoamniotic (%)*
Frequency	35	27	36	2
Mortality	13	11	32	44

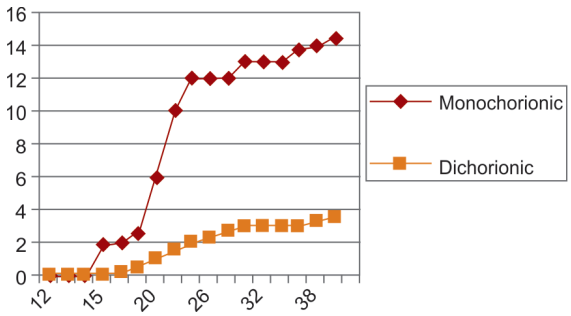

FIGURE 7 Higher perinatal mortality in monochorionic twins.

Chroionicity and amnionicity are prognostic markers in multifetal pregnancy. It is important to define chorionicity by an early scan for better management of these pregnancies.[6] High perinatal morbidity and mortality is associated with monochorionic twins. Selective fetal reduction and invasive testing for chromosomal analysis also require defining chorionicity, as in monochorionic twins, fetal reduction using potassium chloride injection will lead to death of other fetus also. In dichorionic twins, sampling of both fetuses is mandatory.

Assessment of chorionicity using the twin peak lambda sign has a very high sensitivity and specificity.[7] Although chorionicity and amnionicity can be predicted with more than 91% sensitivity by ultrasound, zygosity may not be predicted in all cases.[8] Chorionicity can be assessed as early as 5 weeks gestation but amnionicity cannot be confirmed before the eighth week of gestation.[9] If there has been no earlier scan then the ideal time to check for chorionicity will be the 11–14 weeks nuchal scan. The lambda sign and membrane thickness seem to be superior to other markers listed in table 2.[10] Monochorionic and dichorionic pregnancies are easily identified in early scans (Fig. 8).

In order to understand chorionicity and amnionicity we need to understand the embryology of early pregnancy events. Type of twinning depends upon:

- Two fertilized ova (dizygotic twins)
- Single zygote division (monozygotic twins).

TABLE 2: **Defining chorionicity**

Step 1	Define number of placentas (Fig. 9)	Separate placenta	Dichorionic
		Placenta together	Chorionicity undetermined
Step 2	Define lambda sign/T sign (Fig. 10)	Lambda sign	Dichorionic
		"T"Sign	Monochorionic
Step 3	Thickness of membrane (Fig. 11)	Thick membrane (4 layers)	Dichorionic
		Thin membrane (2 layers)	Monochorionic
Step 4	Sex of fetus	Different sex	Dichorionic
		Same sex	Chorionicity undetermined

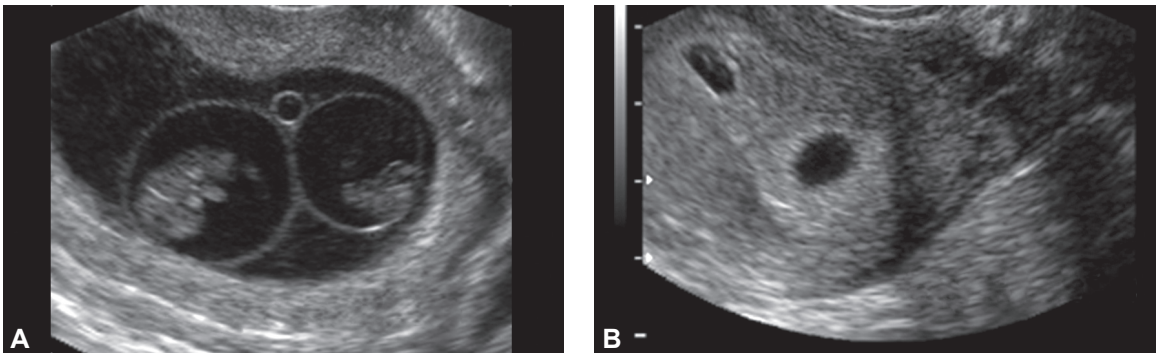

FIGURE 8 Early scan for chorionicity and amnionicity. **A,** Monochorionic-diamniotic twins; **B,** Dichorionic-diamniotic twins.

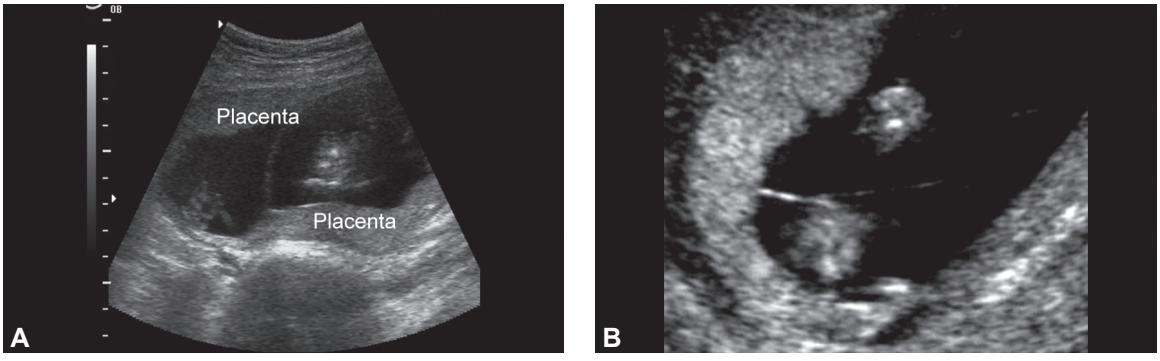

FIGURE 9 Number of placenta. **A,** Two placenta; **B,** Single placenta.

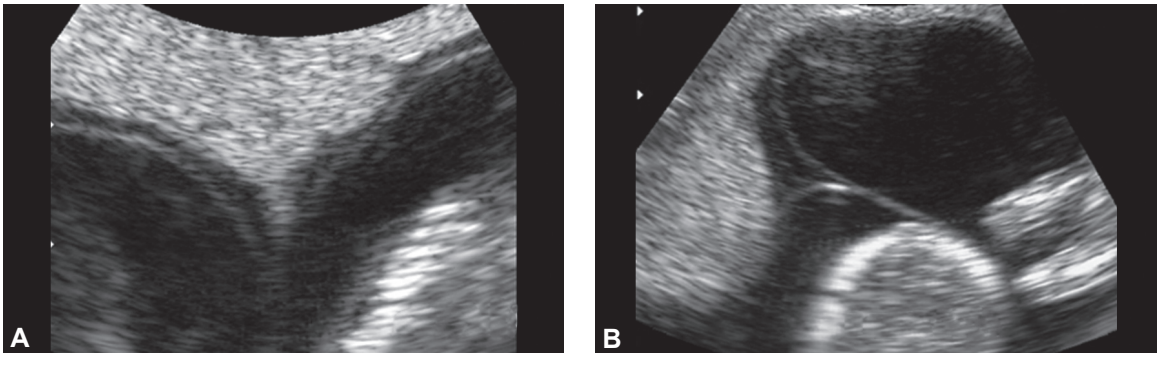

FIGURE 10 **A,** Lambda sign; **B,** "T" sign.

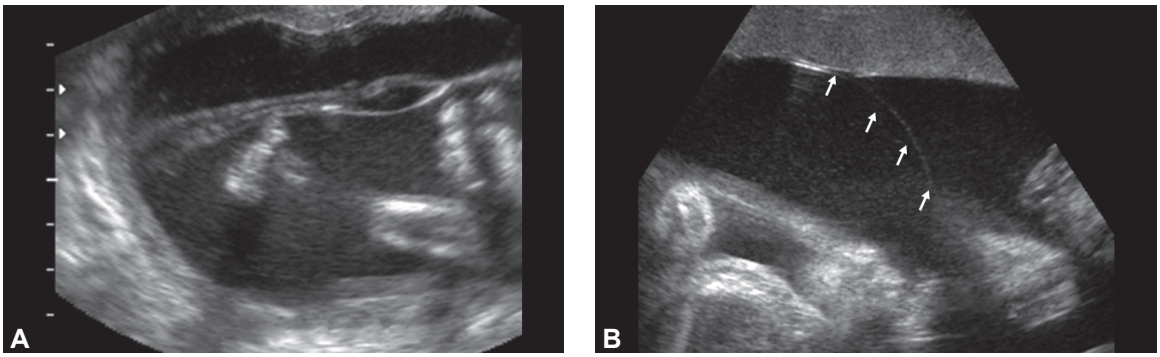

FIGURE 11 Thickness of membrane. **A,** Thick membrane; **B,** Thin membrane.

ZYGOSITY (FIG. 12)

- Can only be determined by DNA fingerprinting
- Prenatally, such testing would require an invasive procedure:
  - Amniotic fluid (amniocentesis)
  - Placental tissue (chorionic villous sampling
  - Fetal blood (cordocentesis).

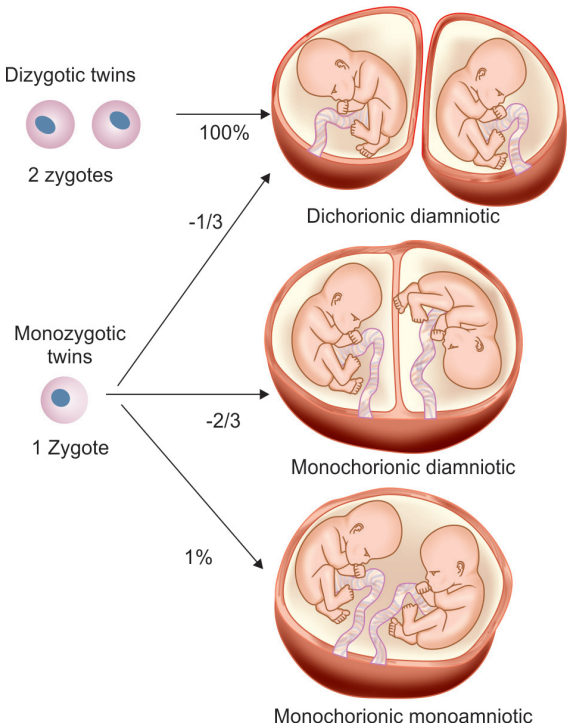

FIGURE 12 Zygosity and chorionicity.

Dizygotic Twins

- All dizygotic twins are dichorionic.

Monozygotic Twins (Fig. 13)

- Dichorionic-diamniotic
- Dichorionic-monoamniotic
- Monochorionic-monoamniotic.

It is believed that a single blastocyst splits the inner cell mass in half, and each half develops into a fetus.

In monozygotic twins all monochorionic twins are:

- Diamniotic
- Monoamniotic
  - Normal fetuses
  - Acardiac twins
  - Parasitic twins
  - Fetus *in fetu*.

Complications in Monochorionic Twins

- Twin-to-twin transfusion syndrome is also known as the *twin oligohydramnios polyhydramnios sequence*. It results in one twin being under perfused and oligoamniotic while the other twin is over perfused and develops polyhydramnios. It carries a mortality of more than 60%. Fetoscopic laser ablation of placental vessels will improve survival rates
- Acardiac twin or twin reversed arterial perfusion syndrome. Also known as the

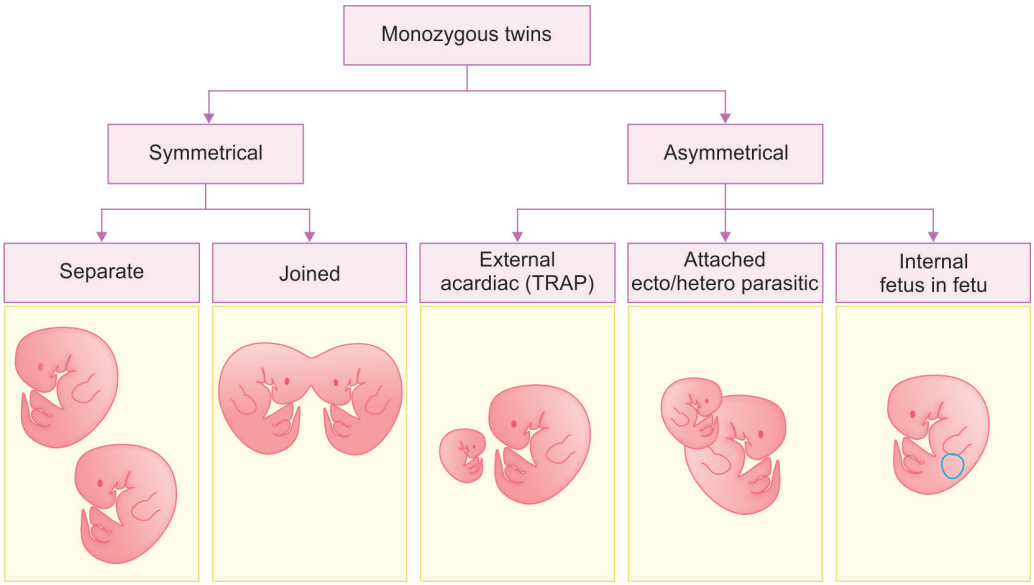

TRAP, twin reverse arterial perfusion.

FIGURE 13 Monozygotic twins.

parasitic twin, or asymmetrical twin, where one embryo maintains dominant development at the expense of the other

- Conjoined twins may be joined at the head or torso and require surgical separation after birth
- Cord entanglement
- Fetus in fetu where a rudimentary fetus is found inside the live fetus.

Ultrasound is hence of immense value in dating a pregnancy accurately. This ensures that we perform prenatal screening procedures at the right time and the decision to intervene and induce labor is also taken at the correct time. Determining the chorionicity and amnionicity in multifetal pregnancy is extremely important. It allows us to follow monochorionic pregnancies more carefully to identify cases of TTTS and take corrective measures.

REFERENCES

1. Reece EA, Gabrieli S, Degennaro N, et al. Dating through pregnancy: a measure of growing up. Obstet Gynecol Surv. 1989;44(7):544-55.
2. Callen PW. Ultrasonography in Obstetrics and Gynecology. 5th ed. Philadelphia, PA: Saunders; 2007.
3. Pederson JF. Fetal crown-rump length in measurement by ultrasound normal pregnancy. Br J Obstet Gynaecol. 1982;89(11): 926-30.
4. MacGregor SN, Tamura RK, Sabbagha RE, et al. Underestimation of gestational age by conventional crown-rump length dating curves. Obstet Gynecol. 1987;70(3 pt 1):344-8.
5. Hadlock FP, Shah YP, Kanon DJ, et al. Fetal crown-rump length: reevaluation of relation to menstrual age (5-18 weeks) with high-resolution real time US. Radiology. 1992;182(2): 501-5.
6. Weisz B, Pandya P, Dave R, et al. Scanning for chorionicity: comparison between sonographers and perinatologists. Prenat Diagn. 2005;25(9):835-8.
7. Wood SL, St Onge R, Connors G, et al. Evaluatiolon of twin peak or lambda sign in determining chorionicity in multiple pregnancy. Obstet Gynecol. 1996;88(1):6-9.
8. Scardo JA, Ellings JM, Newman RB. Prospective determination of chorionicity, amnionicity, and zygosity in twin gestations. Am J Obstet Gynecol. 1995;173(5):1376-80.
9. Monteagudo A. Sonographic assessment of chorionicity and amnionicity in twin pregnancies: how, when and why? Croat Med J. 1998;39(2):191-6.
10. D'Alton ME, Dudley DK. The ultrasonographic prediction of chorionicity in twin gestation. Am J Obstet Gynecol. 1989;160(3):557-61.

for detailed information on obstetrics & gynecology books, visit our website www.jaypeebrothers.com, for detailed information on obstetrics & gyne

A Practical Guide to First Trimester of PREGNANCY

Key Features

- Events of the first trimester lay the foundation, as well as seal the fate of a pregnancy. This book provides the road map to a safe delivery of a healthy child
- It serves as a practical guide to management of first trimester and its complications and incorporates a blend of accepted guidelines, practical inputs, and recent advances
- Physiological changes of pregnancy are discussed, highlighting the importance of booking visit, diet counselling, and prescribing medicines in the first trimester
- Various pathological conditions associated with pregnancy are discussed in detail
- Ultrasound imaging, biochemical, and invasive testing for fetal anomalies is illustrated richly by figures and algorithms
- Safety of surgical procedures for gynecological and nongynecological emergencies is discussed in detail
- Special focus on pregnancy follow-up after in vitro fertilization conception
- Topics like first trimester bleeding, sexual behavior, and twin pregnancy are also dealt with
- Also covers termination of pregnancy and its medicolegal aspects
- Written by experts in the field, this book contains systematic information in a user friendly format, supported by illustrations, tables, figures, and algorithms.

Mala Arora FRCOG DNB FICOG FICMCH
Director, Noble IVF Centre, Faridabad, Haryana, India
Consultant, Fortis La Femme, Greater Kailash, New Delhi, India
E mail: narindermala@gmail.com



Alok Sharma MD DNA MRCOG
Consultant Obstetrician and Gynecologist
Deen Dayal Upadhyay Hospital
Shimla, Himachal Pradesh, India



Shelving Recommendation
OBSTETRICS & GYNECOLOGY

Available at all medical book stores
or buy directly from Jaypee Brothers through online shopping
at www.jaypeebrothers.com

JAYPEE BROTHERS
Medical Publishers (P) Ltd.
www.jaypeebrothers.com