ics & gynecology books, visit our website www.jaypeebrothers.com, for detailed information on obstetrics & gynecology books

Precancerous Lesions of Cervix

Prevention, Early Diagnosis and Management

Maninder Ahuja

Co-Authors
Partha Basu
Dipanwita Banerjee

Foreword
Hema Divakar

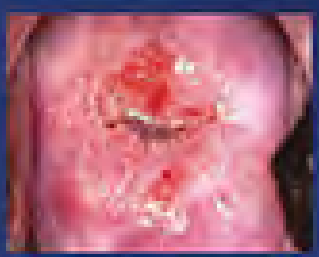



CONTENTS

1. Human Papillomavirus Carcinogenesis and Natural History in Cancer Cervix **1**
Shalini Rajaram

Genome of Human Papillomavirus 2
Mechanism of Carcinogenesis by HPV 3
Viral Persistence 5
Clinical Implications of HPV Oncogenesis 5

2. Primary Prevention Cervical Cancer: HPV Vaccination **7**
Maninder Ahuja

Constituents of Vaccines 9
Formulation of Vaccine 9
Administration and Storage 10
Dosage Schedule of Vaccines 10
Immunogenicity 11
Adverse Side Effects 12
Efficacy 13
Future Vaccines 14
Future Therapeutic Vaccines 14
Some Special Cases 14

3. The Pap Smear as a Screening Test for Cervical Cancer/Precancerous Lesions **17**
Radhika Srinivasan, Arvind Rajwanshi

The 2001 Bethesda System of Reporting Cervical Pap Smears 20
Interpretation/Result 20

4. Practical Aspects of Smear Taking for Cervical Lesions **32**
Maninder Ahuja

Cervical Cancer Screening Modalities 32
Cytology Testing 33
Visual Inspection with Acetic Acid (VIA) and Visual Inspection after Application of Lugol's Iodine (VILI) 39

5. Management of Abnormal Pap Smear **42**
Dipanwita Banerjee

Indications of Pap Smear 42
Cervical Cytological Classification 43

Management Algorithms Following Colposcopy 47
Abnormal Pap Smear in Pregnancy 48
Follow-Up after Treatment 48

6. Approach to Population-based Screening Using LBC and HPV **50**
Manu Noatay
Pap Smear Techniques 51
HPV Testing 56
Papanicolaou and HR-HPV Testing 58
HPV Detection Technology and Various Assays 59

7. Pap Smear as Primary Screening Tool **65**
Sumita Mehta, Ria Malik
Accuracy of Pap Smear 65
Limitations of Cervical Cytology as Screening Modality 66
Harms of Screening 67

8. VIA and VILI in Low-resource Settings **69**
Srabani Mittal
Visual Screening Tests 69

9. Role of Human Papillomavirus Detection in Cervical Cancer Screening **77**
Neerja Bhatla
Strategies of HPV Testing for Primary Screening 78

10. Basics of Colposcopy **81**
MM Samsuzzoha, Bhaskar Pal
Cervix 81
Colposcope 82

11. Detection of Cervical Neoplasia through Colposcope **90**
Partha Basu
Indications for Colposcopy 90
Detection of Cervical Precancers Through Colposcope 91
Colposcopy Report (Based on the International Federation of Cervical Pathology and Colposcopy (IFCPC) Terminology 2011) 105

12. Problems in Colposcopy **106**
Saritha Shamsunder, Paramita Hazari
Patient-related Factors 106
Colposcopist-related Factors 108
Equipment-related Factors 110

13. Management of Cervical Intraepithelial Neoplasia **111**
Amita Maheshwari

Diagnosis of CIN 111
Natural History of CIN 111
Overview of Management of CIN 111
Special Populations 115
Post-treatment Follow-up 115

14. Ablative Methods for Treatment of Cervical Intraepithelial Neoplasia **117**
Vijay Zutshi

Indications of Ablative Therapy 117
Contraindications of Ablative Therapy 117
Cryotherapy 118
Cold Coagulation 119
Laser Vaporization 120
Follow-up after Ablative Therapy 122

15. Excisional Therapy for the Management of Cervical Intraepithelial Neoplasia **124**
Sharmila A Pimple, Gauravi A Mishra, Surendra S Shastri

Evidence for Loop Electrosurgical Excisional Procedure 124
Indications for Loop Electrosurgical Excisional Procedure 125
Advantages of Excisional Methods 128
Adverse Effects 129
Residual or Recurrent Disease 130
Knife Cone Biopsy 130
Laser Conization 131

Self-Assessment Test **135**

Index *143*

3

The Pap Smear as a Screening Test for Cervical Cancer/Precancerous Lesions

Radhika Srinivasan, Arvind Rajwanshi

INTRODUCTION

Cervical cancer is a major public health problem worldwide with approximately 500,000 new cases detected each year of which approximately 25 percent or 125,000 is contributed by India. It is also the most common cause of cancer-related death in India in women. The high mortality is because of presentation at an advanced stage at various centers across the country. The lack of an organized screening program has no doubt resulted in this grim scenario. The Pap test has been the cornerstone of screening for cervical cancer in the developed countries for the last few decades. In 1943, George Papanicolaou published a classic monograph along with Herbert Traut regarding the presence of abnormal cells in the vaginal fluid of women with cervical cancer. This test was later introduced into clinical practice in the West. If there is a single test that has reduced the incidence of and mortality from any cancer, it is the Pap test. The use of the PAP smear as a screening device lead to a 75 percent reduction in the incidence of, and a 70 percent reduction in the mortality from cervical cancer in the Western countries. Unfortunately, in India very little headway has been made with the result that cervical cancer is the leading cause of cancer-related deaths in women.

Rationale for screening by the Pap test: It has been long recognized that the development of cervical cancer is preceded by morphologically well recognized "pre-cancer"—or what is referred as cervical intraepithelial neoplasia (CIN) proceeds in a predictable fashion over a long period, allowing ample opportunity for intervention and prevention of its progression to invasive cancer.[1] These early precursor lesions of cervical pre-cancer can be detected by the Pap smear forming the rationale for using the Pap test as a screening test for cervical cancer.

Cervical intraepithelial neoplasia (CIN): The cervical pre-cancerous lesions affecting the squamous epithelium lining the cervix which are recognized morphologically by the histopathologist are referred to as CIN and 3 grades are seen. These are CIN 1, CIN 2 and CIN 3. In CIN 1, the atypia in the epithelium is restricted to the lower 1/3rd; cellular maturation is evident. Further, qualitatively

JAYPEE BROTHERS

the atypia is mild with mild hyperchromasia and enlargement of nuclei and loss of polarity. In CIN 2 and 3, 2/3rd to full-thickness dysplasia which is qualitatively of moderate to severe degree is noted.[1] It is important to note here that assessment of the qualitative nature of the abnormality is more important than thickness of epithelium involved as one can have CIN1 changes involving the full thickness of the epithelium.

Alternative terminology: The term "squamous intraepithelial lesion" (SIL) is used in place of CIN in many centers to maintain uniformity with the cytological terminology. CIN 1 corresponds to low grade squamous intraepithelial lesion (LSIL) whereas as CIN 2 and 3 are together referred to as or high-grade squamous intraepithelial lesion (HSIL). This terminology applies to both cytology and histopathology of cervix and is discussed in detail below.

The natural history of cervical pre-cancer has been studied well (**Table 3.1**).[1,2] CIN 1 or LSIL lesions usually regress, but may persist in about 1/3rd cases and may progress to HSIL/CIN 3 in less than 10 percent cases. On the other hand about 20 percent cases of HSIL may progress to frankly invasive cancer.

The rate of progression of LSIL to higher grade lesions may well take several years but from HSIL to invasive cancer may take as little as a few months to a 2 to 3 years. Hence, it is important to identify these precursor lesions and manage them accordingly so as to prevent invasive cancer.

Methods for Collection of Cervical Cytology Sample or Pap Smear

There are two techniques available for sampling the cervix. These are:

1. Conventional smear
2. Liquid-based cytology

These techniques are briefly described below:

How to take a conventional Pap smear: The Pap smear may be obtained from the cervix using the Ayre's spatula or preferably an endocervical brush. The latter is preferred as there is better sampling of the transformation zone and the endocervix. Using a Cusco's speculum, the cervix is visualized and any obscuring elements like blood or mucus is gently removed with saline. The long arm of the spatula or mid part of the brush is inserted into the cervical canal and is gently rotated 360° so that the entire TZ is sampled. The device is removed and the material obtained is immediately transferred onto a numbered glass slide taking

Table 3.1 Rate of progression, persistence and regression of CIN lesions[1,2]

	Regress %	*Persist %*	*Progress to CIN3%*	*Progress to Inv Ca %*
CIN1	60	30	10	<1
CIN2	40	35	20	5
CIN3	30	48	N/A	22

JAYPEE BROTHERS

care to cover 75 percent of the surface area and on one side only. The slide is immediately put into a coplin jar containing the fixative 95 percent ethanol. The slide should be fixed in this fixative for approximately 30 minutes after which it may be taken out wrapped in foil and dispatched to a laboratory. Alternatively the slides may be sent to the laboratory in the coplin jar itself. (*Note*: A glass jam bottle can substitute for a coplin jar provided slides are prevented from sticking to each other by using a paper clip).

How to collect liquid based cytology samples: There are two main liquid based cytology (LBC) systems available—the SurePath™ (BD Diagnostics, India) and the Thin Prep (Hologic) systems. The manufacturer's instructions should be followed for sample collection. In Thin Prep system, the brush is rotated in the vial containing the fixative to transfer the contents whereas in the Surepath system, the entire head of the sampling device is detached and put into the sampling vial. The sampling vial, labeled with patient details is dispatched to the laboratory and no smear needs to be done, which is the major difference between the conventional and LBC systems. The entire vial is processed in the lab as per manufacturer's instructions.

Although both techniques are equally sensitive for detection of abnormal squamous lesions, some studies have shown a greater sensitivity for detection of glandular abnormalities in LBC system. LBC offers several advantages over conventional smears which are shown in **Table 3.2**.

The most important advantage of LBC preparation is the reduction in unsatisfactory rate, a visually pleasing cell spread making screening more effective in terms of laboratory productivity and most of all the ability to be able to perform ancillary testing including reflex HPV testing from the same sample.

Pap smear reporting: As per the cervical cancer screening program—world health organization Government of India (CCSP WHO-GOI) guidelines, Pap smears are to be reported using the bethesda system 2001 (TBS-2001) format.[3] This is a well

Table 3.2 Conventional Pap smear vs LBC system

	Conventional smear	*LBC Pap smear*
Unsatisfactory rate	5-10%	1-2%
Obscuration by blood/mucus	Yes	No
Cell spread	Variable	Uniform, monolayer
Cell morphology	Good	Very good
Ease of screening smear	No	Yes
Detection of organism	Yes	Yes
Reflex HPV testing from same sample	Not possible	Possible
Ancillary studies like IHC, PCR, etc.	Not possible	Possible

JAYPEE BROTHERS

validated system that originated in the USA but is used in several other countries including India. TBS 2001 is a standard system of nomenclature that provides.

- A clear statement of adequacy of specimen
- General categorization of smears
  - Negative for epithelial abnormality
  - Positive for epithelial abnormality
- Clinically relevant information with appropriate recommendations for further evaluation the terminology also reflects our current understanding of the pathogenesis of cervical neoplasia.

THE 2001 BETHESDA SYSTEM OF REPORTING CERVICAL PAP SMEARS[3]

Specimen type: Conventional smear/Liquid-based preparation.

SPECIMEN ADEQUACY

- Satisfactory for evaluation
  - *Transformation zone component/endocervical cells*: Present/Absent (Other quality indicators such as partially obscured by blood/inflammation should be mentioned)
- Unsatisfactory for evaluation, (specify reason)
  - Specimen rejected/not processed (mismatch in labeling/slide broken/number not visible/both sides smearing done)
  - Specimen processed and examined but unsatisfactory for evaluation because of (>75% obscuration by blood/mucus/inflammation).

INTERPRETATION/RESULT

Negative for Intraepithelial Lesion or Malignancy

- Organisms
  - *Trichomonas vaginalis*
  - Fungal organisms morphologically consistent with *Candida spp.*
  - Shift in flora suggestive of bacterial vaginosis
  - Bacteria morphologically consistent with herpes simplex virus.
- Other non-neoplastic findings
  - Reactive changes associated with
  - Inflammation/radiation/intrauterine contraceptive device
  - Glandular cells posthysterectomy
  - Atrophy.

Other

Endometrial cells in a woman ≥40 years of age.

JAYPEE BROTHERS

Epithelial Cell Abnormality

Squamous Cell

- Atypical squamous cells
  - Of undetermined significance (ASC-US)
  - Cannot exclude HSIL (ASC-H)
- Low-grade squamous intraepithelial lesion
- High-grade squamous intraepithelial lesion
- Squamous cell carcinoma.

Glandular Cell

- Atypical
  - Endocervical/endometrial/glandular cells, NOS
- Atypical
  - Endocervical/glandular cells, favor neoplastic
- Endocervical adenocarcinoma *in situ*
- Adenocarcinoma
  - Endocervical/endometrial/extrauterine/NOS.

Explanatory Notes[4]

Specimen adequacy: For a conventional smear, a specimen is considered as adequate if there a minimum of 8000 well-visualized and well-preserved squamous cells. For LBC smears, there should be an estimated minimum of 5000 well-preserved and well-visualized squamous cells.

The presence or absence of endocervical cells/metaplastic squamous cells are indicated in the report which should serve as a quality indicator. Their presence indicates adequate sampling of the transformation zone. However their absence is not a contra indication for reporting the smear.

A '*satisfactory smear*' is when the specimen is adequate and there are no obscuring elements. In **Figures 3.1A to D** panel shows satisfactory smear (**Fig. 3.1A**) with adequate representation of the squamocolumnar junction (**Fig. 3.1B**) indicating the 'transformation zone' component. Squamous cells, endocervical columnar cells are identified. Endometrial cells may be seen (**Fig. 3.1C**). On the contrary, the smear is labeled as '*unsatisfactory*' when the overall cellularity is inadequate, there is obscuration of epithelial cells by blood, mucus or inflammatory cells making further evaluation impossible. Apart from this, if the specimen is unlabelled or wrongly labeled or if the slide is broken making identification difficult, then again it is unsatisfactory for reporting. An Unsatisfactory report warrants an immediate repeat smear. Further, the clinician must take corrective action to ensure that the factors responsible for this are not repeated.

General categorization: The bethesda system simplifies this aspect of reporting into those with no evidence of intraepithelial lesion or malignancy (NILM) and

JAYPEE BROTHERS

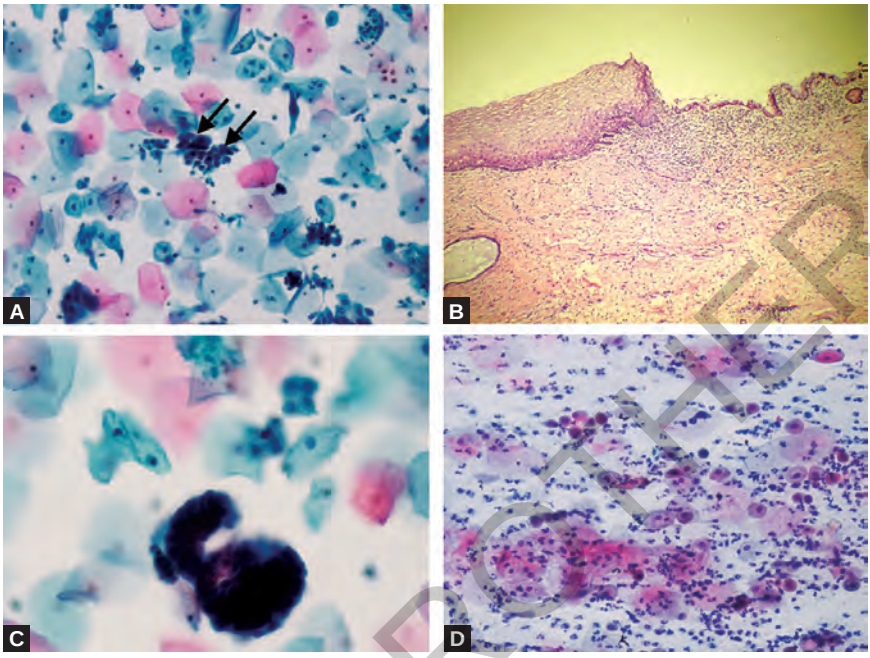

Figs 3.1A to D (A) Papanicolaou smear showing normal smear pattern. Arrows, endocervical cells; (B) Histopathology section of squamocolumnar junction of cervix; (C) Pap smear showing benign endometrial cells; (D) Pap smear, atrophic pattern showing predominance of parabasal cells. [A,B and D, X200; C, X 400]

those with an 'epithelial cell abnormality' which is qualified further. Thus a report of NILM immediately reassures the clinician that the woman requires no further management and may be scheduled for her next smear after 3 years.

Organisms: A 'normal' Pap smear shows Dodderlein's bacilli or lactobacilli in the background consistent with the normal flora. The organisms that may be identified in a Pap smear are

- Coccobacilli (*Gardrenerella vaginalis*) with consequent altered flora, referred to as bacterial vaginosis. These organisms frequently cover the squamous cells which are referred to as 'Clue cells (**Fig. 3.2A**)'
- *Candida spp.*—pseudohyphae and/or spares are seen (**Fig. 3.2B**)
- *Trichomonas vaginalis* seen as pear shaped organism with cytoplasmic granulation and an eccentric indistinct nucleus; flagella may be seen in LBC specimen (**Fig. 3.2C**)
- *Actinomyces spp.*—filamentous organisms seen in clusters giving a 'cotton wool' appearance with an associated polymorphonuclear infiltrate (**Fig. 3.2D**)
- Leptothrix—a commensal identified as long filamentous organisms

JAYPEE BROTHERS

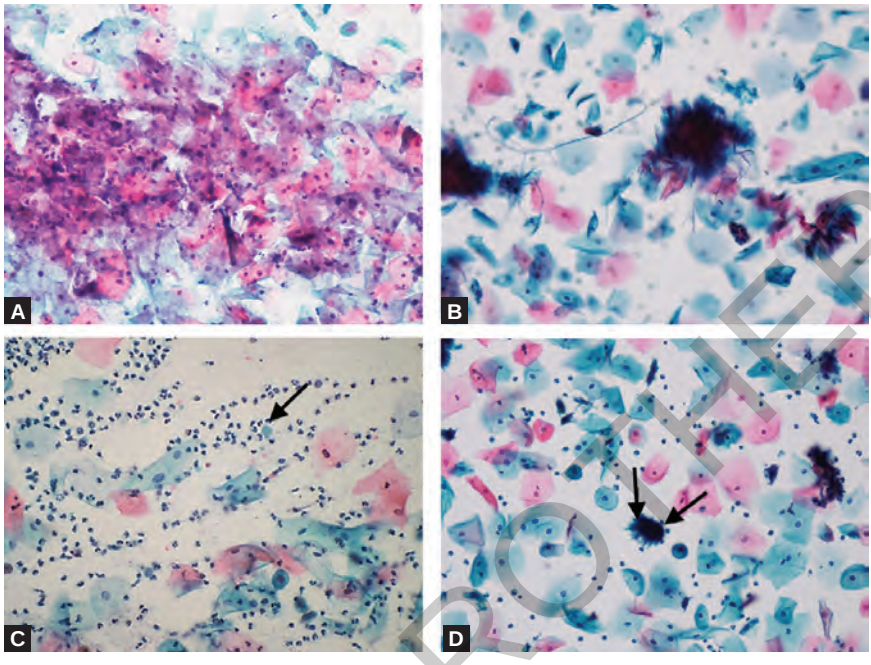

Figs 3.2A to D Benign cellular changes of inflammation with: (A) Bacterial vaginosis. Note coccobacilli crowding and obscuring squamous cells (Clue cells); (B) Pseudohyphae of *Candida spp.*; (C) *Trichomona vaginalis* (arrow); (D) *Actinomyces spp.* (arrows) [A-D X200]

- Herpes simplex virus—the cytopathic changes include multinucleation, molding of nuclei and margination of chromatin. Occasionally intranuclaer eosinophilic inclusion surrounded by a clear halo may be seen.

Reactive changes associated with inflammation, repair, atrophy and with intrauterine devices when present are indicated in the smear. Cellular changes associated with inflammatory include nuclear changes such as nuclear enlargement, binucleation or multinucleation, mild nuclear hyperchromasia or hypochromasia; cytoplasmic changes such as perinuclear halo, cytoplasmic vacuolation, polychromasia. In repair, in addition to inflammatory changes, aggregates of metaplastic cells with associated neutrophilic response are seen; nucleoli may be prominent but are regular and nuclear chromatin is fine and is evenly dispersed. Reactive cellular changes of radiation include nuclear enlargement, hyperchromasia, smudgy chromatin, prominence of nucleoli and bi/multinucleation. Cytoplasmic vaculolization and polychromatic staining may also be observed. Intrauterine device associated changes are mostly seen in the glandular cells and comprise of cytoplasmic vacuolation, increased nucleo-cytoplasmic ration and prominence of nucleoli.

In *atrophy* (**Fig. 3.1D**), there is a preponderance of parabasal cells which may be seen in sheets and also dispersed singly. There is mild nuclear enlargement, chromatin is evenly distributed. Background may show basophilic amorphous

JAYPEE BROTHERS

material, inspissated mucus variable inflammation comprising of neutrophils and histiocytes. Degenerated orangeophilic/or eosinophilic parabasal cells with a pyknotic nucleus called parakeratotic cells may also be seen.

A report of epithelial abnormality is broadly categorized into 'Squamous cell' and 'glandular cell' abnormalities. The cytological features of each of these categories are described in detail.

Low grade squamous intraepithelial lesion or LSIL (with or without HPV associated changes): The abnormality is in the more mature cells, i.e. in the intermediate and superficial appearing cells. The abnormalities include nucleomegaly (nucleus is >3 times size of an intermediate cell nucleus) with hyperchromasia and fine to coarse chromatin. Nucleoli are not usually seen; however, bi- and multinucleation may be seen (**Fig. 3.3A**). *Koilocytosis*, a feature associated with HPV infection may be seen with any grade of dysplasia. Typical koilocytes have nuclei which are hyperchromatic and with condensed chromatin having a perinuclear halo and a peripheral rim of densely satined or condensed cytoplasm (**Fig. 3.3A** inset). The corresponding histology is shown in **Figure 3.3B**.

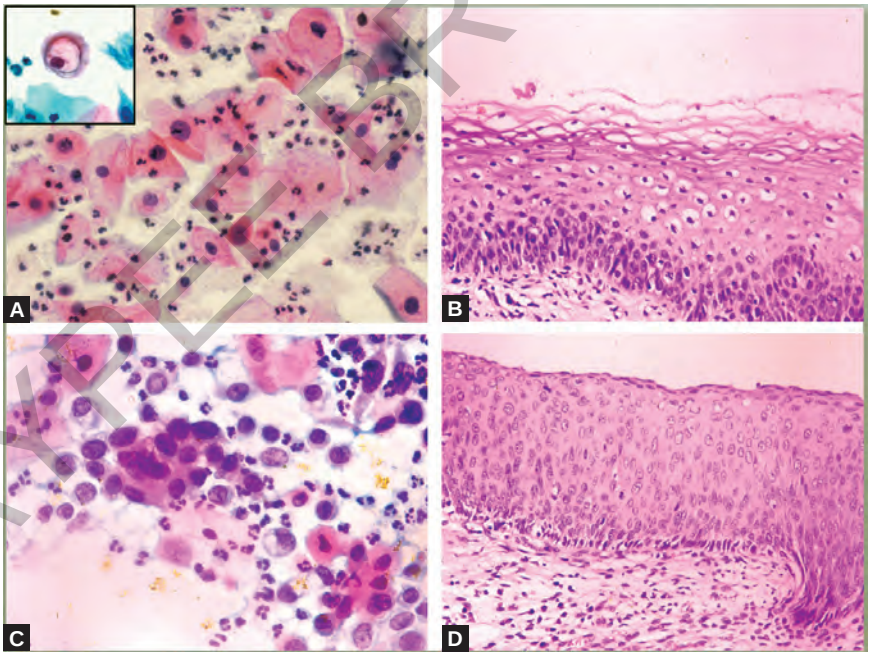

Figs 3.3A to D Squamous intraepithelial lesion (SIL): (A) Pap smear showing LSIL changes in the form of nuclear enlargement and mild hyperchromasia. Inset shows koilocyte; (B) Histopathology section showing CIN1. The dysplasia is limited to the lower 1/3rd of the epithelium; (C) Pap smear showing HSIL changes in the form of high nucleo-cytoplasmic ratio and hyperchromasia; (D) Histopathology section showing CIN3 with dysplasia involving the full thickness of the epithelium [A –D, X400]

JAYPEE BROTHERS

High grade squamous intraepithelial lesion or HSIL: The cytological changes affect cells that are smaller and are less mature than in LSIL. These atypical cells may be seen singly or in aggregates with obvious nuclear enlargement resulting in high nucleo-cytoplasmic ratio, significant nuclear hyperchromasia and pleomorphism, chromatin that is fine or coarsely granular, nuclear membrane that is irregular and indented (**Fig. 3.3C**). The numbers of abnormal cells in SIL can be variable from numerous to scant. The corresponding histology is shown in **Figure 3.3D**.

Squamous cell carcinoma (**Figs 3.4C and D**): The atypical cells display all features of malignancy. There is marked variation in cell shape and size with caudate cells (tadpole cells), spindle shaped cells (fiber cells) frequently with orangeophilic cytoplasm. The nuclei display marked nuclear hyperchromasia with irregularly distributed coarse chromatin, irregular nuclear membrane; nucleoli may be prominent and macronucleoli may be present. Presence of tumor diathesis is a characteristic feature of an invasive cancer. This is appreciated in the background as hemorrhage and necrosis. Tumor diathesis is less well appreciated in LBC smears where the necrotic debris tends to cling to tumor cells referred to as 'clinging diathesis'. The numbers of atypical cells in squamous cell carcinoma is usually much higher than in HSIL; however when there is extensive hemorrhage and necrosis, only a few tumor cells or naked nuclei may be seen.

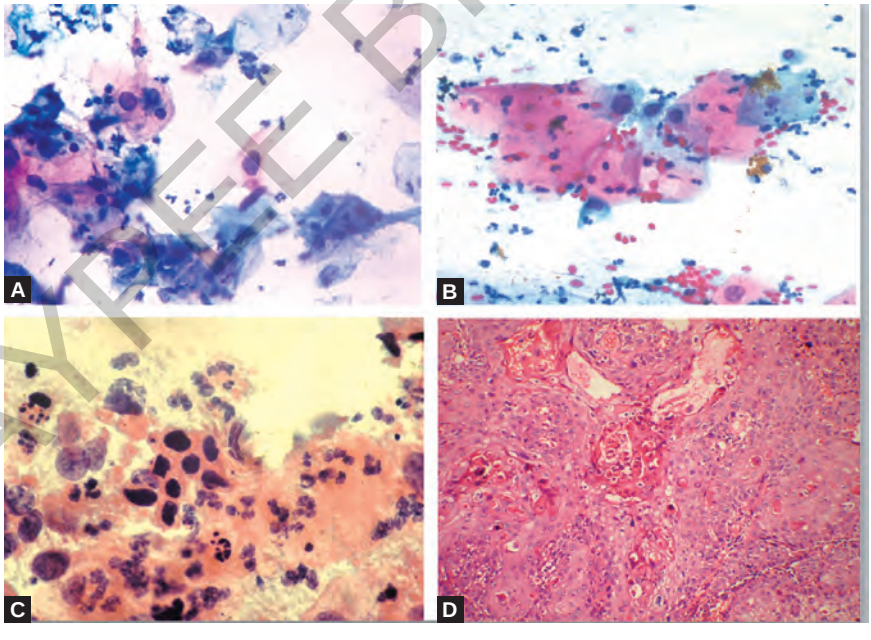

Figs 3.4A to D (A) ASC-US, Pap smear showing an occasional superficial cell with nuclear enlargement; (B) ASC-H, Pap smear showing 3–4 cells with nuclear changes; (C and D) Pap smear and corresponding histopathology section showing keratinizing squamous cell carcinoma [A-D X200]

JAYPEE BROTHERS

Atypical squamous cells: It is defined as an epithelial cell abnormality which exceed those attributable to a benign reactive process but that which fall short of a diagnosis of squamous intraepithelial lesion (SIL). TBS 2001 recommends further qualification of ASC into:

- *ASC-US*: Significance is undetermined
- *ASC-H*: HSIL is not excluded.

ASC is not a diagnostic entity by itself but rather reflects the limitation of the technique/limitation of the interpretative abilities of the cytoscreeners/cytopathologists and represents a vast spectrum of cases ranging from benign reactive processes to invasive cancer. ASC-US smears (**Fig. 3.4A**) show cells with mild (about 1.5-2 times) nuclear enlargement and mild hyperchromasia. ASC-H shows cells with significant hyperchromasia (**Fig. 3.4B**), hence therm HSIL is not excluded. The ASCUS-LSIL triage study or ALTS, a randomized study of 5060 women was a landmark trial that provided valuable insights into the clinical significance and the varied histological outcomes of this group of low grade squamous lesions and also provided the optimal management algorithms.[5] The inter-observer agreement for a cytodiagnosis of ASCUS is only fair and on expert review ASCUS may be downgraded to NILM or upgraded to SIL. Follow-up histology of ASC-US revealed CIN2 or worse lesions in about 15 percent cases; rest were benign inflammatory conditions and squamous metaplasia. Cases of ASC which are positive for HPV DNA have a higher frequency of CIN2 or worse lesions on subsequent follow-up. Further, in the ALTS study, ASC-H constituted approximately 10 percent of cases reported as ASC.[5] ASC-H implies a more severe lesion that requires immediate attention as high grade lesions may be seen in 30 to 40 percent cases.[6] The histological outcome of ASC in our setup is slightly different with higher frequency of detection of high grade lesions including of squamous cell carcinoma.[7]

In a woman whose Pap smear is reported as ASCUS, all 3 options may be considered (**Flow chart 3.1**). The best option is reflex HPV testing and colposcopy restricted to those who are HR-HPV positive. However, if woman cannot afford this test, a repeat Pap smear is advised after an interval of 6 months and managed as shown above. If the woman cannot be relied upon to attend follow-up, immediate colposcopy is advisable. Thus the treatment of ASC-US is individualized and depends on several factors.

The management of ASC-H is similar to HSIL in view of the high proportion of detection of CIN2 or worse lesions in these cases. Immediate colposcopy with concurrent treatment based on colposcopic lesions along with biopsy or biopsy followed by appropriate treatment based on the biopsy findings are suitable (**Flow charts 3.2 and 3.3**).

Glandular Abnormalities

Adenocarcinoma: Endocervical/endometrial/extra-uterine.

JAYPEE BROTHERS

Flow chart 3.1 Management options of women with Pap smear report of ASCUS

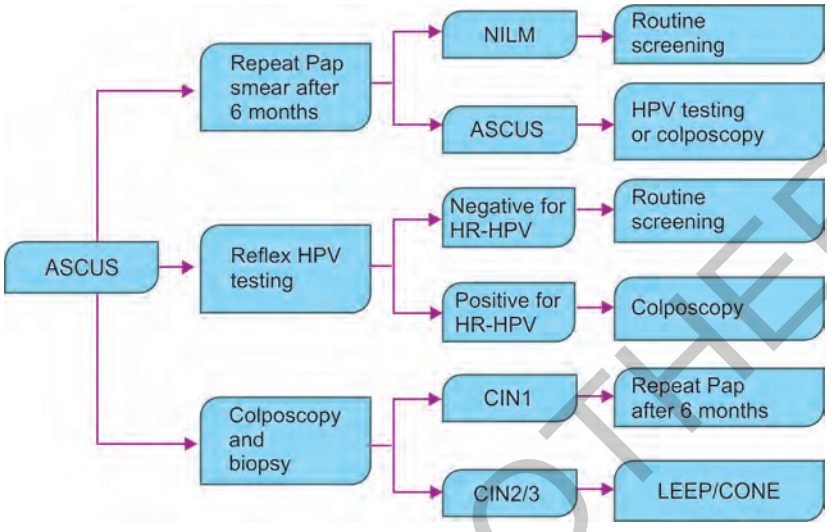

Flow chart 3.2 Management of ASCH diagnosed on Pap smear

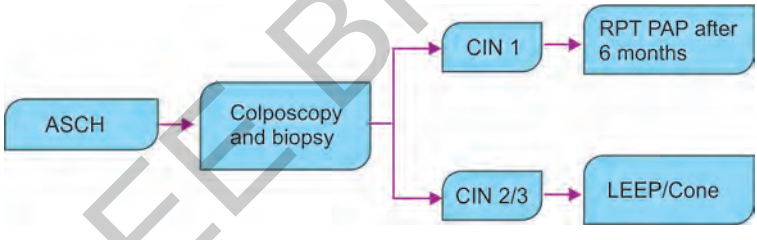

Endocervical adenocarcinoma: Smears are very cellular and show abnormality in the glandular cell clusters. Nuclear enlargement, nuclear pleomorphism, overlapping, fine vesicular but irregular nuclear chromatin, irregular nuclear membrane and nucleolar prominence are features that are observed in the endocervical glandular cells. Tumor diathesis is also appreciated.

Endometrial adenocarcinoma may also shed cells in pap smears. As these are detached and exfoliated cells in contrast to the scraped cells in an endocervical adenocarcinoma, they are seen as smaller groups of more cohesive cells with subtle nuclear abnormalities. Frequently they may just be recognized as atypical glandular cells. Nuclei display moderate hyperchromasia, pleomorphism, irregular chromatin and small prominent nucleoli. Cytoplasm is scanty and often vacuolated. Tumor diathesis may be observed in higher grade tumors.

Endocervical adenocarcinoma in situ (AIS) is by definition a high-grade endocervical glandular lesion that is characterized by nuclear enlargement,

JAYPEE BROTHERS

Flow chart 3.3 Algorithms for squamous epithelial abnormalities detected on Pap smear

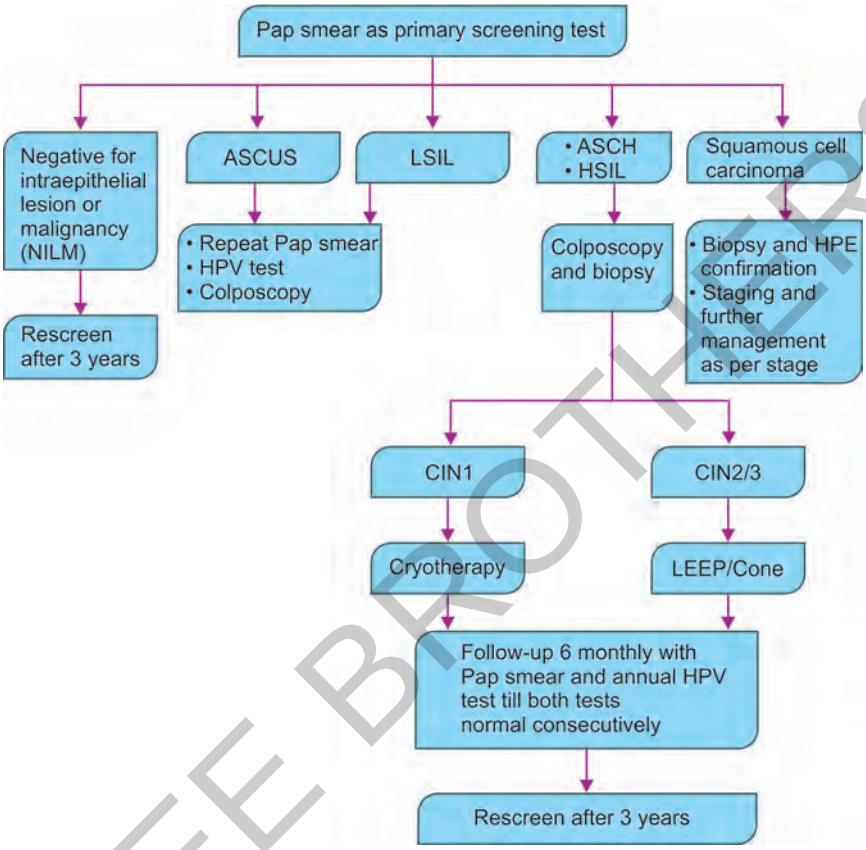

hyperchromasia, stratification and mitotic activity but without invasion. In pap smears, cells occur in strips and clusters with nuclear crowding and overlapping. A palisading nuclear arrangement with cytoplasmic tags protruding from the periphery alluded to as 'feathering' is seen. Nuclei are enlarged, elongated in shape and are stratified. Nuclear hyperchromasia is present and the chromatin is finely granular and evenly dispersed. Nucleoli are small, mitosis are common. Nucleocytoplasmic ratio is increased. Background is typically clean with no tumor diathesis.

Atypical glandular cells (AGC) by definition display nuclear atypia that exceeds obvious reparative or reactive changes but that lack unequivocal features of an invasive or an *in situ* adenocarcinoma.

- AGC may be of endocervical/endometrial type or NOS
- *Subcategories*:
  - AGC-not otherwise specified (AGC, NOS)
  - AGC-favor neoplasia (AGC, FN)

JAYPEE BROTHERS

detailed information on obstetrics & gynecology books, visit our website www.jaypeebrothers.com, for detailed informatio

Precancerous Lesions of Cervix

Prevention, Early Diagnosis and Management

Salient Features

- Covers everything from epidemiology to primary and secondary prevention of cervical cancer
- Includes various management strategies for premalignant lesions of cervix
- Useful guide for the practicing gynecologists



Maninder Ahuja is a Senior Consultant Gynecologist with over forty years of experience in the field of gynecology. She has keen interest in the preventive and positive health strategies for the women in midlife. Her areas of interest include preventive oncology, colposcopy and excisional procedures.

She is active in professional organizations such as Federation of Obstetric and Gynaecological Societies of India (FOGSI). Currently, she is the Vice President, FOGSI and the President, Indian Menopause Society, the Deputy Secretary General, South-Asian Federation of Menopause Societies, the Founder Secretary, Faridabad Chapter of Indian Menopause Society and the President, Faridabad Obstetrics and Gynecological Society (FIGO).

She has already authored the book *Step by Step Management of Menopause* and many chapters in various books including *Jeffcoate's Principles of Gynaecology*. Because of her interest in lifestyle modifications, she has produced many DVDs on *Role of Exercise from Adolescents to Menopause* for prevention of various morbidities of midlife and beyond.

Her interest in reducing the burden of cervical cancer led her to conceive the idea of producing the book *Precancerous Lesions of Cervix: Prevention, Early Diagnosis and Management*.

Available at all medical book stores
or buy directly from Jaypee Brothers through online shopping
at www.jaypeebrothers.com

JAYPEE BROTHERS
Medical Publishers (P) Ltd.
www.jaypeebrothers.com

Branching
Recommendation
OBSTETRICS &
GYNECOLOGY