ers.com, for detailed information on ophthalmology books, visit our website www.jaypeebrothers.com, for detailed information on ophthalmology books

Manual of Oculoplasty Orbitopathies & Dacryology



Subhash Goswamy

Contents

Part I Fundamental Concepts

1. Basic Information 3
The Approach 4
Variations with Age 5
In General, Normal Appearance of Adult Eyes 6
Variations from Normal Appearance in Morphology 7
Basic Principles in Oculoplasty 10
The Outcome of Meticulous Surgical Efforts 12
Proper Knowledge and Use of Suture Material 13
Subtle Tips for Decent Suturing 14
The Scars 15
Management of Disease Process 16
The Fundamental Concepts of Surgery 17
Our Anti-inflammatory Agent Policy and Philosophy 19

Part II An Atlas of Observations, Analyses, Pitfalls and Remedies

Section A: Esthetic Aspects

2. Anomalies and Deformities of Lid Margins 25
Panorama of Lid Colobomas 28
Acquired Defects 33

3. Acquired Lid Swellings 41
Study of Sequence of Events of Diseases 44

4. Ectropion and Entropion 51
Ectropion 52
Entropion 60

5. Assorted Surgical Procedures 71
Bucket Handle Operation (Cutler Beard Technique) 76

6. Ptosis and Blepharophimosis 81
Experience in Management of Ptosis 82
Management of Ptosis 82
Aims 82
When to Operate! 85
Surgical Principles 92
Levator Palpebrae Superioris (LPS) Resection Operation Steps 95
Pros and Cons of Sling Operation 98
Steps of Sling Operation 99
Few Comments about Fasanella Servat Operation 101

Limitations in Achieving Ideal Ptosis Correction 103
Let Us Review Limitations for Operation Outcome 107
Management of Blepharophimosis Syndrome 108

7. Blepharochalasis (Baggy Eyelids) **111**
Blepharochalasis 112
Fornicial Herniation of Fat Lobules 117

8. Dermolipomas and Dermoids **119**
Dermolipomas and Dermoids 120
Dermolipomas 121
Dermoids 128
Computed Tomography Scan (CT Scan) Revelations in Varied Cases 130
Big Orbital Dermoids Adequately Operated Upon 132

9. Hemangiomatous Malformations **135**
Panoramic Illustrations of Some Surgeries Documented 146
Arteriovenous Malformation 150

10. Conjunctival and Limbal Blemishes **153**
Conjunctival and Limbal Blemishes 154
Fornicial Cysts 159
Pterygium 161

11. Pitfalls in the Management of Lids and Orbital Trauma **167**
Post-traumatic Ocular Damage 176

12. Foreign Bodies in Orbit **179**

13. Contracted Socket and Enucleation **187**
Contracted Socket and Enucleation 188
Cardinal Steps in Repair of Conjunctival Contracted Socket 192
Salient Features about Evisceration and Enucleation 197

14. Ichthyosis and Acute Ocular Myositis Complex **199**
Ichthyosis 200
Lamellar Desquamation of Skin of Newborn (Syn. Collodion Baby) 200
Ichthyosiform Dermatoses 200
Ocular Problems 202
Acute Ocular Myositis Complex 203

Section B: Orbitopathies

15. Developmental Anomalies **215**
Cyclops 216

16. Orbital Inflammations **227**

17. Endocrinal Exophthalmos **241**
Ocular Management 246
We cannot Cure Endocrinal Exophthalmos 246

18. Benign Orbital Lesions **247**

19. Bony Orbit Degenerative Conditions **255**

20. Malignant Tumors in Children **261**
Medulloblastoma 263
Acute Myeloid Leukemia 264
Rhabdomyosarcoma 265

21. Malignant Tumors in Adults **267**

22. Orbital Fractures **279**

Section C: Dacryology

23. Epiphora **289**
Partial or Total Blockage of Lacrimal Drainage Passages 291

24. Surgical Management of Complete Blockage of Nasolacrimal Duct **299**
Dacryocystorhinostomy 304
Postoperative Care after Dacryocystorhinostomy 308

Epilogue **311**

Index *313*

Chapter 3

Acquired Lid Swellings



JAYPEE BROTHERS

INTRODUCTION

There is bound to be some overlap of conditions presented in Chapters 2 and 3. However the stress and outlook for their management can be easily discerned. Kindly review the first two schematic drawings of lid margin and lids in relation to eye and orbits (*See* Figs 1 and 2, Chapter 2), for better understanding of diseases under discussion now. *Most of these give cosmetic blemish and are treatable.*

Fortunately a good majority of these lid blemishes are preventable. All that is needed is practice of basic hygiene principles, such as:

- Hair-bearing parts of skin *must be washed* with soap and water regularly
- Do not rub the eyes knowingly *with dirty* hands, cloth, tissue or handkerchief
- While cleaning or rubbing the eyes, be aware that your hands are clean
- At the time of washing your eyes, *give gentle massage* of lids to keep the many lid glands openings patent and draining well their useful secretions
- Do not share cosmetics for eyelids with anybody. *Further*, wash and wipe clean the cosmetics every day. *Be aware that* the cosmetic debris, shedding epithelial cells, foreign bodies and infective agents obstruct flow of tears into the punctum, canaliculi and lacrimal sac leading to acquired dacryocystitis and its consequences.

Those who practice *hygienic precautions* do not suffer, *and when* early signs of lid infections appear, get prompt treatment. *Nip in the bud the growth of unwanted 'acquired eye blemishes!'*

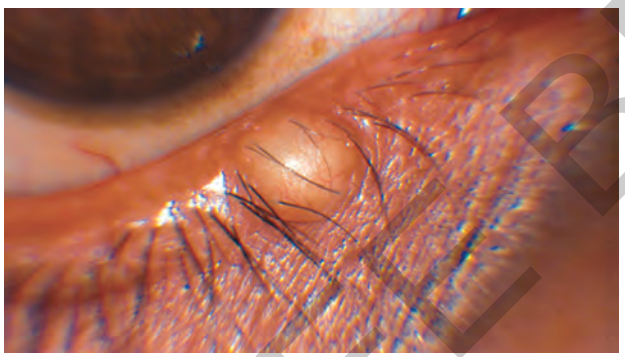

Fig. 3.1 Cyst of Moll

As is evident from the title of this Chapter, that is 'the acquired swellings', we will not present here the two most common conditions of the lids and their surroundings viz. dermoids and hemangiomas as they deserve separate detailed discussion in individual Chapters 8 and 9.

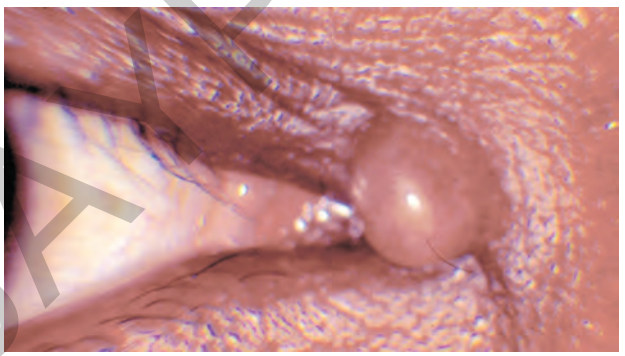

Fig. 3.2 Cyst of Zeis

Cyst of Moll or Zeis: It is swellings of the respective glands situated anterior to the lid margin strip amongst the rows of eyelashes. Closure of their openings leaves milky cyst (of Moll) (**Fig. 3.1**) or watery cyst (of Zeis) (**Fig. 3.2**). They can occur anywhere along the eyelid margin, *and may be multiple, usually they are noninfective, unless incision or drainage, etc. is tried. Their* ***proper treatment*** is complete excision after horizontal skin incision and careful dissection. Then, there will be no recurrence or cosmetic blemish and infection is avoided.

JAYPEE BROTHERS

They have to be differentiated from 'the stye' (acute hordeolum externum), which is infection of the hair follicle and its accompanying glands. *When* this is subtly differentiated in early stages, the eyelash is plucked and pus drained followed by local Betadine treatment, *satisfactory resolution is achieved.*

Otherwise, we observe multiple eyelashes root infection with the covering skin and muscle infection, pouring pus, matted lashes and angry inflamed skin with or without ulcers and crusts. *The collective picture is termed infective (ulcerative) blepharitis* (**Fig. 3.3**).

This needs effective full course of appropriate systemic antibiotics (Minocycline course given once a day for 1 week gave us good results). This is *supplemented with* local cleaning of lash-bearing skin thoroughly along with removal of crusts and scales, followed by local application of tetracycline ointment after drying the cleaned area and painted with Betadine solution. This gave us quick and satisfactory results.

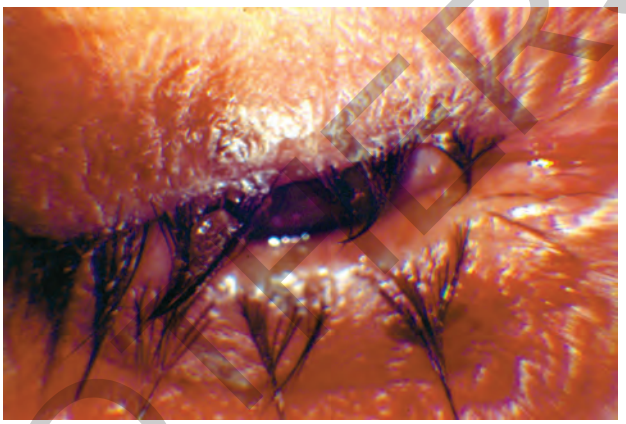

Fig. 3.3 Infective blepharitis

The condition of *squamous blepharitis* giving lid margin inflammation is due to fluffy desquamation of skin amongst roots of lashes. Scratching of lid margins with finger nails or coarse tissues aggravates the condition (excoriation), leading to superficial epithelial inflammation giving more itching and more inflammation—a vicious cycle.

Generally this is neglected by the patient or overlooked by the treating physician. If neglected too long, the inflamed skin may get infected leading to ulcerative blepharitis.

All that is required is early reporting, prompt diagnosis followed by advice for basic hygiene and if desquamation and inflammation are more, treat with local steroid and antibiotic ointment application after cleaning and drying the area for a limited period and progressively reduce its use.

JAYPEE BROTHERS

STUDY OF SEQUENCE OF EVENTS OF DISEASES

At this juncture, we wish to emphasize the purpose of detailing the sequence of events of some diseases, is to clearly understand *the pathogenesis steps through clinical pictures*. Thereby, we can strategize to arrest and reverse the condition, thus remove or minimize the blemish at the earliest. The sequence observed through clinical *pictures gives deep impression and awareness* than the mere words for the treating surgeon. *Hence management plan or plans* are *better explained to* patient and are *better executed*, giving minimal blemishes or none at all.

Therefore the objective of this Manual and the Atlas will be better served and the desired benefits will reach the patients.

When prompt treatment for acute lid margin glands infection is either neglected or inadequately applied, *we observe stages of either subacute hordeolum externum with scab or abscess or cellulitis* (**Figs 3.4 to 3.6**).

These conditions need drainage of pus if any, followed by appropriate course of systemic and local antibiotics and anti-inflammatory drugs till complete resolution of swelling and its reactions. We found local application of Betadine solution at pus drainage site very useful, as it penetrates deeper into the swelling.

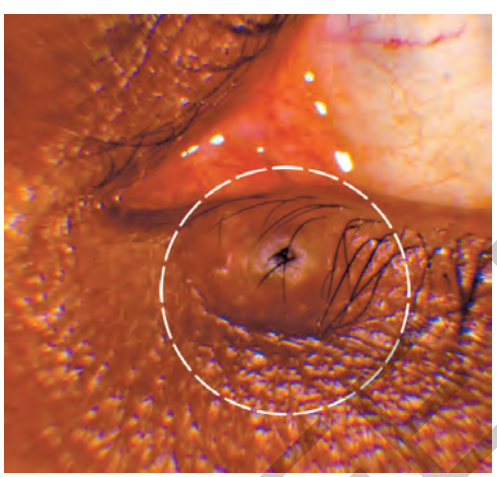

Fig. 3.4 Scab

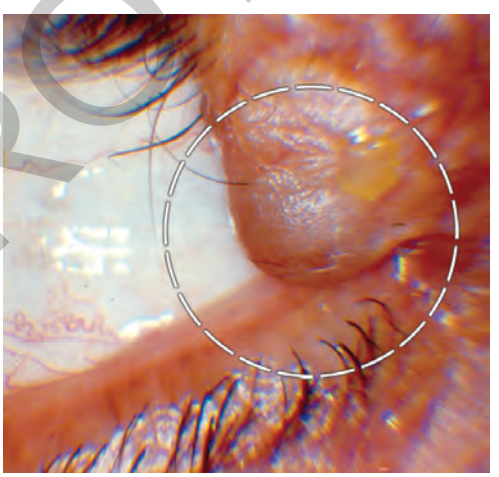

Fig. 3.5 Abscess



Fig. 3.6 Cellulitis

JAYPEE BROTHERS

When only local surface application of antibiotic is done for subacute or chronic infected swelling, this results in surface healing of skin but not the infected glands. This is termed as *antibioma* and must be avoided to let it form as infection penetrates deeper tissues resulting in possible permanent scarred knotty swelling (**Fig. 3.7**).

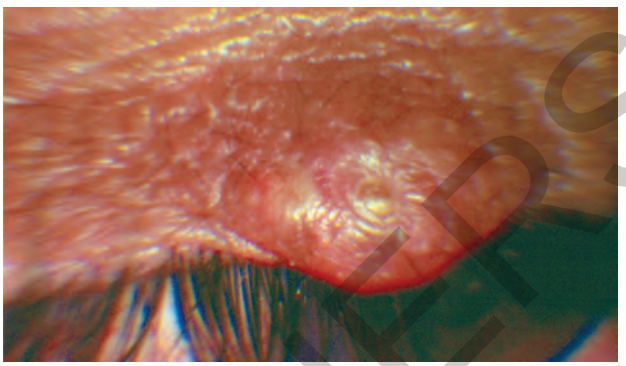

Fig. 3.7 Antibioma

Similarly when acute hordeolum internum cases are left untreated or are partially treated by 'some eye drops' (as patient often describes), *they progress to form granulomas* with or without draining pus *and may result in chronic tarsitis* with multiple chalazia (**Figs 3.8A to C**). Needless to say they are preventable and treatable by *efficient and vigilant management*.

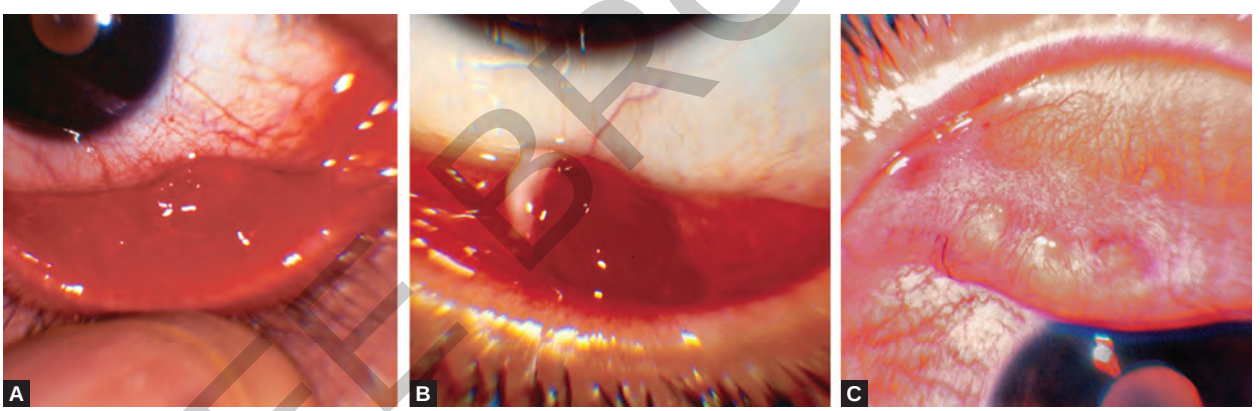

Figs 3.8A to C Granulomas: (A) Subacute; (B) With draining pus; (C) Chronic with multiple pitted scars

Some chalazia (chronic hordeolum internum) grow outward through tarsus and orbicularis and present as cystic swelling (**Fig. 3.9**). These should be excised in toto from horizontal skin incision and sent for histopathology to rule out meibomian carcinoma.



Fig. 3.9 Chalazia grow outward through tarsus and orbicularis as a cystic swelling

JAYPEE BROTHERS



Fig. 3.10 Retention cyst

Similarly try and excise other cystic swellings of the lid in full to avoid recurrence with cellulitis, etc. On histopathological study, most of them prove to be *'retention cyst'* (**Fig. 3.10**).

Lid cysts must not be punctured, aspirated or incised and drained. In case while excising the cyst wall breaks, make extra effort to recognize and remove all the cystic wall membrane, otherwise recurrence with inflammation and possible infection and cellulitis will ensue. Some surgeons have tried intracystal injection of corticosteroids with limited success in tiny cysts, in most cases this leaves firm knotty scarred nodule, which again has to be excised.

Beware of shortcuts to proper procedures to achieve cure of the curable swellings promptly!

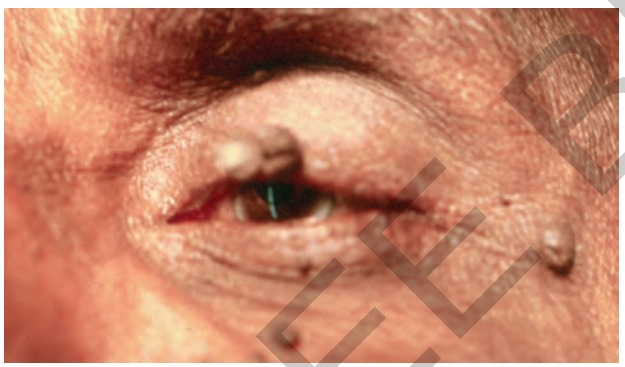

Fig. 3.11 Multiple swelling in the lids

There may be *multiple swellings* in the same or all lids, which may be cystic or solid (**Fig. 3.11**). Plan their complete excision leaving minimal scars merging with skin creases, with or without removal of redundant skin in such a fashion that improves cosmesis. Be a patient and innovative plastic surgeon. Here we prefer general anesthesia and ample time to plan and execute.

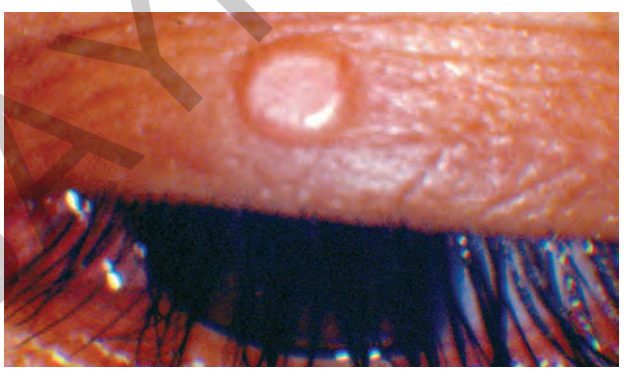

Fig. 3.12 Sebaceous cyst with an umbilicus

Lid swellings should be preferably differentially diagnosed clinically and confirmed histologically. Here is a typical picture of *sebacious cyst* with an umbilicus (**Fig. 3.12**). An elliptical incision around swelling is needed, followed by dissection of cyst, then the muscle and skin gap is minimized to *avoid pitted and broad scar.*

JAYPEE BROTHERS

Never incise a dermoid cyst (**Fig. 3.13**) or even sebaceous cyst. Avoid extensive inflammation, infection and recurrence and bad cosmetic appearance.

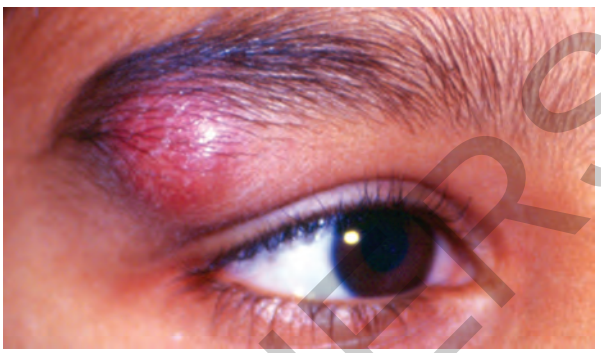

Fig. 3.13 Infected dermoid cyst with cellulitis

Differentially diagnose the swelling due to frontocele (**Fig. 3.14**) and confirm with MRI or CT scan to plan complete removal with curettage of sinus mucosa. When extensive sinus involvement is there, preferably perform operation along with ENT surgeon as a team.

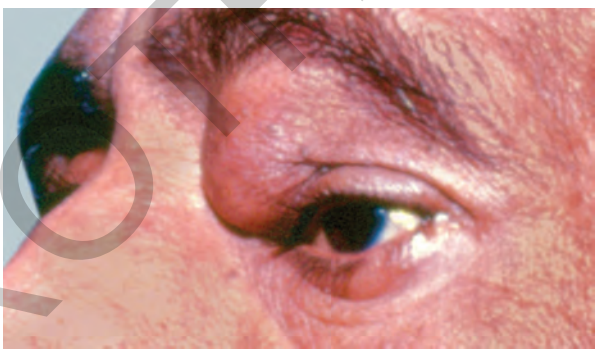

Fig. 3.14 Swelling due to frontocele

Drug-induced allergic dermatitis involving all four lids, should be differentiated from *unilateral herpes eruptions* mostly close to lid margins in early stages, which later on involves the whole of nasociliary nerve skin distribution over the forehead. Drug allergy gives irritation and drying, while herpes zoster eruption is accompanied by pain (**Figs 3.15 to 3.17**).

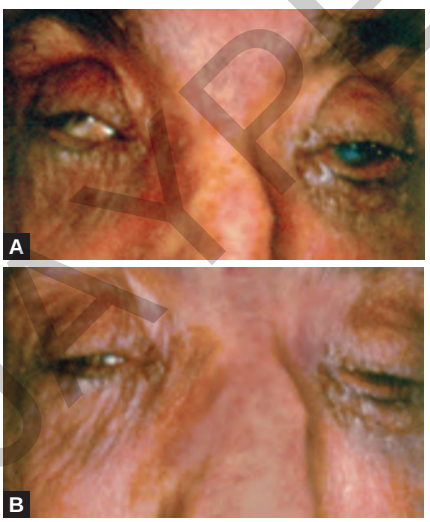

Figs 3.15A and B Drug allergy

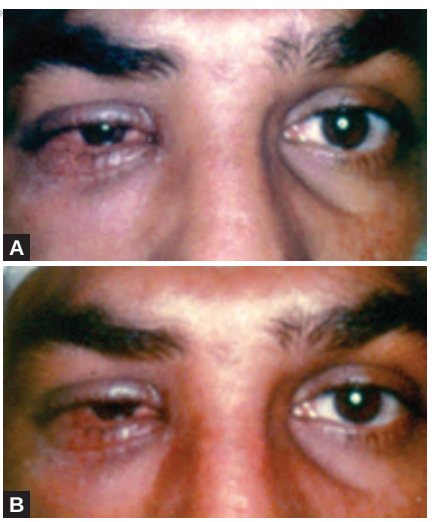

Figs 3.16A and B Herpes zoster

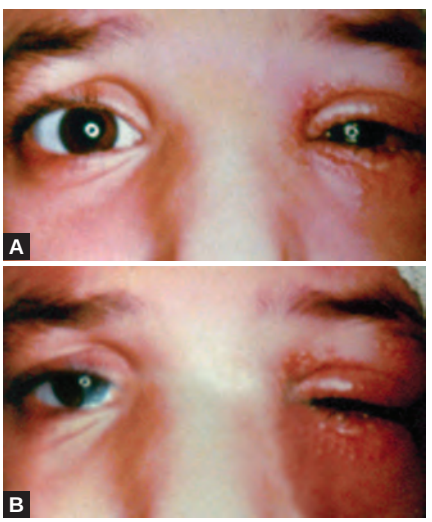

Figs 3.17A and B Herpes simplex

JAYPEE BROTHERS

For *drug allergy,* stop the drug and give local application of steroid cum antibiotics ointment according to severity. *For herpes zoster* systemic antiviral agent use is essential, because it is neurotropic inflammation of the nerve ganglion.

Sometimes herpes simplex vesiculations are also seen over the lids. This requires only local antiviral ointment, because this is a dermatropic viral infection.

Acute lid swelling can be hematoma, abscess or more severe reaction to some insect bite (**Figs 3.18 to 3.20**). Assess the situation from history of patient and the signs and symptoms. Inflammation should be treated medically, but the abscess requires drainage and the suitable systemic antibiotic course, as discussed in Part I. Observe abscess damages the skin badly, hence treat early to prevent residual blemishes.



Fig. 3.18 Lid swelling due to insect bite



Fig. 3.19 Lid swelling due to acute abscess

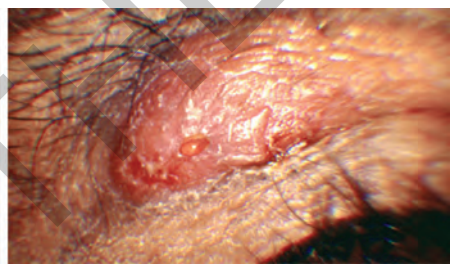

Fig. 3.20 Lid swelling due to chronic abscess

Inflammation of some skin glands (e.g. sebaceous) may be seen from acute to chronic stages, with accompanying adjoining skin reaction and outward proliferation of epithelium as a stalk containing inspissated chalky white glandular secretions (**Figs 3.21A to D**). They assume the shape of an *'epithelial horn'*. There is no evidence of infection, and the inflammation is due to leaked secretions. They must be completely excised with an elliptical incision as described before.

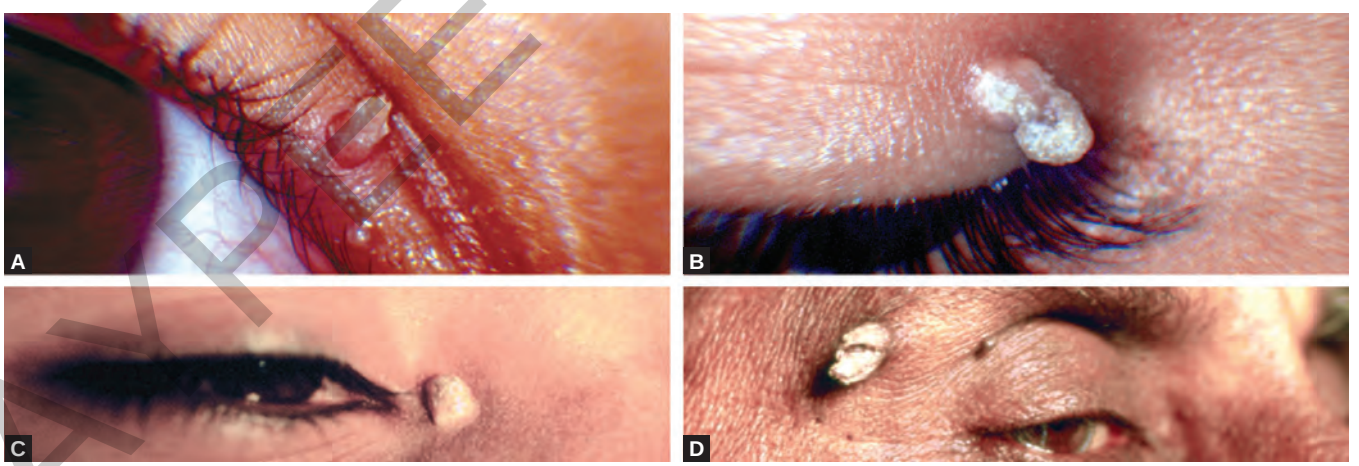

Figs 3.21A to D Inflammation of skin glands appearing as 'epithelial horns': (A) Acute; (B) Subacute; (C and D) Chronic stage

JAYPEE BROTHERS

The more common multiple lids skin blemishes are 'freckles' (light-brown flat marks on the skin) in some individuals, specially those frequently exposed to sunlight and with advancing age, and it may be a family feature. They may be lightened or masked by cosmetic make-up. Some persons may develop *hypertrophy of epithelium as 'tiny skin tags'*, which can be removed by appropriate energy cauterization, which should be applied at the earliest rather than late when they grow bigger. '*Skin tags*' must not be confused with *tiny mulberry like growth of viral origin, called mulluscum contagiosum*. They should also be appropriately cauterized early as they are highly infective and can spread anywhere in the body and to others by contact. Another similar blemish is *'black heads'*, which is accumulation of secretions mixed with dirt in skin pores, which can be easily squeezed out in longstanding cases, but they should be prevented by good hygienic care of the skin daily. Lastly be aware of *early neurofibromata*, which look like skin tags, but are more firm and have deeper subcutaneous growth as well. They should also be removed at the earliest to minimize scar blemishes.

Apocrine hidrocystosis with tiny multiple white cystic swellings over the lids skin, may sometimes assume bigger cystic swelling and are labeled *hydrocystoma* (**Figs 3.22A and B**). Excise this as any other cyst.

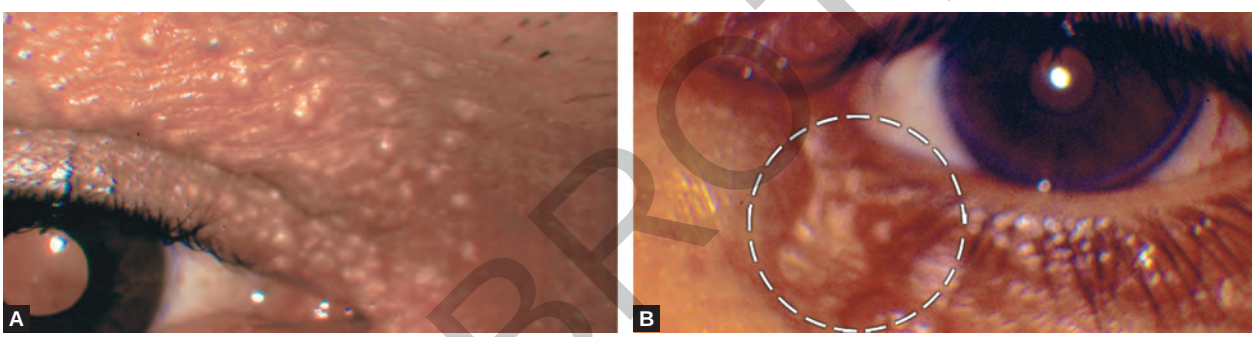

Figs 3.22A and B (A) Apocrine hidrocystosis with tiny multiple white cystic swellings over the lids skin; (B) The hydrocystoma

Solid marginal swellings should be differentially diagnosed by excision biopsy, *to be benign as amelanotic nevus or meibomian tumor* (granuloma or cancer) (**Figs 3.23A and B**). Operative procedures for either case are enunciated with other texts in the book (Chapter 5) as shaving of lesion or shelling out of the swelling.

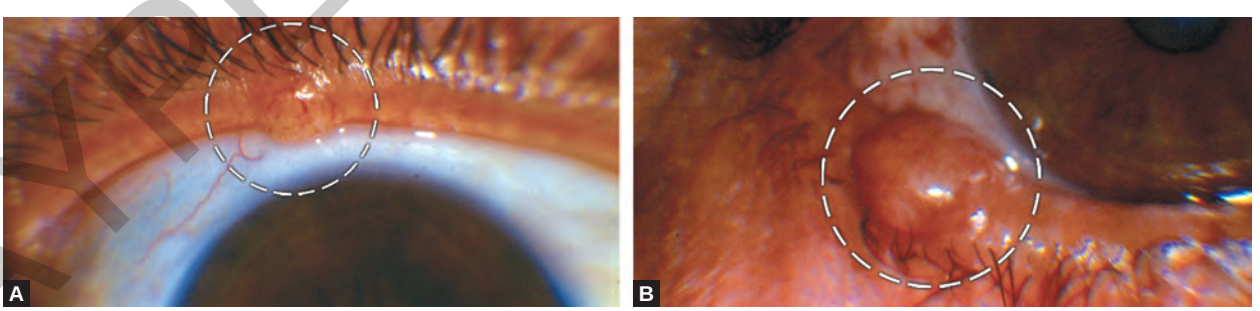

Figs 3.23A and B (A) Amelanotic nevus; (B) Meibomian tumor

JAYPEE BROTHERS

Clinical picture for *early stage of 'meibomian cell carcinoma'* gives suspicion (confirm histologically), but less doubtful in *late stage* (**Figs 3.24A and B**). This requires liberal lid excision of about half the lid and repair by bucket handle procedure (detailed in Chapter 5).

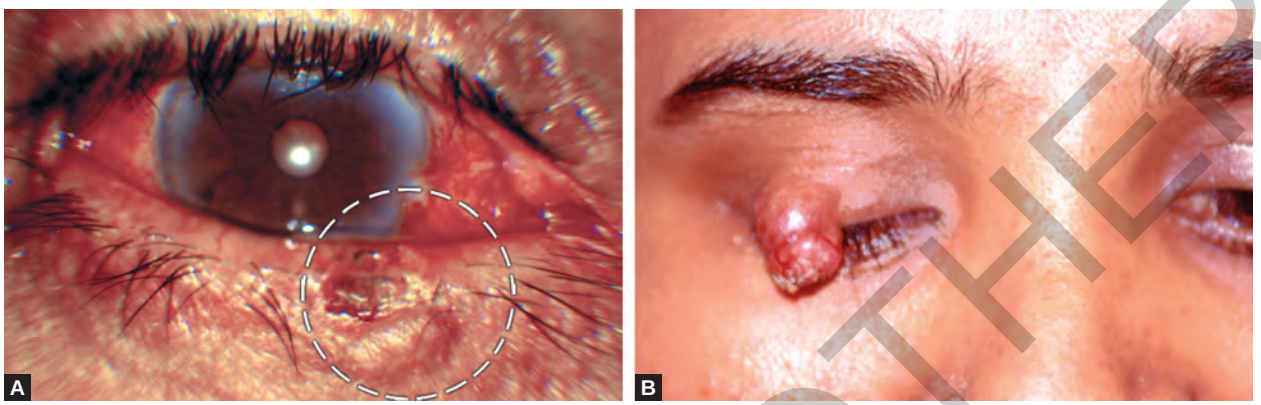

Figs 3.24A and B Meibomian cell carcinoma

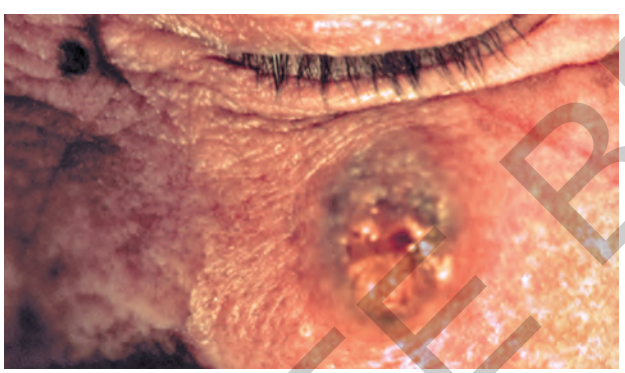

Fig. 3.25 Basal cell carcinoma

This is the typical clinical picture of *'basal cell carcinoma' (rodent ulcer)* and requires liberal superficial lid excision to prevent further local extension (**Fig. 3.25**). Fortunately they are locally invasive but not metastic.

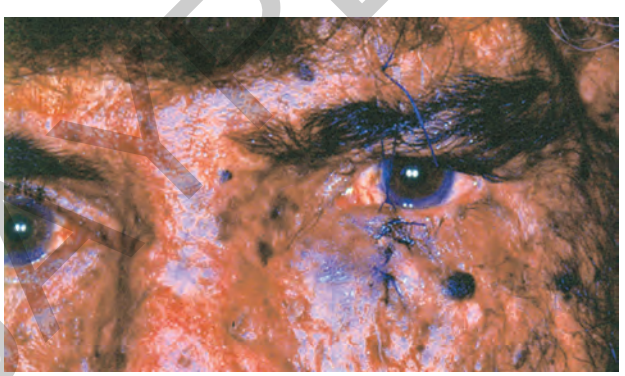

Fig. 3.26 Xeroderma pigmentosa

This is an appearance of very late stage *'xeroderma pigmentosa'*, (**Fig. 3.26**) and its different pigmented or nonpigmented swellings can have varied cancerous diagnoses which cannot be totally eliminated at this stage to give better esthetic appearance of the face or other sun exposed parts of the body. This has hereditary history, *so progeny counseling must be given. To medical science it is a defeat thus far.* Probably even genetic engineering in manifest case is not possible. *We are helpless at present!* We have seen many early stages of the condition progress relentlessly under our observation from childhood to adulthood in the same family despite all precautions for avoiding sun exposure.

JAYPEE BROTHERS

r detailed information on ophthalmology books, visit our website www.jaypeebrothers.com, for detailed information on ophthalmology books, visit our

Manual of
Oculoplasty, Orbitopathies & Dacryology

With an Atlas of personal experiences for observations, analyses, pitfalls and remedies, subject matter presented in this Manual pertains to the second most common type of patients seeking Ophthalmic consultation in various clinics and eye centers. Of course, the first is correction of refractive errors.

- A precious reference Manual for all ophthalmologists, neonatal pediatricians, orbit and plastic surgeons.
- Highlights fundamental concepts and ethical scientific approach.
- Details normal ophthalmic area facies, acceptable variations, the extent of treatable variations and the deformities.
- Deals with congenital, acquired, degenerative, traumatic and iatrogenic defects of orbits and ophthalmoplastic afflictions of eyes and adnexa.
- A subtle sequence of events in pathogenesis of lid margin, lid swellings, dermolipomas, hemangiomas and dacryology have been analyzed and depicted, stressing early and efficient management to resolve the problems without esthetic blemishes.
- Our first visual contact with others immediately reveals unacceptable morphological appearance of the ophthalmic area. The patients and their dear ones demand effective and early amelioration of those defects to the extent possible. The 24 chapters of this manual discuss the prevention and early and late management of most of those cosmetic blemishes.



Subhash Goswamy did his MS (Ophthalmology) in 1964 from All India Institute of Medical Sciences, New Delhi, India. The same year he was selected for a coveted Fellowship of International Brain Research Organization under the Aegis of UNESCO. Under this fellowship, he worked at the University of Strasbourg in France, where his work was awarded with Doctorat-en-Science in 1967. He returned to join the faculty of Dr Rajendra Prasad Centre of Ophthalmic Sciences at AIIMS, New Delhi, India, continuing clinical, research and teaching work till 1978. Thereafter, he worked as a Senior Consultant Ophthalmologist at Narinder Mohan Hospital, Ghaziabad, Uttar Pradesh, India; Sir Ganga Ram Hospital, New Delhi and Ibn Sina Hospital, Kuwait, till October 2005.

Besides the routine Ophthalmic practice and surgery, his special interest in superspecialty of Orbit and Oculoplasty started in 1960 while working in the Eye Department of Christian Medical College at Ludhiana, Punjab, India. Like any ophthalmic surgeon, he continued to endeavor to find pitfalls in surgical procedures and find ways of improving his surgical skills and the resultant better outcome of his management of ophthalmic problems of the patients.

The Manual is the result of vast experience of the author seeing and handling of huge and varied cases of Oculoplasty, Dacryology and Orbital disorders for over 50 years. Their surgical management was done either alone or in collaboration with ENT, neuro, plastic, cancer and maxillofacial surgeons, besides the endocrinologists and chemotherapists. Anomalies in the field of Oculoplasty from day one of birth till old age have been managed and properly documented. The variety of this vast personal documentation is being shared with one and all, with a fervent hope that future surgeons will enhance their clinical acumen for betterment of this clinical superspeciality and improved patient care. A surgeon stops improving unless one continues critical analysis of one's results and skills.

He has already shared parts of his enormous clinical and surgical experiences at various professional fora at National and International conferences, besides teaching departments. He is a fellow of the International Society of Orbital Disorders (ISOD) and life-member of Oculoplastic Society. His presentations of clinical work took him to Singapore, Jakarta, Jogdjakarta, Japan, Istanbul, Morocco, Dubai, Fujairah, Sharjah, France, Germany, Amsterdam, Dhaka, Lahore, over and above, various clinical disciplines and departments of Kuwait and different cities of India.

Shelving
Recommendation
OPHTHALMOLOGY

ISBN 978-93-5152-389-1

Available at all medical book stores
or buy directly from Jaypee Brothers through online shopping
at www.jaypeebrothers.com

JAYPEE BROTHERS
Medical Publishers (P) Ltd.
www.jaypeebrothers.com