hers.com, for detailed information on ophthalmology books, visit our website www.jaypeebrothers.com, for detailed information on ophthalmology books



Includes 3 Interactive
DVD-ROMs
Containing 55 Surgical Videos
Duration 3 hours

International Society of Glaucoma Surgery

ISGS Textbook of
GLAUCOMA SURGERY

Tarek M Shaarawy
Tanuj Dada
Shibal Bhartiya



JAYPEE

Contents

Section 1: Preoperative Evaluation and Overview of Glaucoma Surgical Techniques

1. Preoperative Assessment of a Glaucoma Patient **3**

Sarwat Salim

- Patient Age and Life Expectancy 3
- General Health 4
- Anticoagulation Therapy 4
- Visual Acuity and Refractive Error 4
- Diagnosis 7

2. Intraocular Pressure Reduction Conundrum: Surgery or Drugs? **10**

Shibal Bhartiya, Monica Gandhi, Colin Clement, Parul Ichhpujani, Tarek M Shaarawy

- Ocular Adverse Effects and Complications 13

3. Indications for Trabeculectomy and Tubes: Which to Choose, When and How? **20**

Graham A Lee, Ivan Goldberg

- Trabeculectomy 20
- Ex-Press 27
- Tubes 27

4. Newer Glaucoma Surgical Procedures: How and When to Choose? **34**

Shibal Bhartiya, Parul Ichhpujani

- Introduction and Rationale 34
- Anatomical Basis 34
- Indications and Contraindications 37
- Complications 37
- Scientific Evidence So Far 38
- Ongoing Clinical Trials 40
- Current Positioning of These Procedures versus Gold Standard 40

5. New Surgical Techniques **42**

Marco Nardi, Francesco Nasini, Paolo Martinelli

- The Surgical Approach 42

6. Criteria for Surgical Success **48**

Shibal Bhartiya, Ivan Goldberg

- Types of Success 48
- Nonintraocular Pressure Criteria of Surgical Success 49

Section 2: Lasers in Glaucoma Surgery

7. Selective Laser Trabeculoplasty 53

Laura Beltran-Agullo, Jason Cheng, K Sheng Lim

- Mechanism of Action 53
- Indications and Laser Efficacy 54
- Long-term Success 55
- Laser Protocol 55
- Repeated Selective Laser Trabeculoplasty 55
- Predictive Factors for Laser Success 56
- Complications 56
- Technique 56

8. Lasers in Angle Closure Glaucoma 60

Chelvin CA Sng, Joel Aduan, Maria Cecilia Aquino, Paul Chew Tec Kuan

- Introduction and Anatomical Basis 60
- Laser Peripheral Iridotomy 60
- Argon Laser Peripheral Iridoplasty 62

9. Transscleral Diode Cyclophotocoagulation 65

Shibal Bhartiya, Parul Ichhpujani, Dewang Angmo

- Mechanism of Action 65
- Pearls and Pitfalls 68
- Complications 68

10. Endoscopic Cyclophotocoagulation 71

Colin I Clement, Philip A Bloom

- Patient Selection 71
- Surgical Technique 71
- Operative Technique 72
- Postoperative Care 74
- Treatment Outcomes 74
- Combined with Cataract Surgery as A Primary Surgical Treatment 75
- Comparison to Transscleral Cyclophotocoagulation 76
- Comparison to Trabeculectomy 77
- Comparison to Tube-Shunt Surgery 77
- Complications 77

Section 3: Trabeculectomy: Technique and Rescue Operations

11. Trabeculectomy 83

Peng T Khaw, Peter Shah, Freda Sii, Joseph Abbott

- Anesthesia 83
- Informed Consent 84
- Preoperative and Intraoperative Therapeutics 84
- Surgical Technique 85
- Postoperative Management 93
- Complications 96
- Postoperative Complications 98

12. Ex-PRESS™ Mini Glaucoma Shunt: Surgical Technique **104**
Jeffrey R SooHoo, Leonard K Seibold, Malik Y Kahook
- Anatomy 105
- Indications and Contraindications 105
- Surgical Steps 105
- Results 106
- Complications and Management 107
- Pearls and Pitfalls 107

13. Bleb Management **110**
Thomas Edwards, Jonathan Goodfellow, Jonathan Crowston, Michael Coote
- Topical Steroid 110
- Bleb Massage/Releasable Suture Removal 111
- Bleb Needling and 5-Fluorouracil Injection 111
- Complications 112

14. Resurrecting the Failing Filtering Bleb **114**
Sung Chul Park, Robert Ritch
- Filtering Bleb Appearance and Function 114
- Risk Factors for Filtration Failure 116
- Signs of Filtration Failure 116
- Management of Filtration Failure 119
- Trephination 122

15. Releasable Sutures in Trabeculectomy **128**
Parul Ichhpujani, Shibal Bhartiya
- Mechanism of Action 128
- Techniques 128
- How to Use One or Two Releasable Sutures? 132
- When to Remove the Releasable Suture? 132
- How to Remove the Releasable Suture? 132
- What to Look for after Suture Release? 133
- Complications 133

16. Repeat Trabeculectomy **135**
Ahmed M Abdelrahman, Yasmine El Sayed
- Subsequent Management Options after Failure of the Initial Trabeculectomy 135
- Risks and Technical Considerations during Repeat Trabeculectomy 136
- Postoperative Treatment 138
- Outcomes of Repeat Trabeculectomy 139

17. Combined Cataract and Glaucoma Surgery **142**
Oscar Albis-Donado, Giovanna Casale-Vargas
- Preoperative Evaluation 143
- Indications 143
- Cataract Surgery 144
- Combined Trabeculectomy and Cataract Surgery 144

18. Modulation of Wound Healing **153**
Colin I Clement, Dilani Siriwardena, M Francesca Cordeiro
- Modulation of Wound Healing 153

19. Late Hypotony Post-Trabeculectomy **167**
Tanuj Dada, Dewang Angmo
- Risk Factors 167
- Etiology and Pathophysiology 169
- Pathophysiology 171
- Preventive Measures 171

Section 4: Nonpenetrating Glaucoma Surgery

20. Nonpenetrating Deep Sclerectomy, Viscocanaloplasty and Ancillary Goniopuncture **181**
Sangtam Tiakumzuk, Mermoud André
- Anatomical Basis 181
- Indications and Contraindications 182
- Surgical Steps 183
- Results 187
- Complications and Management 187
- Ancillary Goniopuncture 188

21. Implants in Deep Sclerectomy **190**
Oana Stirbu, Susana Duch Tuesta
- Introduction and Anatomical Basis 190
- Indications 192
- Contraindications 192
- Surgical Steps 192
- Postoperative Care 196
- Complications and Management 196
- Pearls and Pitfalls 197

22. Carbon Dioxide Laser-Assisted Deep Sclerectomy **198**
Amr Aref, Tarek M Shaarawy
- Anatomical Basis 199
- Surgical Steps 200
- Results 201
- Complications and Management 201
- Pearls and Pitfalls 201

23. Canaloplasty with Suture Stenting **203**
Matthias C Grieshaber
- Technique 203
- Patient Selection 205
- Intraoperative Testing of the Outflow System 206
- Clinical Results 207
- Conclusions and Outlook 207

24. Complications in Canaloplasty **209**

Gabor B Scharioth

- Typical Intraoperative Complications of Deep Sclerectomy 209
- Typical Intraoperative Complications of Canaloplasty 210
- Typical Postoperative Complications of Canaloplasty 213

Section 5: Glaucoma Drainage Devices

25. Ahmed Glaucoma Valve **217**

Kleyton Barella, Vital Paulino Costa

- Introduction and Anatomical Basis 217
- Indications 217
- Contraindications 219
- Surgical Steps 219
- Results 219
- Complications and Management 221

26. Complications with the Ahmed Valve **223**

Oscar Albis-Donado, Sonia Corredor-Casas, Rafael Castaneda-Diez

- Complications and Their Management 223
- Intraoperative Complications 223
- Early Postoperative Complications 228
- Perivalvular Fibrosis and the Hypertensive Phase 230
- Histopathology 231
- Other Late Postoperative Complications 232
- Strabismus and the Ahmed Valve 233

27. Baerveldt Glaucoma Implant **237**

Leonard K Seibold, Jeffrey R SooHoo, Malik Y Kahook

- Introduction and Anatomical Basis 237
- Indications 238
- Contraindications 238
- Surgical Steps 238
- Results 242
- Complications and Management 243
- Pearls and Pitfalls 244

28. Molteno Glaucoma Drainage Device **245**

Jonathan Goodfellow, Thomas Edwards, Jonathan Crowston, Michael Coote

- Indications 246
- Surgical Technique 246
- Complications: Prevention and Management 248

Section 6: Pediatric Glaucoma

29. Surgical Management for Childhood Glaucoma–Part 1 **253**
Velota CT Sung
- Angle Surgeries 253
- Filtering Surgeries 255
- Cyclodestructive Procedures 258

30. Surgical Management for Childhood Glaucoma–Part 2 **261**
Velota CT Sung
- Surgical Outcomes 261
- The Baerveldt Tube Implant with Mitomycin C and Donor Sclera Graft Procedure 262
- Management of Complications 264

31. Illuminated Microcatheter-Assisted Circumferential Trabeculotomy for Primary Congenital Glaucoma **269**
Tanuj Dada, Shikha Gupta
- Principle of Congenital Glaucoma Surgery 269
- Surgical Options for Congenital Glaucoma 269
- Newer Surgical Options 271
- Microcatheter-assisted Circumferential Trabeculotomy 271
- Surgical Technique 271
- Indications 273
- Contraindications 274
- Intraoperative Problems 274
- Postoperative Treatment 274
- Review of Literature 274
- Our Results 274
- Limitations and Advantages 276

Section 7: Special Situations

32. Lens in Angle-Closure Glaucoma **281**
Loon Seng Chee, Dawn Lim Ka-Ann, Anna Marie Tan Wee Tien, Joel Aduan, Paul Chew Tec Kuan
- Treatment of Primary Angle-closure and Primary Angle-closure Glaucoma 281
- Surgical Pearls 283
- Postoperative Management 286
- Complications 287

33. Goniosynechialysis **288**
Rahat Husain, Tin Aung
- Indications 288
- Contraindications 288
- Surgical Steps 289
- Results 289
- Complications and Management 290
- Pearls and Pitfalls 290

34. Postpenetrating Keratoplasty Glaucoma **292**

Murali Ariga, Praveena C, Malarkodi P, Nivean M, Srinivas K Rao

- Definition 292
- Incidence 292
- Clinical Features 293
- Mechanisms of Glaucoma Postpenetrating Keratoplasty 294
- Management 294
- Trabeculectomy 297

35. Glaucomatous Complications of Refractive Surgery **302**

Gonzalo Muñoz, Moza Dekhain, José I Belda Sanchís, Daniel Elíes

- Glaucoma Associated with Phakic Intraocular Lens Implantation 302
- Glaucoma after Laser-assisted in Situ Keratomileusis 306

36. Management of Glaucoma Post Vitreoretinal Surgery **309**

Rathini Lilian David, Lingam Vijaya, Janvi Shah

- Glaucoma after Scleral Buckling Procedures 309
- Glaucoma after Intravitreal Gas Injection 309
- Glaucoma after Silicone Oil Injection 310
- Indications for Trabeculectomy 311
- Indications for Glaucoma Drainage Devices 311
- Contraindications for Antiglaucoma Surgery 311
- Surgical Technique 311
- Results 312
- Complications and Management 315
- Pearls and Pitfalls 315

37. Management of Neovascular Glaucoma **316**

Syril Dorairaj, Michael W Stewart, Sribhargava Natesh, Christopher C Teng

- Introduction and Anatomical Basis 316
- Surgical Treatment to Reduce Intraocular Pressure 317
- Tube Shunts/Drainage Devices 318
- Laser Cyclophotocoagulation 320
- Results 320
- Complications 320
- Pearls and Pitfalls 322

38. Phacoemulsification in Eyes with Previous Glaucoma Filtering Surgery **324**

Tanuj Dada, Dewang Angmo, Shikha Gupta

- Preoperative Evaluation 325
- Intraoperative Measures 326
- Postoperative Considerations 328
- Outcomes of Phacoemulsification in Eyes with a Filtering Bleb 329
- Influence of Cataract Extraction on the Visual Fields 332
- Influence of Cataract Extraction on the Outcome of Hypotony Following Trabeculectomy 332

Section 8: New Microsurgical Devices in Glaucoma Surgery

39. Suprachoroidal Shunts **337**

Wanda D Hu, Marlene R Moster

- Anatomical Basis 337
- Indications and Contraindications 339
- Surgical Steps 339
- Results 342
- Complications and Management 343
- Pearls and Pitfalls 344

40. Biodegradable Collagen Implants in Trabeculectomy **346**

Tanuj Dada, Parul Ichhpujani, Dewang Angmo

- What is the Use of Collagen Implants in Filtering Surgery? 347
- Types of Collagen Implants 347
- Surgical Technique 347
- Surgical Steps 347
- Postoperative Care 349
- Scientific Evidence on the Use of Collagen Implants 350
- Complications 351

41. New Glaucoma Surgical Alternatives: Classification and Future Horizons **353**

Tarek M Shaarawy, MM Moschos, MB Sherwood

- Terminology 353
- Classification 353
- Results 359
- Miniaturized High-intensity Focused Ultrasound Device 363

Index *367*

3 Indications for Trabeculectomy and Tubes: Which to Choose, When and How?

Graham A Lee, Ivan Goldberg

JAYPEE BROTHERS

TRABECULECTOMY

The trabeculectomy procedure drains aqueous through a channel created beneath a scleral flap and into a bleb. It aims to reduce and stabilize intraocular pressure (IOP) at or below target.

Indications

It is required when maximum medical or laser therapy fails to lower IOP to target levels. It is indicated when the threat to sight by *not* operating exceeds the threat by operating.

Contraindications

- Trabeculectomy is unlikely to succeed when the conjunctiva is scarred: the bleb will not form and the scleral channel will close. Inflammation is a risk factor for scarring.
- Aphakia is a relative contraindication as there is a reduced blood-eye barrier to proinflammatory proteins and hence increased scarring. Vitrectomy is required to prevent vitreous incarceration into the sclerostomy.
- Extensive scleromalacia prevents the creation of an adequate scleral flap.
- If safe for life, cessation of anticoagulants is critical to reduce bleeding.

Surgical Steps (Trabeculectomy with Mitomycin C)

1. Monitored local anesthesia with longer acting agent (e.g. ropivacaine 1%). Avoid adrenaline to minimize mydriasis. A general anesthetic may benefit high-risk cases, e.g. only eye, long eyes more than 26 mm or uncooperative patients (e.g. children, intellectually impaired, dementia).
2. Consider conjunctival vasoconstriction with apraclonidine 1% or brimonidine 0.2% to reduce conjunctival bleeding.
3. Betadine prep, dry eyelid skin then drape. Steri-strip lashes out of the field if necessary.
4. Use a speculum that doesn't put pressure on the globe, doesn't catch the stitch and provides good exposure of the conjunctival fornices.
5. Use a 7/0 Vicryl or silk for a corneal traction suture to provide superior limbal exposure (Fig. 3.1).
   - Advance the tip rather than follow curve of needle, needs to be at least half depth to avoid cheese-wiring through the cornea. If perforation occurs,

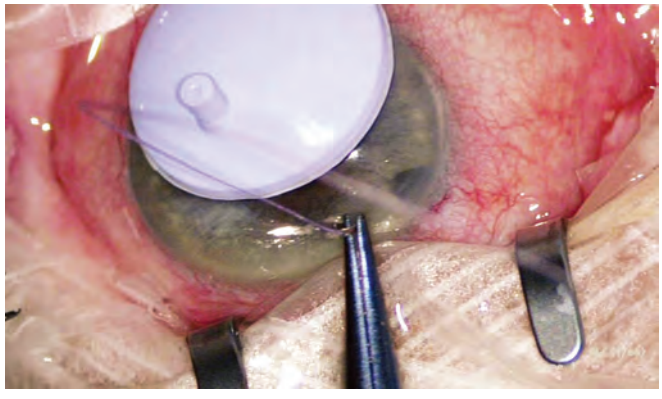

Fig. 3.1: Corneal traction suture

replace in an adjacent area of cornea. Use non-toothed forceps such as Pierce, Fechtner to avoid trauma to conjunctiva whilst providing counter traction.
   - Alternatively, an Ong speculum is specifically designed to roll the globe downward.
6. Cover cornea with light protection shield. Attach traction suture to drape with an artery forceps.
7. Open the most anterior edge of conjunctiva with semiblunt nose Westcott scissors and non-toothed forceps, e.g. Pierce, Fechtner
   - Position away from previous surgery if redo-trabeculectomy or superior cataract wound. Avoid superior scleral extracapsular cataract extraction (ECCE) wounds if possible as scarred tissue easy to buttonhole and difficult to close.
   - Make flap smaller if thin conjunctiva.
8. Very carefully dissect plane between Tenon's capsule and sclera, avoiding buttonholing of the conjunctiva (Fig. 3.2).
   - If very thin tissues, avoid extensive dissection and be extremely careful to handle tissues minimally. It is essential to get into the right plane directly onto sclera.
   - It can hydrate Tenon's with balanced salt solution (BSS) on a water bottle cannula to thicken tissue (Fig. 3.3).
   - Dissect either side of superior rectus.
   - Clean episcleral tissue off sclera with rounded blade, e.g. Beaver.
   - Use wet-field cautery sparingly on low power, e.g. 20, to avoid excessive charring of the tissues (reduces proinflammatory necrotic tissue).
9. Prepare pledgets for mitomycin C (MMC). These can be cut from cellulose or polyvinyl alcohol (PVA) microsponges. Alternatively, a PVA corneal protection shield can be cut in half.
10. Add 1 mL of MMC into a disposable container. The concentration can be altered by adding appropriate volumes of sterile water. The dose is determined by the state of the conjunctiva and Tenon's capsule.
    0.1 mg/mL (0.01%): Thin
    0.2–0.3 mg/mL (0.02–0.03%): Standard normal
    0.3–0.4 mg/mL (0.03–0.04%): Thick, inflamed or scarred
    - Squeeze out excess and leave on side of container. This reduces MMC exposure to unintended areas of the conjunctiva.
    - Alternatively, consider using a 30 gauge needle on a tuberculin syringe to inject 10 µg of MMC in 0.1 mL (0.01%) into sub-Tenon's capsule 8–10 mm superior to the limbus and tease the injected MMC bolus toward but not right onto the limbus.
11. Measure and mark a 3 mm posterior and 4 mm across scleral flap. The size and shape of the flap varies according to operator preference.
    - Variations include triangular, rectangular, trapezoidal, semicircular and "W" shapes.
    - Make scleral flap smaller if risk of overdrainage, e.g. if thin conjunctiva.
    - Cut back edge of scleral flap with calibrated diamond knife 270–300 µ thick (Fig. 3.4).
    - Tunnel forward into peripheral cornea just anterior to the palisades of Volk with a crescent blade keeping to the same depth (Fig. 3.5). Need to avoid cutting too deep hence entering the anterior chamber or cutting too shallow resulting in a thin or free flap.
    - If flap complications occur, the trapdoor can be sutured closed and refashioned in an adjacent area.

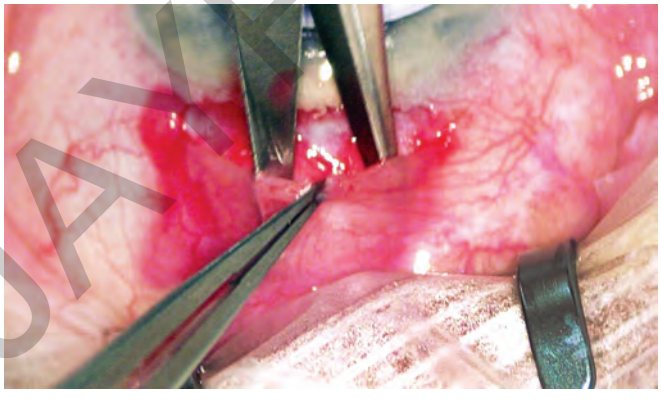

Fig. 3.2: Conjunctival dissection

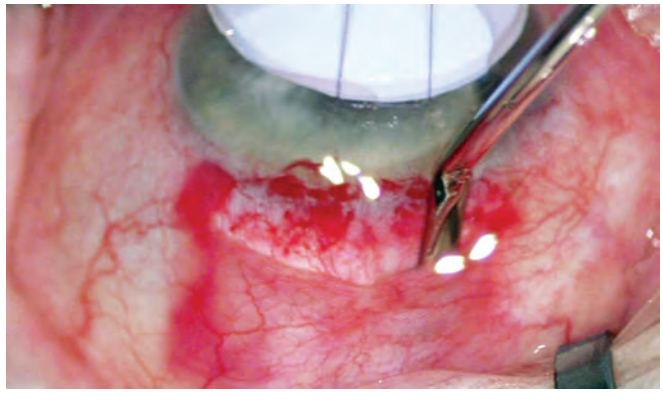

Fig. 3.3: Tenon's hydration

JAYPEE BROTHERS

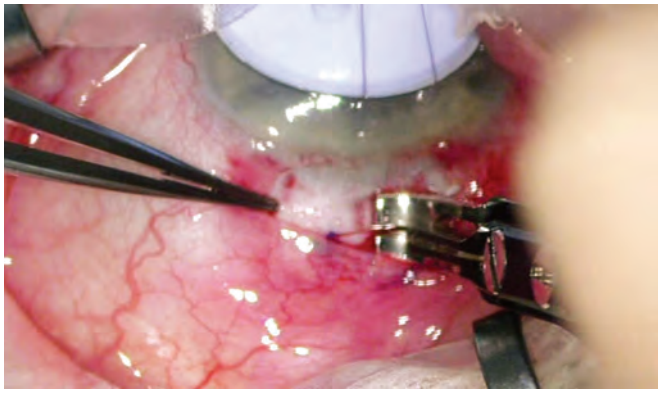

Fig. 3.4: Scleral flap with calibrated diamond knife

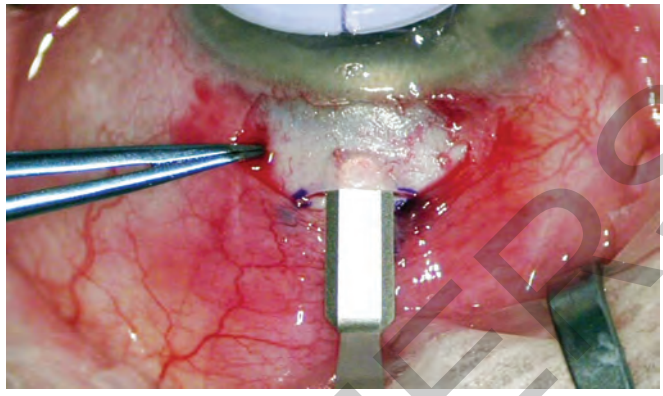

Fig. 3.5: Crescent blade

If premature entry of the anterior chamber occurs, the anterior chamber can be reformed with an ophthalmic viscoelastic device (OVD) with care to avoid entry of MMC during application.

- Use a diamond knife (Fig. 3.6) or equivalent or Vannas scissors to cut the sides of the trapdoor, avoiding cutting any deeper than the scleral bed, otherwise may damage underlying choroid.
- Sides are cut anteriorly to just behind the scleral limbus to encourage backward flow of draining aqueous.
- There is often a collector channel if the flap is created at 12 o'clock. This needs to be gently cauterized otherwise can lead to postoperative bleeding (Fig. 3.7). If bleeding occurs around the flap, it is best to avoid cautery too close to the edge as this can lead to shrinkage of the sclera and potential difficulties in flap closure.

12. If MMC has not been injected, hold conjunctival edge with non-crushing forceps, clamp or conjunctival retractor (Fig. 3.8).
    - Avoid tearing of the conjunctiva
    - Place three pledgets posteriorly and either side of the scleral flap and one under the flap. Protect the conjunctival edge from exposure to the MMC by drying any excess away.
    - The exposure time of 30 seconds to 3 minutes can vary according to the state of the conjunctiva or Tenon's. Most effect on the fibroblasts occurs in the first 1 minute.
    - After removal of pledgets, washout copiously with BSS.
13. Use a diamond knife to cut reverse stepped one-third corneal thickness troughs perpendicular and anterior to the sides of the trapdoor (Fig. 3.9). Avoid cutting too deep as recovery of the suture postoperatively is more

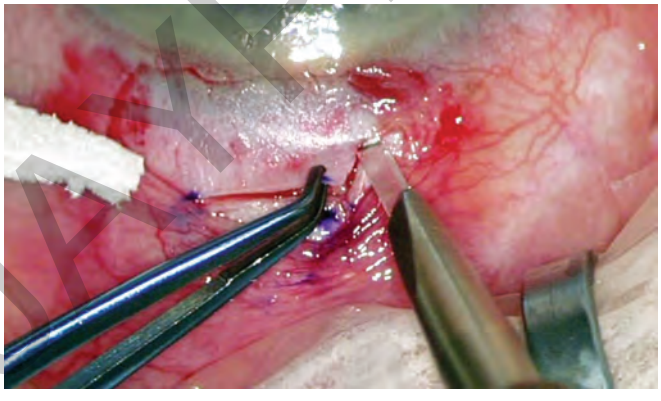

Fig. 3.6: Diamond blade

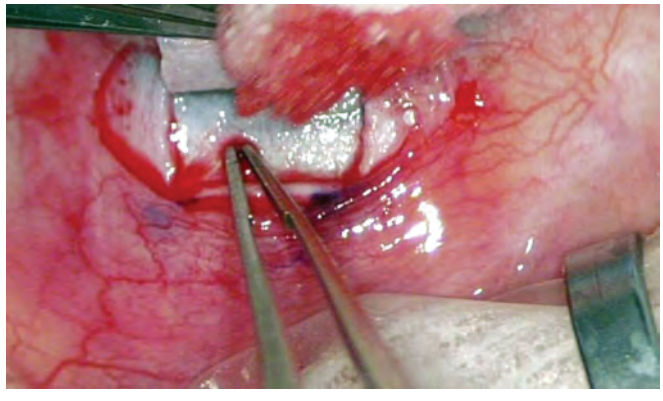

Fig. 3.7: Collector channel

JAYPEE BROTHERS

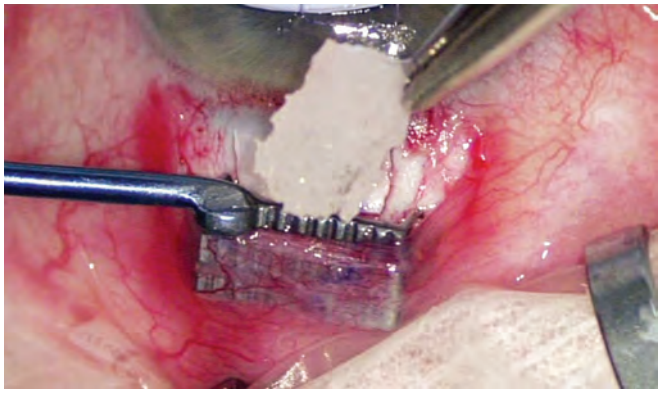

Fig. 3.8: Mitomycin C (MMC) pledgets

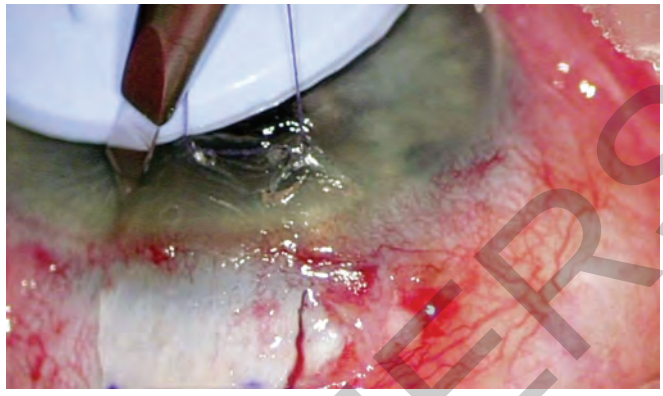

Fig. 3.9: Corneal troughs

difficult and there is a risk of a full thickness corneal incision into the corneal extent of the scleral trapdoor dissection.

14. Preplace 10/0 nylon-buried releasable sutures:
    - Starting just behind limbus, pass suture to emerge in pre-incised corneal trough (Fig. 3.10). Hold needle lower down the shaft than usual.
    - Pass needle back into trough, through cornea into lamella of flap.
    - Emerge on top of flap and pass into full-thickness corner of scleral flap at 45° (Fig. 3.11) and into the corresponding corner of the scleral bed (Fig. 3.12). Avoid buttonholing the overlying conjunctiva with the tip of the needle.
    - Leave a small loop of suture on top of the trapdoor and cut suture end long (Fig. 3.13).
    - Place suture ends away to side.
    - Repeat for other side of trapdoor.
    - Keep flap moist with BSS to prevent shrinkage.
15. Release traction suture or ease speculum opening to avoid pressure on the anterior chamber.
16. Use a 15° blade to make an oblique inferotemporal paracentesis over iris to avoid risk of lens damage. This allows access to reform the anterior chamber with BSS if required. Alternatively, an anterior chamber maintainer infusing BSS can be placed in eyes at risk from hypotony, e.g. buphthalmos, high myopia, anterior megalophthalmos.
17. Enter anterior chamber with a 15° or 30° blade in one smooth action starting at one end under the scleral flap whilst holding it up with non-toothed forceps (Fig. 3.14).
    - Avoid cutting the preplaced nylon sutures.
    - Avoid too posterior entry of the anterior chamber as there is risk of choroidal hemorrhage and vitreous prolapse.
18. Create sclerostomy with a punch, e.g. Khaw (Fig. 3.15), Kelly, Luntz-Dodick
    - Need to grab lip of Descemet's and bite definitively, at 90° to Descemet's.
    - Assistant clears corneal tissue from the jaws of the punch with each bite.

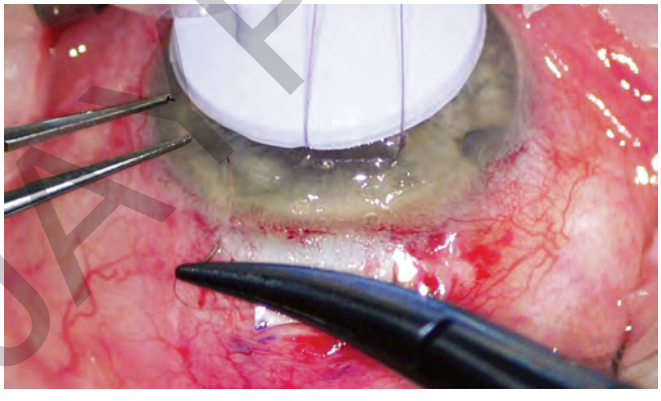

Fig. 3.10: Preplaced 10-0 nylon

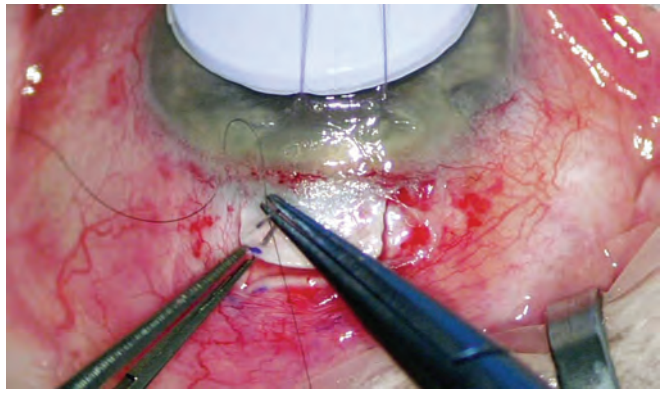

Fig. 3.11: 10-0 nylon in scleral flap

JAYPEE BROTHERS

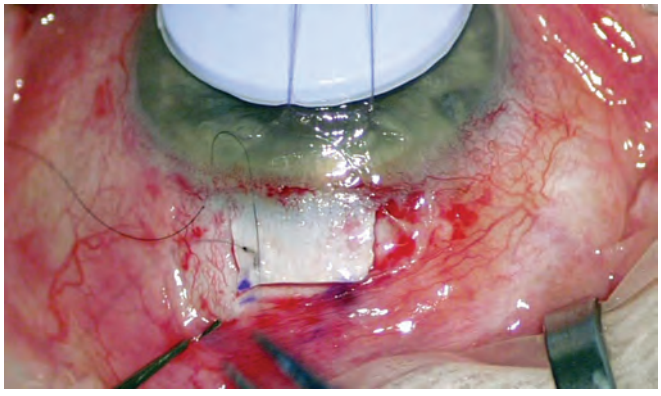

Fig. 3.12: 10-0 in scleral bed

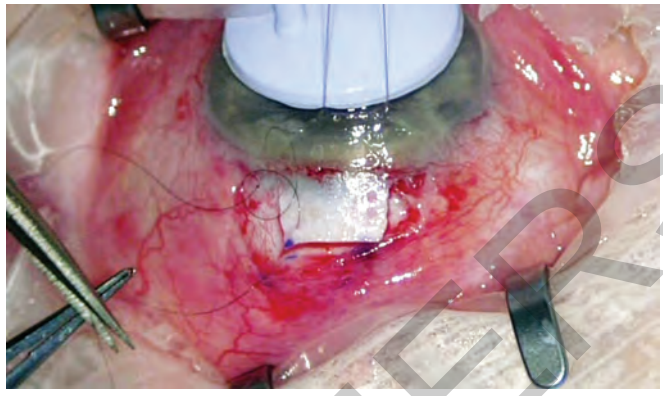

Fig. 3.13: Cut 10-0 nylon long

- Size of sclerostomy approximately 1–1.5 mm, i.e. 3 bites with Khaw, 1–2 bites with Kelly.

19. Grasp peripheral iris with toothed Colibri forceps and cut full-thickness iridectomy with Vannas scissors.
    - If the iris is cut tangential to the limbus, the iridectomy will be broad based (preferred) rather than if cut perpendicularly, resulting in a narrower and longer iridectomy (that can result in diplopia and predispose to iris entrapment in ostium).
    - Iris generally will not bleed if eye has adequate pressure. If bleeding occurs, then a fine tip retinal cautery can be useful for hemostasis.
    - Iridectomy is not always required particularly if the eye is pseudophakic and the anterior chamber deep. If the iris presents to the sclerostomy, then iridectomy is indicated to prevent iris incarceration into the sclerostomy.
20. Stroke iris back into position by massaging peripheral cornea. Reform the anterior chamber using the water bottle cannula and BSS via the sclerostomy or via the paracentesis.
21. Tie the 10/0 nylon preplaced sutures with a 3 throw loop (Fig. 3.16).
    - Avoid leaving loops too long as more difficult to remove the suture postoperatively as gets caught on Tenon's tissue.
    - Pull suture tight so that trapdoor sits flush in scleral bed.
    - Egress of fluid through the trapdoor needs to be minimal so that the anterior chamber remains formed. The drainage can be tested by pushing gently on the sclera behind the flap.
    - Cut ends long, but avoid protrusion beyond the conjunctival edge.
    - If the trapdoor is leaking excessively, then further releasable sutures can be placed at the posterior and/or side edges (Fig. 3.17). This can particularly occur in young tissues.

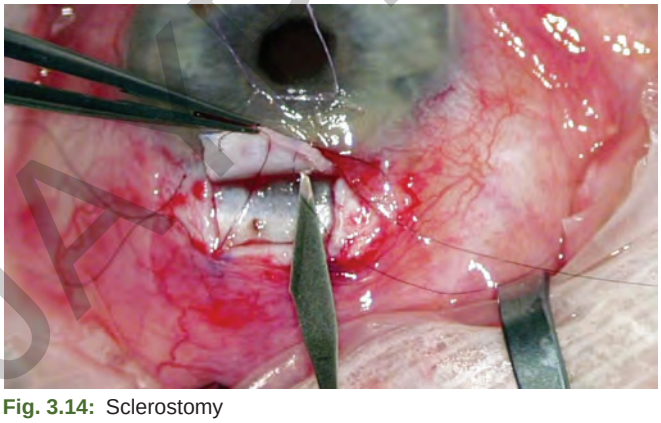

Fig. 3.14: Sclerostomy

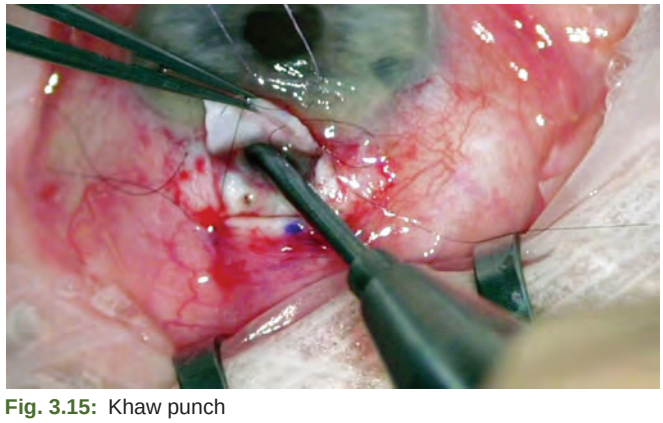

Fig. 3.15: Khaw punch

JAYPEE BROTHERS

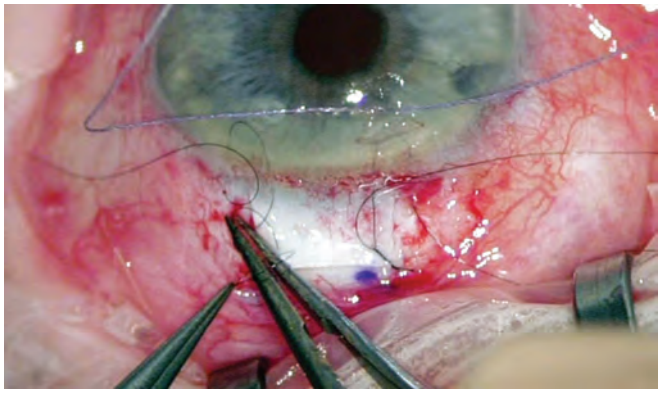

Fig. 3.16: Triple throw knot

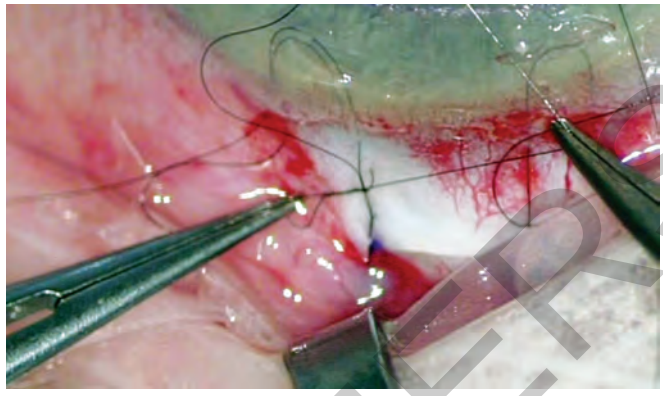

Fig. 3.17: Extra trapdoor suture

22. Closure of conjunctival edge with 10/0 nylon or 9/0 Vicryl. This is a critical part of the operation and needs to be done carefully to achieve a water-tight seal. This step can take as long again as the rest of the trabeculectomy.
    - Reposition conjunctiva to original position with caution to avoid tearing.
    - Pass suture into clear cornea, tangential to limbus (Fig. 3.18).
    - Purse-string conjunctival edge: Three passes
    - Knot 3-1-1 is tied so that knot is buried sub-conjunctivally and hence is comfortable for patient.
    - Cut ends very short with a 15° blade, making sure the ends are buried (Fig. 3.19).
    - Place end-to-end mattress sutures along scleral limbal edge, making sure knots are buried subconjunctivally (Figs 3.20 and 3.21).
      - Avoid cutting the underlying scleral flap sutures—if this occurs, the flap may need to partially reopened to replace the releasable suture.
      - Avoid multiple passes through the conjunctival edge as there is a risk of leak from the needle puncture sites.
      - Avoid cautery of the conjunctiva particularly if the tissues are very thin.
      - Avoid toothed forceps as risk of buttonhole—tying forceps are useful.
    - Repeat purse string suture on the other wound corner (Fig. 3.22).
      - If the conjunctiva is too tight to be closed, the speculum can be loosened or if that is not successful, then a subconjunctival (not full thickness through Tenon's) relieving incision can made high in the fornix.
      - Alternatively, use a running limbal horizontal mattress.
23. Reform the anterior chamber. Check wound is Seidel negative with fluorescein 2% (Fig. 3.23).
24. Inject subconjunctival antibiotic and steroid inferiorly.
25. Carefully remove traction suture. Eyepad and shield.
26. Rest semi-upright overnight.

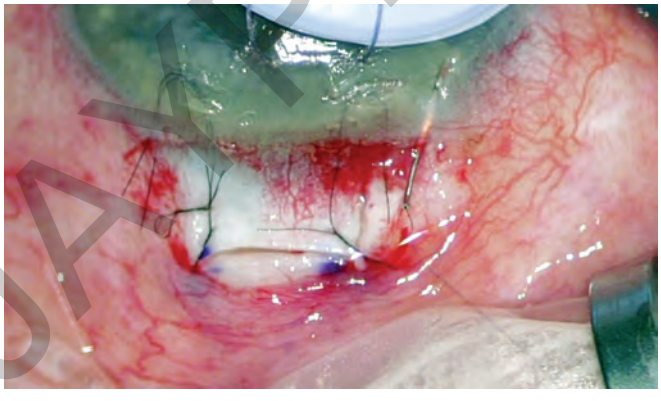

Fig. 3.18: Purse string suture

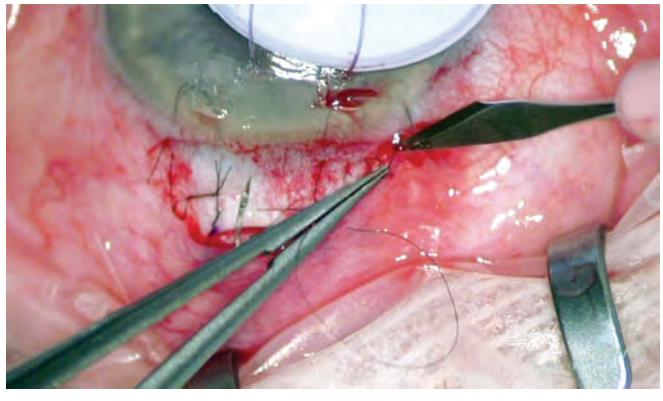

Fig. 3.19: Cutting ends short

JAYPEE BROTHERS

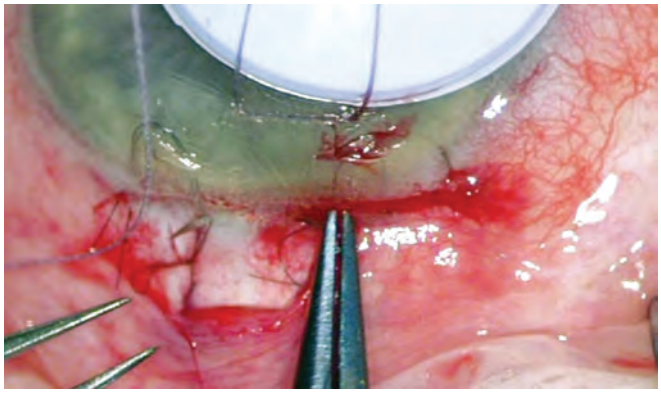

Fig. 3.20: Horizontal mattress

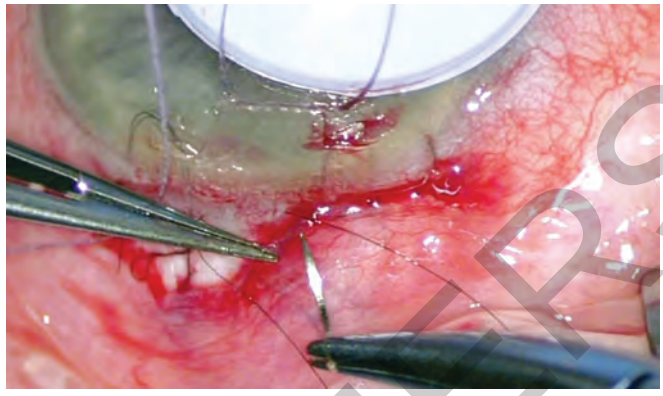

Fig. 3.21: Horizontal mattress conjunctival pass

27. Use postoperative topical steroid and antibiotic tapering dose for 4–6 months.
28. Postoperative management critical in the first 3–4 weeks.
    - Patient may require 2–3 daily review to monitor IOP and modify flow via the trapdoor as appropriate.

Results: The key to success is the creation of a diffuse bleb with normal conjunctiva. The IOP should be at stable target level. Glaucoma medication may be required to maintain IOP.

Pearls and Pitfalls

- Patient must stop anticoagulation medications including anti-inflammatories, fish oil at least 1 week prior to surgery if it is safe for him or her to do so.
- Need to choose the right patient—preoperative assessment of conjunctiva.
- Patients need to have realistic expectations that trabeculectomy is designed to lower IOP rather than improve the vision and to know ahead of the operation that vision may fluctuate at a suboptimal level for some months.
- Ensure ideal operating conditions to maximize outcomes.
- Postoperative follow-up as important as the surgical procedure.

Comment: Trabeculectomy is our preferred drainage operation requiring the right conditions for maximal success.

Augmentation

Trabeculectomy often needs augmentation as there is a tendency for the body to heal over the drainage site. The options are 5-fluorouracil (5-FU) and MMC. Traditionally, 5-FU is reserved for lower risk of scarring cases and MMC for higher risk cases, however, the dose and timing are modifiable according to the case (Table 3.1).

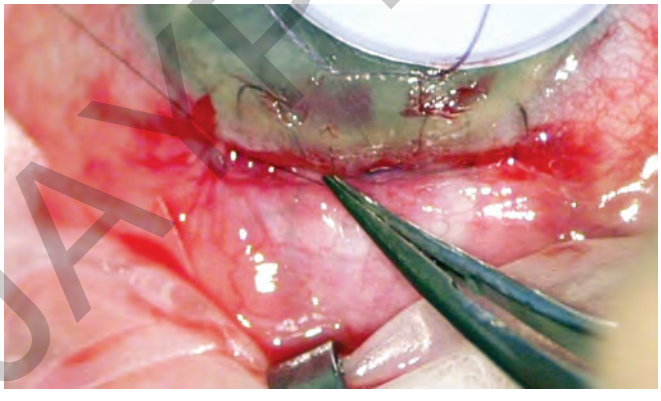

Fig. 3.22: Opposite purse string

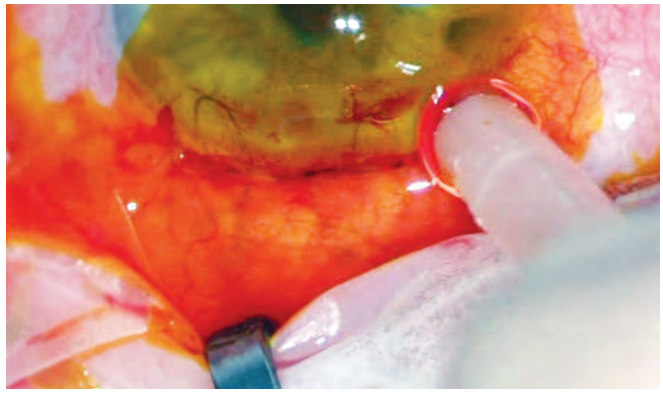

Fig. 3.23: Fluorescein test

JAYPEE BROTHERS

Table 3.1: Augmentation of trabeculectomy

	Five-fluorouracil	*Mitomycin C*
• Derivative	• Synthetic pyrimidine analog	• Streptomyces cespitosus
• pH	• 9	• 6–7.5
• Duration of action	• 4–6 weeks	• Lifelong
• Concentration	• 2.5–5% (25–50 mg/mL)	• 0.01–0.04% (0.1–0.4 mg/mL)

High-risk patients: Mitomycin C 0.03–0.04% or up to 20 µg injected

- Patients less than 50 years
- Previous failed trabeculectomy
- Uveitis
- Traumatic
- Neovascular
- African-Caribbean or Asian.

Moderate-risk patients: Mitomycin C 0.02% or up to 10 µg injected

- Patients 50–70 years
- Previous ocular surgery (not trabeculectomy)
- Long-term topical treatment
- Ocular atopy.

Low-risk patients: None-MMC 0.01%

- Patients more than 70 years
- Primary open angle glaucoma.

For MMC, both the concentration and/or duration can be adjusted according to the state of the conjunctiva. It can be assessed preoperatively at the slit lamp, but may not be known till formation of the conjunctival flap at the beginning of the trabeculectomy. The concentration of the MMC can be diluted with sterile water and the timing reduced. Most of the fibroblastic destruction occurs in the first minute, so any longer than 3 minutes is not necessary and leads to toxicity, resulting in avascularity and thinning of the bleb.

Results: This method of trabeculectomy was recently reviewed by Kirwan et al.[1] In a total of 428 eyes in 395 patients, antifibrotics were used in 400 cases (93%): MMC in 271 (63%), 5-FU in 129 (30%), and no antifibrotic in 28 (7%). At 2 years, IOP (mean ± standard deviation) was 12.4 ± 4 mm Hg, and 342 patients (80%) achieved an IOP less than or equal to 21 mm Hg and 20% reduction of preoperative IOP without IOP-lowering medication, whereas 374 patients (87%) achieved an IOP less than or equal to 21 mm Hg and 20% reduction of preoperative IOP overall. An IOP less than or equal to 18 mm Hg and 20% reduction of preoperative IOP were achieved by 337 trabeculectomies (78%) without IOP-lowering treatment and by 367 trabeculectomies (86%) including hypotensive medication. Postoperative treatments included suture manipulation in 184 patients (43%), resuturing or revision for hypotony in 30 patients (7%), bleb needling in 71 patients (17%), and cataract extraction in 111 of 363 patients (31%). Subconjunctival 5-FU injection was performed postoperatively in 119 patients (28%). Visual loss of more than two Snellen lines occurred in 24 of 428 patients (5.6%). A total of 31 of the 428 patients (7.2%) had late-onset hypotony (IOP < 6 mm Hg after 6 months). In three of these, visual acuity decreased by more than two Snellen lines. Bleb leaks were observed in 59 cases (14%), 56 cases (95%) of which occurred within 3 months. Two patients developed blebitis. Bleb-related endophthalmitis developed in 1 patient within 1 month postoperatively and in one patient at 3 years. There was an endophthalmitis associated with subsequent cataract surgery. In conclusion, this survey shows that good trabeculectomy outcomes with low rates of surgical complications can be achieved, but intensive proactive postoperative care is required.

EX-PRESS

This is a small shunt device that can be used as part of the trabeculectomy operation. It is inserted under the scleral flap via a sclerostomy. This device avoids the use of the scleral punch and the need for a peripheral iridectomy. This may be an advantage in cases at risk of iris bleeding, e.g. anticoagulation, neovascularization and risk of vitreous prolapse. The potential disadvantages include foreign body insertion, dislocation, endothelial or iris trauma from the tip, flap erosion and potential for blockage. The cost of the device does not provide significant advantages in most cases.

TUBES

Glaucoma drainage devices work by providing an artificial conduit for aqueous to leave the anterior chamber and directed into a bleb that forms over the plate of the device. The two main types are: (1) non-valved, e.g. Molteno, Baerveldt and (2) valved, e.g. Ahmed. There is also a range of sizes, depending on the patient requirements. The choice of tube depends on the surgeon, with the recommendation to become familiar with one particular type, learning to utilize the benefits and overcome any limitations.

JAYPEE BROTHERS

Indications

A tube is required when maximum medical or laser therapy is unable to reduce IOP to target levels and a trabeculectomy procedure is unlikely to succeed, such as in the presence of significant conjunctival scarring and/or inflammation.

Contraindications

- Tube insertion is technically difficult when the conjunctiva is scarred and there are potential issues with closure of the conjunctiva at the end of the procedure. There is an option to use other quadrants of conjunctiva if possible.
- In aphakic patients, vitrectomy is required to remove the vitreous to stop vitreous incarceration into the tube.
- Cessation of all anticoagulants is critical to reduce bleeding.

Surgical Steps (Baerveldt Tube)

1. Monitored local anesthesia with longer acting agent, e.g. ropivacaine 1%. Avoid adrenaline as dilates the pupil. A general anesthetic may be required in high-risk cases, e.g. only eye, long eyes more than 26 mm or uncooperative patients, e.g. children, intellectually impaired, dementia.
2. Can vasoconstrict conjunctival vessels with apraclonidine 1% or brimonidine 0.2% to reduce conjunctival bleeding.
3. Betadine preparation, dry eyelid skin and drape. Steristrip lashes out of operating field.
4. Use a speculum that doesn't put pressure on the globe, doesn't catch the stitch and provides good exposure of the conjunctival fornices.
5. 7/0 Vicryl or silk traction corneal traction suture
   - Advance the tip rather than follow curve of needle, needs to be at least 1 of 2 depths to avoid cheese-wiring through the cornea. If perforation occurs, replace in adjacent cornea. Use non-toothed forceps such as Pierce, Fechtner to avoid trauma to conjunctiva whilst providing counter traction.
6. Cover cornea with light protection shield. Attach traction suture to drape with an artery forcep.
   - Rotate eye inferonasally for maximal exposure of the superotemporal conjunctiva.
   - Avoid previous trabeculectomy sites if possible.
7. Fornix-based conjunctival flaps with radial relieving incisions (to just beyond muscle insertions) superiorly and temporally one quadrant apart (Fig. 3.24).
   - Identify superior and lateral recti using double squint hooks, ensuring clean dissection below muscles (site of plate) (Fig. 3.25).
   - If conjunctiva is very scarred, consider another quadrant or may need crescent blade to fashion the flap.
8. Gentle wet-field cautery for meticulous hemostasis.
9. Dissect subconjunctival space inferotemporally for burying the stent.
10. Take Baerveldt tube within the plastic case, leaving the packaging suture intact.

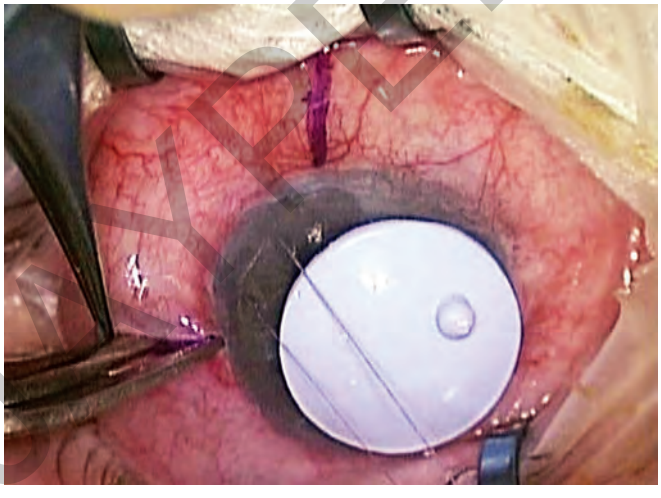

Fig. 3.24: Fornix-based conjunctival flaps (FBCF)

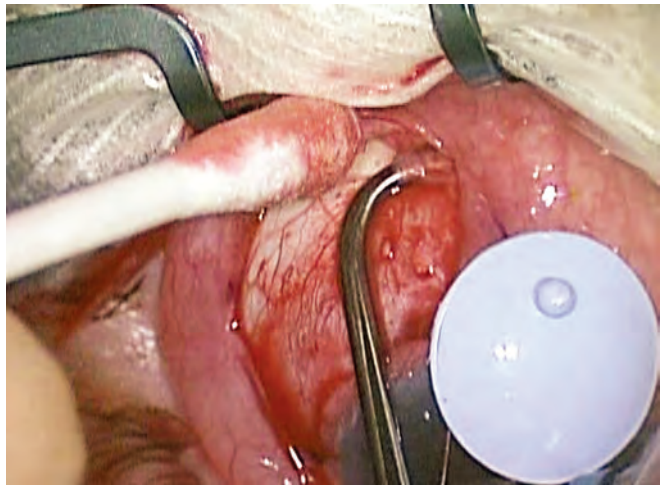

Fig. 3.25: Identify superior recti (SR)

JAYPEE BROTHERS

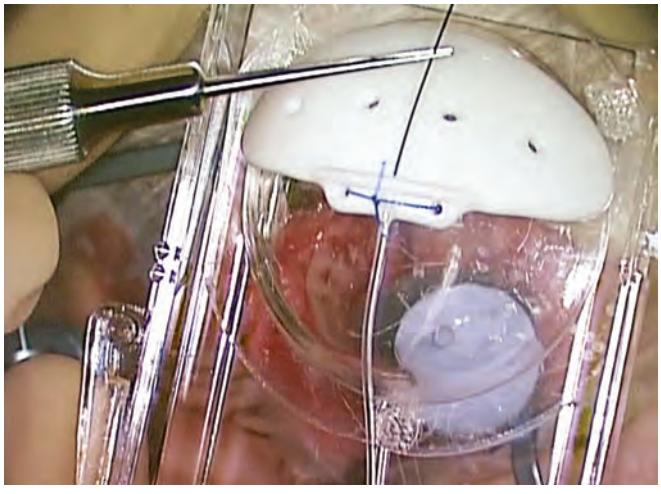

Fig. 3.26: Stent with 4-0 nylon

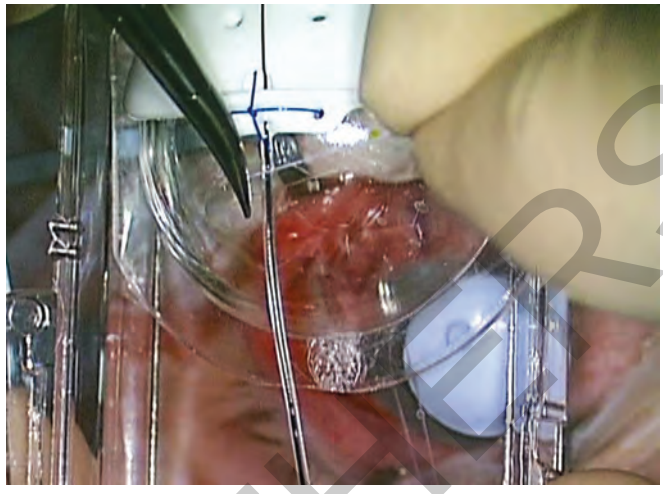

Fig. 3.27: Vicryl tie

11. Place Baerveldt 350 (or 250 if preferred) for size—adult size single plate—pediatric size too small.
12. Thread 3-4/0 nylon or 3/0 supramid (braided nylon) from above plate halfway along tube (Fig. 3.26).
13. Tie off tube with 7/0 Vicryl (Fig. 3.27)—test water tightness with a 27G Rycroft cannula on a 3 mL syringe with BSS (Fig. 3.28).
    - Take care not to cut through tube if suture over-tightened.
14. Place two through and through Sherwood slits with a 10/0 nylon needle (Fig. 3.29) just distal to the suture to allow early flow from the tube. The Baerveldt shunt can now be removed from the plastic case.
15. Insert the plate behind the recti.
    - The assistant can retract the conjunctiva with 2 squint hooks each around the muscle.
    - Heavier non-toothed forceps, e.g. Moorfields, Bonaccolto can be used to grasp the plate without damaging the silicone (Fig. 3.30).
    - This step is made easier if there has been adequate exposure and dissection around the muscles.
    - Plate should be 8–10 mm behind limbus to reduce risks of diplopia and encourages a posterior bleb.
    - The plate is fixed to the sclera by suturing with 10/0 nylon through the eyelets (Fig. 3.31). The ends are cut long and the knot rotated. It is easier to place the sutures first prior to tying off. Beware not to perforate the sclera as may be thin.
16. Insertion of the tube into the anterior chamber
    - Plan entry site for tube.
    - Avoid previous trabeculectomy site or thinned sclera.

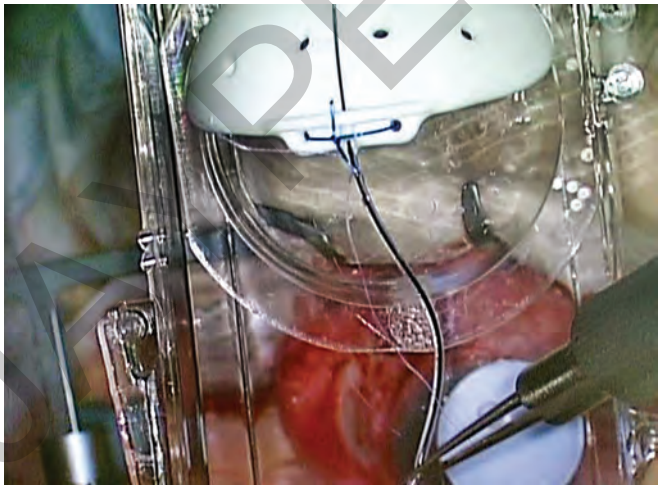

Fig. 3.28: Balanced salt solution (BSS) test

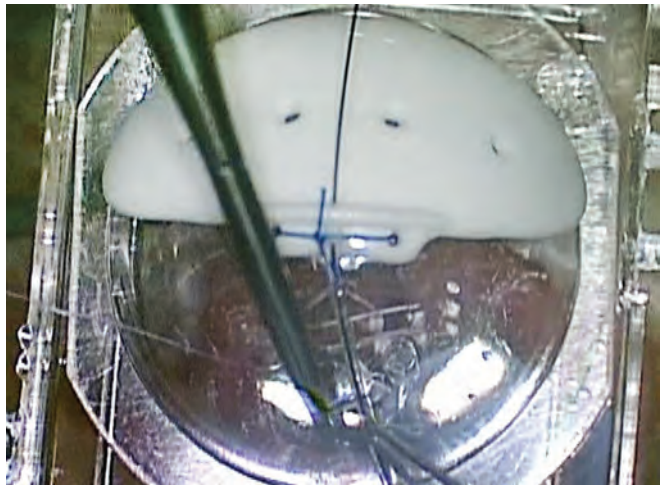

Fig. 3.29: Sherwood slit

JAYPEE BROTHERS

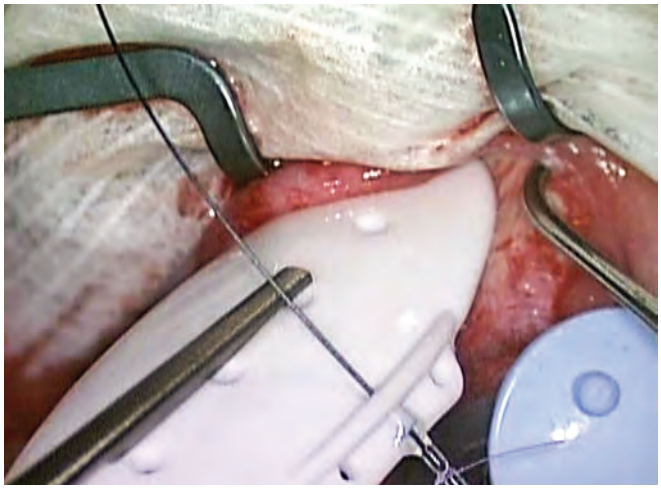

Fig. 3.30: Place plate

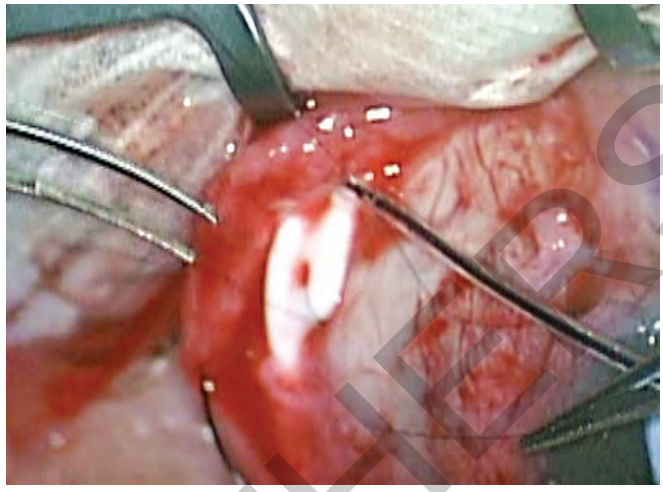

Fig. 3.31: Nylon suture

- Commence scleral track with half thickness cut down into sclera with diamond blade.
- Burrow with bent 23 gauge needle bevel up under sclera (Fig. 3.32) into peripheral cornea and enter midway between cornea and iris, parallel to the iris plane.
- Cut tube to appropriate length bevel up (not too long otherwise will catch in the tunnel), just beyond limbus (Fig. 3.33).
- Better to be shorter than longer as long tube end will hit endothelium or lens; however if too short may dislodge.
- Endothelial touch will result in decompensation and iris touch can lead to uveitis, iris damage and/or hyphema.
- Better to perform in one pass if possible to avoid multiple track steps.
- This is a critical step to get right.
- Viscoelastic use in the anterior chamber can assist in maintaining the angle, however, may distort the anatomy if over-filled.

17. Grasp end of tube with non-toothed curved tying forceps, e.g. Tennants and place in tunnel—should be a tight fit.
    - A small amount of viscoelastic in the tunnel may assist placement.
    - If position is not correct, then will need to repeat above in another position.
18. Seal tunnel with 10/0 nylon cross-over suture either side of tube

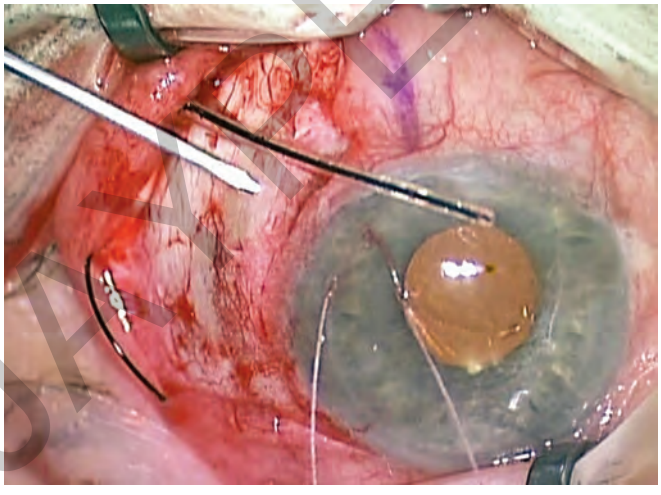

Fig. 3.32: 23 gauge needle track

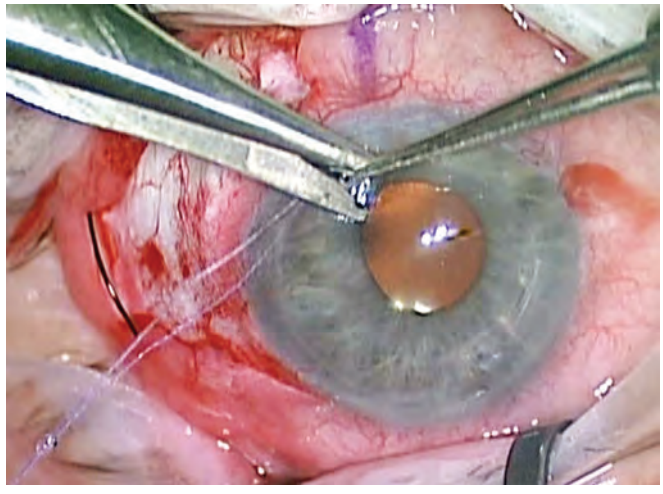

Fig. 3.33: Cutting tube

JAYPEE BROTHERS

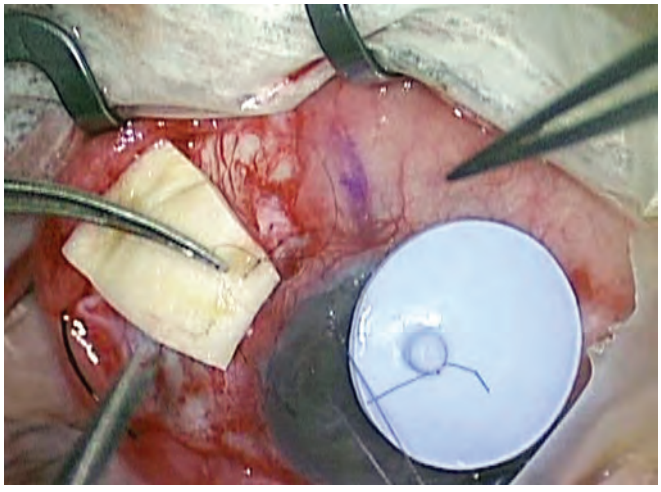

Fig. 3.34: Scleral patch

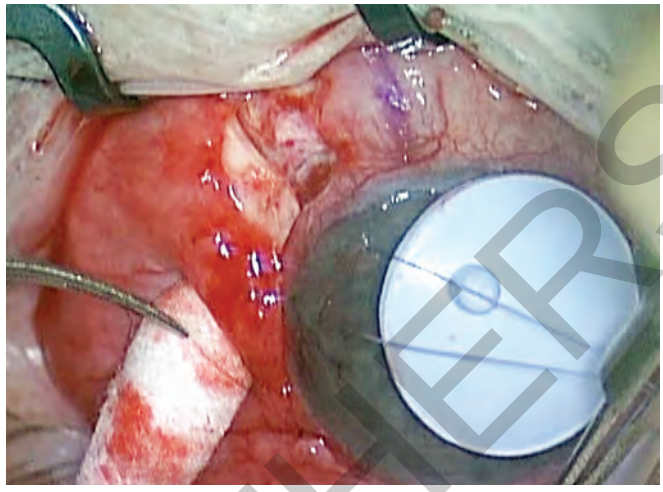

Fig. 3.35: Purse string

19. Cover tube with full-thickness scleral patch (Fig. 3.34) or substitute, e.g. pericardium, cornea using buried interrupted 8/0 nylon at each corner.
    - Patch needs to cover tube from anterior to the tube entry site to where tube enters plate. This is to prevent long-term tube erosion.
20. Reposition the conjunctiva carefully down over the plate and scleral patch graft. If there is any tension over the area, there is potential for conjunctival retraction.
    - If the conjunctiva is very tight, an option is to dissect the patch graft thinner. A relieving forniceal incision is not advisable as this damages the conjunctival coverage of the plate.
21. Close the conjunctiva with buried 10/0 nylon or 9/0 Vicryl purse-string sutures to both anterior corners (Fig. 3.35). The relieving incisions can then be closed from anterior to posterior using a continuous running horizontal mattress 9/0 Vicryl horizontal mattress (Fig. 3.36). The knot is buried anteriorly for patient comfort. The limbal edge can be closed using end-to-end 10/0 Nylon or 9/0 Vicryl-buried interrupted sutures.
22. *Option*: To achieve further seal of the wounds, subconjunctival fibrin glue (Tisseel) can be injected via a 27G Rycroft cannula over the scleral patch graft (Fig. 3.37). This needs to be performed in one rapid action as the glue sets quickly and occludes the cannula—the supplied plastic cannula is too wide bore.

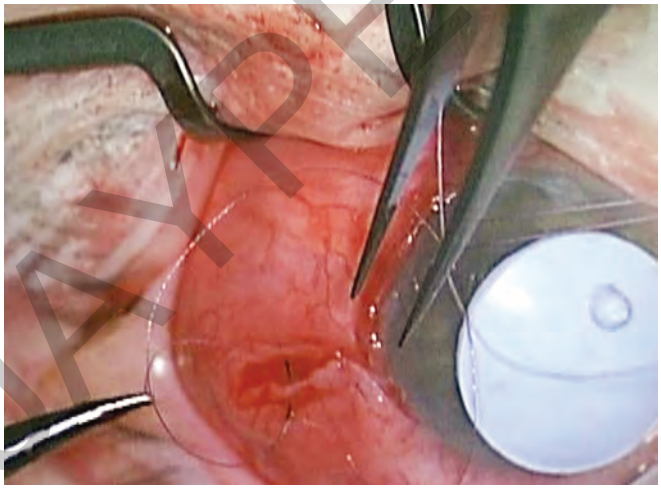

Fig. 3.36: Running mattress

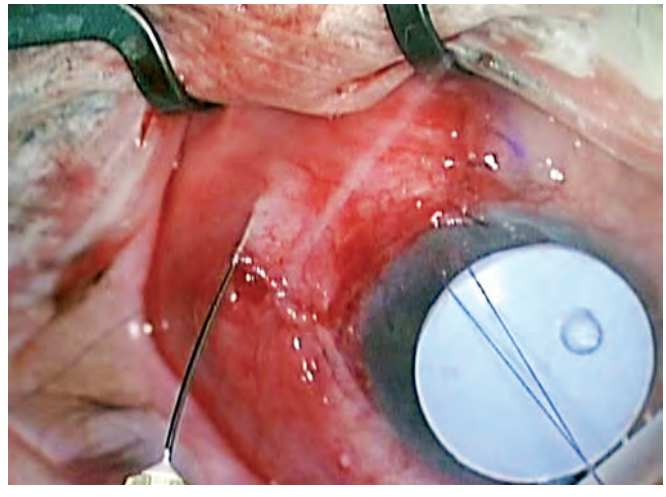

Fig. 3.37: Tisseel glue

JAYPEE BROTHERS

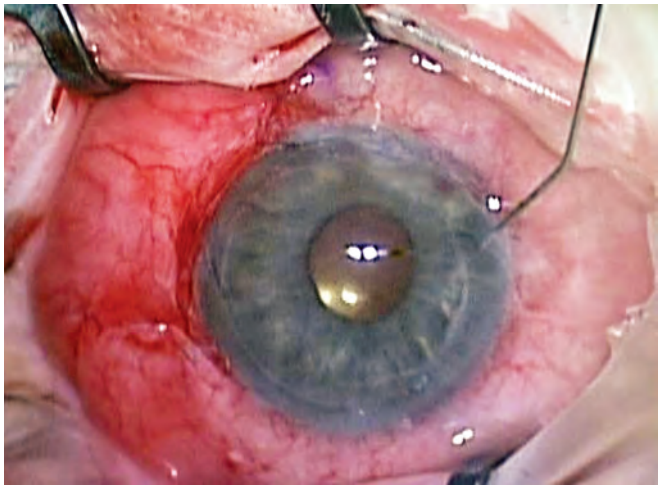

Fig. 3.38: Reformation of anterior chamber (AC)

23. Take out anterior chamber infusion if inserted and reform anterior chamber (Fig. 3.38).
    - Must avoid hypotony.
    - If anterior chamber shallowing occurs, need to identify cause of leak.
    - If required, the anterior chamber can be partially filled with a cohesive type of ophthalmic visco-surgical device (OVD), e.g. Healon, Provisc. Avoid heavier OVD or dispersive type otherwise risk of high pressure spike.
24. Inject subconjunctival antibiotic and steroid inferiorly.
25. Carefully remove traction suture. Eyepad and shield.
26. Rest semi-upright overnight.
27. Postoperative topical steroid and antibiotic tapering dose for 4–6 months.
28. Postoperative management critical in the first 3–4 weeks.
    - Patient may require 2–3 daily review to monitor IOP and manage IOP spikes.
    - Patient stays on topical glaucoma medications and may require oral acetazolamide.
    - The Vicryl suture generally opens at 4–6 weeks postoperatively, with a sudden fall in IOP. The patient needs to be aware of this occurring and stop the glaucoma medications.
    - If the IOP is remaining high after 4 weeks, then the nylon stent can be removed. If Supramid is used, then this is not usually removed until 3 months.
    - Topical steroids are continued 3–6 months.

Results: The aim is the creation of a bleb over the plate, with the tube in a suitable position in the anterior chamber, not touching the endothelium or iris. The IOP should be at stable target level. Further glaucoma medications may be required to maintain the target IOP.

Pearls and Pitfalls

- If safe to do so, the patient must stop anticoagulation medications including anti-inflammatories, fish oil at least 1 week prior to surgery.
- If the patient is aphakic, need to perform a complete vitrectomy prior to tube insertion to prevent vitreous incarceration of tube.
- Need to choose the right patient—preoperative assessment of conjunctiva.
- Patients need to have realistic expectations.
- Ideal operating conditions to maximize outcomes.
- Tube can be placed in the sulcus behind the iris provided the tube is visible at or within the pupil margin and patient is pseudophakic.
- Tube can be placed pars plana in vitrectomized eyes.
- Postoperative follow-up imperative as IOP spikes or hypotony can result in vision loss. Need a low threshold for active intervention, i.e. go back to theater and rectify cause.

Results: Outcomes for tubes have been compared to trabeculectomy in 212 eyes in 212 patients in a multi-center randomized controlled trial—the tube versus trabeculectomy (TVT) study.[2] At 5 years, IOP [mean ± standard deviation (SD)] was 14.4 ± 6.9 mm Hg in the tube group and 12.6 ± 5.9 mm Hg in the trabeculectomy group (P = .12). The number of glaucoma medications (mean ± SD) was 1.4 ± 1.3 in the tube group and 1.2 ± 1.5 in the trabeculectomy group (P = .23). The cumulative probability of failure during 5 years of follow-up was 29.8% in the tube group and 46.9% in the trabeculectomy group (P = .002; hazard ratio = 2.15; 95% confidence interval = 1.30–3.56). The rate of reoperation for glaucoma was 9% in the tube group and 29% in the trabeculectomy group (P = .025). In conclusion, tube shunt surgery had a higher success rate compared to trabeculectomy with MMC during 5 years of follow-up in the TVT Study. Both procedures were associated with similar IOP reduction and use of supplemental medical therapy at 5 years. It is however important to note that the technique for trabeculectomy

JAYPEE BROTHERS

varied across the centers and is not neccessarily consistent with the trabeculectomy outcomes described in this chapter.

Comment: Tube insertion is our preferred drainage operation if trabeculectomy is not indicated and the patient has a good visual prognosis. In patients with a poor visual prognosis, other techniques such as diode laser cycloablation are preferable.

REFERENCES

1. Kirwan JF, Lockwood AJ, Shah P, et al. Trabeculectomy in the 21st century: a multicenter analysis. Ophthalmology. 2013;120(12):2532-9.
2. Gedde SJ, Schiffman JC, Feuer WJ, et al. Treatment outcomes in the Tube versus trabeculectomy (TVT) study after 5 years of follow-up. Am J Ophthalmol. 2012:153(5); 789-803.

JAYPEE BROTHERS

detailed information on ophthalmology books, visit our website www.jaypeebrothers.com, for detailed information on ophthalmology books, visit our web

ISGS Textbook of
GLAUCOMA SURGERY

Salient Features

- A unique video-assisted skill transfer module providing glaucoma surgical training
- Each chapter includes text and photographs with accompanying surgical videos
- Includes Laser surgery for open and closed angle glaucomas
- Penetrating and nonpenetrating glaucoma surgical techniques
- Pediatric glaucoma surgery
- Glaucoma drainage devices
- Minimally invasive surgery with new microsurgical devices (Hydrus, iStent, Cypass, Trabectome, ExPress, Midi-arrow, Aquesys etc.)
- Managing complications of each surgical technique
- Special situations such as post keratoplasty, vitreoretinal surgery.








Shelving
Recommendation
OPHTHALMOLOGY

ISBN 978-93-5152-206-5

Available at all medical book stores
or buy directly from Jaypee Brothers through online shopping
at www.jaypeebrothers.com

JAYPEE BROTHERS
Medical Publishers (P) Ltd.
www.jaypeebrothers.com