www.jaypeebrothers.com, for detailed information on otolaryngology books, visit our website www.jaypeebrothers.com

Introductory Head & Neck Imaging

Eugene Yu
Lalitha Shankar

Foreword
Suresh K Mukherji



JAYPEE

Contents

1. **Imaging techniques in head and neck** **1**
Colin S Poon, Jessie Aw
- Computed tomography *2*
- Magnetic resonance imaging *4*
- Positron emission tomography *9*
- Ultrasound *10*
- X-ray esophagram *12*

2. **Radiographic anatomy and pathology of the temporal bone** **15**
Samantha Shankar, Alan Johnson, Vinh Nguyen
- Embryology *15*

Normal CT and MRI anatomy of the temporal bone *16*
- The external ear *16*
- The middle ear *18*
- The facial nerve *25*
- The inner ear *25*
- Imaging of the temporal bone with CT and MRI *36*

Temporal bone pathology *37*
- The external ear *37*
- The middle ear *48*
- Facial nerve *63*
- The inner ear *68*
- Trauma *79*

3. **Imaging of the orbit** **86**
Makki Almuntashri, Edward Kassel
- Anatomy of the orbit *86*
- Congenital anomalies *92*

- Orbital infections *98*
- Orbital neoplasms *105*
- Inflammatory diseases of the orbit *122*
- Trauma of the orbit *129*
- Intraocular detachments *133*
- Some overall thoughts about the orbit *134*

4. Imaging of the paranasal sinuses **142**
David Ashton, Dzung Vu, Lalitha Shankar, Eugene Yu

- Normal anatomy *142*
- Paranasal sinus imaging anatomy *146*
- Benign lesions *215*

5. Diseases of the nasopharynx **229**
Manas Sharma, Eugene Yu, Peter Yang

- Anatomy *229*
- Imaging of the nasopharynx *230*
- Diseases of the nasopharynx *231*
- Nasopharyngeal cysts *231*
- Lymphoid hyperplasia/hyperplastic adenoid *233*
- Juvenile angiofibroma *234*
- Nasopharyngeal tuberculosis *237*
- Nasopharyngeal carcinoma *240*
- Lymphoma *247*
- Other rare nasopharyngeal disorders *251*

6. Imaging of the masticator and parapharyngeal spaces **257**
Dorothy Lazinski

Part I: The masticator space *257*

- Anatomy *257*
- Imaging anatomy *259*
- Muscles of mastication *262*

- Mandible *267*
- Odontogenic tumor *269*
- Neurogenic lesions *273*

Part II: The parapharyngeal space *279*
- Anatomy *279*
- Pathology *283*
- Patterns of parapharyngeal fat displacement *284*
- Infection *286*
- Tumors *287*
- Retrostyloid parapharyngeal space *294*

7. Radiographic anatomy and pathology of the oral cavity **302**
Claudia Kirsch, Kristin McNamara
- Cross-sectional anatomy of the oral cavity *303*
- Imaging of the oral cavity with CT and MRI *309*
- Pathology *310*

8. Oropharynx **333**
Aditya Bharatha, Keng-Yeow Tay
- Radiologic anatomy *333*

9. Diseases of the parotid gland **355**
Andrew Law, Andrew Thompson
- Embryology *355*
- Anatomy *355*
- Imaging overview *357*
- Normal variants *360*
- Pathology *360*
- Autoimmune/inflammatory/infiltrative *364*
- Trauma *369*
- Benign neoplasms *369*
- Malignant neoplasms *382*

10. Perineural disease in the head and neck **394**
Manas Sharma, Laurent Létourneau-Guillon

- Anatomy *398*
- Imaging considerations: techniques and features *409*
- Normal variants and differential diagnosis *419*

11. Imaging evaluation of cervical lymph nodes **421**
Reza Forghani, Hugh D Curtin

- Physiology and radiologic anatomy of cervical nodes *422*
- Pathology *447*

12. The larynx and the hypopharynx **505**
Eric S Bartlett

- The role of imaging *507*
- Imaging anatomy—larynx *509*
- Imaging anatomy—hypopharynx *516*
- Anatomic details *518*
- Pathology *519*

13. Carotid, prevertebral, and perivertebral spaces **531**
Daniel M Mandell

Carotid space *531*
- Anatomy *531*
- Pseudolesions *532*
- Vascular diseases *533*
- Neoplastic *539*
- Nerve sheath neoplasms *543*

Retropharyngeal space *548*
- Anatomy *548*
- Infectious or inflammatory *549*
- Neoplastic *552*

Perivertebral space *555*
- Anatomy *555*
- Infectious or inflammatory *555*
- Neoplastic *557*

14. Vascular lesions of the head and neck **560**
Juan Pablo Cruz, Timo Krings, Tom Marotta

- Vascular malformations *560*
- Traumatic vascular lesions *572*
- Other vascular diseases *579*
- Vascular tumors *584*
- Hypervascular lymphadenopathies *603*

15. Diseases of the thyroid gland **610**
Andrew Law, Andrew Thompson

- Embryology *610*
- Anatomy *610*
- Imaging overview *612*
- Pathology *617*
- Inflammatory *618*

16. Introduction to radiation oncology **634**
Karen P Chu, Annie Hsu, Arjun Sahgal

- Clinical radiation oncology *643*
- Clinical radiotherapy planning *646*

Index 659

chapter 3

Imaging of the orbit

Makki Almuntashri, Edward Kassel

Abstract

A comprehensive review of the imaging anatomy of the orbit, followed by a discussion of various congenital, infectious, neoplastic, inflammatory and traumatic conditions that can affect the orbital contents.

Keywords

Orbit, globe, eye, anatomy, infection, neoplasm

Anatomy of the orbit

The orbit is a conical shaped cavity that contains the eye (globe), extraocular muscles, vascular supply, cranial nerves (CN) and the surrounding fat. It has four bony walls which are lateral, medial, superior and inferior. The lateral wall is formed by frontal process of zygomatic bone anteriorly and greater wing of sphenoid posteriorly. The medial wall is formed by four bones from anterior to posterior; frontal process of maxillary bone, lacrimal bone, lamina papyracea of ethmoid and lesser wing of sphenoid bone. The roof is formed by orbital process of frontal bone, complemented by the lesser wing of the sphenoid bone more posteriorly while the floor is formed by maxillary process of zygomatic bone laterally and orbital plate of maxillary bone medially which contain the infraorbital foramen (**Figures 3.1A and B**).

The orbital cavity is pyramidal shaped, narrows posteriorly forming the orbital apex which has three openings; optic canal, superior and inferior orbital fissures (**Figures 3.2A to C**). The optic canal is located superomedially within the lesser wing of sphenoid. It transmits the optic nerve (CN2) and ophthalmic artery. The superior orbital fissure, lateral to the optic canal and formed by the lesser wing of sphenoid medially and greater wing of sphenoid laterally, transmits the superior ophthalmic vein, oculomotor (CN3), trochlear (CN4),

JAYPEE BROTHERS

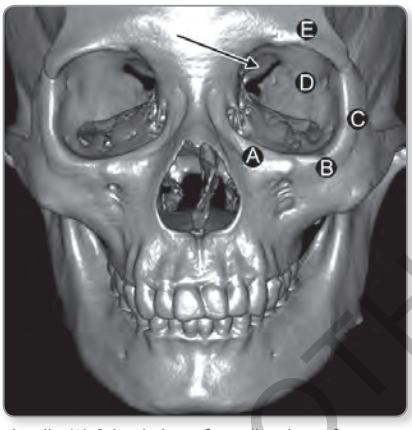

Figure 3.1A Orbital walls: (A) Orbital plate of maxillary bone forming medial aspect of orbital floor. (B) maxillary process of zygomatic bone forming lateral aspect of orbital floor. (C) Frontal process of zygomatic bone forming anterior aspect of lateral wall. (D) Greater wing of sphenoid forming posterior aspect of lateral wall. (E) Orbital process of frontal bone forming the roof of orbit

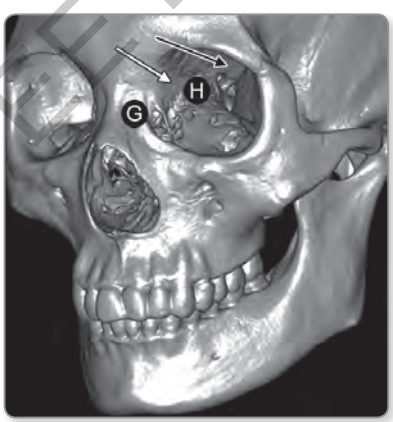

Figure 3.1B Medial wall from posterior to anterior: Black arrows in Figures A and B represent lesser wing of sphenoid. (H) Ethmoidal bone (lamina papyracea). White arrow: Lacrimal bone. (G) Frontal process of maxillary

JAYPEE BROTHERS

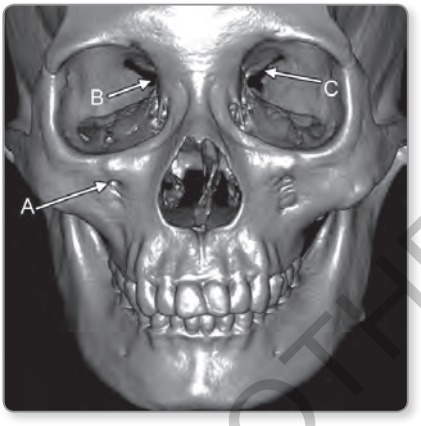

Figure 3.2A Foramina: Arrow (A) Infraorbital foramen. Arrow (B) Optic canal. Arrow (C) Superior orbital fissure

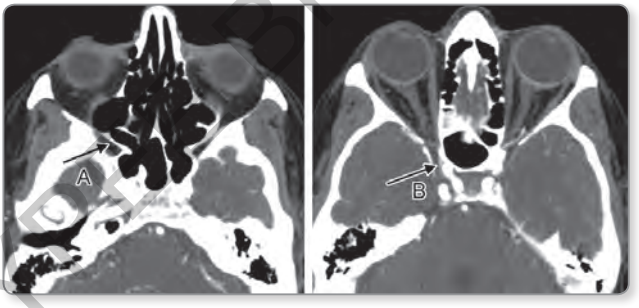

Figure 3.2B Foramina: Arrow (A) Right inferior orbital foramen. Arrow (B) Right superior orbital foramen

ophthalmic division of trigeminal (CN V1) and abducent nerves (CN6). The inferior orbital fissure inferolaterally, bordered by the maxillary bone medially and greater wing of sphenoid laterally, communicates with the pterygopalatine fossa and transmits the maxillary division of trigeminal nerve (CN V2) intracranially by its communication with foramen rotundum.

JAYPEE BROTHERS



Figure 3.2C Optic canal

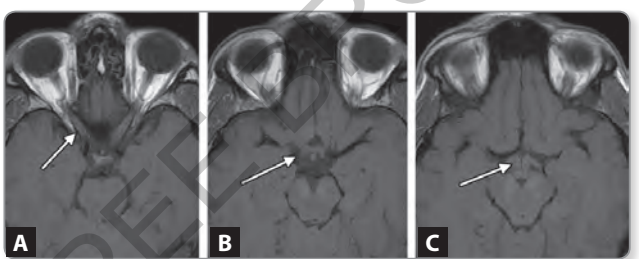

Figures 3.3A to C Optic pathway: (A) Optic nerve extending from the intraorbital portion to prechiasmatic portion (arrow). (B) Optic chiasma. (C) Optic tract extends from the optic chiasm to optic radiations in the occipital lobe

The optic nerve is formed from brain tissue (oligodendrocyte) without surrounding Schwann cells in contrast to peripheral nerves. It is surrounded by cerebrospinal fluid (CSF) and covered by three meningeal layers in a fashion similar to the brain, i.e. an outer dura, middle arachnoid and inner pia layers and called the optic nerve sheath, and courses from the optic disc at the retina to the optic chiasm at the suprasellar region carrying sensation to the visual cortex in the occipital lobes via optic tracts and radiations (**Figures 3.3A to C**).

JAYPEE BROTHERS

CN V1, a sensory division of the trigeminal nerve, supplies the skin about the upper eyelid and superior aspect of the orbit.

CN 3, 4 and 6 are motor nerves that supply the extraocular muscles, which include four recti muscles (superior rectus, inferior rectus, medial rectus and lateral rectus muscles), two oblique muscles (superior and inferior oblique) and the levator palpebrae superioris (**Figures 3.4A and B**).

The superior oblique muscle is supplied by the trochlear nerve (CN4) and the lateral rectus muscle is supplied by the abducent nerve (CN6), with the remainding extraocular muscles supplied by the oculomotor nerve (CN3). A helpful mnemonic to remember the nerve supply to the extraocular muscles is SO4 LR6 (SO4 = superior oblique is supplied by CN4, LR6 = lateral rectus is supplied by CN6).

The eyeball (eye or globe) is protected by the bony orbit and covered anteriorly by the eyelid. With the exception of the cornea and conjunctiva at the anterior aspect of the globe, the wall of the globe is formed from three layers: outer sclera, middle uvea and inner retina. Clinically the eyeball refers to just the sclera and choroid layers, with the retina offering no appreciable thickness. The outer layer of the globe is covered by Tenon's capsule, a fibroelastic membrane that forms a socket enclosing the posterior 4/5 of the globe, separating

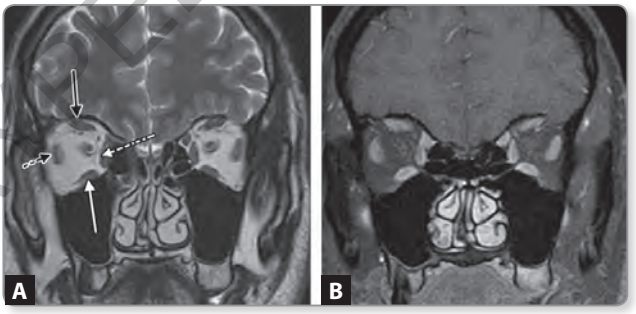

Figures 3.4A and B Extraocular muscles: (A) Coronal T2 of orbit shows superior rectus muscle (black arrow), lateral rectus muscle (black dotted arrow), inferior rectus muscle (white arrow), and medial rectus muscle (white dotted arrow). (B) Coronal T1 fat sat after gadolinium: Note normal enhancement of the muscles

JAYPEE BROTHERS

the globe from the surrounding orbital fat, to allow free movement of the globe. Tenon's space is that space between the capsule and the sclera.

The sclera represents the large posterior opaque globe covering, formed from collagen-elastic tissue that extends from the optic nerve attachment posteriorly to the corneoscleral junction anteriorly. The cornea will cover the small transparent anterior segment of the eye. The uvea, a pigmented richly vascular layer, consists of three components; the choroid posteriorly, iris anteriorly and ciliary body connecting the choroid to iris. The iris is a thin pigmented membrane behind the cornea and anterior to the lens, surrounding a central opening called the pupil. The thin inner retinal layer is the neural sensory layer.

The lens, formed from epithelium, fibers and surrounding capsule, is located behind the iris and held in position by the suspensory ligament of the lens (Zonule) that is attached to the ciliary body on each side.

The globe is divided into anterior and posterior segments by the ciliary body. The anterior segment is divided by the iris into anterior and posterior chambers. These chambers are filled by the aqueous humor secreted by the ciliary bodies and communicate with



Figure 3.4C Coronal CT orbit shows superior oblique muscle (large circular black arrow), inferior oblique muscle (straight white arrow) and lacrimal gland (straight black arrow)

JAYPEE BROTHERS

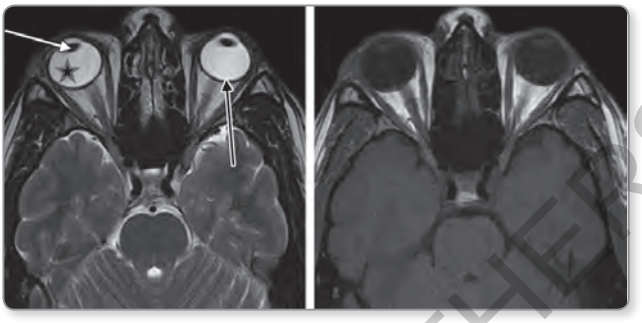

Figure 3.5 MR of the eye (T2WI and corresponding T1WI) show the lens (white arrow), vitreous (5-points star) and eye wall (black arrow) formed by sclera, uvea and retina from outer to inner

each other through the pupil. The posterior segment is filled by the vitreous humor which contains mostly water with small amount of protein (**Figure 3.5**).

The lacrimal gland, located in the superolateral portion of the orbit (**Figure 3.4C**), secretes clear fluid which flows across the anterior orbit to drain into the lacrimal sac, at the medial inferior aspect of the orbit, and nasolacrimal duct to reach the inferior meatus of the nasal cavity.

The orbit receives its blood supply by the ophthalmic artery, which is the first branch of the internal carotid artery, and drains via the superior and inferior ophthalmic veins. The superior ophthalmic vein drains into the cavernous sinus and the inferior vein anastomoses with the pterygoid plexus (**Figures 3.6A and B**).

Congenital anomalies

Anophthalmia

Anophthalmia or absence of the eye is an extremely rare congenital defect.

JAYPEE BROTHERS

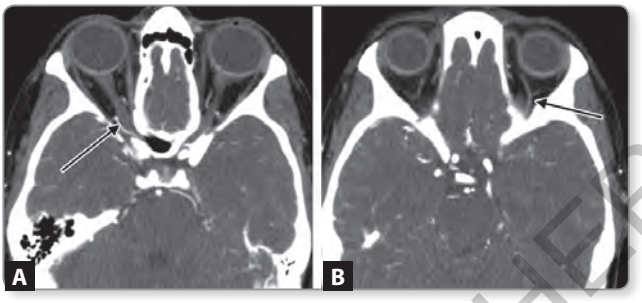

Figures 3.6A and B Axial CT angiogram shows ophthalmic artery running from the ICA to orbit (A) and superior ophthalmic vein (B)

Microphthalmia

Microphthalmia denotes a small globe and can be either congenital or acquired. Congenital microphthalmia may be isolated, syndromic, or associated with other entities such as congenital infections or persistent hyperplastic primary vitreous. When the globe is congenitally small, the orbit is underdeveloped as opposed to acquired diminution of the eye.

Acquired microphthalmia, seen as a result of trauma, surgery or inflammation, is termed phthisis bulbi. In Phthisis bulbi, the eye is small, frequently irregular in configuration, and calcification may be present (**Figure 3.7**).

Persistent hyperplastic primary vitreous

Persistent hyperplastic primary vitreous (PHPV) is a congenital ocular abnormality due to incomplete regression of embryonic ocular blood supply. It is characterized by presence of a central hyaloid artery remnant in a small globe. CT imaging shows a dense vitreous due to the presence of hemorrhage, debris and rarely calcifications. MR imaging (**Figure 3.8**) typically shows abnormally high signal on T1 and T2-weighted images of the vitreous that varies based on age of the blood contents. Common clinical presenting symptoms/signs are leukokoria, poor vision and retinal detachment.

JAYPEE BROTHERS

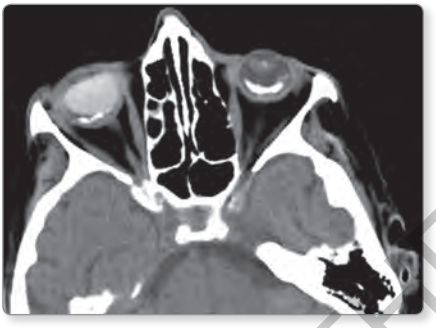

Figure 3.7 CT head of 54-year-old male with bilateral phthisis bulbi. Both globes are small with irregular outline. There is calcification at posterior aspect of both eyes. Note dense vitreous on the right

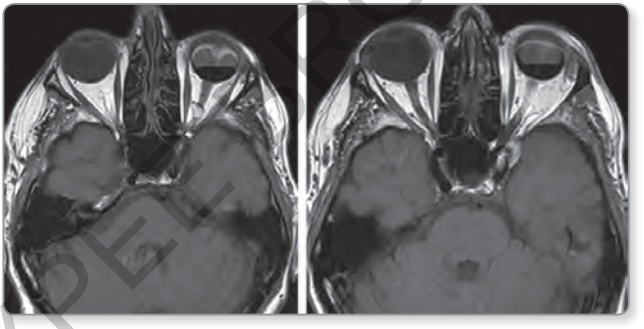

Figure 3.8 Axial T1 MRI of orbit: 57-year-old patient with left eye blindness. Images show small left eye with persistent hyaloid artery in mid vitreous in keeping with persistent hyperplastic primary vitreous. Note dark signal in the dependent portion of eye in keeping with hemosiderin related to old hemorrhage

JAYPEE BROTHERS

Macrophthalmia

Macrophthalmia represents enlargement of the globe that may be related to various etiologies as mentioned below. The most common cause is axial myopia (**Figure 3.9**).

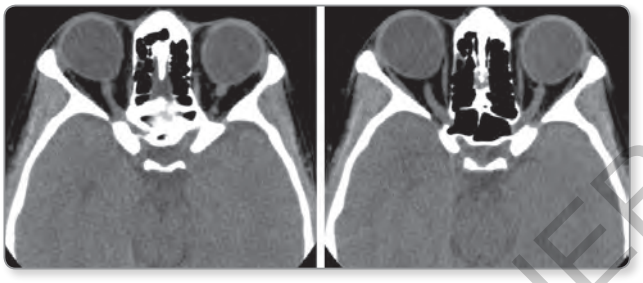

Figure 3.9 CT images of orbits of 29-year-old female with elongation of both eyes related to myopia

Buphthalmos (Ox eye)

Buphthalmos represents enlargement of the globe, seen in infants and children with glaucoma due to elevated intraocular pressure, characterized by increased axial diameter, with sclera thickening. Approximately 50 percent of patients with neurofibromatosis type 1 who have orbital involvement have glaucoma.

Staphyloma

Staphyloma represents a nonspecific enlargement of the globe related to thinning of the sclera-uveal wall and has an association with myopia. Staphyloma (**Figure 3.10**) tends to be a more focal enlargement or bulge, usually posterotemporal and may also be caused by radiation or previous infection.

Coloboma

Coloboma is a focal congenital gap or defect of the ocular tissue with outpouching of the vitreous, typically located at the optic nerve head insertion or the posterior globe and is commonly bilateral. If confined to the optic disc, it is termed an optic disc coloboma and if separated or extending beyond the optic disc, it is a chorioretinal coloboma. Clinical presentations in colobomas are variable based on extent of involvement and ranges from a decrease in visual acuity

JAYPEE BROTHERS

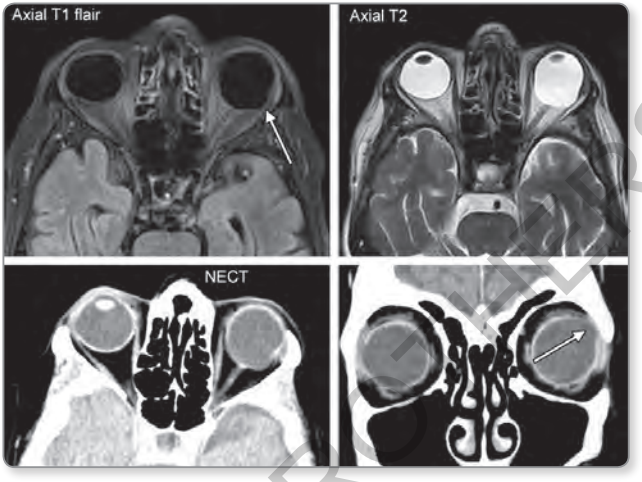

Figure 3.10 MR and CT orbits of 81-year-old female with focal bulge posterotemporal aspect left globe seen on axial T1 FLAIR, axial T2 and axial/coronal unenhanced CT. Note focal decreased thickness of the eyewall (arrows) at the posterior bulge (Staphyloma) and adjacent posterior aspect of the globe

which is the most common to visual loss when retinal detachment is present (**Figures 3.11A to C**). Coloboma may be sporadic, autosomal dominant when nonsyndromic, or syndromic and usually autosomal recessive.

Dermoid and epidermoid cysts

Dermoid and epidermoid cysts are developmental, non-neoplastic cysts caused by congenital failure of ectoderm to separate from the underlying structures, and sequestration of surface ectoderm or inclusion of dermal elements at site of suture closure. They represent 5 percent of orbital masses, with the majority (about 65–75%) being extraconal in the superolateral aspect of anterior orbit at the fronto-zygomatic suture. The remainder mostly occurs in the superonasal aspect of the frontolacrimal suture with other sites infrequent.

JAYPEE BROTHERS

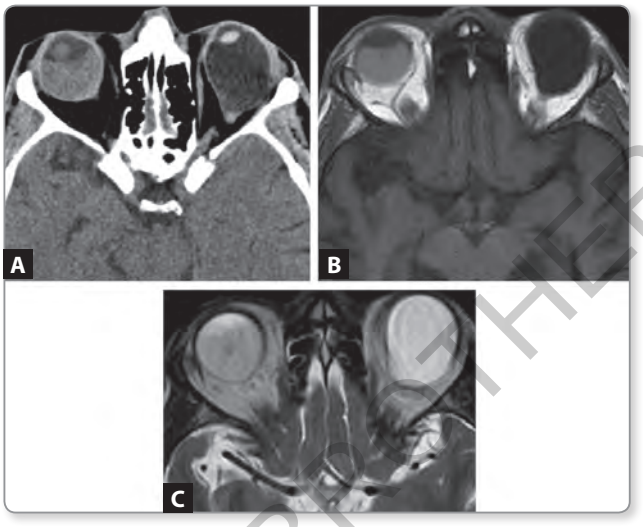

Figures 3.11A to C A 43-year-old female with bilateral coloboma and hemorrhage in right vitreous. (A) (Non enhanced CT orbit) shows dense hemorrhage in the vitreous of right eye. (B) and (C) (T1WI and T2WI MR) show bilateral coloboma. The hemorrhage is hyperintense on T1 and intermediate/slightly hypointense on T2

These cysts tend to be non-tender painless masses, fixed to the underlying bone (in opposition to sebaceous cysts), but may present as an enlarged painful mass if inflamed by associated infection or rupture, whether spontaneously or following trauma.

Imaging of dermoid and epidermoid demonstrates well demarcated cysts with thin rim. Presence of fat (HU -30 to -80 on CT) and/or high signal on T1WI on MR is characteristic of dermoid (**Figure 3.12**), while high signal (restricted diffusion) on DWI (MR diffusion weighted images) is indicative of epidermoid cyst. Scalloping and thinning of adjacent bone are common due to pressure erosion by the longstanding, slow growth of these lesions. Surgical resection is curative.

JAYPEE BROTHERS

or detailed information on otolaryngology books, visit our website www.jaypeebrothers.com, for detailed information o

Introductory Head & Neck Imaging

Salient Features

- The book is a most comprehensive text.
- Written in straightforward, clear, lucid and easy-to-grasp language.
- Covers the various components of head and neck imaging.
- Helpful for radiology residents, neuroradiology fellows and general radiologists.
- Each of the chapters focuses on a particular anatomic region of the extracranial head and neck and also included an introductory chapter on the Introduction of Radiation Oncology.
- Asset to radiologists-in-training, fellows, general radiologists and also physicians in affiliated specialties such as otolaryngology, and radiation oncology.



Eugene Yu MD FRCPC Assistant Professor, Departments of Medical Imaging and Otolaryngology—Head and Neck Surgery, University of Toronto, Canada. He completed his Medical School Degree in 1996, University of Toronto, Canada. His residency training was in Medical Imaging at the University of Toronto and he is currently a Fellow of the Royal College of Physicians and Surgeons, Canada. He did a Post-residency Fellowship in Neuroradiology, University of Toronto, Canada. He is the Site Director of the Neuroradiology Fellowship Program and the Radiology Residency Program, Princess Margaret Hospital, Toronto, Ontario, Canada. His academic focus is in Head and Neck Radiology. He is an active member of the American Society of Head and Neck Radiology, the North American Skull Base Society, the Eastern Neuroradiological Society and an associate member of the American Head and Neck Society. He is also a member of the Faculty Advisory Committee of the University of Toronto Medical Journal and a member of Medical Imaging Committee for Undergraduate Medical Education at the University of Toronto.



Lalitha Shankar MD FRCPC Associate Professor, University of Toronto, is a practicing radiologist in Toronto, Canada. She graduated from Calcutta University with an MBBS and her residency training was from University of Toronto in 1983. Her contributions to Head and Neck Radiology through the many years include peer-reviewed articles, chapters in several books and author of 3 books—*Atlas of Imaging of the Paranasal Sinuses* (1st and 2nd Edition) and *Imaging of the Head and Neck*. She has served as a visiting professor in several universities and continues to teach Head and Neck Radiology.

Shelving Recommendation
OTOLARYNGOLOGY
RADIOLOGY

ISBN 978-93-5152-207-2

Available at all medical book stores
or buy directly from Jaypee Brothers through online shopping
at www.jaypeebrothers.com

JAYPEE BROTHERS
Medical Publishers (P) Ltd.
www.jaypeebrothers.com

Join us on facebook.com/jaypeebrothers