cardiology books, visit our website www.jaypeebrothers.com, for detailed information on cardiology books

JAYPEE

TRANSESOPHAGEAL ECHOCARDIOGRAPHY OF CONGENITAL HEART DISEASES

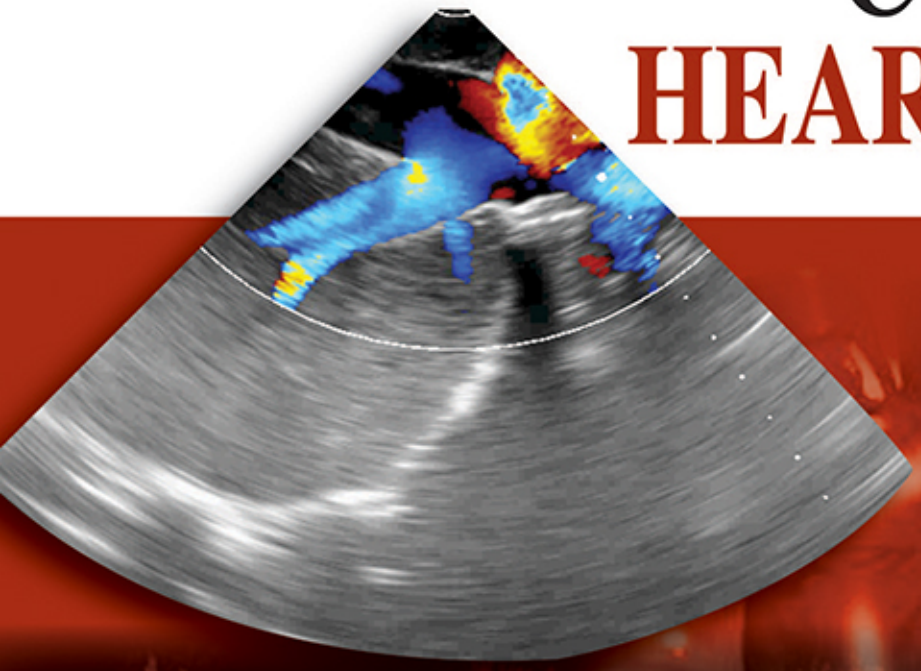



Includes DVD-ROM

Editors
Poonam Malhotra Kapoor
Sarvesh Pal Singh

Forewords
MC Misra
Navin C Nanda
Balram Airan
Usha Kiran
Yatin Mehta

Under the Aegis of SCA—Delhi and NCR

Contents

1. Introduction to TEE for Congenital Heart Disease **1**

Usha Kiran, Poonam Malhotra Kapoor, Sarvesh Pal Singh, Ajay Jha

Indications for TEE in Patients with Congenital Heart Disease 1; TEE Guided Interventions 2; Contraindications for the use of TEE 2; Definitions 2; Significance 3; Imaging Planes and Orientation 3; Goals of the Examination 3; Probe Insertion 4; Probe Manipulation 5; ACHD: Transesophageal Echocardiographic Imaging Algorithm 5

2. Chambers, Valves and Normal Dimensions **7**

Sandeep Chauhan, Poonam Malhotra Kapoor, Jitin Narula, Rajshekhar

Left Ventricular Measurements 9; Right Ventricular Dimensions 10; Nadas' Criteria 11; Reference values for Normal Adult Transesophageal Echocardiography Measurements 11

3. TEE Views in Congenital Heart Disease **12**

Sarvesh Pal Singh, Poonam Malhotra Kapoor

Midesophageal Four Chamber View 16; Midesophageal Two Chamber View 17; Midesophageal Bicommissural View 18; Midesophageal Long-axis View 19; Midesophageal Aortic Valve Long-axis View 20; Midesophageal Aortic Valve Short-axis View 21; Midesophageal Bicaval View 22; Midesophageal Descending Thoracic Aorta Long-axis View 23; Midesophageal Descending Thoracic Aorta Short-axis View 24; Midesophageal Ascending Aorta Long-axis View 25; Midesophageal Ascending Aorta Short-axis View 26; Midesophageal Left Atrial Appendage View 27; Midesophageal Modified Bicaval View 28; Midesophageal Right Pulmonary Vein View 29; Midesophageal Right Ventricle Inflow-outflow View 30; Lower Esophageal Coronary Sinus View 31; Transgastric Views 32; Probe Manipulation to Achieve Transgastric Views 32; Transgastric Modified Hepatic Vein View 33; Transgastric Two Chamber View 34; Transgastric Apical Short-axis View 35; Transgastric Basal Long-axis View 36; Transgastric Basal Short-axis View 37; Transgastric Mid-papillary Short-axis View 38; Transgastric Right Ventricle Inflow-outflow View 39; Transgastric Right Ventricle Inflow View 40; Transgastric Basal Right Ventricle Outflow View 41; Deep Transgastric Long-axis View 42; Upper Esophageal Aortic Arch Long-axis View 43; Upper Esophageal Aortic Arch Short-axis View 44

4. TEE for Atrial Septal Defect **46**

Poonam Malhotra Kapoor, Vishwas Malik, Milind Hote, V Devagourou, Arun Subramaniam

Pathophysiology 46; Different Types of Arterial Septal Disease 47; Clinical Symptoms of Atrial Septal Defect 49; Clinical Investigations 51; Atrial Septal Defect Echocardiogram 51; Guidelines Where Preoperative Transesophageal Echocardiography for Atrial Septal Defect is Must 52; Preoperative Assessment of TEE 52; Atrial Septal Aneurysms 55; Robotic Atrial Septal Defect Closure 55; TEE for ASD Device Closure 55; TEE for Minimally Invasive ASD Closure 57; Postdevice Closure Assessment 60; Postoperative TEE Assessment 61; Types of 2° ASD and Device Closure 61; Advantages of Minimally Invasive Cardiac Surgery for ASD Closure 63; Spectrum of Minimally Invasive Cardiac Surgery 63; Quantification of 3D Over 2D TEE 64; Future and Controversies 69

5. TEE for Ventricular Septal Defect **70**

Poonam Malhotra Kapoor, Parag Gharde, Sarvesh Pal Singh, Kalpana Irpachi

Types of VSD 70; Clinical Features 71; Clinical Examinations 71; CVS Examination 71; ECG in Ventricular Septic Defect 72; X-ray Findings in Ventricular Septal Defect 73; Transesophageal Echocardiography in Ventricular Septal Defect 74; Preoperative TEE Assessment 74; Postoperative TEE Assessment: Using Same Views as for Unrepaired VSD 78; TEE for VSD Device Closure 78; Ventricular Septal Defect Complications 80; Gerbode Ventricular Septal Defect 80

6. TEE for Atrioventricular Septal Defect **82**

Sarvesh Pal Singh, Poonam Malhotra Kapoor, Arin Choudhury, Arun Subramaniam

Chest X-ray: PAV 83; ECG 83; Transesophageal Echocardiography Views 84; Preoperative Transesophageal Echocardiography 84; Postoperative TEE Assessment 86; Fetal Echocardiogram in AVSD 87; Complications 87; Long-term Outcome 87

7. TEE for Pulmonary Stenosis **89**

Poonam Malhotra Kapoor, Sarvesh Pal Singh, Jitin Narula

Pathophysiology of Pulmonary Stenosis 89; Branch Peripheral Pulmonic Stenosis 90; Causes and Clinical Presentation 90; Infundibular Pulmonary Stenosis 91; Clinical Signs of Pulmonary Stenosis 91; Pulmonary Artery and Vein Stenosis 92; Why is Pulmonary Stenosis a Concern? 92; Severity Definitions of Pulmonary Stenosis 94; Tetralogy of Fallot with Infective Endocarditis 94; Etiology of MPA Endocarditis 94; TEE Assessment of Pulmonary Stenosis 96; Perioperative Cardiopulmonary Bypass (2D Echocardiography Findings) 97; Postoperative Pulmonary Stenosis Assessment 98

8. TEE for Double-Chambered Right Ventricle **99**

Poonam Malhotra Kapoor, Sarvesh Pal Singh, Sanjay Kumar, Balaswaroop Sahu

Natural History of DCRV 99; Associated Anomalies 100; Transesophageal Echocardiography Views of DCRV 100; Role of Echocardiography in Diagnosing Double-chambered Right Ventricle in Adults 100; Preoperative TEE Assessment 100; Electrocardiogram of DCRV 101; Postoperative TEE Assessment 103

9. TEE for Patent Ductus Arteriosus **104**

Poonam Malhotra Kapoor, SN Das, Sarvesh Pal Singh, RS Rajput

Clinical Features of Patent Ductus Arteriosus 104; X-ray 105; ECG 105; Role of TEE in PDA 106; TEE Views for Patent Ductus Arteriosus: For Simultaneous Coarctation of Aorta to be Ruled Out 106; Preoperative TEE Assessment 106; Postoperative TEE Assessment 107; Role of TEE in Percutaneous Device Closure of PDA 107; Echo Assessment Following Repair using the Same Views as for Unrepaired ASD 107

10. TEE for Aortic Coarctation **108**

Poonam Malhotra Kapoor, Suruchi Hasija, Pawan Jain

Clinical Features of Aortic Coarctation 108; Physiology 109; Transesophageal Echocardiographic Evaluation 109; Transesophageal Echocardiography Assessment of Aortic Coarctation 109; Management of Aortic Coarctation 110; Transesophageal Echocardiography Assessment Following Coarctation Repair 110

11. TEE for Tetralogy of Fallot **111**

Poonam Malhotra Kapoor, Milind Hote, Sameer Taneja, Dinesh Chandra

Etiology 111; Components of TOF 111; Embryology 111; Associated Anomalies in TOF 112; Syndromes Associated with TOF 112; Cyanotic Spells in TOF 112; Squatting Episode 113; Clinical Features in TOF 113; Complications 114; Anesthesia Consideration in TOF 115; 3D Transesophageal Echocardiography in TOF 116; Preoperative TEE Assessment 116; Postoperative TEE Assessment 117;

12. TEE for Double Outlet Right Ventricle **120**

Poonam Malhotra Kapoor, Sarvesh Pal Singh, Jitin Narula, Suruchi Ladha

Various Criteria for Classification of DORV 121; Other Anomalies with DORV 121; Aortic Over-ride 122; Chest X-ray 122; Electrocardiography 122; Use of TEE in DORV 122; Two-dimensional TEE for DORV in TOF 123; Ventricular Septal Defect 124; Location of VSD in DORV 124; Preoperative Assessment of DORV on TEE 124; Assessment for Routability of VSD 124; Anatomy and Suggested Two-dimensional Views for Routability of Ventricular Septal Defect 125; Postoperative Assessment of DORV on TEE 125

13. TEE for Transposition of Great Arteries **127**

Sarvesh Pal Singh, Jitin Narula, Poonam Malhotra Kapoor, Sachin Talwar

Preoperative TEE Assessment 127; Transesophageal Echocardiography for Senning Procedure 129; Assessment of the Pulmonary Venous Pathway 130; Assessment of Systemic Venous Pathway 131; Assessment of Baffle 131; Perioperative Care, Post-Senning Operation 131; Postoperative TEE Assessment 132

14. TEE for Congenitally Corrected Transposition of Great Arteries **137**

Poonam Malhotra Kapoor, Sarvesh Pal Singh, Jitin Narula, Sachin Talwar

Corrected Transposition of Great Arteries 138; Preoperative TEE Assessment 138; Postoperative TEE Assessment 141

15. TEE for Ebstein's Anomaly **143**

Poonam Malhotra Kapoor, Sarvesh Pal Singh, Jitin Narula, Pankaj Kumar

Embryology 143; Pathophysiology 143; Clinical Presentation in Ebstein's Anomaly 144; Clinical Implications 144; ECG in Ebstein's Anomaly 145; X-ray in Ebstein's Anomaly 146; Transesophageal Echocardiography for Ebstein's Anomaly 146; Echocardiography of Ebstein's Anomaly 146; Preoperative TEE Assessment: 2D and 3D 146; Postoperative TEE Assessment 148

16. TEE for Double-Inlet Left Ventricle **152**

Poonam Malhotra Kapoor, Sarvesh Pal Singh, Jitin Narula, Suruchi Ladha

Morphology 152; Ventricles 152; Associated Anomalies with DILV 153; Pathophysiology/Natural History of DILV 153; Clinical Presentation 153; Tests to Diagnose DILV 154; Transesophageal Echocardiography of DILV 154

17. TEE for Univentricular Heart **156**

Poonam Malhotra Kapoor, Ujjwal Chowdhury, Sarvesh Pal Singh, Jitin Narula

Morphology 156; Atrioventricular Connections 157; Incidence and Significance 157; Univentricular Physiology 157; Aortopulmonary Shunt 158; Bidirectional Glenn Shunt 158; Total Cavopulmonary Anastomosis 158; Preoperative Assessment 158; Obstruction of Anastomosis 159; Echocardiography of Univentricular Heart 159

18. TEE for Total Anomalous Pulmonary Venous Connection **162**

Poonam Malhotra Kapoor, Vishwas Malik, Umed Kumar, Kulbhushan Saini

Darling's Modification of Types of TAPVC 163; Pathophysiology of TAPVC 163; Total Anomalous Pulmonary Venous Connection (Supracardiac) 164; X-ray Chest PAV in TAPVC 164; X-ray Chest TAPVC 165; ECG in TAPVC 165; Anesthetic Consideration 165; Preoperative Consideration 166; Intraoperative Consideration 166; Preoperative Assessment of 2D TEE for TAPVC 166; Postoperative TEE Assessment 168; 3D TEE 168; 3D TEE for Surgical Technique 168

19. TEE for Cor Triatriatum **169**

Poonam Malhotra Kapoor, Neeti Makhija, Sarvesh Pal Singh

Pathophysiology 169; Embryological Origin 170; Intraoperative TEE 170; Congenital Cardiac Lesions Associated with CTS 171; Differentiation between Supramitral Ring and Cor Triatriatum 171

20. TEE for Left Superior Vena Cava **173**

Sarvesh Pal Singh, Poonam Malhotra Kapoor, Arindam Choudhury

Pathophysiology 173; Importance of LSVC to the Cardiac Surgeon 174; Identification 174; TEE for LSVC Diagnosis 174; LSVC Presence in CHD 175

21. TEE for Pulmonary Artery Hypertension **177**

Poonam Malhotra Kapoor, Minati Choudhury, SN Das, Sarvesh Pal Singh

Causes of Pulmonary Artery Hypertension 178; Chest X-ray Features of PAH 178; Echocardiographic Features in Pulmonary Arterial Hypertension 180; Preoperative 2D TEE Assessment 181; Evaluation with Color Flow Doppler 181

22. TEE for Eisenmenger's Syndrome **184**

Poonam Malhotra Kapoor, Sameer Taneja

Pathophysiology of Eisenmenger's Syndrome 184; Clinical Implications 185; Eisenmenger's Syndrome: A Progressive Disease 186; Eisenmenger's Physiology: Clinical Assessment 186; Choices 186; 2D Echo: Eisenmenger's Syndrome 188; Different Congenital Intracardiac or Extracardiac Defects can Cause Eisenmenger's Syndrome 190; Echo Predictors 191

23. TEE for Patent Foramen Ovale **193**

Poonam Malhotra Kapoor, Arin Choudhury, Jitin Narula, Sanjay Kumar

Structure of Patent Foramen Ovale 194; Clinical Features of Patent Foramen Ovale 194; Detection of a Right-to-left Shunt through a PFO 194; Transesophageal Echocardiogram 194; Preoperative TEE Assessment of Patent Foramen Ovale 195; Postoperative Echo Assessment Following Repair 195

24. TEE for Tricuspid Atresia **196**

Poonam Malhotra Kapoor, Sachin Talwar, Parag Gharde, Sameer Taneja

Anatomy 196; Etiology and Clinical Features 196; Chest X-ray of Tricuspid Atresia 197; ECG Findings 198; Case Presentation 198; TEE Confirms the Diagnosis of Tricuspid Atresia 199

25. Echo Resources **201**

Poonam Malhotra Kapoor, Kalpana Irpachi

Echo Resources 201; Societies 203; Websites 203

Index *205*

DVD Contents

Chapter 3
TEE VIEWS IN CONGENITAL HEART DISEASE

S. No. Video Name

1. *Video 1:* Midesophageal four chamber view for identification of four chambers, IAS, IVS, MV and TV.
2. *Video 2:* Midesophageal two chamber view to show the LV and LA and also provide detailed evaluation of the mitral valve and regional assessment of the LV anterior and inferior walls.
3. *Video 3:* Midesophageal bicommissural view for a detailed view of LA, LV and MV leaflets and their scallops.
4. *Video 4:* Midesophageal long-axis view for LV function, MV disease, AV and aortic root disease to view the aortic over-ride and IVS in detail.
5. *Video 5:* Midesophageal aortic valve long-axis view showing the aortic and mitral valves and regional assessment of LV, also excellent for aortic annulus and AML length.
6. *Video 6:* Midesophageal aortic valve short-axis view the 3 cusps of AV, calcification in the 3 cusps, presence and quantification of AS and AR.
7. *Video 7:* Midesophageal bicaval view outline and video to see the IAS.
8. *Video 8:* Midesophageal descending thoracic aorta long-axis view showing the descending thoracic aorta in the center.
9. *Video 9:* Midesophageal descending thoracic aorta short-axis view showing the descending thoracic aorta. Ideal for IABP placement evaluation and see left pleural effusion.
10. *Video 10:* Midesophageal ascending aorta long-axis view showing the relation of the RPA and aorta.
11. *Video 11:* Midesophageal ascending aorta short-axis view showing the ascending aorta, superior vena cava (short-axis), main pulmonary artery, right pulmonary artery, left pulmonary artery (turn probe tip to left), pulmonic valve.
12. *Video 12:* Midesophageal left atrial appendage view showing left atrial appendage and left upper pulmonary valve.
13. *Video 13:* Midesophageal modified bicaval view showing right atrial appendage and superior vena cava.
14. *Video 14:* Midesophageal right pulmonary vein view to show the position between aorta, superior vena cava and the right pulmonary artery, seen to the right side in figure B.
15. *Video 15:* Midesophageal right ventricle inflow-outflow view showing the right ventricle and atrium, left atrium, right atrium tricuspid valve, aortic valve, right ventricle outflow tract, pulmonic valve and main pulmonary artery.
16. *Video 16*
17. *Video 17:* Transgastric modified hepatic vein view showing anterior vena cava, hepatic veins and right atrium.
18. *Video 18:* Transgastric two chamber view showing left ventricle and atrium coronary sinus and mitral valve.
19. *Video 19:* Transgastric apical short-axis view showing left and right ventricle.
20. *Video 20:* Transgastric basal long-axis view showing mitral leaflets, mitral subvalvular apparatus, left ventricle (anteroseptal and inferolateral walls: basal and mid segments), LV outflow tract, aortic valve and proximal ascending aorta.
21. *Video 21:* Transgastric basal short-axis view showing mitral and tricuspid valve.
22. *Video 22:* Transgastric mid-papillary short-axis view showing left and right ventricles and papillary muscles.
23. *Video 23:* Transgastric right ventricle inflow-outflow view showing right atrium, PV and TV, RV.
24. *Video 24:* Transgastric right ventricle inflow view showing right ventricle and atrium, tricuspid valve: Chordae and papillary muscles.
25. *Video 25:* Transgastric basal right ventricle outflow view showing LV, RV, TV and PV.
26. *Video 26:* Deep transgastric long-axis view showing left ventricle and outflow tract, interventricular septum, aortic valve and ascending aorta, left atrium, mitral valve, right ventricle, pulmonic valve.
27. *Video 27:* Upper esophageal aortic arch long-axis view showing aortic arch, innominate vein and mediastinal tissue.
28. *Video 28:* Upper esophageal aortic arch short-axis view showing aortic arch, left brachiocephalic vein, pulmonary artery and pulmonic valve.

Chapter 4
TEE FOR ATRIAL SEPTAL DEFECT

S. No. Video Name

1. *Video 1:* 2D assessment of atrial septal defect. Midesophageal 4 chamber view (probe rotated to right) showing interatrial septal aneurysm and an ostium secundum atrial septal defect. The repair of the defect in such a scenario is done by excising the interatrial septum aneurysm and closing the atrial septal defect with a prosthetic or pericardial (in case of associated mitral regurgitation) patch. Also seen is the tricuspid value and superior vena cava.
2. *Video 2:* 2D assessement of mitral valve in atrial septal defect. Transgastric basal view showing the anterior mitral leaflet, postcleft repair in a patient with ostium primum atrial septal defect and moderate mitral regurgitation.
3. *Video 3:* Color Doppler assessment of atrial septal defect. Midesophageal bicaval view showing superior vena cava type sinus venosus atrial septal defect shunting from left to right.
4. *Video 4:* 2D echo showing percutaneous closure of an ostium secundum atrial septal defect. The catheter containing the amplatzer ductal occluder device is seen traversing the atrial septal defect.
5. *Video 5:* 2D and Color Doppler assessment of atrial septal defect. Midesophageal bicaval view showing superior vena cava type sinus venosus atrial septal defect shunting from left to right.
6. *Video 6:* Color Doppler echocardiography in a patient for percutaneous atrial septal defect closure. The catheter containing the amplatzer septal occluder is seen traversing the atrial septal defect. A small mosaic jet is seen along the catheter.
7. *Video 7:* Color Doppler in midesophageal right ventricle inflow-outflow view showing the deployed amplatzer septal occlude device without any residual shunt across the atrial septal defect. In this view it may appear that the left rim of the device is resting on the aortic valve but this finding is just because of the angle at which the device is being imaged. In the midesophageal 4 chamber view it was clear that the aortic valve is free from the device.
8. *Video 8:* Color Doppler in midesophageal 4 chamber view showing a fully deployed and well approximated amplatzer septal occluder with no residual shunt and free of mitral valve annulus.
9. *Video 9:* Color Doppler in midesophageal right ventricle inflow-outflow view showing a fully deployed and well approximated amplatzer septal occluder with no residual shunt and free of mitral valve annulus.
10. *Video 10:* Color Doppler in midesophageal descending thoracic aortic long axis view showing blood flow through abdominal aorta on cardiopulmonary bypass when perfused via a femoral artery cannula during Robotic cardiac surgery.
11. *Video 11:* 2D echo for percutaneous cannulation of superior vena cava. Midesophageal bicaval view showing superior vena cava cannula for robotic atrial septal defect closure. The cannula tip is in the right atrium which is the incorrect position of the cannula.
12. *Video 12:* 2D echo for percutaneous cannulation of superior vena cava. Midesophageal bicaval view showing superior vena cava cannula for robotic atrial septal defect closure. The cannula tip is at the junction of right atrium and superior vena cava which is the correct position of the cannula.
13. *Video 13:* 2D echocardiography showing midesophageal descending thoracic aorta short axis view progressing to long axis view. This is the ideal view to visualize the retrograde guidewire insertion during cannulation of femoral artery in Redo surgeries, Robotic cardiac surgeries and placement of intra-aortic counterpulsation balloon. The tip of intra-aortic counterpulsation balloon may also be located in this view.
14. *Video 14:* Color Doppler echocardiography showing blood flow in the midesophageal descending thoracic aorta long axis view. Note the nonpulsatile nature of blood flow because the patient is on cardiopulmonary bypass. The flow is from left side of image towards right side of image.
15. *Video 15:* Color Doppler echocardiography showing blood flow in the midesophageal descending thoracic aorta long axis view. Note the pulsatile nature of blood flow and the flow is from right of image towards left of image.
16. *Video 16:* 2D echo showing the placement of guidewire in descending thoracic aorta for cannulation of the femoral artery. The arterial cannula is not visible because it rarely traverses the abdominal aorta.
17. *Video 17:* Color Doppler in midesophgeal descending thoracic aortic long axis view showing blood flow through abdominal aorta on cardiopulmonary bypass when perfused via a femoral artery cannula.
18. *Video 18:* 2D echocardiography in midesophgeal bicaval view showing the placement of guidewire for percutaneous placement of superior vena cava cannula. The guidewire is hitting the interatrial septum causing arrhythmias.
19. *Video 19:* 2D echo for percutaneous inferior vena cava cannulation. Modified hepatic vein view showing guidewire placement for the placement of inferior vena cava cannula. The cannula should be 1 cm proximal to the inferior vena cava right atrial junction.
20. *Video 20:* Color Doppler in modified hepatic vein view showing the confluence of hepatic and portal vein to form the inferior vena cava.

21. *Video 21:* 2D echocardiography in modified hepatic vein view showing the placement of guidewire for percutaneous cannulation of inferior vena cava cannula.
22. *Video 22:* Color Doppler echocardiography showing the draining of inferior vena cava into right atrium in the modified deep transgastric view.
23. *Video 23:* 2D echocardiography in midesophageal view showing left atrial hematoma after minimally invasive cardiac surgery.
24. *Video 24:* 2D echo for percutaneous cannulation of superior vena cava. Midesophageal bicaval view showing superior vena cava cannula for robotic atrial septal defect closure. The cannula tip is at the junction of right atrium and superior vena cava which is the correct position of the cannula.
25. *Video 25:* 2D echo for percutaneous cannulation of superior vena cava. Midesophageal bicaval view showing superior vena cava cannula for robotic atrial septal defect closure. The cannula tip is in the right atrium which is the incorrect position of the cannula.

Chapter 5
TEE FOR VENTRICULAR SEPTAL DEFECT

S. No. Video Name

1. *Video 1:* Color Doppler midesophageal aortic valve short axis view showing left superior pulmonary vein stenosis in a patient with VSD.
2. *Video 2:* Color Doppler modified midesophageal aortic valve short axis view showing flow across left superior pulmonary vein after resection of membrane.
3. *Video 3:* 2D assessement of mitral valve in atrial septal defect. Transgastric basal view showing the anterior mitral leaflet postcleft repair in the same patient with ostium primum atrial septal defect and moderate mitral regurgitation.
4. *Video 4:* 2D echocardiography in midesophageal aortic valve short axis view showing prolapse of septal leaflet of TV into subaortic VSD causing closure of ventricular septal defect.
5. *Video 5:* 3D echocardiography in deep transgastric view showing a subaortic ventricular septal defect just adjoining the septal leaflet of tricuspid valve.
6. *Video 6:* 2D echocardiography in deep transgastric view showing a subaortic ventricular septal defect just adjoining the septal leaflet of tricuspid valve.
7. *Video 7:* 2D echocardiography in deep transgastric view showing a subaortic ventricular septal defect just adjoining the septal leaflet of tricuspid valve and beneath the aortic valve.
8. *Video 8:* 2D echocardiography in deep transgastric view showing subaortic membrane (complete) just below aortic valve.
9. *Video 9:* 2D echocardiography in deep transgastric view showing (closer look) subaortic membrane (complete) just below aortic valve.
10. *Video 10:* Color Doppler in midesophageal long axis view showing subaortic membrane (partial) just below aortic valve.
11. *Video 11:* 2D echocardiography in deep transgastric view showing a supramitral ring (complete).

Chapter 7
TEE FOR PULMONARY STENOSIS

S. No. Video Name

1. *Video 1:* Tetralogy of Fallot in pulmonary stenosis.
2. *Video 2:* Double chamber right ventricular in pulmonary stenosis.
3. *Video 3:* Pulmonary insufficiency.
4. *Video 4:* Transesophageal echocardiography of pulmonary stenosis.
5. *Video 5:* Atrial septal defects in pulmonary stenosis.

Chapter 8
TEE FOR DOUBLE-CHAMBERED RIGHT VENTRICLE

S. No. Video Name

1. *Video 1:* 2D echo in midesophageal right ventricle inflow-ouflow view showing a perimembranous ventricular septal defect and a muscle bundle obstructing the flow in right ventricular outflow tract in a patient with double chambered right ventricle.
2. *Video 2:* 2D echo in midesophageal right ventricle inflow-ouflow view showing the repair of ventricular septal defect with a Dacron patch and resection of the muscle bundle leading to a patent right ventricular outflow tract.

Chapter 9
TEE FOR PATENT DUCTUS ARTERIOSUS

S. No. Video Name

1. *Video 1:* Color flow Doppler in modified ME descending thoracic aorta short axis view (Probe rotated to right to visualize left pulmonary artery) showing patent ductus arteriosus.

Chapter 11
TEE FOR TETRALOGY OF FALLOT

S. No. Video Name

1. *Video 1:* 2D echo deep transgastric view showing a subaortic ventricular septal defect and aortic over-ride

in a patient with Tetralogy of Fallot. The aortic root is always enlarged because of the over-ride.

2. *Video 2:* 2D echocardiography in mid papillary transgastric view showing normal left ventricular function.
3. *Video 3:* 2D echocardiography in upper esophageal ascending aortic short axis view showing pulmonic valve stenosis.
4. *Video 4:* Color Doppler in midesophageal long axis view showing a subaortic ventricular septal defect shunting from left to right and infundibular pulmonary stenosis in a patient with Tetralogy of Fallot.
5. *Video 5:* 2D echo in midesophageal right ventricle inflow-outflow view showing subaortic ventricular septal defect and infundibular pulmonary stenosis in a patient with Tetralogy of Fallot.
6. *Video 6:* Color Doppler in midesophageal right ventricle inflow-outflow view showing subaortic ventricular septal defect and infundibular pulmonary stenosis in a patient with Tetralogy of Fallot.

Chapter 12
TEE FOR DOUBLE-OUTLET RIGHT VENTRICLE

S. No. Video Name

1. *Video 1:* 2D echocardiography in midesophageal long axis view showing a subaortic ventricular septal defect with over-riding of aorta (>50% in this case) in a patient with double-outlet right ventricle.
2. *Video 2:* 2D echocardiography in deep transgastric long axis view showing a subaortic ventricular septal defect with over-riding of aorta (>50% in this case) in a patient with double-outlet right ventricle. Because of so much of over-ride the right ventricle ejects directly into the aorta. Note the mitral valve in its cross-section.

Chapter 13
TEE FOR TRANSPOSITION OF GREAT ARTERIES

S. No. Video Name

1. *Video 1:* 2D echo for assessment of ventricular septal defect in transposition of great arteries. The echocardiogram shows an anterior muscular ventricular septal defect with a subpulmonic extension. In transposition of great arteries, the pulmonary artery is arising from left ventricle, hence the extension towards systemic outflow is no more subaortic but subpulmonic.
2. *Video 2:* 2D echo showing the atrial baffle post-double switch operation. Left atrium (constructed by pericardium posteriorly is now directed to the left ventricle and the left ventricle now ejects into the aorta (arterial switch done).
3. *Video 3:* 2D echo for evaluation of regressed left ventricle in transposition of great arteries. Transgastric midpapillary short axis view showing the comparative shape and size of both the right and left ventricles. Note the banana shaped left ventricle and well developed right ventricle.
4. *Video 4:* 2D echo for evaluation of regressed left ventricle in transposition of great arteries. Midesophageal 4 chamber view showing a restrictive upper muscular ventricular septal defect in a patient with transposition of great arteries.
5. *Video 5:* 2D echo for assessment of ventricular septal defect in transposition of great arteries. The midesophageal 4 chamber view shows a large inlet ventricular septal defect with both the ventricles lying side by side.
6. *Video 6:* 2D echo and color Doppler assessment of transposition of great arteries. The midesophageal long axis view shows accessory mitral tissue in the left ventricular tract causing obstruction and gradient across left ventricular outflow tract.
7. *Video 7:* 2D echo for assessment of transposition of great arteries. The midesophageal long axis view showing the connection from left atrium to left ventricle to pulmonary artery.
8. *Video 8*: 2D echo for assessment of transposition of great arteries. The midesophageal long axis view showing the connection from right atrium to right ventricle to aorta.

Chapter 14
TEE FOR CONGENITALLY CORRECTED TRANSPOSITION OF GREAT ARTERIES

S. No. Video Name

1. *Video 1:* 2D echo in midesophageal long axis view showing the relation between aorta and pulmonary artery. Right ventricle ejects into aorta which is anterior to pulmonary artery.
2. *Video 2:* 2D echo in midesophageal 4-chamber view showing perimembranous ventricular septal defect with right atrium opening into left ventricle and left ventricle ejecting into pulmonary artery.
3. *Video 3:* 2D echocardiography in midesophageal 4-chamber view, of a patient who has undergone "Double Switch Operation", showing an atrial baffle made from atrial wall. The neo left atrium made from pericardium is seen opening into the left ventricle and the left ventricle ejecting into the aorta.
4. *Video 4:* 2D echo in transgastric midpapillary short axis view showing left and right ventricles (crescent-shaped) after a Double Switch Operation. Note the underfilled morphologic right ventricle.
5. *Video 5:* 2D echocardiography in deep transgastric view showing the cross-section of tricuspid valve morphological right ventricle ejecting in the aorta in a patient with congenitally corrected transposition of great arteries.

6. *Video 6:* 2D echo post-Double Switch Operation (Senning + Rastelli procedure) showing pulmonary artery conduit arising from right ventricle on left side of screen.
7. *Video 7:* Color Doppler post-Double Switch Operation (Senning + Rastelli procedure) showing unobstructed blood flow through pulmonary artery conduit arising from right ventricle on left side of screen
8. *Video 8:* Color Doppler post-Double Switch Operation (Senning + Rastelli procedure) showing unobstructed blood flow from inferior vena cava to the right atrium.
9. *Video 9:* 2D echo post-Double Switch Operation (Senning + Rastelli procedure) showing a Dacron patch between the atria used to create the baffle.
10. *Video 10:* Color Doppler post-Double Switch Operation (Senning + Rastelli procedure) showing unobstructed blood flow in the left atrium.
11. *Video 11:* 2D echo in a patient with congenitally corrected transposition of great arteries showing the corrected anatomy after the Double Switch Operation (Senning + Rastelli procedure).

Chapter 15
TEE FOR EBSTEIN'S ANOMALY

S. No. Video Name

1. *Video 1:* TEE image of a patient with Ebstein's anomaly showing apical displacement of the TV leaflet and the thin, "atrialized" portion of the affected right ventricular wall.
2. *Video 2 to 6:* The septal leaflet of the TV was tethered to the ventricular septum. Showing the dilated RV and "dubble appearance".

Chapter 16
TEE FOR DOUBLE-INLET LEFT VENTRICLE

S. No. Video Name

1. *Video 1:* 2D echo in transgastric basal view showing both the atrioventricular valves opening into the single large morphological left ventricle (seen from the apex of heart).
2. *Video 2:* 2D echocardiography in midesophageal 4 chamber view showing a dextroposed aorta from morphological left ventricle in a patient with double-inlet left ventricle.
3. *Video 3:* TEE in bicaval view showing discard out LV instead of RV.

Chapter 17
TEE FOR UNIVENTRICULAR HEART

S. No. Video Name

1. *Video 1:* 2D echo in midesophageal bicaval view (probe turned to right) showing thrombus in the conduit of the Fontan circulation. Note the spontaneous echo contrast proximal to the thrombus.
2. *Video 2:* 2D echo in midesophageal bicaval view (probe turned to right) showing thrombus in the conduit of the Fontan circulation.
3. *Video 3:* Color Doppler echocardiography, in modified midesophageal bicaval view (probe turned to right), showing stenosis of the anastomosis between prosthetic conduit and inferior vena cava in a patient who has undergone Fontan operation.
4. *Video 4:* Color Doppler echocardiography, in modified midesophageal bicaval view (probe turned to right), showing stenosis of the anastomosis between prosthetic conduit and inferior vena cava in a patient who has undergone Fontan operation.

Chapter 18
TEE FOR TOTAL ANOMALOUS PULMONARY VENOUS CONNECTION

S. No. Video Name

1. *Video 1:* 2D echo in midesophageal 4 chamber view showing a dilated coronary sinus which is present in coronary sinus total anomalous pulmonary vein connection.
2. *Video 2:* Color Doppler in midesophageal 4 chamber view showing increased blood flow through the coronary sinus indicative of coronary sinus total anomalous pulmonary vein connection.

Chapter 20
TEE FOR LEFT SUPERIOR VENA CAVA

S. No. Video Name

1. *Video 1:* 2D echo in midesophageal modified aortic valve short axis view (probe rotated to left) showing left superior vena cava as a distinct entity near the left atrial appendage.
2. *Video 2:* 2D echo in midesophageal 4 chamber view showing a distinct vessel near the lateral annulus of mitral valve. Left superior vena cava is seen (arrow).
3. *Video 3:* Color Doppler in midesophageal modified aortic valve short axis view (probe rotated to left) showing blood flow in left superior vena cava near the left atrial appendage.

All above videos do not have voice over

Chapter 3

TEE Views in Congenital Heart Disease

Sarvesh Pal Singh, Poonam Malhotra Kapoor

Chapter Outline

- Midesophageal Four Chamber View
- Midesophageal Two Chamber View
- Midesophageal Bicommissural View
- Midesophageal Long-axis View
- Midesophageal Aortic Valve Long-axis View
- Midesophageal Aortic Valve Short-axis View
- Midesophageal Bicaval View
- Midesophageal Descending Thoracic Aorta Long-axis View
- Midesophageal Descending Thoracic Aorta Short-axis View
- Midesophageal Ascending Aorta Long-axis View
- Midesophageal Ascending Aorta Short-axis View
- Midesophageal Left Atrial Appendage View
- Midesophageal Modified Bicaval View
- Midesophageal Right Pulmonary Vein View
- Midesophageal Right Ventricle Inflow-Outflow View
- Lower Esophageal Coronary Sinus View
- Transgastric Views
- Probe Manipulation to Achieve Transgastric Views
- Transgastric Modified Hepatic Vein View
- Transgastric Two Chamber View
- Transgastric Apical Short-axis View
- Transgastric Basal Long-axis View
- Transgastric Basal Short-axis View
- Transgastric Mid-papillary Short-axis View
- Transgastric Right Ventricle Inflow-Outflow View
- Transgastric Right Ventricle Inflow View
- Transgastric Basal Right Ventricle Outflow View
- Deep Transgastric Long-axis View
- Upper Esophageal Aortic Arch Long-axis View
- Upper Esophageal Aortic Arch Short-axis View

INTRODUCTION

Transesophageal echocardiography (TEE) has the unique advantage of portability and the ability to obtain high-resolution images of the abnormal cardiovascular anatomy, function and is relatively easy to perform with a low risk of complications.

Transesophageal echocardiography use has become an integral part in the care of cardiac surgical patients.

JAYPEE BROTHERS

This is evolving to be used in other subspecialties. The purpose of this article is to introduce the novice echocardiographer to a stepwise approach in image orientation and acquisition in TEE for CHD. This chapter is based on the ASE Guidelines (J Am Soc Echocardiogr. 2013;26:921-64) which give 28 essential TEE views for a comprehensive TEE examination in a child/infant/neonate, which is a step up from the previous 20 essential TEE views **(Tables 1 to 3)**.

TABLE 1 Recommended transesophageal echocardiography

Window (depth from incisors)	*Cross section*	*Multiplane angle range*	*Structure imaged*
UE (20–25 cm)	Aortic arch LAX	0°	Aortic arch, left brachiocephalic vein
	Aortic arch SAX	90°	Aortic arch, PA, PV, left brachiophalic vein
Midesophageal (30–40 cm)	Four chamber	0°–20°	LV, LA, RA, MV, TV, IAS
	Mitral commissural	60°–70°	MV, LV, LA, LAA
	Two chamber	80°–100°	LV, LA, LAA, MV
	LAX	120°–160°	LV, LA, AV, LVOT, MV, ascending aorta
	RV inflow-outflow	60°–90°	RV, RA, TV, RVOT, PV, PA
	AV SAX	30°–60°	AV, IAS, coronary ostia, LVOT, PV
	AV LAX	120°–160°	AV, LVOT, proximal ascending aorta, right PA
	Bicaval	80°–110°	RA, SVC, IVC, IAS, LA, CS
	Ascending aortic SAX	0°–60°	Ascending aorta, SVC, PA, right PA
	Ascending aortic LAX	100°–150°	Ascending aorta, right PA
	Descending aorta SAX	0°	Descending thoracic aorta, left pleural space
	Descending aorta LAX	90°–110°	Descending thoracic aorta, left pleural space
TG (40–50 cm)	Basal SAX	0°–20°	LV, MV, RV, TV
	Mid – SAX	0°–20°	LV, RV, papillary muscles
	Two chamber	80°–100°	LV, MV, chordae, papillary muscle, CS, LA
	LAX	0°–120°	LVOT, AV, MV
	RV inflow	100°–120°	RV, TV, RA, TV chordae, papillary muscle
Deep TG (45–50 cm)	LAX	0°–20°	LVOT, AV, ascending aorta, arch

JAYPEE BROTHERS

TABLE 2 Minimal perioperative transesophageal echocardiography study (II)

YOE view		*Structure seen*	*Information provided*
	TG mid SAX	RV free wall; ventricular septum; LV anterior, lateral, inferior, posterior wall	Global and regional LV and RV function, wall thickness. Hypertrophy? Preload?
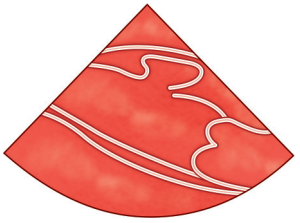	TG LAX	LV posterior wall, anterior septum, papillary muscles, mitral valve, LVOT, aortic valve	Global and regional LV function, aortic flow (Doppler). LVOT obstruction? Aortic stenosis? Aortic regurgitation?
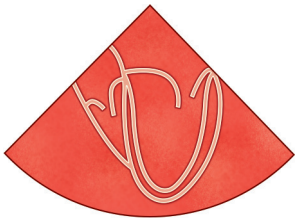	MOE four chamber	RA, tricuspid valve, RY, atrial and ventricular septum, LA, mitral valve, LV lateral wall	Global and regional RV and LV function, LA, RA size, function, masses, septal shape, transmitral flow (Doppler). Tricuspid. mitral regurgitation? Mitral stenosis? SAM?
	MOE two chamber	LA, LA appendage, mitral valve, LV inferior and anterior wall	Global and regional LV function, transmitral flow (Doppler). Mitral regurgitation, stenosis?
	MOE LAX	LA, mitral valve. LVOT, aortic valve, LV anteroseptal and posterior wall	Global and regional LV function, SAM? Aortic stenosis, regurgitation?

JAYPEE BROTHERS

TABLE 3 Minimal perioperative transesophageal echocardiography study (II)

YOE view		*Structure seen*	*Information provided*
	MOE AV SAX	AV, cusps, sinuses of Valsalva, coronary ostia	Tricuspid or bicuspid valve? Cusp mobility, valve opening area. Aortic stenosis? Vegetations?
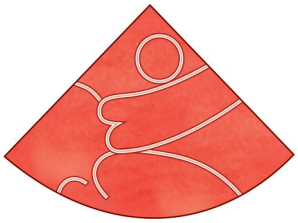	MOE AV LAX	AY, cusps, aortic root, sinotubular junction, ascending aorta, right pulmonary artery SAX	Aortic dimensions, wall composition, cusp mobility. Aortic stenosis, regurgitation? Dissection? Aneurysm? Atheroma?
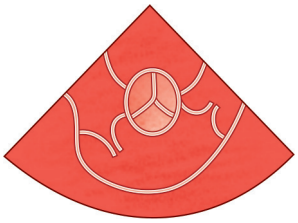	MOE RV inflow-outflow	RA, tricuspid valve, RV inflow and outflow tract, pulmonary valve, main pulmonary artery LAX	RV global and regional function. Tricuspid, pulmonary regurgitation? RV systolic pressure (Doppler), thrombi? Foreign bodies
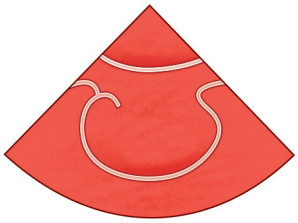	MOE bicaval	LA, atrial septum, inferior and superior caval veins, RA	Septum shape and motion. Open foramen ovale? Atrial septum defect? Thrombi?
	Descending aortic SAX	Aortic wall and lumen, posterior mediastinum	Aneurysm? Dissection? Rupture? Atheroma? Interamural/periaortic hematoma? Effusion?

JAYPEE BROTHERS

MIDESOPHAGEAL FOUR CHAMBER VIEW

- **Multiplane angle range:**
  - 0–20 degrees
  - *Sector depth:* ~ 12–14 cm
- **Anatomy imaged:**
  - Left ventricle and atrium
  - Right ventricle and atrium
  - Mitral and tricuspid valves
  - Interatrial and interventricle septum
- **Clinical utility (Figs 1A to C):**
  - *Ventricle function:* Global and regional
  - *Intracardiac chamber masses:* Thrombus, tumor, air, foreign bodies
  - *Mitral and tricuspid valve evaluation:* Pathology, pathophysiology
  - Congenital or acquired interatrial and ventral septal defects
  - Hypertrophic obstructive cardiomyopathy evaluation.

Probe Manipulation

- The ME four-chamber view is obtained by turning the probe to the left (counterclockwise rotation of the probe) or to the right (clockwise rotation of the probe) is performed to center the mitral valve (MV) and left ventricle in the sector display.
- The image depth is then adjusted to ensure viewing of the left ventricular (LV) apex. The multiplane angle should be rotated to approximately 10 to 20 until the aortic valve (AV) or LV outflow tract (LVOT) is no longer in the display and the tricuspid annular dimension is maximized. Because the apex is at a slightly inferior plane to the left atrium, slight retroflexion may be required to align the MV and LV apex.

A color flow Doppler sector with the Nyquist limit set at 50 to 60 cm/sec should be placed over both the MV and TV to aid in the identification of valvular pathology (regurgitation and/or stenosis), as well as to the IAS to identify shunt flow.

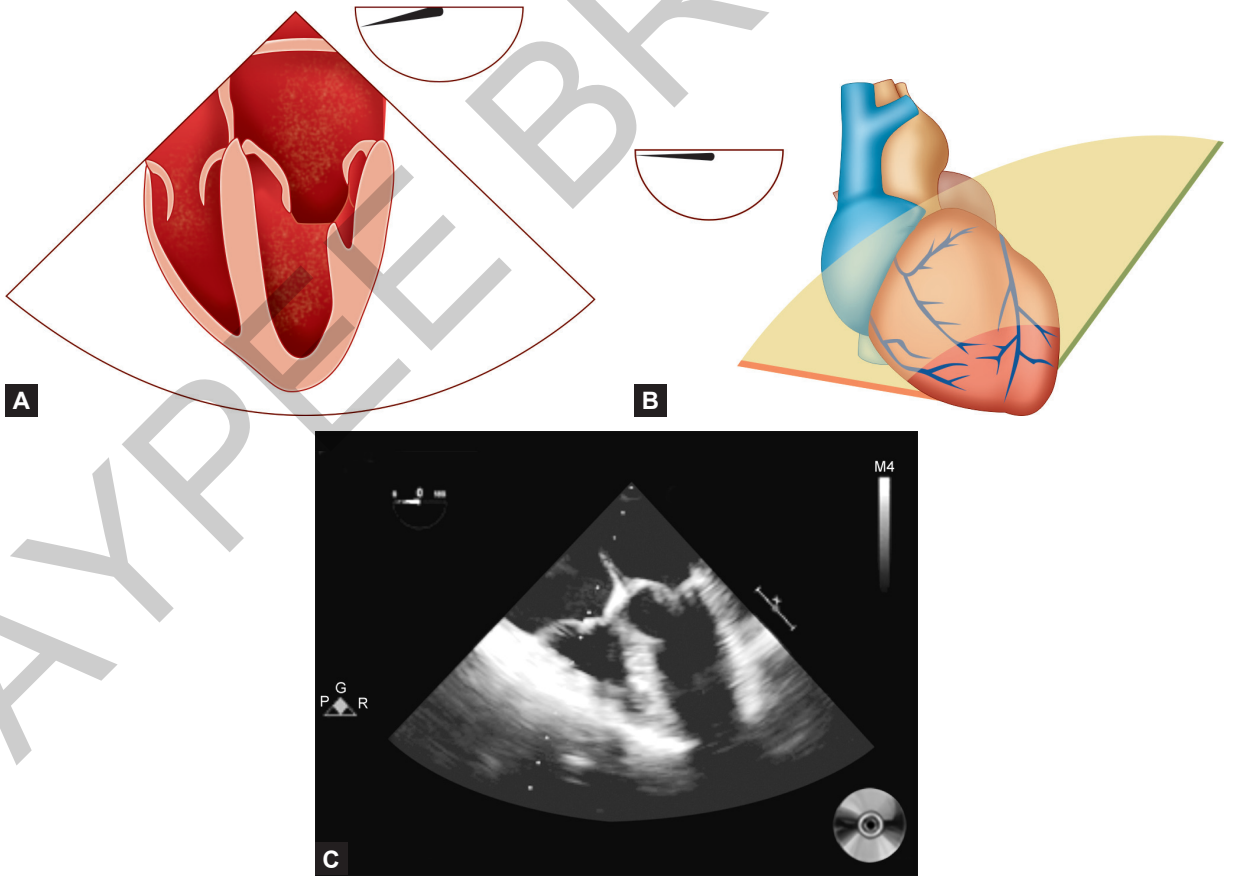

Figures 1A to C (A) Midesophageal four chamber view; (B) Animation of midesophageal four chamber view; (C) **(Video 1)** Midesophageal four chamber view for identification of four chambers, IAS, IVS, MV and TV

JAYPEE BROTHERS

MIDESOPHAGEAL TWO CHAMBER VIEW

- **Multiplane angle range:**
  - 80–100 degrees
  - *Sector depth:* ~ 12–14 cm
- **Anatomy imaged left ventricle, atrium, and atrial appendage:**
  - Mitral valve
  - *Left pulmonary veins:* Turning probe to left
  - Coronary sinus (short-axis or long-axis by turning probe tip to left)
  - Left atrium
  - Left ventricle
  - Left atrial appendage
- **Clinical utility (Figs 2A and B):**
  - *Left ventricle function:* Global and regional
  - *Left ventricle and atrial masses:* Thrombus, tumor, air, foreign bodies
  - *Mitral valve evaluation:* Pathology, pathophysiology
  - Ventricular diastolic evaluation via transmitral and pulmonary vein Doppler flow profile analysis
  - *Coronary sinus evaluation:* Coronary sinus catheter placement; dilation secondary to persistent left superior vena cava.

Probe Manipulation

- From the ME four-chamber view, rotating the multiplane angle forward to between 80 and 100 degrees until the right ventricle disappears from the image the ME two-chamber view will develop.
- Diagnostic information obtained from this view includes global and regional LV function, MV function, and regional assessment of the LV anterior and inferior walls.
- The basal inferior and mid inferior wall segments are perfused by the RCA, whereas the apical inferior, apical cap, apical anterior, mid anterior, and basal anterior wall segments are perfused by the LAD coronary artery.

A color flow Doppler sector with the Nyquist limit at 50 to 60 cm/sec should be applied over the MV to aid in the identification of valvular pathology (regurgitation and/or stenosis). The coronary sinus is seen in short-axis (SAX), as a round structure immediately superior to the basal inferior LV segment.

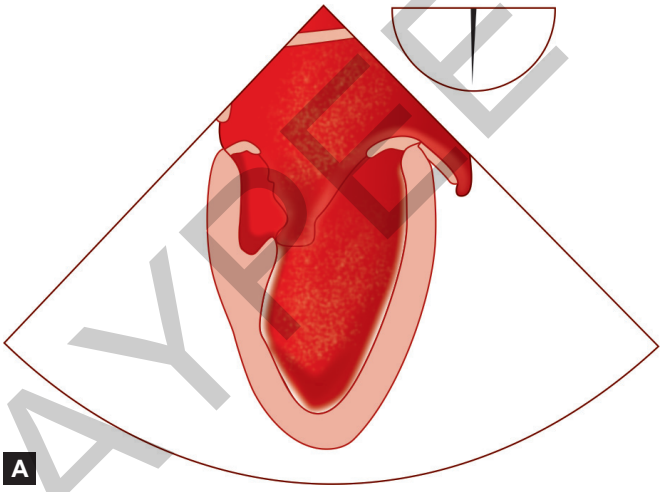

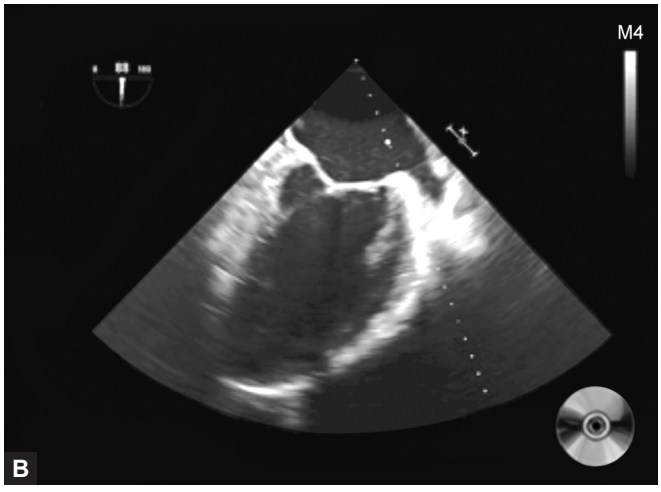

Figures 2A and B (A) Outline of midesophageal two chamber view; (B) **(Video 2)** Midesophageal two chamber view to show the LV and LA and also provide detailed evaluation of the mitral valve and regional assessment of the LV anterior and inferior walls

JAYPEE BROTHERS

MIDESOPHAGEAL BICOMMISSURAL VIEW

- **Multiplane angle range:**
  - 60–70 degrees
  - *Sector depth:* ~ 12 cm
- **Anatomy imaged:**
  - Left ventricle and atrium
  - Mitral valve
- **Clinical utility (Figs 3A to D):**
  - *Left ventricle function:* Global and regional
  - *Left ventricle and atrial masses:* Thrombus, tumor, air, foreign bodies
  - *Mitral valve evaluation:* Pathology, pathophysiology
  - Ventricular diastolic evaluation via transmitral Doppler flow profile analysis.

Probe Manipulation

- From the ME four-chamber view, rotating the transducer angle to between 60 and 70 will generate the ME mitral commissural view.
- Extreme turning of the probe to the right and left enables visualization of parts of the MV annulus (or sewing ring of prosthetic valves).
- In addition, the anterolateral and posteromedial papillary muscles with their corresponding chordae are prominent structures in the ME commissural view.
- Diagnostic information obtained from this view includes regional LV function, anterior/anterolateral and inferior/inferolateral walls and MV function and left atrial appendage.

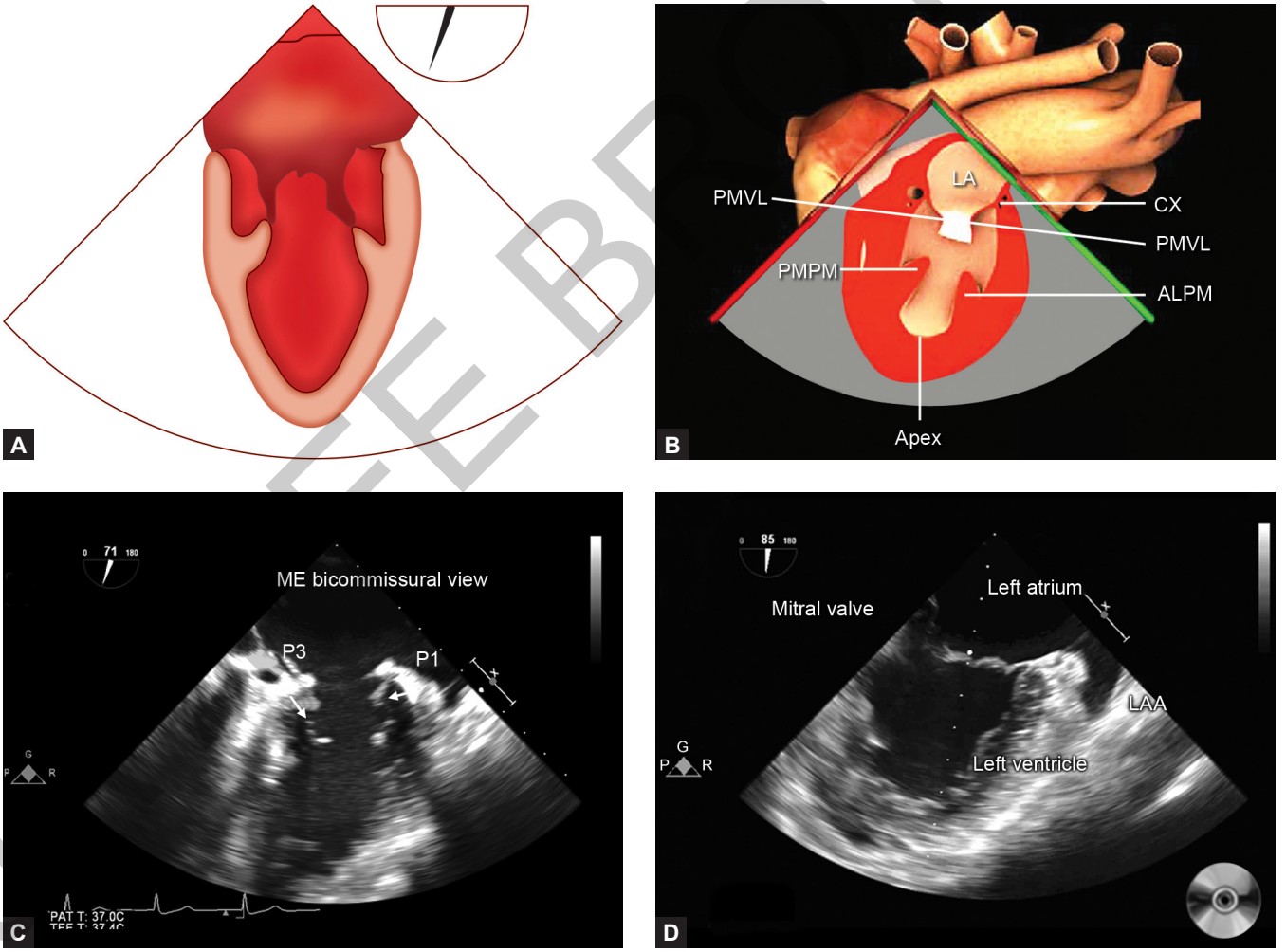

Figures 3A to D (A) Outline of midesophageal bicommissural view; (B) Simulator of midesophageal bicommissural view; (C) Midesophageal bicommissural view; (D) **(Video 3)** Midesophageal bicommissural view for a detailed view of LA, LV and MV leaflets and their scallops

JAYPEE BROTHERS

MIDESOPHAGEAL LONG-AXIS VIEW

- **Transducer angle:**
  - 120 degrees
- **Level:**
  - Midesophageal
- **Maneuver (from prior image):**
  - Anteflex
- **Clinical utility (Figs 4A to C):**
  - LV function
  - MV disease
  - AV and aortic root disease
  - Interventricular septum pathology.

Probe Manipulation

Increasing the omni, while slightly rotating the probe counterclockwise brings in the long-axis view, with similar structures seen as that in the parasternal long-axis and apical long-axis of transthoracic echo. This is the best view to look at the LVOT and anteroseptum as well as A2 and P2 of the mitral valve.

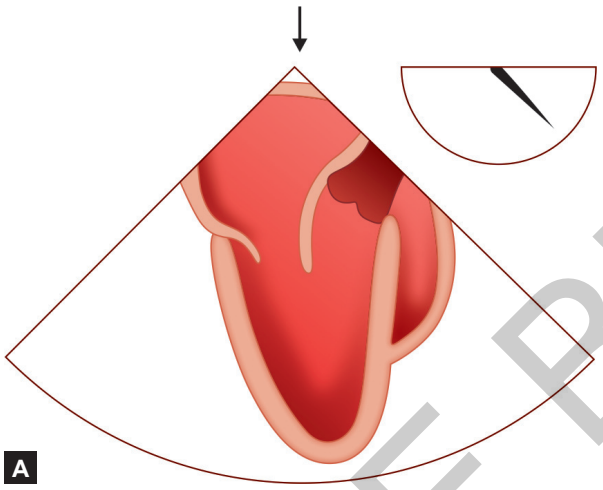

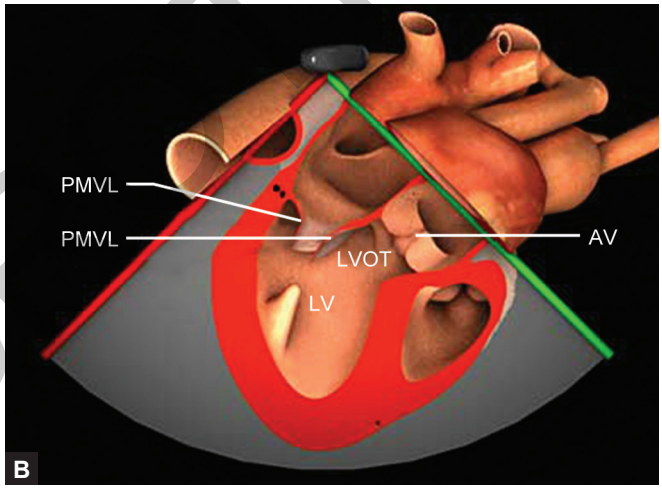

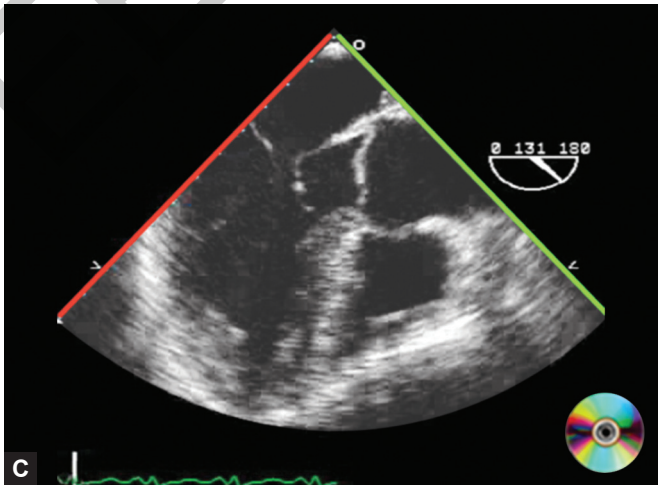

Figures 4A to C (A) Outline of midesophageal long-axis view; (B) Simulator of midesophageal long-axis view; (C) **(Video 4)** Midesophageal long-axis view for LV function, MV disease, AV and aortic root disease to view the aortic over-ride and IVS in detail

JAYPEE BROTHERS

MIDESOPHAGEAL AORTIC VALVE LONG-AXIS VIEW

- **Multiplane angle range:**
  - 120–160 degrees
  - *Sector depth:* ~ 8–10 cm
- **Anatomy imaged:**
  - Aortic valve
  - Proximal ascending aorta
  - Left ventricular outflow tract
  - Mitral valve
  - Right pulmonary artery
- **Clinical utility (Figs 5A to C):**
  - *Aortic valve:* Pathology, pathophysiology
  - *Ascending aorta pathology:* Atherosclerosis, aneurysms and dissections
  - *Mitral valve evaluation:* Pathology, pathophysiology.

The AV LAX view is suitable for assessing the grade of AR with color Doppler. Application of color Doppler in the normal AV demonstrates no transvalvular flow during diastole but laminar flow during systole.

Probe Manipulation

- From the ME two-chamber view, rotating the multiplane angle forward to between 120 and 160 until the LVOT and AV come into the display develops the ME LAX view.
- Visualized structures include the left atrium, MV, left ventricle, LVOT, AV, and proximal ascending aorta.
- This view offers diagnostic information regarding chamber volume and function, MV and AV function, LVOT pathology, and regional assessment of the left ventricle.

Color flow Doppler can be applied to the MV, LVOT, and AV to aid in the identification of valvular pathology (regurgitation and/or stenosis).

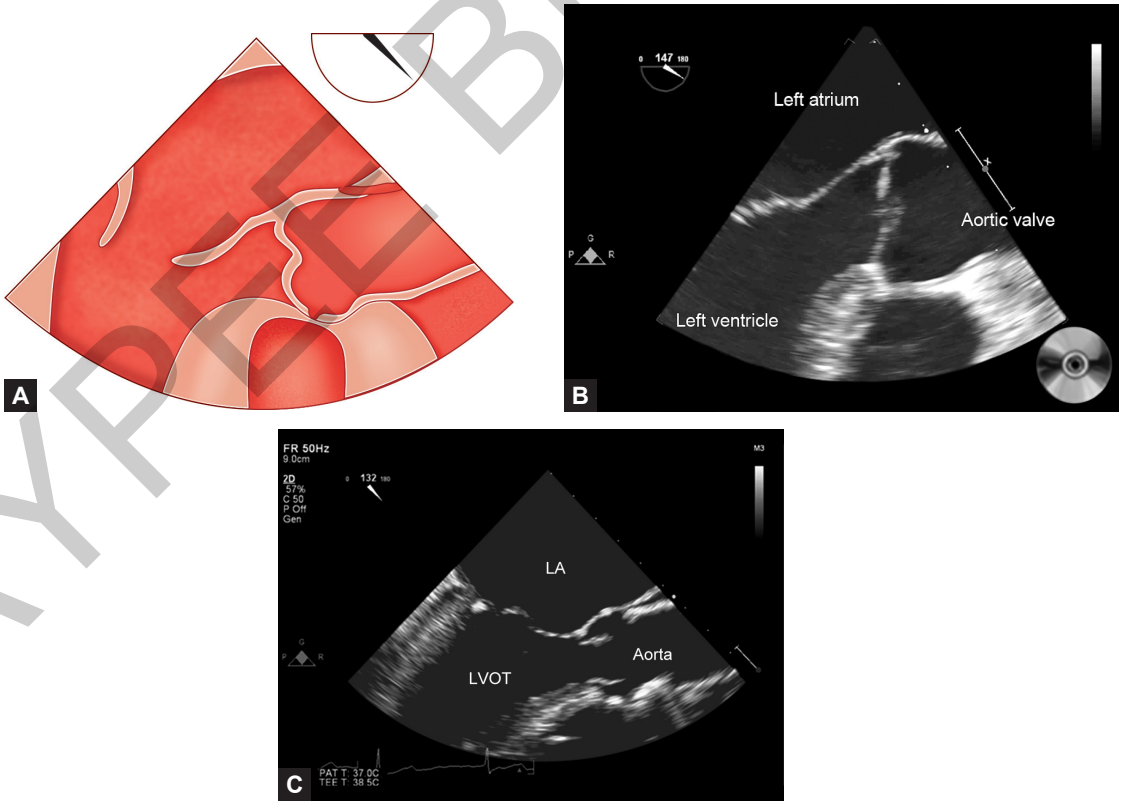

Figures 5A to C (A) Outline of midesophageal aortic valve long-axis view; (B) **(Video 5)** Midesophageal aortic valve long-axis view showing the aortic and mitral valves and regional assessment of LV, also excellent for aortic annulus and AML length; (C) Midesophageal aortic valve long-axis view in systole

JAYPEE BROTHERS

MIDESOPHAGEAL AORTIC VALVE SHORT-AXIS VIEW

- **Multiplane angle range:**
  - 30–60 degrees
  - *Sector depth:* ~ 10–12 cm
- **Anatomy imaged aortic valve:**
  - Interatrial septum
  - Coronary ostia and arteries
  - Right ventricular outflow tract
  - Pulmonary valve
- **Clinical utility (Figs 6A to C):**
  - *Aortic valve:* Pathology, pathophysiology
  - *Ascending aorta pathology:* Atherosclerosis, aneurysms and dissections
  - *Left and right atrial masses:* Thrombus, embolus, air, tumor, foreign bodies
  - Congenital or acquired interatrial septal defects evaluation.

Probe Manipulation

- At 40–60° the characteristic short-axis view of the aortic valve (MOE AV SAX) is obtained. The right coronary cusp and sinus are located at the bottom, contiguous with the RV wall; the non-coronary sinus lies on the left and the left coronary sinus on the right.
- The AV cusps should be clearly identified. For a trileaflet valve, the left coronary cusp should be posterior and on the right side of the image. The noncoronary cusp is adjacent to the IAS.
- The right coronary cusp is anterior and adjacent to the RVOT.

Color flow Doppler can be applied over the AV to aid in identifying aortic regurgitation and seeing the VC width and the aortic annulus.

The systolic orifice area can be measured by planimetry (or calculated via the continuity equation using other views). "Normal" individuals may have a tiny jet of trace aortic regurgitation (AR), often located in the center of the AV. In the presence of AR, the SAX view is particularly useful in defining the locus of the regurgitant orifice. Slight withdrawal of the TEE probe demonstrates the proximal ascending aorta. Advancement of the probe depicts the LVOT.

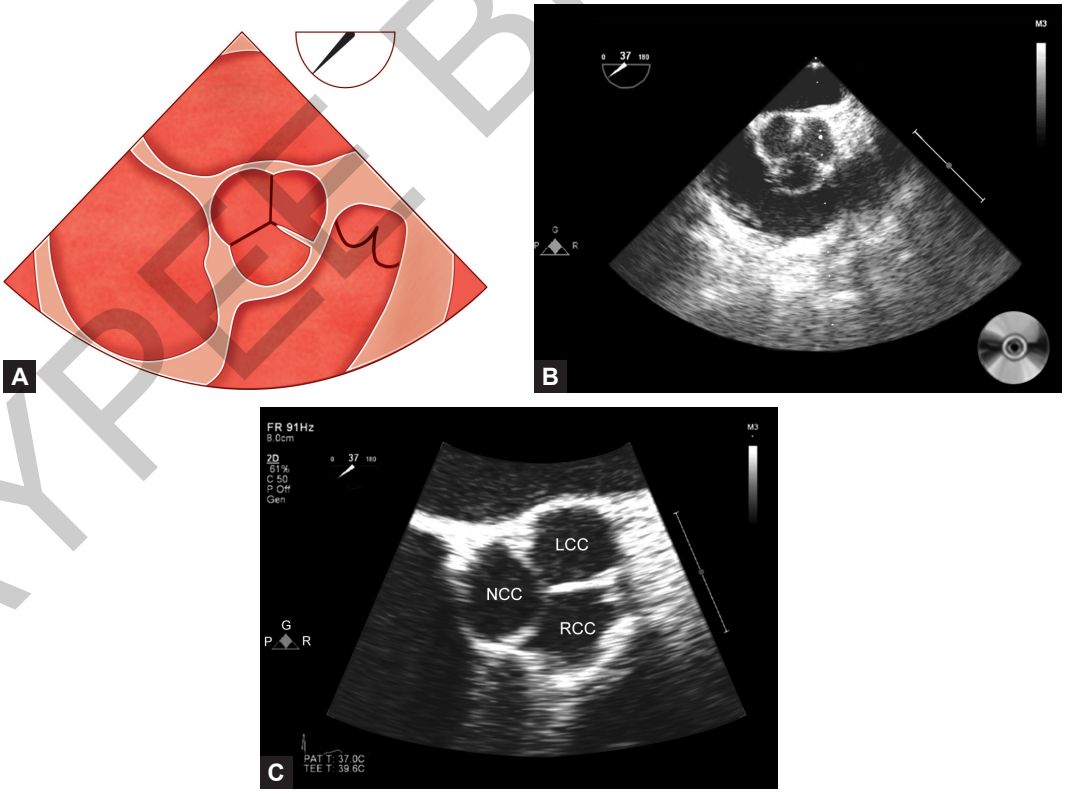

Figures 6A to C (A) Midesophageal aortic valve short-axis view with AV in center; (B) **(Video 6)** Midesophageal aortic valve short-axis view the 3 cusps of AV, calcification in the 3 cusps, presence and quantification of AS and AR; (C) Midesophageal aortic valve short-axis view in diastole

JAYPEE BROTHERS

MIDESOPHAGEAL BICAVAL VIEW

- **Multiplane angle range:**
  - 80–110 degrees
  - *Sector depth:* ~ 8–10 cm
- **Anatomy imaged:**
  - Right and left atrium
  - Superior vena cava (long-axis)
  - *Inferior vena cava orifice:* Advance probe and turn to right to visualize inferior vena cava in the long-axis, liver, hepatic and portal veins
  - Interatrial septum
  - *Right pulmonary veins:* Turn probe to right
- **Clinical utility (Figs 7A and B):**
  - *Right and left atrial masses:* Thrombus, embolus, air, tumor, foreign bodies
  - *Superior vena cava pathology:* Thrombus, sinus venosus atrial septal defect
  - Inferior vena cava pathology (thrombus, tumor)
  - Femoral venous line placement
  - Coronary sinus catheter line placement
  - *Right pulmonary vein evaluation:* Anomalous return, Doppler evaluation for left ventricular diastolic function.

Probe Manipulation

- From the ME RV inflow-outflow view, the multiplane angle is rotated forward to 80 to 110 and the probe is turned clockwise to the ME bicaval view.
- From this view, catheters or pacing wires entering the right atrium from the superior vena cava are well imaged.

Color Doppler of the IAS, including the use of a lower Nyquist limit setting, may be used to assess the presence of a low-velocity interatrial shunt. Agitated saline may also be injected after the administration of a Valsalva maneuver for further documentation of a right-to-left component.

The inferior and superior vena cava are seen entering the right atrium. This bicaval view can also be obtained at the mid-esophageal level as the ME bicaval view. By rotating the imaging plane to 100–110°, the junction of the inferior vena cava, with the right atrium on the left and the right atrial appendage on the right, can be seen. The fine linear and usually quite mobile structure arising from the junction is Eustach's valve.

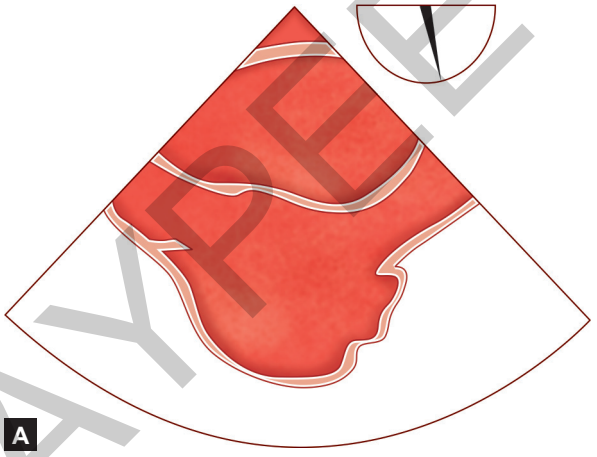

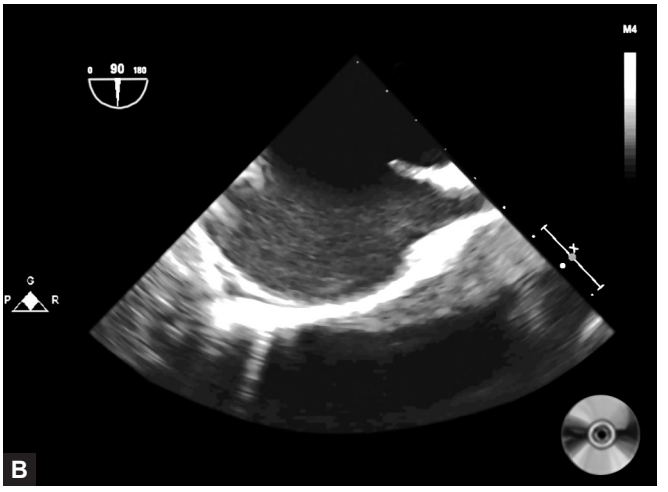

Figures 7A and B (A) Outline of midesophageal bicaval view; (B) **(Video 7)** Midesophageal bicaval view outline and video to see the IAS

JAYPEE BROTHERS

MIDESOPHAGEAL DESCENDING THORACIC AORTA LONG-AXIS VIEW

- **Multiplane angle range:**
  - 90 degrees
  - *Sector depth:* ~6
- **Probe adjustments**
  - Neutral
- **Anatomy imaged:**
  - Descending aorta in long-axis in longitudinal plane
- **Clinical utility (Figs 8A to C):**
  - Aortic atherosclerosis
  - Aortic dissection
  - Intra-aortic balloon pump (IABP) placement.

Probe Manipulation

- The LAX view is obtained at a transducer angle of approximately 90 to 100 degrees. Image depth should be decreased to enlarge the size of the aorta and the focus set to be in the near field. Finally, gain should be adjusted in the near field to optimize imaging.
- While keeping the aorta in the center of the image, the probe can be advanced or withdrawn to image the entire descending aorta **(Figs 8A to C)**. Because there are no internal anatomic landmarks in the descending aorta, describing the location of pathology is difficult.
- One approach to this problem is to identify the location in terms of distance from the incisors. The descending thoracic aorta is located posterior and to the left of the esophagus and when imaging this structure the transesophageal echocardiographic probe faces the left thoracic cavity. Thus, intercostal arteries are typically seen arising from the aorta toward the right side of the screen.
- When imaging the descending thoracic aorta, the hemiazygous vein (which drains the left posterior thorax) may be seen in the far field of imaging. In the mid to upper thorax, this vein joins the azygous vein (which drains the right posterior thorax). This venous structure is typically parallel to the aorta and aortic arch, eventually draining into the superior vena cava.

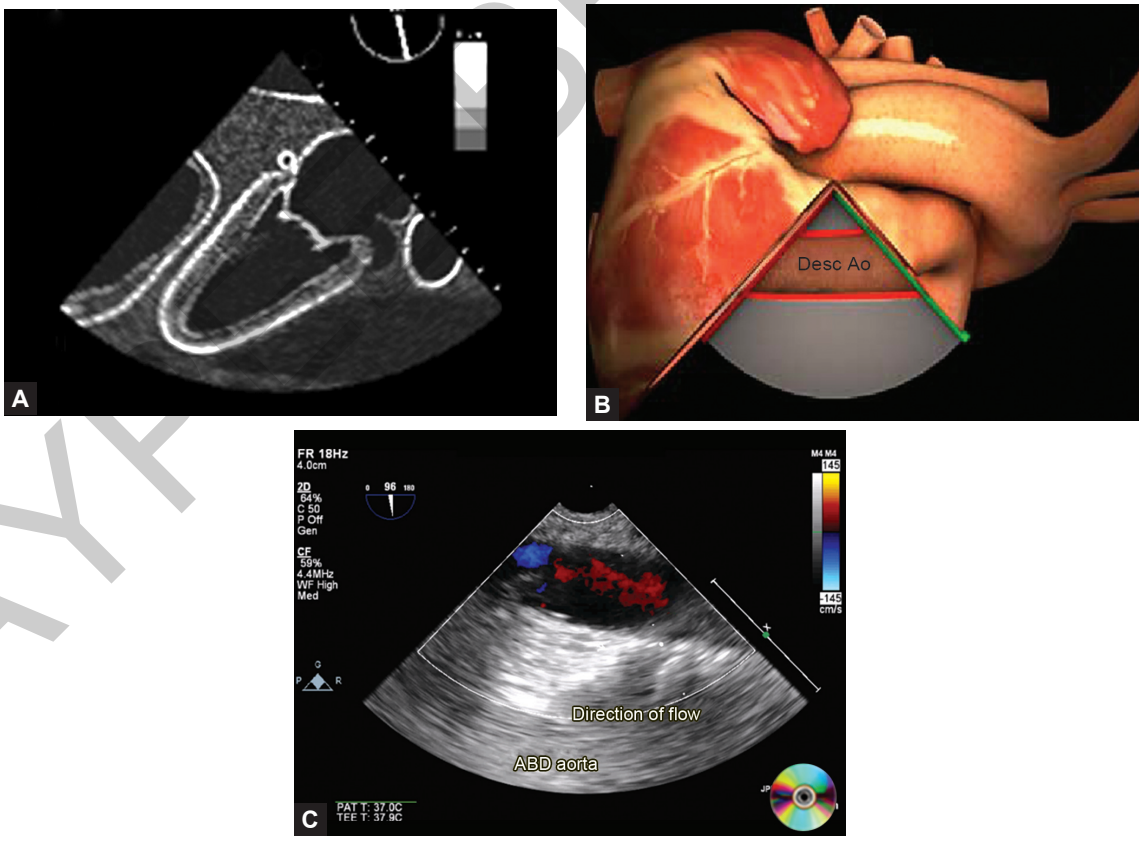

Figures 8A to C (A) The diagrammatic view of midesophageal descending thoracic aorta long-axis view; (B) Simulator view of midesophageal descending thoracic aorta long-axis view; (C) **(Video 8)** Midesophageal descending thoracic aorta long-axis view showing the descending thoracic aorta in the center

JAYPEE BROTHERS

for detailed information on cardiology books, visit our website www.jaypeebrothers.com, for detailed info

TRANSESOPHAGEAL ECHOCARDIOGRAPHY OF CONGENITAL HEART DISEASES

Salient Features

- Represents a unique contribution as the only contemporary reference to focus exclusively on the clinical applications of transesophageal echocardiography (TEE) in congenital heart disease (CHD) in a practical and manual format with related ECGs and X-rays in the same pathology
- Includes detailed TEE images and videos on recent topics like pulmonary stenosis, atrial septal device closure, Ebstein's anomaly, *d*-transposition of the great arteries (*d*-TGA), univentricular heart, etc.
- Presents a comprehensive, modern and integrated review of the subject in light of the cumulative experience and most recent advances in the technology
- Involves 113 TEE videos on different spectrums of congenital heart diseases and ECGs, X-rays and case scenarios in a practical manner
- Includes a DVD-ROM, which contains the echocardiographic pictures and videos of various congenital heart diseases
- Designs the step-by-step Echocardiography in Congenital Heart Disease as a handbook of students, general physicians, technicians, anesthetists, and cardiologists, to be used for quick reference for recognization of both common and rare congenital heart diseases that one may encounter during their daily practice with TEE
- Only authenticated book available for the TEE in CHD for all examinees in all medical branches.

Poonam Malhotra Kapoor MD DNB MNAMS FIACTA FTEE FISCU is currently working as a Professor, Department of Cardiac Anesthesia, Cardio-Neuro Center, All India Institute of Medical Sciences (AIIMS), New Delhi, India. She is the Co-editor of Annals of Cardiac Anesthesia; and Coordinator and Office-in-Charge, Indian Association of Cardiovascular Thoracic Anesthesiologists (IACTA) Education and Research Cell, which conducts Fellowship examinations in TEE and cardiac examination. She is also the Examiner of DM, IGNOU, DNB Cardiac Anesthesia and Delhi University. She is the Founder Secretary, Society of Cardiac Anesthesia, New Delhi and National Capital Region (NCR), India. She is an Author of the bestseller books on *Manual of ECMO and 2100 MCQs in Cardiac Anesthesia—Anesthesia Review*.



Sarvesh Pal Singh MD DM FIACTA FTEE is the Senior Resident, Department of Cardiac Anesthesia, Cardio-Neuro Center, All India Institute of Medical Sciences (AIIMS), New Delhi, India. He has been working in the Department of Cardiac Anesthesia for past six years. He has several publications pertaining to transesophageal echocardiography to his name. He has keen interest in TEE in complex congenital heart disease.



Available at all medical book stores
or buy directly from Jaypee Brothers through online shopping
at www.jaypeebrothers.com

JAYPEE BROTHERS
Medical Publishers (P) Ltd.
www.jaypeebrothers.com

Join us on facebook.com/jaypeebrothers

Shelving Recommendation
CARDIOLOGY

ISBN 978-93-5152-219-5