our website **www.jaypeebrothers.com,** for detailed information on otorhinolaryngology books, visit our website **www.jaypeebrothers.c**

Surgical Techniques in Otolaryngology—Head & Neck Surgery

PEDIATRIC OTOLARYNGOLOGIC SURGERY




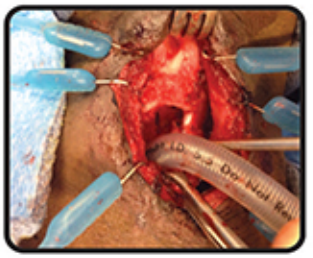

Series Editor
Robert T Sataloff

Swapna K Chandran
Matthew B Hirsch

JAYPEE

Contents

Section 1: Otology

1. Tympanostomy and Tube Placement **3**

Matthew B Hirsch

- Details of Procedure 3

2. Repair of the Perforated Tympanic Membrane **5**

Matthew B Hirsch, Arun K Gadre

- Myringoplasty 5
- Tympanoplasty 6
- Steps of the Procedure 6

3. Repair of Ossicular Chain Abnormalities **11**

Beth N McNulty, Arun K Gadre

- Considerations 12
- Surgical Technique 13

4. Surgical Treatment of Chronic Otitis Media **17**

Matthew B Hirsch

- Preoperative Planning 17
- Procedure 18
- Drilling 18

5. Cochlear Implantation **21**

Arun K Gadre, Lynzee N Alworth, Katie L Austin, Paul A Tennant

- Background 21
- Other Treatment Options 21
- Preoperative Evaluation—Indications/Candidacy Criteria 21
- Surgical Steps 25
- Modifications in Technique 35
- Postoperative Care 36
- Complications 36

Section 2: Congenital

6. Cleft Lip and Palate 41
Matthew B Hirsch, Mark E Chariker
- Evaluation and Management 41
- Surgical Techniques 42

7. Congenital Neck Masses 47
Matthew B Hirsch, Swapna K Chandran
- Pharyngeal Arch Abnormalities 47
- Thyroglossal Duct Cysts 49
- Lymphatic Malformations 50
- Arteriovenous Malformations 51
- Lingual Thyroid 51

8. Congenital Midline Nasal Masses 53
Sarah B Jacob, Swapna K Chandran
- Operative Procedure 54

Section 3: Sinonasal

9. Pediatric Chronic Rhinosinusitis 59
Sarah B Jacob, Swapna K Chandran
- Surgical Techniques for Balloon Sinuplasty 59

Section 4: Tonsillectomy and Adenoidectomy

10. Extracapsular Tonsillectomy 65
Julie L Goldman
- Surgical Technique 65

11. Intracapsular Tonsillectomy 69
Swapna K Chandran
- Steps in the Procedure 69

12. Adenoidectomy 73
Swapna K Chandran
- The Steps of Adenoidectomy 73

Section 5: Surgery of the Upper Aerodigestive Tract

13. Surgical Management of Laryngomalacia **77**
Swapna K Chandran
- Supraglottoplasty 77
- Epiglottoplasty 78

14. Endoscopic Management of Subglottic Lesions **79**
Swapna K Chandran
- Subglottic Stenosis 79
- Surgical Techniques for Endoscopic Balloon Dilation and Cold Steel 79

15. Open Laryngotracheal Procedures **83**
Swapna K Chandran
- Anterior Cricoid Split 83
- Laryngotracheal Reconstruction 84
- Partial Cricotracheal Resection 85

16. Tracheotomy **89**
Swapna K Chandran
- Surgical Technique 89

17. Deep Neck Infections **93**
Kevin L Potts
- Peritonsillar Abscess 93
- Retropharyngeal or Retroesophageal Abscess 94
- Parapharyngeal Abscess 96
- Suppurative Lymphadenitis 97

18. Benign and Malignant Tumors of the Head and Neck **99**
Jeffrey M Bumpous
- History and Physical Examination 99
- Laboratory Examinations 100
- Radiology Examinations 100
- Benign Tumors 100
- Malignant Tumors 102
- Special Management Topics 107

Index *109*

CHAPTER 3

Repair of Ossicular Chain Abnormalities

Beth N McNulty, Arun K Gadre

JAYPEE BROTHERS

INTRODUCTION

The most important aim of surgery to eradicate chronic ear disease is to prevent serious disease-related intracranial complications such as meningitis; secondary and tertiary goals include the eradication of chronic otorrhea and preservation or restoration of hearing respectively. The extent of disease and patient reliability often determines when and how the third goal is met. In cases of extensive disease, this often requires delayed intervention with a "second look" surgery, ensuring there is no residual cholesteatoma prior to reconstruction. The involved portion of the ossicular chain may be banked for use as an autograft during the reconstruction. When limited disease is noted, an immediate reconstruction may be considered.

Patients commonly present with conductive or mixed hearing loss and this may be secondary to an ossicular fixation or a discontinuity of the ossicular chain. Complete ossicular discontinuity will demonstrate a maximum (60 dB) conductive hearing loss on pure-tone audiometry (Fig. 3.1). Ossicular fixation may result from severe

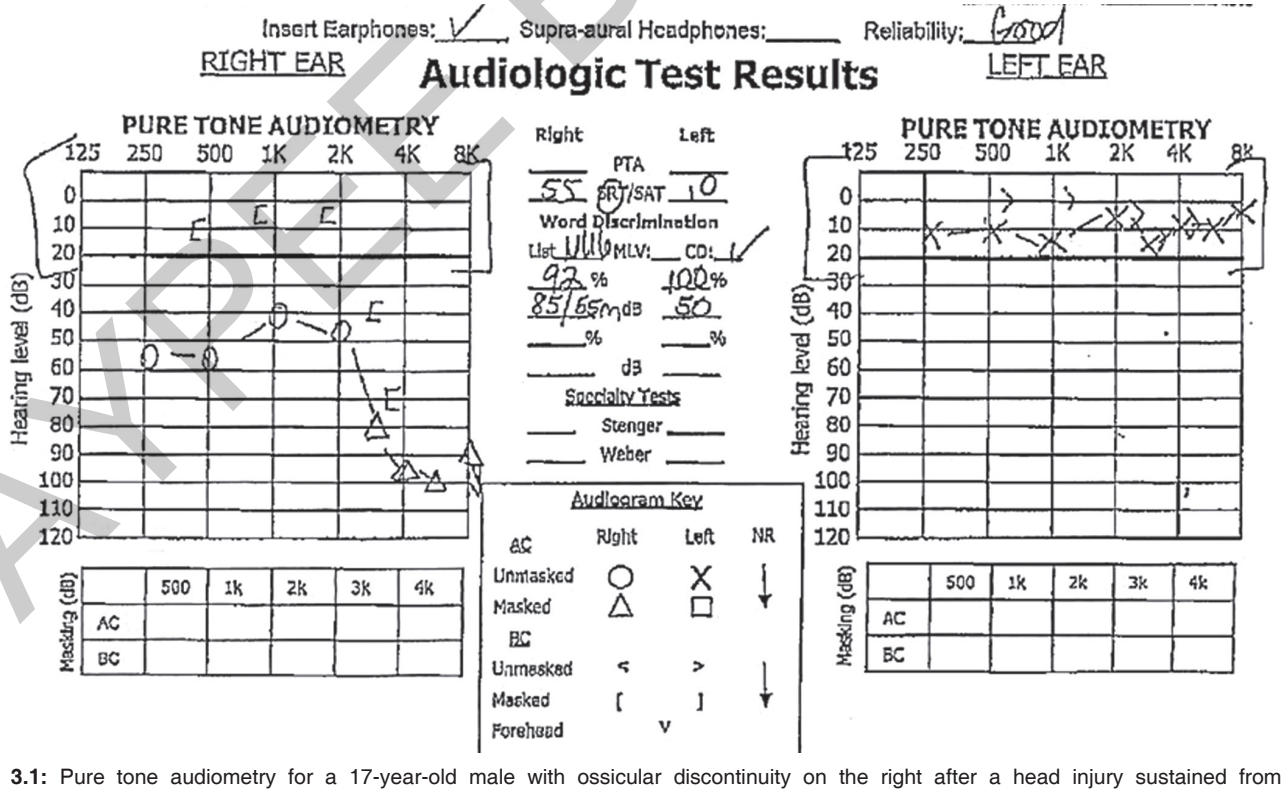

Fig. 3.1: Pure tone audiometry for a 17-year-old male with ossicular discontinuity on the right after a head injury sustained from a motor vehicle accident.

tympanosclerosis. There may be fixation of the stapes in the oval window region or the incus and malleus in the attic. The fixation may involve the ossicles in the oval window and the attic simultaneously. Ossicular discontinuity may be iatrogenic in the approach for middle ear masses or disease. Discontinuity may result from erosion, fracture, or trauma. Cholesteatoma is the most common cause of ossicular erosion; however, chronic eustachian tube dysfunction alone can also be the culprit.[1]

CONSIDERATIONS

One must be thoughtful when considering immediate versus delayed reconstruction, as previously described. When evaluating a patient for delayed reconstruction, it is best to medically optimize the patient to ensure that there is no evidence of infection or drainage noted preoperatively.

The materials available for use in ossicular reconstruction have evolved over time. Ossicular autografts may be used for immediate reconstruction or harvested at the initial operation and banked for future reconstruction. This practice has fallen out of favor with many otologic surgeons as it requires a meticulous sculpting technique, may succumb to scar fixation or a loss of continuity to the stapes,[2] or may become fixated (Figs. 3.2A to D). Cadaveric homografts are no longer used, secondary to the concern for infectious disease transmission.[3]

Advancements in technology have led to the development of multiple synthetic devices that are now

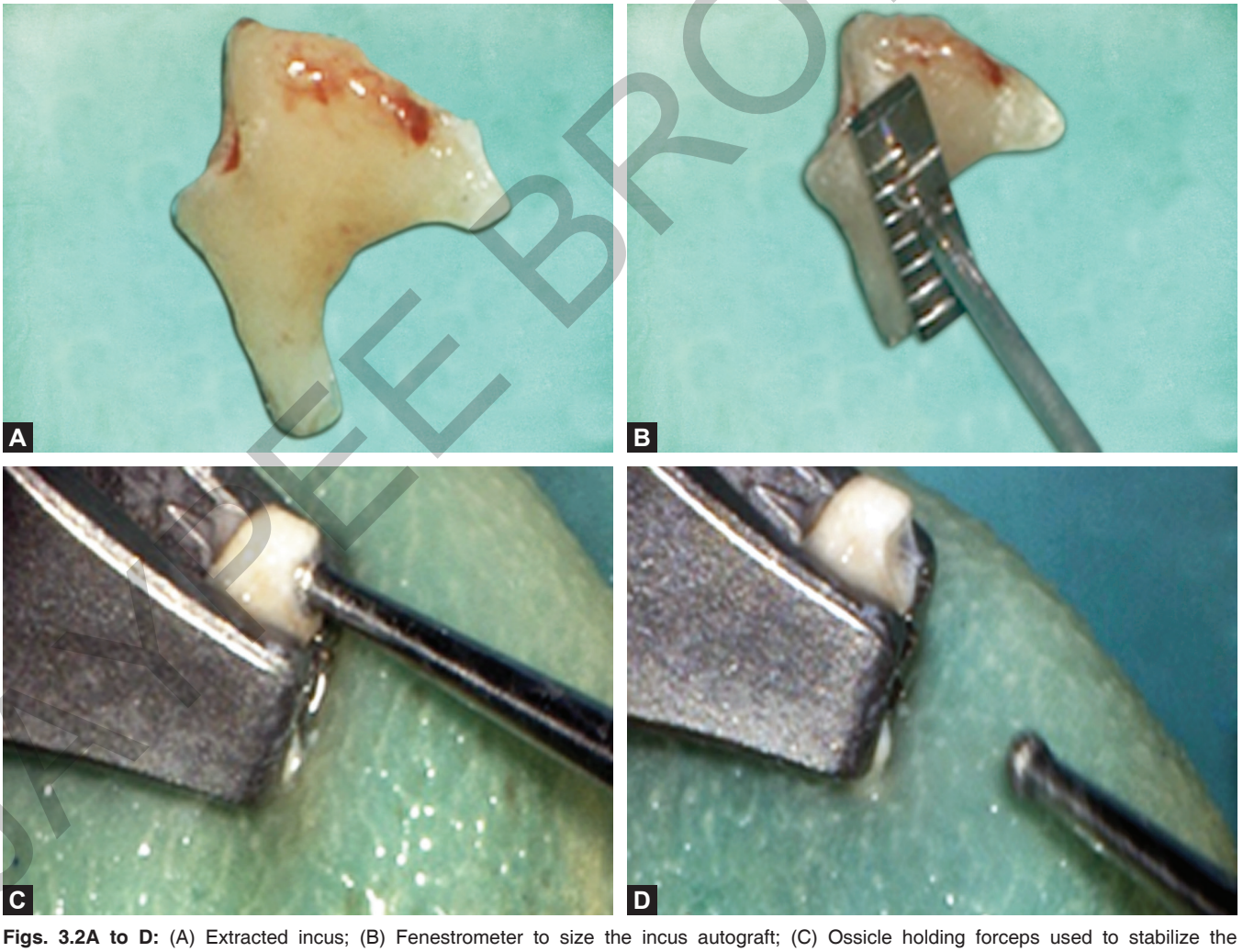

Figs. 3.2A to D: (A) Extracted incus; (B) Fenestrometer to size the incus autograft; (C) Ossicle holding forceps used to stabilize the autograft as the drill is used to create an acetabulum in the body of the incus; (D) The resultant acetabulum in the body of the incus.

JAYPEE BROTHERS

available for use. The partial ossicular replacement prosthesis (PORP) is used in cases of a remaining stapes suprastructure, the total ossicular replacement prosthesis (TORP) for cases in which the stapes suprastructure is absent. Alloplastic ossicular prostheses, such as Plastipore®, an alloplast made from a high-density polyethylene sponge (HDPS) is nonreactive and porous to encourage tissue ingrowth. Hydroxylapetite may be used as bone cement, composed of calcium and phosphorous it acts like a bony implant with osseointegration over time. One may sculpt the shape as desired and then allow the material to set for 4–6 minutes prior to implantation. Preformed hydroxylapetite PORPs and TORPs are also available. Titanium prostheses are commonly used, with the advantages of a light weight, ease of implantation and low extrusion rate.[4] Previous reports have shown the closure of the air-bone gap to greater than 20 dB for both partial and total ossicular prostheses[5] (Fig. 3.3).

SURGICAL TECHNIQUE

The head of the bed is rotated 180°; the patient's head should be at the end of the bed. A shoulder roll is placed and the patient's head is turned so that the involved ear is facing the surgeon. If a facial nerve monitor will be used, the electrodes are placed and the function of the monitor is confirmed at this time.

In cases of ossicular erosion as a result of cholesteatoma, whether reconstruction is at the time of the initial operation or a second look procedure, a postauricular approach is likely warranted. One may consider a transcanal approach or exploratory tympanotomy in trauma cases or patients with fixation resulting from tympanosclerosis. The postauricular approach has the advantage of the simultaneous harvest of a fascia graft.

1. The postauricular incision will be 2–3 mm posterior to the postauricular crease, therefore any hair that may complicate the surgical field should be restrained or an electric shaver can be used. The ear is prepped and draped in a sterile fashion; ioban may be helpful to prevent contamination of the surgical field.
2. The auricle is retracted so that the planned incision site can be marked and injected with a local anesthetic. A nasal speculum may then be used to assist with a four-quadrant canal injection. The postauricular incision should extend from the takeoff of the helical crus down to the mastoid tip.

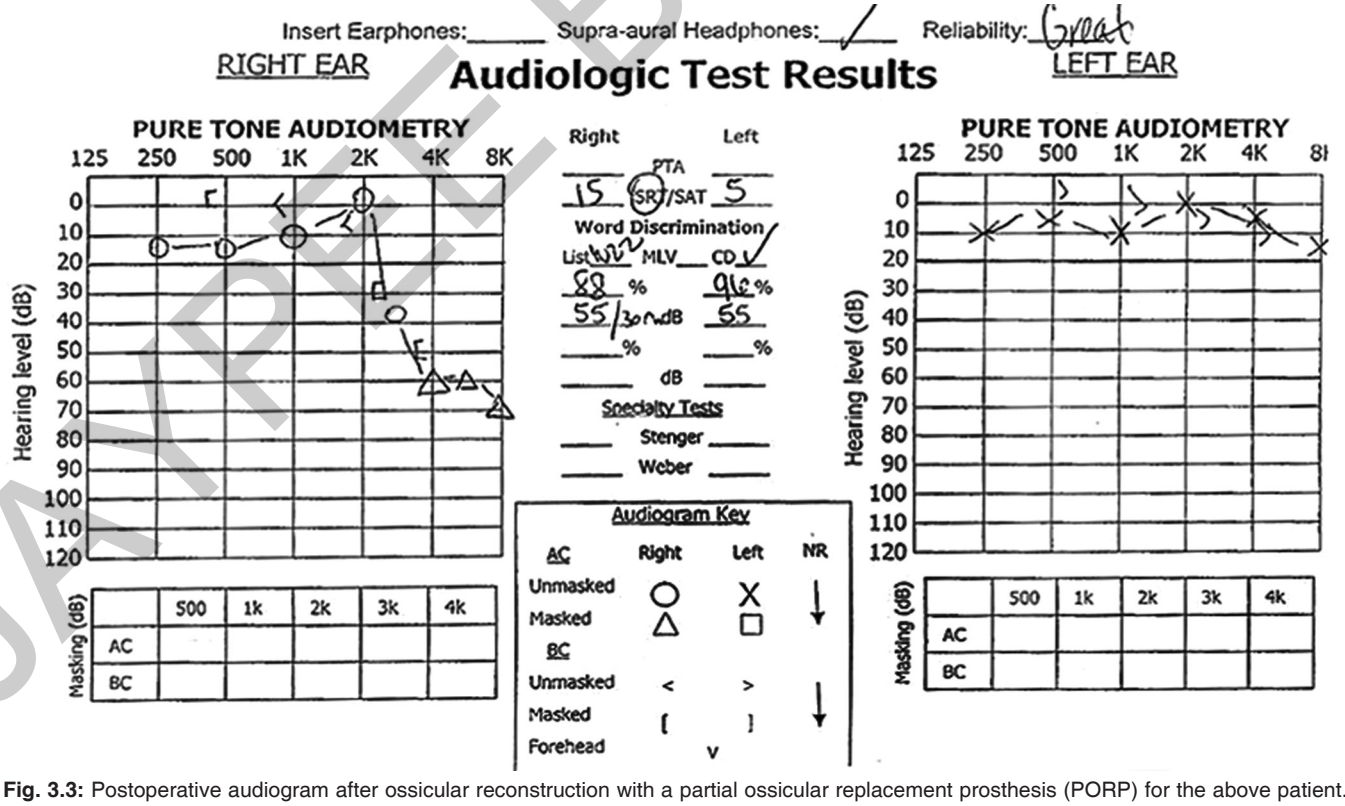

Fig. 3.3: Postoperative audiogram after ossicular reconstruction with a partial ossicular replacement prosthesis (PORP) for the above patient.

JAYPEE BROTHERS

3. Once the skin incision is made, the harvest of a fascial graft should follow. It is the surgeon's preference, either temporoparietal or temporalis fascia may be harvested. The graft is then placed in the fascial press for approximately 10 minutes.
4. The subcutaneous incision is next carried along the full length of the incision transecting through the posterior auricularis musculature. Once this muscle is transected, one should skive anteriorly, retracting the auricle at the same time with the index finger in the canal so as to not penetrate the canal skin. A self-retaining retractor may be used at this point.
5. A modified Palva flap is next created. This is a quadrangular flap with the superior leg extending from the canal along the temporal line. The inferior leg also extends from the canal posteriorly, beginning at the mastoid tip and curving superiorly to avoid transecting the inserting muscle fibers of the sternocleidomastoid. The inferior and superior legs are connected posteriorly and a periosteal elevator is used for a subperiosteal dissection continuing along the bony canal wall.
6. The vascular strip is created with canal incisions at the tympanomastoid and tympanosquamous suture lines. This should be approximately 4–6 mm from the bony annulus. A Penrose drain is next inserted through this incision and a mosquito clamp holds this away from the surgical field as a retractor. The tympanomeatal flap is then raised.
7. The mobility of the ossicular chain is first assessed. If ossicular fixation is observed, attempts are made to preserve the uninvolved segment(s) should this apply. Sparing the manubrium of the malleus may allow for a stapes interposition using a PORP. The head of the malleus may be extracted with the use of a malleus nipper. If medialization of the manubrium is noted, sectioning the tensor tympani tendon may facilitate lateralization. When disease is limited to the lenticular process of the incus and the manubrium of the malleus is in a favorable position relative to the stapes, a sculpted incus autograft or hydroxylapetite bone cement may be used.[2]
8. If the disease extends to involve the stapes suprastructure, the anterior and posterior crus may be out fractured and a TORP may then be used. This may be performed with the use of a laser, similar to the technique used during a stapedectomy. The surgeon must exert great care to avoid displacing the footplate into the vestibule when performing this portion of the operation. In general, TORPs do not produce the long-term results that are seen with PORPs. To prevent the medial strut from being displaced off the center of the footplate, a cartilage "shoe" may be used. This entails harvesting a cartilage graft, the size of the oval window niche and creating a hole in its center for which the base of the TORP may sit.[2]
9. Prior to the placement of the prosthesis, a fenestrometer or sizing prosthesis is used (Figs. 3.4 and 3.5A). If an autograft will be used, ossicle holding forceps may stabilize the graft while a drill is used for appropriate sculpting (Figs. 3.2A to D). If using a synthetic prosthesis, the appropriate size may then be selected.
10. The middle ear space is filled with Gelfoam® soaked in Floxin to provide support for the prosthesis (Fig. 3.5C).
11. The fascial graft is next placed (Fig. 3.6B). A cartilage graft may be placed medial to the remaining tympanic membrane or fascial graft in an attempt to prevent extrusion of the prosthesis (see Fig. 3.5D). Extrusion is more common when the prosthesis directly abuts the tympanic membrane.[1] The tympanomeatal flap is then laid back down.
12. The external auditory canal is packed with Gelfoam® soaked in Floxin and two small cotton balls coated in bacitracin. A glasscock ear dressing may be used or a mastoid compression dressing as deemed necessary.

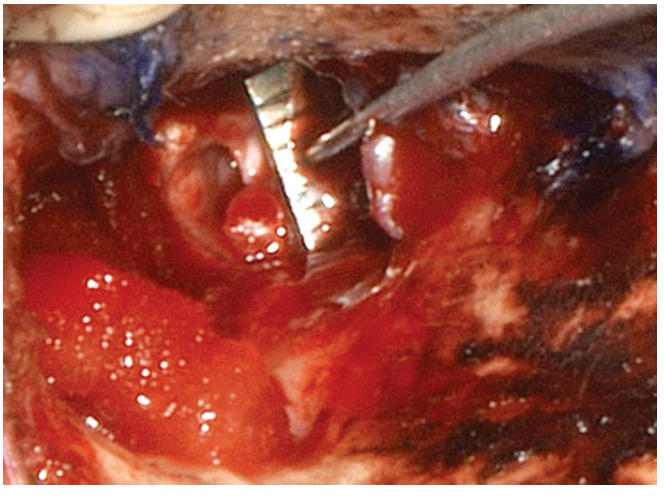

Fig. 3.4: A fenestrometer is used to measure the distance between the manubrium of the malleus and the capitulum of the stapes, as a sizer, prior to placing the prosthesis.

JAYPEE BROTHERS

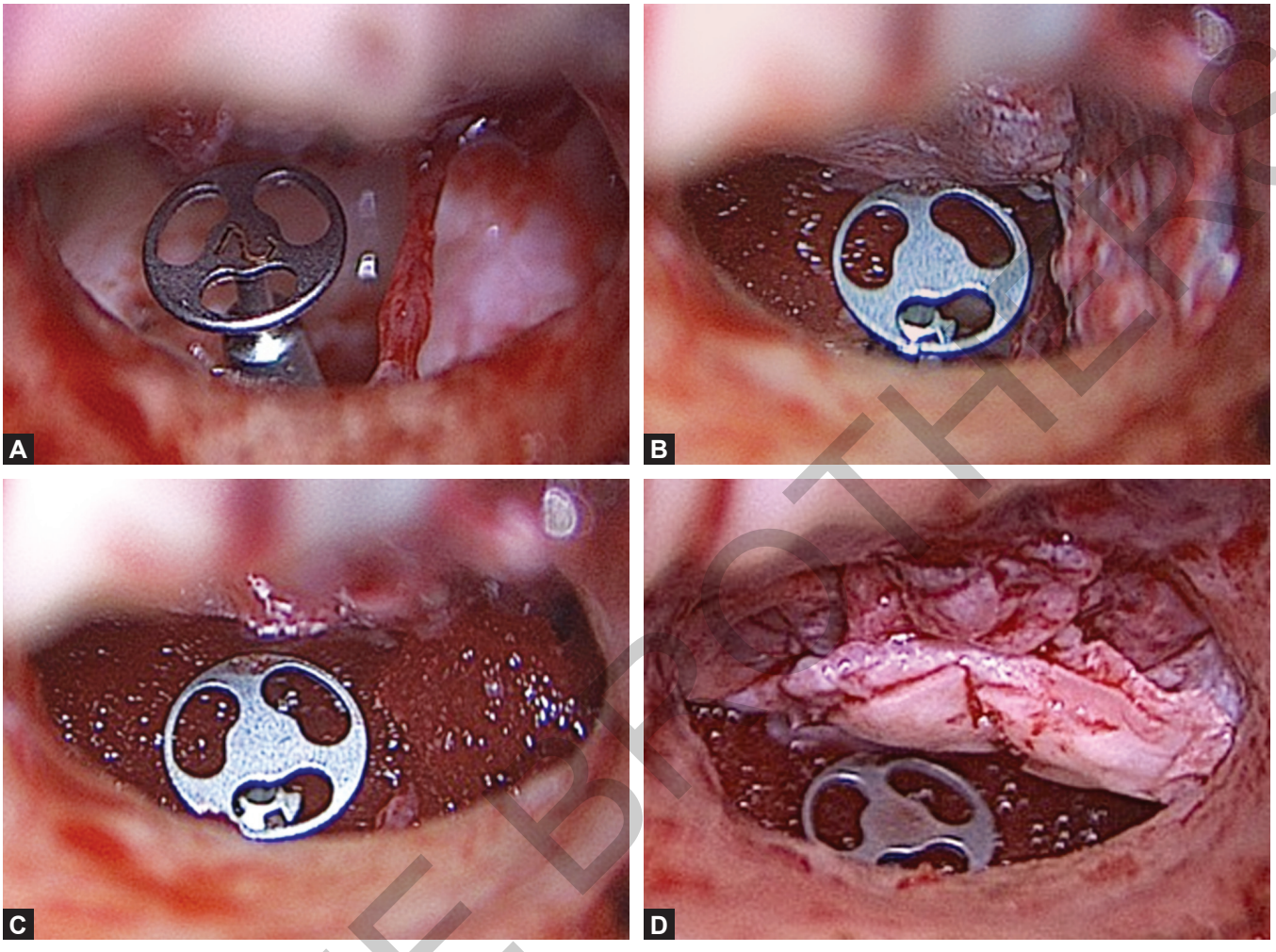

Figs. 3.5A to D: (A) Two millimeters measuring titanium prosthesis; (B) The 2 mm titanium prosthesis being placed atop the capitulum of the stapes; (C) Gelfoam® soaked in Floxin placed in the middle ear space to support the prosthesis; (D) A chondroperichondrial graft is placed medial to the temporalis fascia graft to prevent extrusion.

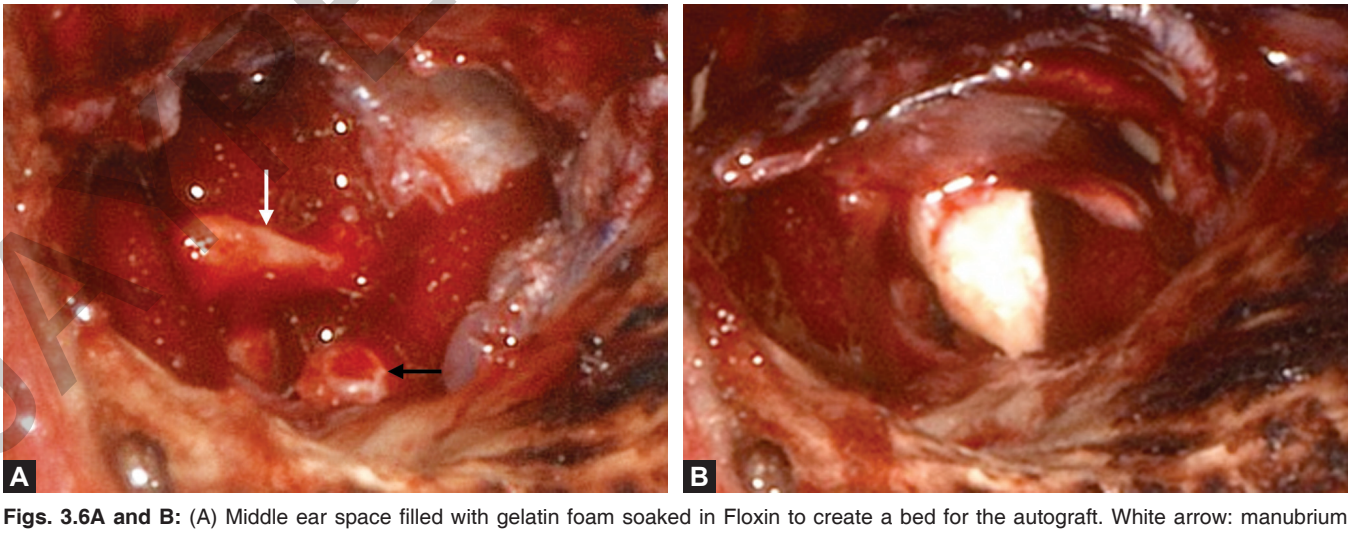

Figs. 3.6A and B: (A) Middle ear space filled with gelatin foam soaked in Floxin to create a bed for the autograft. White arrow: manubrium of the malleus. Black arrow: the capitulum of the stapes; (B) The incus autograft in place, straddling the manubrium of the malleus. A temporalis fascia graft is laid over the ossicular chain and reflected anteriorly for visualization of the autograft.

JAYPEE BROTHERS

REFERENCES

1. Adams ME, El-Kashlan HK. Tympanoplasty and ossiculoplasty. In: Flint PW, Haughey BH, Lund VJ, et al. (Eds). Cummings Otolaryngology: Head and Neck Surgery, 5th Edition. Philadelphia: Mosby Elsevier; 2010.
2. Jackson CG, Glasscock ME, Schwaber MK, et al. Ossicular chain reconstruction: the TORP and PORP in chronic ear disease. Laryngoscope. 1983;93(8):981-8.
3. Hirsch BE. Ossicular chain reconstruction. In: Eugene N (Ed). Meyers Operative Otolaryngology Head and Neck Surgery, 2nd Edition. Philadelphia, PA: Saunders Elsevier; 2008. pp. 1147-62.
4. Athanasiadis-Sismanis A, Poe DS. Ossicular chain reconstruction. In: Gulya AJ, Minor LB, Poe DS (Eds). Glasscock-Shambaugh Surgery of the Ear, 6th Edition. Shelton, CT: People's Medical Publishing House; 2010. pp. 489-96.
5. Kim HH, Battista RA, Kumar A, et al. Should ossicular reconstruction be staged following tympanomastoidectomy. Laryngoscope. 2006;116(1):47-51.

JAYPEE BROTHERS

r detailed information on otorhinolaryngology books, visit our website **www.jaypeebrothers.com,** for detailed information on otorhinola

Surgical Techniques in Otolaryngology—Head & Neck Surgery

PEDIATRIC OTOLARYNGOLOGIC SURGERY

Pediatric Otolaryngologic Surgery is part of a comprehensive series entitled "Surgical Techniques in Otolaryngology—Head and Neck Surgery." Other atlases in this series are devoted to various specialties within the field, including Head and Neck Surgery, Otologic and Neurotologic Surgery, Sinonasal Surgery, Laryngeal Surgery, and Facial Plastic & Reconstructive Surgery.

Eighteen chapters are included in all in this volume. Each chapter outlines the evidence-based medicine and background leading to the development of each surgical procedure, a detailed step-by-step description of the procedures with intraoperative drawings or photographs, and a discussion of the benefits and pitfalls. Alternatives to surgical management are discussed as well.

This volume is a practical guide to otolaryngologists of all levels with an overview of the most common surgical procedures performed in a pediatric otolaryngology practice. It covers everything from tympanostomy tube placement to cochlear implantation, cleft lip and palate repair, and oncologic surgery. Newer surgical procedures such as balloon sinuplasty and airway management are introduced in this volume to give the reader an understanding of the advances made in pediatric otolaryngology as well.

JAYPEE BROTHERS

Available at all medical bookstores or buy directly from Jaypee Brothers at www.jaypeebrothers.com

JAYPEE BROTHERS
Medical Publishers (P) Ltd.
www.jaypeebrothers.com

Join us on facebook.com/jaypeebrothers

Shelving Recommendations
OTORHINOLARYNGOLOGY
PEDIATRICS

ISBN 978-93-5152-223-2