nformation on orthopedics books, visit our website **www.jaypeebrothers.com,** for detailed information on orthopedics books, visit our website **www.jaypeebrothers.com**



INCLUDES
DVD-ROM

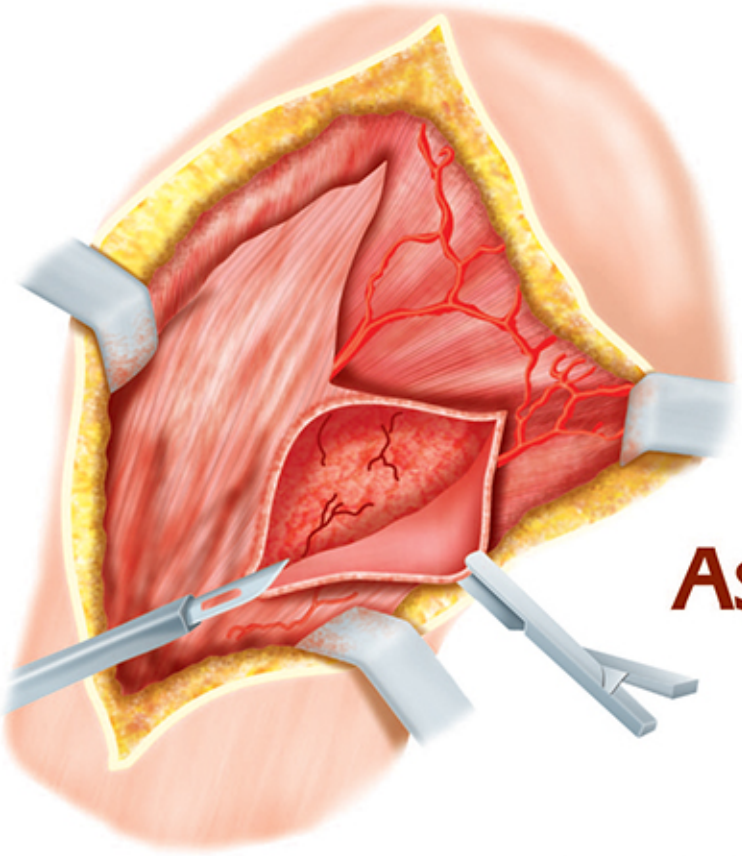

Ashok Rajgopal

KNEE SURGERY

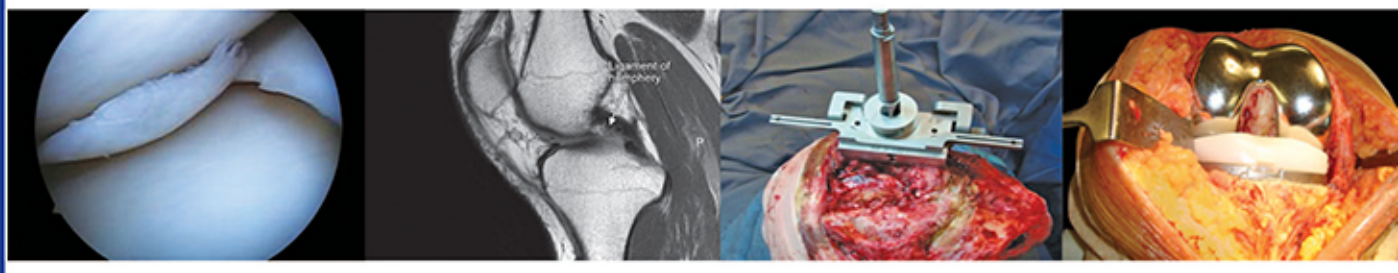

Forewords
Kim C Bertin
Chitranjan S Ranawat

JAYPEE

CONTENTS

SECTION 1: KNEE ARTHROPLASTY

1. History of Total Knee Arthroplasty 3

Michael A Kelly, Yair D Kissin

Total knee arthroplasty development 3
Evolution 4
Mobile-bearing 6
Modularity 6
Hinged prostheses 8
Total knee arthroplasty systems 8
Cementless fixation 9
Patellar resurfacing 9

2. Biomechanics of Normal and Replaced Knee 13

Sharath K Rao, Sandeep Vijayan

Mechanical Axis 13
Patellofemoral joint 13
Tibiofemoral articulation 14
Knee in normal gait 16
Biomechanics of an arthritic knee 18
Role of posterior cruciate ligament in knee replacement 20
Patellofemoral joint 21
Bone loss 21
Mobile-bearing knees 21
Knee biomechanics in high flexion 23
Gender differences in knees 23
Rehabilitation biomechanics 23

3. Surgical Approaches to Total Knee Arthroplasty 26

Sharath K Rao, Sandeep Vijayan

Anatomy 26
Medial parapatellar approach 28
Midvastus approach 30
Subvastus approach 31
Lateral approach 32
Trivector approach 34
Quadriceps (rectus) snip 35
Quadriceps turndown 35
Tibial tubercle osteotomy 36

4. Role of MRI in Evaluation of the Knee 39

Parveen Gulati, Amit Jawa

Technique 39
Menisci 40
Cruciate ligaments 44
Medial collateral ligament 48
Femoral trochlear groove 50
Transient lateral patellar dislocation 50
Evaluation of articular cartilage 50
Cysts, bursae, and ganglion 53
Infections 54
Tubercular knee 54

5. Current Principles of High Tibial Osteotomy, and its Role in Management of Unicompartmental Degenerative Joint Disease 62
Suryanarayan P
Malalignment and osteoarthritis 63
Varus deformity and osteoarthritis 63
Patient selection 65
Open wedge osteotomy 67
Lateral closing wedge osteotomy 70

6. Choice of Knee Implant 76
CJ Thakkar, Anoop Jhurani
History and long-term results of knee prosthesis 76
Fixed compared with mobile-bearings for knee replacement 78
biomechanics of a mobile-bearing knee 78
All polyethylene versus metal-backed tibial components in total knee arthroplasty 79
Monoblock tibia with compression-molded polyethylene: a case for reduced wear 80
High flexion knees 80
Oxinium femoral component 81
Gender-specific knee 81
Body mass index (BMI), age, and types of arthritis 82
Ligament laxity and condition of ligaments 82
Bone quality and bone defects 82
Preoperative range of movement and deformity 82
Training and surgical skills 83

7. The Role of Unicompartmental Knee Arthroplasty in the Arthritic Knee 87
Matthieu Ollivier, Sebastien Parratte, Xavier Flecher, Jean-Noel Argenson
Patient selection and indications 88
Radiological evaluation 88
Age and weight 88
Surgical techniques 89
Tibial finishing and trials 90
Results of modern unicompartment Knee arthroplasty 91

8. Patellofemoral Arthroplasty 100
Jess H Lonner, Joel Kolmodin, Carlos A Higuera
Epidemiology 100
Indications 101
Design considerations 102
Surgical considerations 105
Results 106

9. Cruciate Retaining Total Knee Arthroplasty: Technique and Results 110
Ashok Rajgopal, Attique Vasdev, Vivek Dahiya, Vipin Tyagi
History 111
Posterior cruciate ligament 111
Personal experience 119

10. Posterior Cruciate Substituting Total Knee Arthroplasty 122
Giles R Scuderi, Ajit J Deshmukh, Joseph W Greene
Historical perspective and design features 122

11. Mobile-bearing Total Knee Arthroplasty 130
Samih Tarabichi, Mohamed Elfekky, Azam Badar Khan
Indications and design rationale 131
Biomechanical and clinical review of a mobile-bearing total knee arthroplasty 131
Multidirectional platform 133
Rotating platform 134
Meniscal bearing devices 134
Combination of rotating platform and meniscal bearing 134
Our experience with mobile-bearing total knee replacement 135

12. Patellar Resurfacing in Total Knee Arthroplasty 144
Alfred J Tria Jr, William Baione, Brian Culp
Historical perspective 144
Component designs 145
Complications 151
Outcomes 153

13. Patient-specific Instrumentation in Total Knee Arthroplasty 159
Francesco Benazzo, Stefano Marco Paolo Rossi, Matteo Ghiara, Alberto Combi
Patient-specific instrumentation 159
Surgical technique 160
Literature evidence 160
Our experience 161
Considerations 164

14. Technique of Navigated Total Knee Arthroplasty 165
Arun Mullaji
Surgical approach and exposure 166
Balancing in extension and distal femoral resection 169
Balancing in flexion, femoral sizing, and rotation 171
Tibial sizing and rotation 171
Patella 171
Cementing 172
Closure 172

15. Cementless Total Knee Arthroplasty 176
Aaron G Rosenberg
Basic science of cementless fixation 176
Assessing ingrowth: retrieval studies 181

16. Minimally Invasive Approach to Total Knee Arthroplasty 190
Alfred J Tria Jr, William Baione, Brian Culp
Evolution of approaches 190
History 191
Patient selection 191
Preoperative planning 192
Transitioning to the MIS technique 192
Component considerations 195
Complications 195
Outcomes 196

17. Defect Management in Total Knee Arthroplasty and Role of Trabecular Metal in TKA 199
Hemant Wakankar, Sinukumar Bhaskaran
Bone defects in complex primary total knee arthroplasty 199
Bone defects in revision total knee arthroplasty 200
AORI bone defect classification 200
Guidelines for classifying defects using radiographs 200
Principles of bony reconstruction 201
Options for management of bone defects in complex primary total knee arthroplasty 201
Tantalum: trabecular metal 203

18. Instability Following Total Knee Arthroplasty 206
Andrew A Freiberg, Matthew J Dietz
Risk factors for postoperative instability 206
Categorization of total knee instability 208
Extension instability 208
Global instability 212
Ligament advancement and tightening procedures 214

19. Osteolysis in Total Knee Arthroplasty 219
Douglas A Dennis, Justin Duke
Pathogenesis 221
Factors affecting polyethylene wear 221
Osteolysis diagnosis 225
Osteolysis treatment 226

20. Extensor Mechanism Reconstruction for Ruptures or Deficiencies after Total Knee Arthroplasty 232
Andrea Baldini, Francesco Traverso, Caterina Guarducci, Pierpaolo Summa
Preoperative planning 232
Graft choice criteria 233
Surgical technique 234
Rehabilitation protocol 240
Results 242

21. Complications Following Total Knee Arthroplasty 248
Jack W Shilling, Robert E Booth
Periprosthetic fractures 248
Infection and wound healing concerns 250
Deep venous thrombosis and pulmonary embolism 251
Nerve and vascular injury 252

Stiff total knee 253
Instability 254

22. Principles of Revision Total Knee Arthroplasty 257
Kelly G Vince, Michel Malo
Thoughts experimental keys to revision TKA surgical technique 257
A revision arthroplasty is not a primary knee replacement 263

23. Current Practices in Diagnosing Periprosthetic Infection in Knee 279
Karthikeyan Chinnakkannu, Javad Parvizi
History and physical examination 279
X-ray 280
Serology 280
Knee joint aspiration 281
Synovial CRP 282
Biopsy 282
Culture 282
Algorithm for diagnosis of PJI 284
Other imaging modalities 284
Molecular markers 288
Nonrecommended tests 289

24. Infected Total Knee Arthroplasty and its Management 295
W Klauser, D Kendoff, A Zahar
Classification 296
Diagnostics 296
Joint aspiration 297
Irrigation and debridement 297
Two-stage exchange 298
The spacer 299
Antibiotic therapy 300
Reimplantation 301
One-stage exchange 301

25. Salvage after Failed Total Knee Arthroplasty 311
Mojieb Manzary
Knee arthrodesis 311
Above knee amputation 316
Resection arthroplasty 317

26. Revisions Following Aseptic Failures 319
Ashok Rajgopal, Attique Vasdev, Vivek Dahiya, Himanshu Gupta
Preoperative assessment 320
Surgical technique 321
Explantation 322
Trials 323
Reimplantation 326
Complications 326

27. Total Knee Arthroplasty in the Stiff Knee 328
Ashok Rajgopal, Attique Vasdev, Vivek Dahiya, Vipin Tyagi
Preoperative evaluation 330
Surgical technique 330
Postoperative management 332
Complications 332

28. Hinged Knee Prosthesis 335
Ashok Rajgopal, Attique Vasdev, Himanshu Gupta, Vipin Tyagi
Personal experience 338
Why we chose to use the NexGen RHK? 339

29. Anesthesia and Pain Management of Total Knee Arthroplasty 344
Yatin Mehta, Bijaya Kumar Shadangi
Predictors influencing the outcome of knee arthroplasty 344
Assessment and optimization of comorbidities 345
Multidimensional model of perioperative risk stratification 345

Preoperative medications 346
Anesthetic management 346
Central neuroaxial blockade 347
Regional anesthesia and anticoagulation 348
Intraoperative complication 349
Postoperative pain management 349
Multimodal approach to pain management 350
Patient controlled epidural analgesia (PCEA) 350
Transdermal PCA 351
Step-down analgesia 351

30. Rehabilitation in Total Knee Arthroplasty and Ligament Injuries 354
Kalpana Aggarwal, Shivani Jain, Alok Mohan
The structure and components of knee joint 354
Injuries of knee joint 355
Types of exercise 355

SECTION 2: ARTHROSCOPY AND SPORTS INJURIES OF THE KNEE

31. Knee Anatomy 369
Vivek Pandey, Saumitra Goyal, P Sripathi Rao
Bony architecture 369
Hyaline cartilage 373
Cruciate ligaments 373
Meniscus 378
Medial aspect of the knee 380
Lateral side of the knee 383
Anterior aspect of the knee 385
Fascial structures 386
Posterior aspect of the knee and popliteal fossa 386
Capsule 388
Blood supply to the knee and anastomosis around knee 388
Nerves around the knee joint 389

32. History of Arthroscopy 395
P Sripathi Rao
Professor Kenji Takagi (1888–1963) 396
Eugene Bircher (1882–1956) 396
Michael Burman (1883–1943) 396
Masaki Watanabe (1911–1994) 396
Arthroscopic surgery and the concept of triangulation 397
Arthroscopy in the United States 397
Arthroscopy in Europe 397

33. Portals in Knee Arthroscopy 399
Nicholas A Antao, Nirav N Antao
Portals 400
Universal (inferolateral) portal 400
Incision 401
Inferomedial portal (anteromedial portal/working portal/instrument portal) 401
Accessory anterior Inferior medial portal 402
Superolateral portal 402
Superomedial portal 402
Midpatellar lateral/medial portal 402
Central portal 402
Posterior portals (posteromedial) 403
Prerequisites before doing this portal 403
Surface marking 403
Posterolateral portal 404
Postero accessory Secondary portals 404
Trans-septal portal 405
Management of arthroscopy portals 405
Complications of arthroscopy 405
Latrogenic articular cartilage damage 405
Hemarthrosis 405
Thromboembolism 405
Complex regional pain syndrome (CRPS) 406
Compartment syndrome 406

34. Clinical Examination and Diagnostic Arthroscopy of the Knee Joint **408**
P Sripathi Rao, Vivek Pandey
Anterior instability 408
Posterior instability 409
Varus instability 410
Valgus instability 411
Rotatory instabilities 412
Diagnostic arthroscopy of the knee 413
Portals 414

35. The Menisci: Menisectomy and Meniscal Repair **421**
Vivek Dahiya, Attique Vasdev, Himanshu Gupta, Ashok Rajgopal

36. Meniscal Allograft Transplantation **427**
Dinshaw Pardiwala, Sujit Kadrekar, Waseem Siddiqui
Biomechanics 427
Indications 428
Allograft selection and biology 428
Lateral meniscus
Allograft transplant 430
Medial meniscus
Allograft transplant 432
Concomitant procedures 433
Complications 433
Postoperative rehabilitation 433
Results and outcomes 433

37. Cartilage Defects: Mosaicplasty/Microfracture/ Autologous Chondrocyte **440**
David V Rajan, K Santosh Sahanand
Basic science 440
Evaluation 441
Principles of treatment 442
Treatment options 442
Chondroplasty 443
Microfracture 443
Mosaicplasty 445
Autologous chondrocyte implantation 447
Future trends 449

38. Classification of Knee Ligament Injuries (Including Dislocations) **451**
Raju Easwaran
Basics 451
Evolution of knee instability classification 451
Directional/position classification system 452
Energy of injury classification system 453
Anatomical classification 454

39. Anterior Cruciate Ligament Reconstruction **456**
Ashok Rajgopal, Attique Vasdev, Vivek Dahiya, Himanshu Gupta
Preoperative evaluation 457
Surgery 457
Graft selection 458
Surgical technique 459

40. Double-bundle ACL Reconstruction: Principles and Surgical Technique **469**
J Clement Joseph
Surgical technique 470
Rehabilitation 474
Discussion 475

41. Posterior Cruciate Ligament Reconstruction **476**
Vivek Pandey, Charles H Brown, Sachin Tapaswi
Anatomy 476
Operative treatment 482
Single-bundle tibial tunnel technique PCL reconstruction using quadrupled hamstring graft 485
Double-bundle PCL reconstruction using quadriceps tendon-bone graft 491

42. Posterolateral Complex Knee Injuries **502**
Pranjal Kodkani
Normal anatomy and functional biomechanics 503
Injuries to the postero-lateral complex 505
Treatment options 510
Technique of PLC reconstruction 513

43. Revision Options in Failed ACL and PCL Reconstruction 516

Nishith Shah, Rohan K Vakta

Failed ACL reconstruction 516
Important steps to be considered in revision ACL reconstruction 526
Revision posterior cruciate ligament (PCL) Reconstruction 527
PCL reconstruction: surgical technique 530

44. Dislocation of the Knee 536

Ashok Rajgopal, Vivek Dahiya, Vipin Tyagi

Incidence 536
Mechanism of injury 536
Classification 536
Vascular injury 537
Neurologic injury 538
Evaluation 538
Principles of management of a knee dislocation 538
Rehabilitation 539

45. Illustration of Knee MRI 541

Jatinder Pal Singh

Imaging protocol and MRI anatomy 541
Cruciate ligament pathologies 547
Meniscal pathologies 551
Collateral ligament pathologies 557
Anterior structures of the knee 558
Impingement syndromes 561
Synovial pathologies 563
Cartilage pathologies 565
Marrow pathologies 567
Cysts and bursae 572

46. Atlas: Arthroscopy 575

Ashok Rajgopal, Attique Vasdev, Vivek Dahiya, Vipin Tyagi, Himanshu Gupta

Index 603

Chapter 3

Surgical Approaches to Total Knee Arthroplasty

Sharath K Rao, Sandeep Vijayan

JAYPEE BROTHERS

INTRODUCTION

The surgical approach selected for total knee arthroplasty should be simple, surgeon-friendly and reproducible. For the surgeon, it is an important decision to choose the appropriate surgical approach. The approach selected should be flexible enough to adjust for intraoperative modifications and innovative enough for difficult primary cases.

ANATOMY

Thorough understanding of the local anatomy of the knee is essential for the surgeon to perform the various surgical approaches used in primary and revision total knee arthroplasty. Wound dehiscence and wound edge necrosis are the complications seen in the cases of revision and in primary knees with previous surgical scars. Because of this reason, it is essential to know the local blood supply to the skin and other different regions of the knee. Thorough knowledge of vascular anatomy also helps in preventing patellar osteonecrosis and postoperative hematomas.

Blood Supply to Skin

Blood supply to skin (**Figure 3.1**) around the knee is well documented. Microanatomical studies have demonstrated an anastomosis just superficial to the deep fascia. Perforators passing through the deep fascia feed this anastomosis.[1] Blood vessels penetrate the superficial fascia from this anastomosis to feed the skin (**Figure 3.1**). There is little or no communication between them in the superficial layer. Because of this reason superficial dissection above the deep fascia is likely to hamper the blood supply to the skin. For this reason, making an incision to 5–10 mm close to the old scar produces edge necrosis. Perforators to the skin usually come from the medial side from the saphenous artery.

Nerves are also similarly distributed traversing from medial to lateral. Infrapatellar branch of saphenous nerve is frequently transected in routine anterior and anteromedial incisions. This might leave a transient or permanent area of hypoesthesia on the anterolateral aspect of skin below the knee.

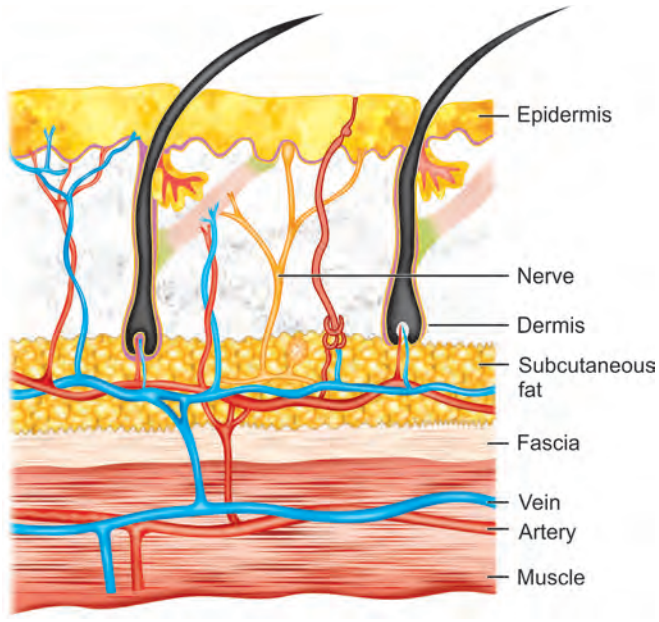

Figure 3.1 Blood supply to the skin over the knee

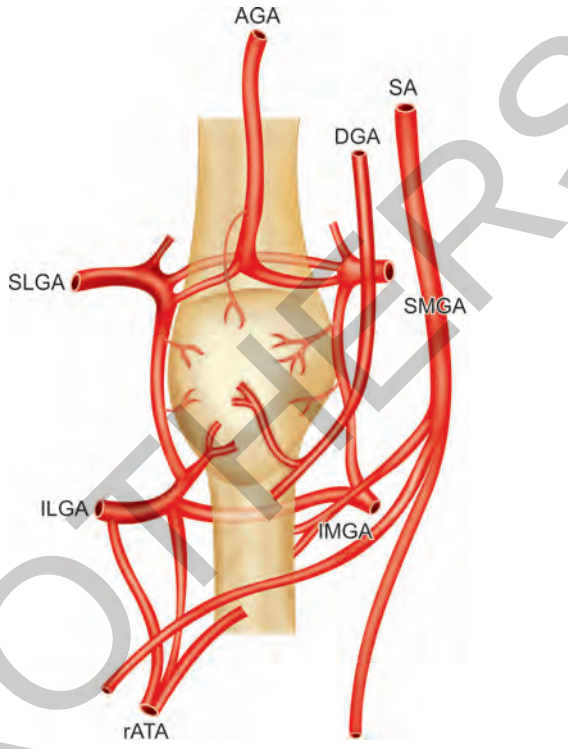

Figure 3.2 Blood supply to the patella and arterial anastomoses around the knee. *Abbreviations:* AGA, anterior genicular artery; DGA, descending genicular artery; SA, saphenous artery; SMGA, superior medial genicular artery; IMGA, inferior medial genicular artery, SLGA, superior lateral genicular artery; ILGA, inferior lateral genicular artery; rATA, recurrent branch of anterior tibial artery

Blood Supply to Patella

There is a rich plexus of arteries surrounding the patella (**Figure 3.2**). This plexus is contributed by four genicular arteries, namely superior medial genicular artery (SMGA), inferior medial genicular artery (IMGA), superior lateral genicular artery (SLGA) and inferior lateral genicular artery (ILGA). This plexus is also joined by descending genicular artery (DGA) and anterior tibial recurrent arteries (rATA).[2-4] Medial parapatellar incision will disrupt the three medial blood vessels feeding the plexus. If in addition lateral retinacular release is done, the lateral genicular vessel may also be disrupted. Excision of patellar fat pad disrupts the recurrent anterior tibial artery and excision of lateral meniscus disrupts the ILGA. Hence, the incidence of patellar vascular disruption and patellar fragmentation incidence are higher when medial parapatellar incision is combined with lateral release.[5,6]

Skin Incision

Vascularity of the skin on the anterior aspect of the knee is medially based; hence, lateral flaps are more hypoxic.[7,8] Basically, three skin incisions are described—anterior midline, medial parapatellar and curved medial (**Figure 3.3**). Medial parapatellar incision is oriented relative to Langer's lines.[9] During knee flexion, the medial parapatellar skin incision is under less tension as compared to anterior midline incision.[10] The curved medial approach is more likely to produce lateral flap hypoxia leading to wound dehiscence when compared to the anterior midline and medial parapatellar incisions. Based on its extensibility, and the authors need for further exposure and its potential for subsequent healing the anterior midline approach is prefered (**Figiure 3.4**). The incision is centered over the patella and extends proximally and distally to ~10 cm. Distally, it ends 1 cm medial to the tibial tubercle. The same skin incision can be readily used if there is the need of revision.

When there are previous scars, the longitudinal part of the scar is incorporated with the incision and the

JAYPEE BROTHERS

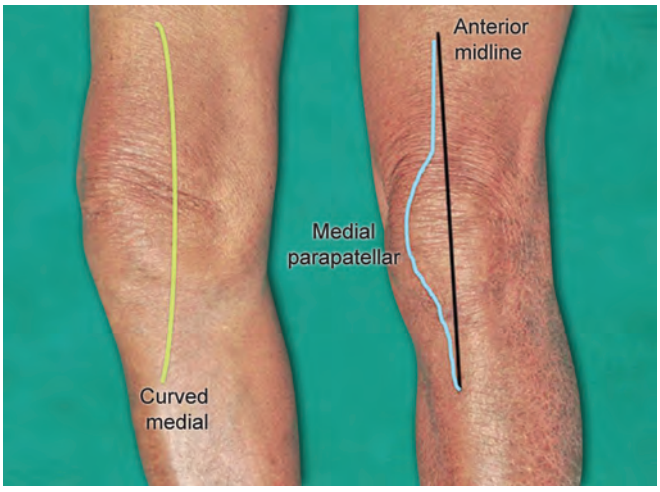

Figure 3.3 Basic skin incisions on the knee for total knee arthroplasty. Anterior midline (black), medial parapatellar (blue) and curved medial (yellow)

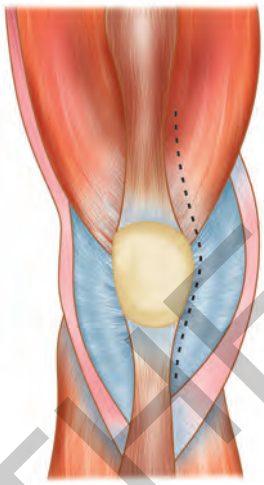

Figure 3.5 Langenbeck's medial parapatellar approach

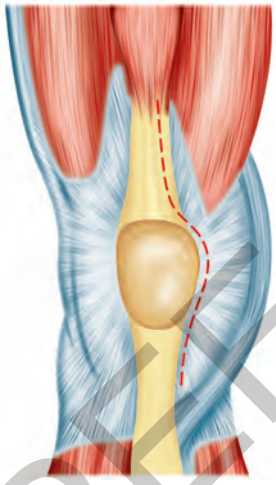

Figure 3.4 Authors preferred medial parapatellar approach

horizontal part of the scar is crossed vertically rather than at an acute angle to avoid necrosis. If there is more than one longitudinal scar, the lateral most scar is used for the incision.

Deep dissection after skin incision should be carried directly through the subcutaneous fat and deep fascia to the extensor mechanism. No flap should be elevated between the skin and fat especially on the lateral side to avoid hypoxia. This incision is made with the knee in flexion.

MEDIAL PARAPATELLAR APPROACH

Introduction

The medial parapatellar approach is the workhorse as far as any surgery on the knee joint is concerned. This is also the primary approach to total knee arthroplasty. Further modifications of this approach are described later to minimize the tissue damage, maximize the exposure and address specific problems.

Procedure

The original description of Langenbeck involved the superior dissection through the vastus medialis, which is no longer followed for the fear of knee stiffness (**Figure 3.5**). Insall's modification of incising the quadriceps tendon at the junction of medial one-third and lateral two-thirds is classically followed.[11] Insall described peeling of the quadriceps from the medial border of the patella (**Figure 3.6**). Langenbeck described leaving a cuff of tissue on the medial border of the patella for the future closure. Distally, incision is carried out 5 mm medial to the patellar tendon. The author's bias is to make the proximal incision 0.5–1 cm medial to the tendon. The incision leaves a 5 mm cuff of tissue attached to the medial border of the patella to facilitate closure. A 5 mm cuff of tissue is also

JAYPEE BROTHERS

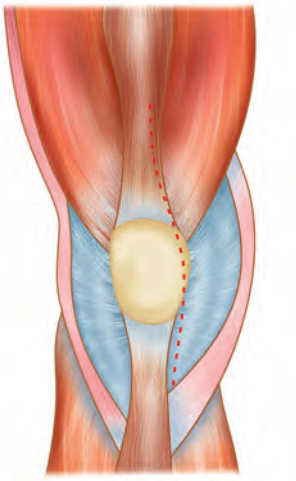

Figure 3.6 Insall's medial parapatellar approach

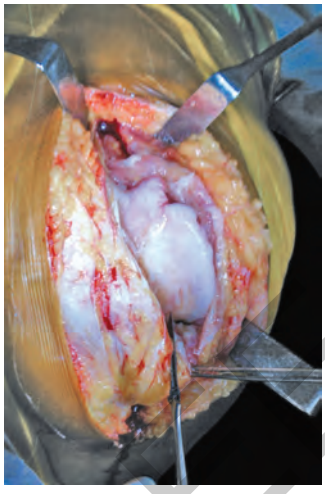

Figure 3.7 Cutting of the anterior horn of medial meniscus

left along the medial border of the patellar tendon. This entire deep dissection can easily be done with the knee in extension.

The anterior horn of medial meniscus is cut at this juncture (**Figure 3.7**). Further dissection can be done either in the extension or flexion of the knee depending on the surgeon's preference. The medial dissection is carried out at this juncture. The extent of medial dissection depends on the existing deformity. The external rotation of the tibia aids in this dissection.

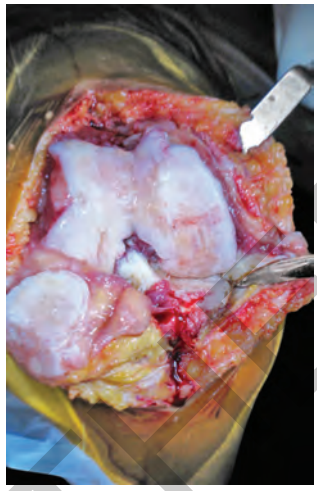

Figure 3.8 Medial dissection showing elevated periosteal sleeve with the medial meniscus

Initially, in the proximal tibia, medial release is done at least 1 cm distal from the joint line till the posteromedial aspect exposes the entire osteophytes. This is done either with cautery or the periosteal elevator. The author prefers to retain the entire medial meniscus with the sleeve at this juncture to protect the medial collateral ligament (**Figure 3.8**). Osteophytes from the medial side of tibia and femur are excised.

From here on, a systematic approach in a clockwise direction in the left knee and an anticlockwise direction in the right knee will greatly help.[12] The medial gutter is inspected, adhesions are released and excessive synovium is excised. Anterior synovium from the distal femur is reflected to expose the supracondylar region of the femur for anterior referencing. The lateral gutter is then inspected, adhesions are released and if needed synovectomy is performed. Osteophytes from the lateral femur are excised. The fat pad is detached from the meniscus and anterior horn of lateral meniscus is incised vertically. The excision of lateral meniscus at this stage helps in everting the patella. The patella is everted and the knee is slowly taken into flexion. When the knee is flexed and the patella is everted, the fat pad is assessed and some amount of fat pad may be excised, depending on the hypertrophy (**Figure 3.9**).

The anterior cruciate ligament is excised at this stage and the tibia can easily be subluxated forward.

JAYPEE BROTHERS

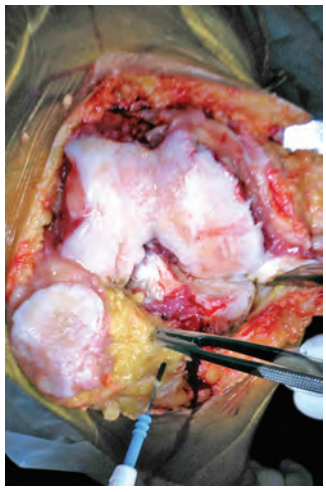

Figure 3.9 Partial removal of fat pad and patellar eversion

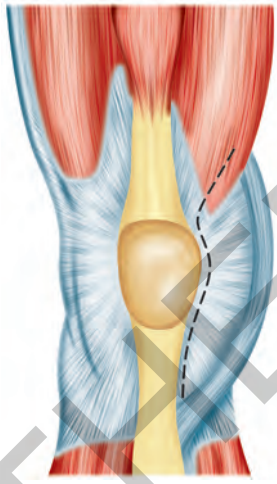

Figure 3.10 Midvastus approach

Surgical Tips

- Horizontal markings with the marking pen or electrocautery on the medial side of the patella on two cut edges of soft tissue helps in the proper approximation during later suturing.
- Release of lateral patellofemoral ligament and excision of the adequate fat pad help in the exposure of the lateral tibial plateau.
- If the patellar tendon is at risk of avulsion, fixation pins can be used at the tendon insertion.
- Retaining the medial meniscus till the end protects the medial sleeve of soft tissues, especially the medial collateral ligament.
- Resection of the lateral meniscus is done early for the better exposure of the lateral side.

MIDVASTUS APPROACH

Introduction

This approach was described and popularized by Engh and Parks.[13] Starting at the superomedial border of the patella, the vastus medialis muscle fibers are split (**Figure 3.10**). This approach maintains the intact extensor mechanism above the patella. The patellar blood supply is also less compromised. Parentis et al. observed electromyographic evidence of nerve injury while using this approach.[14] The relative contraindications to this approach are obesity, hypertrophic arthritis, flexion of less than 80° in the knee and previous high tibial osteotomy. If further exposure is needed, a quadriceps snip cannot be combined with this approach. For a further extensile approach, one has to combine tibial tubercle osteotomy with the midvastus approach.

Procedure

A standard anterior midline skin incision is made and dissection is continued through subcutaneous fat and superficial fascia. With the knee in flexion, vastus medialis muscle with its insertion to patella and quadriceps tendon is identified. The superomedial border of the patella is identified and the vastus medialis muscle is split 4 cm from the patella to its medial border. Underneath a capsule is incised leaving a cuff of tissue attached to the patella and the dissection is carried till the patellar tendon insertion to tibial tubercle. The joint is entered superiorly by incising the capsule deep to the split vastus medialis. Patella is everted and if necessary more of vastus medialis muscle can be split by blunt dissection. Closure of the capsule is done at 60° of knee flexion and the split muscle need not be sutured.

JAYPEE BROTHERS

Surgical Tips

- The sharp dissection with a scalpel should be restricted only up to 4 cm from the patella into the vastus medialis muscle.
- Medial dissection on the proximal tibia is completed before trying to evert the patella. Further blunt dissection of the vastus medialis muscle while trying to evert the patella is facilitated by this medial dissection.

SUBVASTUS APPROACH

Introduction

This approach was popularized by Hoffmann et al.[15] This is a more anatomic nature of arthrotomy. The extensor mechanism is left intact (**Figure 3.11**). Patellar tracking is better with this approach and the incidence of lateral release is less. Medial vascularity of the patella is undisturbed and is an important issue when the lateral retinacular release is done for better patellar tracking. This approach is, however, difficult to use in obese patients' knees where previous arthrotomy was done, post-high-tibial osteotomy and in revision situations. The only way to convert this approach into an extensile approach is by doing a tibial tubercle osteotomy. Stiff knees and valgus knees that require a fair amount of dissection laterally may be contraindication for this approach.

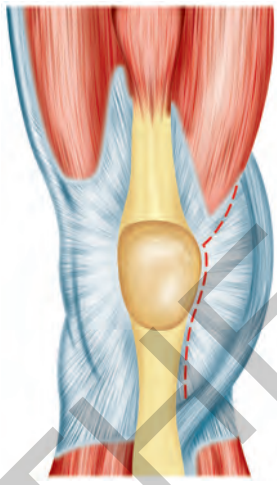

Figure 3.11 Subvastus approach

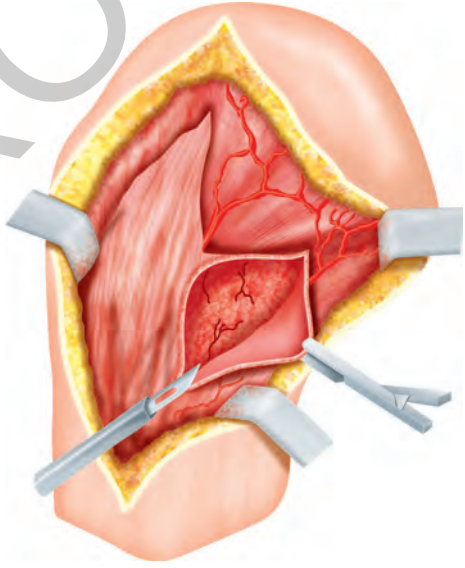

Figure 3.12 Subvastus—'L' incision on capsule

Procedure

A standard anterior midline skin incision is made and dissection is continued through subcutaneous fat and superficial fascia with knee in 90° of flexion. Blunt dissection is used to separate the epimuscular fascia from the vastus medialis down to its insertion. At this juncture, the knee can be extended and the inferior edge of the vastus medialis is identified. Vastus medialis muscle is lifted from the medial intermuscular septum and the periosteum using blunt finger dissection. At the midpatellar level, tendinous insertion of vastus medialis to the capsule is incised transversely (**Figure 3.12**). The entire extensor mechanism is retracted laterally and arthrotomy is done. The patella can be everted and the knee can be slowly flexed. Further dissection of the vastus medialis from the septum and periosteum can be done at this stage if needed. After arthroplasty, patellar tracking can be visualized through the inferomedial window. If lateral retinacular release is necessary it can be done from outside in, looking and palpating the tight structures. The capsular closure is done beginning at the apex of L-shaped incision.

JAYPEE BROTHERS

Surgical Tips

- Extension of vastus medialis blunt dissection beyond 10 cm is avoided, because this dissection can injure the septal or articular branch of DGA artery.
- While using this approach, excessive dissection can be avoided if the entire arthroplasty procedure is done without everting the patella and by laterally displacing it.

LATERAL APPROACH

Introduction

Keblish is the originator of this approach for valgus knees.[16] In valgus knees, the lateral structures are tight and this approach directly deals with the contracted structures. With this approach, extensive lateral retinacular release is incorporated in the lateral arthrotomy. This approach naturally corrects the external rotation. The medial blood supply to patella is not hampered. With the medial approach and extensive lateral release, the blood supply to the patella may get jeopardized. The stability of the medial structures is not compromised with this approach. The posterolateral corner of the knee can be easily accessed with this approach.[17] Rehabilitation is easier since the medial tissues are intact. In stiff knees, the extensile approach can be used by adding either lateral to medial quadriceps snip or tibial tubercle osteotomy to this approach.

The disadvantages of this approach are relatively poor visualization of the medial side, difficult orientation to anatomy and difficulty in everting the patella medially. The large lateral defect may invariably be created but can be avoided by coronal Z plasty of soft tissues.

Procedure

Skin incision is on the lateral patellar border in line with the Q angle. The incision is taken lateral to the tibial tubercle by 1–2 cm (**Figure 3.13**).

The iliotibial (IT) band is exposed by separating the vastus lateralis muscle, and the IT band is fingerstriped from the femur till the posterolateral corner. Varus stress to knee in extension further tightens the IT band and 'pie crusting' and lengthening of the IT band is done under digital control. This release is performed 10 cm above the joint line.

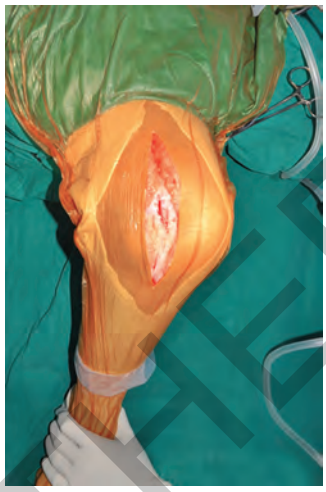

Figure 3.13 Skin incision for lateral approach



Figure 3.14 Coronal Z plasty—thick line represents the more lateral retinacular incision and thinner line the more medial capsulo-synovial incision

The incision is extended superiorly to the center of the quadriceps tendon. The lateral retinaculum is divided laterally leaving 2–4 cm cuff of tissue attached to the patella. This is carried out till the middle of Gerdy's tubercle. Incision to the deeper capsule, synovium and fat pad is made medially almost at the rim of the patella (**Figures 3.14 and 3.15**). This ensures coronal soft tissue Z plasty (**Figures 3.16 and 3.17**). When the lateral edge of the retinaculum is sutured to the medial edge of

JAYPEE BROTHERS

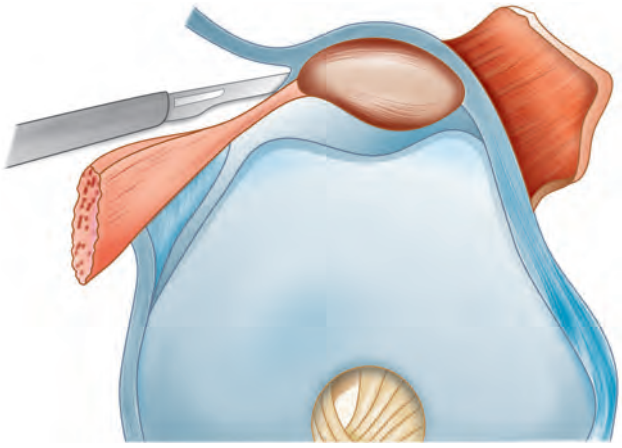

Figure 3.15 Cross-sectional diagram of coronal Z plasty incision

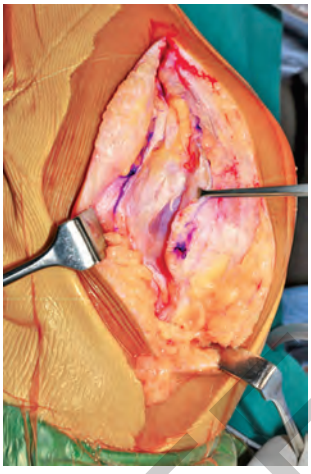

Figure 3.16 Coronal Z plasty showing the lateral incision of the retinaculum

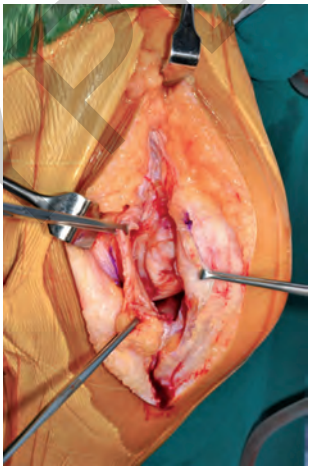

Figure 3.17 Coronal Z plasty showing the medial incision of the capsulo-synovial tissue and exposure of the joint

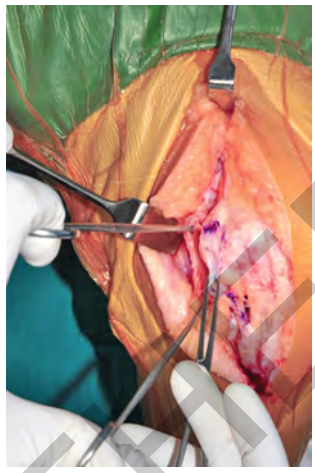

Figure 3.18 Coronal Z plasty showing the two layers to achieve closure



Figure 3.19 Coronal section diagram depicting the closure of the Z plasty

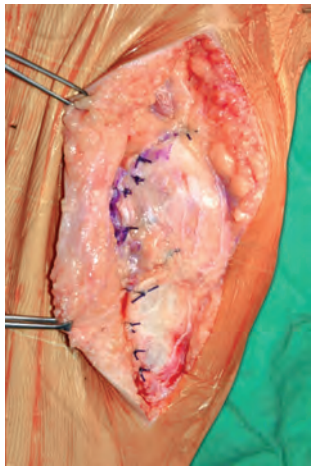

Figure 3.20 Final closure of the coronal Z plasty

JAYPEE BROTHERS

capsule—synovial complex, the adequate soft tissue coverage of the prosthesis is achieved (**Figures 3.18 to 3.20**).

Keblish recommends elevating the fascial sleeve from the Gerdy's tubercle for valgus deformities of more than 40°. The patella can be dislocated or everted medially as the knee is flexed. This can be assisted by holding the patella with the Weber's forceps. Release of the soft tissue sleeve from the lateral tibia can be easily done. After completing the TKA, coronal Z plasty of the anterior soft tissue sleeve is closed as described earlier.

Surgical Tips

- Proximal quadriceps, middle vastus lateralis and inferior fat pad dissection need to be considered separately.
- The avulsion of the patellar tendon can be avoided by using fixation pins on the tibial tubercle.
- If the medial evertion or dislocation of the patella is problematic, the surgeon has two choices: either to do a tibial tubercle osteotomy or preferably a lateral to medial rectus (quadriceps) snip.

TRIVECTOR APPROACH

Introduction

The trivector approach is based on the concept of the quadriceps pull of extension being directed in a trivector fashion and retaining the integrity of these three vectors (**Figure 3.21**). This is a good approach for optimal patellar tracking and to avoid patellar clunks.

Procedure

Standard midline skin incision is made. Quadriceps tendon and vastus medialis muscle junction is exposed. One to two cm cuff is retained medial to the patella and 1 cm medial to the patellar tendon. Superiorly, 1–2 cm medial to the quadriceps tendon and 6 cm superior to the patella, the vastus medialis is incised and continued inferiorly (**Figure 3.22**). Here the quadriceps tendon is not affected.

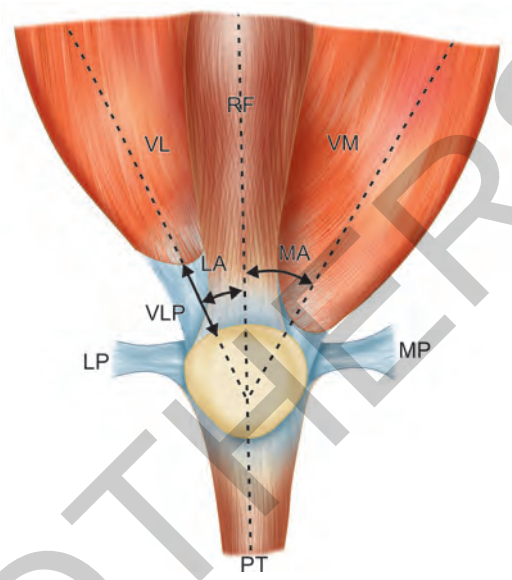

Figure 3.21 Principle of the trivector approach. *Abbreviations:* RF, rectus femoris; VM, vastus medialis; VL, vastus lateralis; MP, medial patellofemoral ligament; LP, lateral patellofemoral ligament; MA, angle between VM and RF (55–70°); LA, angle between VL and RF (22–45°); VLP, the distance between distal fibers of VL and superolateral corner of patella

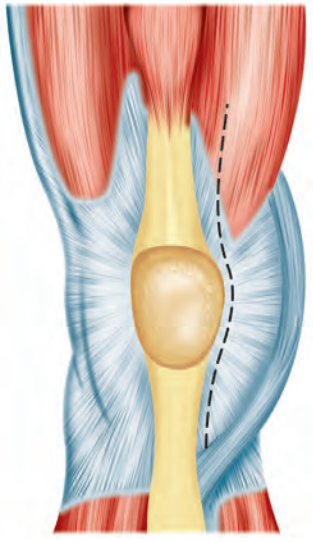

Figure 3.22 Trivector approach

Surgical Tips

At least 60% of the vastus medialis muscle fibers are kept intact on the medial side. Closure is preferably done in 100° of knee flexion.

JAYPEE BROTHERS

QUADRICEPS (RECTUS) SNIP

Introduction

Quadriceps or rectus snip was described by Garvin.[18] This was further modified by Insall.[5] This is a technically simple procedure that can be easily combined with a medial parapatellar approach and is useful in stiff knees. It does not affect the recovery and the function of quadriceps muscle and invariably spares superior lateral genicular vessels.

Procedure

A standard medial parapatellar arthrotomy is performed. All the scar tissues from the lateral and medial gutters and osteophytes are removed. The guideline to do a lateral retinacular snip is when there is difficulty in everting the patella without placing the patellar tendon at risk. At this juncture, a decision on performing the quadriceps snip is taken. The proximal limit of the rectus incision is extended proximally and laterally at approximately 45° to transect the rectus femoris tendon at its musculotendinous junction. After this, the patella can be mobilized distally and laterally. If the exposure is inadequate, a lateral retinacular release can be added and if the exposure is still inadequate, quadriceps turndown is done.

Surgical Tips

- An attempt to preserve the SLGAs done to prevent the devascularization of the patella.
- Medial rectus snip can be done while using the lateral approach to the knee, to enhance the exposure.
- Active knee extension can be started immediately after surgery.

QUADRICEPS TURNDOWN

Introduction

This approach, initially described by Coonse and Adams, has undergone many modifications over the years.[19] This approach is preferred for stiff knee, ankylosed knee, severe varus, and revision knees. This approach should be used only if and after quadriceps snip is unable to expose the knee and evert the patella.[20]

Procedure

The anterior midline standard approach is applied. Medial and lateral parapatellar gutters are cleared off adhesions. Osteophytes from the femur and tibia are excised. The quadriceps snip is performed at an angle of 45° in the lateral oblique direction and extended proximally till the musculotendinous junction (**Figure 3.23**). If patellar eversion is still not possible, a lateral release is done (**Figure 3.24**). If the exposure is still limited, a quadriceps modified V-Y turndown is done by connecting the lateral release incision to the quadriceps snip incision (**Figure 3.25**). The patella along with the quadriceps tendon is turned down and kept moist with a wet gauze throughout the procedure (**Figure 3.26**). After the surgery, medial parapatellar and quadriceps snip are closed and the lateral release incision can be left open.

Surgical Tips

- The posterior aspect of the patellar tendon is released adequately before the procedure is undertaken.
- Vastus medialis and vastus lateralis bridges are kept intact for further suturing.

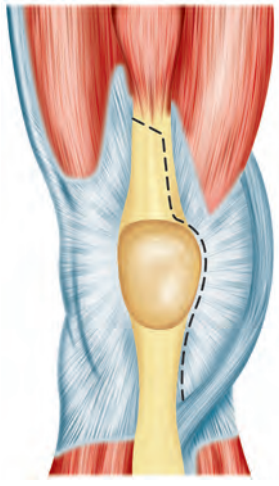

Figure 3.23 Quadriceps turndown—step 1 depicting a quadriceps snip

JAYPEE BROTHERS

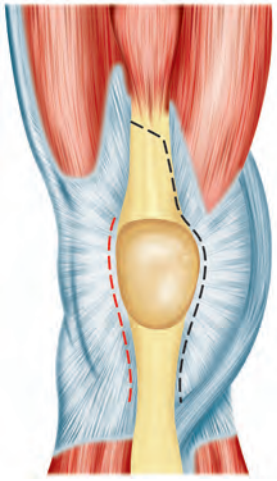

Figure 3.24 Quadriceps turndown—step 2 depicting lateral retinacular incision (red dotted lines) along with the quadriceps snip (black dotted lines)

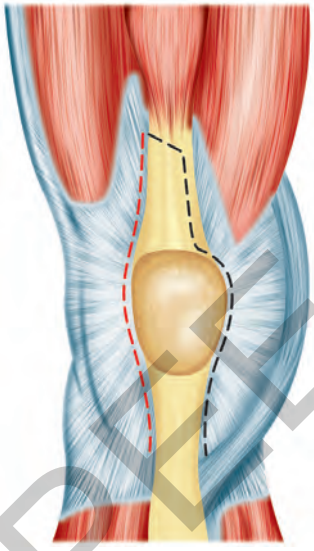

Figure 3.25 Quadriceps turndown—step 3 connecting the lateral retinacular incision to the rectus snip

- Usage of a fixation pin at the patellar tendon insertion is a useful technique to avoid the rupture of the patellar tendon.
- Knee bracing for two weeks is necessary after this procedure.
- While this approach affords excellent visibility, the persistent extensor lag is the major disadvantage that restricts its usage.

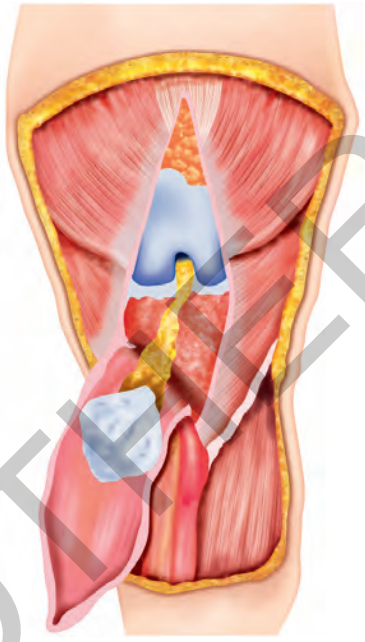

Figure 3.26 Quadriceps turned down

TIBIAL TUBERCLE OSTEOTOMY

Introduction

This is a technique adopted for stiff knees, when there is a patella baja, in revision situations and in previous severe varus deformities.[21,22]

Procedure

Anterior midline standard TKA incision that is extended distally medial to the tibial tubercle for 6–8 cm is made. An oscillating saw is used to do a transverse osteotomy of the tibial tubercle. The osteotomy extends at least 6–8 cm distally from the proximal edge of the tibial tubercle. A curved osteotome is used to complete the osteotomy laterally. The periosteal hinge and lateral muscular attachment are kept intact to the tubercle on the lateral side (**Figure 3.27**). The entire osteotomized fragment is osteoclased and the exposure completed. Three SS wires are necessary to repair the osteotomy and at least one of them should be through the medial cortex of the tibia (**Figure 3.28**).

JAYPEE BROTHERS

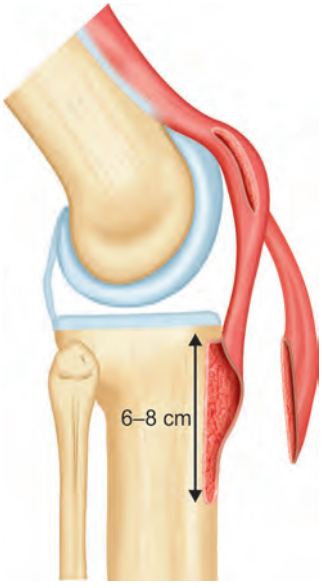

Figure 3.27 Tibial tubercle osteotomy



Figure 3.28 Tibial tubercle osteotomy fixation

Surgical Tips

- The skin incision is avoided on the tibial tubercle, but it is done medial to it.
- While using the tibial tray, using a stem to bypass the osteotomy safeguards the weak bone.
- Less than 3 cm of osteotomy length is avoided and fixing the osteotomy with screws is also avoided.
- In patients who kneel down, osteotomy is not a good choice because of skin irritation.

REFERENCES

1. Haertsch PA. The blood supply to the skin of the leg: a post-mortem investigation. Br J Plast Surg. 1981;34:470-77.
2. Scapinelli R. Blood supply of the human patella: its relation to ischaemic necrosis after fracture. J Bone Joint Surg Br. 1967;49:563-70.
3. Laskin RS. Soft tissue techniques in total knee replacement. In: Laskin RS (Ed.), Total knee replacement. London: Springer-Verlag; 1991. pp. 41-53.
4. Insall JN, Kelly MA. Anatomy. In: Insall JN, Windsor RE, Scott WN, Kelly MA, Aglietti P (Eds), Surgery of the knee, vol. 1, 2nd edn. New York: Churchill Livingstone; 1993. pp. 1-20.
5. Insall JN. Surgical approaches. In: Insall JN, Windsor RE, Scott WN, Kelly MA, Aglietti P (Eds), Surgery of the knee, vol. 1, 2nd edn. New York: Churchill Livingstone; 1993. pp. 135-48.
6. Ritter MA, Herbst SA, Keating EM, Faris PM, Meding JB. Patellofemoral complications following total knee arthroplasty: effect of a lateral release and sacrifice of the superior lateral genicular artery. J Arthroplasty. 1996;11:368-72.
7. Younger ASE, Duncan CP, Masri BA. Surgical approaches in revision total knee arthroplasty. J Am Acad Orthop Surg. 1998;6:55-64.
8. Johnson DP. Midline or parapatellar incision for knee arthroplasty. J Bone Joint Surg Br. 1988;70:656-8.
9. Langer K. On the anatomy and physiology of the skin. Br J Plast Surg. 1978;31:3-8.
10. Johnson DP, Houghton TA, Radford P. Anterior midline or medial parapatellar incision for arthroplasty of the knee. J Bone Joint Surg Br. 1986;68:812-4.
11. Insall J. A midline approach to the knee. J Bone Joint Surg Am. 1971;53:1584-6.
12. Douglas DR, Broune RB. In: Paul AL, Jess HL (Eds), Knee arthroplasty, vol. 1, 3rd edn. Philadelphia, PA: Lippincott Williams and Wilkins; 2009. pp. 1-18.
13. Engh GA, Parks NL. Surgical technique of the mid vastus arthrotomy. Clin Orthop. 1998;351:270-4.

JAYPEE BROTHERS

14. Parentis MA, Rumi MN, Deol GS, et al. A comparison of the vastus splitting and median parapatellar approaches in total knee arthroplasty. Clin Orthop. 1999;367:107-16.
15. Hoffmann AA, Plaster RL, Murdock LE. Subvastus (southern) approach for primary total knee arthroplasty. Clin Orthop. 1991;269:70-7.
16. Keblish PA. The lateral approach to the valgus knee. Surgical technique and analysis of 53 cases with over two-year follow-up evaluation. Clin Orthop. 1991;271:52-62.
17. Munzinger V, Boldt J, Keblish P (Eds). Primary knee arthroplasty. Heidelberg: Springer-Verlag; 2005.
18. Garvin KL, Scuderi G, Insall JN. Evolution of the quadriceps snip. Clin Orthop. 1995;321:131-7.
19. Coonse K, Adams JD. A new operative approach to the knee joint. Surg Gynecol Obstet. 1943;77:344-7.
20. Scott RD, SIliski JM. The use of a modified V – Y quadricepsplasty during total knee replacement to gain exposure and improve flexion in the ankylosed knee. Orthopedics. 1985;8:45-8.
21. Whiteside LA. Exposure in difficult total knee arthroplasty using tibial tubercle osteotomy. Clin Orthop. 1995;321:32-5.
22. Whiteside LA, Ohl MD. Tibial tubercle osteotomy for exposure of the difficult total knee arthroplasty. Clin Orthop. 1990;260:6-9.

JAYPEE BROTHERS

for detailed information on orthopedics books, visit our website **www.jaypeebrothers.com,** for detailed information on orthopedics books, visit our website **www.jaypee**

KNEE SURGERY

Salient Features

- Comprehensive coverage from anatomy to advanced techniques
- Coverage of recent technology and futuristic pathways
- Recent advances in complex knee arthroplasty issues such as infections covered exhaustively
- Abundant pictorial depiction of arthroscopic appearances
- Includes the chapters devoted to MRI appearances of the normal knee and disease pathology
- Covers complex sports injury issue such as revision ligament reconstruction.



Ashok Rajgopal is the Chairman of Medanta Bone and Joint Institute, Medanta—The Medicity, Gurgaon, NCR, India. As a dedicated knee surgeon, he has almost 30 years of experience in knee surgery. In addition, he has vast experience of trauma surgery as well. He was appointed the Honorary Orthopedic Surgeon to the then President of India, His Excellency Mr KR Narayanan, in 1997.

A prolific surgeon, he has several firsts to his credit—he performed the first bilateral total knee replacement surgery in India in April 1987 and the first MIS unicompartmental surgery in March 2002. A member of the Zimmer Global Persona Developer Team, he has contributed significantly to the designing of the PERSONA Knee system.

On the eve of our nation's 65th Republic Day, in recognition of his immense contribution to the field of orthopedics, the President of India conferred him with the Padmashri, the fourth highest civilian honor of the country. As a mark of recognition of his contribution to the field of orthopedics, he was awarded the Honorary Fellowship of the Royal College of Surgeons (Orthopedics), Edinburgh, Scotland, UK, in 2010 and also the Bharat Shiromani Award for professional excellence in the field of orthopedics, for the years 2008–2009.

He is the Founder Secretary and Past President of the Asia-Pacific Arthroplasty Society (APAS) and Past President of the Indian Arthroscopy and the Indian Hip and Knee Societies. He was awarded the Lifetime Achievement Award by the APAS in 2012.

He has successfully treated several international level sports persons for a variety of knee-related sports injuries. These players have gone on to win laurels for the country after their surgery.

A keen academician, he is a much sought after speaker at several international and national conferences and has also chaired several orthopedics conferences both in India and abroad. In addition, he has to his credit several articles in international journals and chapters in orthopedic textbooks. He is on the editorial board of the KSSTA (*Knee Surgery Sports Traumatology and Arthroscopy*) and a Reviewer for the *Journal of Bone and Joint Surgery* (JBJS) (British Volume), both well-known and widely read journals of orthopedic surgery.

Available at all medical book stores
or buy directly from Jaypee Brothers through online shopping
at www.jaypeebrothers.com

JAYPEE BROTHERS
Medical Publishers (P) Ltd.
www.jaypeebrothers.com

Join us on facebook.com/jaypeebrothers

Shelving
Recommendations
ORTHOPEDICS
SURGERY

ISBN 978-93-5152-225-6