our website www.jaypeebrothers.com, for detailed information on dermatology books, visit our website www.jaypeebrothers.com

Celebrating 50 YEARS
Passion, Quality and Innovation in Healthcare Publishing

Atopic Dermatitis and Pruritus
Interesting Cases

An initiative of
Atopic Dermatitis Centers of Reference and Excellence (ADCARE)
Global Allergy and Asthma European Network (GA^{2}LEN)

Editor
Kiran Godse

Associate Editor
Anant Patil

Foreword
Torsten Zuberbier

JAYPEE

Contents

SECTION 1— INTERESTING CASES: ATOPIC DERMATITIS

Case 1: **Severe Atopic Dermatitis in a Patient with a History of Renal Transplantation** 3
Barbara Rogala, Lesia Rozłucka, Andrzej Bożek

Case 2: **Recalcitrant Red Plaque in a Patient with Atopic Dermatitis** 8
Chuda Rujitharanawong, Kanyalak Munprom, Rungsima Kiratiwongwan, Sumanas Bunyaratavej, Kanokvalai Kulthanan

Case 3: **Successful Treatment of Prurigo Nodularis with Dupilumab in an Elderly Patient with Atopic Disease** 11
Paulo Ricardo Criado, Roberta Fachini Jardim Criado

Case 4: **Two Cases of Severe Adult-onset Atopic Dermatitis Responsive to Dupilumab** 19
Justin Greiwe, Jonathan A Bernstein

Case 5: **A Quality-of-life Game Changer: Treatment with Dupilumab in an Adult with Atopic Dermatitis** 25
Line Brok Nørreslet, Yasemin Topal Yüksel, Tamara Theresia Lund, Tove Agner, Simon Francis Thomsen

Case 6: **Refractory Atopic Dermatitis in a Young Male Patient: Course and Symptoms Following Start of Dupilumab** 29
Tamara Theresia Lund, Line Brok Nørreslet, Yasemin Topal Yüksel, Tove Agner, Simon Francis Thomsen

Case 7: **Erythrodermic Early Onset Atopic Dermatitis Clinically Mimicking Mycoses Fungoides/Sezary Disease** 32
Ferrucci S, Tavecchio S, Angilieri L, Germiniasi F, Berti E, Boneschi V

Case 8: **Food Allergy, Vaccination and Atopic Dermatitis Treatment in Children** 35
Luis Felipe Ensina, Fernanda Sales da Cunha, Ana Paula Cusato-Ensina

Case 9: **Do Not Miss Contact Allergy in Atopic Dermatitis Patients** 38
Esra Saraç, Emek Kocatürk

Case 10: **Successful Treatment of Epidermolysis Bullosa Pruriginosa with Anti-IgE Therapy (Omalizumab): A Case Report and 4 Years Follow-up** 44
Salma Ahmed Taha, Maryam Ali Al-Nesf, Amina Mohamednoor Al-Obaidli

Case 11: **The Cause Behind Multiple Drug Hypersensitivity Reactions in a Patient with Atopic Dermatitis** 48
Iman Nasr, Shamsa H Al Maawali, Prabha MP Liyanage

Case 12: **Severe Atopic Dermatitis: Fast Effectiveness and Safety of Dupilumab** 52
Marisa Paulino, Célia Costa

Case 13: **Role of Patch Testing in Atopic Dermatitis** 55
Michael Rudenko

Case 14: **Eczema Herpeticum in a Patient with Atopic Dermatitis during Treatment with Selective JAK1 Inhibitor: A Case Report** 57
Michał Adamczyk, Bartłomiej Wawrzycki, Joanna Bartosińska, Dorota Krasowska

Case 15: **Dupilumab-induced Face Dermatitis in Patients with Adult-onset Atopic Dermatitis and Severe Asthma** 62
Mona Al-Ahmad, Eman Alsayed, Wafaa Talaat

Case 16: **Dupilumab in the Treatment of Severe Atopic Dermatitis and Eczema Herpeticum Refractory to Systemic Treatment** 65
Omar Lupi, Solange Oliveira Rodrigues Valle

Case 17: **Red Face during Dupilumab Therapy** 69
E Serra-Baldrich, V Flores–Climent, J Spertino, L Puig

Case 18: **A Case Report of a Patient with Refractory Severe Atopic Dermatitis and Extremely High Total Serum IgE Levels Treated with High Doses of Omalizumab in Combination with Conventional Therapy** 72
Maia Gotua, Nino Lomidze, Giorgi Shengelidze, Elene Kakabadze, Ketevan Kvaratskhelia, Nana Dolidze

Case 19: **Atopic Dermatitis in Skin of Color** 76
Kiran Godse, Kripa Ajmera, Gauri Godse, Anant Patil

Case 20: **Herbal Preparations Causing Irritation in a Patient with Atopic Dermatitis: A Case Report** 79
Tejaswini Shekhar Sharma, Gauri Godse, Anant Patil, Feroz K

SECTION 2— INTERESTING CASES: PRURITUS

Case 1: **Long-term Efficacy and Safety of Dupilumab in Prurigo Nodularis: A Case Report** 85
Germiniasi F, Tavecchio S, L Angileri, Berti E, Ferrucci S

Case 2: **Generalized Purpuric Macules with Intense Pruritus: A Single Case Report** 89
Chuda Rujitharanawong, Nuttagarn Jantanapornchai, Charussri Leeyaphan, Penvadee Pattanaprichakul, Kanokvalai Kulthanan

Case 3: **Importance of Dietary History in the Presence of a Biopsy Suggestive of Urticarial Vasculitis** 93
Iman Nasr, Humaid A Al Wahshi, Shamsa H Al Maawali, Ethar Said Mohamed Al Hajri

Case 4: **Chronic Suffering from Undiagnosed Generalized Itching, Papules, and Plaques: The Relief Impact of a Single Dermoscope Examination** 98
Gabriel Peres, Vidal Haddad Jr, Roberta Fachini Jardim Criado, Walter Belda Junior, Paulo Ricardo Criado

Case 5: **A Case of Pruritus with Symptomatic Dermographism Previously Treated as Eczema** 104
Ryo Saito, Hajime Shindo, Shunsuke Takahagi, Akio Tanaka, Michihiro Hide

Case 6: **Immediate and Long-lasting Resolution of Pruritus and Skin Lesions by Targeting the IL-5 Receptor** 107
Guillet Carole, Steinmann Simona, Rosset Nina, Kolm Isabel, Schmid-Grendelmeier Peter

Case 7: **An Unexpected Cause of Symptomatic Dermographism: Scabies** 112
Esra Saraç, Emek Kocatürk

Case 8: **Intensive Pruritus, Excoriations and Inflammatory Papules Masking Dermatitis Herpetiformis** 117
Maia Gotua, Elene Kakabadze

Case 9: **Diagnosis and In Vivo Detection of *Sarcoptes Scabiei* by Dermoscopy** 121
Sushrut Save, Kiran Godse

Case 10: **Prurigo Nodularis Treated Successfully with Dupilumab: Case Report and Review of the Literature** 124
Jennifer Astrup Sørensen, Jesper Grønlund Holm, Simon Francis Thomsen

Index 131

SECTION

1

Interesting Cases: Atopic Dermatitis

JAYPEE BROTHERS

JAYPEE BROTHERS

CASE 1

Severe Atopic Dermatitis in a Patient with a History of Renal Transplantation

Barbara Rogala, Lesia Rozłucka, Andrzej Bożek

JAYPEE BROTHERS

CASE PRESENTATION

A 22-year-old Caucasian man was urgently admitted to the Dermatology and Allergology Department due to generalized erythroderma in the course of severe atopic dermatitis (AD). The patient reported increasing skin deterioration for several weeks before hospitalization, accompanied by a mild increase of temperature. Exacerbation of the symptoms, by his own admission, coincided with a prolonged (several weeks) high exposure to dust and mold (old and damp apartment). The patient did not associate deterioration of his health status with either food or medication intake. He emphasized that the symptoms intensified despite the medication recommended during the last visit in the Outpatient Dermatology Clinic.

COURSE OF ILLNESS

The patient has suffered from atopic dermatitis (AD) since the age of 3 years. The course of the disease varied with periods of remission and exacerbation. Initial mild form of the disease progressed periodically to moderate form, treated in the Outpatient Dermatology and Allergology Clinic at the place of residence. During the early childhood, the patient noted a significant relationship between the exacerbation of skin lesions and the consumption of chicken eggs and milk. Later, he did not observe any adverse food-related reactions.

Since 12 years old, the patient suffered from periodic allergic rhinitis during the tree dusting season and was treated symptomatically with antihistamine drugs. During this period, the patient presented signs and symptoms of bronchial asthma. Exacerbations during the fall-winter period were periodically treated with inhaled corticosteroids and β2-mimetics. Presently, the patient does not experience symptoms of asthma.

Additionally, the patient was diagnosed with nephroangiosclerosis and renal hypertension in the early childhood. In 2006, the right kidney transplant was performed due to the progressive vascular sclerosis with increasing kidney failure and arterial hypertension. The postoperative course was uneventful. The patient received chronic, immunosuppressive

therapy (tacrolimus and mycophenolate mofetil), which was constantly supervised by the nephrologist.

Since 2013, there was a significant worsening of the AD symptoms, despite continued use of topical corticosteroids, emollients, and oral antihistamines. An addition of prednisone in a dose of 10–15 mg daily allowed for a relative control of the disease symptoms. Immunosuppressants were administered chronically: Tacrolimus 3 mg daily and mycophenolate mofetil 750 mg daily.

First Hospitalization

In November 2019, the patient was hospitalized in the Department of Dermatology and Allergology due to exacerbation of AD. Assessment of skin condition showed 65–70 points according to the SCORAD (SCORing Atopic Dermatitis) scale. A laboratory test revealed an increased C-reactive protein level, leukocytosis (12.51 × 10^3/μL), eosinophilia (7.8%), and increased total immunoglobulin E (IgE) level (2,500 IU/mL); serum levels of IgA, IgM, IgG, and c1q complex were within the normal. The results of aeroallergen and food-specific IgE concentration are presented in **Table 1**.

Autoimmune profiles (ANA1, ANA2, ANA3) were negative. Genetic testing revealed mutation of the filaggrin gene *2282del4* as a heterozygote. In cultures from skin lesions, nose and throat, a significant increase of *Staphylococcus aureus* was found. An antibiotic was applied according to the antibiogram (amoxicillin 3 × 1 g/day) as well as prednisone 15 mg/day and loratadine 2 × 20 mg/day. In addition, external treatment was modified to include first-line topical corticosteroids (clobetasol propionate) followed by tacrolimus (0.1%) ointment, which resulted in a clinical improvement. The immunosuppressive therapy was continued without change of drug dosage, all in consultation with the nephrological transplant center.

TABLE 1: Serum-specific IgE concentration of inhalant and food allergens (Polycheck) and their interpretation.

Lp.	Allergen	sIgE (kU/L)	Class
Inhalant panel			
1.	Sweet vernal grass pollen	83.00	5
2.	Cocksfoot pollen	68.00	5
3.	Timothy Grass pollen	94.00	5
4.	Rye pollen	80.00	5
5.	Alder pollen	66.00	5
6.	Birch pollen	67.00	5
7.	Hazel pollen	27.00	4
8.	White oak pollen	8.20	3
9.	Ragweed pollen	0.54	1
10.	Mugwort pollen	0.59	1
11.	Plantain pollen	91.00	5
12.	*Dermatophagoides pteronyssinus*	74.00	5
13.	*Dermatophagoides farinae*	≥100	6
14.	Cat epithelia	91.00	5
15.	Dog epithelia	≥100	6
16.	Horse epithelia	<0.15	0
17.	*Penicillium notatum*	4.30	3
18.	*Cladosporium herbarum*	0.90	2
19.	*Aspergillus fumigatus*	2.40	2
20.	*Alternaria alternata*	2.90	2
21.	CCD marker	2.70	2
Food panel			
1.	Egg white	21.00	4
2.	Egg yolk	5.10	3
3.	Milk	<0.15	0
4.	Baker's yeast	1.10	2
5.	Wheat flour	3.80	3

Continued

JAYPEE BROTHERS

Continued

Lp.	Allergen	sIgE (kU/L)	Class
6.	Rye flour	2.70	2
7.	Rice	2.80	2
8.	Soybean	<0.15	0
9.	Peanut	0.40	1
10.	Hazelnut	12.20	3
11.	Almond	0.28	0
12.	Apple	1.10	2
13.	Kiwi	0.22	0
14.	Apricot	0.36	0
15.	Tomato	0.61	1
16.	Carrot	0.80	2
17.	Potato	1.30	2
18.	Celery	3.20	2
19.	Codfish	<0.15	0
20.	Crab	7.90	3
21.	CCD marker	3.20	2

sIgE (kU/L)	Class	Interpretation
<0.35	0	No specific antibody detectable
0.35–<0.7	1	Very weak antibody concentration
0.7–<3.5	2	Weak antibody concentration
3.5–<17.5	3	Clear antibody concentration
17.5–<50	4	Strong antibody concentration
50–<100	5	Very strong antibody concentration
>100	6	Extremely high antibody concentration

(CCD: cross-reactive carbohydrate determinant; sIgE: specific immunoglobulin E)

Due to a significant improvement of the patient's skin condition, the patient was discharged from the hospital on a reduced dose of prednisone to 10 mg/day. In the following 2 months, the disease stabilized; there was no itching of the skin and a reduction of skin lesions' size was noted.

Second Hospitalization

Sudden exacerbation of the disease took place in January 2020. The patient was readmitted to the Department of Dermatology and Allergology. The physical findings on admission were as follows: Generalized extensive erythema (SCORAD 90), exudative lesions with numerous erosions, very strong burning and hyperalgesia of the skin, and temperature rise. No other significant deviation in the physical examination was identified. The immunosuppressive treatment was continued according to the scheme recommended by the nephrologist—mycophenolate mofetil 2 × 500 mg/day and 2 mg of tacrolimus in the morning and 1 mg in the evening as well as antibiotic therapy (initially amoxicillin + clavulanic acid 3 times 1 g/day orally and then cefuroxime, initially 2 times 750 mg and then 2 times 1.5 g intravenously), antihistamine (bilastine 20 mg twice a day) and 4 mg of dexamethasone intravenous twice a day.

The external treatment was intensified (cholesterol ointment, boric acid compresses, emollients and mometasone furoate). After the nephrology consultation, a decision to replace mycophenolate mofetil with methotrexate 15 mg/day was made.

After the third dose of methotrexate a dry, paroxysmal cough, increased body temperature (37.8°C), laryngitis, stomach ache, and diarrhea (four to six stools per day) were recorded. Suspecting a *Clostridium difficile* infection, the specific test was performed. A presence of the antigen *Clostridium difficile*, in the absence of the toxin, was identified.

Nevertheless, due to the clinical presentation, vancomycin (250 mg/day for 10 days) was administered. Dexamethasone was set aside; prednisone 20 mg/day was used together with bilastine 20 mg twice a day. Skin care practices were maintained (cholesterol

JAYPEE BROTHERS

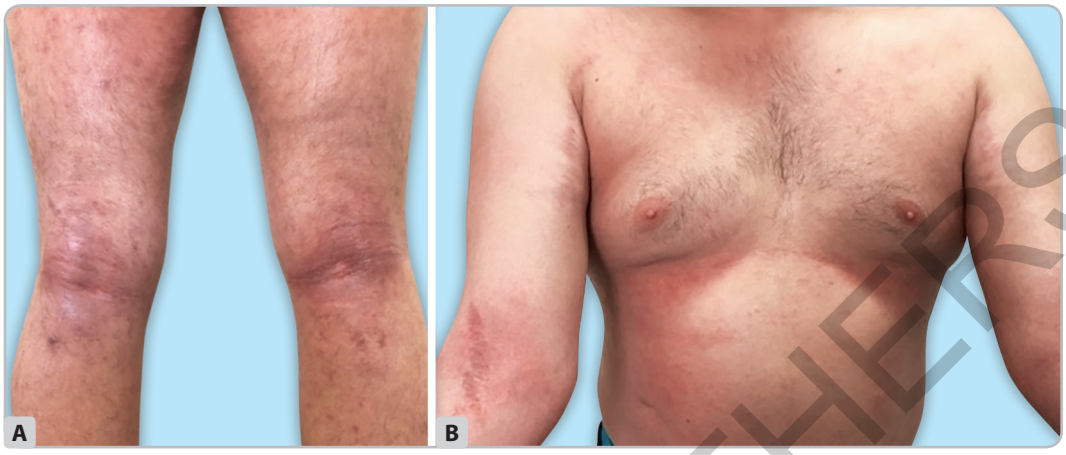

FIGS. 1A AND B: Patient's skin condition during the latest visit in the hospital outpatient clinic.

ointment, emollients cooling ointment with hydrocortisone) and hypertension treatment was continued (amlodipine 10 mg/day, ramipril 2.5 mg/day). Due to the cough, nebulization of budesonide 2 times 1.0/day was given. The immunosuppressive treatment was continued. Diarrhea and cough subsided within 48 hours.

A significant improvement of the skin condition was noted: From a generalized form to regional lesions on the lower limbs, elbow flexion areas as well as neck and face (SCORAD: 60–65 points).

Follow-up

The patient received the treatment as above, with gradual reduction of prednisone to 10 mg/day (other drugs, including the remaining immunosuppressive regimen, as during the hospitalization). Topical treatment included mometasone furoate, tacrolimus and fludrocortisone acetate (on face) and emollients. Presently, the patient is constantly monitored in the Hospital Outpatient Clinic. **Figure 1** presents the patient's skin condition during the last control visit.

DISCUSSION

Atopic dermatitis is a chronic inflammatory skin disorder. The pathophysiology of the disease is not completely understood. It is a complex interplay between immune dysregulation, environmental and infectious agents, and disturbed skin function.[1] Although our patient demonstrates a high degree of sensitization to aeroallergens, it does not explain completely the aggravation of the disease, which turns into severe after several years of renal transplantation. Having experienced exacerbation of his skin disorder in response to house mites and molds, the patient has taken avoidance measures. It can be assumed that the immunosuppressive drugs administered after the renal transplantation might be responsible for the worsening of the disease.[2,3]

Nevertheless, it is worth noticing that post-transplant immunosuppressive agents are frequently advised in the management of patients with severe AD.[4-7]

In spite of the application of the commonly recommended treatment, which included topical emollients/moisturizers, corticosteroids, and calcineurin inhibitors, the condition of

JAYPEE BROTHERS

the patient's AD exacerbated and became complicated with erythroderma. The condition of the skin significantly improved following the application of antibiotics and prednisone. This strongly implicates skin infection as the main cause of the AD exacerbation. Filaggrin mutation, which was confirmed in the patient, is a known factor predisposing to skin superinfection.[8] However, the effect of chronic immunosuppressive therapy on the exacerbation of AD cannot be completely excluded.

CONCLUSION

Patients suffering from severe AD and concomitant severe medical disorders should remain under constant control of several specialists.

KEY MESSAGES

- Although IgE-mediated sensitization to the airborne allergens is an important feature of the AD pathophysiology, it is not the sole factor of its underlying mechanism.
- IgE-mediated sensitization may have limited clinical relevance, particularly in the severe stage of the disease.
- Severe exacerbation of the AD may be observed in some groups of patients in spite of the application of the recommended treatment (topical corticosteroids and optimal care practices) and allergens' avoidance.
- The skin infection, as a causative factor of severe AD exacerbation, should be taken into account, particularly in patients with filaggrin mutation and concomitant, not only atopic, diseases.

REFERENCES

1. Wollenberg A, Barbarot S, Bieber T, Christen-Zaech S, Deleuran M, Fin-Wagner A, et al. Consensus-based European guidelines for treatment of atopic eczema (atopic dermatitis) in adults and children: part II. J Eur Acad Dermatology Venereol. 2018;32:850-78.
2. Arikan C, Kilic M, Tokat Y, Aydogdu S. Allergic disease after pediatric liver transplantation with systemic tacrolimus and cyclosporine a therapy. Transplant Proc. 2003;35:3039-41.
3. Granot E, Yakobovich E, Bardenstein R. Tacrolimus immunosuppression - An association with asymptomatic eosinophilia and elevated total and specific IgE levels. Pediatr Transplant. 2006;10:690-3.
4. Murray ML, Cohen JB. Mycophenolate mofetil therapy for moderate to severe atopic dermatitis. Clin Exp Dermatol. 2007;32:23-7.
5. Phan K, Smith SD. Mycophenolate mofetil and atopic dermatitis: systematic review and meta-analysis. J Dermatolog Treat. 2019;1-5.
6. Keaney TC, Bhutani T, Sivanesan P, Bandow GD, Weinstein SB, Chenung LCC, et al. Open-label, pilot study examining sequential therapy with oral tacrolimus and topical tacrolimus for severe atopic dermatitis. J Am Acad Dermatol. 2012;67:636-41.
7. Lyakhovitsky A, Barzilai A, Heyman R, Baum S, Amichai B, Solomon M, et al. Low-dose methotrexate treatment for moderate-to-severe atopic dermatitis in adults. J Eur Acad Dermatology Venereol. 2010;24:43-9.
8. Clausen ML, Edslev SM, Andersen PS, Clemmensen K, Krogfelt KA, Agner T. *Staphylococcus aureus* colonization in atopic eczema and its association with filaggrin gene mutations. Br J Dermatol. 2017;177:1394-400.

JAYPEE BROTHERS

CASE 2

Recalcitrant Red Plaque in a Patient with Atopic Dermatitis

Chuda Rujitharanawong, Kanyalak Munprom, Rungsima Kiratiwongwan, Sumanas Bunyaratavej, Kanokvalai Kulthanan

CASE PRESENTATION

A 6-year-old Thai boy with atopic dermatitis (AD) presented with a history of progressive itchy rash at the right side of his face for 1 month. He was diagnosed as AD flare-up at another hospital, and he was treated with oral prednisolone 10 mg/day for 1 week together with topical mometasone furoate-cream. The lesion initially improved, but then it began to gradually spread across his right cheek all the way to his nose. He had no history of pet contact.

Physical examination revealed a well-circumscribed, erythematous, scaly plaque on the right cheek, right eyelid, and nose (**Fig. 1**).



FIG. 1: A 6-year-old Thai boy with atopic dermatitis presented with a history of progressive itchy rash at the right side of his face for 1 month.

JAYPEE BROTHERS

for detailed information on dermatology books, visit our website www.jaypeebrothers.com, for detailed information on dermatolog

Atopic Dermatitis and Pruritus
Interesting Cases

Salient Features

- Interesting cases of atopic dermatitis and pruritus useful for practicing dermatologists, family physicians and allergy specialists
- World renowned authors from Atopic Dermatitis Centers of Reference and Excellence (ADCARE)

Kiran Godse MD PhD FRCP (Glasgow) is Professor at Dr DY Patil Medical College and Hospital, Navi Mumbai, Maharashtra, India. He is the President of Skin Allergy Research Society, India. Dr Godse is a part of expert group Skin Allergy Research Society, which authored Guidelines on Management of Atopic Dermatitis in India published in 2019.

He is a part of an expert group which has published EAACI/GA²LEN/EDF/WAO guidelines on urticaria. He is a focus section director for urticaria session at American Academy of Dermatology (AAD) summer meeting since 2013. He has received Indian Association of Dermatologists, Venereologists and Leprologists (IADVL) oration on urticaria in 2010. He has devised a urticaria meter, Urticaria Control Test (UCT) meter and skin writometer for diagnosis and management of urticaria. Dr Godse has edited two books on urticaria.

Printed in India

Available at all medical bookstores
or buy online at www.jaypeebrothers.com

JAYPEE BROTHERS
Medical Publishers (P) Ltd.
EMCA House, 23/23-B, Ansari Road,
Daryaganj, New Delhi - 110 002, INDIA
www.jaypeebrothers.com

Join us on facebook.com/JaypeeMedicalPublishers

Shelving Recommendation
DERMATOLOGY

ISBN 978-93-5152-238-6