brothers.com, for detailed information on dermatology books, visit our website www.jaypeebrothers.com, for detailed information on dermatology books

JAYPEE

SIXTH EDITION

Bhutani's Color Atlas of DERMATOLOGY









Neena Khanna • Saurabh Singh

Contents

1. Pyodermas 1

Impetigo Contagiosa 3
Ecthyma 3
Bullous Impetigo 5
Staphylococcal Scalded Skin Syndrome 5
Cellulitis 7
Folliculitis 7
Boil (Furuncle) 7
Carbuncle 9
Principles of Management of Pyodermas 9
Anthrax 11
Non-Pyococcal Dermatoses Simulating Pyodermas 11
Infections Caused by Resident Flora 11

2. Fungal Infections 15

Pityrosporum Infection 17
Dermatophytoses (Ringworm) 19
Candidiasis (Candidosis) 27
Mycetoma (Madura Foot) 29
Subcutaneous Zygomycosis 33
Sporotrichosis 33
Chromomycosis 35
Lobomycosis (Keloidal Blastomycosis) 37
Cryptococcosis 37
Histoplasmosis 39

3. Viral Infections 41

Warts 43
Molluscum Contagiosum 45
Measles 47
Herpes Simplex 49
Varicella-Zoster Virus Infection 51

4. Leprosy 55

Etiology 57
Epidemiology 57

Spectrum 57
Cardinal Features of Leprosy 57
Clinical Manifestations 59
Reactions in Leprosy (Lepra Reactions) 61
Investigations 63

5. Cutaneous Tuberculosis 71
Etiology 73
Epidemiology 73
Clinical Manifestations 73
Investigations 77

6. Diseases Caused by Arthropods and Parasites 81
Scabies 83
Pediculosis 85
Leishmaniasis 89
Filariasis 93
Cutaneous Myiasis 93
Investigations 93
Cysticercosis 95
Insect Bites/Reactions 95
Dracunculosis (Guinea Worm Infestation) 95
Cutaneous Larva Migrans (Creeping Eruption) 95
Onchocerciasis 97

7. Dermatitis and Eczema 99
Atopic Dermatitis 101
Nummular Eczema 103
Pompholyx 105
Seborrheic Dermatitis 105
Stasis Eczema 107
Irritant Contact Dermatitis 107
Allergic Contact Dermatitis 109
Photocontact Allergic Dermatitis 111
Infective Dermatitis (Infectious Eczematoid Dermatitis) 113
Asteatotic Eczema (Eczema Craquelé) 115
Napkin Dermatitis (Diaper Dermatitis) 115
Lip-Licking Dermatitis 115
Lichen Simplex Chronicus 115

Prurigo Nodularis 115
Dermatitis Artefacta (Factitial Dermatitis) 117
Erythroderma (Exfoliative Dermatitis) 117

8. Abnormal Vascular Responses **119**
Urticaria 121
Erythema Multiforme 123
Epidermal Necrolysis 125
Figurate Erythemas and Cyclosporine (Gyrate Erythemas) 127
Drug Eruptions 129
Cutaneous Vasculitis 131
Pyoderma Gangrenosum 133
Behçet's Syndrome 135

9. Papulo-Squamous Disorders **137**
Psoriasis 139
Reiter's Syndrome 147
Lichen Planus 147
Lichen Planus Pigmentosus 153
Lichen Nitidus 153
Keratosis Lichenoides Chronica (Nekam's Disease) 155
Pityriasis Rosea 155
Pityriasis Rubra Pilaris 155

10. Autoimmune Vesiculobullous Dermatoses **159**
Pemphigus 161
Pemphigoid (Bullous Pemphigoid, BP) 169
Herpes Gestationis (Pemphigoid Gestationis, PG) 173
Benign Mucosal Pemphigoid (Cicatricial Pemphigoid, CP) 173
Chronic Bullous Dermatosis of Childhood (CBDC) 175
Dermatitis Herpetiformis (DH) 177

11. Metabolic and Nutritional Dermatoses **181**
Cutaneous Xanthomatoses 183
Amyloidosis 185
Follicular Mucinosis (Alopecia Mucinosa) 189
Acanthosis Nigricans 189
Porphyrias 191
Lipoid Proteinosis 197

Sarcoidosis 197
Skin in Endocrinological Diseases 199
Cutaneous Manifestations of Malnutrition 203

12. Disorders of Skin Pigmentation 207
Disorders of Decreased Pigmentation 209
Disorders of Increased Pigmentation 213
Reticulate Pigmentary Disorders 219

13. The 'Connective Tissue Diseases' 221
Lupus Erythematosus 223
Scleroderma 229
Lichen Sclerosus 235
Dermatomyositis 237
Relapsing Polychondritis 239

14. Disorders Due to Physical Agents 241
Disorders Due to Mechanical Injury 243
Disorders Due to Temperature Change 243
Disorders Due to Exposure to Light 245
Idiopathic Photodermatoses 247
Disorders Due to Exposure to Miscellaneous Physical Stimuli 253

15. Diseases of the Skin Appendages 255
Disorders of Sebaceous Glands 257
Acne Variants 261
Disorders of Apocrine Glands 265
Disorders of Hair 267
Non-Cicatricial Alopecia 267
Cicatricial Alopecias 271
Disorders of Nails 275

16. Genodermatoses 281
Keratinizing Disorders 283
Epidermolysis Bullosa (EB) 293
Ectodermal Dysplasias 297
Inherited Tumors and Tumor Syndromes 297
Disorders of Connective Tissue 303
Pigmentary Disorders 305

Disorders of Genomic Instability 307
Poikilodermatous Disorders 309
Syndromes with Silver Hair 309
Other Genodermatoses 311

17. Nevoid Conditions 317
Vascular Nevi 319
Epidermal Nevi 325
Pigmented Lesions 331
Other Linear/Nevoid Disorders 335

18. Cutaneous Tumors 339
Epidermal Tumors 341
Benign Appendageal Tumors 343
Dermal Tumors 349
Cysts of Epidermal Origin 351
Benign Vascular Tumors 353
Premalignant Skin Conditions 355
Malignant Tumors of Epidermal Origin 361
Cutaneous T Cell Lymphoma (CTCL) 365
Reactive Tumorous Conditions 371
Metastatic Malignant Tumors 375

19. Sexually Transmitted Diseases 377
Syphilis 379
Gonorrhea 381
Non-Gonococcal Urethritis 383
Chancroid 385
Donovanosis (Granuloma Inguinale) 387
Lymphogranuloma Venereum 387
Genital Herpes 387
Genital Warts 389
Genital Molluscum Contagiosum 389

20. HIV Infection and Acquired Immunodeficiency Syndrome 391
Epidemiology 393
Etiology 393
Clinical Manifestations 397
Diagnosis 407

21. Miscellaneous and Rare Dermatoses 417
Granulomatous Disorders 419
Neutrophilic Dermatoses 421
Cutaneous Mucinoses 423
Cutaneous Pseudolymphomas 425
Perforating Disorders 429
Rare Hair Disorders 431
Miscellaneous Diseases Involving Genitalia 431
Other Miscellaneous Dermatoses 433
Amyloidosis Cutis Dyschromica 437

22. Therapeutics in Dermatology 439
Topical Therapy 440
Vehicles 440
Active Substances 441
Intralesional Therapy 445
Systemic Therapy 445
Prescriptions for Common Dermatoses 449
Formulations of Historical Value!! 453

23. Diagnostic and Therapeutic Photomedicine 455
Diagnostic Photomedicine 457
Wood's Lamp 459
Therapeutic Photomedicine 459
Targeted Phototherapy 462
Extracorporeal Photopheresis 463
Balneophototherapy 463

24. Cosmetic Dermatology 465
Procedures in Cosmetic Dermatology 467

25. Lasers in Dermatology 475
Principles of Laser Surgery 476
Lasers Used in Dermatology 476
Indications for Laser Therapy 478
Side Effects and Complications 478
Recent Advances in Lasers 479
Glossary and Clinical Examination 481
Clinical Terms 481
Index 485

2

Fungal Infections



JAYPEE BROTHERS



Pityriasis versicolor: hypopigmented, discrete and confluent macules with branny scales.



Pityriasis versicolor: hyperpigmented, scaly macules—discrete and confluent. Note many lesions perifollicular.



Pityriasis versicolor: hyperpigmented macules with scaling accentuated by scratching. With permission of Elsevier, Illustrated Synopsis of Dermatology and Sexually Transmitted Infections.



Pityrosporum folliculitis: follicular papules and pustules on trunk. With permission of Elsevier, Illustrated Synopsis of Dermatology and Sexually Transmitted Infections.

JAYPEE BROTHERS

Fungi broadly classified as moulds (e.g. dermatophytes), yeasts (e.g. *Candida spp*), and dimorphic fungi (Malassezia, histoplasmosis, coccidioidomycosis).

Fungal infections of skin either superficial or deep (subcutaneous). Or skin involved incidentally in systemic fungal infections.

- ***Superficial:*** three groups of fungi relevant in superficial fungal infections–dermatophytes (*Trichophyton*, *Epidermophyton*, *Microsporum spp*), *Candida spp* and *Pityrosporum spp* Humidity, occlusion, diabetes, immune deficiency states predispose to superficial fungal infections.
- ***Deep:*** variable geographic distribution of subcutaneous fungal infection. Mycetomas and sporotrichosis common in India and the tropics.
- ***Incidental involvement in systemic mycoses:*** immune deficiency states predispose to infections such as cryptococcosis, histoplasmosis and candidosis.

PITYROSPORUM INFECTION

Etiology

Malassezia furfur, a saprophytic dimorphic, resident fungus.

Epidemiology

Very common in warm humid climates. Usually affects adolescents and adults.

Clinical Manifestations

Pityriasis Versicolor

Cosmetically objectionable asymptomatic, hypopigmented (on dark skin) and/or hyperpigmented (on white skin), well-defined, perifollicular, small macules with fine branny scales (accentuated by scratching). Confluence may produce large lesions. On the front and back of the chest, neck, upper arms. Recurrences frequent.

Pityrosporum (Malassezia) Folliculitis

Itchy, erythematous, small follicular papules/pustules. Back, chest, proximal extremities.

Investigations

Wood's Lamp

Yellow fluorescence.

Direct Microscopy

Potassium hydroxide (KOH) mount of scales (pityriasis versicolor)/pustule (pityrosporum folliculitis) shows typical meat ball and spaghetti appearance—short septate hyphae and thick walled spores.

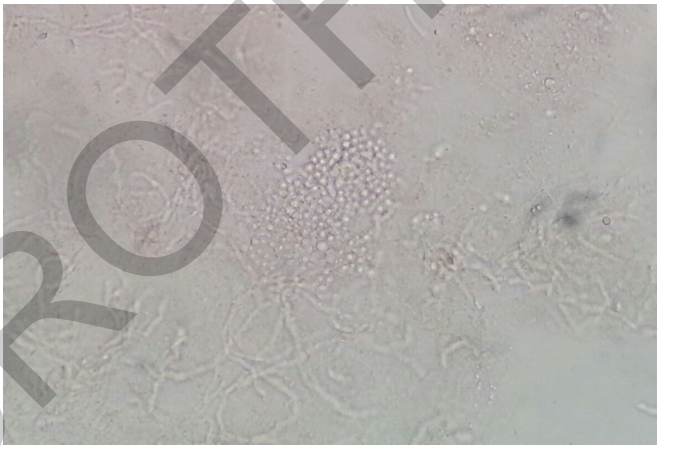

Potassium hydroxide mount of scale of pityriasis versicolor: shows typical spaghetti and meat ball appearance. (short septate hyphae and thick walled spores).

Culture

Usually not required.

Treatment

General Measures

Keep skin dry. Avoid use of synthetic occlusive garments that prevent evaporation of sweat.

Specific Therapy

Topical therapy

Indicated for limited disease. Several choices available—ketoconazole, 2% shampoo, used twice a week for 4–6 weeks. Lathered on affected skin and left for 5–10 minutes for 3 consecutive days. Alternatively, 2.5% selenium sulphide

JAYPEE BROTHERS



Tinea corporis: well-defined, annular lesion with erythematous scaly border with papulovesicles and relatively, clear center.

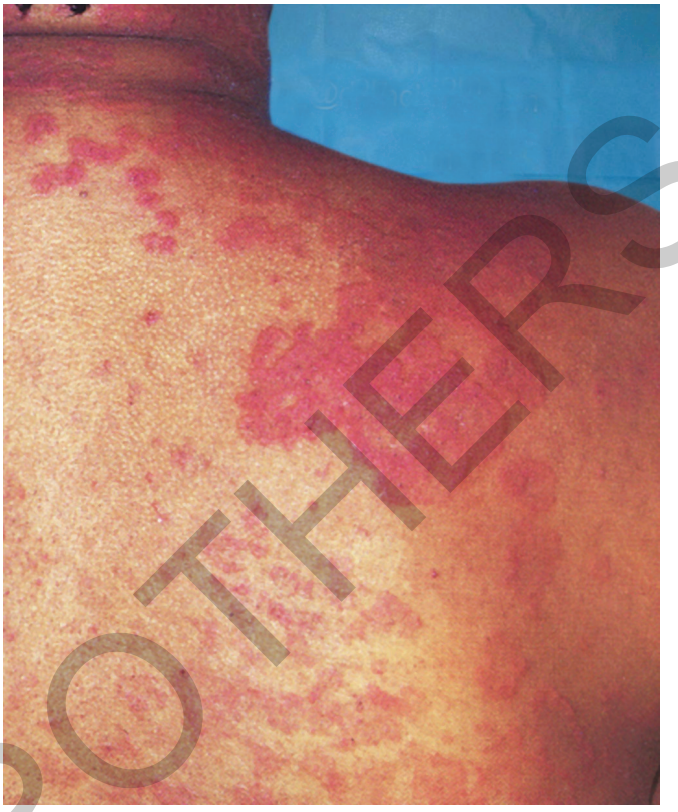

Tinea corporis: circinate lesions; note 'active' erythematous elevated border.



Tinea imbricata: concentric lesions with brown scales and almost clear intervening skin.



Tinea faciei: circinate lesions. This one has incomplete central clearing.

JAYPEE BROTHERS

suspension applied overnight, 2–3 times a week and less frequently as improvement occurs. Other antifungals such as 1% tolnaftate, imidazole compounds (2% miconazole, 1% clotrimazole, 1% econazole) and 1% terbinafine equally effective.

Systemic therapy

Indicated in extensive lesions. Or recurrent disease. Ketoconazole, 400 mg single dose. Or itraconazole 400 mg single dose. Fluconazole, 400 single dose. Terbinafine orally not effective.

DERMATOPHYTOSES (RINGWORM)

Etiology

Infections caused by dermatophytes (species *Trichophyton, Epidermophyton* or *Microsporum*).

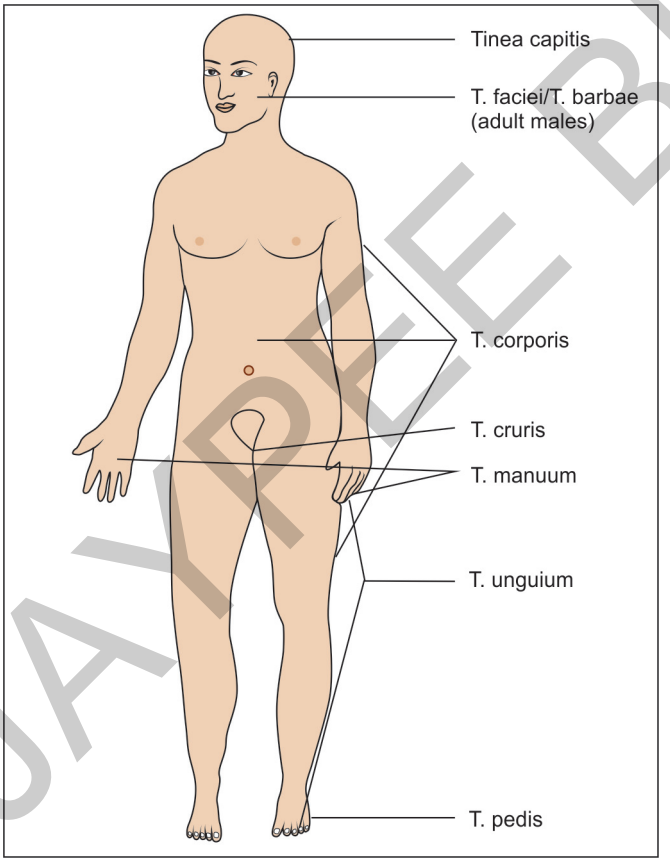

Sites of predilection: Tinea.

Nomenclature

Designated as tinea (to indicate ringworm) followed by the name of the affected part, hence tinea capitis for infection of scalp, tinea cruris for ringworm of groins, thighs and buttocks, tinea corporis (trunk and limbs), tinea barbae (beard), tinea faciei (face), tinea pedis (feet), tinea manuum (hands) and tinea unguium (nails).

Clinical Manifestations

Tinea Corporis

Classic ringworm. All age groups, but generally adults, affected. Any dermatophyte species. Single or multiple, small or large, itchy, well-defined, circinate or annular plaques. Papulovesicles and scales at the active border. Central portion relatively clear; spread peripherally. Heal with hyperpigmentation. Trunk, extremities involved.

Variants

Tinea imbricata

Uncommon variant of tinea corporis confined to certain geographical areas. Caused by *Trichophyton concentricum*. Extremely itchy concentric rings of brownish scales attached at one edge. And clear intervening skin.

Tinea faciei

Tinea of face.

Tinea incognito

Tinea infection modified by steroids. Manifests as ill-defined scaly lesions with minimal inflammation. Diagnosis often based on a positive KOH mount.

Tinea Cruris

Common. Adults affected more frequently. And males due to regional anatomical differences and type of apparrel. Itchy, often bilaterally symmetrical, large half-moon shaped or multiple small, well-defined, oval or circinate scaly plaques with papulovesicles at the active border. Central clearance often incomplete. Groins, thighs, buttocks and scrotum involved.

JAYPEE BROTHERS

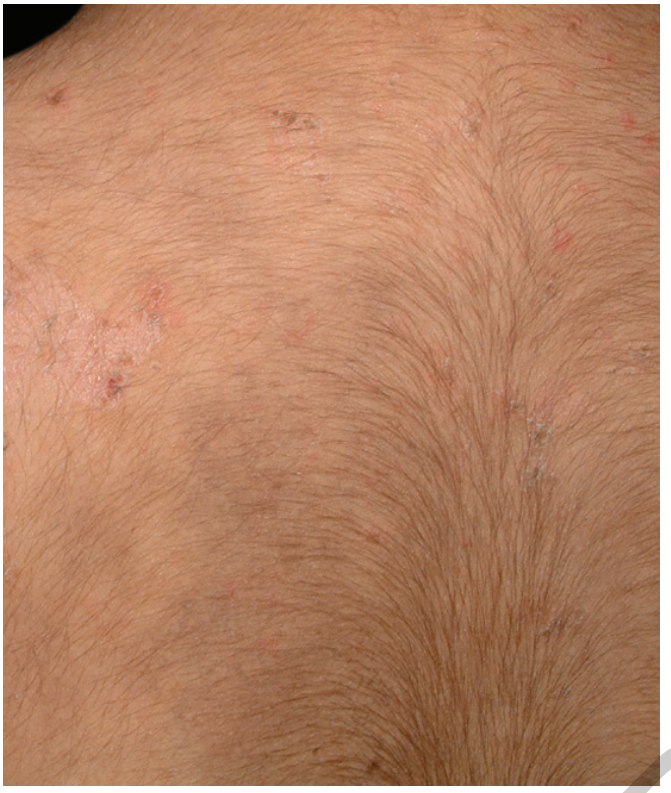

Tinea incognito: ill-defined scaly lesions with minimal scaling. Patient was using topical steroids. With permission of Elsevier, Illustrated Synopsis of Dermatology and Sexually Transmitted Infections.

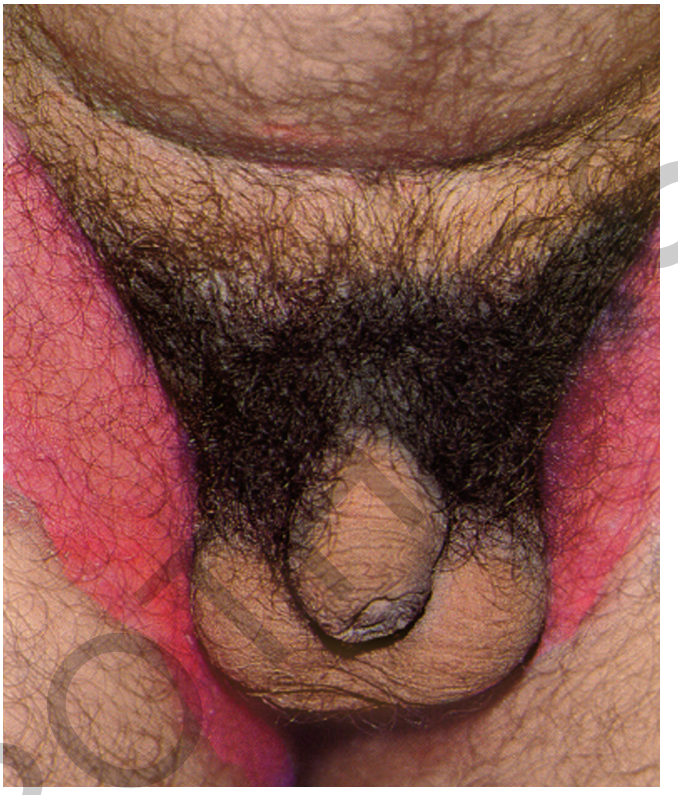

Tinea cruris: bilateral well-defined half moon-shaped lesions with 'active' borders.

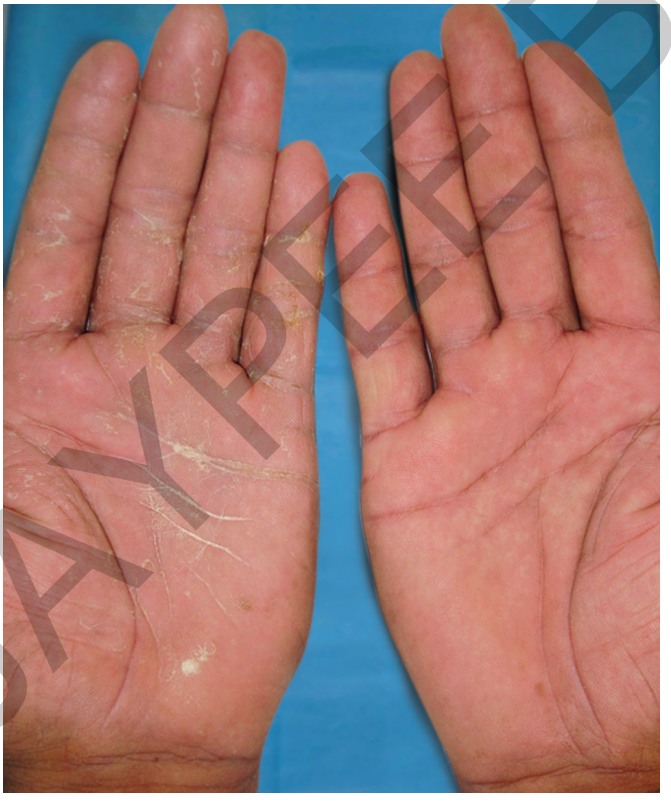

Tinea manuum: well-defined scaly lesions on the palm; unilaterality conspicuous.



Tinea pedis, intertriginous variant: scaly lesions in between the lateral toe spaces.

JAYPEE BROTHERS

Tinea Manuum

Relatively uncommon. Adults affected. Diffuse hyperkeratosis with fine white scales. Or well-defined, circular, scaly patches on the palm. Often unilateral.

Tinea Pedis (Athlete's Foot)

Commonly affects 'shoe-wearing' adult population. Armed forces personnel and athletes particularly affected, hence called 'athlete's foot'. Hyperhidrosis predisposes. Nail infection a frequent association. Three variants:

- ***Intertriginous type:*** itchy maceration, scaling and fissuring particularly in the lateral toe web spaces (3rd and 4th).
- ***Hyperkeratotic type:*** diffuse hyperkeratosis with fine scales on soles and heels.
- ***Vesicular type:*** multiple (often painful) blisters or pustules.

Tinea Capitis

Children, boys more often. Degree of inflammation variable:

- ***Non-inflammatory type:*** circular or oval scaly, mildly inflammatory partially alopecic areas with broken-off, dull-grey hair or black dots. Hair break off or can be pulled out easily.
- ***Inflammatory type:*** follicular pustules. Or inflammed, boggy, painful swellings, studded with exudative folliculopustules-kerion. Cervical lymphadenopathy frequent.
- ***Favus:*** special variant; characterized by hair surrounded by yellowish, cup-shaped crusts called scutula. Results in extensive cicatricial alopecia. Common in Kashmir and the Middle East.

Tinea Barbae

Adult males affected. Inflammatory swellings with follicular pustules—similar to kerion. Occasionally well-defined alopecic patches with scaling and dull broken-off hair. Affected hair either break or can be pulled out painlessly with relative ease.

Tinea Unguium

Caused by dermatophytes *c.f.*, onychomycosis which is caused by any fungus. Adults affected. Cosmetic problem and a reservoir of infection (so association with tinea of other sites). Asymmetric involvement; all nails seldom affected. Toe nails more frequently involved. Several subtypes recognized:

- ***Distal lateral subungual onychomycosis (DLSO):*** manifests as yellow-white subungual hyperkeratosis and onycholysis.
- ***White superficial onychomycosis (WSO):*** manifests as small, white, speckled or powdery patches on surface of nail plate which becomes roughened and crumbles easily.
- ***Proximal subungual onychomycosis (PSO):*** manifests as area of leukonychia in proximal nail plate that moves distally with nail growth. Seen in HIV-infected.
- ***Endonyx onychomycosis (EO):*** manifests as milky white discoloration of the nail plate with no subungual hyperkeratosis or onycholysis.

Investigations

Diagnosis often clinical. In doubtful cases, KOH mount, Wood's lamp examination (in tinea capitis), culture (in tinea unguium), and rarely biopsy necessary.

Wood's Lamp Examination

Helpful in screening epidemics of tinea capitis. Typically green fluorescence, though not all species fluoresce.

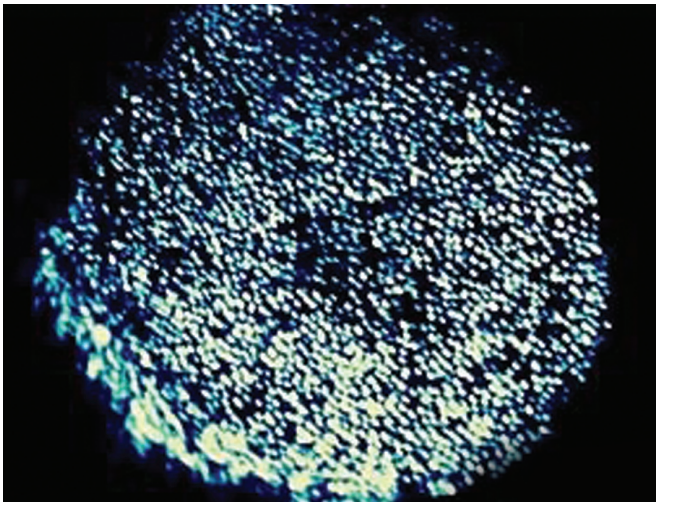

Wood's lamp of tinea capitis: green fluorescence. Useful for screening epidemics, though not always positive.

JAYPEE BROTHERS



Tinea pedis, hyperkeratotic variant: diffuse scaling of the soles of the feet.



Tinea capitis, non-inflammatory variant: alopecic areas with black dots. With permission Elsevier.



Tinea capitis, kerion: solitary boggy plaque, studded with follicular pustules, overlying hair sparsening.



Tinea capitis, kerion: alopecic areas with multiple inflammatory swellings.

JAMES BROTHERTON

Direct Microscopy

Samples include skin scrapings, nail clippings or plucked hair dissolved in KOH. Area cleaned and active edge of skin lesion superficially scraped with scalpel. Or hair pulled. Or nail clippings and subungual debris collected and treated in a drop of 10–20% KOH solution, on a glass slide for half an hour or longer (hair and nails require several hours). Viewed under microscope with subdued light. Fungal elements seen as long septate, branching filaments (hyphae) in dermatophytoses. In tinea capitis 2 patterns seen–endothrix (infection within hair shaft) and ectothrix (infection outside hair shaft).

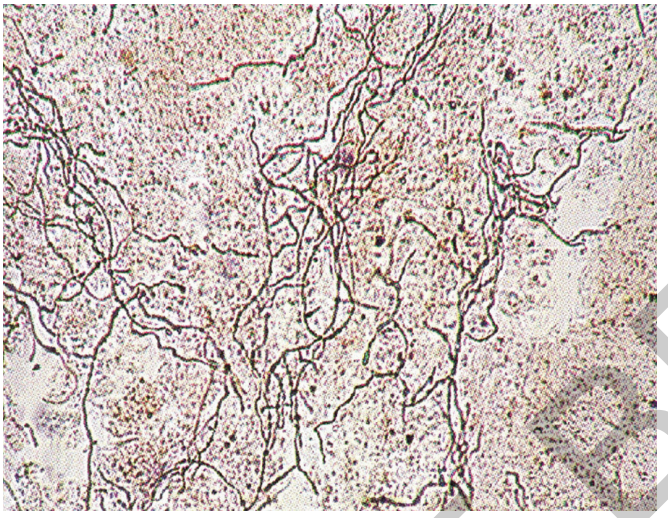

Potassium hydroxide mount of tinea corporis: septate hyphae of dermatophytes.

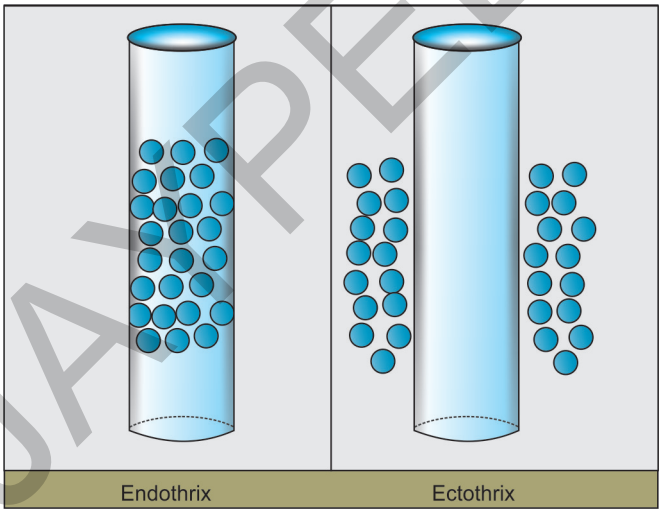

Tinea capitis: diagrammatic representation of endothrix and ectothrix. In endothrix, organisms (spores or arthroconidia) inside the hair shaft while in ectothrix they are outside the shaft.

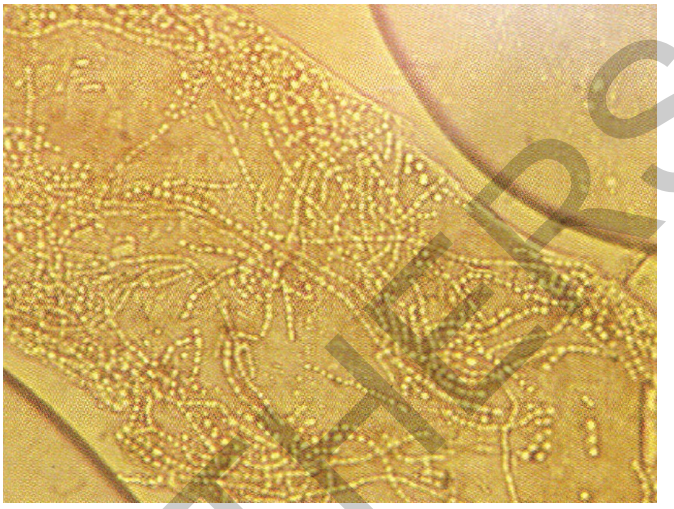

Potassium hydroxide mount of tinea capitis, endothrix: spores inside hair shaft. With permission Macmillan Fungal infections.

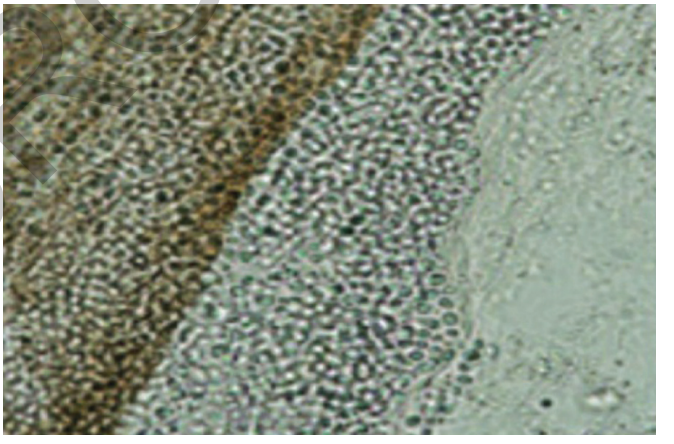

Potassium hydroxide mount of tinea capitis, ectothrix: spores on surface of hair shaft.

Culture

Necessary for onychomycosis to differentiate dermatophytic (tinea unguium) from non dermatophytic infections to optimize treatment. Culture media used include Sabouraud's dextrose agar and dermatophyte culture medium.

JAYPEE BROTHERS



Tinea capitis, favus: depressed crusted lesions with cicatricial alopecia.



Tinea barbae: inflammatory boggy swelling with pustules, in beard area of adult male.



Tinea unguium, distal lateral subungual onychomycosis: manifests as distal and lateral yellow white subungual hyperkeratosis and onycholysis.



Tinea unguium, proximal subungual onychomycosis: area of leukonychia in proximal part of nail plate.

JAYPEE BROTHERS

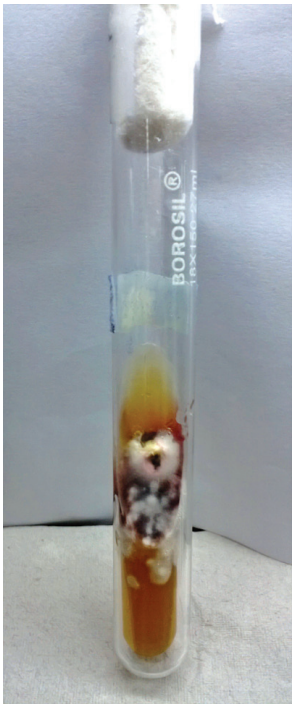

Culture of dermatophyte: Growth occurs in 7–14 days. Speciation based on culture characteristic and morphology of micro and macroconidia on microscopy.

Courtesy: Dr Immaculata Xess, Department of Microbiology, All India Institute of Medical Sciences (AIIMS), New Delhi.

Histopathology

Rarely required. Fungal elements best visualized using special stains like PAS.

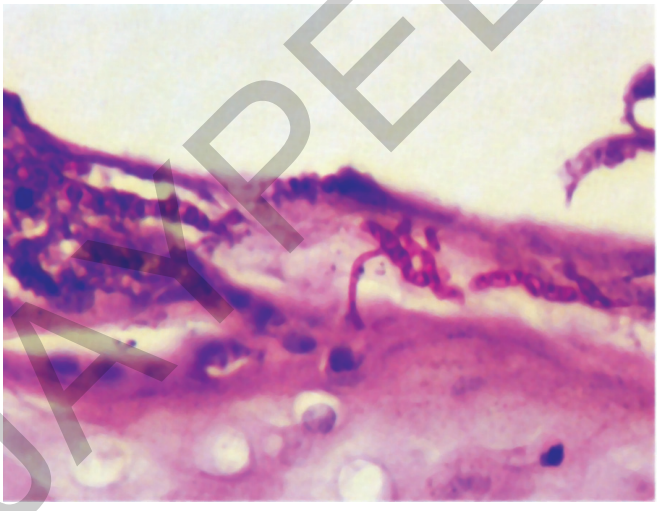

Histopathology of tinea pedis: PAS positive septate hyphae in stratum corneum.

Treatment

General Measures

Keep area dry and areated.

Tinea capitis: Use antifungal shampoos. Do not share combs/brushes.

T. pedis: Avoid occlusive footwear.

T. cruris: Avoid synthetic underclothes.

Specific Therapy

Topical therapy

Topical therapy adequate for localized lesions (except tinea unguium. And tinea capitis and barbae). Regular application of any of the several antifungal agents (creams, gels, lotions, powders) of imidazoles (1% clotrimazole, 2% miconazole, 1% econazole, 2% ketoconazole, 0.5% fluconazole), 1% tolnaftate, 1% ciclopirox olamine, 1% haloprogin, 1% naftifine hydrochloride, 1% terbinafine, 1% butenafine, 20% undecylinic acid and its salts. Continue treatment for a couple of weeks, after clinical subsidence. Distal involvement of single nail plate may be treated with 1% amorolfine lacquer once a week. Or 8% ciclopirox lacquer daily for 8–9 months.

Systemic therapy

Invariably needed for tinea unguium, tinea capitis and tinea barbae. And extensive tinea corporis or resistant tinea cruris infections.

Terbinafine: fungicidal. Treatment of choice (except for some forms of tinea capitis, where griseofulvin preferred). Given as 250 mg daily for 2 weeks (tinea corporis, cruris, pedis, manuum) to 6 weeks (finger nail infection) to 12 weeks (toe nail infection). Cost a limiting factor.

Itraconazole: Broad spectrum. Preferred to terbinafine in onychomycosis which has not been speciated by culture. Given as 400 mg × 7 day pulses every month for 2 (finger nail infection)-3 (toe nail infection) cycles.

Griseofulvin: Treatment of choice for tinea capitis (caused by *Microsporum spp*). Given as 10 mg/kg, after a fatty meal for 6–12 weeks.

JAYPEE BROTHERS



Candidal paronychia: subacute inflammation of the posterior and lateral nail folds with detachment from nail plate. Deformity of the nail plate secondary to involvement of nail matrix.



Candidal intertrigo: macerated and eroded interdigital space.

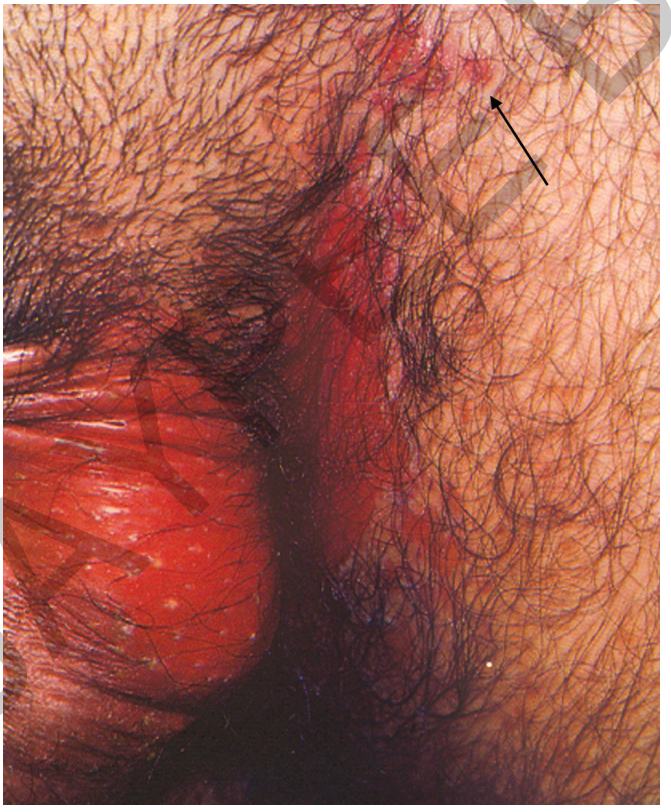

Candidal intertrigo: acutely inflamed erythematous lesions in the folds of skin. Note satellite vesiculo-pustules.



Napkin candidiasis: acutely inflamed intertriginous areas with satellite vesiculo-pustules.

JAYPEE BROTHERS

for detailed information on dermatology books, visit our website www.jaypeebrothers.com, for detailed information on dermatology books, visit our web

Bhutani's Color Atlas of DERMATOLOGY

Salient Features

- Enlarges greatly with added emphasis on clinical manifestations supplemented with a cryptic histopathological description and supported by several color photomicrographs
- Includes the body diagrams, biopsy images, flow charts and tables to make the atlas comprehensive
- Divides into 25 chapters with various diseases conventionally grouped
- Adds several new contents including the one on lasers, cosmetic dermatology and on phototherapy and photodiagnosis
- Discusses the principles and practice of treatment
- Updates to keep up with newer trends in disease manifestations and treatments
- Classifies some diseases etiologically while others have been grouped conventionally
- Incorporates newer therapies (albeit briefly) to make the atlas comprehensive
- Useful for medical students, general practitioners and residents in dermatology and internal medicine.

Neena Khanna graduated from Christian Medical College (CMC), Vellore, Tamil Nadu, and postgraduated in Dermatology and Venereology from All India Institute of Medical Sciences (AIIMS), New Delhi, India. She is presently working as Professor, Department of Dermatology and Venereology, AIIMS, New Delhi, India.

Saurabh Singh graduated and postgraduated (Dermatology and Venereology) from All India Institute of Medical Sciences (AIIMS), New Delhi, India. He is presently working as an Assistant Professor, Department of Dermatology and Venereology, Employees' State Insurance Corporation (ESIC) Medical College and Hospital, Faridabad, Haryana, India. He has to his credit several national and international publications and awards, and he has been speaker at many national and international conferences. He has immense interest in dermatological research, dermatopathology, descriptive dermatology and clinical photography.

Shelving Recommendation
DERMATOLOGY

ISBN 978-93-5152-302-4

9 789351 523024

Available at all medical bookstores or buy online at www.jaypeebrothers.com

JAYPEE BROTHERS
Medical Publishers (P) Ltd.
www.jaypeebrothers.com

Join us on facebook.com/JaypeeMedicalPublishers