ers.com, for detailed information on otolaryngology books, visit our website www.jaypeebrothers.com, for detailed information on otolaryngology boo

Essentials of Ear, Nose & Throat

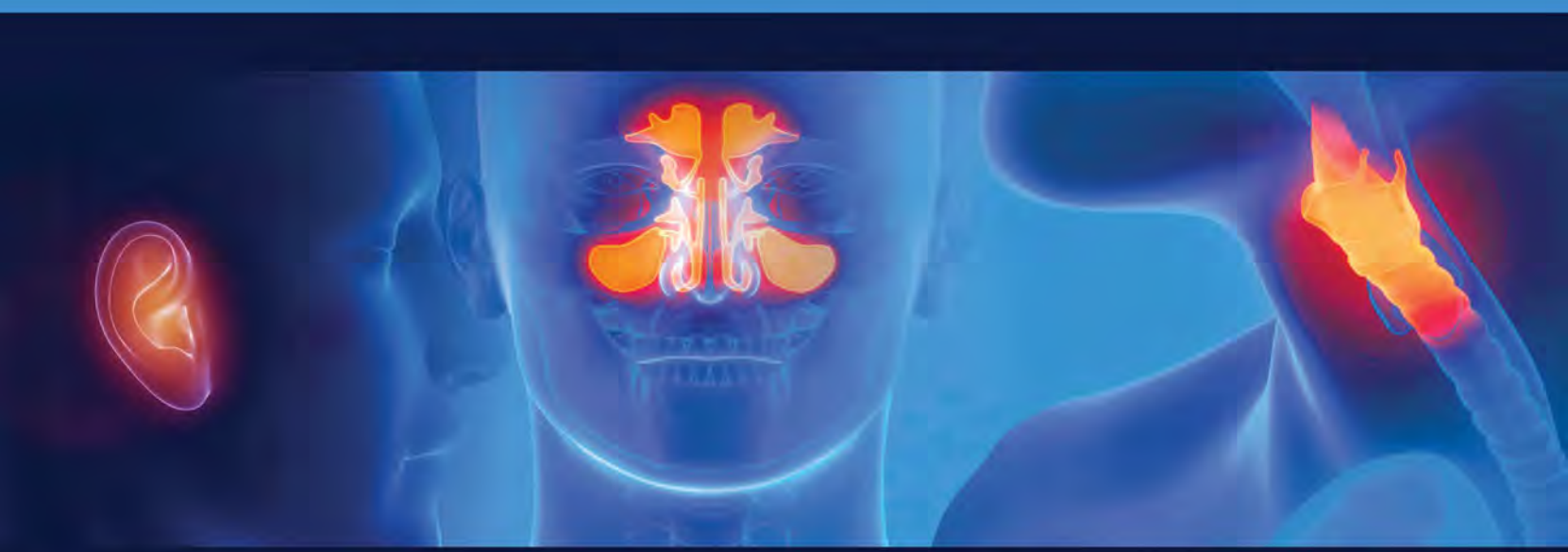

Mohan Bansal

JAYPEE

CONTENTS

Section 1 General

1. History and examination 1
   - Introduction to otorhinolaryngology
   - History taking and Physical examination
   - General set-up

Section 2 Ear

2. Anatomy of ear 4
3. Physiology of hearing and vestibular system 24
4. Otologic symptoms and examination 30
   - Ear symptoms and examination
   - Otalgia (earache)
   - Otorrhea (ear discharge)
   - Ear polyp
   - Tinnitus
5. Hearing evaluation 38
   - Audiology and acoustics
   - Types of hearing loss
   - Hearing evaluation
6. Conductive hearing loss and otosclerosis 51
7. Sensorineural hearing loss 59
8. Hearing impairment in infants and young children 69
9. Hearing aids and cochlear implants 76
10. Diseases of external ear and tympanic membrane 85
11. Disorders of Eustachian tube 95
12. Acute otitis media and otitis media with effusion 101
13. Chronic suppurative otitis media and cholesteatoma 109
14. Complications of suppurative otitis media 117
15. Evaluation of vertigo 130
16. Peripheral vestibular disorders 136
    - Benign paroxysmal positional vertigo
    - Acute vestibular neuritis
    - Meniere's disease
    - Labyrinthitis
    - Perilymphatic fistula
17. Central vestibular disorders 144
    - Migraine
    - Cerebrovascular strokes
    - Multiple sclerosis
    - Motion sickness
    - Psychophysiologic
    - Cervical vertigo
18. Facial nerve disorders 148
19. Tumors of the ear and cerebellopontine angle 160
    - Tumors of external ear
    - Tumors of middle ear and mastoid
    - Acoustic neuroma (Schwannoma)

Section 3 Nose and Paranasal Sinuses

20. Anatomy and physiology of nose and paranasal sinuses 169
21. Nasal symptoms and examination 184
    - History taking and examination of nose
    - Smell
    - Nasal obstruction
    - Nasal valves disorders
    - Proptosis
    - Epistaxis (nosebleed)
22. Diseases of external nose and vestibule 196

23. Infectious rhinosinusitis 200
- Classification
- Viral rhinosinusitis
- Acute bacterial rhinosinusitis
- Chronic rhinosinusitis
- Complications of rhinosinusitis
- Nasal polyps

24. Nasal manifestation of systemic diseases 213
- Granulomatous conditions
- Atrophic rhinitis
- Rhinosporidiosis
- Fungal sinusitis

25. Allergic and nonallergic (vasomotor) rhinitis 222

26. Nasal septum disorders 229
- Diseases of nasal septum
- Hypertrophied turbinates
- Nasal synechia
- Choanal atresia

27. Maxillofacial trauma 235
- Maxillofacial injuries
- Oroantral fistula
- Cerebrospinal fluid rhinorrhea
- Foreign body nose
- Rhinolith
- Nasal myiasis

28. Tumors of nose and paranasal sinuses 246

Section 4 Oral Cavity and Salivary Glands

29. Anatomy of oral cavity 255

30. Oral symptoms and examination 258
- Oral cavity symptoms and examination
- Evaluation of oral cancer patients

31. Oral mucosal lesions 262
- Red/white lesions
- Vesiculobullous/ulcerative lesions
- Lesions of tongue

32. Disorders of salivary glands 271
- Inflammatory disorders
- Obstructive disorders (sialolithiasis)
- Neoplasms
- Xerostomia (Sjogren's syndrome)
- Frey's syndrome (gustatory sweating)

33. Neoplasms of oral cavity 280
- Benign tumors
- Malignant tumors

Section 5 Pharynx and Esophagus

34. Anatomy and physiology of pharynx and esophagus 288

35. Pharyngeal symptoms and examination 297
- Evaluation of pharynx
- Evaluation of esophagus
- Dysphagia

36. Pharyngitis and adenotonsillar disease 303

37. Obstructive sleep apnea 311

38. Tumors of nasopharynx 317
- Juvenile nasopharyngeal angiofibroma
- Nasopharyngeal carcinoma
- Thornwaldt's disease

39. Tumors of oropharynx 325
- Malignant tumors
- Benign tumors
- Parapharyngeal tumors
- Stylalgia (Eagle's syndrome)

40. Tumors of hypopharynx 331

41. Disorders of esophagus 335

Section 6 Larynx, Trachea and Bronchus

42. Anatomy and physiology of larynx 346

43. Laryngeal symptoms and examination 355
- Endoscopy examination and stroboscopy
- Hoarseness of voice
- Stridor

44. Infections of larynx 361
- Acute infections of larynx
- Chronic laryngitis
- Edema of larynx

45. Benign tumors of larynx 368
- Non-neoplastic
- Neoplastic
- Saccular swellings

46. Neurologic disorders of larynx 374
- Laryngeal paralysis
- Phonosurgery

47. Speech and voice disorders 379

48. Malignant tumors of larynx 382

49. Management of impaired airway 390
- Tracheostomy
- Cricothyrotomy
- Percutaneous dilational tracheostomy
- Congenital lesions of larynx
- Foreign bodies of air passages
- Laryngotracheal trauma

SECTION 7 Neck

50. Anatomy of neck 402
- Lymph nodes of head and neck
- Neck dissection
- Thyroid and parathyroid glands

51. Cervical symptoms and examination 408
- History and examination of neck and lymph nodes
- History and examination of thyroid, hypothyroidism, hyperthyroidism and investigations

52. Neck masses 413

53. Neoplasms of thyroid 417

54. Deep neck infections 425
- Pertinent anatomy
- Head and neck space infections
- Trismus

SECTION 8 Operative Procedures and Instruments

55. Middle ear and mastoid surgeries 432
- Myringotomy and tympanostomy tubes
- Simple cortical mastoidectomy
- Radical mastoidectomy
- Modified radical mastoidectomy
- Tympanoplasty, myringoplasty and ossiculoplasty

56. Operations of nose and paranasal sinuses 441
- Nasal endoscopy (sinuscopy)
- Endoscopic sinus surgery
- Antral puncture (lavage)
- Inferior meatal antrostomy
- Caldwell-Luc operation
- Septoplasty
- Submucous resection of nasal septum (SMR)

57. Adenotonsillectomy 450

58. Endoscopies 456
- Direct laryngoscopy and microlaryngoscopy
- Bronchoscopy rigid and flexible
- Esophagoscopy rigid and flexible

59. Instruments 463
- OPD instruments
- Mastoid and earmicrosurgery
- Operations of nose and paranasal sinuses
- Mouth gags and retractors
- Adenotonsillectomy and quinsy
- Endoscopes
- Tracheostomy and airway devices

Section 9 Related Disciplines

60. Diagnostic imaging 475
- Conventional radiology in ENT
- CT anatomy of ear, nose, throat, head and neck

61. Radiotherapy and chemotherapy 484

62. Laser surgery and cryosurgery 492
- Laser surgery
- Photodynamic therapy
- Radiofrequency surgery
- Cryosurgery
- Hyperbaric oxygen therapy

63. Human immunodeficiency virus infection 498

Problem-oriented Cases 168, 254, 354, 431

Pearls and Nuggets 29, 58, 75, 129, 147, 221, 234, 261, 296, 324, 412, 424, 503

Index 505

Chapter 2

Anatomy of Ear

Specific Learning Objectives

After going through the chapter, you should be able to answer the following questions:

- What are the parts of external ear and their characteristic features and nerve supply?
- What are the contents and boundaries of middle ear?
- Name the different parts of all the three middle ear ossicles.
- Describe the intratympanic muscles and their functions.
- What are the different parts of the inner ear?
- Describe the anatomy of cochlea.
- What are the cochlear and vestibular aqueducts and their clinical significance?
- What do you know about the organ of Corti?
- Enumerate the structural and neural differences between the inner and outer hair cells.
- Trace the hearing pathway from the cochlea to the cerebrum.
- Name the vestibular reflexes and enumerate their importance.

The ear is a complex organ. Its functional components, the hearing apparatus and balancing organ are situated in the temporal bone of skull. Ear has intimate relationship to the brain occupying middle and posterior cranial fossa, jugular bulb, sigmoid sinus, internal carotid artery and cranial nerves V, VI, VII, VIII, IX, X, XI and XII. For the sake of description, the ear is divided into three parts (Fig. 2.1):

1. External ear
2. Middle ear
3. Internal ear

EXTERNAL EAR ANATOMY

The external ear is divided into auricle (pinna) and external acoustic or auditory canal (EAC). The tympanic membrane separates external ear from the middle ear.

AURICLE

The auricle (Figs 2.2A and B) is made up of a framework of a single piece of yellow elastic cartilage (except its lobule), which is covered with skin. The skin is adherent to the perichondrium on its lateral surface, while it is comparatively loose on the medial surface. Epithelium is squamous keratinizing. Sebaceous glands and hair follicles are found in the subcutaneous tissue. Adipose tissue is present only in the lobule. There are various elevations and depressions, which can be seen on the lateral surface of pinna. Incisura terminalis is devoid of cartilage and lies between the tragus and crus of the helix (Fig. 2.2B).

- ***Endaural incision:*** It is made in incisura terminalis for the surgery of external auditory canal (EAC) and middle ear. It does not cut through the auricular cartilage.
- ***Frost bite:*** The outer surface of pinna is more prone to frost bite because the skin is adherent to the underlying perichondrium. There is no subcutaneous tissue.

Contd…

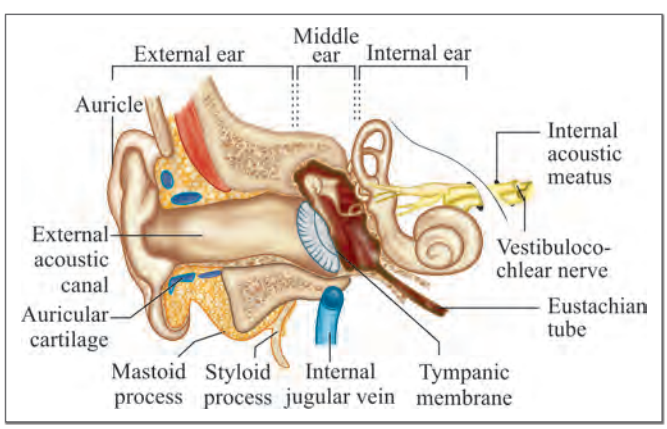

Fig. 2.1: Three parts of the ear: external, middle and internal

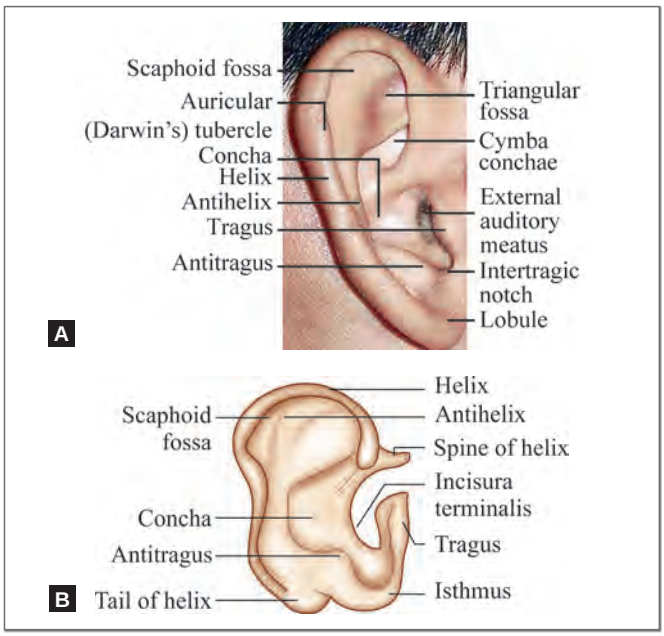

Figs 2.2A and B: External features of auricle. (A) Photographic; (B) Diagrammatic representation

Contd...

- ***Sebaceous cysts:*** They are more common on medial surface of pinna, especially lower part of retroauricular sulcus.
- ***Grafts in rhinoplasty:*** The conchal cartilage is frequently used to correct depressed nasal bridge. The composite grafts of the skin and cartilage can be used for repair of defects of ala of nose.
- ***Grafts in tympanoplasty:*** Tragal and conchal cartilage and perichondrium and fat from lobule are often used during tympanoplasty operations.

Nerve Supply (Figs 2.3A and B)

- ***Auriculotemporal nerve (CN V_3):*** It is a branch of mandibular division of trigeminal nerve and supplies anterosuperior part of lateral surface of pinna including tragus and crus of helix.
- ***Facial nerve (CN VII):*** It innervates the skin of concha and antihelix, lobule, and mastoid.
- ***Vagus nerve (CN X):*** Its auricular branch (Arnold's nerve) supplies to concha and postauricular skin.
- ***Greater auricular nerve ($C_{2,3}$):*** This nerve of cervical plexus supplies most of the medial surface of auricle and posterior part of lateral surface and the postauricular region.
- ***Lesser occipital nerve (C_2):*** This nerve of cervical plexus supplies upper part of medial surface of auricle and postauricular region.

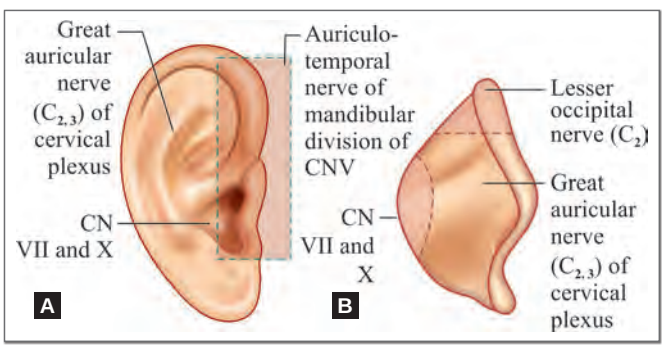

Figs 2.3A and B: Nerve supply of right pinna. (A) Lateral surface; (B) Medial surface

EXTERNAL AUDITORY CANAL (EAC)

- ***Dimensions:*** It is 24 mm long and extends from the concha to the tympanic membrane. Its anterior wall is 6 mm longer than the posterior wall. EAC is usually divided into 2 parts: cartilaginous and bony. Its outer one-third (8 mm) is cartilaginous and inner two-third (16 mm) is bony.
- ***Direction:*** External auditory canal (EAC) is 'S' shaped and not straight. Its outer one-third cartilaginous part is directed upward, backward, and medially, while it's inner two-third bony part is directed downward, forward, and medially.

Examination of tympanic membrane: The pinna is pulled upward, backward, and laterally and this brings the two parts of EAC in alignment.

- ***Cartilaginous EAC:*** It is a continuation of the cartilage that forms the framework of the pinna.
  - ***Skin glands:*** The skin of the cartilaginous canal is thick and contains ceruminous and pilosebaceous glands that secrete wax. The hydrophobic, slightly acidic (pH 6.0–6.5) cerumen is formed in this part of EAC.

- ***Fissures of Santorini:*** Transverse slits in the floor of cartilaginous external auditory canal called ***"fissures of Santorini"*** provide passages for infections and neoplasms to and from the surrounding soft tissue (especially parotid gland). The parotid and mastoid infections can manifest in the EAC.
- ***Hair follicles*** are present only in the outer cartilaginous canal and therefore, furuncles (staphylococcal infection of hair follicles) are seen only in the cartilaginous EAC.

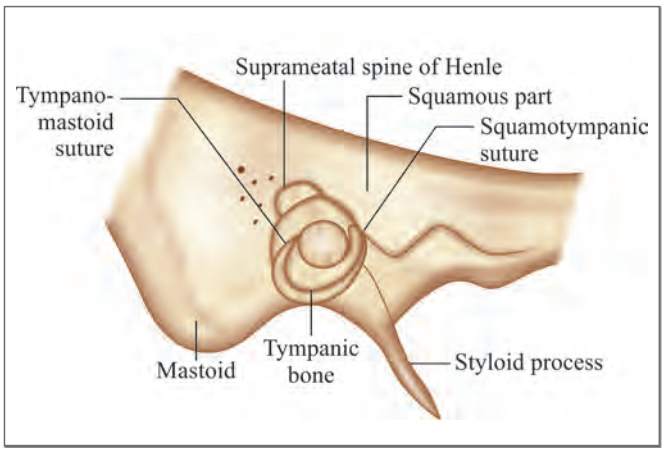

Fig. 2.4: Lateral view of temporal bone showing endomeatal spines and sutures

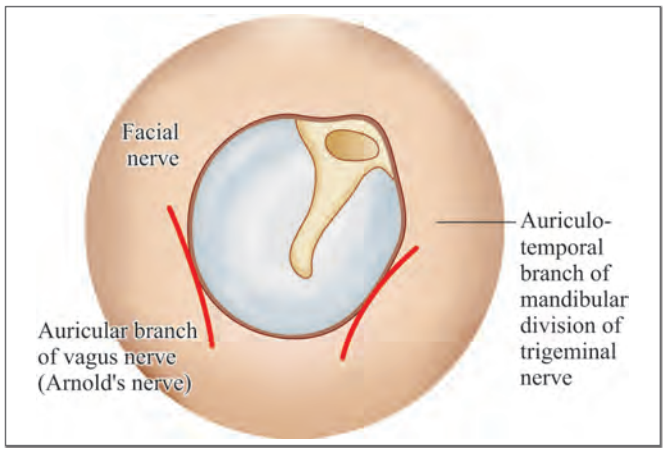

Fig. 2.5: Nerve supply of external auditory canal

- ***Bony EAC:*** It is mainly formed by the tympanic portion of temporal bone but roof is formed by the squamous part of the temporal bone (Fig. 2.4). In the anterosuperior region, squamous part articulates with tympanic bone (tympanosquamous suture). Inferiorly and medially squamous part joins with the lateral superior portion of the petrous bone (petrosquamous suture). Skin of the bony EAC is thin and continuous over the tympanic membrane. Here the skin is devoid of subcutaneous layer, hair follicles, and ceruminous glands.
  - ***Isthmus:*** Approximately, 6 mm lateral to tympanic membrane, bony EAC has a narrowing called the ***isthmus***. Big solid foreign body impacted medial to bony isthmus of EAC are difficult to remove.
  - ***Recess:*** Anteroinferior part of the deep bony meatus, medial to the isthmus has a recess, which is called the ***anterior recess***. The anterior recess of bony EAC acts as a cesspool for discharge and debris.
  - ***Foramen of Huschke:*** In children and occasionally in adults, anteroinferior bony EAC may have a deficiency that is called ***foramen of Huschke***.

Foramen of Huschke permits spread of infections to and from external auditory canal and parotid.

  - ***Relations of bony external auditory canal***
    - ***Superior:*** Middle cranial fossa
    - ***Inferior:*** Parotid gland
    - ***Posterior:*** Mastoid antrum and air cells and the facial nerve
    - ***Anterior:*** Temporomandibular joint (TMJ)
    - ***Medial:*** Tympanic membrane
    - ***Lateral:*** Cartilaginous EAC

Acute mastoiditis causes sagging of posterosuperior part of deeper bony external auditory canal because it is related with the mastoid antrum.

- ***Epithelial migration:*** The skin of EAC has a unique self-cleansing mechanism. This migratory process continues from the medial to lateral side. The sloughed epithelium is extruded out as a component of cerumen.

Nerve Supply (Fig. 2.5)

- ***Auriculotemporal nerve (CN V_3):*** It is a branch of mandibular division of trigeminal nerve and supplies anterosuperior wall of EAC.
- ***Vagus nerve (CN X):*** Its auricular branch (Arnold's nerve) supplies to inferoposterior EAC.
- ***Facial nerve (CN VII):*** It innervates the skin of the posterior part of EAC.

- ***Hitzelberger's sign:*** The hypoesthesia of posterior meatal wall occurs due to the pressure on facial nerve (sensory fibers are affected early) in patients with acoustic neuroma.
- ***Vasovagal reflex:*** While cleaning the EAC, patient may develop coughing, bradycardia, syncope, and even cardiac arrest. They occur because of Arnold's branch of vagus nerve.
- ***Appetite:*** Because of vagal innervation, instilling spirit in EAC before meal can stimulate appetite.
- ***Ramsay Hunt syndrome:*** Vesicles of herpes zoster oticus occur on mastoid and posterior meatal wall, which indicate that this part of external ear has facial nerve innervation.

TYMPANIC MEMBRANE

- ***Dimensions:*** Its dimensions are: 9-10 mm height, 8-9 mm width and 0.1 mm thickness.
- ***Position:*** Tympanic membrane is a partition wall between the EAC and the middle ear. It is positioned obliquely. It forms an angle of 55° with deep EAC. Its posterosuperior part is more lateral than its antero-inferior part.

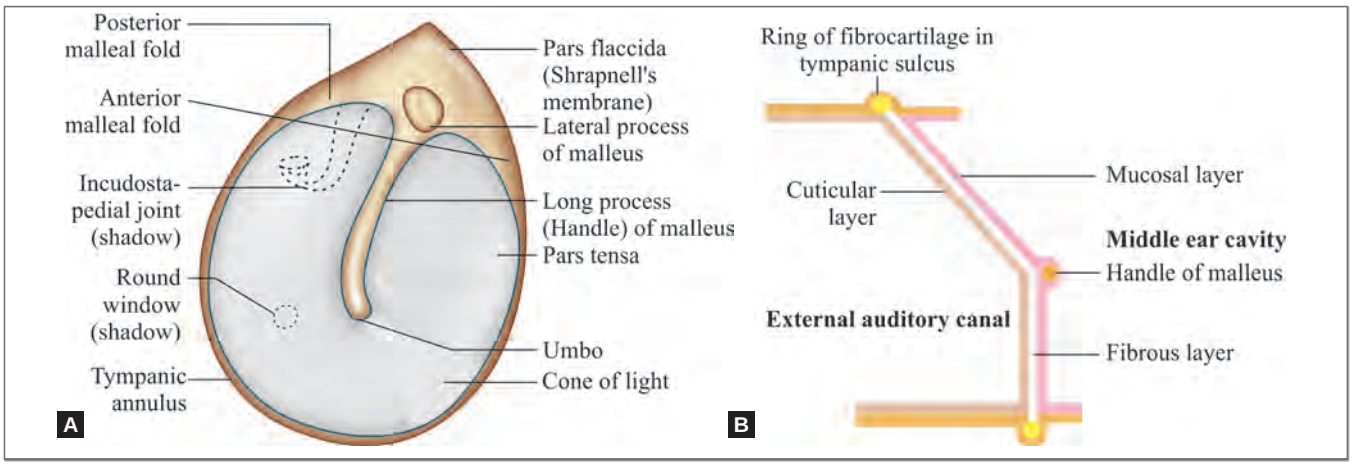

Figs 2.6A and B: (A) Tympanic membrane showing attic, malleus handle, umbo, cone of light and structures of middle ear seen through it on otoscopy; (B) Three layers of tympanic membrane

Parts

Tympanic membrane consists of two parts: Pars tensa and pars flaccida (Fig. 2.6A).

1. ***Pars tensa:*** It forms most of the tympanic membrane.
   - ***Annulus tympanicus:*** Tympanic membrane is thickened in the periphery and forms a fibrocartilaginous ring, called the ***annulus tympanicus*** that fits in the tympanic sulcus.
   - ***Umbo:*** The central part of tympanic membrane near the tip of malleus is tended inward and is called the ***umbo***.
   - ***Cone of light:*** A bright cone of light radiating from the tip of malleus to the periphery in the anteroinferior quadrant is usually seen during otoscopy.
2. ***Pars flaccida (Shrapnell's membrane):*** It is situated above the lateral process of malleus between the notch of Rivinus and the anterior and posterior malleal folds. It is not as tense as pars tensa and may appear little pinkish.

Structure

Tympanic membrane consists of the following three layers (Fig. 2.6B):

1. ***Outer epithelial layer:*** It is continuous with the EAC skin.
2. ***Middle fibrous layer:*** It encloses the handle of malleus and consists of three types of fibers: radial, circular, and parabolic. In comparison to pars tensa, this layer is very thin in pars flaccida and not organized into various fibers.
3. ***Inner mucosal layer:*** It is continuous with the middle ear mucosa.

- ***Otoscopy (Fig. 2.6A):*** Normal tympanic membrane is shiny and pearly-gray in color. Its lateral surface is concave, which is more marked at the tip of malleus (umbo). Attic area lies above the lateral process of malleus and is slightly pinkish. Its transparency varies from person to person. Some middle ear structures can usually be seen through tympanic membrane, such as incudostapedial joint, round window and eustachian tube.
- ***Mobility (seigalization):*** A normal tympanic membrane is mobile and this can be tested with pneumatic otoscope or Siegel's speculum.

Nerve Supply

- ***Auriculotemporal nerve (CN V_3):*** It supplies anterior half of lateral surface of tympanic membrane.
- ***Vagus nerve (CN X):*** Its auricular branch (Arnold's nerve) supplies to posterior half of lateral surface of tympanic membrane TM.
- ***Glossopharyngeal nerve (CN IX):*** Its tympanic branch (Jacobson's nerve) supplies to medial surface of tympanic membrane.

MIDDLE EAR ANATOMY

The middle ear cleft (Fig. 2.7), which is lined by mucous membrane and filled with air, consists of the middle ear, eustachian tube, aditus ad antrum, mastoid antrum and mastoid air cells. Middle ear is a 1–2 cm^3 air-filled cavity

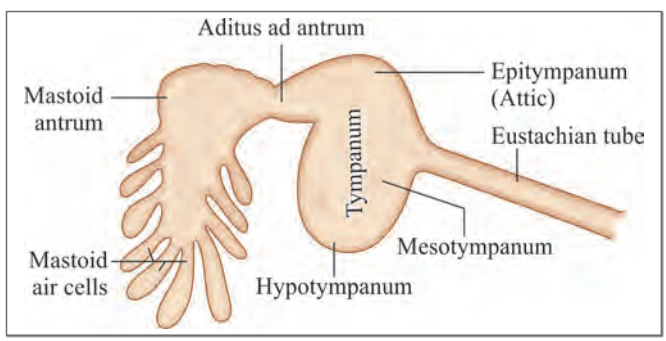

Fig. 2.7: Parts of middle ear cleft

that houses ossicles (malleus, incus, stapes), muscles (tensor tympani, stapedius) and nerves (chorda tympani, tympanic plexus).

Relations of Middle Ear Cleft

- ***Roof:*** Tegmen plate separates it from middle cranial fossa and its contents like meninges and temporal lobe of cerebrum.
- ***Floor:*** Jugular bulb.
- ***Medial:*** Labyrinth. Lateral semicircular canal lie posterosuperior to facial nerve.
- ***Posterior:*** Sigmoid intracranial venous sinus.
- ***Anterior:*** Petrous part of internal carotid artery lying in carotid canal.
- ***Posteromedial:*** Posteromedial to mastoid air cells is situated cerebellum in the posterior cranial fossa.
- ***Cranial nerves:***
  - ***CN V and CN VI:*** They lie close to the apex of the petrous pyramid.
  - ***CN VII:*** The horizontal tympanic part is situated in the medial wall of middle ear, while vertical mastoid part runs between the middle ear and mastoid air cells system.

Parts of Middle Ear (Tympanum)

The dimensions of middle ear are shown in Figure 2.8. The tympanum is traditionally divided into three parts—mesotympanum, epitympanum, and hypotympanum (Fig. 2.9).

1. ***Mesotympanum:*** This is the portion of middle ear that lies at the level of pars tensa.
2. ***Epitympanum (attic):*** This is the portion of middle ear that lies above the level of pars tensa and medial to Shrapnell's membrane and the lateral bony attic wall.
3. ***Hypotympanum:*** This is the portion of middle ear that lies below the level of pars tensa.

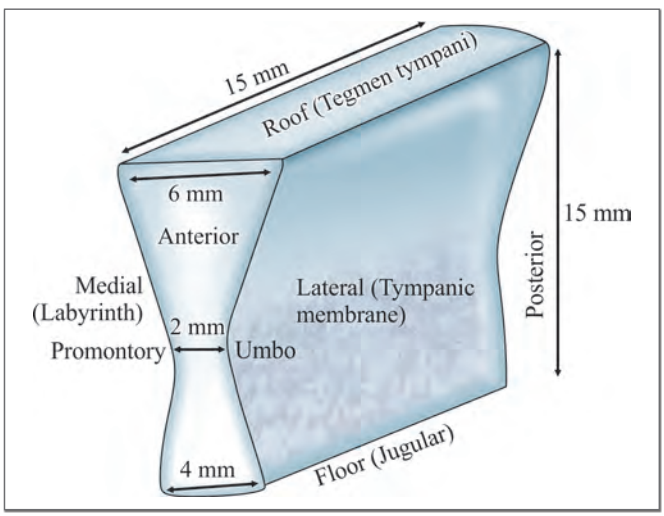

Fig. 2.8: Dimensions of tympanum

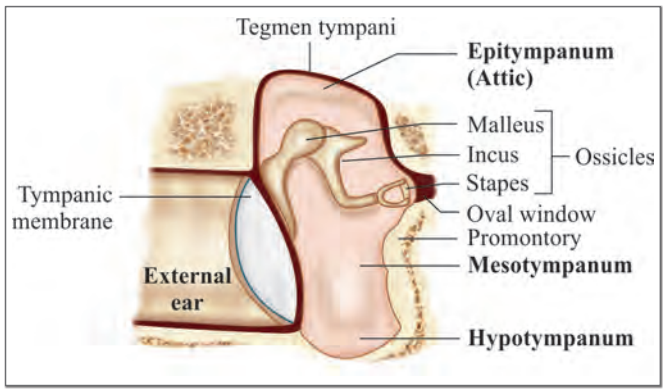

Fig. 2.9: Parts of middle ear seen on coronal section

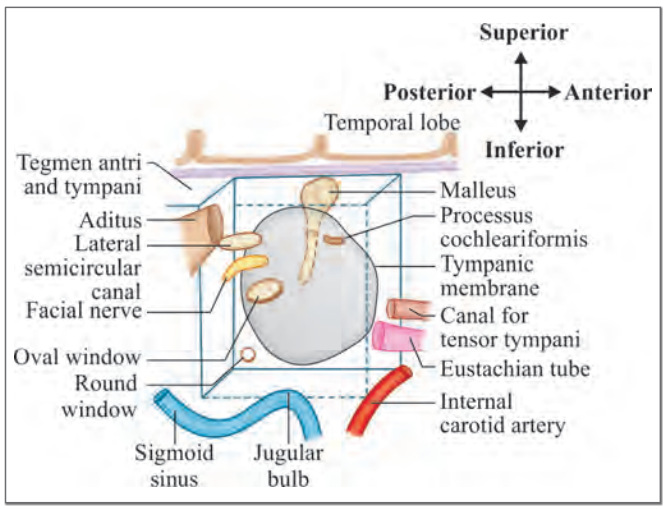

Fig. 2.10: Six boundaries of tympanum. Medial wall is seen through the tympanic membrane

- ***Protympanum:*** The portion of middle ear around the eustachian tube opening is termed as ***protympanum***.

Boundaries of Middle Ear

Middle ear has six boundaries—roof, floor, and medial, lateral, anterior and posterior walls (Fig. 2.10).

1. ***Roof (tegmental wall):*** It is formed by tegmen tympani (a thin plate of bone), which extends posteriorly to form the roof of the aditus and antrum (tegmen antri). Tegmen tympani separates middle ear from the middle cranial fossa.
2. ***Floor (jugular wall):*** A thin plate of petrous temporal bone separates tympanic cavity from the jugular bulb.

Dehiscent roof of jugular fossa: The floor of middle ear may be congenitally dehiscent. In such cases, jugular bulb projects into the middle ear and is at greater risk of injury during surgery because it is just covered by middle ear mucosa.

3. ***Anterior (carotid wall):*** A thin plate of petrous part of temporal bone separates the middle ear cavity from the internal carotid artery. The anterior wall has the following features:
   - ***Eustachian tube:*** It connects the middle ear with nasopharynx. It aerates and drains the middle ear. *See* Chapter on 'Disorders of Eustachian Tube'.

Otitis media: Malfunctioning of Eustachian tube is the key cause of middle ear infections.

   - ***Canal of tensor tympani muscle:*** It is situated in the roof of eustachian tube.
   - Canal for chorda tympani nerve.
   - Attachment of anterior malleolar ligament.
4. ***Posterior (mastoid wall):*** It lies close to the mastoid air cells and presents following structures:
   - ***Pyramid:*** It is a bony projection through the summit of which appears the tendon of the stapedius muscle that is inserted to the neck of stapes.
   - ***Aditus ad antrum:*** It is an opening through which mastoid antrum opens into the attic. It lies above the pyramid. Its relations are following:
     - ***Medial:*** Bony prominence of the horizontal semicircular canal.
     - ***Lateral:*** Fossa incudis, to which is attached the short process of incus.
     - ***Inferior:*** Fallopian canal for facial nerve.
     - ***Superior:*** Tegmen antri.
   - ***Facial nerve:*** The vertical mastoid part of the fallopian canal for facial nerve runs in the posterior wall just behind and below the pyramid.
   - ***Facial (suprapyramidal) recess (Fig. 2.11):*** This recess is a depression in the posterior wall lateral to the pyramid. Its boundaries are following:
     - ***Medial:*** Vertical part of CN VII.
     - ***Lateral:*** Chorda tympani (branch of CN VII) and tympanic annulus.
     - ***Superior:*** Fossa incudis, in which lies short process of incus.

Intact canal wall mastoidectomy: The middle ear is approached (posterior tympanotomy or facial recess approach) through the facial recess without disturbing posterior meatal wall (Fig. 2.12).

   - ***Sinus (infrapyramidal) tympani:*** This deep recess lies medial to the pyramid. It is bounded by the subiculum below and the ponticulus above.
5. ***Medial (labyrinthine wall) (Figs 2.13 and 2.14):*** It is formed by the lateral wall of labyrinth. It presents following structures:
   - ***Promontory:*** It is a bony bulge which is due to the basal coil of cochlea.
   - ***Oval window (fenestra vestibuli):*** The footplate of stapes is placed in this window.
   - ***Round window (fenestra cochleae):*** It is covered by the secondary tympanic membrane.
   - ***Horizontal tympanic part of fallopian canal for facial nerve:*** It lies above the oval window.

Facial palsy: The tympanic segment of facial nerve canal may be congenitally dehiscent and the exposed facial nerve becomes vulnerable to injuries during middle ear surgeries and infection in cases of otitis media.

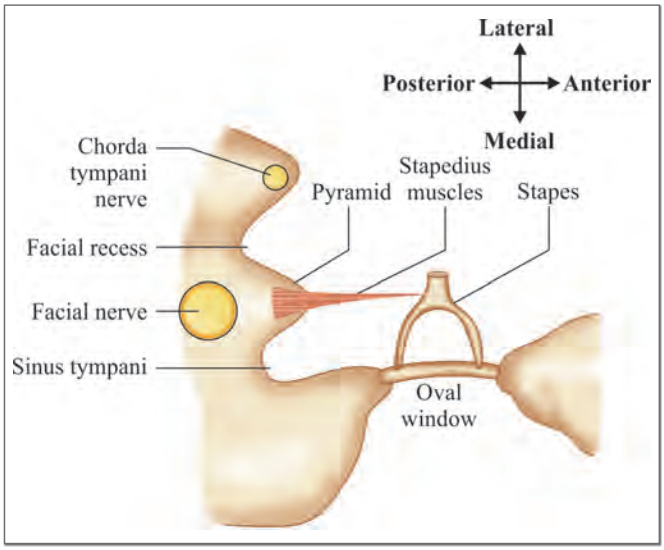

Fig. 2.11: Facial recess and sinus tympani relations with facial nerve and pyramidal eminence

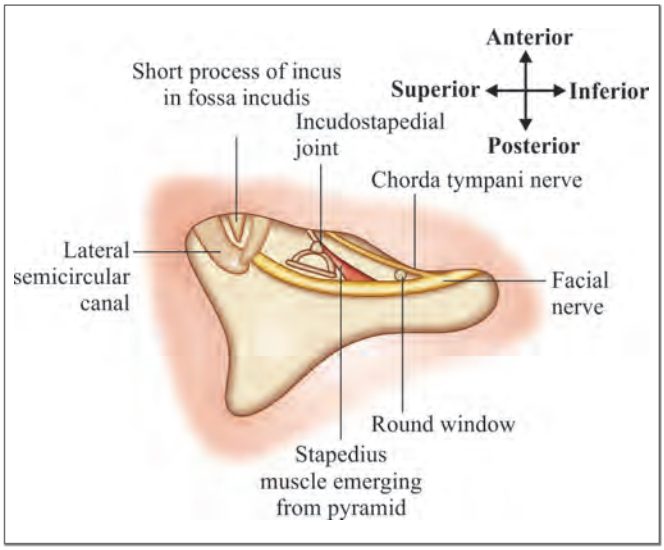

Fig. 2.12: Posterior tympanotomy. Structures of middle ear seen through the opening of facial recess

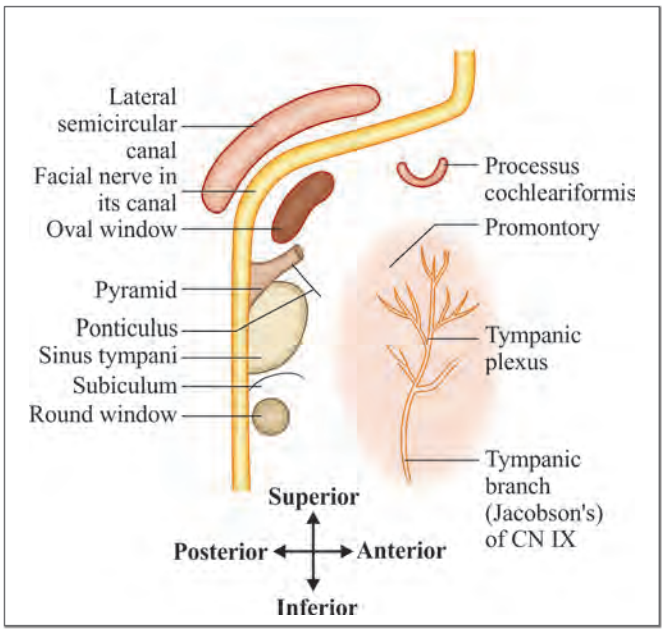

Fig. 2.13: Medial wall of middle ear

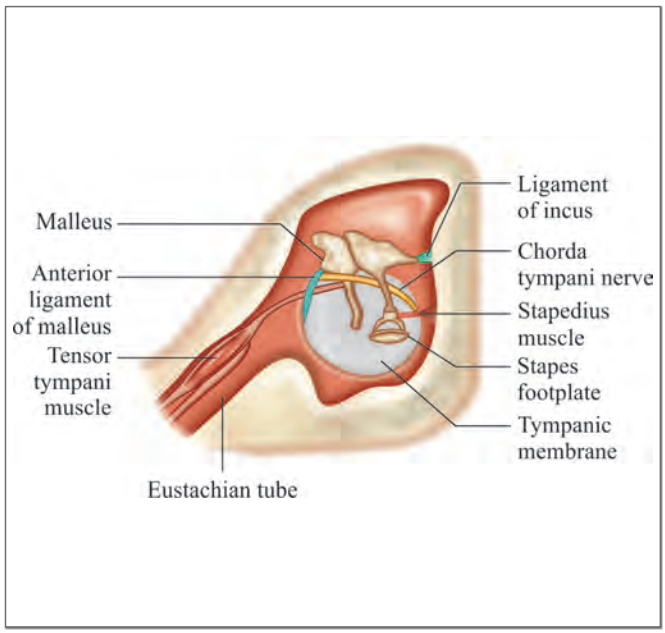

Fig. 2.15: Right tympanic membrane, ossicles, and eustachian tube seen from medial side

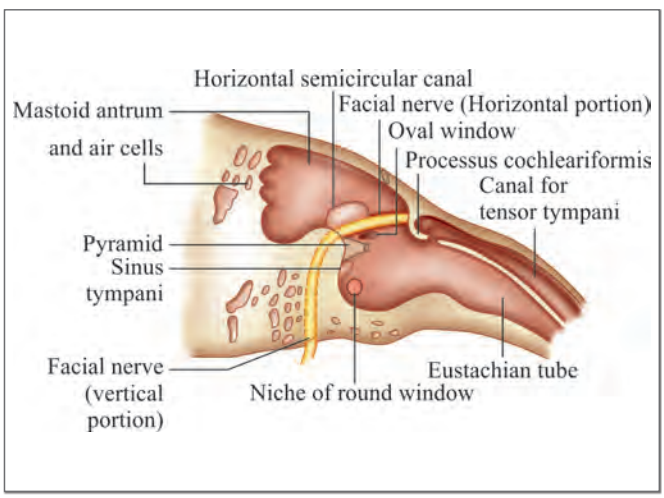

Fig. 2.14: Medial wall of middle ear cleft

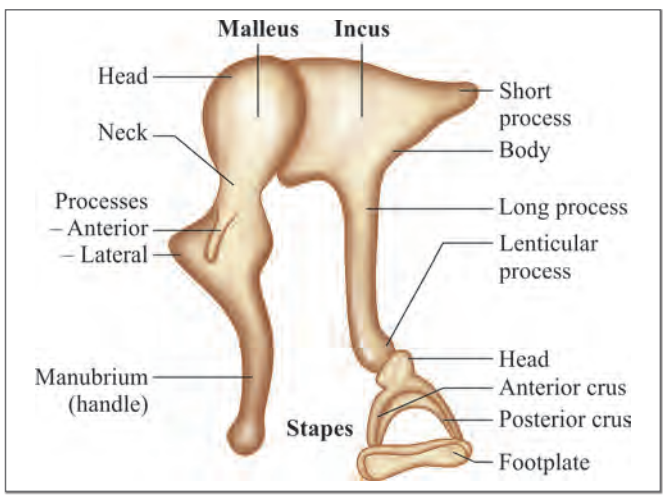

Fig. 2.16: Middle ear ossicles

- ***Lateral semicircular canal:*** It lies above the fallopian canal of facial nerve.
- ***Processus cochleariformis:*** It is a hook-like projection, which lies anterior to the oval window. The tendon of tensor tympani takes a turn on this process and then is inserted on the neck of malleus.

Processus cochleariformis is an important surgical landmark for the level of the genu of the facial nerve.

6. ***Lateral (membranous wall) (Fig. 2.15):***
   - ***Tympanic membrane:*** Lateral wall is formed mainly by the tympanic membrane. Some structures of the middle ear (such as long process of incus, incudostapedial joint, round window, and eustachian tube) can be seen through the normal semitransparent tympanic membrane.
   - ***Scutum:*** An upper part of epitympanum is formed by outer bony attic wall called ***scutum***.

Ossicles

The ossicles (Fig. 2.16) conduct sound energy from the tympanic membrane to the oval window. There are three middle ear ossicles—malleus, incus and stapes.

1. ***Malleus (hammer):*** It consists of a head, neck, handle (manubrium), and a lateral and an anterior process. It is the largest ossicle and measures 8 mm in length.

- ***Head and neck:*** They lie in the attic.
- ***Manubrium:*** It is embedded in the fibrous layer of the tympanic membrane.
- ***Lateral process:*** It appears as a knob-like projection on the outer surface of the tympanic membrane and provides attachments to the anterior and posterior malleal folds.

2. ***Incus (anvil):*** It consists of following parts:
   - ***Body and short process:*** They lie in the attic.
   - ***Long process:*** It hangs vertically and forms incudostapedial joint with the head of stapes.
3. ***Stapes (stirrup):*** This smallest bone of body measures about 3.5 mm. It consists of head, neck, anterior and posterior crura, and footplate. The footplate is positioned in the oval window by annular ligament.

Intratympanic Muscles

There are two middle ear muscles—tensor tympani and stapedius.

1. ***Tensor tympani (Fig. 2.15):*** It runs above the eustachian tube. Its tendon turns round the processus cochleariformis and passes laterally. It tenses the tympanic membrane.
   - ***Origin:*** Bony tunnel above the osseous part of eustachian tube.
   - ***Insertion:*** Just below the neck of malleus.
   - ***Nerve supply:*** It develops from the 1st branchial arch and is supplied by a branch of mandibular division of trigeminal nerve (CN V_3).
2. ***Stapedius (Fig. 2.15):*** On contraction, it dampens the loud sounds and prevents noise trauma to the inner ear.
   - ***Origin:*** Conical cavity and canal within pyramid.
   - ***Insertion:*** It inserts on the neck of stapes.
   - ***Nerve supply:*** It is developed from the second branchial arch and is supplied by a branch of CN VII (nerve to stapedius).
   - ***Functions:*** Acoustic reflex protects ear from loud sounds.
     - Dampening of middle ear mechanics: Loud sounds (80 dB and above) cause contraction of stapedius that limits stapes movement.
     - Gain control mechanism: Acoustic reflex keep cochlear input more constant and expand dynamic range.
     - Reduction in self generated noise: Stapedius muscle contracts with chewing and vocalization.

Intratympanic Nerves (Figs 2.11 to 2.15)

- ***Tympanic plexus (nerve supply of middle ear):*** The tympanic nerve plexus, which lies on the promontory, supplies to the medial surface of the tympanic membrane, tympanic cavity, mastoid air cells, and the bony eustachian tube. It is formed by following nerves:
  - ***Tympanic branch (Jacobson) of glossopharyngeal:*** It carries secretomotor fibers to the parotid gland. The pathway of secretomotor fibers to the parotid gland consists of inferior salivary nucleus → CN IX → Jacobson's tympanic branch → tympanic plexus → lesser petrosal nerve → otic ganglion → auriculotemporal nerve → parotid gland.



Frey's syndrome: Its treatment includes sectioning of Jacobson's nerve. *See* Chapter 'Disorders of Salivary Glands'.

  - ***Sympathetic fibers:*** Caroticotympanic nerves come from the sympathetic plexus, which is present around the internal carotid artery.
- ***Chorda tympani nerve:*** This branch of the facial nerve enters the middle ear through posterior canaliculus. It runs on the medial surface of the tympanic membrane. It lies between the malleus and long process of incus, above the insertion of tensor tympani. It carries gustatory fibers from the anterior two-third of tongue and parasympathetic secretomotor fibers to the submaxillary and sublingual salivary glands.

Middle Ear Mucosa

Middle ear mucosa wraps ossicles, muscles, ligaments and nerves like peritoneum wraps various viscera in the abdomen. These mucosal folds divide the middle ear into various compartments. So, all the middle ear structures lie outside the mucous membrane. Mucous membrane of the nasopharynx is continuous with that of the middle ear cleft.

- ***Prussak's space:*** It is bounded by pars flaccida (laterally), neck of malleus (medially), lateral process of malleus (inferiorly), and lateral malleal ligament (superiorly). Posteriorly, it opens into epitympanum.
- ***Von Troeltsch anterior pouch:*** It is situated between the pars tensa and anterior malleolar fold.

Middle ear cavity is lined by ciliated columnar epithelium in its anterior and inferior part and mucosa changes to cuboidal type in the posterior part. Attic and mastoid air cells are lined by flat nonciliated epithelium. Eustachian tube is lined by ciliated pseudostratified columnar epithelium with several mucous glands in the submucosa.

MASTOID ANTRUM

This air-containing space (9 mm height, 14 mm width, and 7 mm depth) is situated in the upper part of mastoid. It has the following boundaries:

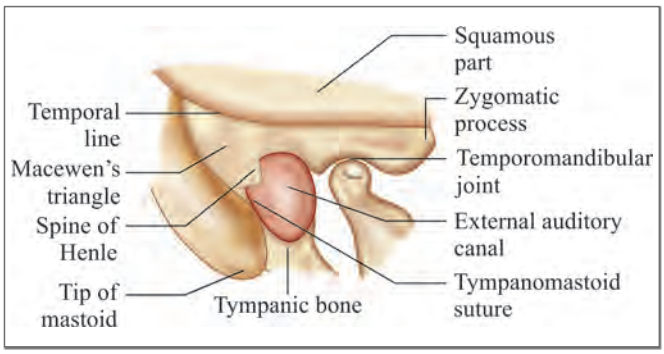

Fig. 2.17: Macewen's triangle. Surface landmark for mastoid antrum

- ***Roof:*** It is formed by the tegmen antri which separates mastoid antrum from the middle cranial fossa.
- ***Lateral wall:*** It is formed by a 1.5 cm thick plate of squamous part of temporal bone, which is marked on the lateral surface of mastoid by suprameatal (Macewen's) triangle (Fig. 2.17). It is covered by postaural skin.
  - ***Boundaries of Macewen's triangle***
    - ***Linea temporalis (temporal line):*** A ridge of bone extending posteriorly from the zygomatic process (marking the lower margin of temporalis muscle and approximating the floor of middle cranial fossa).
    - ***External auditory canal:*** Posterosuperior margin of EAC.
    - ***Tangent:*** A tangent to the posterior margin of EAC.
- ***Medial wall:*** It is formed by the petrous bone and related to the following parts:
  - Posterior semicircular canal
  - Endolymphatic sac
  - Dura of posterior cranial fossa
- ***Anterior:*** Anteriorly, mastoid antrum communicates with the attic through the aditus ad antrum. Medial to lateral relations are as follows:
  - Facial nerve canal.
  - Aditus ad antrum and facial recess lie between tympanum and mastoid antrum (*see* 'Posterior Wall of Middle Ear' in the Section of Boundaries of Middle Ear).
  - Deep bony EAC.
- ***Posterior wall:*** It is formed by mastoid bone and communicates with mastoid air cells.
  - Sigmoid sinus curves downward.
- ***Floor:*** It is formed by mastoid bone and communicates with mastoid air cells. Other deeper relations from medial to lateral sides are.
  - Jugular bulb medial to facial canal.
  - Digastric ridge which gives origin to posterior belly of digastric muscle.
  - Origin of sternocleidomastoid muscle.

Types of Mastoid

The mastoid consists of ***honeycomb*** air cells, which lie underneath the bony cortex. Depending on its development, three types of mastoid are described—cellular, diploeic and acellular (Figs 2.18A, B and C).

1. ***Cellular (well-pneumatized):*** Mastoid cells are well developed with thin intervening septa (Fig. 2.18A).
2. ***Diploeic:*** Mainly there are marrow spaces with few air cells (Fig. 2.18B).
3. ***Acellular (sclerotic):*** There are neither cells nor marrow spaces (Fig. 2.18C).

- ***Citelli's angle (sinudural angle):*** It lies between the sigmoid sinus and middle fossa dura mater.
- ***Bill's island:*** This thin plate of bone left on sigmoid sinus during mastoidectomy helps in retracting the sigmoid sinus. It should not be confused with Bill's bar, which lies in the fundus of internal auditory canal.
- ***Solid angle:*** This area of bony labyrinth lies between the three semicircular canals.
- ***Trautmann's triangle:*** This area is bounded by the bony labyrinth anteriorly, sigmoid sinus posteriorly, and the dura or superior petrosal sinus superiorly.
- ***Donaldson's line:*** This line is a surgical landmark for endolymphatic sac. It passes through horizontal bisecting the posterior semicircular canal. The endolymphatic sac that appears as thickening of the posterior cranial fossa dura is situated inferior to Donaldson's line.

Mastoid Air Cells

Mastoid antrum, which is present in all types of mastoids, is the most constant mastoid air cell. In ***sclerotic mastoid***,

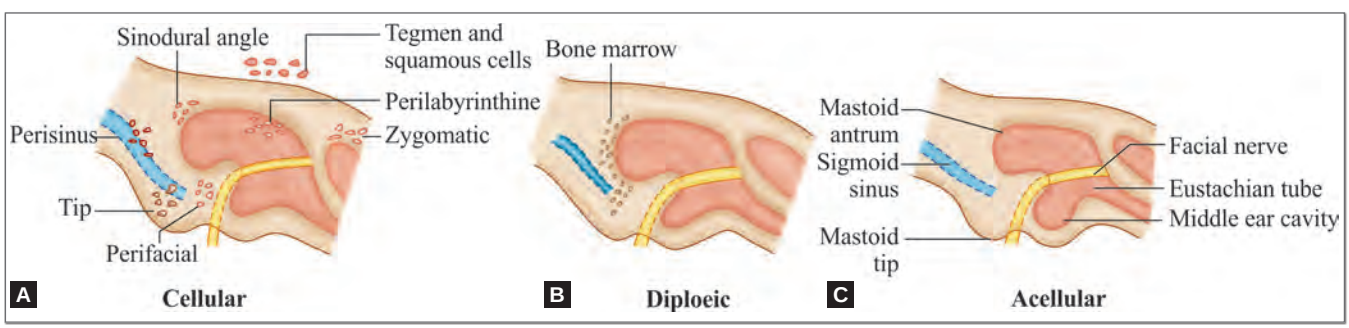

Figs 2.18A to C: Three types of mastoid. (A) Cellular; (B) Diploeic; (C) Acellular

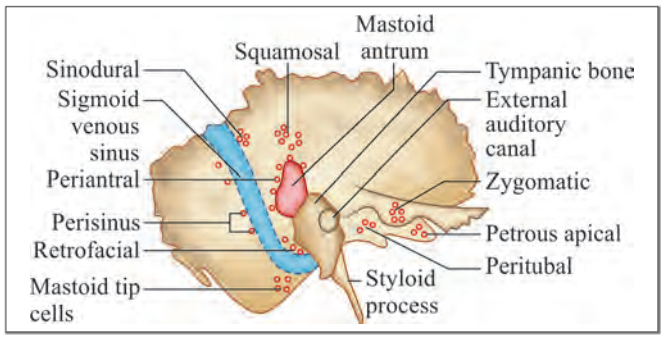

Fig. 2.19: Air cells of temporal bone

antrum is usually small and sigmoid sinus may be anteriorly positioned. In cases of mastoiditis, abscesses may form in these air cells and result in various types of intra and extra cranial complications (*See* Chapter 'Complications of Suppurative Otitis Media').

The mastoid air cells are traditionally divided into several groups (Fig. 2.19) which include:

- ***Zygomatic cells:*** In the root of zygoma.
- ***Tegmen cells:*** In the tegmen tympani.
- ***Perisinus cells:*** Present over the sinus plate.
- ***Retrofacial cells:*** Present round the fallopian canal of facial nerve.
- ***Perilabyrinthine cells:*** They are located above, below and behind the labyrinth. The cells, which are present in the arch of superior semicircular canal, may communicate with the petrous apex.
- ***Peritubal:*** They are present around the eustachian tube. These and the hypotympanic cells communicate with the petrous apex.
- ***Tip cells:*** These large cells lie in the tip of mastoid medial and lateral to the digastric ridge.
- ***Marginal cells:*** These cells, which lie behind the sinus plate, may extend into the occipital bone
- ***Squamous cells:*** They lie in the squamous part of temporal bone.

- ***Mastoid tip:*** It is absent at the time of birth but mastoid antrum is present. Mastoid tip does not develop till 2 years. Therefore, postaural incision for mastoid exploration in children needs modification to avoid injury to the facial nerve.
- ***Mastoid antrum:*** In an adult, it lies 12–15 mm deep to suprameatal triangle. But at the time of birth, it lies just 2 mm deep to suprameatal triangle. The thickness of the bone increases up to puberty at the rate of 1 mm per year.

Korner's Septum

Mastoid develops from the squamous and petrous parts of temporal bone. In some cases, petrosquamous suture persists as a bony plate called ***Korner's septum***, which separates superficial squamous cells from the deep petrosal cells. During the mastoid surgery, Korner's septum causes difficulty in locating the antrum and the deeper cells.

If not recognized, Korner's septum leads to incomplete removal of disease during mastoidectomy. Mastoid antrum can be entered only after the removal of Korner's septum.

Table 2.1: Arteries supplying middle ear

• ***External carotid artery*** ▪ ***Maxillary artery*** ▪ ***Anterior tympanic artery:*** Major contributor ▪ ***Middle meningeal artery*** – *Petrosal branch* – ***Superior tympanic artery:*** *It traverses along the canal for tensor tympanic muscle* – ***Artery of pterygoid canal:*** *Branch that runs along eustachian tube*	• ***Internal carotid artery*** ▪ Petrous part ▪ Caroticotympanic branches

Blood Supply

Arterial Supply

The middle ear is supplied by branches of external and internal carotid arteries (Table 2.1).

Venous Drainage

Veins from the middle ear cleft drain into pterygoid venous plexus, superior petrosal sinus and sigmoid sinus.

Lymphatic Drainage

The lymphatics of middle ear drain into retropharyngeal and parotid nodes. Eustachian tube lymphatics drain into retropharyngeal group of lymph nodes (Table 2.2). Internal ear does not have any lymphatics.

Table 2.2: Lymphatic drainage of ear

Nodes	Region
Preauricular and parotid nodes	Auricle: Concha, tragus, fossa triangularis Cartilaginous EAC
Infra-auricular nodes	Auricle: Lobule and antitragus
Postauricular, deep cervical, and spinal accessory nodes	Auricle: Helix and antihelix
Retropharyngeal nodes draining into upper deep cervical nodes	Middle ear and eustachian tube

INTERNAL EAR ANATOMY

The internal ear (labyrinth), which has organs of both hearing and balance, is divided into bony and membranous labyrinth. The membranous labyrinth is filled with endolymph. Perilymph is filled in the space present between membranous and bony labyrinths.

Bony Labyrinth

Bony labyrinth (Fig. 2.20) consists of three parts: vestibule, semicircular canals, and cochlea. The lateral wall of labyrinth is medial wall of middle ear. The medial wall of labyrinth is the lateral limit of internal auditory canal (IAC) (Fig. 20.21).

Vestibule

This central chamber of the labyrinth (5 mm) has following structures:

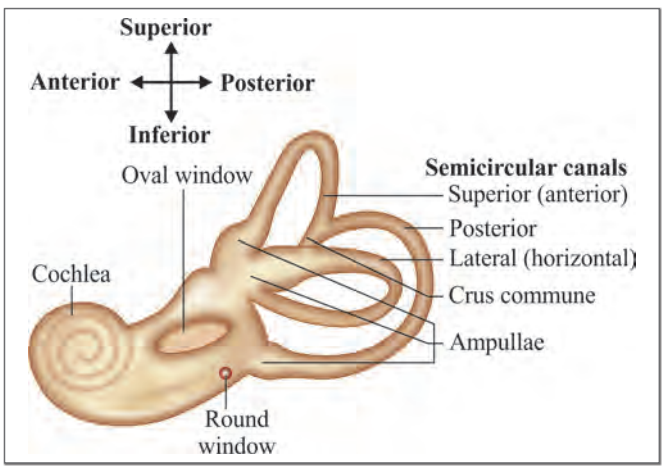

Fig. 2.20: Bony labyrinth of left side. External features seen from lateral side

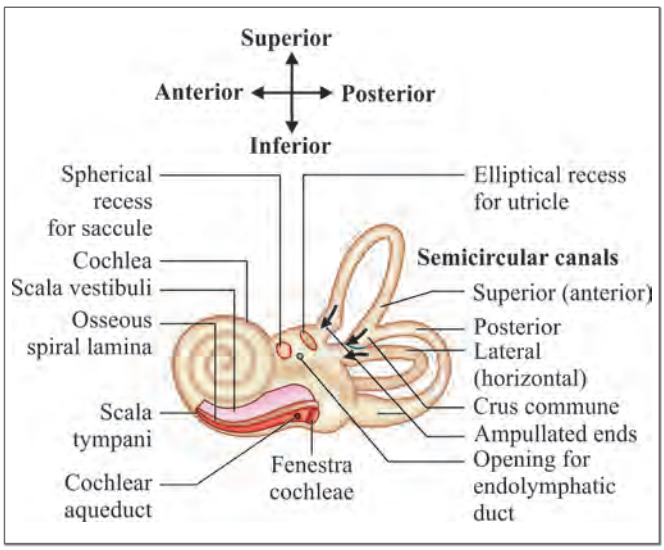

Fig. 2.21: Medial wall of left bony labyrinth seen from lateral side after the removal of its lateral wall

- ***Lateral wall:*** It has oval window:
  - Oval window (fenestra vestibuli): It lies in the lateral wall and closed by footplate of stapes surrounded by annular ligament.
- ***Medial wall (Fig. 2.21):*** It shows following structures:
  - ***Spherical recess:*** It is situated anteriorly and lodges the saccule. Perforations of maculae cribrosa media provides passage for fibers of inferior vestibular nerve.
  - ***Elliptical recess:*** It is situated posteriorly and lodges the utricle. The perforations of maculae cribrosa superior (Mike's dot) provide passage to nerve fibers that supply to utricle and ampulla of superior and lateral semicircular canals.
  - ***Vestibular crest and cochlear recess:*** The spherical and elliptical recesses are separated from each other by vestibular crest. Inferiorly vestibular crest splits to enclose cochlear recess for cochlear nerve fibers.
  - ***Opening of aqueduct of vestibule:*** It is present below the elliptical recess. Through this passes the endolymphatic duct.

Large vestibular aqueduct syndrome: An enlarged vestibular aqueduct is associated with sensorineural hearing loss, Pendred's syndrome and anatomic defects of cochlear modiolus.

- ***Posterosuperior region:***
  - ***Five openings of semicircular canals:*** They are present in the posterosuperior part of vestibule.
- ***Anterior:*** Cochlea opens into the anterior region of vestibule.

Semicircular Canals (SCCs)

There are three SCCs: Lateral (horizontal), posterior, and superior (anterior). Each canal occupies two-third of a circle and has a diameter of 0.8 mm. They lie in planes at right angles to one another. Each canal has two ends, ampullated and nonampullated. All the three ampullated ends and nonampullated end of lateral semicircular canal open independently and directly into the vestibule.

1. ***Superior semicircular canal:*** It is 15–20 mm long and situated transverse to the axis of petrous part of temporal bone. Its anterolateral end is ampullated and opens in the superolateral part of vestibule.
2. ***Lateral semicircular canal:*** It is 12–15 mm long and projects as a rounded bulge into the middle ear, aditus and antrum. It makes an angle of 30° with the horizontal plane. Its anterior end is ampullated and opens into the upper part of vestibule. The posterior nonampullated end opens into the lower part of vestibule below the orifice of crus commune.

- ***Posterior semicircular canal:*** It is 18–22 mm long and situated parallel and close to the posterior surface of petrous part of temporal bone. Its lower end is ampullated and opens into the lower part of vestibule. Its upper limb joins the crus commune.
  - ***Crus commune:*** The nonampullated ends of posterior and superior canals join and form a crus commune (4 mm length), which then opens into the medial part of vestibule. So, the three semicircular canals open into the vestibule by five openings.

Semicircular canals: They connect with the utricle via five openings. Semicircular canals of two sides are paired synergistically (horizontal canals of both sides: and one side posterior with opposite side superior).

Cochlea

The bony cochlea, which is a coiled tube, looks like a snail. Cochlear canal makes 2.5–2.75 turns round a central pyramid of bone called ***modiolus***. The cochlear tube is 30 mm long. It is 5 mm from base to apex and 9 mm around its base.

- ***Modiolus:*** The base of modiolus, which is directed towards internal acoustic meatus, transmits vessels and nerves to the cochlea. The apex lies medial to tensor tympani muscle.
- ***Osseous spiral lamina:*** A thin plate of bone called osseous spiral lamina, winds spirally around the modiolus like the thread of a screw (Fig. 2.22). This bony lamina gives attachment to the basilar membrane and divides the bony cochlear tube into three compartments—1. scala vestibuli, 2. scala tympani and 3. scala media (membranous cochlea).
- ***Rosenthal's canal:*** The spiral ganglions are situated in Rosenthal's canal, which runs along the osseous spiral lamina.
- ***Scala vestibuli:*** This upper most channel is continuous with vestibule and closed at oval window by the stapes foot plate.
- ***Scala tympani:*** This lowermost channel is closed by secondary tympanic membrane of round window.
- ***Promontory:*** The promontory, a bony bulge in the medial wall of middle ear, represents the basal coil of cochlea.
- ***Helicotrema:*** This opening is situated at the apex of cochlea which provides communication between the scala vestibuli and scala tympani. They are filled with perilymph.
- ***Round window (fenestra cochlea):*** On the lateral wall of internal ear (medial wall of middle ear), scala vestibuli is closed by the stapes footplate, while the scala tympani is closed by secondary tympanic membrane of round window.
- ***Aqueduct of cochlea:*** The scala tympani is connected with the subarachnoid space through the aqueduct of cochlea. It is thought to regulate perilymph and pressure in bony labyrinth.

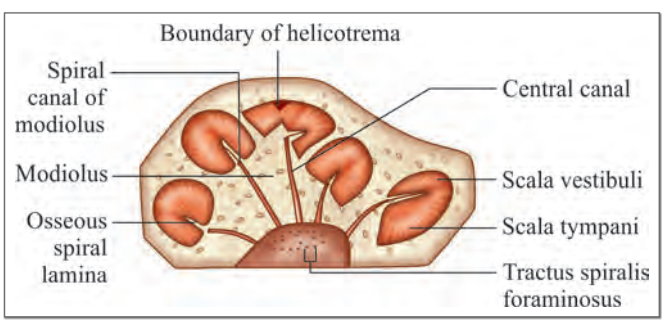

Fig. 2.22: Cross section of bony cochlea

Membranous Labyrinth

Membranous labyrinth (Fig. 2.23) consists of cochlear duct, utricle, saccule, three semicircular ducts, and endolymphatic duct and sac.

- ***Cochlear duct (membranous cochlea or scala media) (Fig. 2.23):*** This blind coiled tube, which appears triangular on cross-section, is connected to the saccule through ductus reunions. It is bounded by the following three walls:
  - ***Basilar membrane:*** It supports the organ of Corti. Its length increases as it proceeds from the basal coil to the apical coil. So, the higher frequencies of sound are heard at the basal coil, while lower tones at the apical coil. The inner thin area is called ***zona arcuata***, while outer thick area is called ***zona pectinata***.
  - ***Reissner's membrane:*** It separates scala media from the scala vestibuli.
  - ***Stria vascularis:*** It contains vascular epithelium and secrets endolymph.
- ***Utricle:*** The utricle, which is oblong and irregular, has anteriorly upward slope at an approximate angle of 30°.

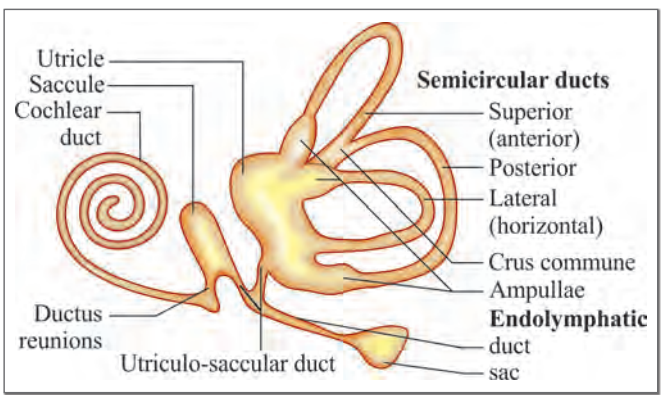

Fig. 2.23: Membranous labyrinth of left side: external features

for detailed information on otolaryngology books, visit our website **www.jaypeebrothers.com,** for detailed information on otolaryngology books, visit o

Essentials of
Ear, Nose & Throat

Salient Features

- Contemporary concise textbook representing ear, nose, throat, head and neck surgery in all of its diversity.
- Instructive boxes, tables, flow charts, line diagrams and photographs to enhance learning.
- Numerous carefully drawn colored illustrations enhancing understanding and retention of facts.
- Clinical applications and key points highlighted and integrated.
- Comprehensive and of broader scope book designed for students, residents and practitioners.
- Brevity, conciseness, readable format and up-to-date discussions.
- Each chapter begins with the Specific Learning Objectives, having set of questions so that students can have targeted and attentive learning.
- Each chapter ends with the Self-evaluation Exercises which consist of MCQs, true or false, filling the gaps and matching for preparing the students for PGME, USMLE and PLAB, short-answer questions and oral/viva questions.
- Problem-oriented cases and additional Pearls and Nuggets.
- Chapters reviewed by senior ENT faculties.



Mohan Bansal got his bachelor and master degrees (MBBS and MS) from SP Medical College (Bikaner) and PhD from BJ Medical College (Ahmedabad). Presently, he is consultant Otolaryngologist (Head and Neck Surgeon). He is the chairman (2015–17) of Editorial Board of Indian Journal of Otolaryngology and Head and Neck Surgery which is an official publication of the Association of Otolaryngologists of India (AOI). He has made contributions to otolaryngology as a teacher, educator, author and consultant. As a part of his PhD original research work, he developed an Expert Computer System for the diagnosis of dizzy patients which is first of its type in the world. In addition to many guest lectures, presentations and publications of scientific papers and chapters in books, he has two prestigious books to his credit.

He has participated, directed and organized conferences, seminars, symposia and workshops at the state, national and international levels and chaired scientific sessions and held key-positions in many organizations. He has many international awards and scholarships to his credit such as Garnett Passe Scholarship to attend and present his work in the XVI World Congress (1997) of International Federation of Oto-Rhino-Laryngology Societies (IFOS) at Sydney in Australia; member the Group Study Exchange (GSE) team (1997) of Rotary Foundation to USA. He was the first Indian who got selected for USA's National Library of Medicine (NLM) Fellowship Program in Medical Informatics and attended its Fall Course (2001) at Marine Biological Laboratory (MBL) Woods Hole Boston Massachusetts. He is well travelled and has been to more than 20 countries of the world. He was member of the IMA's study tour to Southeast Asia (Thailand, Singapore and Hong Kong) coinciding with WONCA (1995).

Available at all medical bookstores
or buy online at www.jaypeebrothers.com

JAYPEE
JAYPEE BROTHERS
Medical Publishers (P) Ltd.
www.jaypeebrothers.com

Join us on facebook.com/JaypeeMedicalPublishers

Shelving
Recommendation
OTOLARYNGOLOGY

ISBN 978-93-5152-331-4