aypeebrothers.com, for detailed information on pathology books, visit our website www.jaypeebrothers.com, for detailed information on patholog

Prithwiraj Maiti

JAYPEE

A Practical Handbook of PATHOLOGY Specimens and Slides



Contents

SECTION — I SPECIMENS 1–98

Chapter 1: Cardiovascular System 1–19
- Mitral stenosis *3*
- Subacute bacterial endocarditis (SABE) *9*
- Atheroma *11*
- Left ventricular hypertrophy *14*
- Fibrinous pericarditis *17*

Chapter 2: Gastrointestinal Tract 20–33
- Stomach *20*
  - Peptic ulcer *20*
  - Gastric carcinoma *23*
- Small intestine *27*
  - Tuberculous ulcer *27*
  - Typhoid ulcer *29*
- Large intestine *31*
  - Colon carcinoma *31*

Chapter 3: Liver 34–48
- Basic histological anatomy of liver *34*
- Fatty liver *35*
- Cirrhosis of liver *40*
- Metastatic carcinoma of liver *47*

Chapter 4: Kidney 49–62
- Large white kidney *49*
- Granular contracted kidney *52*
- Hydronephrosis *55*
- Polycystic kidney disease *57*
- Renal cell carcinoma *60*

Chapter 5: Male Genital System 63–67
- Carcinoma penis *63*
- Seminoma testis *64*
- Benign hypertrophy of prostate/benign prostatic hyperplasia *65*

Chapter 6: Female Genital System 68–73
- Leiomyoma of uterus *68*
- Carcinoma cervix *69*
- Dermoid cyst/benign cystic teratoma *72*

Chapter 7: Breast **74–77**
- Breast carcinoma *74*

Chapter 8: Bones and Joints **78–86**
- Sequestrum *78*
- Tuberculosis of spine (Pott's disease) *81*
- Giant cell tumor of bone *82*
- Osteosarcoma *84*

Chapter 9: Respiratory System **87–98**
- Lobar pneumonia of lung *87*
- Miliary tuberculosis of lung *90*
- Fibrocaseous tuberculosis of lung *90*
- Tuberculosis *91*
- Bronchogenic carcinoma *94*
- Bronchiectasis *97*

SECTION — II SLIDES **99–110**

Chapter 10: Pathology Practical Slides Identification **101–110**
- Acute appendicitis *101*
- Chronic cholecystitis *101*
- Colloid goiter *102*
- Capillary hemangioma *102*
- Cavernous hemangioma *102*
- Tuberculosis of lymph node *103*
- Tuberculosis of intestine *103*
- Adenocarcinoma *103*
- Secretory endometrium *104*
- Proliferative endometrium *104*
- Benign hypertrophy of prostate (BHP) *104*
- Lipoma *105*
- Cirrhosis of liver *105*
- Fatty liver *105*
- Mucinous cystadenoma of ovary *106*
- Basal cell carcinoma of skin *106*
- Squamous papilloma of skin *106*
- Squamous cell carcinoma of skin *107*
- Malignant melanoma of skin *107*
- Scirrhous carcinoma of breast *108*
- Fibroadenoma of breast *108*
- Renal cell carcinoma *108*
- Pleomorphic salivary adenoma *109*
- Seminoma testes *109*
- Giant cell tumor of bone *109*

- Osteosarcoma *110*
- Chronic lymphocytic leukemia (CLL) *110*
- Chronic myeloid leukemia (CML) *110*

Bibliography *111*

Index *113*

CHAPTER 2

Gastrointestinal Tract

Stomach

Before going into detail of description about the stomach specimens, we are briefly recapitulating the various parts of stomach, as it will help you to understand the site of involvement of diseases (Fig. 2.1).

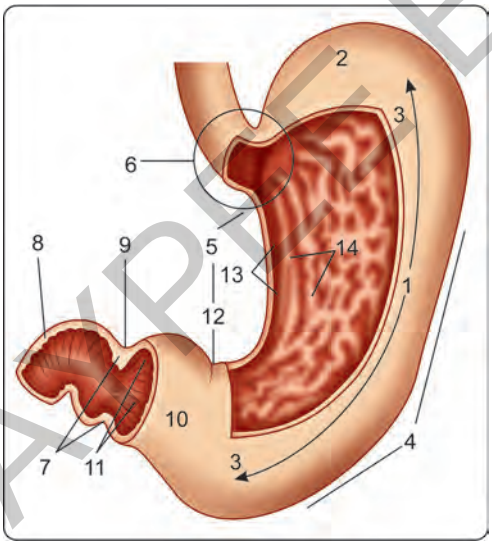

Fig. 2.1: 1. Body of stomach, 2. Fundus, 3. Anterior wall 4. Greater curvature, 5. Lesser curvature, 6. Cardia 7. Pyloric sphincter (valve), 8. Duodenum, 9. Pylorus, 10. Pyloric antrum, 11. Pyloric canal, 12. Angular notch, 13. Gastric canal, 14. Rugal folds

Peptic ulcer

Description

This is a specimen cut open along the greater curvature of stomach, showing mucosal ulcer with the following features:



Fig. 2.2: Peptic ulcer

JAYPEE BROTHERS

Features	Description
Location	Close to lesser curvature (95%)
Number	Usually single
Size	<2 cm in diameter
Shape	Oval/round
Margin	Sharply delineated
Edge	Thickened
Floor	Formed by serous/subserous layer and contains no muscle

– So, the above specimen is identified as "Peptic ulcer" (Fig. 2.2).

Why this is not a specimen of gastric carcinoma?

This is not a specimen of gastric carcinoma because in the ulcerative type of gastric carcinoma the following features are found:

Features	Description
Location	Greater curvature (most common)
Size	Usually >3 cm in diameter
Margin	Usually irregular
Edge	Thickened and everted
Floor	Formed by muscle layer

What are the sites where gastric ulcer may be found?

1. 1st part of duodenum (most common)
2. Stomach
3. Lower part of esophagus
4. Jejunum (after gastrojejunostomy)
5. Meckel's diverticulum (with gastric type of mucosa).

Describe the pathogenesis of peptic ulcer.

- Peptic ulcer is a complication of chronic gastritis.
- It is the result of a prolonged imbalance between the defensive and damaging forces of gastric mucosa and it arises when the damaging forces exceed the defensive ones.
- The pathogenesis of peptic ulcer is described below:

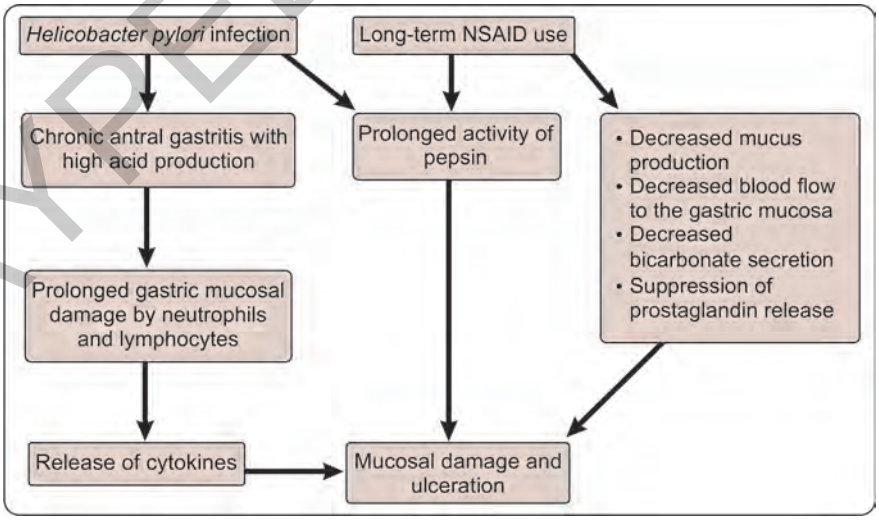

JAYPEE BROTHERS

What are the main causes of duodenal ulcers?

- Duodenal ulcers are more frequent in individuals with:
  1. Alcoholic cirrhosis
  2. Chronic obstructive pulmonary disease (COPD)
  3. Chronic renal failure
  4. Hyperparathyroidism.
- In the last two conditions, *hypercalcemia stimulates gastrin production* and therefore increases acid secretion.

What will be the morphology of the above specimen?

- The classic peptic ulcer is characterized by a *round to oval, sharply punched-out defect.*
- The mucosal margin is usually level with the surrounding mucosa.
- *Hemorrhage* and *fibrin deposition* are seen frequently.
- The *base of peptic ulcers is smooth and clean as a result of peptic digestion of exudate.*
- *In active ulcers the base is formed by [above to downwards*: (Fig. 2.3)]
  1. A predominantly neutrophilic inflammatory infiltrate
  2. A thin layer of fibrinoid debris
  3. Immature granulation tissue
  4. Fibrous tissue.
- Exposed blood vessels may be seen in the ulcer base, typically within the scarred area. The vessel walls are thickened and thrombus may be seen.

What are the complications of peptic ulcer?

1. Perforation and peritonitis: It is a medical emergency.
2. Hemorrhage (leading to hematemesis and melena).
3. Penetration of ulcer into the adjacent structures.
4. Obstruction (due to scar formation) leading to pyloric stenosis.
5. Malignant transformation (very rare).

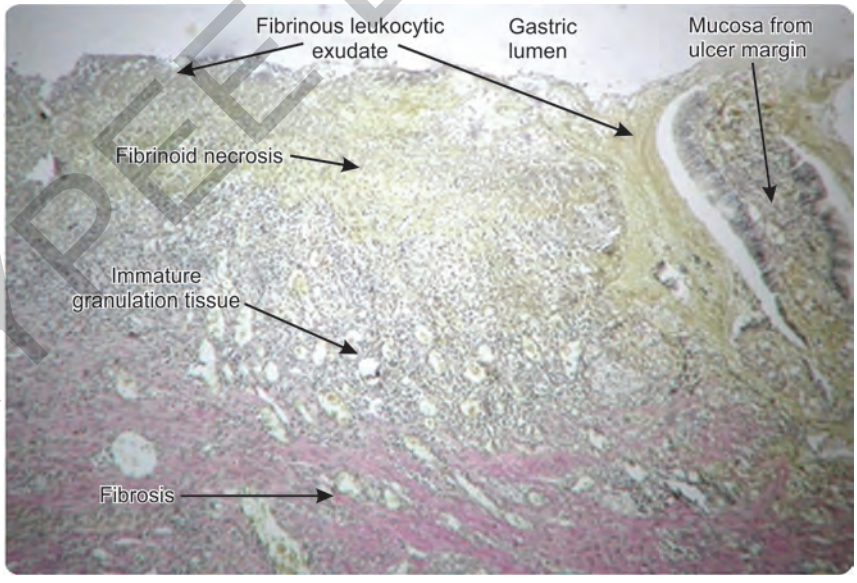

Fig. 2.3: Base of an active ulcer: Reproduced under the permission of Dr Mihai Danciu, Gr T Popa University of Medicine and Pharmacy, Iasi, Romania

JAYPEE BROTHERS

What are the common clinical symptoms of peptic ulcer?

Usually the patients of peptic ulcer come to attention for the following clinical symptoms:

- Epigastric pain: Burning/continuous dull pain; often periodic
- Vomiting
- Bleeding
- Perforation and peritonitis (if complicated).

How can you diagnose peptic ulcer?

1. An upper GI endoscopy (preferably a gastroduodenoscopy) is considered to be the most accurate diagnostic test for peptic ulcer disease and considered to be the "Gold standard" for this purpose.
2. A urea breadth test: It is based on the demonstration of ammonia produced by *H.pylori* from urea by the enzyme "Urease".
3. A barium X-ray to detect any abnormality in the upper GIT (ulcer/ tumor/ hernia/ pouch/ stricture/ swallowing difficulty, etc.).
4. An ELISA test to detect antibodies against *H.pylori* in blood (has the disadvantage of getting a high numbers of false-positive reactions).

Can you name some drugs to treat peptic ulcer?

Two most effective triple drug regimens approved by FDA are:

1. Clarithromycin + Amoxicillin + Lansoprazole/Omeprazole (proton pump inhibitors).
2. Bismuth subsalicylate + Metronidazole + Tetracycline (BMT).

What is the relation between blood group and peptic ulcer?

Peptic ulcer is common among Group O persons.

Gastric carcinoma

Description

This is a specimen of stomach showing the following features (As shown in the following table) and the above specimen is identified as 'Gastric carcinoma' (Fig. 2.4).



Fig. 2.4: Gastric carcinoma

JAYPEE BROTHERS

Types	Description of the growth
Ulcerative type	Present on pylorus. Usually >3 cm in diameter, with thick and everted edge and hard indurated base formed by muscle
Fungating type	Large, cauliflower-like growth projecting in the lumen from mucosa, may cause pyloric obstruction when present in pylorus
Infiltrating type (leather bottle stomach)	Whole stomach is affected, length and cavity are grossly reduced, prominent mucosal fold and thickened wall

What are the types of gastric carcinoma?

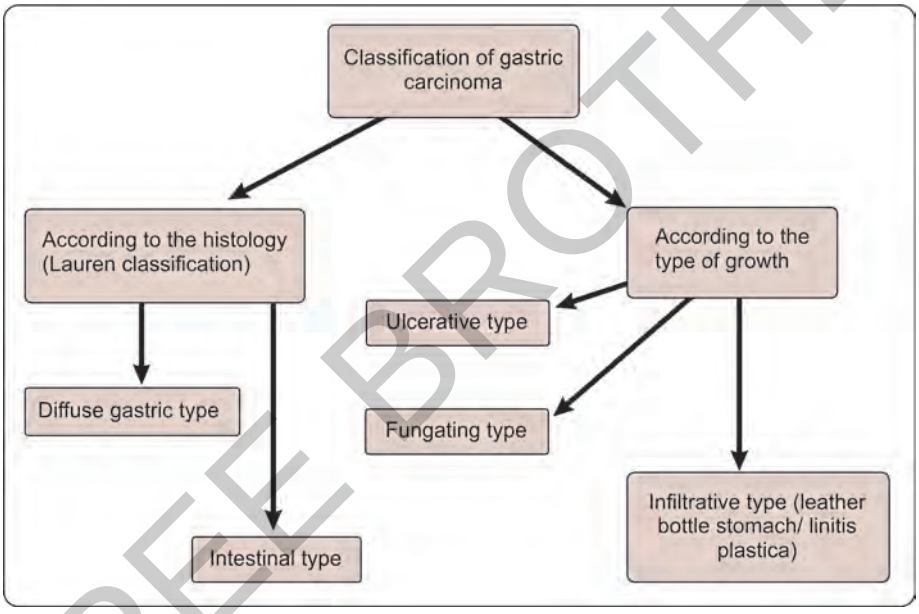

What is the pathogenesis of gastric carcinoma?

Pathogenesis of gastric carcinoma: Diffuse gastric type:

- E-cadherin is a protein that contributes to epithelial intercellular adhesion.
- Mutation in CDH1 gene (which codes E-cadherin) and subsequent loss of E-cadherin function seems to be a key step in the pathogenesis of diffuse gastric cancer.

Pathogenesis of gastric carcinoma: Intestinal type:

- Mutations/ microsatellite instability/ hypermethylation of various genes have been described in sporadic intestinal type gastric cancer:
  1. β-catenin
  2. TGFRII
  3. BAX
  4. IGFRII
  5. p16/INK4a.

JAYPEE BROTHERS

What will be the morphology of the above specimen?

Types of gastric CA	Diffuse gastric type	Intestinal type
Features		
Gross morphology	Diffuse infiltrative growth pattern	Bulky tumors, they typically grow along broad cohesive fronts to form an exophytic mass/an ulcerated tumor
Histology	They are generally composed of discohesive cells that do not form glands but instead have large mucin vacuoles that push the nucleus to the periphery, creating a *signet-ring cell morphology* (Fig. 2.5A)	They usually show a *glandular morphology*; often associated with intestinal metaplasia of the surrounding area (Fig. 2.5B)

It should be remembered at the very beginning that most of the gastric carcinomas involve the gastric antrum and that the lesser curvature is involved more often than the greater curvature.

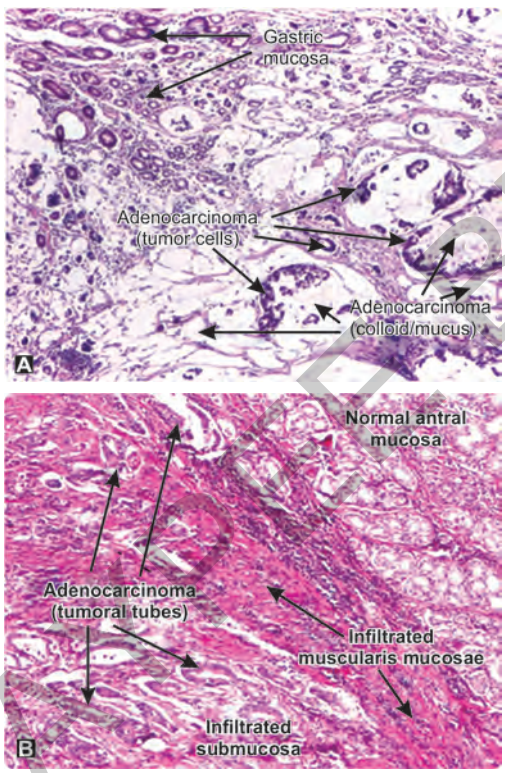

Figs 2.5 A and B: A. Morphology of diffuse type of gastric carcinoma: Presence of large amount of mucus and signet-ring cell morphology. B. Morphology of intestinal type of gastric carcinoma: Glandular morphology and intestinal metaplasia. Reproduced under the permission of Dr.Mihai Danciu, Gr T Popa University of Medicine and Pharmacy, Iasi, Romania

What is linitis plastica/ leather bottle stomach/ Brinton's disease/ diffuse stomach cancer?

It is a special type of stomach cancer characterized by involvement of the whole stomach, with a rigid and thickened wall caused by diffuse infiltration of the whole stomach by tumor cells and extensive fibrosis (Fig. 2.6).

Histologically, diffuse stomach cancer is characterized by a signet-ring cell morphology, caused by large mucin vacuoles pushing the nucleus to the periphery.



Fig. 2.6: Linitis plastica: Stomach opened longitudinally along the lesser curvature showing marked thickening of the gastric wall with mucosal congestion and decrease in rugal folds. Reproduced under the permission of Dr Andrew Ryan, MBBS, FRCPA

JAYPEE BROTHERS

Which other cancers may create a linitis plastica appearance?

Breast and lung cancers that metastasize to the stomach may also create a linitis plastica-like appearance.

How hypochlorhydria helps in carcinogenesis?

- In presence of hypochlorhydria, the growth of *H.pylori* in stomach is promoted.
- This organism reduces dietary nitrate to nitrite.
- Then they convert the dietary amines to N-nitroso compounds (in the presence of nitrites).
- These N-nitroso compounds are highly carcinogenic and they are thought to be an important link between *H.pylori* and gastric cancer.

How can you differentiate between them?

Points	*Ulcer cancer*	*Cancer ulcer*
Definition	It is malignant transformation of a pre-existing chronic peptic ulcer	It is ulceration of a previously existed carcinoma
Finding of an endoscopic biopsy from the corner along with the base of ulcer	Only 1 or 2 bits will show the evidence of carcinoma	All the bits will show the evidence of carcinoma

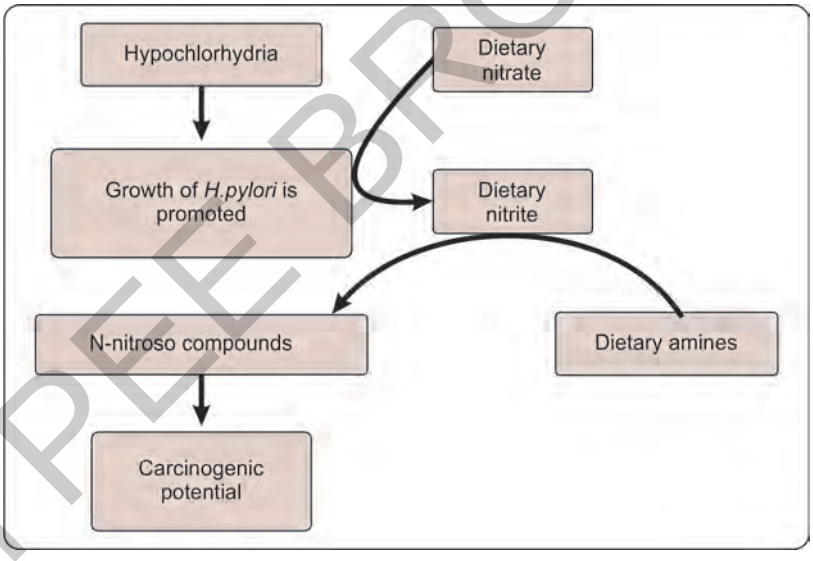

Name some common risk factors for gastric carcinoma.

1. Hypochlorhydria
2. *H.pylori* infection
3. Intestinal metaplasia.

What is the difference between ulcer cancer and cancer ulcer?

What are the modes of spread of gastric carcinoma?

1. Local spread.
2. Metastasis to the supraclavicular lymph node (also called Virchow's node).
3. Metastasis to periumbilical region to form a subcutaneous nodule, termed as Sister Mary Joseph nodule.

JAYPEE BROTHERS

4. Hematogenous spread to liver and lung.
5. Transcelomic spread to ovaries producing Krukenberg's tumor.

Small intestine

Tuberculous ulcer

Description

It is a specimen showing ulcer of the small intestine with:

Features	Description
Long axis	Transversely disposed
Edge	Ragged and irregular
Floor	Showing small protuberances with no congestion of surrounding tissue
Serous coat	Showing presence of tubercles

– So, the above specimen is identified as "Tuberculous ulcer of the small intestine" (Fig. 2.7).

What is the etiological origin of intestinal tuberculosis?

Intestinal TB is usually a form of secondary TB.

What are the various pathogenetic mechanisms of intestinal TB?

- Swallowing of infected sputum
- Dissemination of primary pulmonary tuberculosis
- Ingestion of nonpasteurized milk (contaminated with bovine tuberculosis).

Why TB ulcer is most common in terminal ileum and cecum?

1. TB ulcer occurs in the areas of Peyer's patches and lymphoid follicles. Both terminal ileum and cecum are very rich in both.
2. Movement of gut is sluggish in these parts, so bacteria gets more time to settle down here.

What are the different morphological types of tuberculous lesions found in the gut?



Fig. 2.7: Tuberculous ulcer

JAYPEE BROTHERS

There are mainly 2 morphological types of intestinal TB:

A. Ulcerative type
B. Ulcerohypertrophic type.

It should be mentioned that there are no sharp differences between ulcerative and ulcerohypertrophic lesions and the two can occur at the same time.

Types of the lesion	Features
Ulcerative type (60%)	• Diseased areas are moderately indurated • Mesenteric fat is increased and mesenteric lymph nodes are enlarged • The circumference of the ulcer is studded with nodules of variable size • Characteristically, the established lesion consists of an *annular ulcer involving the entire circumference of a segment* and generally < 3 cm in length • The lumen in the affected region is markedly narrowed, often resulting in a stricture
Ulcerohypertrophic type (30%)	• Ulcerohypertrophic lesions usually affect the ileocecal region, the patient presenting with a large lump in the right iliac fossa • The ileocecal angle is distorted and often obtuse • *On opening, the wall is seen to be markedly thickened* (because of hypertrophy) • Mucosal changes are: a. Cobblestoning b. Pseudopolyposis c. Flattening of mucosal folds

What are the common complications of a TB ulcer?

1. Acute or chronic obstruction from stricture, adhesions or both is the most common complication.
2. Perforation with peritonitis, usually in the ileum proximal to a stricture.
3. Fistulae between loops of bowel/ between the bowel and the skin/ between adjacent organs.
4. Malabsorption from lymphatic obstruction.

What are the clinical presentations of intestinal TB?

- Abdominal pain and distension
- Fever
- Diarrhea
- Weight loss
- Obstruction
- Melena (bleeding from upper GI tract)
- A palpable mass in the abdomen
- Anorexia
- Night sweats.

Why TB ulcers are uncommon nowadays?

The incidence of primary intestinal TB has become very rare nowadays primarily due to control of bovine TB by pasteurization of milk.

JAYPEE BROTHERS

Typhoid ulcer

Description

- This is a specimen of small intestine wall.
- Centrally there is a well-circumscribed raised ovoid lesion in longitudinal alignment, interpreted as an ulcerated Peyer's patch (unlike in tuberculous ulceration, in which the ulcers are arranged with their long axes transverse to the length of the bowel).
- A similar small rounded lesion is present at the lower-end of the specimen and still smaller nodules are scattered throughout.

Features	Description
Long axis	Oriented parallel to the long axis of the gut (longitudinally)
Shape	Oval
Edge	Regular, edematous, congested and raised
Floor	Pitted
Serous coat	Congested and having no tubercle

  - So, the specimen is identified as "Typhoid ulcer" (Figs 2.8 and 2.9).



Fig. 2.8: Typhoid ulcer of small intestine. Reproduced under the permission of Department of Clinical Laboratory Sciences, University of Cape Town, South Africa



Fig. 2.9: Typhoid ulcer

What are the different phases of evolution of typhoid ulcer?

Phases	Features
Phase 1	*Hyperplasia* of lymphoid follicles
Phase 2	*Necrosis* of lymphoid follicles during the 2nd week involving both mucosa and submucosa
Phase 3	*Ulceration* in the long axis of the bowel with the possibility of perforation and hemorrhage
Phase 4	*Healing* takes place from the 4th week onward, and unlike tuberculosis of the bowel with its encircling ulcers, does not produce strictures

Describe the pathogenesis of typhoid ulcer.

- After being ingested, the organism *Salmonella typhi* reaches the small intestine, penetrates the mucosa and carried to the Peyer's patches of the lower small intestine.

JAYPEE BROTHERS

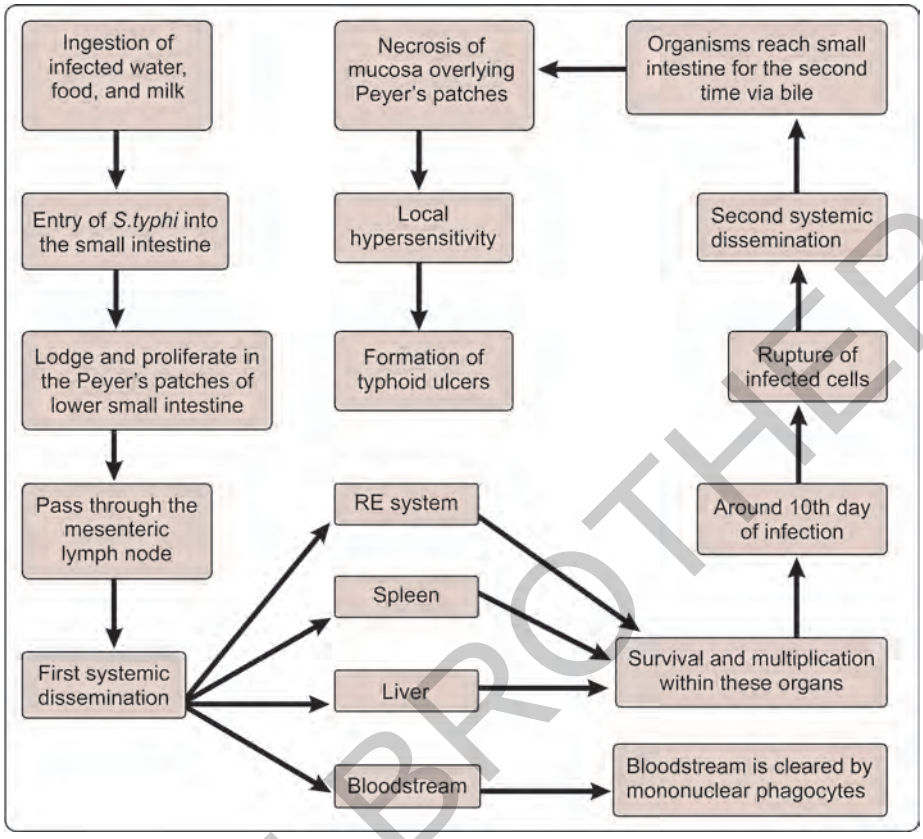

- Here they proliferate because of their special intracellular survival capability within the phagocytes and after passing through the mesenteric lymph nodes, they finally flood the bloodstream causing a systemic dissemination to the liver, spleen, and reticuloendothelial system.
- The bloodstream is immediately cleared by mononuclear phagocytes, but by the special capability of the organism mentioned above, they survive within these organs.
- By about 10th day of infection (varying from 1–3 weeks), the infected cells rupture and the bloodstream is flooded with large number of bacteria. This is the end of incubation period and the patient becomes seriously ill with septicemia.
- As the organisms reach the small intestine second time through bile, local hypersensitivity leads to necrosis of mucosa overlying Peyer's patches and results in formation of ulcer.

What is the most important histologic feature of a typhoid ulcer?

Presence of large number of macrophages, instead of neutrophils.

What is the most dangerous complication of a typhoid ulcer?

- In the 2nd or 3rd week of the illness, if the patient presents with severe generalized abdominal pain, it indicates a perforated typhoid ulcer.
- The patient will show classical features of peritonitis. (Abdominal pain, distension, fever, nausea, vomiting, loss of

JAYPEE BROTHERS

appetite, diarrhea, thirst, low urine output, and constipation).

- So, any patient being treated for typhoid fever who shows a sudden deterioration accompanied by abdominal signs should be considered to have a typhoid perforation until proven otherwise.

What are the different lesions found in complicated typhoid fever?

Organs	*Lesion*
Intestine	Typhoid ulcer
Gallbladder	Cholecystitis
Liver	Typhoid nodules: Small, randomly scattered foci of parenchymal necrosis in which hepatocytes are replaced by macrophage aggregates
Spleen	Congestion and splenomegaly
Bones	Osteomyelitis
Skin	Typhoid rash
Respiratory system	Bronchitis and bronchopneumonia
Bone marrow	Suppression of leukopoiesis
Heart	Toxic myocarditis
CNS	Meningitis

Large intestine

Colon carcinoma

Description

It is a specimen of proximal colon showing polypoid, exophytic masses that extend along one wall of the large-caliber cecum and ascending colon.

- So, this specimen is identified as colon carcinoma (Fig. 2.10).



Fig. 2.10: Carcinoma of colon. Specimen of a part of colon: Lower part of it is cut open to show a projecting fungating polyploid growth (arrows) with glistening surface

JAYPEE BROTHERS

What is the pathogenesis of colon cancer?

The pathogenesis of colon carcinoma has 2 pathways:

A. The classical adenoma-carcinoma sequence pathway (Fig. 2.11)
B. The microsatellite instability pathway (Fig. 2.12).
   – Both are being discussed briefly here in diagrams.

What is the morphology of colon carcinoma?

1. The tumors are composed of tall columnar cells.
2. The invasive component of these tumors elicits a strong stromal desmoplastic reaction, which is responsible for the characteristic firm consistency of the tumor.
3. Glandular morphology with abundant mucin production is associated with poor prognosis.

What are the most common sites of metastasis?

- As a result of portal drainage of the colon, liver is the most common site of metastatic lesions.
- But metastases may also involve the following structures:
  1. Regional lymph nodes
  2. Lungs
  3. Bones.

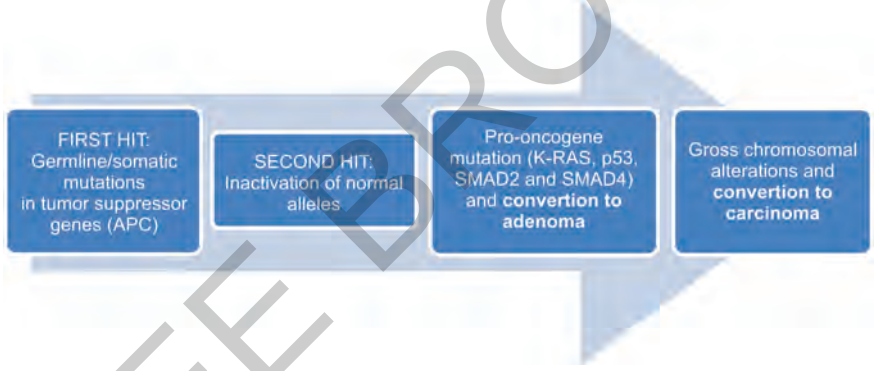

Fig. 2.11: The adenoma-carcinoma pathway

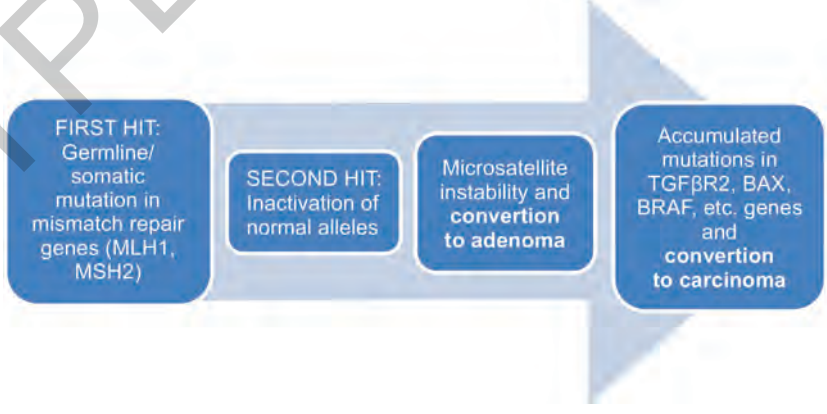

Fig. 2.12: The microsatellite instability pathway

JAYPEE BROTHERS

What are the most common presenting features of colon carcinoma?

Colon cancers	Presenting features
Right-sided	Fatigue and weakness due to iron deficiency anemia
Left-sided	• Occult bleeding • Changes in bowel habits • Cramping left lower quadrant discomfort

Is "Beta catenin" gene mutated in colon cancer?

- The "Beta catenin" commonly mentioned in CA colon is actually the Beta catenin protein, not the Beta catenin gene.
- Mutations in the APC gene in CA colon (the adenoma carcinoma sequence pathway) causes accumulation of Beta catenin protein within the cell cytoplasm, which leads to persistent activation of a transcription factor named TCF within the nucleus. Beta catenin gene is never mutated in colon cancer.
- This causes abnormal cell proliferation and eventually leads to tumor formation.

In which cancers, the Beta catenin gene is actually mutated?

Mutations in Beta catenin gene are commonly associated with:

a. Hepatoblastoma
b. Hepatocellular carcinoma.

Name some of the genes which are mutated in colon cancer.

Types of colon cancer	Genes which are mutated
Hereditary colon cancer	• APC • Mismatch repair genes
Sporadic colon cancer	• MYC • K-RAS • SRC • erbB2 • P^{53} • APC • Mismatch repair genes

JAYPEE BROTHERS

or detailed information on pathology books, visit our website **www.jaypeebrothers.com**, for detailed information on pathology books, visit our webs

A Practical Handbook of

PATHOLOGY

Specimens and Slides

This book is a supplement must for every 2nd professional MBBS student as the pathology specimens and slides are the most important part of the viva examination and often asked in details.

Salient Features

- A concise supplement in simple language
- Comprehensive description of important pathology specimens and in depth discussion of all the relevant topics
- Illustrative charts, tables and diagrams which will help students understanding the relatively hard topics with ease
- A rapid review of all the important topics of systemic pathology which will help PG aspirants to complete a huge portion of systemic pathology in a very short period of time
- Over 100 high quality digital photographs of specimens and slides which will help students getting a strong platform of basics of systemic pathology.



Prithwiraj Maiti is presently a student at the RG Kar Medical College and Hospital, Kolkata, West Bengal, India studying in final year. Besides his academic activities, he is running a well known online organization for preparation of postgraduate entrance examinations named Pgblaster India. He is determined to change the way of digital medical education and broaden different aspects of this new horizon. He is actively involved in free online medical contents creation. Now he is indulged in his 2nd book, *An Ultimate Guide to Community Medicine* with his fellow batchmate Bismoy Mondal, which is on the way of publishing in a few days.

Available at all medical book stores
or buy directly from Jaypee Brothers through online shopping
at www.jaypeebrothers.com

JAYPEE BROTHERS
Medical Publishers (P) Ltd.
www.jaypeebrothers.com

Join us on facebook.com/jaypeebrothers

Shelving
Recommendation
PATHOLOGY

ISBN 978-93-5152-414-4

9 789351 524144