website www.jaypeebrothers.com, for detailed information on dental books, visit our website www.jaypeebrothers.com

Editor **Prashant Babaji**

Foreword **VV Subba Reddy**



CROWNS IN PEDIATRIC DENTISTRY






Contents

1. Introduction and Historical Developments **1**

Prashant Babaji

Historical developments in Pediatric crowns *2*

2. General Considerations **4**

Prashant Babaji, Shashikiran ND

Importance of Restoring Primary Teeth *4*

Materials and Equipment *8*

Isolation Procedure: Rubber Dam Application *10*

Cementation/Cements Used for Cementation of Crowns *16*

3. Different Crowns Used in Pediatric Dentistry **21**

Prashant Babaji, Jalarak C Patel, Poonacha KS, Anju Bansal, Raghavendra Shetty

Classifications of Crowns *21*

Restoration of Severely Decayed Tooth with Post and Core *21*

Full Coronal Restorations in Children *22*

All Metal Crowns *23*

Jalarak C Patel, Poonacha KS, Raghavendra Shetty

Composition of Crowns *23*

Stainless Steel Crowns *23*

Ion Crowns/Nickel-Chromium Crowns *25*

Clinical Procedures for SSC *34*

Reduction of Tooth *39*

Crown Adaptation *43*

Response of Gingival Tissues to Stainless Steel Crown Restoration *51*

Anterior Stainless Steel Crowns *67*

Aluminum Crowns *70*

SSC With Facing/Open Faced Stainless Steel Crown/Chairside Veneered SSC *72*

Veneering Technique for Anterior Stainless Steel Crown *73*

Composite Veneering of Primary Molar SSC *74*

Resin Crowns/Composite Crowns *75*

Composite Strip Crown for Anterior and Posterior Teeth *75*

Composite Shell Crowns *83*

New Millennium Crown *84*

Glass Ionomer Crown *84*

Polycarbonate Crown *85*

Kudos Crowns *88*

PedoNatural Crown *90*
Anju Bansal
Pedo Jacket Crown *93*
Artglass Crowns/Glastech Crowns *94*
Preveneered Stainless Steel Crowns *97*
NuSmile Crowns *100*
Flex White Faced Pediatric Crown *103*
Pedo Pearls (Aluminum Crowns with Facing) *104*
Cheng Crown *107*
Whiter Biter Crown *109*
Pedo Compu Crown *109*
High Density Polyethylene Veneered Crowns For Children *110*
Dura Crowns *110*
All Ceramic/Porcelain/Zirconia Jacket Crown *111*
ZIRKIZ Crowns *111*
EZ-crown *113*
Kinder Krowns *115*
Cerec Crowns-All Ceramic Crowns—CAD/CAM System *119*
Ceramo Base Metal Crown *121*
Biologic Crown *122*
Limitations *122*
Tooth Preparation *122*
Fabrication of Crown Portion *122*
Radiographic Evaluation *123*
Cementation of Biologic Crown *123*

4. Restoration of Destructed Primary Teeth with Post and Core **125**
Prashant Babaji, Vishwajit Rampratap Chaurasia, Ranjithkumar Rampratap Chaurasia, Vinaykumar S Masamatti, Vikram Shetty K
Management of Severely Damaged Teeth *125*
Post Space Designs *127*
Different Types of Posts *127*

5. Management of Complications **133**
Prashant Babaji, Senthilnathan S, Nitin Sharma, Suresh BS
Crown Tilt *133*
Interproximal Ledge *133*
Poor Margins *133*
Over Extension of the Crown *134*
Ingestion/Inhalation of Crown *135*
Obstructed Airway in Children *136*

6. Tables and Charts **141**
Prashant Babaji
Crown Order Forms *146*

Index *153*

CHAPTER 2

General Considerations

Prashant Babaji, Shashikiran ND

JAYPEE BROTHERS

IMPORTANCE OF RESTORING PRIMARY TEETH

Although advances in the application of preventive dentistry techniques, widespread acceptance of community fluoridated water and increased dental education in parents have reduced the incidence of caries in children, there is still a high prevalence of early childhood caries especially in the lower socioeconomic population. Clinically early childhood caries proceeds from early involvement of maxillary incisors to other teeth leading to rapid spread and destruction of other teeth if neglected.

Esthetic treatment of severely decayed anterior primary teeth is one of the greatest challenges to pediatric dentists. In the last half of century the emphasis on treatment of extensively decayed primary teeth shifted from extraction to restoration. Early restorations consisted of placement of stainless steel bands or crowns on severely decayed teeth. While functional, they were unesthetic and their use was limited to posterior teeth. Over the last two decades there has been an explosive interest by adults in esthetic restoration of their compromised dentition. Similarly, a higher esthetic standard is expected by parents for restoration of their children's carious teeth. Esthetic full coverage restorations are available for anterior and posterior primary teeth, which preserve the functions of primary teeth until their exfoliation in healthy state.

Maintenance of primary dentition in a healthy condition is important for the well-being of the child as far as proper masticatory, esthetics; phonetics, space maintenance (Flow chart 2.1) and prevention of aberrant habits are concerned. The major issues of these problems are the development of abnormal oral habits, psychological problems, reduced masticatory efficiency and loss of vertical dimension of occlusion. Owing to these problems, it becomes more important to restore the destroyed crowns to preserve the integrity of the primary dentition until its exfoliation and eruption of permanent teeth. Numerous treatment approaches have been proposed to address the esthetics and retention of restorations in primary teeth such as stainless steel crown, open-faced SSCs, strip crown, PVSSCs, polycarbonate crowns.

Importance of Primary Teeth (Flow Chart 2.1)

Crown may be used on primary teeth in order to:

- Preserve the primary teeth until exfoliation
- Maintain masticatory function
- Maintain esthetic function.

FLOW CHART 2.1 Importance of primary teeth

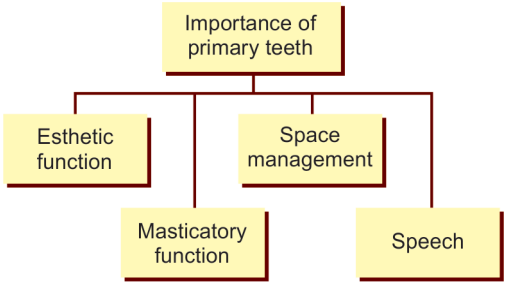

Instructions to Child and Parents after Placement of Crown

Care for Crown

- Avoid sticky, chewy foods (for example, chewing gum, caramel), which have the potential of grabbing and pulling off the crown.
- Minimize use of the side of your mouth with the temporary crown. Shift the bulk of your chewing to the other side of the mouth.
- Minimize chewing hard foods (such as raw vegetables), which could dislodge or break the crown.
- Slide flossing material out-rather than lifting out-when cleaning your teeth. Lifting the floss out, as you normally would, might pull off the temporary crown.

Instructions after Crown Delivery

Discomfort or sensitivity: Newly crowned tooth may be sensitive immediately after the procedure as the anesthesia begins to wear off. If the tooth that has been crowned still has a nerve in it, patient may experience some heat and cold sensitivity. Advice to brush teeth with toothpaste designed for sensitive teeth. Pain or sensitivity that might occur on biting usually means that the crown is too high on the tooth.

Chipped crown: Crowns made up of all porcelain or SSC with facing can sometimes chip. If the chip is small, a composite resin can be used to repair the chip with the crown remaining piece. If the chipping is extensive, the crown may need to be replaced.

Loose crown: Sometimes the cement washes out from the crown. Not only does this allow the crown to become loose, it allows bacteria to leak in and cause decay to the tooth that remains. If a crown feels loose, advise to visit dentist

Crown falls off: Sometimes crowns fall off. Usually this is due to an improper fit, a lack of cement, or a very small amount of tooth structure remaining that the crown can hold on to. If this happens, instruct parents to report to dentist with the crown

Allergic reaction: Because the metals used to make crowns are usually a mixture of metals, an allergic reaction to the metals or porcelain used in crowns can occur, but this is extremely rare. Instruct patient to visit dentist if so.

Dark line on crowned tooth next to the gum line: Instruct child that a dark line next to the gum line of crowned tooth is normal, particularly if a veneered SSC crown is used. This dark line is simply the metal of the crown showing through.

Tooth exfoliation: Crowned tooth exfoliates in a similar manner as that of uncrowned tooth.

General Considerations during Crown Placement

Aseptic Technique

Prevention of disease transmission during and after temporary restoration is required, as it is necessary for all intra-oral procedures. Infection control guidelines for dental offices that have been published by the Center for Disease Control should be followed. Personal protection and barrier protection measures should be followed (e.g. gloves, mask, protective eye wear and lab coat). Cross-contamination should be avoided. Do not touch instruments, areas which have not been sterilized or disinfected. Practice proper hand washing techniques, properly clean, disinfect or sterilize all instruments and equipment.

JAYPEE BROTHERS

Occlusion

Before tooth preparation and crown adaptation check for occlusion. Occlusion is the contact of the mandibular teeth against the opposing maxillary teeth during functional and non-functional movement of the mandible. The static position of the bite is called centric occlusion. Check for incisor, canine and molar relationships.

Sensitivity

Following vital tooth preparation, dentine will be exposed resulting into sensitivity of tooth hence prepared tooth should be covered with varnish before crown cementation.

Gingival Health

There are chances of gingival laceration during tooth preperation which will heal in due time. Gingival inflammation and recession occurs if crown is not properly adapted or irritating cement left after cementing crown. Food impaction occurs if contact areas left open. Hence care should be taken to remove excess cement, crimp the crown for close adaptation, and maintain proximal contact by proximal contouring the crown or by adding solder.

Fracture of Prepared Tooth

If tooth left without crown after preparation for many days then there is chance of tooth fracture. Hence cement the crown in the same visit.

Finish Lines

The finish line is a continuous edge that borders the entire preparation commonly the location where the bur stops. It is essential that you have a mental image of the location and contour of a preparation's finish line in order to contour a temporary restoration for that tooth.

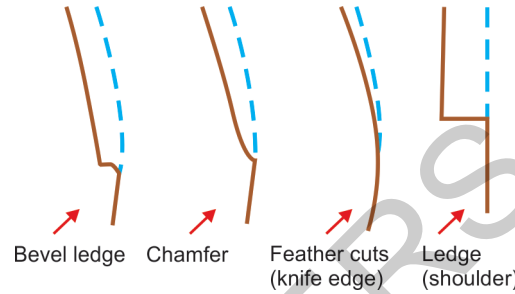

FIGURE 2.1 Gingival finish lines (bevel, Chamfer, feather/knife edge and ledge formation)

Four common forms of finish lines are (Fig. 2.1):

1. Bevel or slant
2. Chamfer or slope
3. Feather or knife edge (a shallower slope)
4. Shoulder or ledge.

When a preparation is cut, the circumference of the tooth either increases or remains the same with the finish line always at the greatest circumference. This shape permits easy placement and removal of a restoration. *Knife edge/feather finish line* is used for primary tooth preparation for crown while shoulder and chamfer finish line for permanent since there is increased cervical constriction in primary teeth. The crown when well adapted, protects the finish line from chipping, and prevents marginal leakage of mouth fluids and bacteria, which could cause sensitivity and decay of the exposed dentin.

Differences between Primary and Permanent Tooth and Tooth Preparation (Fig. 2.2)

- Enamel and dentine are thinner in primary than permanent teeth hence decay spreads faster in primary compared to permanent. Since primary teeth have thinner enamel and dentin (about 1 mm each) extensive occlusal reduction is not indicated during tooth preparation. Hence, semi permanent crowns are used with minimal tooth

JAYPEE BROTHERS

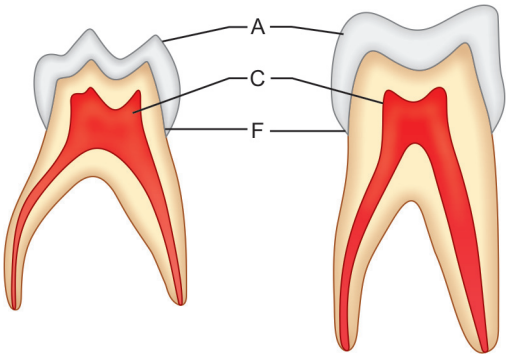

FIGURE 2.2 Differences between primary and permanent teeth [A: Enamel, C: Pulp, F: Dentin]

reduction such as stainless steel crowns, which has thickness of around 0.2 to 0.3 mm only.

- Primary tooth has prominent cervical convergence. Cervical bulge is used for crown retention. Since there is prominent cervical constriction, gingival seat of tooth preparation should be knife/feather edge as compared to shoulder for permanent.
- Root bifurcation starts immediately below cervical area.
- Narrow occlusal table compared to permanent.
- Enamel rods run downwards in permanent (needs beveling due to unsupported rods) and occlusally in primary (which does not leave unsupported rods).
- Pulp horns are more prominent in primary, hence excessive occlusal reduction is not indicated in vital tooth due to chances of pulpal exposure.

Ideal Requirements for Pediatric Crown

- Should be esthetically acceptable/should have natural color
- Should last until exfoliation of primary teeth (durable)
- Should be biocompatible and not irritant to gingiva
- Easily and rapidly placed
- Cost effective
- Should require one visit treatment
- Esthetic covering should not chip off while clinical manipulation or during use in oral cavity
- Should maintain tooth integrity
- Should maintain mesiodistal space until eruption of permanent teeth
- Should retain masticatory function
- Should not abrade opposing teeth.

Objectives of Crown Placement

- To repair or limit the damage from caries
- To protect and preserve tooth structure
- Reestablish adequate function
- Restore esthetics.

Indications

(According to the clinical guidelines for the American Academy of Pediatric Dentistry)

- Children at high risk with anterior and/or posterior decay
- Children with extensive decay
- Large lesions or multiple surface lesions
- Pulpally treated teeth
- Involved inscisal edge
- Extensive cervical caries
- Minimal caries but poor oral hygiene
- Difficult to control moisture due to child behavior management problems.

Other Indications

- Hypoplastic defects
- Significant tooth loss/fracture due to trauma
- Phychologic benefit
- Posterior crown for masticatory function and to maintain arch length
- Unesthetic incisors due to discoloration/ intrinsic stain.

JAYPEE BROTHERS

Contraindications

- Non restorable teeth
- Teeth which can be restored by conventional means.

Advantages

- Maintains esthetics of child
- Avoids development of psychological and functional problems due to loss of primary teeth
- Preserves arch length and space.

Crown Selection

Crown selection can be done by mainly three methods.

1. Selection before tooth preparation by measuring the mesiodistal dimension of tooth to be restored and comparing it with crown
2. Selection after tooth preparation
3. Trial error method

MATERIALS AND EQUIPMENT

Instruments and Others

- Diagnostic equipment—mouth mirror, explorer, probe, tweezer (Fig. 2.3)
- Crowns (Fig. 2.4)
- Cementing equipment—spatula (metal or agate), glass slab, cement mixing pad, cements, composite set (Figs 2.5 and 2.6A)
- Restorative instruments—plastic carrying
- Others—saliva ejector, retraction cord, gauze piece, cotton, vaseline, dental floss
- For tooth preparation—aerator handpiece, straight handpiece burs—round end taper, thin taper, flame-shaped burs (Figs 2.6B and 2.7)
- Finishing and polishing burs and wheels (Fig. 2.4)

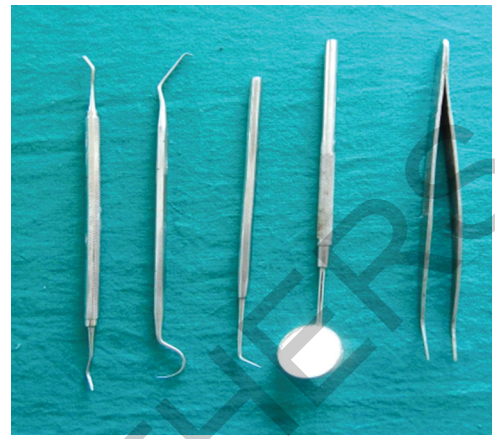

FIGURE 2.3 Diagnostic equipment



FIGURE 2.4 Different crowns and trimming burs



FIGURE 2.5 Different cements and other aids

- Pliers (Fig. 2.8)—crimping, contouring (ball and socket, Gordon pliers) crimping plier, Howe pliers (Fig. 3.10)

JAYPEE BROTHERS

1. **Contouring pliers (Fig. 2.8)**: Gordon pliers (No. 137) used for general contouring and shaping

   Johnson's Ball and socket contouring pliers (No. 800112): Used to improve contour at interproximal contacts and gingival margins for stainless steel and temporary crowns.
2. **Crimping pliers No. 800417, No. 800421**: Specially designed to crimp the gingival margin of SSC and temporary crowns (Fig. 2.8).
3. **Howe pliers (No. 110)**: Straight and curved pliers used to adjust proximal contact and contours (Figs 2.8 and 3.10).

- Scissors—straight, curved (Fig. 2.9)
- **Crown scissors (Fig. 2.9)**:
  A. Festooning-801203
  B and D. Curved scissor-801202
  C. Straight scissor-801201
  E. All-purpose scissors 230-212.

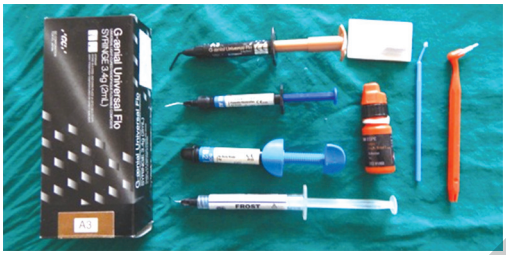

FIGURE 2.6A Composite kit

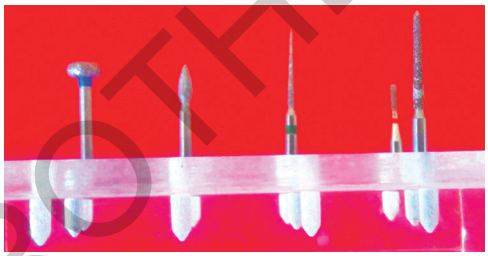

FIGURE 2.7 Various burs



FIGURE 2.6B Handpiece (arotor, straight), different tooth preparation burs (round, round end taper, thin taper, flame-shaped), Crown finishing and polishing burs

JAYPEE BROTHERS

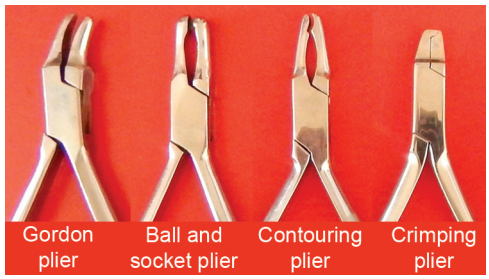

FIGURE 2.8 Crown adaptation pliers

ISOLATION PROCEDURE: RUBBER DAM APPLICATION

Rubber dam isolation method in pediatric restorative dentistry is strongly recommended during tooth preparation and crown placement for better access and visualization.

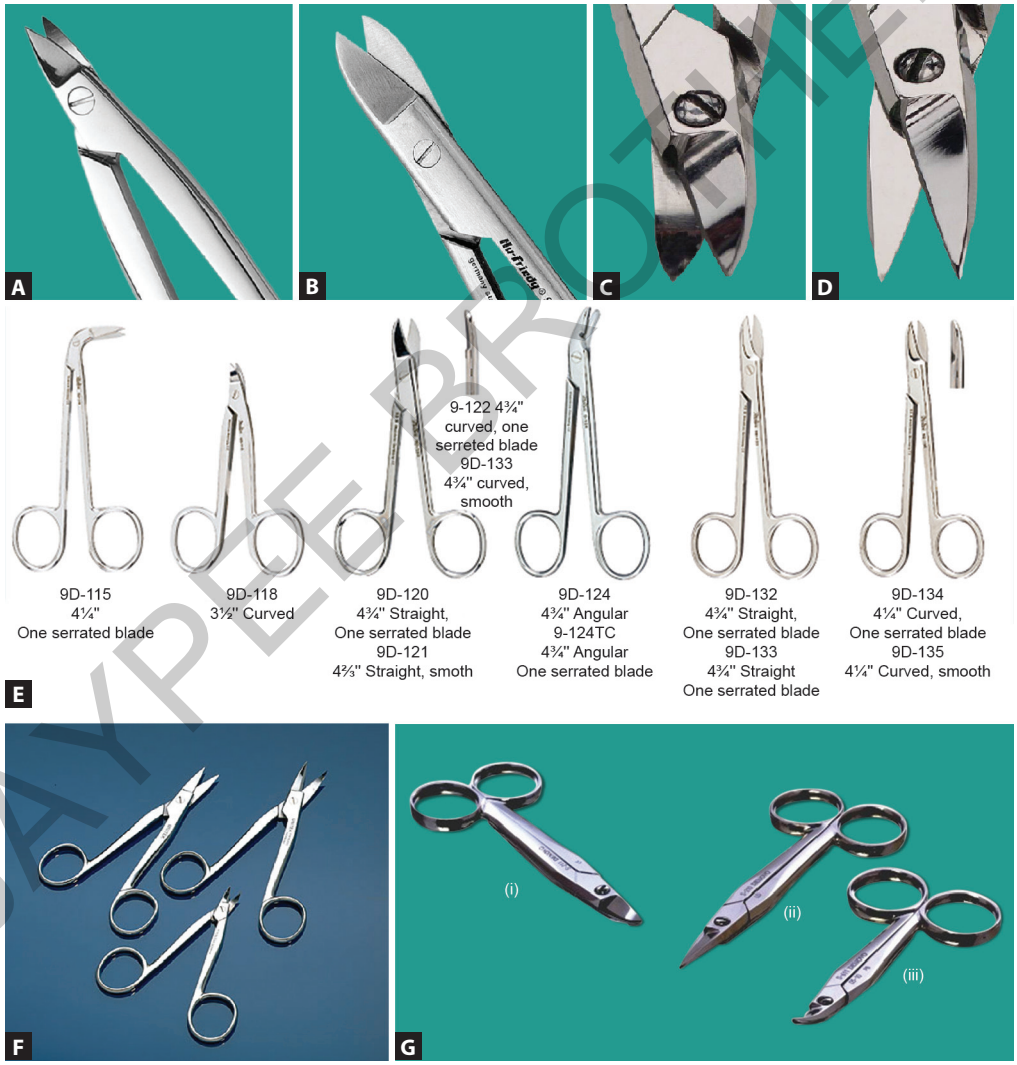

FIGURES 2.9A TO G Crown cutting scissors (Festooning, curved, starignt and all purpose scissors: (A) Festooning scissor; (B) Straight crown cut scissor; (C) Curved scissor; (D) All purpose scissor; (E) Crown cutting scissor; (F and G) Crown cutting scissors: (i) Curved festooning; (ii) Straight smooth; (iii) Curved

JAYPEE BROTHERS

Traditional Dental Dams

- Ash range (Ash Instruments Dentsply, Addlestone Surrey UK)
- Hygenic and Hu Friedy
- Coltene Whaledent
- Zirc
- Roeko
- Ivory by Heraeus Kulzer
- Ultradent

Other Dental Dams

- Optidam by Kerr
- Optradam by Ivoclar Vivadent

Advantages of Rubber Dam

- Better access and visualization of operating area
- Moisture control
- Protects soft tissue injuries by retraction
- Prevents aspiration of foreign bodies such as crown and smaller instruments
- Increases child cooperation
- Acts as barrier in preventing transmission of cross infection
- Enhances the effectiveness of nitrous oxide, when needed for behavior management, by forcing the child to engage in nasal breathing
- Provides clean and dry operatory area.

Indications

- For isolation
- Prevents aspiration of dental equipments and materials
- Prevention of cross infection
- For clear visualization of operatory area.

Contraindications

- Patient with upper airway problems, which restricts nasal breathing such as sinusitis
- Known allergy to latex
- Uncooperative patient.

Rubber Dam Apparatus (Figs 2.10A to F)

- Rubber dam sheet
- Rubber dam frame (metal or plastic)
- Rubber dam template
- Rubber dam punch
- Rubber dam forcep
- Rubber dam clamps (winged or wingless)
- Others—rubber dam napkin, lubricants, dental floss (Fig 2.10G).

Rubber Dam Sheet

One box contains 32 or 56 sheets. It is available as rectangular size (pre cut 150 mm squares) or roll type. It is available as different sizes (5 × 5 or 6 × 6 inch), thickness (thin, medium or thick, medium most commonly used for pediatric and endodontic procedures) and colors (green, blue, purple, black, grey, pink, purple, white and yellow) (Fig. 2.10A). Most rubber dams are made of latex although non latex rubber dams (Silicone versions) are also available. A size 5 × 5 inch medium gauge rubber dam is best suited for use in children. The darker the color, the better will be the contrast between the dam and the tooth. It has dull and shiny surfaces; dull surface should be towards operatory and shiny surface towards tissue. Rubber dam sheets are available in flavored to mask the latex taste. Rubber dam is also available as readymade disposable one as fast dam, quick

JAYPEE BROTHERS



FIGURES 2.10A TO I (A) Rubber dam sheet; (B) Rubber dam frame; (C) Template; (D) Punch; (E) Forcep; (F) Clamps; (G) Rubber dam napkin, dental floss, lubricants; (H) Fast dam, quick dam; (I) Different rubber dam frames (metal and plastic), forcep, punch

dam (Fig. 2.10H). The performance and quality of rubber dam is best where stock is not too old and has been stored in a cool, dry environment, preferably in refrigerator. Old stocks of rubber dam are more susceptible to tear.

Rubber Dam Frame

Rubber dam frames are available in plastic and metal and various sizes corresponding to the size of the dam (Figs 2.10E and I). It can be available as Young's type or Svenska N-O (oval shape) design. The frame is positioned on top of the dam so that the top edge of the dame coincides with the top of the frame arms. Plastic frame is helpful in taking radiographs, which does not interfere the radiographic interpretation.

Rubber Dam Template

This is white sheet showing the landmark areas of primary and permanent teeth for punching hole in rubber dam sheet (Fig. 2.10C).

Rubber Dam Punch (Figs 2.11A and B)

The holes for the teeth are punched on sheet with rubber dam punch so that the rubber dam sheet is centered horizontally on the face and the upper lip is covered by the upper border of the dam without blocking the nostrils. Punching the hole is depends upon the type and number of teeth to be isolated. The size 1 hole punch is used for the mandibular incisors, the size 2 hole punch is used for the maxillary incisors,

JAYPEE BROTHERS

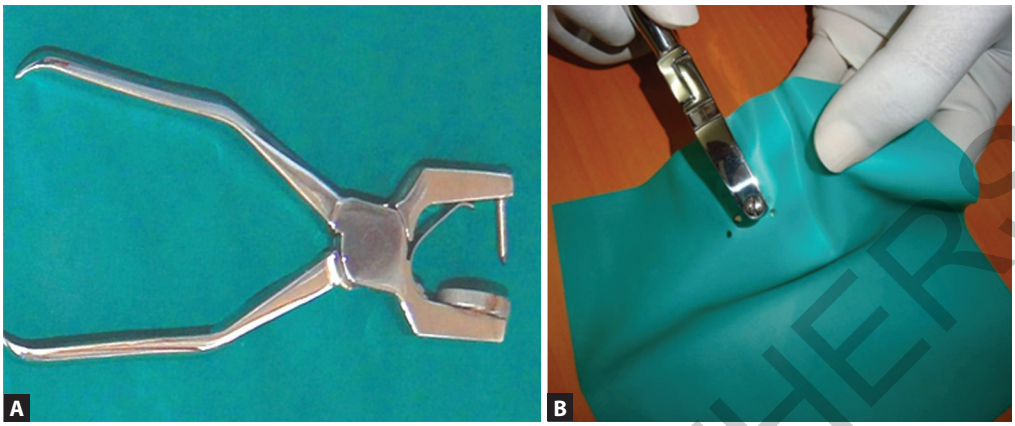

FIGURES 2.11A AND B (A) Rubber dam punch; (B) Method of punching the sheet

size 3 hole for canines and premolars, size 4 for molars (Fig. 2.10I).

Punch the minimum number of holes necessary to adequately isolate the tooth (Fig. 2.11B). While treating interproximal lesions adjacent teeth are also isolated. When isolating several teeth, cutting the interproximal dam material is advised to create a split (Fig. 2.14A).

Rubber Dam Forceps

It is used to hold, carry and remove clamps form tooth surface (Figs 2.10E and I). The rubber dam clamp forceps come in variety of designs. Most forceps designs include the University of Washingston/Stoke, Brewer (Ash, Dentsply, Wey-bridge, Surrey, UK) and Ivory (Heraeus Kulzer, South Bend, IN, USA) patters.

Rubber Dam Clamps (Fig. 2.12)

Rubber dam clamp selection is important for stabilizing the rubber dam. Clamps are classified as winged and wingless one. There are over 50 different designs of rubber dam clamps available. Clamps are available as labeled numerically, alphabetically or color coded. Each clamp consists of set of jaws connected by a bow (Figs 2.13A and B). There are clamps with asymmetric and serrated jaws to provide better anchorage to the tooth. The selected rubber dam clamp should achieve four-point jaw contact at the cervical region of the tooth. The clamp that is chosen will be dependent on the tooth to be isolated, the application technique and operators preference. Winged clamp allow more tissue retraction and one step application, whereas wingless clamps are used with the two step technique. Most rubber dam clamps are made of stainless steel but some are made from



FIGURE 2.12 Rubber dam clamps for primary molars and incisors

JAYPEE BROTHERS

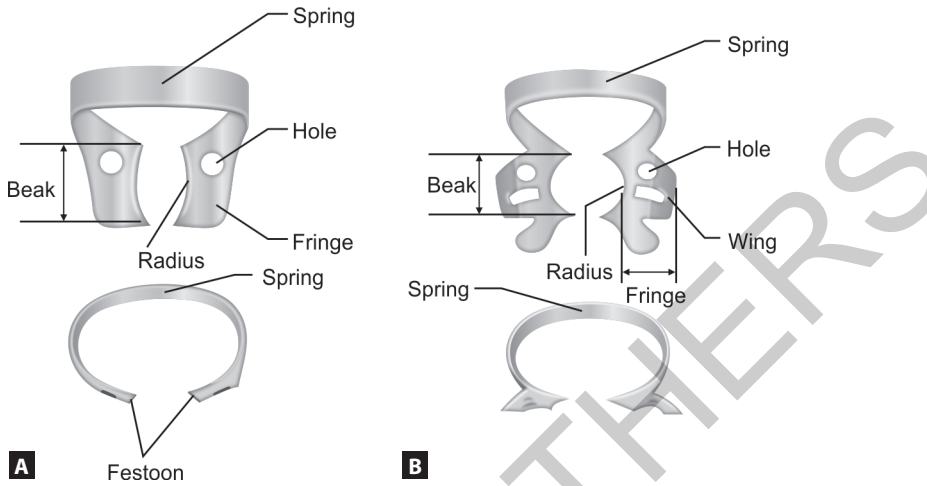

FIGURES 2.13A AND B Wingless (A) and winged (B) clamps

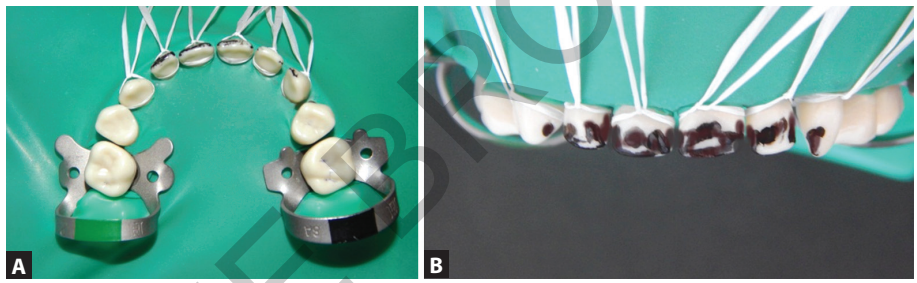

FIGURES 2.14A AND B Individual tooth isolation with rubber dam and securing with floss and clamp

plated steel (susceptible to corrosion). There are even non metallic clamps made of plastic (SoftClamp, KerrHawe, Bioggio, Switzerland). Clamps can also be classified as retentive or bland. Retentive clamps provide four point contact on the tooth.

Always while using rubber damp, it should be tied with dental floss to prevent from accidental swallowing. A 8 to 10 inch length of dental floss may be tied through one of the clamp holes, wound around the bow of the clamp and then passed through and tied to the opposite clamp hole. Some frequently used clamps used in pediatric dentistry are:

- **The 12A clamp** (*Ivory, Miles Inc., Dental Products, South Bend, IN*): It is for clamping the maxillary left second primary molar and the mandibular right second primary molar.
- **The 13A clamp** (*Ivory, Miles Inc., Dental Products, South Bend, IN*): It is for clamping the maxillary right second primary molar and the mandibular left primary second molar.
- **The 2A clamp** (*Ivory, Miles Inc., Dental Products, South Bend, IN; Hygienic Corp, Akron, OH*) for clamping the first primary molars.
- **The 14 clamp** for clamping fully erupted permanent molars
- **The 14A clamp** for clamping partially erupted permanent molars

After selecting the appropriate clamp place a 12 to 18 inch piece of dental floss on the bow

JAYPEE BROTHERS

of the clamp to aid in retrieval of the clamp, if it is dislodged from the tooth and falls into the posterior pharyngeal area.

Other Accessories (Fig 2.10G)

Rubber dam napkin: Rubber dam napkin can be placed between the dental dam and the patients face. This helps to absorb moisture and increase comfort for the patient.

Lubricants: Lubricant such as topical Ultradents or KY jelly can be placed on the underside of the dental dam for easier placement over the teeth and through the interproximal areas.

Rubber Dam Placement Techniques

The rubber dam during application in children should be introduced as any other routine dental procedure. The euphemism terms are used such as; "rain coat" for rubber dam sheet, "button" for clamp and " coat hanger" for frame. Proper local anesthesia should be administered to prevent uneasiness during rubber dam placement.

There are four techniques in rubber dam placement;

1. **Clamp first, then rubber dam:** First a well-fitted abutment tooth clamp is selected and then seated in place. Rubber dam sheet is placed after checking the stability of clamps place index fingers on the dam—buccally and lingually to the abutment hole, stretching the dam to an oval shape and passing it over the bow of the clamp and then over the wings. This method offers excellent visibility on tooth and clamp. Clamp securing, e.g. with dental floss is very important.
2. **Rubber dam first, then clamp:** The abutment hole is stretched in buccal-oral direction and then placed over the teeth till the gingival tissue is visible. The rubber dam is held in this position and an assistant can place clamp. Then the rubber dam can be released.
3. **Bow of clamp in the rubber dam:** The bow of the clamp is placed through the perforation. Then the rubber dam is gathered to one side and held with the hand, while the clamp is placed onto the tooth. Afterwards the rubber dam is placed onto the frame. This technique offers excellent view on the area where the clamp has to be placed.
4. **All in one:** This method involves pre-loading of a winged clamp onto the rubber dam. The perforated rubber dam is placed onto the frame. Then a winged clamp is placed into the opening engaging the wings of the clamp into it. Rubber dam and clamp are applied as a unit together. The "unit" is placed with the rubber dam forceps. Then the dam is slipped off the wings with a flat bladed instrument to the subclamp position. This technique can be accomplished without the aid of an assistant.

For Anterior Teeth

The two most popular techniques for isolating anterior teeth are individual tooth isolation and the split dam/trough technique.

Individual Tooth Isolation

The advantage of individual tooth isolation is that it provides greater deflection of gingival tissues and better moisture control. The disadvantages are ligature ties may cause bleeding of gingival tissues, inhibit rapid removal of the rubber dam and interfere with the placement and finishing of crowns.

The rubber dam is prepared by stretching the dam material over the frame and punching the appropriate number of holes in the dam material, as described earlier. The holes are stretched over the teeth so they poke through the rubber dam. The dam may be stabilized by placing a wooden wedge or a small piece of rubber dam material interproximally between the two teeth distal to the treated teeth. The teeth may be ligated by placing 12 to 18 inches of floss

JAYPEE BROTHERS

for detailed information on dental books, visit our website www.jaypeebrothers.com, for detailed information on dental bo

Crowns in Pediatric Dentistry

Salient Features

- Contains the uses of crowns in pediatric dentistry in concise manner
- Introduces the theoretical and clinical aspects of crown placement from the beginning
- Discusses the different types of crowns used for children. Each crown type is explained by indications, special features, availability, price and clinical procedures
- Covers both conventional and newer anterior and posterior crowns
- Explains restoration of destructed primary teeth and management of complications with crowns
- Includes numerous flow charts and tables for quick review
- Provides useful clinical information to pediatric dentists, general practitioners as well as undergraduate and postgraduate students.



Prashant Babaji did his MDS (2005) from Bapuji Educational Institute, College of Dental Sciences, Davangere, Karnataka, India. Presently, he is working as Professor and Postgraduate Teacher, Department of Pedodontics and Preventive Dentistry, Sharavathi Dental College and Hospital, Shivamogga, Karnataka, India. He has more than 10 years of teaching and clinical experience in pedodontics specialty. He has more than 50 Pubmed, Medline and international publications in various journals. He has done various research works and delivered guest lecturers in the field of dentistry.

Available at all medical bookstores
or buy online at www.jaypeebrothers.com

JAYPEE BROTHERS
Medical Publishers (P) Ltd.
www.jaypeebrothers.com

Join us on facebook.com/JaypeeMedicalPublishers

Shelving Recommendation
DENTISTRY

ISBN 978-93-5152-439-7