otolaryngology books, visit our website **www.jaypeebrothers.com,** for detailed information on otolaryngology books

JAYPEE

CURRENT CONCEPTS OF OTITIS MEDIA & RECENT MANAGEMENT STRATEGIES



Editors
Anand Job
L Paul Emerson

Forewords
Mohan Kameswaran
Ravi Ramalingam
Sunil Chandy

Contents

1. History of Otitis Media **1**
L Paul Emerson, Anand Job

2. Anatomy and Physiology of the Middle Ear **3**
L Paul Emerson, Anand Job

- Endoscopic Anatomy of the Middle Ear Spaces *4*
- Sound Transmission *8*
- Ossicular Coupling *9*

3. Eustachian Tube and its Role in Otitis Media **10**
Anand Job, L Paul Emerson

- Role of the Eustachian Tube in Chronic Otitis Media, Mucosal Disease *10*
- Evolution Effects on Immune System and on Eustachian Tube Function *10*
- Anatomy and Prenatal Growtht *10*
- Histopathology of Mucous Membrane of Tubal Lumen *11*
- Physiology of the Eustachian Tube *13*
- Tests of Eustachian Tube Function *18*
- Treatment *23*
- Management *25*

4. Acute Otitis Media **29**
L Paul Emerson, Anand Job

- Clinical Diagnosis *30*
- Contribution of Acute Otitis Media to Chronic Otitis Media *32*

5. Chronic Otitis Media Associated with Effusion **36**
L Paul Emerson, Anand Job, John Mathew

- Classification of Post-Tympanostomy Tube Otorrhea *39*

6. Chronic Otitis Media **43**
L Paul Emerson, Anand Job

7. Chronic Otitis Media-Mucosal Disease **47**
Anand Job, L Paul Emerson

- Etiopathology *47*
- Bacteriology *47*
- Investigations *48*
- Medical Treatment *48*

8. Microbiology of Acute Otitis Media **51**
Shalini Anandan, L Paul Emerson, Anand Job

9. Microbiology of Chronic Otitis Media **53**
Shalini Anandan, Anand Job, L Paul Emerson

10. Pathophysiology of Chronic Otitis Media **55**
Anand Job, L Paul Emerson

- Role of Inflammatory Mediators in the Pathogenesis of Otitis Media and their Sequelae *56*

11. Prevention of Acute Otitis Media **59**
L Paul Emerson, Anand Job

- Approach to the Child with Recurrent Infections *59*
- Predisposing Factors *60*
- "Normal" Child *60*
- Child with Atopic Disease *61*
- Child with Chroknic Disease *62*
- Child with an Immunodeficiency *62*
- Management of Allergy *65*

12. Vaccination for Preventing Acute Otitis Media **69**
L Paul Emerson, Anand Job

- Prevention of Recurrent Acute Otitis Media *69*
- Vaccine Schedule *70*

13. Eosinophilic Otitis Media **72**
L Paul Emerson, Anand Job

- Clinical Features *72*

14. Preoperative and Intraoperative Considerations **76**
Anand Job, L Paul Emerson, John Mathew

- Factors that Affect Surgical Decisions *76*

15. Classification of Tympanoplasty **81**
Anand Job, L Paul Emerson, John Mathew

- Classification of Tympanoplasty *82*

16. Local Anesthesia for Middle Ear Surgery **84**
L Paul Emerson, Anand Job

- Premedication *84*
- Adverse Effects of Lidocaine *86*
- Adverse Effects of Bupivacaine *87*

17. Approaches for Tympanoplasty **88**
L Paul Emerson, Anand Job, John Mathew

- Transcanal Approach for Myringoplasty *88*
- Endaural Approach *88*
- Retroauricular Approach *88*

2 Anatomy and Physiology of the Middle Ear

L Paul Emerson, Anand Job

INTRODUCTION

The middle ear (ME)-conducting apparatus for hearing consists of the tympanic membrane (TM) and the three ossicles **(Fig. 1)**.

Tympanic Membrane

The orientation of the TM is slightly oblique to the sagittal plane. It is roughly conical in shape and pointing medially. The handle of malleus is attached to the medial aspect of the TM. The TM is divided into the pars flaccida, which is superior to the insertion of the manubrium and inferiorly, the pars tensa. The inferior end of the manubrium is called the umbo.

Malleus

The manubrium or handle of malleus is attached to the pars tensa. It has an anterior process and lateral process. The head, which articulates with the incus, is in the epitympanic recess. The constriction between the manubrium and the head is called the neck of the malleus. The chorda tympani cross the medial surface of the malleus neck.

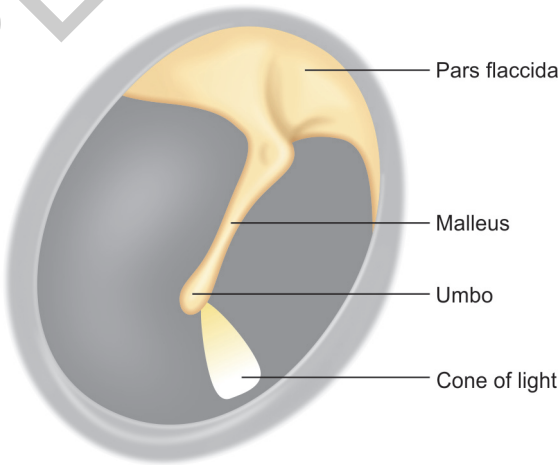

Fig. 1 Picture of the tympanic membrane

JAYPEE BROTHERS

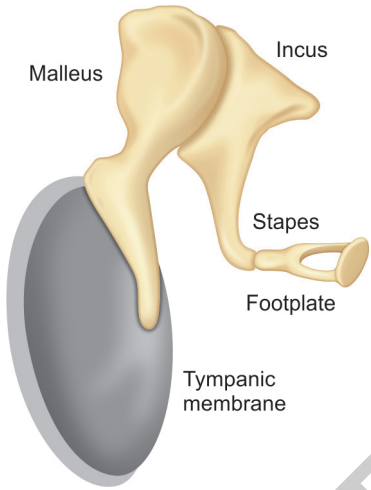

Fig. 2 Middle ear ossicles

Incus

The incus has a body and two processes, short and long. The body of the incus articulates with the head of the malleus in the epitympanic recess. At the end of the long process of the incus is a small region, the lenticular process, which articulates with the head of the stapes. The short process is attached to the cavity wall by the posterior incudal ligament.

Stapes

The stapes has a footplate, two crurae, posterior and anterior, and a head. The head of the stapes articulates with the lenticular process of the incus. The footplate covers the oval window **(Fig. 2)**.

ENDOSCOPIC ANATOMY OF THE MIDDLE EAR SPACES

The recent developments in the field of otology include the study of the ME anatomical structures with Hopkins rod lens system or commonly called the endoscope. This has given a better understanding of the ME anatomy and its intricate structures and also the spread of pathology and its treatment. Initially they were used to visualize the nook and corners of the ME, which were difficult to see with a microscope especially in cholesteatoma clearance. But recent studies have suggested the use of endoscopes in common surgeries and understanding ME spaces gives great confidence to the otologic surgeon **(Fig. 3)**.

Middle ear and subspaces are generally divided into mesotympanum, i.e. medial to the TM, i.e. epitympanum; medial to the scutum and above

JAYPEE BROTHERS

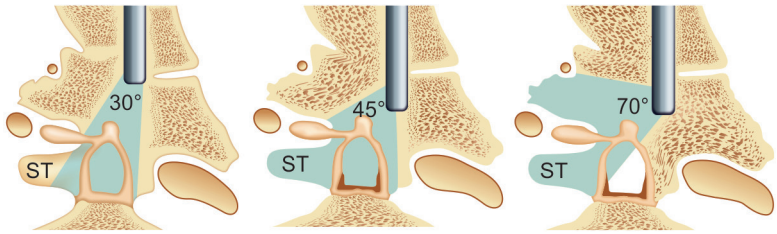

Fig. 3 Use of endoscope for anatomy of middle ear: ST—sinus tympani

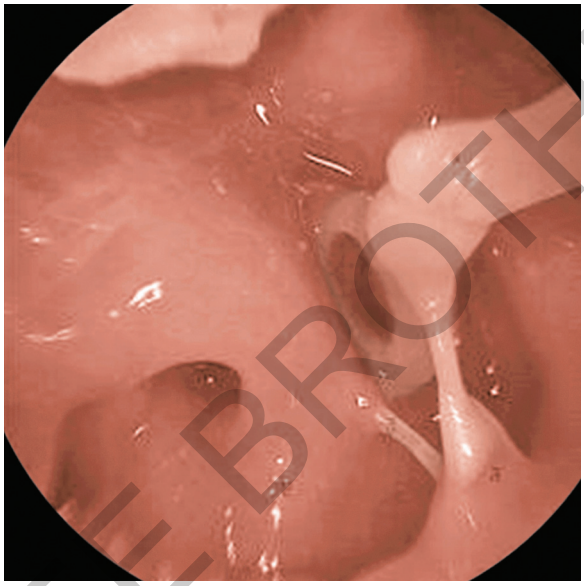

Fig. 4 Middle ear showing subspaces

mesotympanum; and hypotympanum below the mesotympanum; protympanum, i.e. anterior to the mesotympanum; and retrotympanum is that part of the ME that is posterior to the mesotympanum **(Fig. 4)**. The divisions of mesotympanum are as follows:

- Superior—epitympanum
- Anterior—protympanum
- Inferior—hypotympanum
- Posterior—retrotympanum.

Retrotympanum

The retrotympanum is the posterior part of the ME cavity. It contains a number of important structures that can be difficult to visualize during microscopic ear surgery **(Fig. 5)**.

JAYPEE BROTHERS

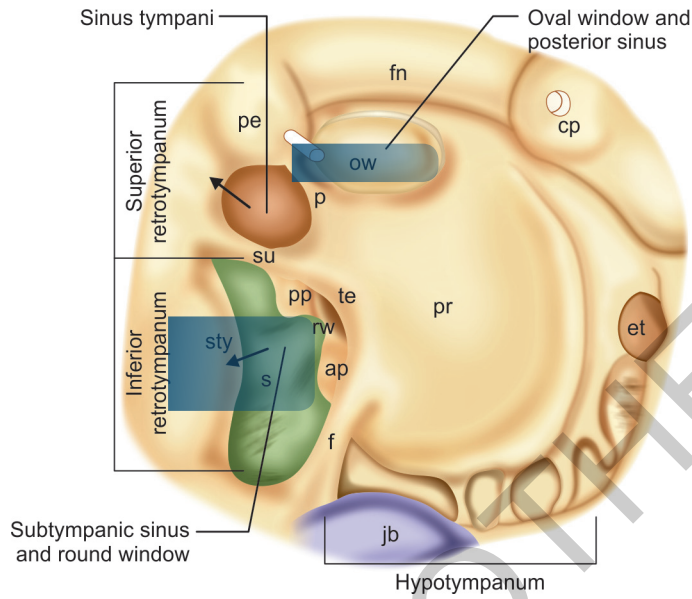

Fig. 5 Various parts of retrotympanum: pe—pyramidal eminence; fn—facial nerve; jb—jugular bulb; p—ponticulum; pr—promontory; rw—round window; su—subiculum; ap—anteriorpillar; cp—cochleariform process; et—Eustachian tube; f—finiculus; pp—posterior pillar

The retrotympanum is divided into superior and inferior by the subiculum a bony ridge in the medial wall of the ME extending to the posteriorly. The different spaces are as follows:

Superior

The space superior to subiculum has four spaces in relation to the vertical portion of facial nerve:

- Two medially, in the anterior aspect, sinus tympani (ST) and posterior tympanic sinus
- Two laterally, in the posterior aspect, facial sinus and lateral tympanic sinus.

Inferior

The space inferior to the subiculum is the sinus sub tympanicus that has been less understood and is now well-established by endoscopic visualization **(Fig. 6)**.

Subpyramidal Space

Subpyramidal space is a space under the pyramidal process and is also prone for persistence of cholesteatoma. There are variations in this space, which leads to residual disease **(Fig. 7)**.

One of the most important structures in retrotympanum is the ST. This cavity is sinus tympani between the medial walls of the ME medially and the pyramidal

JAYPEE BROTHERS

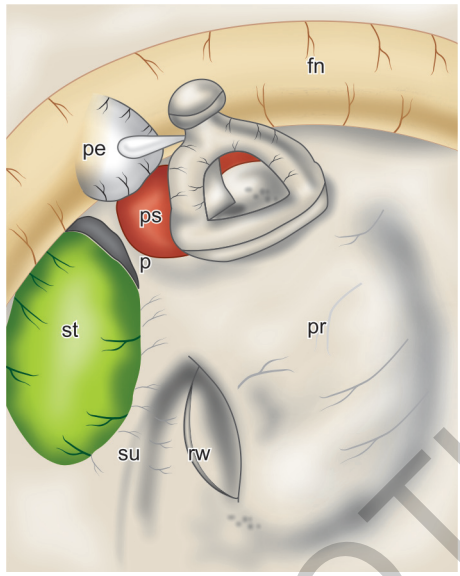

Fig. 6 Showing different spaces present in the retrotympanum: pe—pyramidal eminence; fn—facial nerve; p—ponticulum; pr—promontory; ps—posterior sinus; rw—round window; su—subiculum; st—sinus tympani

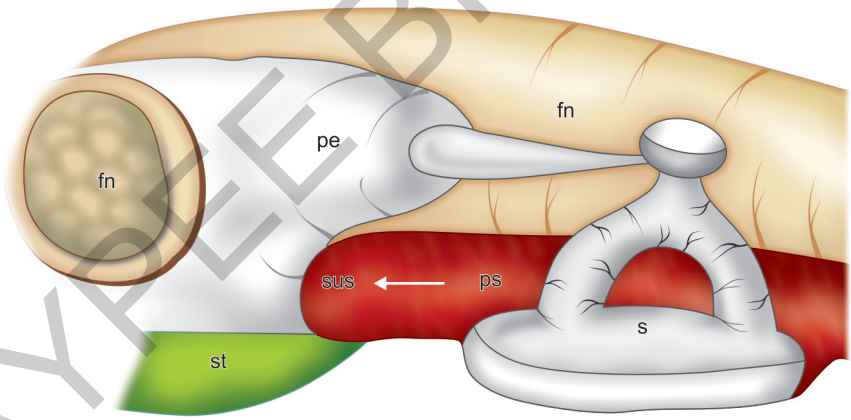

Fig. 7 Endoscopic anatomy of retrotympanum: pe—pyramidal eminence; fn—facial nerve; ps—posterior sinus; st—sinus tympani

eminence (PE) laterally, with the VII nerve posterolaterally. It is bound superiorly by the ponticulus and inferiorly by the subiculum. When cholesteatoma involves the retrotympanum, especially the ST, there may be two important issues:

1. The potential for residual disease due to incomplete removal of disease for lack of adequate exposure.
2. The risk of ossicular dislocation and hearing loss caused during removal of cholesteatoma within a space not easily visualized by microscopic techniques.

JAYPEE BROTHERS

Recently, endoscopes have made possible fresh understanding of the ME, especially the retrotympanum.

Facial Nerve

Facial nerve is an important structure that traverses the ME posterior to the retrotympanum. Housed in a bony canal the nerve passes in a horizontal plane, as it enters the ME and turns inferiorly at the posterior end of the mesotympanum and travels in a vertical plane. It is important to understand the various inner ear structures in relation to the facial nerve.

SOUND TRANSMISSION

The acoustic resistance to the passage of sound through a medium is termed impedance. The transduction of vibratory energy from the air in the external auditory canal (low impedance) to the cochlear fluids (high impedance) is possible as a result of the impedance-matching function of the ME. The TM and the three levers accomplish the required pressure transformation for transduction.

1. *Catenary lever:* The impedance matching mechanism, the catenary lever action, curved membrane effect or buckling effect of the TM, was first explained by Helmholtz (1868), who observed that the umbo of the TM is displaced less than the remaining surface of the TM. Since, the outside edge of the membrane is firmly attached to the annulus and curves medially to attach to the umbo, the displacement of the membrane between the annulus and umbo is larger than at the umbo (Tonndorf and Khanna, 1970). This creates a lever action, which increases the force acting at the umbo by approximately two times or 6 dB (Rosowski, 1996). The principle of this mechanism is shown in **Figures 8A and B**.
2. *Ossicular lever:* The malleus and incus acting as a unit rotate around an axis running between the anterior mallear ligament and the incudal ligament.

   The gain of the ossicular lever is the length of the manubrium of the malleus divided by the length of the long process of the incus (approximately 1.3:1).

   The ossicular lever taken alone produces a small mechanical advantage for sound transmission. The catenary lever is tightly coupled to the ossicular lever, because the TM is extensively adherent to the malleus handle.

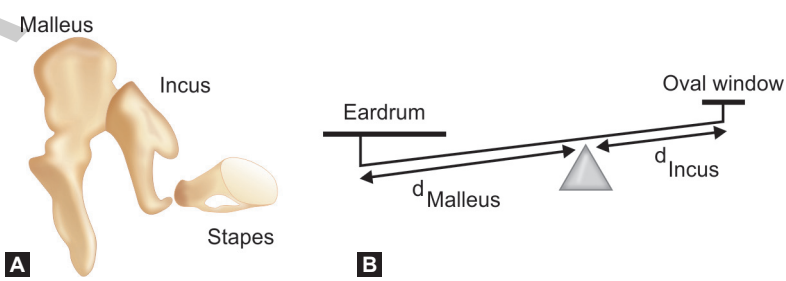

Figs 8A and B (A) Ossicular level mechanism (Hydraulic lever); (B) Cantenary lever mechanism

JAYPEE BROTHERS

Corrected calculations arrive at a combined catenary-ossicular lever ratio of 1:2.3.

3. *Hydraulic lever:* The hydraulic lever acts because of the size difference between the TM and the stapes footplate. Sound pressure collected over the area of the TM and transmitted to the area of the smaller footplate results in an increase in force proportional to the ratio of the areas. The average ratio has been calculated to be 20.8:1.

Taking the three levers together, the ME offers a theoretical gain of approximately 34 dB.

OSSICULAR COUPLING

Ossicular coupling refers to the true sound pressure gain, which occurs through the actions of the TM and the ossicular chain. The true gain of the ME is less than the theorized 34 dB. The pressure gains provided by the normal ME with ossicular coupling is frequency dependent. The actual mean ME gain is 20 dB at 250–500 hertz (Hz), reaching a maximum of 25 dB at 1 kilohertz (kHz), and then decreasing at about 6 dB per octave at frequencies above 1 kHz.

The changes in gain above 1 kHz are caused by portions of the TM moving differently than other portions, depending on the frequency of vibration. At low frequencies, the entire TM moves in one phase. Above 1 kHz, the TM divides into smaller vibrating portions that vibrate at different phases.

Another factor is slippage of the ossicular chain, especially at frequencies above 1–2 kHz. Slippage is due to the translational movement in the rotational axis of the ossicles or flexion in the ossicular joints.

Some energy is lost in sound transmission, because of the forces needed to overcome the stiffness and mass of the TM and ossicular chain.

BIBLIOGRAPHY

1. JoãoFlávioNogueira, Francesco Mattioli, LivioPresutti, Daniele Marchioni. Endoscopic anatomy of the retrotympanum review article otolaryngologic clinics of North America. 2013;46(2):179-88.
2. John J. Rosowski, Albrecht Eiber AudiolNeurootol. 1999;4:121–22, Accessible online at: http://BioMedNet.com/karger
3. Shambaugh,Text book of Ear Surgery. McGraw-Hill Medical; 6 edition.
4. Tonndorf J, Khanna SM. The role of the tympanic membrane in middle ear transmission. Ann Otol Rhinol Laryngol. 1970;79(4):743-53.

JAYPEE BROTHERS

for detailed information on otolaryngology books, visit our website **www.jaypeebrothers.com,** for detailed informatio

Current Concepts of

Otitis Media and

Recent Management Strategies

Salient Features

- Presents the current concepts of otitis media, mucosal disease and surgical management
- Includes the anatomy and physiology of the middle ear with current classification of the anatomy of retrotympanum with the aim of aiding the newly developed endoscopic surgical management
- Offers in-depth coverage of eustachian tube—anatomy, pathophysiology, current concepts of evaluation of eustachian tube function and treatment including its involvement in otitis media
- Describes recent classification of acute otitis media with current guidelines of treatment and chronic otitis media with special emphasis on tympanostomy tube otorrhea, biofilms and their management
- Details the microbiology and pathophysiology of otitis media with special emphasis on prevention and current vaccines available
- Defines the eosinophilic otitis media—a recently recognized entity and its role in otitis media
- Contains comprehensive concepts in surgery, indications, approaches and classification of tympanoplasty, ossicular reconstruction and the various prostheses available along with their advantages
- Establishes hearing rehabilitation.



Anand Job is Professor, Department of ENT-I, Christian Medical College, Vellore, Tamil Nadu, India. He is a Senior Otolaryngologist with special interest in otology. He underwent his undergraduate and postgraduate (DLO and MS) training at Christian Medical College, Vellore and has been working as Professor of ENT for the past 20 years.

He has undergone further training in otology at Tulane Medical Centre, Department of Otolaryngology, New Orleans, USA for six months in 1989 and at the Royal Sussex County Hospital, Brighton, UK from 1991 to 1993.

He has participated in the workshops on provision of Hearing Aids Services for developing countries as Member of WWHearing (World Wide Hearing Care for Developing Countries) in November 2005 and 2006 at WHO, Geneva, USA. He is the Regional Advisor for CBM for the South-Asia Region for hearing impairment.

Besides being an otolarynogologist, he has taken active interest in hospital administration and has been the Principal and Medical Superintendent of Christian Medical College, Vellore, Tamil Nadu, India.



L Paul Emerson is an ENT Consultant, Department of ENT-I, Christian Medical College, Vellore, Tamil Nadu, India. He completed his Masters in ENT from same college. In addition to ENT and Head and Neck surgical work, and teaching undergraduate and postgraduate students, he has special interest in developing technology for assessment of hearing disorders and rehabilitation for the rural community through funding by Christoffel Blindenmission. Towards this end, he is working under the guidance of Dr Anand Job. He has published various articles in Journals and contributed chapters for textbooks. He has participated in various seminars, conferences and workshops both at national and international level.

He thanks Dr Anand Job for giving an opportunity to work under him and co-authoring the book. He is grateful for his guidance and advice and wishes him God's blessing on him and his family.

Finally, the author would like to thank Lord Jesus Christ for guiding him.

Available at all medical bookstores
or buy online at www.jaypeebrothers.com

JAYPEE BROTHERS
Medical Publishers (P) Ltd.
www.jaypeebrothers.com

Join us on facebook.com/JaypeeMedicalPublishers

Shelving Recommendation
OTOLARYNGOLOGY

ISBN 978-93-5152-453-3