Get Full Access
with added features at
emedicine360.com



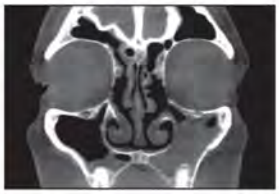

Sataloff's Comprehensive Textbook of
Otolaryngology
Head & Neck Surgery

Rhinology/ Allergy and Immunology

Series Editor
Robert T Sataloff

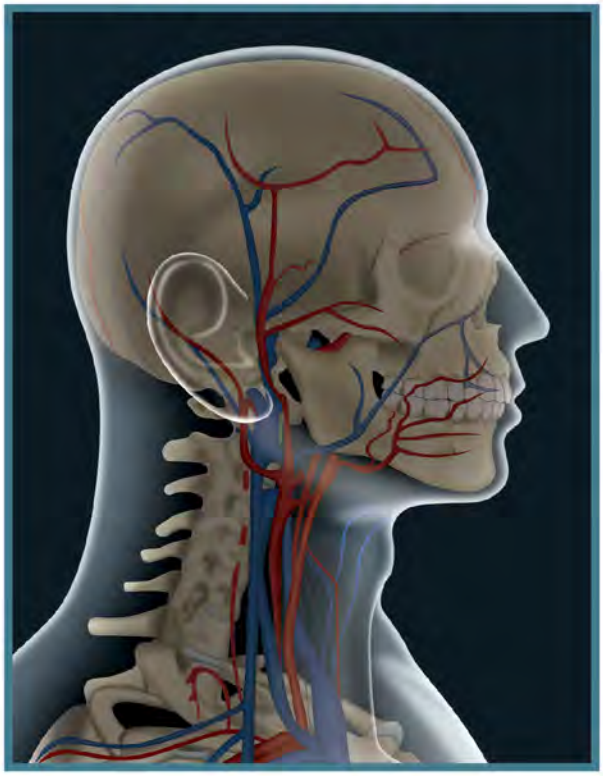

Volume Editors
Marvin P Fried
Abtin Tabaee

JAYPEE

Contents

Section 1: History of Rhinology

1. **The History of Rhinology—From Ancient Times to the 21st Century** 3
   Patrick Colley, Marvin P Fried, Abtin Tabaee

Section 2: Embryology, Anatomy and Physiology

2. **Evolution of the Human Nasal Respiratory Tract: Nose and Paranasal Sinuses** 17
   Samuel Márquez, Anthony S Pagano, William Lawson, Jeffrey T Laitman
3. **Embryology and Development of the Nose and Paranasal Sinuses** 43
   Martin Anderson, Jastin Antisdel, Raj Sindwani
4. **Anatomy of the Nose, Paranasal Sinuses, and Anterior Skull Base** 53
   Ameet Singh, Abtin Tabaee
5. **Physiology of the Nose and Paranasal Sinuses** 73
   Richard A Lebowitz, Whitney Pafford

Section 3: Evaluation of the Nose and Paranasal Sinuses

6. **Clinical Evaluation of the Nose and Paranasal Sinuses** 83
   Steven D Pletcher
7. **Acoustic Rhinometry and Objective Measures of Nasal Airway Obstruction** 91
   Mohamad R Chaaban, Jacquelynne P Corey
8. **Clinical Evaluation and Treatment of Smell and Taste Disorders** 101
   Richard L Doty, James B Snow, Jr
9. **Diagnostic Imaging in Rhinology** 117
   Mira Herman, Daniel Krieger, Andrew McClelland, Susan Sotardi, Ari Spiro, Jenna Le, Caitlin McMullen, Arel Golombeck, Jimmy Lee, Jacqueline A Bello, Joaquim Farinhas
10. **Measuring Quality of Life and Outcomes in Rhinology** 169
    David M Poetker, Timothy L Smith
11. **Practice Management, Coding, and Career Pathways in Rhinology** 179
    Seth M Brown, Michael Setzen

Section 4: Allergy

12. **Epidemiology and Pathophysiology of Allergic Rhinitis** 191
    James W Mims
13. **Evaluation and Diagnostic Testing of Allergic Rhinitis** 201
    David L Rosenstreich, Elina Jerschow, Purvi Parikh, Gabriele de Vos

14. **Treatment of Allergic Rhinitis** 215
Stella Lee, Michael Platt, Sandra Y Lin
15. **Allergy, Reactive Airway Disease, and Rhinosinusitis: The Unified Airway** 233
Rachel Georgopoulos, Elina M Toskala, John H Krouse

Section 5: Disorders of the Nose

16. **Granulomatous and Inflammatory Diseases of the Nose and Paranasal Sinuses** 249
Caitlin McMullen, Alexis H Jackman
17. **Fibro-Osseous Lesions of the Paranasal Sinuses** 263
James Phillips, Bradford A Woodworth
18. **Benign Neoplasms of the Nose and Paranasal Sinuses** 273
Brian Thorp, Kenneth Rodriguez, Brent A Senior
19. **The Nose and Sleep Disorders** 285
Steven Y Park, Samuel N Helman
20. **Sinonasal Effects of Drugs and Toxins** 297
Carrie E Flanagan, Sarah K Wise
21. **Epistaxis** 319
Patricia A Loftus, Alexis H Jackman
22. **Headache and Facial Pain** 331
Charles Parker, Jamie L Gentile, Brian L Hendricks, Ryan A Crane, Allen M Seiden

Section 6: Rhinosinusitis: Etiology, Pathophysiology and Medical Therapy

23. **Classification and Diagnosis of Rhinosinusitis** 359
Troy Woodard, Michael S Benninger
24. **The Pathogenesis of Rhinosinusitis** 365
Michael S Benninger, Janalee K Stokken
25. **Genetic Basis of Rhinosinusitis** 377
Andrew P Lane, Josef Shargorodsky
26. **Immunologic Aspects of Rhinosinusitis** 391
Songhui Ma
27. **Acute Rhinosinusitis** 413
Yan W Ho, Satish Govindaraj
28. **Bacteria in Rhinosinusitis: Infection, Biofilms, and Superantigens** 427
Raewyn G Campbell, James N Palmer
29. **Nasal Polyposis** 439
Stella Lee, Berrylin J Ferguson
30. **Fungus in Paranasal Sinus Disease** 451
Kent Lam, Christopher Vanison, Robert C Kern
31. **Osteitis** 469
Adam S DeConde, Alexander G Chiu, Jeffrey D Suh
32. **Odontogenic Sinusitis** 479
Adam S DeConde, Alexander G Chiu, Jeffrey D Suh

33. **Reflux and Sinusitis** 485
Adrienne M Laury, John M DelGaudio
34. **Complications of Rhinologic Disorders** 493
Philip G Chen, Peter-John Wormald
35. **Antibiotic Therapy in Rhinosinusitis** 507
Patricia A Loftus, Abtin Tabaee, Marvin P Fried
36. **Anti-Inflammatory Therapy for Rhinosinusitis** 515
Alla Y Solyar, Donald C Lanza
37. **Complementary Therapy and Integrative Medicine in Sinonasal Disease** 531
Roheen Raithatha, Sezelle Gereau Haddon
38. **Refractory Chronic Rhinosinusitis** 549
Whitney Zirkle, Rakesh Chandra

Section 7: Anesthesia

39. **Local Anesthesia** 571
Azeem S Kaka, Subinoy Das
40. **Anesthesiology** 577
Jerry Chao, Philip Lebowitz

Section 8: Functional Surgery of the Nasal Airway

41. **Surgery of the Nasal Septum** 595
Waleed M Abuzeid, Sam P Most, Peter H Hwang
42. **Surgical Management of the Nasal Turbinates** 615
Andrea S Wang, Nicole M Hsu, Michael G Stewart
43. **Functional Rhinoplasty** 631
Rebecca E Fraioli, Satyen Undavia

Section 9: Surgery for Inflammatory Sinusitis

44. **Office-Based Rhinologic Procedures** 647
Oscar Trujillo, Ashutosh Kacker
45. **Endoscopic Sinus Surgery for Chronic Rhinosinusitis: Historical Evolution, Indications, and Outcomes** 651
Robert T Adelson, David W Kennedy
46. **Training for Sinonasal Surgery: Past, Present and Future** 669
Rachel Kaye, Marc J Gibber, Marvin P Fried
47. **Innovations in Optics and Instrumentation** 677
Arjuna B Kuperan, Jean Anderson Eloy, Roy R Casiano
48. **Surgical Radiology and Image Guidance Surgery** 689
Jeremiah A Alt, Richard R Orlandi
49. **Primary Endoscopic Sinus Surgery for Chronic Rhinosinusitis** 707
Bozena B Wrobel, Dale H Rice

50. Revision Sinus Surgery 717
Justine BF Millar, Dustin M Dalgorf, Richard J Harvey
51. Endoscopic Surgery of the Frontal Sinus 735
Calvin C Wei, Joseph B Jacobs
52. Minimally Invasive Sinus Surgery and Balloon Sinuplasty 743
Peter J Catalano
53. Open Approaches to the Paranasal Sinuses for Inflammatory Disorders 755
Esther Kim, James Duncavage
54. Odontogenic Disease and Oral–Antral Fistula 765
Richard A Kraut
55. Complications in Endoscopic Sinus Surgery 787
James A Stankiewicz

Section 10: Endoscopic Skull Base Surgery

56. Endoscopic Surgery of the Sella and Suprasellar Region 805
Osaama H Khan, Roheen Raithatha, Vijay K Anand, Theodore H Schwartz
57. Endoscopic Surgery of the Anterior Skull Base 821
Carl H Snyderman, Paul A Gardner, Juan C Fernandez-Miranda, Eric W Wang
58. Endoscopic Surgery of the Pterygopalatine and Infratemporal Fossae 837
Mark E Friedel, Marc R Rosen, Gurston G Nyquist
59. Endoscopic Surgery of the Clivus, Craniocervical Junction, and Posterior Fossa 849
Aldo Cassol Stamm, Diego Rodrigo Hermann, Leonardo Balsalobre, Eduardo de Arnaldo Silva Vellutini
60. Endoscopic Surgery of the Cavernous Sinus and Petrous Apex 859
Seth M Lieberman, Mohammad Al Bar, Roy R Casiano
61. Management of Skull Base Defects: Cerebrospinal Fluid Rhinorrhea, Meningoencephalocele and Endoscopic Skull Base Surgery 871
Edward D McCoul, Abtin Tabaee

Section 11: Endoscopic Surgery of the Orbit

62. Orbital Decompression 899
Eugenie Du, Robert Schwarcz, Bradley A Schiff
63. Endoscopic Dacryocystorhinostomy (DCR) 913
Nipun Chhabra, Giant Lin, Ralph Metson

Section 12: The Future of Rhinology: The Next Frontiers

64. The Future of Rhinology: The Next Frontiers 925
Jeremy T Reed, David W Kennedy
Index 939

Video Legends

Video 19.1 Nasal endoscopy during upper airway examination.
Video 50.1: Modified medial maxillectomy.
Video 50.2: Salvage bilateral sphenoidotomy.

CHAPTER

Embryology and Development of the Nose and Paranasal Sinuses

3

Martin Anderson, Jastin Antisdel, Raj Sindwani

INTRODUCTION

The embryologic development of the nasal cavity and the paranasal sinuses is a complex process. This chapter organizes sinonasal embryologic progression chronologically, according to developmental age. Details of development are examined, beginning with the early formation of the nose, lateral nasal wall, and middle meatal structures, and ending with the maturation of key prenatal structures that continue postnatally. A clinical perspective is offered that frames contemporary surgical approaches to endoscopic sinus surgery in a way that essentially mirrors the embryological development of key sinonasal structures. Gaining a nuanced understanding of sinonasal embryology can provide the practitioner with a unique perspective on the surgical management of diseases that affect this region.

EARLY DEVELOPMENT: THE NOSE AND FACE

Sinonasal development begins early in the sequence of embryologic progression. Between the 2nd and 3rd weeks of development, through the process of gastrulation, the human embryonic disk progresses from a bilaminar layer of cells to a trilaminar structure. The trilaminar embryonic disk is comprised of three cell layers: endoderm, ectoderm and mesoderm. From the ectoderm, along the neural groove, the neural crest cells will develop. The face and nasal structures are derived from three sources of embryonic tissue: ectoderm, mesoderm and neural crest. The majority of facial mesenchymal tissue comes from neural crest cells. The ectoderm provides a tissue cover and a pattern for the developing facial structures through its interactions with the underlying facial mesenchyme.[1]

As early as the 4th week of gestation, at about the same time the embryonic heart begins to beat, embryologic development of the human nasal cavities begins and primordial nasal cavities are evident.[2] At this early stage of development, five structures surround the stomodeum. The stomodeum is an early embryonic structure that will eventually develop into the mouth; the maxillary prominences and the frontonasal prominence will comprise much of the midface, including the palate and external nasal structures. As seen in Figure 3.1, the paired right and left maxillary prominences lie lateral to the medial frontonasal prominence to comprise the structures at the rostral aspect of the stomodeum. Paired right and left mandibular prominences lie inferolateral to the stomodeum. The frontonasal process grows over the developing forebrain and contributes to the formation of the nasal placodes, and by the end of the 4th week of gestation the nasal placodes are evident superolateral to the stomodeum. These structures will eventually become the nose and the nasal cavities.[1-3] Between the 4th and 6th weeks of gestation, separate nasal cavities form as the frontonasal process progresses posteriorly at the midline and fuses with extensions of mesoderm from the bilateral maxillary processes.[2] This fusion creates the midline septum, and thus two distinct nasal cavities. The posterior nasal septum continues to grow inferiorly from the nasofrontal prominence to meet the palatal shelf fusion of the secondary palate. The anterior nasal septum is contiguous with the primary palate, which originates from the nasomedial prominences.[1]

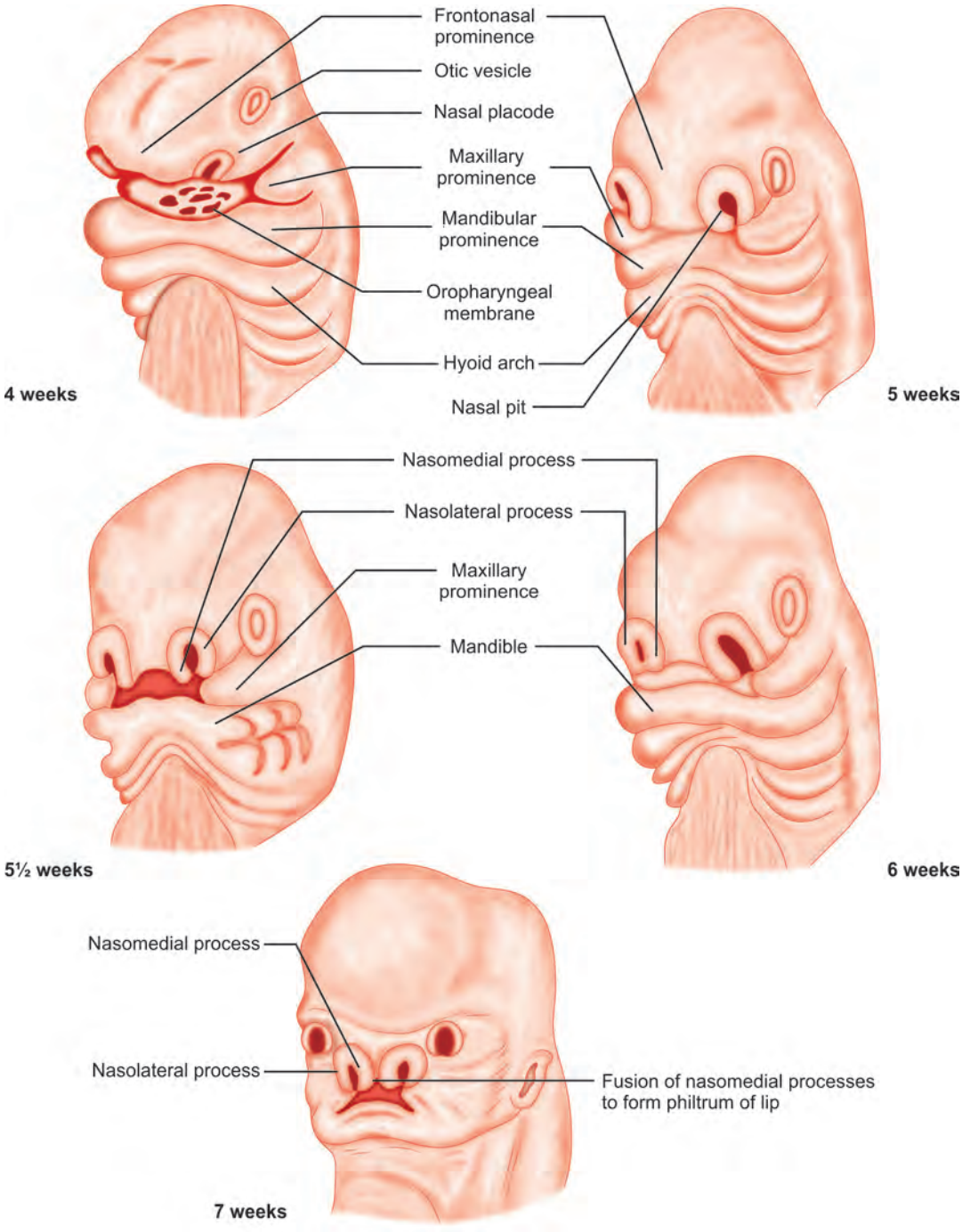

Fig. 3.1: Embryogenesis of the face. Weeks 4–6: The frontonasal process grows over the forebrain and forms the nasal placodes. Separate nasal cavities form as the frontonasal process progresses posteriorly and fuses with the bilateral maxillary processes. Weeks 5–6: Mesenchymal tissue surrounding the nasal placodes raises to form the nasomedial process and the nasolateral process, which will develop into the nares. The nasal pits deepen until only a small oronasal membrane separates the nasal and oral cavities. Weeks 6–8: The fusion of the nasolateral processes and the maxillary processes forms the ala nasi and the lateral border of the nostril bilaterally. Weeks 7–8: Fusion of the nasomedial process with the maxillary process forms the upper maxilla and the philtrum of the upper lip. The nasomedial processes fuse to each other, forming the intermaxillary segment, which will eventually become the primary palate, the tip and crest of the nose, and part of the anterior nasal septum.

As demonstrated in Figure 3.2, beginning at the 4th week of gestation and progressing through the eighth, the primary and secondary palatal shelves fuse in an axial plane to separate the nasal cavity and nasopharynx from the oral cavity and the oropharynx. This fusion of the primary and secondary palates occurs immediately behind the incisive foramen and extends both anteriorly and posteriorly in a zipper-like fashion.[2]

In the 5th week, mesenchymal tissue surrounding the nasal placodes raises in an inverted U-shape, as shown in Figure 3.1. The medial aspect of this "U" is termed the nasomedial process and the lateral aspect is termed the nasolateral process. These nasal prominences will eventually develop into the nares. The elevation of the nasolateral and nasomedial processes gives the appearance that the nasal placodes are depressed. Following this point in development, the nasal placodes are subsequently called the nasal pits. The nasal pits continue to deepen through the 6th week of gestation until only a small oronasal membrane separates the nasal and oral cavities. This membrane disintegrates posterior to the primary palate, creating a connection between the nasal and oral cavities.[1,2,4]

By the end of the 6th week of gestation, the nasolateral processes begin to fuse with the maxillary processes, and this fusion process continues through the 8th week of gestation. The fusion of the nasolateral processes and the maxillary processes form the ala nasi and the lateral border of the nostril bilaterally. Additionally, the fusion of these two structures forms the nasolacrimal groove. The ectoderm, which lies within the nasolacrimal groove, develops into cords of epithelium. These cords detach from the groove and canalize, forming the nasolacrimal ducts and lacrimal sacs. During the 7th and 8th weeks of gestation, the nasomedial processes fuse with the maxillary processes. Fusion of the nasomedial process with the maxillary process forms the upper maxilla and the philtrum of the upper lip. The nasomedial processes subsequently fuse to each other, forming the intermaxillary segment. The intermaxillary segment displaces the frontonasal prominence posteriorly and will eventually become the primary palate, the tip and crest of the nose, and part of the anterior nasal septum. Fusion failure of the nasomedial processes with the maxillary process results in cleft lip or palate deformity.[1,2,4] Piriform aperture stenosis is another anatomic abnormality caused by aberrations at this stage of development. Piriform aperture stenosis is caused by overgrowth of the nasal process of the maxilla during the fusion with the nasomedial processes.[1]

DEVELOPMENT OF THE VOMERONASAL ORGAN

Between the 5th and 7th weeks of gestation, the vomeronasal organ is first noted. It initially appears as bilateral epithelial thickenings of the anterior nasal septum termed the vomeronasal primordium. The vomeronasal primordium invaginates between the 5th and 6th weeks to form a blind pouch called the tubular vomeronasal organ, which separates from epithelium and remains spatially separate from the paraseptal cartilages. In other mammals, the vomeronasal organ has chemoreceptors with direct neural projections to the accessory olfactory bulb, and the accessory olfactory bulb connects to the amygdala and other limbic centers.[1,5,6]

THE LATERAL NASAL WALL: RIDGES AND FURROWS

By the end of the 6th week, the mesenchyme has formed a simple lateral nasal wall. All of the paranasal sinuses will eventually develop from the lateral nasal wall in some respect.[2,7] By the 8th gestational week, as the external architecture of the nose becomes more defined, the lateral nasal wall is also further anatomically developed. As seen in Figure 3.3, during the 7th and 8th weeks of gestation, the lateral nasal wall invaginates to form five to six complex mesenchymal ridges.[2,7-10] The surrounding mesenchymal cells further concentrate to form a cartilaginous nasal capsule that surrounds the nasal cavity. At this stage, the cartilaginous nasal capsule is contiguous with the nasal septal cartilage. In later development, numerous nasal structures will develop from the cartilaginous lateral nasal capsule. Although five to six ridges initially develop, through fusion or regression only three to four ridges ultimately persist. The early uncinate process is also identifiable as a soft tissue swelling on the superolateral aspect of the primordial inferior turbinate. At this stage, the uncinate appears as a double-beak as opposed to the adult hook shape.[1,7,8,11]

The most inferior ridge of the lateral nasal wall, referred to as the "maxilloturbinal," will develop into the inferior turbinate. The remaining ridges are referred to as "ethmoturbinals" and are numbered from inferior to superior. The inferior turbinate thus has a different embryological derivation than the other turbinates, which arise from ethmoturbinals. All ethmoturbinals are considered ethmoid in origin. The first ethmoturbinal is rudimentary and incomplete in the human. It is comprised of an ascending and

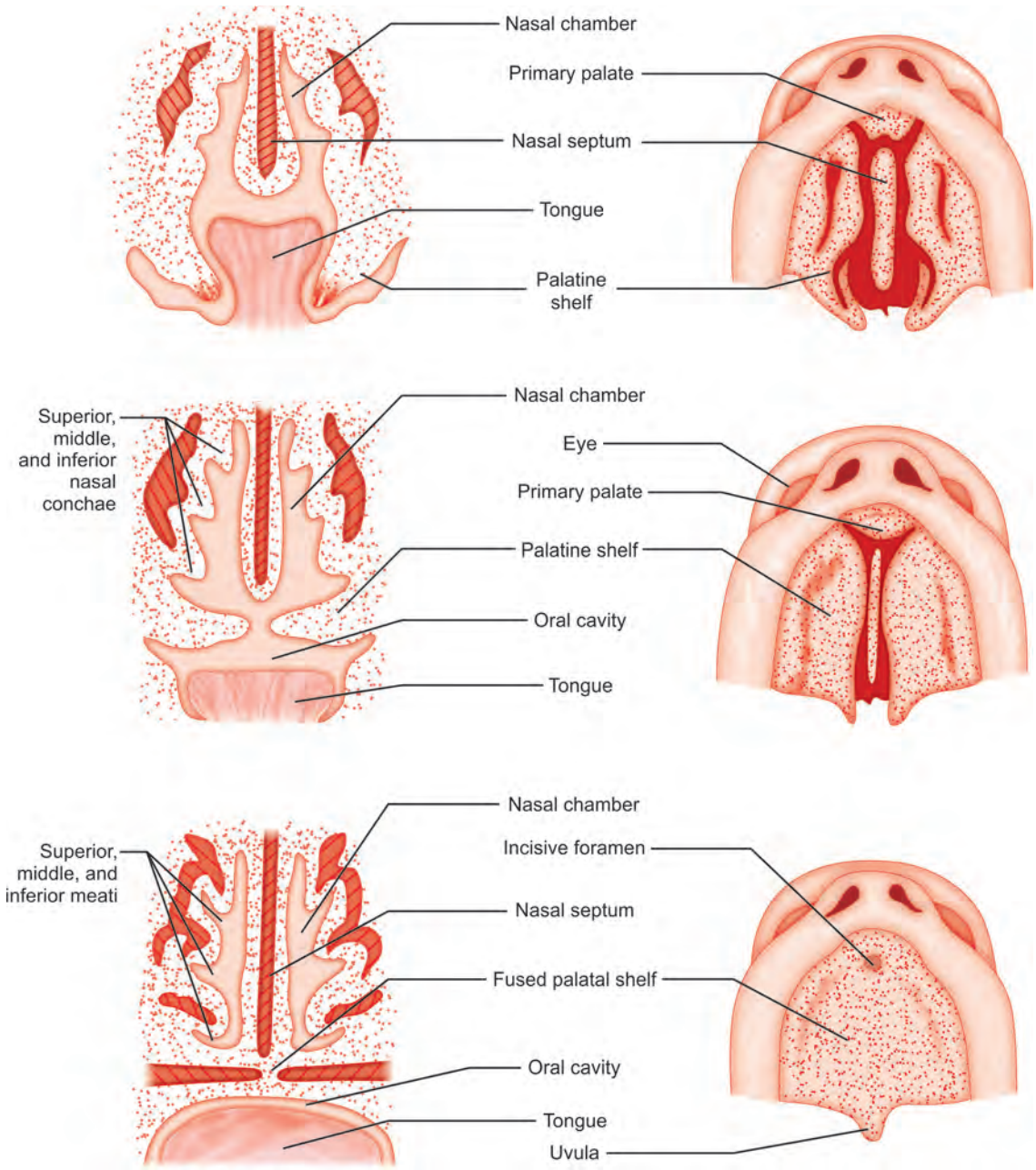

Fig. 3.2: Embryogenesis of the nasal cavity and palate. From weeks 4–8 of gestation, the primary and secondary palatal shelves fuse in an axial plane to separate the nasal cavity and nasopharynx from the oral cavity and the oropharynx. This fusion of the primary and secondary palates occurs immediately behind the incisive foramen and extends both anteriorly and posteriorly in a zipper-like fashion.

descending portion. The ascending portion develops into the agger nasi cell, while the descending portion will develop into the uncinate process. The second and third ethmoturbinals will eventually form the middle and superior turbinates, respectively. The fourth and fifth ethmoturbinals fuse to create the supreme turbinate.[7,8] The ethmoturbinals are also sometimes referred to as preturbinates.

Because of the ethmoturbinal theory, the uncinate process is named the first ground or first basal lamella,

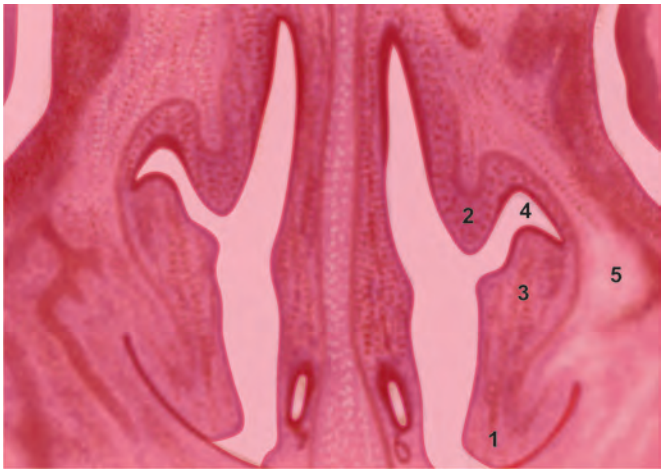

Fig. 3.3: Coronal section at 8 weeks. At 8 weeks, mesenchymal ridges on the lateral nasal wall have formed and the nasal cavity is surrounded by a cartilaginous nasal capsule. In this picture, consistent with histology at 8 weeks, the inferior turbinate (1), middle turbinate (2), primordial uncinate (3), rudimentary infundibulum (4) and the surrounding cartilaginous capsule (5) are evident.

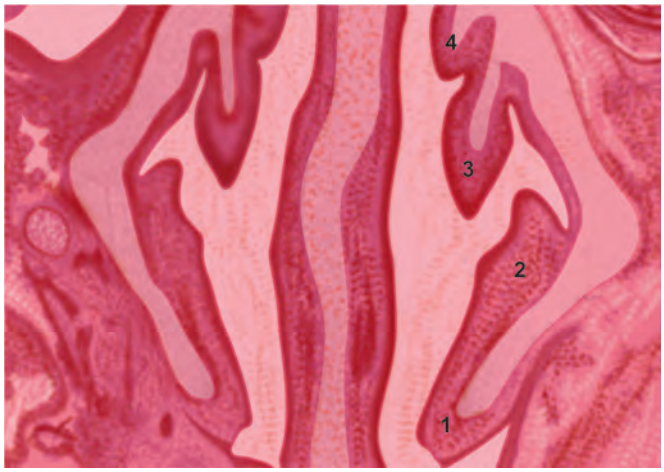

Fig. 3.4: Coronal section at 10 weeks. By 10 weeks, the cartilaginous capsule further extends into the mesenchymal ridges to define the structures of the nasal cavity. The inferior turbinate (1) is formed from the maxilloturbinal. The uncinate process (2), middle turbinate (3), and superior turbinate (4) form from the first, second, and third ethmoturbinals, respectively. The associated meatuses can be seen beneath each rudimentary turbinate.

as it is formed from the first ethmoturbinal. The ethmoid bulla is the second ground lamella, while the middle turbinate is the third ground lamella. Lastly, the attachment of the superior and supreme turbinates are the fourth and fifth ground lamellae, respectively.[7]

Between the ethmoturbinals lie furrows, which later develop into defined meati and recesses.[7,8,10,12,13] The first furrow, which arises between the first and second ethmoturbinals, forms the ethmoid infundibulum, hiatus semilunaris, and middle meatus. The first furrow has an ascending and descending portion. The descending portion contributes to the ethmoid infundibulum, while the ascending portion of the first furrow can also contribute to the frontal recess. The second and third furrows form the superior and supreme meati, respectively.[7,8,14,15] It is interesting to note that most intranasal structures including all of the turbinates (except the inferior turbinate) the uncinate process, ethmoid cells, and indeed even the crista galli are all ethmoidal in embryological derivation.

FORMATION OF MIDDLE MEATAL STRUCTURES

The transition from weeks 9 to 10 marks the progression from embryo to fetus. During weeks 9 and 10 of gestation, as seen in Figure 3.4, cartilaginous projections from the cartilaginous nasal capsule extend into the preturbinates, with the first of these projections noted within the inferior turbinate. An additional cartilaginous bud is also observed at the base of the primordial uncinate process as the uncinate process extends up at the entrance of the middle meatus.[1,7,8,10,13]

Initially, the nasal cavity is lined by a single layer of flattened cells, and then later by two to three layers of spherical cells intermixed with undifferentiated cells. However, at 9 weeks of development as the cartilaginous capsule invades the lateral nasal wall to define the anatomic structures, differentiation of the mucosa is also appreciated with pseudostratified ciliated columnar epithelium appearing within the nasal cavity. The lamina propria of the differentiated mucosa becomes increasingly vascularized during the 9th week of gestation. An invagination of this mucosa arises at the angle of attachment of the uncinate process and extends into the lateral nasal wall further defining the middle meatus. This invagination is the infundibulum and will eventually develop into the maxillary sinus as it extends further inferolaterally. The middle meatus extends further into the lateral nasal wall than the other meatuses, and is the site of initial development of the frontal and anterior ethmoid sinuses in addition to the maxillary sinus.[7,10,16] One to four secondary furrows will form within the ventral and caudal aspect of the primordial middle meatus above the uncinate. One of the small mucosal protrusions between the furrows will become the

bulla ethmoidalis, which will delineate the hiatus semilunaris. The early bulla ethmoidalis is the originating site of both the anterior and middle ethmoid cells. The secondary furrows on either side of the bulla ethmoidalis will develop into the suprabullar and retrobullar recesses. The origin of the frontal sinus is variable in the literature. It is postulated to either arise as an extension of the frontal recess or from an anterior–superior projection of the ethmoid infundibulum. The frontal recess is thus embryologically derived from the anterior ethmoid cells.[2,7,8,10,14]

At the 11th and 12th weeks, at about the same time that the fetal liver begins producing red blood cells, the primordial ethmoid infundibulum is clearly visible and begins to extend as a tract inferolaterally into the maxilla.[1] Week 12 also heralds a clearer distinction of the ethmoid bulla within the middle meatus, now with cartilage extending from the lateral nasal capsule to further define the previously noted mucosal bulge. Additionally, the pseudostratified ciliated epithelium noted during week 9 continues to differentiate until the 14th week of gestation. During weeks 11 and 12, the mucosa begins to exhibit glandular acini and goblet cells, which are first evident in the mucosa of the anterior septum. The mucosal development of the anterior nasal cavity precedes that of the lateral nasal wall and the adjacent paranasal sinuses.[7] Also between weeks 12 and 14 of gestation in the human, the vomeronasal organ loses any receptor cells and nerves it had developed and regresses to the same mucosa as adjacent tissues—pseudostratified ciliated epithelium. Thus, although all embryonic humans develop a vomeronasal organ, by the 14th week it has lost all functional components. Only a remnant of the vomeronasal organ remains through embryologic development and persists postnatally.[5]

ETHMOID AND SPHENOID SINUSES

The 13th and 14th weeks mark the beginning of the embryologic development of the ethmoid and sphenoid sinuses. The nasal mucosa invaginates into the posterior portion of the nasal cartilaginous capsule to form a cavity referred to as the cupolar recess of the nasal cavity. This cartilaginous complex ossifies in later fetal development and is referred to as the ossiculum of Bertini. It will later become the sphenoid sinus. Simultaneous with the primordial development of the sphenoid sinus, the anterior ethmoid cells are also seen arising from the superior middle meatus. The anterior ethmoid cells are visualized



Fig. 3.5: Coronal section at 14 weeks. The ethmoid bulla (4) and uncinate process (3) are clearly visible; all three primordial turbinates, uncinate process, ethmoid bulla, and nasal septum (5) are supported by cartilage that extends from the nasal capsule; and the ethmoid infundibulum (6) extends inferolaterally into the maxillary bone precursor, forming a rudimentary maxillary sinus (7). Inferior turbinate (1) and middle turbinate (2).

as several blind epithelial invaginations, while the posterior ethmoid cells develop from the floor of superior meatus.[2,7,8,10,17] In fact, in histologic studies, it appears that the initial air cells of the anterior and middle ethmoid groups arise and differentiate from the primordial ethmoid bulla. The most ventrocephalic of the invaginations of the ethmoid bulla within the middle meatus will form the primordium for the frontal sinus. Therefore, by 14 weeks the nasal cavity begins to exhibit structures that are identifiable as those that exist in the adult. As seen in Figure 3.5, the ethmoid bulla and uncinate process are clearly visible; all three primordial turbinates, uncinate process, ethmoid bulla, and nasal septum are supported by cartilage that extends from the nasal capsule; and the ethmoid infundibulum extends inferolaterally into the maxillary bone precursor. A portion of the primitive ethmoid infundibulum also extends posteriorly. This extension will continue to grow and will eventually aid in the formation of the posterior ethmoid cells.[1,7,10,14]

OSSIFICATION OF SINONASAL STRUCTURES

By the 15th gestational week, ossification has begun with weeks 15 to 18 subsequently marked by further development of the maxillary sinus and bony maturation of the lateral nasal wall. At the 15th week, the maxillary sinus is surrounded by a sleeve of cartilage and has extended further into the apex of the maxilla. By the 16th week, the floor

of the primordial maxillary sinus is located lower than the inferior turbinate, approximating the orientation observed in the developed adult. During the 17th and 18th weeks, the cartilage capsule surrounding the maxillary sinus now begins to expand, extending further anteriorly, laterally, and inferiorly to increase the volume of the maxillary sinus. The infundibulum and the tract extending to the maxillary sinus run medial to the nasolacrimal duct origin at the eye. Ossification begins at the maxillary and palatine primordia, and from these sites of ossification, bony trabeculae will extend into the lateral nasal wall, first involving the inferior turbinate. Ossification extends up from the hard palate of the maxilla posteriorly to first replace the cartilaginous nasal capsule posterolaterally to form the bony lateral nasal wall.[1,10] Through weeks 17 and 18, the inferior turbinate begins to ossify at its attachment with the lateral nasal wall, with the medial free edge remaining cartilaginous. Ossification progresses laterally to medially from the lateral nasal wall for each of the turbinates. Over the following month of gestation, ossification will progress to involve the attachment of the middle turbinate at the lateral nasal wall as well as nearly the entire course of the nasolacrimal duct. Also over this same time period, the turbinates and uncinate enlarge in size, creating a narrow free airway. The middle and superior turbinates hang vertically, while the inferior turbinate assumes a more curved orientation.[1,7,10]

From the ossified ethmoid bulla, the anterior and middle ethmoid cells further develop. Previously seen as blind mucosal invaginations, the cells of the anterior and middle ethmoid groups are now more developed. In embryologic anatomic studies, during the 22nd week the first cell of the anterior ethmoid group was seen within the anterior–inferior portion of the ethmoid bulla, and during the 23rd week the first cell of the middle ethmoid group was seen within the superior aspect of the ethmoid bulla. As mentioned previously, ossification of the uncinate process and of the supreme turbinate also occurs during the 22nd and 23rd weeks of gestation.[7]

At 24 weeks of gestation, the primordial maxillary sinus has significantly invaginated into the bone of the maxilla. The maxillary sinus and infundibulum remain surrounded by cartilaginous capsule. The capsule is surrounded by woven trabecular bone of the maxilla. Laterally, a vertical plate of bone extends from maxilla to separate the inferior orbit from the lateral cartilaginous capsule. Medially, a second vertical plate of bone extends from the maxilla to separate the inferior turbinate from the lateral nasal cartilaginous capsule, forming the posteroinferior lateral wall of the nasal cavity. Therefore, by 24 weeks of gestation, the lateral nasal wall is nearly complete. The superior and middle turbinates have ossified from the ossification center of the ethmoid. The inferior turbinate, with its dual origins from the maxilla and lateral nasal cartilaginous capsule is also completely ossified. The superior aspect of the nasolacrimal duct is also completely encased in bone. Furthermore, at 24 weeks of gestation, the mucosa of the nasal cavity is a well-developed respiratory epithelium and the process of mucosal differentiation is complete.[1,7,10]

MIDDLE TURBINATE PNEUMATIZATION AND MATURATION OF PRENATAL STRUCTURES

In some subjects, the middle turbinate can undergo pneumatization and the formation of a concha bullosa or intralamellar cells. When it occurs, this "collateral pneumatization" of the middle turbinate proceeds as part of normal ethmoid development. By 32 weeks of gestation, an invagination in the superolateral portion of the middle turbinate is seen, which provides an ostium for the pneumatization of the middle turbinate. By birth, there are often two to three pneumatized cells within the middle turbinate. Also at this gestational age, the middle ethmoid cells are present and drain into the suprabullar furrow. The suprabullar furrow is a depression inferior to the insertion of the middle turbinate and superior to the ethmoid bulla formed from the secondary furrows of the middle meatus discussed earlier.[7]

The lateral nasal wall is well developed and the turbinates are at their adult proportions by 36 weeks of gestation. Although all structures are mature and the nasal capsule is ossified, the turbinates are not yet completely ossified at their distal aspects. A layer of bone surrounds the maxillary sinus and ossification of the nasolacrimal duct is complete down to the inferior meatus. The nasal airway is relatively narrow at this point, due to turbinate growth. Two weeks later, at 38 weeks, the anterior ethmoids can be identified draining into the ethmoid infundibulum.[2,7,10]

POSTNATAL PERIOD

Growth and maturation of sinonasal structures continue after birth. In the newborn, all paranasal sinuses are present to some degree, and all of the paranasal sinuses experience specific periods of significant postnatal growth. The ethmoid and maxillary sinuses are the only sinuses

readily identifiable at birth. The ethmoids are the most developed sinus group at birth and consist of the anterior and posterior ethmoid groups. The posterior ethmoid group is generally not well identified at birth. This group continues to pneumatize postnatally and will open into the superior meatus.[2,7,9,18] Embryologic development of the ethmoid sinuses is as convoluted as their postnatal anatomy. In 1951, Van Alyea stated, "The honeycomb-like appearance of the cells gives the impression of a melange, a hopeless entanglement, a jumble of cells thrown together with little design of reason, and considered en masse, as they usually are, they may well be regarded as a labyrinth."[7,19] There are two theories regarding ethmoid anatomy and drainage. The first posits that the ethmoid is divided into anterior and posterior groups, with the anterior group physiologically clearing into the middle meatus and the posterior group physiologically clearing into the superior meatus. Histologic studies of embryos demonstrate that in reality there are three ethmoid groups—the anterior, middle and posterior groups—with the anterior group physiologically clearing into the infundibulum, the middle group physiologically clearing into the suprabullar recess, and the posterior group physiologically clearing into the superior meatus. The maxillary sinus is the next most developed at birth. The maxillary sinus demonstrates a biphasic postnatal growth pattern, which coincides with periods of facial growth in early childhood and adolescence. The maxillary sinuses will expand and enlarge around 3 years of age and later between 7 years and 18 years of age. In sinusitis, the maxillary sinus is often the most commonly involved. This fact was recognized by Schaeffer in 1916 when he wrote, "the maxillary sinus is often a cesspool for infectious material from the sinus frontalis and certain of the anterior group of cellulae ethmoidales."[7,9,12,18] During the 2nd and 3rd year of life, the intervening cartilage between the sphenoid sinus and the sphenoid bone is slowly resorbed. This reabsorption allows for attachment of the ossiculum of Bertini to the body of the sphenoid. A period of significant sphenoid sinus pneumatization occurs at 6–7 years of age and is typically completed between 9 years and 12 years. Often, upon completion of sphenoid pneumatization at 12 years, the anterior clinoid processes and pterygoids can become collaterally pneumatized. At birth, the frontal sinus is the least developed and does not appear significantly until 5 or 6 years of age. The maturation of the frontal sinus is completed between 12 years and 20 years of age, and will have an adult volume of 4–7 mL.[8,9,17,18]

CLINICAL PERSPECTIVES

The evolution of endoscopic sinus surgery seems to have paralleled the embryologic development of the sinuses themselves. That is, conventional endoscopic sinus surgery has developed into a minimally invasive, minimally disruptive technique that focuses on addressing the lateral nasal wall and ethmoids. The Messerklinger technique supposes that paranasal disease is predominantly a consequence of impaired function of the lateral nasal wall and the anterior ethmoids, and thus addresses these sites primarily by removing anatomic obstructions and enlarging natural ostia and drainage pathways.[14,20] Therefore, much of conventional endoscopic sinus serves to address the embryologic ethmoid complex, as most of the sinuses are ethmoid in origin.

The uncinate process, hiatus semilunaris, ethmoid infundibulum, ethmoid bulla, anterior and posterior ethmoid sinuses, all the turbinates (except the inferior turbinate) and their associated meati are all ethmoid in origin as they arise from the ethmoturbinals. In fact, even the maxillary and frontal sinuses are ethmoid in origin, so it follows that focusing surgical interventions on the anatomic site from which they were derived would aid in the function of the paranasal sinuses. In the Messerklinger technique, the first step is to remove the uncinate process, which developed from the descending portion of the first ethmoturbinal.[15] Second, the ethmoid bulla is removed, which is the precursor of all of the anterior and middle ethmoid sinuses. The ethmoid bulla originally formed from secondary furrows with formed with the rudimentary middle meatus between the first and second ethmoturbinals.[2,7,10] Subsequent steps in conventional endoscopic sinus surgery, all focus on improving natural drainage pathways established through embryologic sinus development of the ethmoid tissues by removing obstructing anatomy or by opening stenotic ostia.

CONCLUSION

Human embryologic sinonasal development is equally as intricate as the anatomy itself. A thorough understanding of sinonasal embryology helps to provide the otolaryngologist with additional insight into the pertinent surgical anatomy. Knowledge of embryology provides an enhanced understanding of the pathophysiologic processes that affect the paranasal sinuses and provides a unique perspective on how these areas are approached surgically.

REFERENCES

1. Neskey D, Eloy JA, Casiano RR. Nasal, septal, and turbinate anatomy and embryology. Otolaryngol Clin North Am. 2009;42:193-205.
2. Walsh WE, Kern RC. Sinonasal anatomy, function and evaluation. In: Bailey BJ, Johnson JT, Newlands SD (Eds). Head and Neck Surgery—Otolaryngology, 4th edition. Philadelphia: Lippincott Williams & Wilkins; 2006.
3. Markus AF, Delaire J, Smith WP. Facial balance in cleft lip and palate I. Normal development of cleft palate. Br J Oral Maxillofac Surg. 1992;30:287-95.
4. Kasper KA. Nasofrontal connections: a study based on one hundred consecutive dissections. Arch Otolaryngol. 1936;23:322-44.
5. Smith TD, Bhatnagar KP. The human vomeronasal organ. Part II: prenatal development. J Anat. 2000;197:421-36.
6. Kreutzer EW, Jafek BW. The vomeronasal organ of Jacobson in the human embryo and fetus. Otolaryngol Head Neck Surg. 1980;88:119-23.
7. Wang RG, Jiang SC. The embryonic development of the human ethmoid labyrinth from 8-40 weeks. Acta Otolaryngol. 1997;117:118-22.
8. Kennedy DW, Woodworth BA. The paranasal sinuses: embryology, anatomy, endoscopic diagnosis, and treat ment. In: Lee KJ (Ed). Essential Otolaryngology: Head and Neck Surgery, 9th edition. New York: McGraw Hill; 2008.
9. Golub JS, Marks SC, Pasha R. Rhinology and paranasal sinuses. In: Pasha R (Ed). Otolaryngology Head and Neck Surgery: Clinical Reference Guide, 3rd edition. San Diego: Plural Publishing; 2011.
10. Arreola GA, Serna NL, Parra RH, et al. Morphogenesis of the lateral nasal wall from 6 to 36 weeks. Otolaryngol Head Neck Surg. 1996;114:54-60.
11. Wang RG, Jiang SC, Gu R. The cartilaginous nasal capsule and embryonic development of human paranasal sinuses. J Otolaryngology. 1994;23:239-43.
12. Schaeffer JP. The nose, paranasal sinuses, naso-lacrimal passageways and olfactory organ. In: Man: A Genetic, Developmental, and Anatomico-Physiological Consideration. Philadelphia: P. Blakiston's Son & Co; 1920.
13. Bingham B, Wang RG, Hawke M, et al. The embryonic development of the lateral nasal wall from 8 to 24 weeks. Laryngoscope. 1991;101:912-97.
14. Stammberger H. Functional endoscopic sinus surgery: the Messerklinger technique. Philadelphia: B.C. Decker; 1991.
15. Kennedy DW, Bolger WE, Zinreich SJ. Diseases of the Sinuses: Diagnosis and Management. Philadelphia: BC Decker, Inc; 2001.
16. Helfferich F, Viragh S. Histological investigations of the nasal mucosa in human fetuses. Eur Arch Ototrhinolaryngol. 1997;254:S39-42.
17. Vidic B. The postnatal development of the sphenoidal sinus and its spread into the dorsum sellae and posterior clinoid processes. Am J Rhinol. 1968;104:177-83.
18. Libersa C, Laude M, Libersa JC. The pneumatization of the accessory cavities of the fossae during growth. Anat Clin. 1981;2:265-73.
19. Van Alyea OE. Nasal sinuses. An anatomic and clinical consideration. Baltimore: Wilkins & Wilkins; 1951.
20. Kennedy DW, Zinreich SJ, Rosenbaum AE, et al. Functional endoscopic sinus surgery: theory and diagnostic evaluation. Arch Otorhinolaryngol. 1985;111:576-82.

Sataloff's Comprehensive Textbook of

Otolaryngology
Head & Neck Surgery
Rhinology/ Allergy and Immunology

Rhinology/Allergy and Immunology is part of a comprehensive series entitled *Sataloff's Comprehensive Textbook of Otolaryngology—Head and Neck Surgery*. Other volumes in the series are devoted to various specialties within the field, including Otology/Neurotology/Skull Base Surgery, Facial Plastic and Reconstructive Surgery, Laryngology, Head and Neck Surgery, and Pediatric Otolaryngology.

Sixty-four chapters are included in this volume. Anatomy and physiology of the nose and paranasal sinuses are discussed in detail, along with evaluation and imaging. Specific disorders covered include granulomatous and inflammatory diseases, fibro-osseous lesions, neoplasms, epistaxis, rhinosinusitis, osteitis, and many more. Separate sections discuss the evaluation and treatment of allergy and rhinitis, anesthesia, surgery of the nasal airway, surgery for inflammatory sinusitis, and endoscopic skull base surgery and surgery of the orbit. This volume is a thorough guide geared toward practicing otolaryngologists and otolaryngology residents. The text is supplemented by hundreds of original illustrations and images along with surgical video clips.



Marvin P Fried MD FACS graduated from Tufts University School of Medicine, followed by training in otolaryngology at Washington University School of Medicine, where he also served as a Fellow of the National Institute of Neurologic Disease and Stroke. He has been on the faculty of Boston University School of Medicine, Tufts University School of Medicine, and Harvard Medical School, being promoted ultimately to Professor of Otology and Laryngology at Harvard. He served as Chief of the Divisions of Otolaryngology at the Brigham and Women's Hospital, Beth Israel Deaconess Medical Center, and Co-Director of the Head and Neck Oncology Program at Dana-Farber Cancer Institute. Since 1999, he has been Professor and Chairman of the Department of Otolaryngology—Head and Neck Surgery at the Albert Einstein College of Medicine and Montefiore Medical Center. Dr. Fried has held numerous leadership positions throughout his storied career, including serving as president of the American Rhinologic Society, Society of University Otolaryngologists, American Society for Laser Medicine and Surgery, and the American Laryngologic Association. He has received numerous awards and citations on a national and international level. He has authored nearly 200 original reports, reviews, chapters, and books. He has been on the editorial board of the leading journals of otolaryngology including Archives of Otolaryngology—Head and Neck Surgery, Laryngoscope, and International Forum of Allergy and Rhinology.



Abtin Tabaee MD FARS FACS graduated magna cum laude from Duke University and received his medical degree with honors from Cornell University Medical College. He completed residency in Otolaryngology–Head and Neck Surgery at New York Presbyterian Hospital, the combined Columbia University-Cornell University-Memorial Sloan Kettering Cancer Center training program. He subsequently completed a fellowship in Rhinology and Endoscopic Sinus and Skull Base Surgery under the mentorship of Dr Vijay Anand. He is Associate Professor of Otolaryngology at Weill Cornell Medical College in New York. His clinical practice is devoted to tertiary care rhinology with an emphasis on complex, refractory sinusitis and neoplasms of the skull base. He is an active member of the national rhinologic academic community with a dedication to advancing the clinical, scientific and educational aspects of the field. He has published numerous peer-reviewed articles and has spoken nationally on clinical and scientific advances in rhinology.

Available at all medical bookstores
or buy directly from Jaypee Brothers
at www.jaypeebrothers.com or www.jpmedpub.com

JAYPEE BROTHERS
Medical Publishers (P) Ltd.
www.jaypeebrothers.com
Join us on facebook.com/JaypeeMedicalPublishers

Shelving Recommendations
OTORHINOLARYNGOLOGY, RHINOLOGY/ALLERGY AND IMMUNOLOGY

ISBN 978-93-5152-456-4
9 789351 524564