s.com, for detailed information on orthopedic books, visit our website www.jaypeebrothers.com, for detailed information on orthopedic book

Ajit N Damle



Tips & Tricks in Orthopedic Surgery

Foreword
Anand S Kelkar

Contents

Section I Upper Extremity

1. Clavicle Fracture 3
Treatment Methods Available *4*

2. Fracture of Lateral End of Clavicle 12
Clinical Diagnosis *12;* Clinical Assessment of Reducibility *12;*
Treatment: Non-operative *13;* Indications for Internal Fixation *15;*
Incision *16;* Associated Injuries *18*

3. Acromioclavicular Dislocation 20
Patient Position and Surgical Technique *20;* Follow up and Implant Removal *21*

4. Posterior Dislocation of the Shoulder 23
Case Study *23*

5. Fracture Dislocation of the Shoulder 27
Cases 1 and 2 *27;* Few Observations *29;* Message *35*

6. Humerus Neck Fracture 36
Few Common Observations *36;* Two-Part Fracture of Neck of Humerus *38;*
Three or More Parts Impacted/Minimally Displaced Fractures *38;* Locking Plate *41;*
Three or More Parts Fracture of Neck of Humerus: Displaced *42;*
Comment on Bone Grafting *45;* Steps of Bone Grafting and Plate Fixation *46;*
Postoperative Care *47;* Nonunion of Fracture of Neck of Humerus *48*

7. Humerus Shaft Interlock Nailing 50
Interlocking Nailing in Humerus *50;* Case 1: Palliative Surgery to Alleviate Pain *50;*
Case 2: Long Oblique Fracture of Upper/3 Area *50;*
Case 3: Segmental Long Oblique Fracture *50;* Case 4: Repeat Surgeries *52;*
Case 5: Fracture in Lower/4 Area *54;* Case 6: Fracture of Lower/3 Area *56;*
Case 7: Fracture of Lower/4 Area *56;* Case 8: 3-Part Fracture of Mid/3 *57;*
Conclusions from the Above Cases *58*

8. Humerus Holstein and Lower Shaft Fracture 59
Holstein Fracture and Fractures in Lower/4 Humerus *59;* Decades Ago *62;*
Future *63*

9. Humerus Lower-End Exposure 64
Posterior Exposure for Fracture of Lower/4 Humerus *64*

10. Elbow Fracture Dislocation 67
Elbow Lateral Dislocation with Sectoral Fracture of Head of Radius *67*

11. Fracture of Medial Epicondyle of Humerus **69**
Clinical Presentation *69;* Treatment *69;* Technique *70;*
Missed Fracture of Medial Condyle of Humerus *70*

12. Capitellum Fracture **72**
Current Trends *72;* Recommendation *74;* Technique *74;*
Clinical Example *75;* Message *75*

13. Radius Neck Fracture **76**
Fracture Epiphyseal Injury to the Neck/Head of the Radius in Adolescence *76*

14. Forearm Fractures **81**
Fracture of Radius and Ulna *81;* General Comments on Plate and IM Nail as an Implant *81;*
Plate as an Implant *82;* Ununited Fracture of Radius and Ulna after Plate Fixation for Both the Bones *84;* Biomechanical Differences in a Plate and a Nail *86;* Nail as an Implant *89;*
Instruments Required *89;* Technique of Radius Nail Insertion *90;* Open Reduction *91;*
Technique of Ulna Nail Insertion *92;* Importance of Achieving a Good Union in the Ulna *95;*
After a Bone Union, Whether the Plate and the Nail Need to be Removed? *97;*
The Technique of Nail Removal *99;* Ulna Nail Removal *99;* Radius Nail Removal *99;*
Nail Removal by a Vertical Osteotomy *100;* The Technique of Vertical Osteotomy *100;*
Radius *105;* Ulna *107*

15. Bow Fracture of Forearm **108**
Bow (Greenstick) Fracture of Radius and/or Ulna *108;*
Untreated/Missed Bow Fracture *108;* Treatment in a Fresh Case *110;*
Steps in Reduction of a Bow Fracture *111*

16. Refracture of Forearm **113**
Fracture Healing and Refracture in Forearm Bones in Adolescence *113;*
Observations *114*

17. Monteggia Fracture Dislocation **116**
Transverse Fracture of Olecranon with Fracture of Head of Radius and
Associated Posterior Dislocation of Elbow *116*

18. Lower/3 Radius and Ulna Fracture in a Child **122**
Fracture of Lower/3 Radius and Ulna in a Child *122;* Which Material for the Cast? *122*

19. Lower/4 Radius and Ulna Fracture in a Child **124**
Case 1: Transverse Displaced Fracture of the Radius and Ulna *124;*
Case 2: An Oblique Fracture of the Radius with a Serrated Fracture of the Ulna *125;*
Case 3: Late Presentation of Case 1 *126;* Case 4: Late Presentation of Case 2 *127;*
Case 5: Greenstick Fracture of Radius Only *129;* Case 6: Greenstick Fracture of Both
Radius and Ulna *129;* Case 7: Redisplacement in an Oblique Fracture I *129;*
Case 8: Re-Displacement in an Oblique Fracture II *130;* Message *130*

20. Malunited Fracture of Lower/4 Radius in a Child **133**
Malunited Fracture of Lower/4 Radius *133*

21. Inferior RU Dislocation in a Child **136**
Inferior Radioulnar (RU) Joint Dislocation *136*

22. Colles' Fracture **137**
Undisplaced Colles' Fracture *137;* Typical Cases *141*

23. Comminuted Fracture of Lower Radius **153**
Comminuted Fracture of Lower-End of Radius *153*

24. Fracture of Neck of 5th Metacarpal **155**
The Technique *156;* Postoperative Immobilization *157*

25. Emergency Room Technique **158**
Emergency Room Care *158*

Section II Lower Extremity and Pelvis

26. Pelvis and Acetabulum Fractures **175**

27. Fracture of Neck of Femur **190**
Intracapsular Fracture of Neck of Femur *190;* Impacted Fracture of Neck of Femur *191;* Impacted Fracture in the 3rd Decade of Life *195;* Fracture of Neck of Femur in the Middle Age *195;* Basi-Trochanteric Fracture *198;* Ipsilateral Fracture of Neck and Shaft of Femur *200;* Fracture of Neck of Femur in Adolescence *206;* Osteotomy in Fracture of Neck of Femur *209;* Stress Fracture *215;* Types of Partial Hip Replacement *215;* First Aid on Arrival and Diagnosis *217;* Important Steps in a Bipolar Replacement *218;* Few Technical Things *221*

28. Fracture of Trochanter **226**
Problems of Internal Fixation *227;* Fracture Morphology *227;* Assessment of a Fracture *228;* Method of Internal Fixation *228;* Timing and Factors for Surgery *228;* Choice of Implant *228;* Patient Position *229;* Fracture Reduction *229;* Fracture Reduction and Implant Position *229;* Technique of DHS *229;* Tricks in Fracture Reduction and Plate Fixation *231;* Lesser Trochanter Fixation *242;* Primary Bone Grafting *244;* Fracture Collapse and Medialization *244;* Medialization after a Lateral Wall Osteotomy/ Fracture *246;* Trochanteric Stabilization Plate *248;* Special Situation in Inter-Trochanteric Fractures *250;* Long Medial Beak *253;* When Further Medialization and Telescoping is Expected *255;* Mechanical Complications *259;* 95 Degree DCS in Trochanteric Fracture *264;* Intracapsular and Extracapsular Fracture *264;* Few Unfortunate Situations *265;* Technique and Observations in a Bipolar Replacement in a Failed DHS *265;* Re-Attachment of Greater Trochanter *268*

29. Fracture of Subtrochanteric Area **270**
Subtrochanteric Fracture and Jewett Nail Plate ***270;*** Limb Length *271;* Few Case Studies *271;* **Subtrochanteric Fracture: DHS Fixation** ***274;*** Observations and Suggestions *277;* **Subtrochanteric Fracture: DCS** ***279;*** Technique of the Screw Insertion in the Calcar *280;* **Intramedullary Device in Subtrochanteric Fracture** ***286***

30. Fracture of Femur Shaft **290**
The Operation Room at Any Time *291;* Non-operative Methods *292;* Fracture of Femur Shaft in Infants and Adolescence *293;*

Technique to Assess Rotary Alignment in a Shaft Fracture *294;*
Typical Cases *301;* Periprosthetic Fracture *317;*
Special Situations in Removal of Femur Nail and/or a Plate *322*

31. Ipsilateral Femur and Tibia Fractures **324**
On Arrival *324*

32. Fracture of Patella **326**
Incision and Exposure *326;* Timing of Surgery *326;* Anesthesia *326;*
Instrumentation *327;* Implants *327;* Principles *328;* Technique *329;*
Late Presentation of Fracture of Patella *330;* Fracture of Patella of Different Patterns *331*

33. Post-Stiffness Fractures **340**

34. Fracture of Anterior Tibial Eminence **345**
Fixation with a Circlage Wire *345;* Fracture of the Anterior Tibial Eminence with Associated Fracture of Tibial Condyle 346*;* Clinical Examples *346*

35. Fracture of Posterior Tibial Eminence **351**
An Isolated Injury 351

36. Fractures of Tibial Condyle **356**
Introduction to the Fracture of Tibial Condyle ***356****;* Fracture Morphology and Site of Fracture *357;* The Incision for a Good Exposure *360;* Fracture of Tibial Condyle in a Neuropathic Joint *361;* **Bicondylar Fracture of Tibia** ***361****;* Options Possible *365;* **Choice of a Plate for Fracture of Tibial Condyle** ***373****;* Technique of Fracture Fixation *375;* How Can One Achieve This? *377;* **Diagnosis and Missed Fracture of Tibial Condyle** ***377****;* Treatment *380;* Contusion Fracture of Lateral Tibial Condyle *382;* Fracture of Lateral Tibial Condyle in the Elderly *382;* Widening of the Lateral Tibial Condyle *383;* Fracture of Anterior Tibial Eminence and Undisplaced Fracture of Lateral Condyle *383;* Incorrect History and Fasciotomy *384;* **Fracture of Lateral Tibial Condyle** ***384****;* A Split Fracture of Lateral Condyle with Minimum Displacement *384;* Lateral Condyle Elevation from Medial Side *389;* Implant Removal *393;* **Learning from Cases** ***393****;* **Medial Tibial Condyle Fracture** ***404****;* **Nonunion in Fracture of Tibial Condyle** ***410****;* **Post-Stiffness Fracture of Tibial Condyle** ***412****;* **Posteromedial and Posterolateral Condyle Fracture of Tibial Plateau** ***413****;* Clinical Examples *414*

37. Fractures of Tibial Shaft **424**
Non-operative Method *429*

38. External Fixator **436**
Review of the Principles and Technique of Application of External Fixation *436;*
The Components of Assembly *437;* Uniplaner, Unilateral Fixator *440;*
Prestressing and Final Fixation *441;* Triangularization *443;*
Case Examples: Use of an External Fixator *444;*
Lessons Learnt from the Above Cases *447*

39. External Fixator in Open Fracture of Tibia **450**
Fixation of Fibula *450;* Refracture after External Fixator Removal *457*

40. Tibia Interlock Nailing **459**
Few Preferences *459;* Few Practical Observations in Tibia Interlock Nailing *460;*
Segmental Fracture of Tibia *466*

41. Stress Fracture of Tibia **469**

42. Tibia Plate Fixation **475**
Width of a Tibia Plate *475;* Which Surface of Tibia? *475;* Message *480*

43. Tibia Lower MIPO Plate **481**
How would I Plan? *483;* MIPO Technique: Must Obtain a Good Reduction! *485;* Long Segment of Tibia with Comminution *487*

44. Ankle Injuries **491**
Introduction ***491;*** Management in General *491;* Could This have been Avoided? *493;* The Outcome *495;* **Medial Malleolus Fixation** ***495;*** Reduction Technique and Which Implant? *495;* **Ankle Lateral Malleolus** ***500;*** Level of Fracture of the Fibula *502;* X-ray Views and Positioning *502;* Timing of Surgery *503;* Patient Positioning *504;* Implants for the Lateral Malleolus *505;* Non-operative Method: Protocol *507;* Complications after a Fracture of Lateral Malleolus *509;* Late Presentation *510;* Tibio-Fibular Diastasis *512;* **Adduction Fracture of Ankle** ***513;*** **Trimalleolar Fracture of Ankle** ***518;*** **Ankle: What to Avoid?** ***522;*** **Ankle: Medial and Posterior Malleolus Large Fragments** ***529;*** Lateral Column Segmental Fracture *529;* **Ankle Open Fracture** ***530;*** Suggested Steps *531;* **Ankle External Fixation** ***531;*** **Ankle Fractures and Diabetes** ***533;*** **Ankle Fracture in Treated Case of Clubfoot** ***538;*** **Ankle Refracture** ***538;*** **Childress Procedure** ***539;*** **Ankle Injuries in Children** ***540;*** **Tillaux Injury** ***542;*** **Ankle Fusion after Bimalleolar Fracture** ***542;*** Bone Cuts *543* Follow-up Care *545;* Cast Removal *545;* Case Examples *545*

45. Foot Injuries **547**
Stress Fracture of Metatarsals *547;* Not to Do *548;* Fracture of Distal Part of 5th Metatarsal *548*

46. Tips for Better Care **551**

Index *553*

CHAPTER 3

Acromioclavicular Dislocation

X-ray with weights suspended from the wrist reveals grade of an injury. If, patient holds a weight in a hand, the muscles tend to be tight and the skiagram may not reveal exact nature and degree of the AC joint injury.

Prior to innovation of a good method of internal stabilization of the acromioclavicular joint, one would treat such an injury by a Robert Jone strapping method with a satisfactory outcome (Fig. 3.1).

Today, especially in cases with multiple fractures in one limb, stabilization of this joint permits early mobilization of adjacent joints.

For internal fixation, following technique is useful (Fig. 3.2):

PATIENT POSITION AND SURGICAL TECHNIQUE

The steps in patient positioning and surgical exposure are the same as in surgery for fracture of lateral/4 clavicle.

Gelpi retractor is a useful instrument for good exposure. A transverse incision is taken on the lateral/3 clavicle, such that the medial end of the incision is slightly posterior to the clavicle,

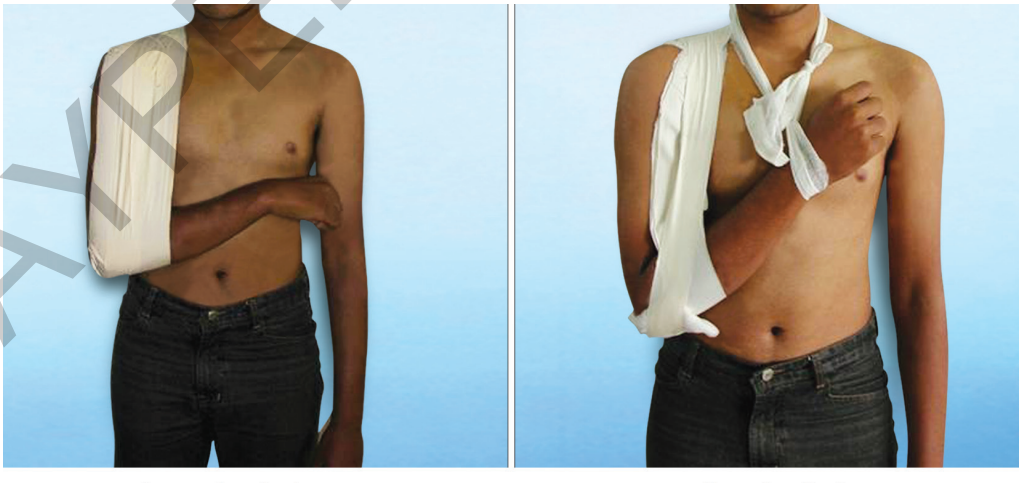

Incorrect method Correct method

Figure 3.1 Strapping

JAYPEE BROTHERS

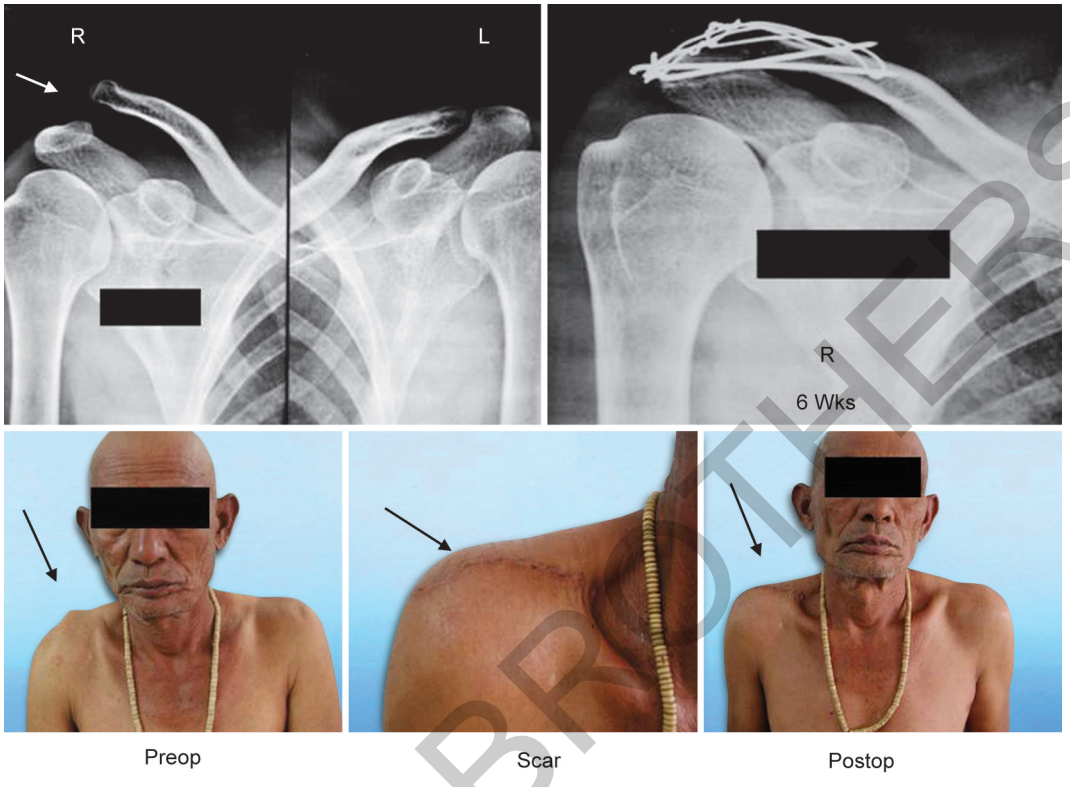

Figure 3.2 X-ray and operative technique

where the K-wire exits from the clavicle. Both the clavicle and the acromion are exposed well and provisional reduction done by pushing the elbow proximally and upwards.

Coraco-clavicular ligaments are studied and possibility of their suturing/reconstruction is assessed.

After passing each K-wire, one should confirm in exact AP and both tangential projections in a 'C' arm and that the K wire is intra-osseous. This is important, as though clinically, the wire may appear to be in the center of the acromion, it could be close to the inferior plate of acromion.

In the recovery room, and later on, while the patient lying on the back, a pillow support under the elbow makes the patient comfortable.

During the follow up, one should encourage active external rotation movement of the shoulder to prevent a stiff shoulder. This is especially important in the elderly and patients with diabetes, in whom, post-immobilization stiff shoulder is common. As in postoperative management of a case of fracture lateral/4 clavicle, it is important to use a neutral shoulder splint. This prevents internal rotation contracture, keeps the patient pain-free and assists easy restoration of the external rotation movement.

FOLLOW UP AND IMPLANT REMOVAL

At the end of 6 weeks, usually the shoulder range is restored well. However, one must follow up the case every month, for first three months, and then, every 2 months. At the end of five to six months, the implants are to be removed and this MUST be emphasized to the patient or else

JAYPEE BROTHERS

an X-ray taken after six to twelve months shows a broken and migrated K-wire! This instruction should be given on the discharge card as well.

It is observed that often a K-wire breaks at the AC joint level due to some motion in the joint and then the medial part of the K-wire migrates medially from the clavicle towards the root of the neck, towards important nerves and vessels.

It is better to remove the implant at the earliest before they migrate quite away from the clavicle and is quite challenging to remove it. At least, the K wires should be removed, leaving the circlage in place. Removal of K wires is a procedure of less magnitude as an unbroken K-wire can be removed axially from the lateral end (Fig. 3.3).

Instead of the K wires, it was recommended to use a malleolar screw as well. I have used the screw as well. However, the thickness of the acromion should be adequate compared to the diameter of the screw.

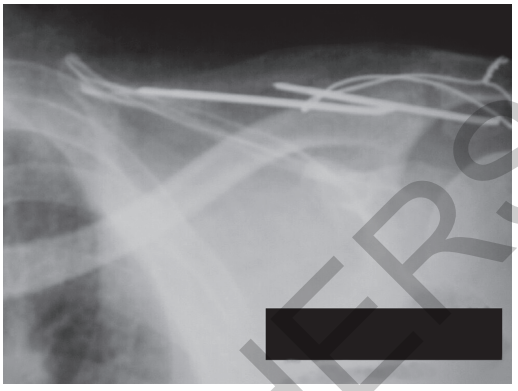

Figure 3.3 K-wire migration

JAYPEE BROTHERS

for detailed information on orthopedic books, visit our website www.jaypeebrothers.com, for detailed information on orthopedic books, visit

Tips & Tricks in Orthopedic Surgery

Salient Features

- A simple and well-illustrated book.
- Explains the uncommon situations as well.
- Contains anatomical region-wise chapters in simple language, with self-explanatory illustrations.
- Formulated to fulfill the need of a practical concise manual for fracture management.
- Special attraction is the illustrated chapter on emergency room technique.
- Illustrations are from a self-made photographic gallery.
- Case assessment on arrival, step-by-step management of fractures, and pre-operative planning are described.
- Instruments and implant options in preoperative preparation and equipment layout in the OR will help to make a procedure safe and comfortable.



Ajit N Damle is a Consultant, Ratna Hospital and Joshi Hospital (Maharashtra Medical Foundation), Pune, Maharashtra, India. He is a surgeon from earlier generation, having passed MS (General Surgery), and later D Ortho and MS (Orthopedics). He is from the first batch of MS (Orthopedics), from University of Pune, Maharashtra, India.

He has work experience of both in rural and urban areas, and is aware of circumstances at both the places. He has an experience of over forty years. He has seen a changing phase of management from non-operative to operative methods. He is the first surgeon from Pune to attend the Davos advanced AO course in fracture management: Theoretical basis and practical management.

He has seen the changing scenario of precision-made implants and instrumentation, invention of power tools, 'C' arm unit and other diagnostic imaging modalities.

He has dedication, devotion and passion for maintaining a wide range of equipment and implants. He is known for personal peri-operative patient care and enjoying well-maintained instrumentation.

Available at all medical bookstores
or buy online at www.jaypeebrothers.com

JAYPEE BROTHERS
Medical Publishers (P) Ltd.
www.jaypeebrothers.com

Join us on facebook.com/JaypeeMedicalPublishers

Shelving
Recommendation
ORTHOPEDICS

ISBN 978-93-5152-484-7