on orthopaedic books, visit our website **www.jaypeebrothers.com,** for detailed information on orthopaedic books, visit our website **www.jaypeebrothers.com**

Get Full Access with added features at **emedicine360.com**

Celebrating 50 Years — Passion, Quality and Innovation in Healthcare Publishing

orthopaedic books, visit our website **www.jaypeebrothers.com,** for detailed information on orthopaedic books, visit our website **www.jaypeebrothers.com**

Get Full Access with added features at **emedicine360.com**

Celebrating 50 Years — Passion, Quality and Innovation in Healthcare Publishing

THE SPINE

Volume 1

Medical & Surgical Management

Alexander R Vaccaro
Brian W Su
Kazuhiro Chiba
Marcel F Dvorak
H Michael Mayer
S Rajasekaran
Luiz R Vialle
Yan Wang
Magdy Gamal Youssef

Foreword
Robert Gunzburg



JAYPEE

Contents

Volume 1

Section 1: General

Magdy Gamal Youssef

1. **The Aging Lumbar Spine** 3
   Isaac L Moss, Howard S An, Stephen P Banco
2. **Anatomy of the Cervical, Thoracic, and Lumbar Spine** 17
   Ahmed S Mohamed, Alex Ching
3. **Clinical Biomechanics of the Spine** 34
   Tristan B Fried, Christopher K Kepler, Paul W Millhouse, John Koerner, Henry Dunn, Benjamin Eachus, Priscilla K Cavanaugh, Anita Mikkilineni, Alexander R Vaccaro
4. **Biomechanics of Spinal Fixation** 42
   Micah Smith, Doug Burton, Darrel S Brodke
5. **Physical and Neurologic Examination of the Spine** 57
   Charla R Fischer, Ryan T Cassilly, Melvin C Makhni, Mark Weidenbaum
6. **Electrodiagnostic Studies of the Spine** 76
   Toshihiko Taguchi, Yasuaki Imajo, Mark L Dumonski
7. **Interventional Spinal Diagnostics and Therapeutics** 85
   Naresh Kumar, Pankaj Kandwal, Wong Hee Kit
8. **Surgical Considerations in the Obese Patient** 103
   H Michael Mayer
9. **Surgical Considerations in the Geriatric Patient** 111
   Xuesong Zhang, Yan Wang
10. **Surgery of the Sympathetic System: Thoracoscopic Sympathectomy** 121
    Sonia Teufack, Joshua E Heller
11. **Stereotactic Radiosurgery of the Spine** 125
    David M Neils, James McGee, Daniel R Fassett
12. **Intraoperative Neuromonitoring during Spine Surgery** 135
    Adam T Doan, Maurice L Goins, Richard W Vogel, Anthony K Sestokas
13. **Anesthesia and Perioperative Care of Patients for Spine Surgery** 151
    Mitch Giffin, Donald Griesdale, Terrence Waters, Kevin Froehlich, Michael Negraeff, Jonathan McEwen, Henrik Huttunen
14. **Spinal Orthoses** 167
    Christopher Bailey, Parham Rasoulinejad, Abdulaziz Alkuwari, David Hannallah

15. **Measuring Outcomes in Spinal Surgery** 176
Christopher K Kepler, Eric Harris

16. **Outpatient Rehabilitation of Lumbar Spine Disorders** 185
Mitchell Freedman, Theodore Conliffe, Zach Broyer, Ari C Greis, Anupam Sinha, Jeffrey Gehret, Natacha Falcon

Section 2: Developmental Disorders
Luiz R Vialle

17. **Embryology of the Spine** 197
George M Ghobrial, Akio Iwanami, EnYaw Hong, Alexander R Vaccaro, James S Harrop

18. **Anatomy and Physiology of Congenital Spinal Lesions** 206
Mamoru Kawakami

19. **Congenital Anomalies of the Cervical Spine** 219
Paul Klimo Jr, Jonathan Reding, Nelson Astur, Melvin D Helgeson, Michael S Muhlbauer

20. **Congenital Anomalies of the Spinal Cord** 239
G Balamurali, S Rajasekaran

21. **Occult Spinal Dysraphism and Tethered Spinal Cord** 258
Elias Dakwar, Amer F Samdani

22. **Surgical and Nonsurgical Treatment of Myelomeningocele and Associated Anomalies** 266
Jean A Ouellet, Fahad H Abduljabbar, Guillaume Raclos, Benoit Jenny, Romain Dayer

23. **Chiari Malformation and Syringomyelia** 295
John Ratliff

24. **The Spine in Osteogenesis Imperfecta** 302
Andrew H Milby, Paul W Esposito, Vincent M Arlet

25. **Scheuermann's Disease** 316
JC Le Huec, E Harly, S Aunoble, A Faundez

26. **Spinal Deformity in Familial Dysautonomia** 321
Eiman Shafa, Suken A Shah

Section 3: Metabolic Disorders
S Rajasekaran

27. **Nonoperative and Operative Management of Paget's Disease** 329
Ganesh Swamy, Kenneth Thomas

28. **Spinal Disorders Associated with Skeletal Dysplasias and Metabolic Diseases** 337
Anuj Singla, Patrick J Cahill

29. **Operative and Nonoperative Management of Rheumatoid Arthritis** 349
Jeremey Reynolds, Christopher Brown

30. **Operative and Nonoperative Management of Ankylosing Spondylitis** 358
K Tack Kim

Section 4: Bone Grafting

Luiz R Vialle

31. Techniques and Complications of Bone Graft Harvesting **371**
Alexander T Brothers, John Koerner, Christopher K Kepler, Alexander R Vaccaro, Paul W Millhouse, Michael Abdou, Priscilla K Cavanaugh, Anita Mikkilineni, Henry Dunn, Benjamin Eachus, Tristan B Fried, Murat Korkmaz

32. Bone Graft Substitutes **379**
John Street

33. Vascularized Bone Grafts in Spine Surgery **400**
Gregory Gebauer

34. Bone Morphogenetic Protein and Lumbar Fusion **411**
Bhavuk Garg, Alok D Sharan

Section 5: Cervical Spine

Brian W Su

35. Standard and Extended Transoral Approaches to the Upper Cervical Spine **421**
Morio Matsumoto

36. Anterior Cervical Approaches **430**
Dennis Q Chen, Brian C Werner, Adam L Shimer

37. Anterior Approaches to the Cervicothoracic Junction **439**
Adewale Adeniran, Adam M Pearson

38. Evaluation and Treatment of Axial Neck Pain **443**
Jesse L Even, James D Kang

39. Cervical Spondylotic Radiculopathy: Clinical Evaluation and Nonoperative Treatment **452**
G Balamurali, S Rajasekaran

40. Surgical Treatment of Cervical Spondylotic Radiculopathy including Anteriorly and Posteriorly Based Procedures **463**
Klaus John Schnake

41. Cervical Spondylotic Myelopathy: Clinical Evaluation and Nonoperative Treatment **472**
Andrew H Milby, Mark Tantorski, Scott D Daffner, Vincent M Arlet, Harvey E Smith

42. Anteriorly Based Surgical Treatment of Cervical Spondylotic Myelopathy Excluding Ossification of the Posterior Longitudinal Ligament **480**
Toshitaka Yoshii, Atsushi Okawa

43. Posteriorly Based Surgical Treatment of Cervical Spondylotic Myelopathy **490**
Brian W Su, Nestor Fiore

44. Natural History and Surgical Treatment for Ossification of the Posterior Longitudinal Ligament **507**
Kraig Kristof, Jeffrey S Fischgrund

45. Occipitocervical and Atlantoaxial Fusion **525**
Han Jo Kim, Jin S Yeom, Ron A Lehman, K Daniel Riew

46. Instrumentation of the Subaxial Spine **536**
Lei Shi, Wei Lei, Geng Cui, Yabo Yan, You Wang, Ningtao Ren, Brian W Su

47. Surgical Treatment of Congenital Foramen Magnum Lesions: Transoral Approach and Foramen Magnum Decompression **552**
Paolo Perrini , Nicola Di Lorenzo, James A Sanfilippo

48. Kyphotic Cervical Deformity Correction including Post-traumatic and Post-laminectomy Kyphosis **562**
Lyle C Young, John M Rhee

49. Osteotomies in the Cervical Spine **570**
Hossein Elgafy, Erik Peterson

50. Management of Soft Tissue Injuries of the Cervical Spine: Whiplash Injury and Associated Disorders **579**
David H Kim, Eric Carkner, Gyu Ho Lee

51. Closed Management of Cervical Spine Injuries **590**
Peter Lewkonia, Saurabh Rawall

52. Cervical Spine Injuries in the Athlete: Return-to-Play Criteria **604**
Venu M Nemani, Han Jo Kim, K Daniel Riew

53. Upper Cervical Spine Trauma **610**
Christopher A Burks, Adam L Shimer

54. Nonoperative and Operative Treatment of Subaxial Cervical Spine Trauma including Dislocations **626**
Sreeharsha V Nandyala, Alejandro Marquez-Lara, Ankur S Narain, Fady Y Hijji, Daniel K Park, Kern Singh

55. Revision Anterior and Posterior Cervical Spine Surgery **636**
Han Jo Kim, K Daniel Riew

Section 6: Spinal Cord Injury

Kazuhiro Chiba

56. Acute Management of Spinal Cord Injury **647**
Shelly Wang, Jefferson R Wilson, Michael G Fehlings

57. Pharmacology and Timing of Surgical Intervention for Spinal Cord Injury **662**
Marcel F Dvorak, Melissa Nadeau, Brian K Kwon

58. Pediatric Spine Trauma and Spinal Cord Injury **669**
Paul C Celestre, Ashish Upadhyay, John R Dimar II

59. Penetrating Spinal Cord Injury **680**
Christian P DiPaola, Thomas A St John

60. Novel Approaches to Neural Repair and Regeneration after Spinal Cord Injury **691**
Murat Korkmaz, John Koerner, Paul W Millhouse, Abhijeet B Kadam, Christopher K Kepler, Alexander R Vaccaro, Priscilla K Cavanaugh, Anita Mikkilineni, Henry Dunn, Benjamin Eachus, Tristan B Fried, Priyanka Kumar

61. Nutrition in Spinal Cord Injury **706**
Jordan Glaser, Kris Radcliff

62. Rehabilitation of the Spinal Cord Injury Patient **716**
Jesse D Ennis, Rhonda Willms, Andrea Townson

Volume 2

Section 7: Lumbar Spine 1

H Michael Mayer

63. Anterior and Lateral Exposures to the Lumbosacral Spine **733**
Priscilla K Cavanaugh, Henry Dunn, Paul W Millhouse, Christopher K Kepler, Alexander R Vaccaro, Murat Korkmaz, Michael Abdou, Anita Mikkilineni, Benjamin Eachus, Tristan B Fried

64. Posterior Approaches to the Lumbosacral Spine **744**
Se Young Pyo, Peter Grunert, Marjan Alimi, Guang-Ting Cong, Roger Härtl, Rodrigo Navarro, Micaella Zubkov

65. Surgical Approaches and Reconstruction of the Sacrum **757**
Nicolas Dea, Peter Paul Varga

66. Spinal Pelvic Fixation Techniques **766**
George M Ghobrial, Christopher M Maulucci, Joshua E Heller

67. Lumbar Pedicle Screw Fixation **771**
Scott D Daffner, David B McConda

68. Transfacet, Translaminar, and Cortical Screw Fixation of the Lumbar Spine **779**
Kushagra Verma, Jeffrey Rihn, Alexander R Vaccaro

69. Anterior Lumbar Interbody Fusion **786**
Ning Lu, Yan Wang, Andrew P White

70. Posterior Lumbar Interbody Fusion **804**
Kelli L Crabtree, Paul M Arnold, Karen K Anderson

71. Transforaminal Lumbar Interbody Fusion **813**
Takashi Tsuji

72. Lateral Lumbar Interbody Fusion Techniques: Degenerative and Scoliotic **817**
Todd Lansford, Murat Pekmezci, Vedat Deviren

73. Nonoperative Treatment of Lumbar Disc Herniation **829**
Teija Lund, Steven Zeiller, Jens-Ivar Brox

74. Open Operative Treatment of Lumbar Disc Herniations **841**
Luca Papavero

75. Cauda Equina and Conus Medullaris Syndrome **855**
Rojeh Melikian, Thomas D Cha

76. Lumbar Nucleus Pulposus Replacement **863**
Timothy Roberts, James P Lawrence

77. Annular Disease and Surgical Treatment of the Annulus **875**
Daniel Tarazona, Gregory D Schroeder, Mayan Lendner, Satishchandra Gore

78. Surgical Management of Lumbar Degenerative Disc Disease **882**
Sandeep N Gidvani, Babak Khamsi, Jeffrey C Wang

Section 8: Lumbar Spine 2

Yan Wang

79. Nonoperative Treatment of Lumbar Stenosis **907**
Keya Mao, Peng Li

80. Lumbar Spinal Stenosis: Open Operative Treatment **915**
Anuj Singla, Jonathan R Mason, Francis H Shen

81. Lumbar Interspinous Implants **924**
Dennis S Meredith, Alan S Hilibrand

82. Operative Treatment of Low-grade Lumbar Degenerative Spondylolisthesis **930**
Shyam Ajit Patel, Naderafshar Fereydoonyan, Brian W Su, D Greg Anderson

83. Operative Treatment of High-grade Lumbar Spondylolisthesis **942**
Eijiro Okada, Morio Matsumoto

84. Nonoperative Treatment of Fractures of the Thoracolumbar Spine **949**
FC Oner, Agnita Stadhouder, Wilco Jacobs

85. Surgical Indications and Management of Thoracolumbar Fractures **959**
James T Dunlap, Joon Y Lee, Mark S Eskander

86. Thoracolumbar Trauma: Lower Lumbar Fractures **970**
Klaus John Schnake, Çağdaş Bicen

87. Surgical Treatment for Sacral Fractures **978**
Kota Watanabe, Chambliss Harrod

88. Nonoperative and Operative Treatment of Sacroiliac Joint Dysfunction **990**
Andrew K Simpson, Thomas D Cha

89. Tarlov Cysts **997**
Lindsey Ross, Doniel Drazin, Frank Acosta

90. Failed Back Surgery Syndrome **1005**
Srinivasu Kusuma, Jonathan Allen, Munish C Gupta

Section 9: Motion Preservation

Alexander R Vaccaro

91. Biomechanics of Motion Preservation Strategies **1023**
Hans-Joachim Wilke

92. Posterior Pedicle-Based Dynamic Stabilization of the Lumbar Spine **1034**
Bernhard Jeanneret, Stefan Schaeren

93. Total Facet Replacement **1038**
Darren R Lebl, Frank P Cammisa, Federico P Girardi, Alexander R Vaccaro

94. Lumbar Disc Replacement **1043**
Michael F Duffy, Jack E Zigler

95. Cervical Disc Replacement **1059**
Beejal Y Amin, Paul D Ackerman, Hai LE, Rishi Wadhwa, Kyle Malone, William Smith, Praveen Mummaneni, Alexander R Vaccaro

Section 10: Thoracic Spine

Kazuhiro Chiba

96. Thoracic Disc Herniation **1071**
Yukihiro Matsuyama

97. Thoracoscopic Approach for Spinal Disorders **1077**
Eli M Baron, Doniel Drazin, Neel Anand, J Patrick Johnson

98. Thoracic Discectomy and Corpectomy **1085**
Brian C Werner, Francis H Shen

99. Thoracic Pedicle Screw Fixation **1094**
Ivan Cheng, Michael P Stauff

100. Direct Lateral Thoracic Interbody Fusion **1105**
Henry Dunn, Christopher K Kepler, Inge Preissl, Alexander Geftler, Ute Lingemann Meyer, Daniel Rosenthal, Paul W Millhouse, Alexander R Vaccaro, Tristan B Fried, Murat Korkmaz, Michael Abdou, Priscilla K Cavanaugh, Anita Mikkilineni, Benjamin Eachus

Section 11: Pediatrics

S Rajasekaran

101. Back Pain in Children and Adolescents **1113**
Yan Wang, Hui Liu

102. Congenital Scoliosis **1126**
Michael Ruff, Doug Burton

103. Neuromuscular Scoliosis **1138**
Kirk W Dabney, Peter Gabos, Julieanne Sees

104. Nonoperative Treatment of Adolescent Idiopathic Scoliosis **1160**
David P Roye Jr, David L Skaggs, Nicholas Feinberg, Jennifer Hope

105. Operative Treatment of Adolescent Idiopathic Scoliosis **1174**
Daniel Sucato, John Vorhies

106. Anterior Lumbar and Thoracolumbar Correction and Fusion for AIS **1186**
Gene Cheh, Yongjung J Kim

107. Short Segment 'Bone-on-Bone' Fusion for Adolescent Idiopathic Scoliosis **1199**
Robert W Gaines, Gregory Gebauer

108. Spondylolysis and Spondylolisthesis in Children **1209**
Alexander J Schupper, Paul W Millhouse, Jonathan Krystal, Roberto Postigo

109. Immature Spine and Athletic Injuries **1228**
Toshinori Sakai, Koichi Sairyo

Section 12: Adult Deformity

Alexander R Vaccaro

110. Sacropelvic Morphology and Spinopelvic Alignment **1241**
Alexander J Schupper, Justin K Scheer, Justin S Smith, Benjamin Blondel, Virginie Lafage, Frank Schwab, Christopher P Ames

111. Nonoperative Treatment of Adult Deformity **1254**
Manish Singh, Justin S Smith, Christopher I Shaffrey

112. Preoperative Considerations for the Adult Deformity Patient **1265**
Andrew Tarleton, Sigurd Berven, Alexander R Vaccaro

113. Surgical Treatment of Adult Thoracolumbar Idiopathic Scoliosis **1275**
Stephen J Lewis, Noah DH Lewis

114. Surgical Management of Adult Lumbar Degenerative Scoliosis **1285**
Yan Wang, Guoquan Zheng, Arvind Bhave, Jun Sup Kim, Troy Mounts, Alexander R Vaccaro

115. Osteotomy Techniques for Coronal and Sagittal Plane Thoracolumbar Deformities **1295**
Noriaki Kawakami, Melvin D Helgeson

116. Surgical Treatment of Spinal Deformities in the Setting of Osteoporosis **1306**
Tobias A Mattei, Carlos R Goulart, Daniel R Fassett

Section 13: Tumor, Vascular Malformations, and Infection

Marcel F Dvorak

117. Primary Bony Spinal Lesions **1325**
Thomas R Hickernell, Chandhanarat Chandhanayingyong, Francis Y Lee

118. Tumors of the Sacrum **1343**
David B Bumpass, Jacob M Buchowski, Corey O Montgomery, Douglas J McDonald

119. Metastatic Tumors of the Spine **1358**
Stefano Boriani, Gisberto Evangelisti, Simone Colangeli, Riccardo Ghermandi, Alessandro Gasbarrini

120. Intradural Intramedullary and Extramedullary Tumors **1375**
Tony Goldschlager, Nicolas Dea

121. Spinal Intradural Vascular Malformations **1392**
Giuseppe MV Barbagallo, Francesco Certo, Vincenzo Albanese, Francesco Signorelli

122. Spinal Infections, Pyogenic Osteomyelitis, and Epidural Abscess **1408**
George M Ghobrial, Srinivas K Prasad

123. Spinal Tuberculosis **1417**
S Rajasekaran, Rishi Mugesh Kanna, T Ajoy Prasad Shetty

Section 14: Complications

Marcel F Dvorak

124. Medical Complications in the Adult Spinal Patient **1447**
Daniel A Baluch, Ngoc-Lam Nguyen, Alpesh A Patel

125. Management of Cerebral Spinal Fluid Leaks **1456**
James T Dunlap, James D Kang

126. Complications of Lumbosacral Spine Surgery **1464**
Sumihisa Orita, Kazuhisa Takahashi

127. Management of Intraoperative Neurologic Loss **1481**
Anne Kathleen B Ganal-Antonio, Kenneth MC Cheung

128. Complications of Anterior and Posterior Cervical Spine Surgery **1500**
Jason Pui Yin Cheung, Keith Dip Kei Luk

129. Complications of Anterior and Posterior Thoracic Spine Surgery **1515**
Atsushi Seichi

Section 15: Minimally Invasive Surgery and Navigation
Alexander R Vaccaro

130. Minimally Invasive Endoscopic Cervical Foraminotomy **1523**
Anuj Prasher, Bobby Tay

131. Minimally Invasive Techniques of the Thoracic Spine **1535**
Steven J Fineberg, Matthew Oglesby, Fady Y Hijji, Ankur S Narain, Kern Singh

132. Minimally Invasive Lumbar Surgery for Disc Herniations and Stenosis **1545**
Michael Abdou, Abhijeet B Kadam, Paul W Millhouse, John Koerner, Alexander R Vaccaro, Henry Dunn, Benjamin Eachus, Tristan B Fried, Priscilla K Cavanaugh

133. Minimally Invasive Transforaminal Lumbar Interbody Fusion **1556**
William Tally, Giuseppe MV Barbagallo

134. Minimally Invasive Deformity Surgery **1562**
Michael Y Wang, Hamadi Murphy, Mayan Lendner, Christie Stawicki, Taolin Fang, Alexander R Vaccaro

135. Use of Navigation in Spine Surgery **1572**
T Ajoy Prasad Shetty, S Rajasekaran, Alexander R Vaccaro

Index *1599*

CHAPTER 65

Surgical Approaches and Reconstruction of the Sacrum

Nicolas Dea, Peter Paul Varga

Snapshot

- Anatomy
- Classification of Sacral Resection
- Surgical Approach
- When is Reconstruction Necessary?
- Reconstruction Strategies
- Outcomes

INTRODUCTION

Pathologies involving the sacrum are diverse and rare. Approach and, when necessary, reconstruction of the sacrum is challenging because of its unique anatomical features, biomechanical role, and close apposition to other important structures outside the usual expertise of the spinal surgeon. The complex anatomy of the pelvic region makes resection of sacral tumors a multidisciplinary undertaking. Proficiency in the different surgical techniques of sacral reconstruction is often hard to acquire because of the rarity of their application.

Tumors of the sacrum account for 1–7% of all spinal tumors.[1] Because of their nonspecific initial symptomatology, they tend to be large and locally advanced at the time of diagnosis. They can also be overlooked radiologically, both because of incomplete sacral imaging techniques and because of the intrinsic sacral anatomical properties, which can make lesions in this area hard to define.[2] The majority are metastatic lesions originating from either hematogenous or solid primary malignancies. The most common primary malignant tumor of the sacrum is a chordoma, while the most common benign tumor is a giant cell tumor. The optimal management of sacral tumors is determined by numerous factors including anatomical characteristics of the tumor, preoperative functional status of the patient, and, more importantly, intrinsic biology of the tumor.[3] While oncologic cure is seldom a goal in metastatic disease, it often is for primary spinal tumors. In fact, surgery plays a key role in the management of most primary tumors. The Enneking classification, originally described for tumors of the appendicular skeleton, remains the fundamental foundation for approaching primary mesenchymal tumors, including those originating from the spine.[4] For each Enneking stage, a specific resection margin is recommended.[5] Because most primary tumors originating in the sacrum are chemo- and radioresistant, en bloc resection with adequate margins is often the only method of achieving local control. Moreover, adhering to the Enneking principles has been correlated with reduced local recurrence rate, improved tumor-free survival, and improved life expectancy, while maintaining acceptable morbidity and health-related quality of life outcomes.[6-13] Respecting the Enneking principles for aggressive benign and malignant tumors of the sacral region is technically challenging, both from a resection and reconstruction perspective.

This chapter focuses on surgical decision making for reconstruction of the sacrum. Relevant anatomy, biomechanics, reconstruction indications, and strategies are reviewed. A more detailed discussion on sacral tumors will be provided in other chapter of this book.

JAYPEE BROTHERS

ANATOMY

A basic tenet of performing any surgical procedure is a good understanding of the relevant anatomy. The human sacrum consists of five separate sacral vertebrae that fuse to form a large triangular-shaped bone. Fusion of the sacrum begins at puberty and is usually complete by 25–33 years of age.[14] The end result reflects the axial load-bearing function of the human sacrum, incorporating the wide sacral ala on each side. The sacrum is concave anteriorly, both in the rostrocaudal and in the mediolateral planes, and convex posteriorly. The sacrum is separated anteriorly from the upper part of the rectum by the sacral plexus, and, at the lower part of the rectum, only a dense fascia intervenes between the two structures.[15] The sacrum articulates superiorly with the L5 vertebral body through the L5-S1 intervertebral disc and the facet joints; inferiorly with the coccyx through ligamentous attachments or bony union; and on each side with the iliac bone through the sacroiliac joints. The sacroiliac joints are synovial structures and end at the S2 level. The lumbosacral junction is located anterior to the sacroiliac joint complex, creating a rotatory force on the sacrum. The force vector is counterbalanced by strong ligaments: the interosseous and posterior sacroiliac ligaments are the strongest of these, resisting forward tilt of the upper end of the sacrum. Other ligaments includes the sacrotuberous and sacrospinous ligaments, which resist posterior tilt of the inferior sacrum and coccyx, and the iliolumbar ligaments, which resist forward migration of the L5 vertebral body.[16] Forces are transmitted from the spine to the sacrum and then to the pelvic girdle via the sacroiliac joints.[17] Consequently, spinopelvic stability is not compromised as long as these structures are preserved (*see* below).

Although a detailed vascular and neural anatomy of the pelvic region is beyond the scope of this chapter, its knowledge is essential before undertaking sacral resection. In fact, at presentation, sacral tumors are often so large that they may distort normal vascular anatomy. The presacral venous plexus may become congested and dilated and be a cause of significant blood loss if overlooked. Preoperative embolization is very useful to better define the patient's specific vascular anatomy and to limit intraoperative blood loss.

CLASSIFICATION OF SACRAL RESECTION

Fourney et al.[18] reported on the Texas MD Anderson Cancer Center experience with sacral neoplasm.[18] On the basis of their experience on 29 consecutive patients, who underwent en bloc resection of primary sacral tumors, they proposed a novel classification based on the level of nerve root sacrifice as opposed to the level of osteotomy. They divided the type of sacral resections into two groups: those used for midline lesions and those used for eccentric tumors. The midline sacral resection group was further subdivided based on the level of the nerve root sacrifice (Fig. 65.1). Low sacral amputation was defined as sacrifice of S4 nerve roots and below, midsacral amputation as sacrifice of at least one S3 nerve root, and high sacral amputation as sacrifice of at least one S2 nerve root or when only unilateral S1 root sacrifice was necessary. For more locally advanced tumors, when both S1 nerve roots had to be divided a total sacrectomy was performed. When the tumor extended beyond the sacrum to involve the lumbar spine as well, a translumbar amputation or "hemicorporectomy" was performed. The eccentric group included en bloc resection of one sacroiliac joint and hemisacrectomy. This classification of sacral resection has since been used by other centers with lots of experience in dealing with en bloc sacral resections.[19] Another surgical classification for sacral tumors based on anatomical position in the sagittal and cross-sectional plane, as well as anterior extension into the pelvic cavity, has also been proposed.[20]

SURGICAL APPROACH

Once local and systemic staging is completed, histopathological diagnosis is confirmed, and en bloc resection deemed necessary based on evidence-based principles, multidisciplinary surgical planning takes place. It cannot be overstated that most of these cases require multidisciplinary expertise. The level of the sacrectomy is decided based on the extent of bony involvement and the most proximal roots involved. The expected neurological deficits should then be discussed with the patient to obtain operative consent. The relationship between the anterior extension of the tumor, rectum, and retroperitoneal vessels will also guide the choice of the approach. If the posterior wall of the rectum is involved, a general surgery colleague should be consulted and a diverting colostomy considered. Vascular structures within the pelvis can also be displaced or involved by the tumor, in which case a vascular surgeon can be of a great aid to facilitate the dissection. Finally, a plastic surgeon is often required because of the extensive cavity created by the resection and to assist with flap closure.

JAYPEE BROTHERS

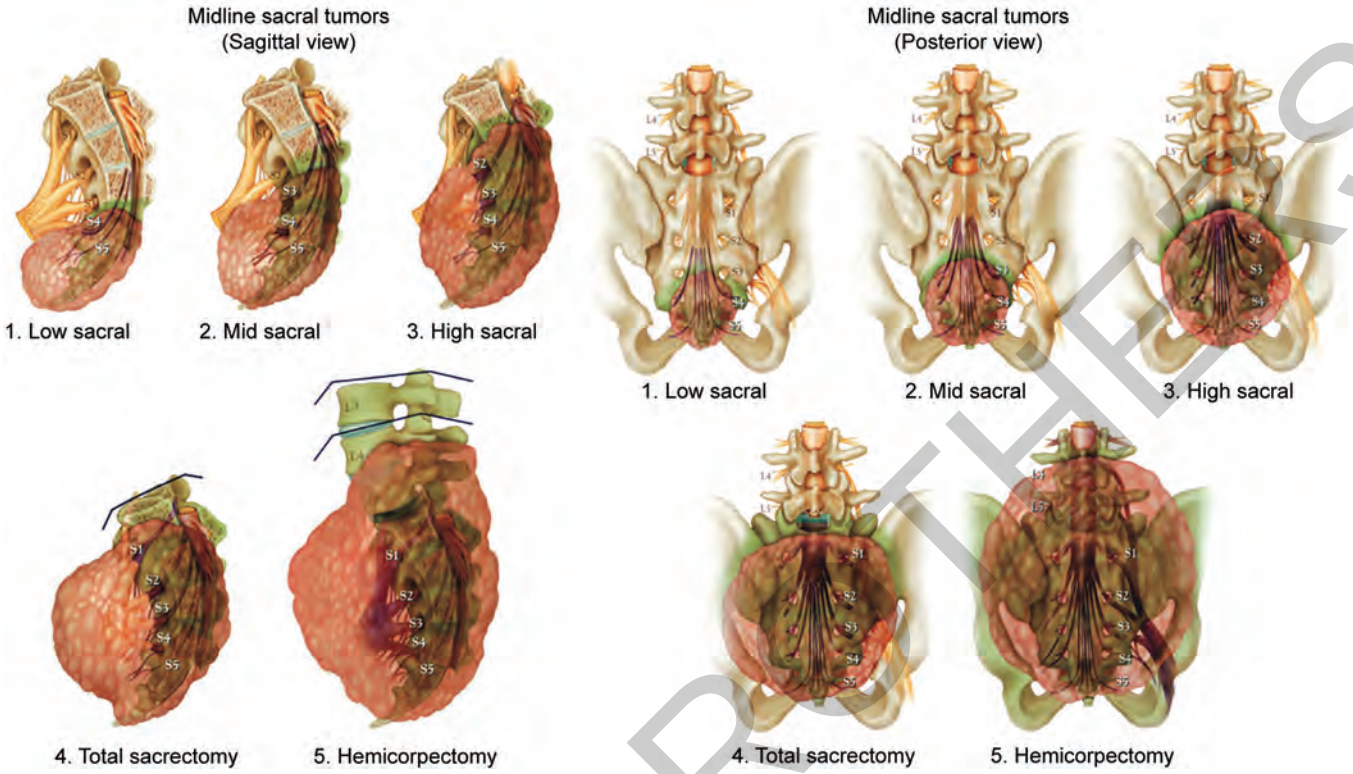

Fig. 65.1: Levels of sacral resection for midline sacral tumors.
Source: With permission from Fourney DR, Rhines LD, Hentschel SJ, et al. En bloc resection of primary sacral tumors: classification of surgical approaches and outcome. J Neurosurg Spine. 2005;3(2):111-22.

Anterior, posterior, combined, and simultaneous approaches have been described in the literature. The goals of the anterior approach are to dissect the anterior portion of the tumor and to ligate the main tumoral vessels.[21] It allows for careful mobilization of the rectum as well. The anterior approach is also used to harvest the rectus myocutaneous flap that can be used to fill the surgical void in high sacrectomies. The posterior approach is then used to deliver the tumor and to proceed with reconstruction. The combined anterior–posterior approach is mainly used for hemicorporectomy, total sacrectomies, and selected high sacrectomies.[16,19,21,22] A simultaneous anteroposterior approach is also described,[23] but is often not the preferred approach since it is difficult to expose both anteriorly and posteriorly—as well as when they are done separately—and the approach complicates subsequent reconstruction.[16] The posterior approach alone is appropriate for most high, middle, and low sacral resections.[16,19] Mc Loughlin et al.[24] described a total sacrectomy performed in a single-stage posterior approach. There are three factors that preclude the use of a single-stage posterior approach: tumoral involvement of the rectum, tumoral extension into the lumbar spine requiring a hemicorporectomy, and involvement of the iliac vessels.[25]

WHEN IS RECONSTRUCTION NECESSARY?

Aside from the already challenging primary oncologic goal of the surgery, restoration of spinopelvic stability is also of paramount importance. A landmark biomechanical study by Guntenberg in the 1970s showed that a partial sacrectomy done at the S1-2 level weakens the pelvic ring by about 30%, and a more extensive submaximal sacrectomy done 1 cm below the sacral promontory, preserving 50% of the sacroiliac joints, weakens it by about 50%.[26] On the basis of the physiologic loads transmitted from the sacrum to the pelvic girdle, the authors concluded that weight bearing was safe without reconstruction, as long as at least 50% of the sacroiliac joints were preserved on each side, corresponding to at least the upper half of the S1 vertebra. This indication for stabilization is accepted in the literature.[18,19] Even if the sacrospinous and sacrotuberous

JAYPEE BROTHERS

ligaments are transected with these lower sacral resections, the strong sacroiliac joint-posterior sacroiliac ligament complex suffices to assure stability. The potential for fatigue fracture after high sacral amputation seems to be of limited clinical significance. Bergh et al.[7] reported that six of 18 patients with high sacral resection (at or above the S1-S2 disc space) developed fatigue fracture in the remaining part of the sacrum.[7] However, only one patient suffered from disabling pain despite surgical intervention. No patient with sacral amputation below the S1-S2 disc space developed insufficiency fractures. Another biomechanical study, however, concluded that reconstruction should be considered when the sacrectomy is done cephalad to the S1 foramina.[27] Hugate et al.[27] also showed that the pattern of failure was vertical fractures through the sacrum (most often Dennis zone II), while none of their specimens failed at the sacroiliac joint level.[27] Another more recent biomechanical analysis showed that partial transverse sacrectomy involving S1 could result in rotational instability, and resection of greater than half of S1 further leads to compressive instability. The authors then concluded that reconstruction should be considered if the resection is at or above the S1–S2 level.[28]

When a total sacrectomy is performed, the lumbar spine is entirely disconnected from the pelvic ring and hence surgical reconstruction is indicated despite the added complexity and potential morbidity.[18,19,29] Reconstruction allows for earlier mobilization and return to activities. Some authors advocate that reconstruction should be avoided because of the risk of infection and hardware failure.[30,31] Stability is then dependent on the formation of a biologic sling composed of muscle and scar tissue between the pelvis and the lumbar spine. Prolonged immobilization is however required if no reconstruction is attempted. For hemisacrectomy and unilateral sacroiliac joint removal, some recommend upfront stabilization[19] (Fig. 65.2), while some do not routinely perform lumbopelvic reconstruction if the contralateral joint is intact and there is no anterior pelvic deficiency.[18]

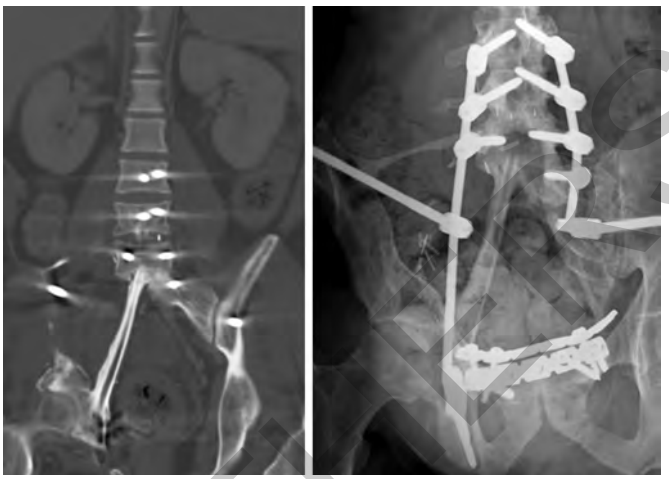

Fig. 65.2: Example of a complex reconstruction using a vascularized fibula graft, and instrumentation bridging L3 to ischial tuberosity on the right, and L3 to ileum on the left following a hemipelvectomy and complete resection of the right-sided sacroiliac joint.

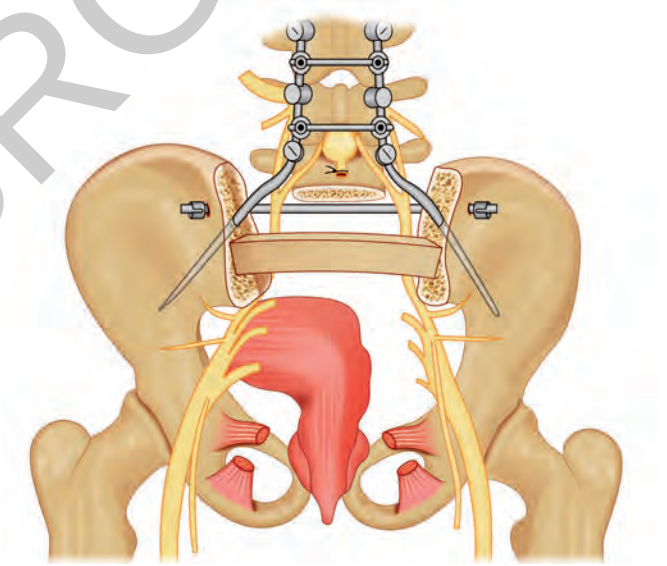

Fig. 65.3: Illustration of the initial modified Galveston L-rod technique.
Source: With permission from Gokaslan ZL, Romsdahl MM, Kroll SS, et al. Total sacrectomy and Galveston L-rod reconstruction for malignant neoplasms. Technical note. J Neurosurg. 1997;87(5):781-7.

RECONSTRUCTION STRATEGIES

Multiple lumbopelvic reconstruction techniques have been described.[16,19,21,29,32-38] Most techniques used are a modification of the Galveston method initially described for neuromuscular scoliosis.[39] Gokaslan et al.[29] described a modified Galveston L-rod technique for sacral reconstruction after total sacrectomy in two patients harboring a sacral giant-cell tumor. The original technique involves the placement of bilateral L3-L5 pedicle screws. A vertical rod is then placed on each side from the pedicle screws proximally and then bent laterally in between the two cortices of the ilium distally. Cross-connectors are used to secure the construct. To prevent axial rotation, a transiliac bar is then placed to fix iliac bones to each other. A tibial allograft is used to close the space between the two ilia. A combination of autologous and allogeneic bone graft is

JAYPEE BROTHERS

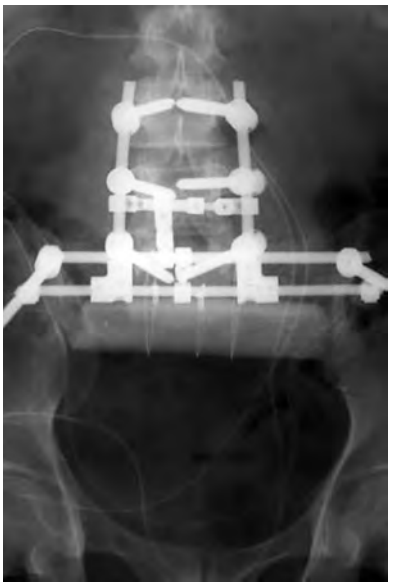

Fig. 65.4: Postoperative X-ray, depicting the updated modified Galveston technique.
Source: With permission from Gallia GL, Haque R, Garonzik I, et al. Spinal pelvic reconstruction after total sacrectomy for en bloc resection of a giant sacral chordoma. Technical note. J Neurosurg Spine. 2005;3(6):501-6.

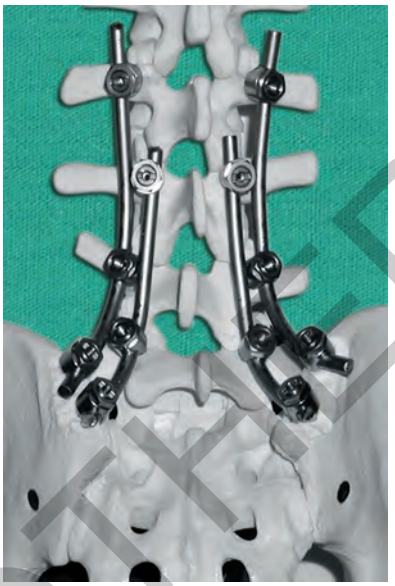

Fig. 65.5: Model showing the four-rod with bilateral dual-iliac screws technique.
Source: Spine by Lippincott Williams & Wilkins. Reproduced with permission of Lippincott Williams & Wilkins in the format reprint in a book/textbook via Copyright Clearance Center.

placed from the transverse processes of L3 to the medio-posterior aspect of the ileum to achieve solid bony union (Fig. 65.3). With follow-up, this construct was found to suffer from some biomechanical limitations. More specifically, this method does not optimally resist axial and rotational forces across the horizontal axis resulting in rod breakage between the L5 pedicle screws and the ilium, and loosening of the iliac portion of the rod, respectively. To overcome these limitations, Gallia et al.[36] described an updated version of the modified Galveston technique using poly-axial iliac screws instead of the L-shaped rod. Iliac screws overcome the potential drawback of the difficulty associated with contouring the Galveston rods. A transiliac bar was used and connected to the pedicle screw rods using L-shaped connectors. A rod connecting the iliac screws was then linked to the construct using various cross-connectors (Fig. 65.4).[36] Later, a four-rod technique involving bilateral dual iliac screws was described to better address the problem of rod fracture at the lumbo-pelvic junction (Fig. 65.5).[32]

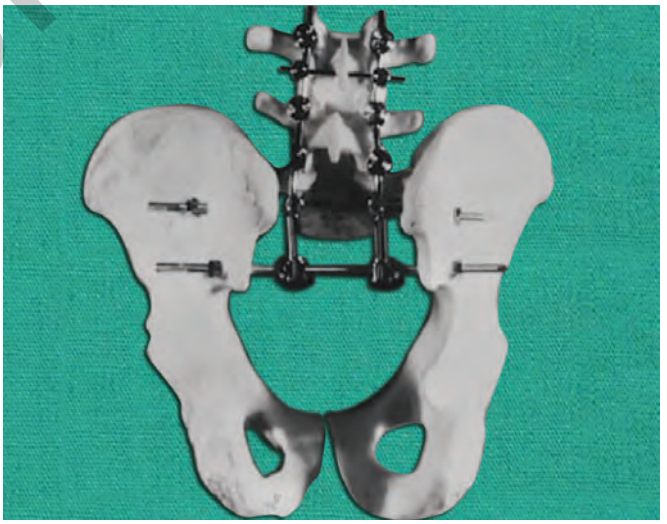

Fig. 65.6: Model depicting the triangular frame reconstruction method.
Source: Journal of Orthopaedic Science by Springer Japan KK. Reproduced with permission of Springer Japan KK in the format use in a book/textbook via Copyright Clearance Center.

Another method of spinopelvic reconstruction, called triangular frame reconstruction, was described by Murakami et al.[40] After a total sacrectomy has been performed, the spinal column is pulled down (3 cm) and L5 is affixed to the ilium bilaterally with a sacral rod. Another sacral rod extending into the pelvis is then connected to the spinal rod, which is affixed to the pedicle screws of L3-L5 (Fig. 65.6).

JAYPEE BROTHERS

Kawahara et al.[35] conducted a finite-element analysis of reconstruction methods used after a total sacrectomy. In their analysis, they described a novel reconstruction technique consisting of both posterior and anterior instrumentation. The posterior instrumentation consisted of L3-L5 pedicle screws connected to iliac screws via a rod. Anteriorly, they put two pedicle screws in the inferior endplate of L5 which they connected to a sacral rod, itself connecting to both sides of the pelvis. Using this model, Kawahara et al. concluded that there was a low risk of instrument failure and loosening after total sacrectomy. They compared this technique with the modified Galveston and triangular frame reconstruction techniques, and found that the former was associated with excessive stress at the spinal rod level while the latter led to excessive stress at the iliac bone level.

Another technique using two to three pairs of bicortical iliac screws connected to L3–L5 pedicle screws via a single U-shaped rod has been described.[19,41] This closed-loop technique is believed to provide improved stability of the lumbopelvic junction in fexion–extension and rotation (Fig. 65.7).

To relieve the stress on the posterior instrumentation and the iliac bone, Dickey et al.[42] described a new form of anterior reconstruction using structural fibular grafts combined with a pedicle screw-rod instrumentation to create a triangular construct along the anatomic force transmission vectors from the femoral heads to the lumbar spine.



Fig. 65.7: Postoperative X-ray showing the closed-loop U-rod reconstruction technique.

In a case of hemicorporectomy, Gallia et al.[33] described a novel technique of lumbopelvic reconstruction using a distractible cage to reconstruct the anterior column.

A custom-made prosthesis has also successfully been tried to restore spinopelvic stability. On the basis of preoperative imaging and necessary extent of resection, Wuisman et al.[34] reported on the usage of a custom-made sacral prosthesis on one patient suffering from a primary osteosarcoma of the sacrum. One disadvantage of this technique is the inability to make any intraoperative adjustments.

The appropriate method of reconstruction largely depends on the experience of the surgeon and on specific tumor/patient characteristics. Multiple biomechanical studies have, however, been conducted to compare some of these sacral reconstruction strategies.[35,40,43-47] Kelly et al.[45] compared the four-rod and the two-rod techniques both with and without cross-links. They found that the four-rod lumbopelvic reconstruction technique provided significantly greater stability in flexion and extension as compared to a conventional cross-linked two-rod technique in a human cadaveric sacrectomy model. The four-rod technique also significantly reduced the motion at the L5-pelvic junction, which may be clinically relevant in achieving solid bony union. The addition of cross-links further improved stability in axial rotation. Yu et al.[44] reported on biomechanical superiority of dual-iliac screw over the single iliac screw method for cases involving high sacrectomies with unilateral sacroiliac joint resection and for total sacrectomies. The dual-rod dual-iliac screw technique provided the most rigid fixation among the four techniques using posterior fixation only.[43] The biomechanical advantage of adding anterior support (either L5 inferior end plate screws/sacral rod, triangular fibular flaps, or a compound method) to the four-rod technique has also been demonstrated,[35,46,47] at the cost of significant technical difficulties and potential disturbance to the pelvic viscera.

Pelvic incidence is a key determinant of sagittal balance. Pelvic incidence does not change in adulthood, despite traditional lumbosacral surgeries. However, with total sacrectomies and total disarticulation of the sacroiliac joints, pelvic incidence is altered.[48] Although long-term studies are lacking, change in pelvic incidence may be relevant clinically, and thus should be taken into consideration during lumbopelvic reconstruction.

Another important consideration in total and high partial sacrectomies is the significant surgical cavity created by

JAYPEE BROTHERS

the resection. Despite advances in reconstructive microsurgical techniques, the repair of the large void created by tumoral resection remains a challenging undertaking.[49] This task is further complicated by preoperative radiation therapy and difficult access to adequate recipient vessels in the sacral area. The main techniques used are the vertical rectus abdominis myocutaneous (VRAM) flap, bilateral gluteal advancement flap, gluteal rotation flap, gluteal thigh flap, and free flap reconstruction. The VRAM flap is harvested during the anterior approach and, consequently, cannot be used in posterior approach only. The VRAM flap is thus not the preferred reconstructive method for middle and low partial sacrectomies, typically done with a posterior approach alone. Miles et al.[50] published their experience of 27 flaps in 25 patients and concluded that in patients with no preoperative radiation therapy and intact gluteal vessels, the use of bilateral gluteal advancement flaps should be an option to consider. When there is a history of radiation to the area or if the gluteal vessels are damaged by the surgical resection, the use of a VRAM flap should be considered. When a previous laparotomy precludes the use of the VRAM flap, then a free flap should be contemplated as a final option. Others have, however, reported that a prior laparotomy has no detrimental effect on the effective or safe use of a transabdominal pedicled VRAM flap.[51] The MD Anderson group reported on their 15-year experience on 50 patients.[52] In their experience, the resection volume was the main factor determining flap choices: gluteus-based flap being most commonly used for small and medium cavities and VRAM flap as the preferred option for large defects. The overall complication rate was 44%, but the flap choice was not an independent predictor of complications.

Another goal of the soft tissue reconstruction is to avoid parasacral herniation of the abdominal content. This can be accomplished by using a mesh[53] or the myocutaneous flap itself.[51]

In the case of extensive defects created with posterior approach only, Dasenbrock et al.[54] published their data on 34 patients with sacral tumors in whom reconstruction was achieved using a human acellular dermal matrix along with gluteus maximus myocutaneous flaps. Of note, gluteal arteries are preserved in a posterior-only approach, assuring a robust blood supply to the gluteus flap. They showed this technique to be a valid option with comparable rate of wound complications to other techniques and low rate of parasacral herniation.[54]

OUTCOMES

Neurological Function

From a neurological perspective, sacral roots often need to be sacrificed to achieve an evidence-based en bloc oncological resection, putting bowel, bladder, and sexual function at risk. Cases of low sacrectomies (distal to S3) usually lead to perineal hypoesthesia and may result in sexual dysfunction.[3] Sphincter and motor function are usually preserved, however. Todd et al.[55] showed that preservation of bowel and bladder continence after major sacral resection is possible in the majority of patients following unilateral sacral root resection or if at least one S3 root is preserved in the case of bilateral sacral resection. A strong association between the number of S3 roots preserved and continence was also reported in another study.[56] Aside from the expected unilateral sensory-motor loss, most patients with unilateral sacral root resection (S1-S5) will have preserved or partially impaired bowel and bladder functions.[18,55,57] In cases of total sacrectomies with bilateral S1 root sacrifice, clinically relevant motor deficits may interfere with independent mobility. With intact L5 root function, a significant proportion will, however, be able to ambulate independently after rehabilitation.[18,19,58]

Postoperative Care and Complications

If successful bony and soft tissue reconstruction has been achieved, patients are mobilized as soon as tolerated postoperatively. They are nursed in specialized airbeds to reduce the risk of pressure sore and wound breakdown. The expected deficits are confirmed postoperatively and rehabilitation initiated as soon as possible. Psychological support should also be offered if needed.

Sacral tumor resections are significant surgeries associated with significant complications. They are also demanding for the surgical team: total sacral resection often lasting >10 hours,[41] and even >30 hours for two-stage procedures.[29] Significant blood loss is also to be expected with reported values ranging from 6.5 L to 40 L for single-stage operations and 10.1–80 L for two-stage operations.[29] Early postoperative deaths have also been published secondary to cerebral infarction and sepsis.[59] Other major complications include rectal and other visceral injury, vascular injury, hardware failure, unexpected neurological deficit (which can be secondary to traction injury to the lumbar plexus), dural tear, and wound problems.[37,59] The proximity of the anus, the risk of incontinence, the possibility of unrecognized rectal injury as well as the

JAYPEE BROTHERS

large surgical dead space created, all contribute to significantly high wound complication rates of 25 to 46%.[25,52,56] In a study of 50 patients who underwent a sacrectomy, Guo et al.[56] showed that bowel incontinence is associated with delayed wound healing. They concluded that bowel diversion procedures should be considered in select cases when bowel incontinence is expected based on the level of resection. Median length of hospital stay between 6.5 and 91 days is reported. These are significantly influenced by the extent of sacral resection,[18] the use of a flap closure, occurrence of adverse events, and bowel incontinence.[56]

CONCLUSION

Low-grade malignant and aggressive benign sacral tumors are best treated with an en bloc resection with appropriate surgical margins. In the sacral region, it involves performing varying extents of sacral resection. These surgical interventions can be very challenging and should be assessed by a multidisciplinary team in a center with such expertise. Depending on the level of the sacrectomy, spinopelvic instability may occur and reconstruction may become necessary. There is currently no consensus about the best reconstruction technique. Decisions should then be made according to surgeon experience, as well as specific patient preferences and tumor characteristics. Because of the inherent surrounding anatomy of the sacrum and also because the often large size of these tumors at the time of diagnosis, there is a significant risk for potentially serious complications. Expected neurological deficits from such interventions should be discussed at length with patients preoperatively. With careful patient selection and meticulous surgical planning, successful clinical outcomes can be anticipated, although further quality of life studies would certainly add to the current literature.

- En bloc resection with appropriate margins is the treatment of choice for low-grade malignant and aggressive benign sacral tumors.
- Sacral resections are technically challenging procedures and are better dealt with in an experienced center with a multidisciplinary team.
- Meticulous surgical planning and patient selection are key in the successful completion of these resections.
- Lumbopelvic reconstruction is necessary when >50% of the sacroiliac joints are resected and allows for earlier mobilization.
- Multiple spinopelvic reconstruction techniques have been described, the best one being determined by surgeon experience and specific patient-tumor characteristics.

REFERENCES

1. Feldenzer JA, McGauley JL, McGillicuddy JE. Sacral and presacral tumors: problems in diagnosis and management. Neurosurgery. 1989;25(6):884-91.
2. Dickman C, Fehlings M, Gokaslan Z. Spinal Cord and Spinal Column Tumors: Principles and Practice. Thieme Medical Publishers Inc. New York, 2006.
3. Sciubba DM, Petteys RJ, Garces-Ambrossi GL, et al. Diagnosis and management of sacral tumors. J Neurosurg: Spine. 2009;10(3):244–256.
4. Enneking WF. A system of staging musculoskeletal neoplasms. Clin Orthop Relat Res. 1986;204:9-24.
5. Chan P, Boriani S, Fourney DR, et al. An assessment of the reliability of the Enneking and Weinstein-Boriani-Biagini classifications for staging of primary spinal tumors by the Spine Oncology Study Group. Spine. 2009;34(4):384-91.
6. Boriani S, Biagini R, De Iure F, et al. En bloc resections of bone tumors of the thoracolumbar spine. A preliminary report on 29 patients. Spine. 1996;21(16):1927-31.
7. Bergh P, Kindblom LG, Gunterberg B, et al. Prognostic factors in chordoma of the sacrum and mobile spine: a study of 39 patients. Cancer. 2000;88(9):2122-34.
8. Fisher CG, Saravanja DD, Dvorak MF, et al. Surgical management of primary bone tumors of the spine. Spine. 2011; 36(10):830-6.
9. Boriani S, Chevalley F, Weinstein JN, et al. Chordoma of the spine above the sacrum. Treatment and outcome in 21 cases. Spine. 1996;21(13):1569-77.
10. Fisher CG, Keynan O, Boyd MC, et al. The surgical management of primary tumors of the spine: initial results of an ongoing prospective cohort study. Spine. 2005;30(16):1899-908.
11. Yamazaki T, McLoughlin GS, Patel S, et al. Feasibility and safety of en bloc resection for primary spine tumors: a systematic review by the Spine Oncology Study Group. Spine. 2009;34 (22 Suppl):S31-8.
12. Boriani S, Saravanja D, Yamada Y, et al. Challenges of local recurrence and cure in low grade malignant tumors of the spine. Spine. 2009;34(22 Suppl):S48-57.
13. Hsieh PC, Xu R, Sciubba DM, et al. Long-term clinical outcomes following en bloc resections for sacral chordomas and chondrosarcomas: a series of twenty consecutive patients. Spine. 2009;34(20):2233-9.
14. Cheng JS, Song JK. Anatomy of the sacrum. Neurosurg FOCUS. 2003;15(2):E3.
15. Gray H, Clemente CD. Anatomy of the Human Body. Lea and Febiger. Philadelphie, 1985.
16. Zhang H-Y, Thongtrangan I, Balabhadra RSV, et al. Surgical techniques for total sacrectomy and spinopelvic reconstruction. Neurosurg FOCUS. 2003;15(2):E5.
17. Doty J, Rengachary S. Surgical Disorders of the Sacrum. Thieme Medical Publishers Inc. New York, 1993.
18. Fourney DR, Rhines LD, Hentschel SJ, et al. En bloc resection of primary sacral tumors: classification of surgical approaches and outcome. J Neurosurg Spine. 2005;3(2):111-22.
19. Varga PP, Bors I, Lazary A. Sacral tumors and management. Orthop Clin NA. 2009;40(1):105-23, vii.
20. Zhang Z, Hua Y, Li G, et al. Preliminary proposal for surgical classification of sacral tumors. J Neurosurg Spine. 2010;13 (5):651-8.

JAYPEE BROTHERS

21. Tomita K, Tsuchiya H. Total sacrectomy and reconstruction for huge sacral tumors. Spine. 1990;15(11):1223-7.
22. Stener B, Gunterberg B. High amputation of the sacrum for extirpation of tumors. Principles and technique. Spine. 1978; 3(4):351-66.
23. Localio SA, Eng K, Ranson JH. Abdominosacral approach for retrorectal tumors. Ann Surg. 1980;191(5):555-60.
24. McLoughlin GS, Sciubba DM, Suk I, et al. En bloc total sacrectomy performed in a single stage through a posterior approach. Neurosurgery. 2008;63:ONS115-20.
25. Clarke MJ, Dasenbrock H, Bydon A, et al. Posterior-only approach for en bloc sacrectomy. Neurosurgery. 2012;71(2): 357-64.
26. Gunterberg B, Romanus B, Stener B. Pelvic strength after major amputation of the sacrum. An experimental study. Acta Orthop Scand. 1976;47(6):635-42.
27. Hugate RR, Jr., Dickey ID, Phimolsarnti R, et al. Mechanical effects of partial sacrectomy. Clin Orthop Relat Res. 2006; 450:82-8.
28. Yu B, Zheng Z, Zhuang X, et al. Biomechanical effects of transverse partial sacrectomy on the sacroiliac joints: an in vitro human cadaveric investigation of the borderline of sacroiliac joint instability. Spine. 2009;34(13):1370-75.
29. Gokaslan ZL, Romsdahl MM, Kroll SS, et al. Total sacrectomy and Galveston L-rod reconstruction for malignant neoplasms. Technical note. J Neurosurg. 1997;87(5):781-7.
30. Wuisman P, Lieshout O, Sugihara S, et al. Total sacrectomy and reconstruction: oncologic and functional outcome. Clin Orthop Relat Res. 2000;381:192-203.
31. Simpson AH, Porter A, Davis A, et al. Cephalad sacral resection with a combined extended ilioinguinal and posterior approach. J Bone Joint Surg Am. 1995;77(3):405-11.
32. Shen FH, Harper M, Foster WC, et al. A novel "four-rod technique" for lumbo-pelvic reconstruction: theory and technical considerations. Spine. 2006;31(12):1395-401.
33. Gallia GL, Suk I, Witham TF, et al. Lumbopelvic reconstruction after combined L5 spondylectomy and total sacrectomy for en bloc resection of a malignant fibrous histiocytoma. Neurosurgery. 2010;67(2):E498-502.
34. Wuisman P, Lieshout O, van Dijk M, et al. Reconstruction after total en bloc sacrectomy for osteosarcoma using a custom-made prosthesis: a technical note. Spine. 2001;26 (4):431-9.
35. Kawahara N, Murakami H, Yoshida A, et al. Reconstruction after total sacrectomy using a new instrumentation technique: a biomechanical comparison. Spine. 2003; 28(14):1567-72.
36. Gallia GL, Haque R, Garonzik I, et al. Spinal pelvic reconstruction after total sacrectomy for en bloc resection of a giant sacral chordoma. Technical note. J Neurosurg Spine. 2005;3(6):501-6.
37. Jackson RJ, Gokaslan ZL. Spinal-pelvic fixation in patients with lumbosacral neoplasms. J Neurosurg. 2000;92(1 Suppl):61-70.
38. Doita M, Harada T, Iguchi T, et al. Total sacrectomy and reconstruction for sacral tumors. Spine. 2003;28(15): E296-301.
39. Allen BL, Ferguson RL. The Galveston technique for L rod instrumentation of the scoliotic spine. Spine. 1982;7(3): 276-84.
40. Murakami H, Kawahara N, Tomita K, et al. Biomechanical evaluation of reconstructed lumbosacral spine after total sacrectomy. J Orthop Sci. 2002;7(6):658-64.
41. Varga PP, Lazary A. Chordoma of the sacrum: "en bloc" total sacrectomy and lumbopelvic reconstruction. Eur Spine J. 2010;19(6):1039-40.
42. Dickey ID, Hugate RR, Fuchs B, et al. Reconstruction after total sacrectomy: early experience with a new surgical technique. Clin Orthop Relat Res. 2005;438:42-50.
43. Mindea SA, Chinthakunta S, Moldavsky M, et al. Biomechanical comparison of spinopelvic reconstruction techniques in the setting of total sacrectomy. Spine. 2012;37(26):E1622-27.
44. Yu B-S, Zhuang X-M, Li Z-M, et al. Biomechanical effects of the extent of sacrectomy on the stability of lumbo-iliac reconstruction using iliac screw techniques: what level of sacrectomy requires the bilateral dual iliac screw technique? JCLB. 2010;25(9):867-72.
45. Kelly BP, Shen FH, Schwab JS, et al. Biomechanical testing of a novel four-rod technique for lumbo-pelvic reconstruction. Spine. 2008;33(13):E400-6.
46. Zhu R, Cheng L-M, Yu Y, et al. Comparison of four reconstruction methods after total sacrectomy: a finite element study. JCLB. 2012;27(8):771-6.
47. Cheng L, Yu Y, Zhu R, et al. Structural stability of different reconstruction techniques following total sacrectomy: a biomechanical study. JCLB. 2011;26(10):977-81.
48. Gottfried ON, Omeis I, Mehta VA, et al. Sacral tumor resection and the impact on pelvic incidence. J Neurosurg Spine. 2011;14(1):78-84.
49. Diaz J, McDonald WS, Armstrong M, et al. Reconstruction after extirpation of sacral malignancies. Ann Plast Surg. 2003;51(2):126-9.
50. Miles WK, Chang DW, Kroll SS, et al. Reconstruction of large sacral defects following total sacrectomy. Plast Reconstr Surg. 2000;105(7):2387–2394.
51. Glatt BS, Disa JJ, Mehrara BJ, et al. Reconstruction of Extensive partial or total sacrectomy defects with a transabdominal vertical rectus abdominis myocutaneous flap. Ann Plast Surg. 2006;56(5):526-31.
52. Garvey PB, Rhines LD, Feng L, et al. Reconstructive strategies for partial sacrectomy defects based on surgical outcomes. Plast Reconstr Surg. 2011;127(1):190-9.
53. Junge K, Krones CJ, Rosch R, et al. Mesh reconstruction preventing sacral herniation. Hernia. 2003;7(4):224-6.
54. Dasenbrock HH, Clarke MJ, Bydon A, et al. Reconstruction of extensive defects from posterior en bloc resection of sacral tumors with human acellular dermal matrix and gluteus maximus myocutaneous flaps. Neurosurgery. 2011; 69(6):1240-47.
55. Todd LT, Jr, Yaszemski MJ, Currier BL, et al. Bowel and bladder function after major sacral resection. Clin Orthop Relat Res. 2002;397:36-39.
56. Guo Y, Palmer JL, Shen L, et al. Bowel and bladder continence, wound healing, and functional outcomes in patients who underwent sacrectomy. J Neurosurg Spine. 2005;3(2): 106-10.
57. Nakai S, Yoshizawa H, Kobayashi S, et al. Anorectal and bladder function after sacrifice of the sacral nerves. Spine. 2000;25(17):2234-9.
58. Fourney DR, Gokaslan ZL. Current management of sacral chordoma. Neurosurg FOCUS. 2003;15(2):E9.
59. Zileli M, Hoscoskun C, Brastianos P, et al. Surgical treatment of primary sacral tumors: complications associated with sacrectomy. Neurosurg FOCUS. 2003;15(5):E9.

JAYPEE BROTHERS

for detailed information on orthopaedic books, visit our website **www.jaypeebrothers.com,** for detailed information on orthopaedic books, visit our website **www**

THE SPINE

Medical & Surgical Management

Alexander R Vaccaro MD PhD MBA is Richard H Rothman Professor and Chairman of Orthopedic Surgery; and Professor of Neurosurgery at the Sidney Kimmel Medical College at Thomas Jefferson University in Philadelphia, Pennsylvania, USA. He is also President of the Rothman Institute, Philadelphia, USA.



Brian W Su MD is Medical Director of Spine Surgery at Marin General Hospital and Surgeon-in-Chief of California Orthopedics and Spine Center in Larkspur, California, USA.



Kazuhiro Chiba MD PhD is Professor and Chairman of the Department of Orthopedic Surgery, National Defense Medical College in Saitama, Japan.



Marcel F Dvorak MD FRCSC MBA is Professor of Orthopedics at University of British Columbia in Vancouver, Canada. He holds the Cordula and Gunter Paetzold chair of Clinical Spinal Cord Injury Research and is former Division Head of Spine at Vancouver General Hospital.



H Michael Mayer MD PhD is Chairman of the Spine Center at Schön Klinik München Harlaching and Professor of Neurosurgery at the Paracelsus Medical University, Salzburg in Austria. He is also the Past President of the Spine Society of Europe and the German Spine Society.



S Rajasekaran MS DNB FRCS (Ed) MCh (Liv) FACS FRCS (Eng)PhD is Chairman of the Department of Orthopedic and Spine Surgery at Ganga Hospital in Coimbatore, Tamil Nadu, India. He is also the president of SICOT, CSRS-AP, international chair elect of AOSpine and the past president of ISSLS, Association of Spine Surgeons of India and Indian Orthopaedic Association.



Luiz R Vialle MD PhD is Professor of Orthopedics at the School of Medicine, Pontifical Catholic University in Curitiba, Brazil. He is a spine surgeon at the University Hospitals and is also the founder and past president of the Brazilian Spine Society and past president of AOSpine International.



Yan Wang MD is Professor and Director of the 301 Orthopedic Hospital of The General Hospital of Chinese PLA in Beijing, China. He is also President of the Chinese Academy of Orthopedic Surgeons, Chairman of the Chinese Spine Society, and past president of Chinese Orthopedic Association.



Magdy Gamal Youssef MD is Professor of Spine Surgery at the Ain Shams University in Cairo, Egypt. He is also Head of the spinal units at International Medical Center Cairo IMC. He is the former Chairperson of AOSpine Egypt and the former Chairperson of AOSpine Education in Middle East.



Available at all medical bookstores or buy online at www.jaypeebrothers.com

JAYPEE BROTHERS
Medical Publishers (P) Ltd.
www.jaypeebrothers.com

Join us on facebook.com/JaypeeMedicalPublishers

Shelving Recommendation
ORTHOPEDICS

ISBN 978-93-5152-494-6