ebrothers.com, for detailed information on orthopedic books, visit our website www.jaypeebrothers.com, for detailed information on orthopedic books

JAYPEE

ADULT DEGENERATIVE SCOLIOSIS

Coronal and Sagittal Deformities: Treatment and Management





Editors

James S Harrop

Alexander R Vaccaro

Associate Editor

Ahmed J Awad

Foreword

Edward C Benzel

Contents

Section 1: Lumbar Degenerative Scoliosis

1. **Thoracolumbar Spine Anatomy and Pathoetiology of Degenerative Scoliosis** **3**
   Shyam A Patel, Jeffrey A Rihn
   - Spinal Anatomy *3*
   - Thoracic and Lumbar Anatomy *4*
   - Demographics and Epidemiology *5*
   - Pathoetiology *5*
   - Initiation of Curvature *7*
   - Genetic Etiologies *9*
2. **Imaging and Radiographic Measurement Techniques for Lumbar Degenerative Scoliosis** **12**
   Ahmed J Awad, Kenan Al-khalili, Christopher M Maulucci, Joshua E Heller, James S Harrop
   - Conventional Radiography *12*
   - Cobb Angle Technique *13*
   - Global Balance *15*
   - Rotatory Subluxation *15*
   - The SRS-Schwab Classification *16*
   - Advanced Imaging *18*
3. **The Importance of Spinal Alignment in the Management of Lumbar Degenerative Scoliosis** **21**
   Marco Girolami, Shian Liu, Virgine Lafage, Frank J Schwab
   - Degenerative Scoliosis *21*
   - Pathology of DDS vs AISA *21*
   - Clinical Presentation *24*
   - Radiological Evaluation *26*
   - Treatment *29*
4. **Natural History of Non-operative Treatment for Lumbar Degenerative Scoliosis** **33**
   Randall B Graham, Tyler R Koski
   - Radiographic Progression *33*
   - Clinical Progression *33*
   - Case Presentation *34*
5. **Clinical and Biomechanical Differences in the Treatment of Adult Degenerative and Idiopathic Scoliosis** **37**
   Dennis S Meredith, Todd J Albert
   - Initial Presentation and Evaluation *38*
   - Goals of Treatment and Surgical Considerations *39*

Section 2: Surgical Planning

6. **When is Posterior Decompression alone Adequate in the Setting of Lumbar Degenerative Scoliosis?** **45**
   Louis F Amorosa, Alan S Hilibrand
   - Case Presentation *46*
   - Discussion *47*
7. **Determining Fusion Levels in Lumbar Degenerative Scoliosis** **55**
   Adam J Bevevino, Ronald A Lehman, Lawrence G Lenke
   - Clinical and Radiographic Evaluation *56*

- Case Presentation *57*
- The Distal Fusion Level *57*
- The Proximal Fusion Level *60*
- Complications *62*

8. Is an Interbody Fusion Always Necessary? **64**
Beejal Y Amin, Tarik Ibrahim, Rishi Wadhwa, Hai Le, Charles Eichler, Praveen Mummaneni

- Case Presentation *64*
- Discussion *65*
- Types of Interbody Material *69*
- Indications and Contraindications *70*
- Things not to do and Complications *71*

9. Lateral Lumbar Interbody Fusion for Treatment of Degenerative Scoliosis **75**
Kasra Ahmadinia, Frank M Phillips

- Case Report *76*
- Discussion *76*
- Complications *78*

10. When Does One Stop at L5 as a Distal Fusion Level Instead of the Sacrum in Multilevel Fusions for Lumbar Degenerative Scoliosis? **81**
Alp Yurter, Daniel M Sciubba

- Case Presentation *81*
- Discussion *84*
- Choosing L5 as Site of Distal Fusion *85*
- Complications *86*

Section 3: Surgical Techniques

11. Anterior Approaches to the Lumbar Spine **93**
Shay Bess, Bryan Kramer, Salvador A Brau

- Indications for Anterior Column Support, and Outcomes Following Anterior Spinal Surgery for Adult Spinal Deformity *93*
- Contraindications to Anterior Lumbar Approach *94*
- Surgical Technique *96*
- Clinical and Biomechanical Evaluation of ALIF vs TLIF *98*
- Complications Associated with Anterior Lumbar Approaches *98*

12. Posterior Fusion Techniques for Lumbar Degenerative Scoliosis **102**
Christopher M Maulucci, Mark E Oppenlander, Joshua E Heller

- Case Presentation *102*
- Preoperative Workup *102*
- Surgical Principles *103*
- Bone and Bone Substitute Options *104*
- Advantages of Posterior-Only Approach *104*
- Disadvantages of Posterior-Only Approach *105*
- Complications *105*

13. Ponte Osteotomy **106**
Anthony M Petrizzo, Jeffrey M Spivak

- Case Presentation *107*
- Surgical Technique *108*
- Benefits of the Ponte Osteotomy *109*
- Things Not To Do *109*
- Complications *110*

14. Smith-Peterson Osteotomies **112**
Robert F Heary, John C Quinn
- Illustrative Case Presentation *115*
- Complication Management *118*

15. Pedicle Subtraction Osteotomy **121**
John Paul Kelleher, Paul J Schmitt, Christopher P Ames, Christopher I Shaffrey, Justin S Smith
- Case Presentation *123*
- PSO Indications *123*
- PSO Surgical Technique *124*
- Complications *128*

16. Vertebral Column Resection in Adult Degenerative Scoliosis **131**
Han Jo Kim, Lawrence G Lenke
- Case Presentation *131*
- Surgical Technique *131*
- Discussion *133*
- Complications *134*

17. The Lateral Approach **136**
Rodrigo Amaral, Luis Marchi, Leonardo Oliveira, Luiz Pimenta
- Case Presentation *136*
- Surgical Principles *138*
- Why Do It This Way *140*
- Things Not To Do *141*
- Complications and Management *141*

18. Spino-pelvic Fixation Strategies in the Setting of Lumbar Degenerative Scoliosis **144**
Carlo Bellabarba, Emiliano Vialle, Richard J Bransford
- Case Presentation *144*
- Discussion *146*
- Why Do It This Way? *152*
- What to Avoid *153*
- Complications *153*

19. Circumferential Approaches **156**
Louis F Amorosa, Anita Mikkilineni, Alexander R Vaccaro
- Case Presentation *156*
- Surgical Principles (Goals) *158*
- Why Do It This Way *161*
- Things Not To Do *161*
- Complications *162*

20. Less Invasive Surgery for Adult Degenerative Scoliosis **166**
Michael CL Suryo, Victor Popov, D Greg Anderson
- Case Presentation *166*
- Rationale for the Chosen Surgical Approach *168*
- Drawbacks of the Chosen Approach *168*
- Complications of the Approach *168*
- Discussion *168*

Index *171*

CHAPTER 3

The Importance of Spinal Alignment in the Management of Lumbar Degenerative Scoliosis

Marco Girolami, Shian Liu, Virgine Lafage, Frank Schwab

Chapter Outline

- Degenerative Scoliosis
- Pathology of DDS vs AISA
- Clinical Presentation
- Radiological Evaluation
- Treatment

DEGENERATIVE SCOLIOSIS

Adult scoliosis is defined as a spinal deformity in a skeletally mature patient with a Cobb angle >10°.[1,2] The previously reported incidence of asymptomatic adult scoliosis varied from 1.4% to 32%;[3–5] however, the actual incidence is >60% of patients over the age of 60.[6] Most healthcare providers, regardless of their specialty, are bound to encounter such a patient.

Spinal deformity in the adult has many known etiologies but the following two categories include the largest number of patients: adolescent idiopathic scoliosis in the adult (AISA) and de novo degenerative scoliosis (DDS).[7]

The first category refers to patients with scoliosis (idiopathic) developed before bone skeletal maturity during childhood and adolescence, which may have progressed or become symptomatic with age.[8]

The second category includes patients in whom the spinal deformity developed after skeletal maturity and most commonly involves some form of degenerative disease in the middle age.

Although the causes of AISA and DDS appear quite different, they may share a common pathway in symptomatic patients: gradual loss of intersegmental stability with aging, and subsequent progressive deformity and pain. These consequences trigger a vicious cycle, where deformity and degeneration enhance one another with a simultaneous increase of symptoms.[9]

Certainly, many adult deformities may not fit clearly into the categories of AISA or DDS, such as traumatic, metabolic, osteoporotic, or iatrogenic deformities. In a large number of cases it is even difficult to decide if a curve is AISA or DDS due to the presence of both typical rotation changes of adolescent idiopathic scoliosis (AIS) and degenerative changes.

PATHOLOGY OF DDS VS AISA

Both DDS and AISA fall under the broader category of adult spinal deformity (ASD), and can lead to marked disability that may ultimately require surgical correction. However, there are differences in the clinical and pathological progression of these conditions. A brief description of the etiology of AISA, followed by a more comprehensive discussion of DDS can illuminate the distinctions between these two conditions, and set the groundwork for a larger discussion on the importance of sagittal plane alignment in the setting of lumbar scoliosis.

While the pathology of AISA starts before spinal skeletal maturity has been reached and progresses slowly in adulthood, the degenerative changes that

JAYPEE BROTHERS

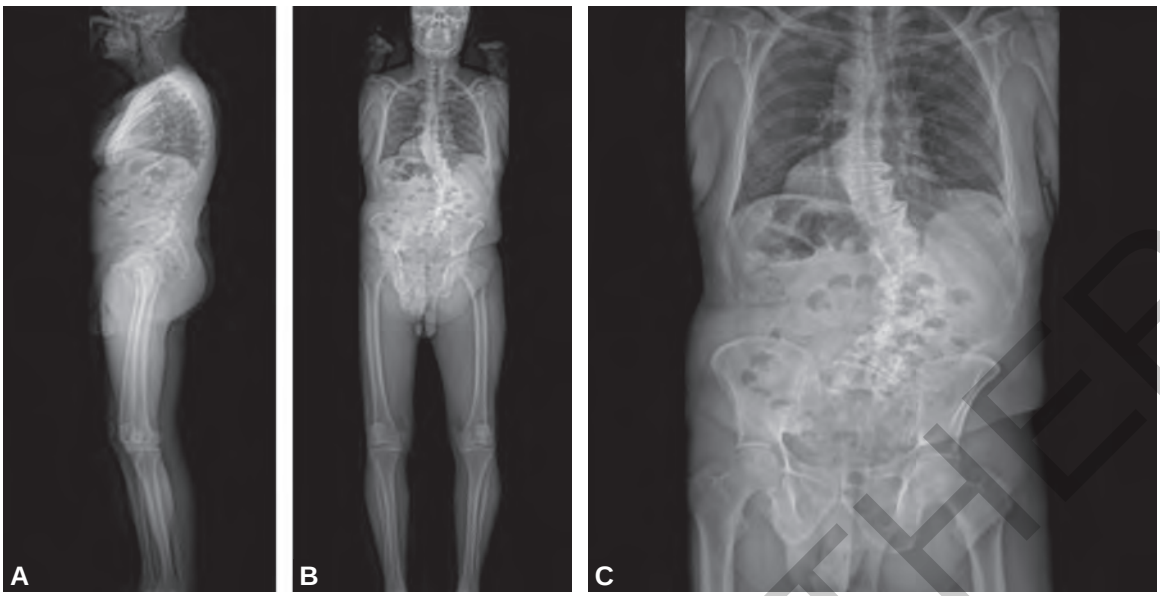

Figs. 3.1A to C: Adolescent idiopathic scoliosis in the adult. (A) Standing lateral weight bearing full-body radiograph in a subject presenting with adolescent idiopathic scoliosis of the adult demonstrating a well-preserved lumbar lordosis (LL 64°, SVA 36.50 mm, PI-LL = 21°). (B) Standing anteroposterior weight-bearing full-body radiograph of the same patient showing a marked scoliotic deformity. (C) Close-up of the lumbar region and pelvis with a maximum Cobb angle of 50°. (LL, lumbar lordosis; PI, pelvic incidence; SVA, sagittal vertical axis).

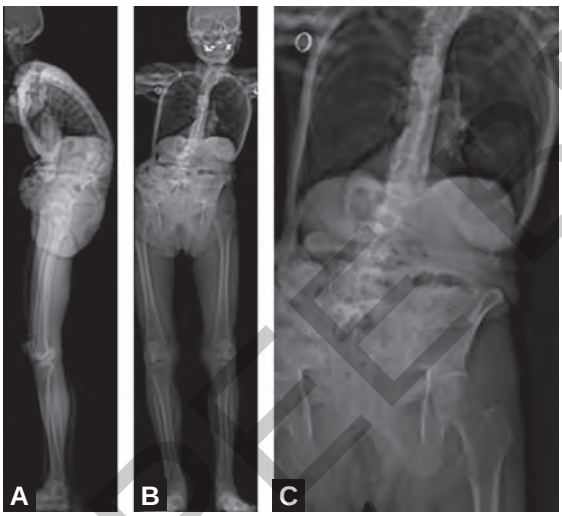

Figs. 3.2A to C: De novo degenerative scoliosis. (A) Standing lateral weight-bearing full-body radiograph in a subject presenting with de novo scoliosis as an adult, demonstrating a loss of lumbar lordosis, loss of disk space and deformity at the lumbar and thoracolumbar junction, and severe sagittal malalignment (LL 8°, SVA 173.31 mm, PI-LL = 49°). (B) Standing anteroposterior weight-bearing full-body radiograph of the same patient. (C) Close-up of the lumbar region and pelvis with a maximum Cobb angle of 31°. (LL, lumbar lordosis; PI, pelvic incidence; SVA, sagittal vertical axis).

lead to sagittal deformity in DDS occur well after final ossification and maturation of the vertebrae. The actual etiology of adolescent idiopathic scoliosis (AIS) is still being elucidated; some postulate that hormonal imbalance, asymmetric growth, and muscle imbalance play a role, though there is concomitant evidence that a possible familial contribution exists, given that 30% of AIS patients have a family history of scoliosis.[10]

Regardless of etiology, adolescents with idiopathic scoliosis can continue to evolve from an initial coronal deformity in their early teens to a progressive and more symptomatic sagittal deformity in the adult years (Figs. 3.1A to C). Because AISA starts in adolescence, these curves tend to exhibit more rotational components, coronal aberrations, and thoracic deviations compared to DDS, though in severe AISA there can be a concomitant degenerative component.[8,11]

In contrast, in DDS, degeneration of soft tissues alone is responsible for the initiation and progression of deformity. Adult degenerative scoliosis is also known as de novo scoliosis because its onset is often clinically apparent after a period of seemingly normal spinal growth and alignment as a child and young adult. Changes in alignment occur due to the degeneration of disks, facet arthropathy, and supportive soft tissue changes. Unlike AISA, these changes tend to be more regional, localized to the lumbar spine (Figs. 3.2A to C).

The trigger of a lumbar degenerative scoliosis is considered an asymmetrical degenerative process of a disk in one or more segments. At the biochemical level, a normal disk maintains an equilibrium between matrix synthesis and degradation; however, with aging, there is a decrease in agrecan

JAYPEE BROTHERS

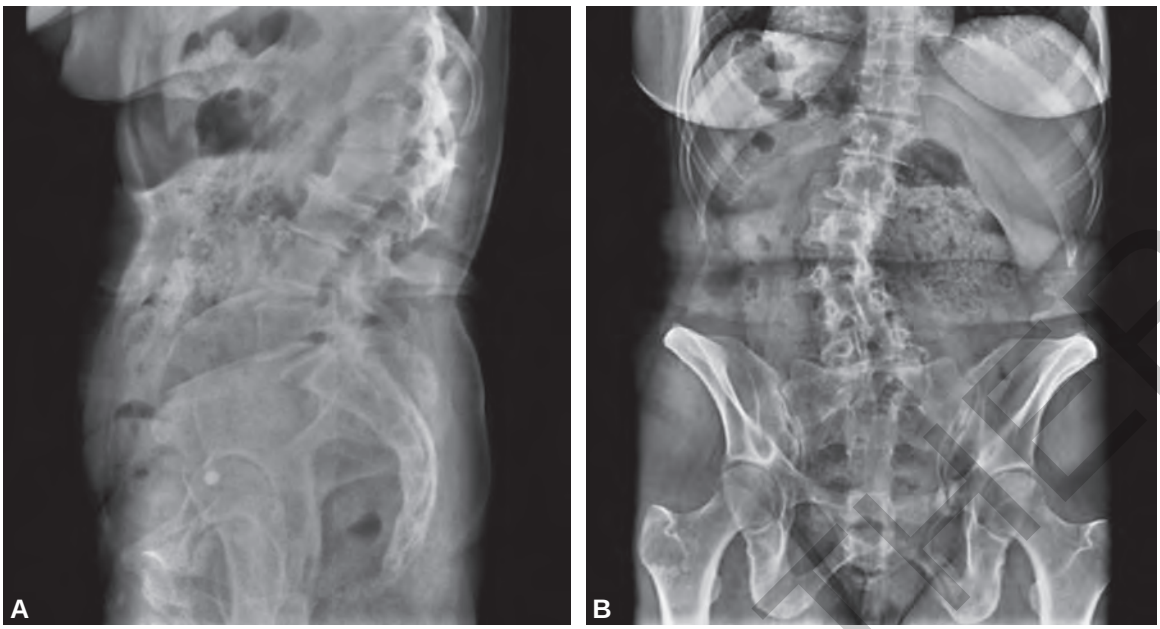

Figs. 3.3A and B: Translational shifts (rotatory subluxation and spondylolisthesis). (A) Lateral radiograph of a patient with spondylolisthesis of L5-S1. (B) Anterior-posterior radiography demonstrating midline spinous processes and pedicles in the thoracic region with progressive axial rotation starting at L1, Nash and Moe Grade +, and rotatory subluxation at L1-L2 and L3-L4.

(a proteoglycan), water, and collagen, and an increased expression of matrix metalloproteinases (MMPs).[12] As age increases, biochemical changes accumulate until they affect macroscopic changes such as fissuring and radial tears, and loss of disk height with water and proteoglycan loss.[13] While the central portion of a healthy disk is relatively avascular, angiogenesis is a response to the degenerated disk with fissures and tears. This increase in vascularization is accompanied by an invasion of inflammatory cells such as macrophages, which release more cytokines and proteases; increased expression of substance P has also been found in degenerated disks, further irritating the nociceptive nerve terminals that innervate the inner nucleus and annulus.[12] The degenerative changes at these levels alter the physiological load sharing at the level of that functional spinal unit (FSU), and can possibly extend to the whole spine.

Alterations in the load sharing affect both structures of the anterior column and the posterior arch.[14] The loss of the intervertebral disk shock absorption function increases the contact and erosion of end plates of the two adjacent vertebrae, triggering sclerosis, a biological reaction of the subchondral bone and subsequent osteophyte formation. This condition is known as spondylosis.[13] Additionally, disk degeneration affects the structures of the posterior arch, changing the physiological face of the articular process joints surfaces leading to hypertrophy. This leads to calcification of the joint capsules and ligamentum flavum and development of osteophytes. This condition is known as facet arthropathy. Hypertrophy and osteophyte formation compromise spinal and foraminal canals, where the cauda equina and nerve roots can be compressed and stretched.[13] These reactive changes should contribute to stability, but can lead to instability.[15] White and Panjabi described instability as "a loss of the spine's ability, under physiological loads, to maintain patterns of displacement so as to avoid neurologic deficits, incapacitating deformity, and intractable pain".[16] Instability can enhance the pathogenic vicious cycle, leading to translational shifts [rotatory subluxation or spondylolisthesis (Figs. 3.3A and B)] that ultimately cause the dynamic component of the symptoms (pain with lateral bending).[9]

While a condition localized to one spinal level can expand to affect the rest of the spine, a focal condition can also be a manifestation of a degenerative process that has already been ongoing throughout the whole spine. Compared to idiopathic scoliosis, degenerative discogenic curves are typified by lateral and rotatory subluxation and less coronal angulation and vertebral body involvement.[9] The most common location of the curve is in the lumbar and thoracolumbar spine, usually L2-L3 or L3-L4.

JAYPEE BROTHERS

CLINICAL PRESENTATION

The typical patient with DDS presents as a 60 year old with a history of chronic lower back pain, which is worsening and accompanied by recent onset of leg pain or numbness.[17] It is generally accepted that DDS presents clinically after the age of 40, with an equal distribution among males and females, and an increased prevalence as age increases.[17]

However, the first clinical signs of DDS can start as early as age 30 with disk degeneration and MRI changes.[12,18] The next 10–20 years are characterized by facet degenerative joint disease and wedging of the disk spaces. Untreated, the natural course of DDS can advance to a stable spine ankylosis, where the patient has a spontaneous fusion of the lumbar vertebrae, or unfavorable degeneration such as spondylolisthesis, stenosis, and deformity.[15] These changes usually occur in the lumbar spine and are accompanied by a loss of lumbar lordosis and increased pelvic retroversion. Coronal and sagittal global malalignment (often termed "imbalance") are late complications.[19]

In addition, global sagittal alignment [specifically, sagittal vertical axis (SVA)] increases with age.[20] Therefore, not only does prevalence rise with age, but sagittal form worsens as well.

Symptoms

In terms of symptomatology, many cases of DDS are mild to moderate and relatively asymptomatic. However, when DDS patients develop symptoms, they can present with a combination of back pain, radicular symptoms (radiating leg pain, weakness, and numbness), neurogenic claudication unrelieved by lumbar flexion or sitting, loss of upright posture, bowel and urinary dysfunction, and even cauda equina syndrome (CES).[21] Radiculopathy and lower back pain are the most common complaints, and the quality of the leg and back pain may be severe enough to blight quality of life.[22,23] Additionally, disk degeneration may cause damage to the nociceptive nerve fibers, further exacerbating the pain in the lower back.[12]

While pain and disability are markers of sagittal deterioration, they are not necessarily correlated with coronal plane deformities. Deviations in coronal curvatures may appear visually striking and may also lead to some mechanical back pain and asymmetric radiculopathies, but their main manifestation is often cosmetic. Coronal Cobb angle is not a significant contributor to clinical complaints.[24-27]

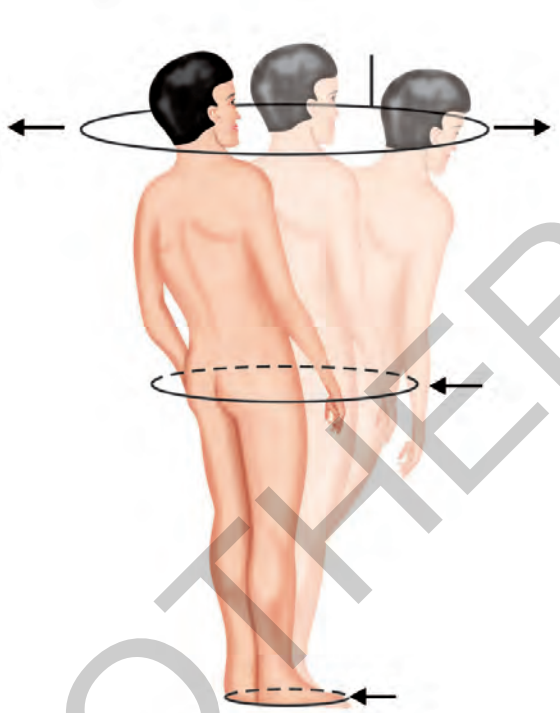

Fig. 3.4: Dubousset's cone of economy. The cone of economy originates from the feet and projects upward to define the range of mobility the body can achieve with minimal energy expenditure. (H, head; P-L, pelvic level; P-S, polygon of sustentation.)
Source: Picture from Dubousset J.[29]

In the general ASD population, elderly patients tend to present with these severe manifestations of DDS and have regional symptoms around the lumbar and thoracolumbar spine. However, younger adults with ASD tend to be less debilitated, because the etiology is more likely to be AISA, though degenerative changes can be concurrent.[28]

Compensation

As the disease progresses, patients can compensate for the sagittal malalignment with the bony and soft tissue structures in the spine, pelvis, hip, and lower extremities. The body's effort is aimed at maintaining the head in alignment over the pelvis in the sagittal plane to maintain an upright posture and horizontal gaze. The energy expenditure to maintain a horizontal gaze is increased as the sagittal alignment deviates from the body's gravity line (GL); this concept is in line with Dubousset's cone of economy (Fig. 3.4).[29] In this theory, there is a constant attempt to maintain an upright posture with the least amount of energy

JAYPEE BROTHERS

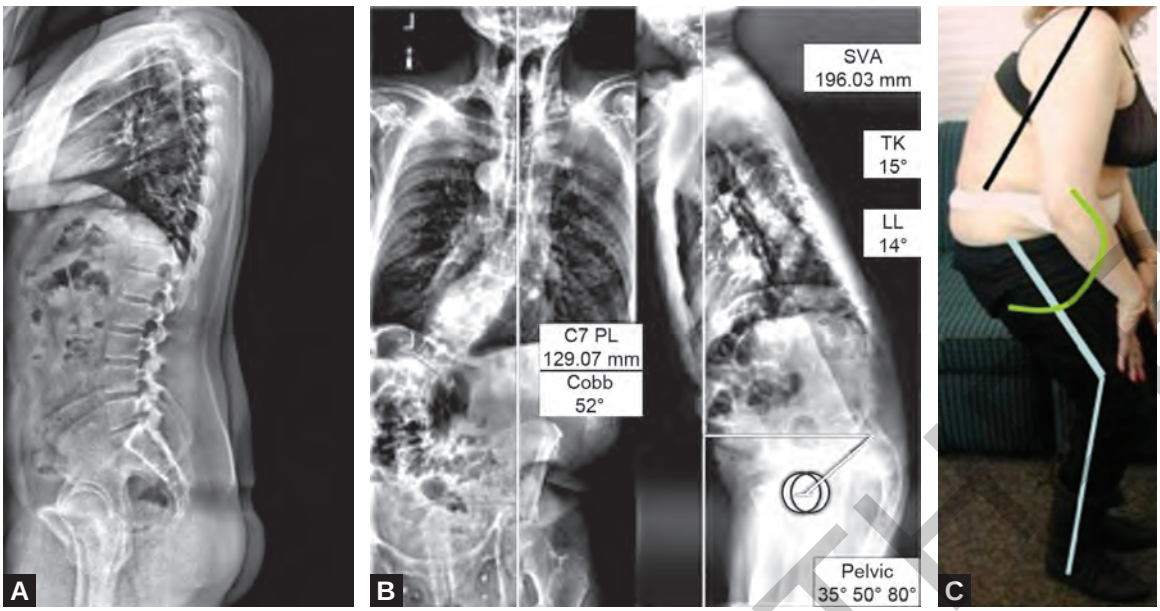

Figs. 3.5A to C: Compensations: TK loss, pelvic retroversion, hip extension, knee flexion, ankle extension. (A) Lateral radiograph demonstrating progressive loss of thoracic kyphosis in response to loss of lumbar lordosis leading to flat back syndrome. (B) Anterior-posterior and lateral radiograph, demonstrating increased pelvic retroversion as outlined by high pelvic tilt defined as the angle between the line from the bicoxofemoral axis to the sacral end plate midpoint, and the line vertical from sacral end plate midpoint. As the pelvis rotates backward, the hips are put in a position of extension, and the upper body is brought more in line above the femoral heads. (C) A patient, with clinically apparent pelvic retroversion, knee flexion, and ankle extension to stay within her cone of economy.

expenditure. The more a person deviates from the center of the cone, the more energy is required until finally, outside the cone there is need for an external device in order not to fall. Patients with disease progression strive to economize their energy by staying within the center of this cone, and by doing so develop a particular appearance or posture due to the presence of these compensatory mechanisms.

First, the thoracic spine will respond to changes in the lumbar spine. Patients with a low lumbar lordosis and increased SVA tend to reduce their thoracic kyphosis to maintain the head over the pelvis.[30] Thoracic compensation is achieved initially through muscular effort and contributes to pain in the thoracic region despite its origin in the lumbar region. Thus, a loss of lumbar lordosis will often be accompanied by a loss of thoracic kyphosis, so that patients will develop a progressively flat back (Fig. 3.5A). In fact, correction of lumbar lordosis can lead to compensatory normalization of the thoracic spine (increased kyphosis) postoperatively.

Next, retroversion of the pelvis can commonly occur to compensate for a malalignment of the spine. When a patient sustains a loss of lumbar lordosis, the pelvis rotates backward, generating a flattened buttock appearance (Fig. 3.5B). This produces extension and external rotation of the hip and recruitment of the posterior muscles of the thigh and gluteal region, causing a higher demand on muscular effort to maintain an upright position. Patients with DDS can quickly develop fatigue with standing and often cannot stand for extended periods, with progressive loss of endurance over time.

Furthermore, these adaptative changes place the hips in a nonphysiological position, affecting the gait pattern because no additional hip extension is available for the gait cycle. This is reflected in patients' complaints of reduced walking distance and fatigue.

In some instances the pelvis does not retrovert; in these situations patients should be examined for possible hip pathology. It is important to detect any hip conditions, i.e. a fixed flexion contracture of the hip, which can be elicited with the Thomas test,[30] because they can prevent successful sagittal realignment surgery.

Another common compensation is knee flexion (Fig. 3.5C). When this presentation is seen clinically, it implies recruitment of the anterior muscles of the thigh, additionally affecting gait pattern with increased energy expenditure and decreased walking autonomy.

JAYPEE BROTHERS

Finally, ankle extension (plantarflexion) is an ultimate effort to maintain the GL of the body as close as possible to its natural position within the posterosuperior corner of the sacral end plate and the head of the femur. GL is an extension of the body's center of gravity projecting onto the ground, and should remain between the feet, even in the case of an increased SVA and truncal inclination.[31] Ankle extension is among the last ways the body can compensate to maintain the GL within the cone of economy: outside the cone and the patient will fall.

It is interesting to observe how the lower limb is deeply involved in the adaptative changes of axial skeleton pathology. This highlights the importance of a global evaluation of the patient with ASD.

Clinical Implications of Symptomatology

Management of adult spinal deformity is driven by disability and symptom relief.[32]

There exists a dilemma for the spine surgeon who treats DDS, since it is based on patient perception of their symptoms as measured by health-related quality of life (HRQOL) scores. Nonoperative treatments can be effective in the early stages of symptomatic ASD, but usually become ineffective as the degree of deformity increases. While it is important to utilize nonoperative options such as injections and physical therapy, it is crucial to keep in mind that ASD is a chronic, progressive disease and the longer surgery is deferred, the harder it may be to correct the deformity. In reality, exhausting nonoperative management also provides the patient with the potential for having an increased improvement in HRQOL postoperatively, which may not occur if surgery takes place too early in the course of the disease. In properly selected cases, surgery can offer significant improvement.[33-35]

Therefore, it is vital to identify a classification system that enables spine professionals to characterize patients and identify the most appropriate treatment in order to define expectations and risks for every patient.

RADIOLOGICAL EVALUATION

Although the most notable visual findings in radiological evaluation of scoliosis can be present in the coronal plane, which has historically been the target of treatments, more and more studies have demonstrated the significant contributions of sagittal plane deformity and the need for sagittal plane analysis. These, in addition to the well-known rotatory component in the axial plane, establish scoliosis as a triplanar deformity.

The Road to Classification

There have been numerous attempts by various groups to classify the different aspects of ASD's complex pathology.[36] This highlights the need within the field of spine surgery to define criteria, subdivide groups, and compare the different subtleties of how ASD presents.

Radiography is a common, well-accepted practice in caring for patients with ASD. In evaluating radiographs, it is crucial to identify clinically relevant radiological parameters that are repeatable, and used to follow patients and predict outcomes. A classification based on such radiologic parameters and correlated with HRQOL measures may be an important tool.

Schwab et al.[24] demonstrated a statistically significant correlation between pain [measured with the visual analogue scale (VAS)] coronal parameters, and sagittal parameters. Coronal parameters, such as lateral listhesis and vertebral obliquity of the lumbar spine, and sagittal parameters, such as lumbar lordosis and thoracolumbar kyphosis, were correlated with higher VAS scores. Moreover, they demonstrated that traditionally accepted coronal parameters, such as Cobb angle and the number of vertebrae involved, do not correlate with a high VAS.

In 2005, Glassman et al.[25] demonstrated a statistically significant increase in disability in thoracolumbar and lumbar curves, compared to thoracic curves, and in patients with positive, compared to negative or neutral, sagittal alignment. The more distal the kyphosis and the more positive the sagittal alignment, the less tolerated it is by the patient. They also noticed that coronal malalignment was correlated with HRQOL but only in patients without prior surgery. This study also confirmed the observation of Schwab et al.[24] that coronal curve magnitude is not significantly correlated to HRQOL scores. Furthermore, it was also noted that age served as an independent factor related to increase in gravity of symptoms and poor HRQOL scores.

Sagittal vertical axis, defined as the offset between the sagittal C7 plumb line and the posterosuperior corner of S1, needs to be understood in the context of the multiple parameters that

JAYPEE BROTHERS

contribute to it. In a subsequent study, Glassman et al.[26] evaluated the positive SVA subgroup and concluded that the severity of symptoms increased in a linear fashion with increasing SVA. However, there are multiple contributions to an increased SVA along the spine. Osseous and positional changes that modulate SVA can occur within the spine at the thoracic, and lumbar regions, and outside the spine at the pelvis and lower extremities. This study showed a lack of correlation between SVA deviation as a global indicator of alignment and lumbar kyphosis as a regional indicator of alignment, suggesting that the contributions to SVA are a complex interaction of many parameters that can not easily be teased apart. Thus, the severity and spectrum of symptoms in a patient with a high SVA may be different from another patient with the same high SVA—it simply depends on whether and where the compensation occurred.

To some degree, these parameters behave independently and the cause of SVA deviation can be from any number of combinations of thoracic hyperkyphosis, lumbar hypolordosis, pelvic tilt (PT), etc.

During that same year, a preliminary classification was released based on lumbar lordosis and L3 obliquity; however, it did not take into account global alignment.[37] Classification systems would continue to evolve for the next several years.

From these experiences, a new classification in 2006 based on the model of the Lenke classification for AIS was developed.[27] Patients with ASD were organized by curve location, lumbar lordosis severity, and intervertebral subluxation (taken either from sagittal or coronal planes). The weak point of this classification was that it did not consider pelvic parameters, but it did show a clear shift of attention from coronal to sagittal plane parameters.

This leads to the most recent classification system,[38] developed in 2012 that accounts for curve location, lumbar lordosis, and the final crucial component—pelvic parameters.

Development of Pelvic Parameters

The relationship between pelvic shape and spine morphology has been observed since the 1950s by the French anatomist Delmas. However, his observations were purely qualitative and not utilized clinically.

In the 1980s a number of studies investigating the relationship between spine and pelvis were published by numerous authors. In 1982, Stagnara et al.[39] evaluated the spine in the context of the pelvis and found a relationship between lumbar lordosis and inclination of the sacral end plate. Further building on the ideas of spino-pelvic harmony, in 1983 Marnay and Vidal[40] proposed a simple model for the relationship of the thoracolumbar junction and pelvis acting as two separate hinges that are coupled together. And in 1985, During et al.[41] made the first attempt to identify and describe pelvic parameters.

The actual parameters used today were described by Duval-Beaupere et al.[42] in 1992; she defined the pelvic parameters of pelvic incidence (PI), PT, and sacral slope (SS). In 1998, Legaye et al.[43] proposed PI as "the fundamental parameter" for the spino-pelvic alignment. It defines not only what an acceptable lumbar lordosis would be, but even how much pelvic retroversion may occur. In fact, there is a geometrical relationship between the morphological fixed parameter (PI) and the positional dynamic parameters (PT and SS): PI = PT + SS.

These well-known parameters have been extensively described, and are reviewed here briefly. PI is the angle between the line from the bicoxofemoral axis and the midpoint of the sacral end plate and the line perpendicular to sacral end plate (Fig. 3.6). PT is the angle between the line from the bicoxofemoral axis and the midpoint of the sacral end plate and the vertical line from that midpoint (Fig. 3.6). SS is the angle between the line extending from the sacral end plated and the horizontal line drawn from the posterosuperior corner of S1 (Fig. 3.6). A full understanding and visualization of these parameters is critical in grasping the importance of the most current classification approaches.

More recent literature in 2009 by Lafage et al.[44] conducted a combined analysis of SVA and PT. The study established the importance of the relationship between global alignment and pelvic compensation. In many cases, SVA alone is insufficient in determining whether a patient has sagittal misalignment; for example, a patient with a low, seemingly normal SVA could have increased pelvic retroversion to compensate and bring his SVA within normal limits. Such a patient's condition is actually worse than what a low SVA value may infer, as pelvic retroversion masks the apparent truncal offset. This demonstrates the need for a more comprehensive classification scheme, one which takes into account global alignment and pelvic parameters.

JAYPEE BROTHERS

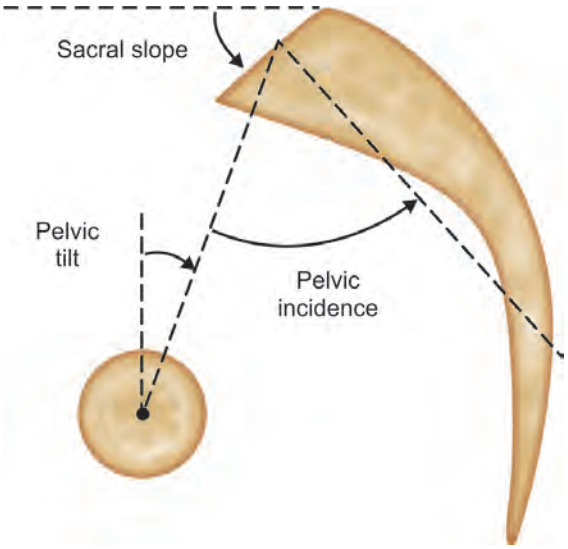

Fig. 3.6: Pelvic parameters (PI, PT, SS). (PI, pelvic incidence; PT, pelvic tilt; SS, sacral slope.)

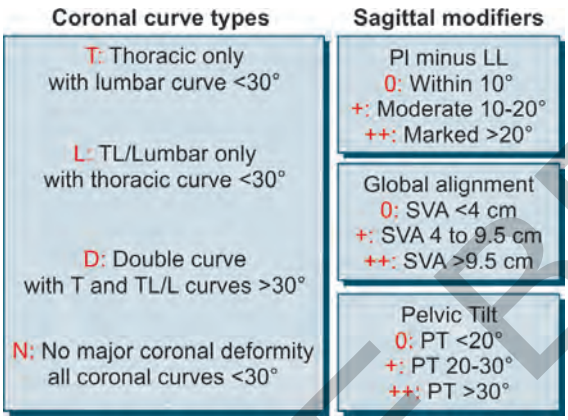

Fig. 3.7: SRS-Schwab classification scheme. Guide to the classification system, including curve type and three sagittal modifiers. (LL, lumbar lordosis; PI, pelvic incidence; PT, pelvic tilt; SVA, sagittal vertical axis.)

SRS-Schwab Classification of Adult Spinal Deformity

This most recent classification takes into account both coronal and the sagittal aspects of the deformity and includes pelvic parameters.[38] Similar to the Lenke classification of AIS,[45] ASD curve type is the overriding classifier, but the three modifiers are PI-LL, PT, and SVA (Fig. 3.7).

The *curve type* is determined on the basis of maximal coronal angle measured according to standard Cobb technique on a standard anteroposterior free-standing radiograph of the spine (14" × 36"). The major curve is the curve with the largest Cobb angle measurement and a minor curve is any other curve that does not have the largest Cobb angle measurement.

Curve type T: Patients with a thoracic major curve of >30° (apical level of T9 or higher) and lumbar curve <30° are classified with curve type T.

Curve type L: Patients with a lumbar or thoracolumbar major curve of >30° (apical level of T10 or lower) and thoracic curve <30° are classified with curve type L.

Curve type D: Patients with a double major curve, with each curve >30° are classified with curve type D.

Curve type N: Patients with no coronal curve >30° (i.e. no major coronal deformity) are classified with curve type N (normal).

The first sagittal modifier takes into account 2 radiographic parameters: PI and lumbar lordosis (LL). The *PI-LL modifier* expresses the importance of a harmonious relationship between spinal and pelvic parameters. It represents the difference between PI and LL, which is measured with the Cobb method in the sagittal plane between the superior end plate of L1 and the superior end plate of S1.[46]

- Patients with a PI-LL value of <10° are classified with a PI-LL modifier "0".
- Patients with a PI-LL value between 10° and 20° are classified with a PI-LL modifier "+".
- Patients with a PI-LL value >20° are classified with a PI-LL modifier "++".

The PT modifier assesses the degree of pelvic retroversion. PT is a crucial parameter in assessing spinal deformity. High values of PT express increased pelvic retroversion, a compensatory mechanism that can reduce the apparent extent of global sagittal malalignment. This parameter is highly correlated with pain and disability.

- Patients with a PT of <20° are classified with a PT modifier "0".
- Patients with a PT between 20° and 30° are classified with a PT modifier "+".
- Patients with a PT >30° are classified with a PT modifier "++".

The global alignment modifier groups patients based on cutoffs of SVA associated with increases in pain and disability. SVA is radiographic indicator of global alignment, defined as the offset between the sagittal C7 plumb line and the posterosuperior corner of the sacrum.[46]

- Patients with a SVA of <40 mm are classified with a SVA modifier "0".
- Patients with a SVA between 40 mm and 95 mm are classified with a SVA modifier "+".
- Patients with a SVA of >95 mm are classified with a SVA modifier "++".

JAYPEE BROTHERS

This classification scheme has been validated for its inter- and intra-rater reliability as well as its clinical correlations to HRQOL measures such as ODI, SF-36, and SRS-22.[38,47] Additionally, this scheme provides a framework and a common language that can help guide treatment decisions, research, surgical planning, and patient counseling regarding expectations.

TREATMENT

Care for ASD, like other orthopaedic conditions, is a balance between maximizing nonoperative management and intervening when surgical correction is most likely to lead to improved function and reduced pain. The only recommended preventative approaches (without clear data) for ASD are proper nutrition, adequate physical exercise, avoidance of smoking and inappropriate physical loads to minimize disk degeneration.

Treatment for ASD targets pain and disability (unlike AIS which targets curve progression and aesthetics). The source of pain is multifactorial, as are treatment options. Patients DDS will often be started on, or will present with a history of NSAID use for pain relief of their lower back pain. Steroid injections in the regional muscles, joints, or spinal canal can also allay the pain and be diagnostic and therapeutic. Careful consideration should be given with regards to narcotic medications in ASD, as with any other chronic pain condition. Other medications like tricyclic antidepressants have a sedative and analgesic effect at low doses, and can be considered for night-time pain control. In a geriatric population, gabapentin may also serve as a suitable adjunct.[22]

As described above, the soft tissues such as the hip extensors and knee flexors can compensate in sagittal deformity to maintain the SVA near the GL. However, this compensatory mechanism places a high demand on energy expenditure and muscle fatigue contributes to the already ongoing chronic pain. Other treatments that target this muscle stiffness and soreness include physical therapy to improve function and core strengthening exercises to improve strength and optimize a patient's cardiac reserve. However, symptomatic deformities are often unresponsive to nonsurgical treatment.

Surgical intervention is considered when spinal deformity is significant and symptoms progress beyond tolerable limits. Patients who develop marked pain and unacceptable disability despite exhausting nonsurgical management options should be evaluated for surgery, given that spinal instability, radiculopathy and sagittal malalignment are correlated with poor HRQOL scores.

Posterior spinal fusion with metal implants and bone graft with or without decompression of the nerve roots is the most common surgical approach, though severe cases require osteotomies to resect and realign the spine. Because SVA and PT rely heavily on PI and LL, and PI is a morphological parameter that cannot be changed, the osteotomy must target LL.[48,49] The targeted value of lumbar lordosis should approximate the value of PI, within 10°, in order to recreate spino-pelvic harmony.

Osteotomy not only allows for proper lumbar lordosis to be restored (given that loss of lumbar lordosis is a common finding among DDS patients) but also serves as the one controllable intraoperative parameter among the clinically crucial spinopelvic parameters (PI, LL, SVA, and PT). Correcting the regional lumbar lordosis simultaneously impacts the global sagittal alignment and pelvic retroversion. However, the degree to which SVA and PT can be corrected is only fully apparent postoperatively, though there have been many formulas developed to predict the values.[48,49]

Osteotomy techniques include partial facet resection, complete facetectomy, partial body resection, partial body and disk resection, complete body and disk resection, and multiple vertebrae and disk resection. Partial facet resections such as a Smith-Peterson osteotomy (SPO)[50] can achieve a deformity correction of around 5°, and is suitable for patients with a flexible anterior column. Complete facetectomies where the superior and inferior facets as well as the spinous processes are resected (Ponte technique) can achieve an even greater degree of correction around 5–10°. Partial body resections, also called a pedicle subtraction osteotomy (PSO)[51-53] or wedge resection, are suited when >20° of segmental correction is needed, and can achieve a deformity correction of about 25–35°; however, PSOs are most often used for idiopathic or iatrogenic flat-back deformities with a fixed sagittal malalignment as opposed to DDS. The other more aggressive osteotomies[19,54] are also not often used in correcting DDS, but do permit a three-plane correction, and necessitate rib resection and cage support in the thoracic spine.

JAYPEE BROTHERS

CONCLUSION

ASD is a condition with a high prevalence. No matter the etiology, be it idiopathic, degenerative or less frequent causes, they all share the same final pathway of deformity and degeneration enhancing one another in a vicious cycle.

The pathology of ASD starts after spinal skeletal maturity with biochemical changes in the disk responsible for discogenic degeneration, leading to loss of intersegmental stability, alterations in load sharing, and progressive sagittal malalignment with age.

There are a variety of possible presentations depending on whether neurologic structures are compromised. Most commonly, symptoms of spinal stenosis and radiculopathy are found in conjunction with loss in standing, walking endurance and tissue back pain. In addition to this, there are compen-satory mechanisms that can be observed inside and outside the spine, so a global assessment is fundamental to evaluating the patient with lumbar degenerative disease.

There have been many attempts at classification schemes in the past and there is a long history behind the development of the spinopelvic parameters in use today. The most current classification, SRS-Schwab, describes deformity in its coronal, sagittal, and pelvic relationships.

Treatment involves both nonoperative and operative management, with careful consideration of symptoms, disability, disease progression, and risk/benefit ratio.

Alignment and balance are often used as synonyms, but maybe they take on different implications. In uniting the international effort to advance scoliosis research, it is imperative to agree on terminology. Sagittal alignment refers to a geometrical relationship between the spine, pelvis, and the rest of the body. Sagittal balance refers not only to the geometry of alignment but also includes muscular forces, proprioception, and the vestibular apparatus that all contribute to upright homeostasis. As intuitive as this may seem, imaging studies detect mainly bony alignment, so other factors contributing to overall upright posture should also be taken into account when deciding how to deliver patient care. Achieving a correct alignment is a good starting point for sagittal balance in the patient with lumbar degenerative scoliosis.

REFERENCES

1. Scoliosis Research Society [Internet]. Available from: http://www.srs.org/patient_and_family/glossary/index.htm?alpha = S. Accessed Aug 26, 2013.
2. Scoliosis Research Society [Internet]. Available from: http://www.srs.org/patient_and_family/glossary/. Accessed Aug 26, 2013.
3. Biot B, Pendrix D. Frequence de la scoliose lombaire a l'age adulte. Ann Med Phys. 1982;25:251-4.
4. Carter OD, Haynes SG. Prevalence rates for scoliosis in US adults: results from the first National Health and Nutrition Examination Survey. Int J Epidemiol. 1987;16(4):537-44.
5. Francis RS. Scoliosis screening of 3,000 college-aged women. The Utah Study – phase 2. Physical Therp. 1988;68(10):1513-6.
6. Schwab F, Dubey A, Gamez L, et al. Adult scoliosis: prevalence, SF-36, and nutritional parameters in an elderly volunteer population Spine. 2005;30(9):1082-5.
7. Briard JL, Jegou D, Cauchoix J. Adult lumbar scoliosis. Spine. 1979;4(6):526-32.
8. Ascani E, Bartolozzi P, Logroscino CA, et al. Natural history of untreated idiopathic scoliosis after skeletal maturity. Spine. 1986;11(8):784-9.
9. Aebi M. The adult scoliosis. Eur Spine J. 2005;14 (10):925-48.
10. Scoliosis Research Society. Available from. http://www.srs.org/patient_and_family/scoliosis/idiopathic/adolescents/. Accessed Aug 26, 2013.
11. Weinstein SL. Natural history. Spine. 1999;24(24): 2592.
12. Benoist M. Natural history of the aging spine. Eur Spine J. 2003;12 (Suppl 2):S86-9.
13. Giunti A, Laus M. Le radicolopatie spinali. Bologna: Aulo Gaggi Editore Bologna; 1992. p. 538.
14. Kapandji IA. The Phisiology of the Joints, 6th edition. London, England: Churchill Livingstone; 2008. p. 352.
15. Kirkaldy-Willis WH, Farfan HF. Instability of the lumbar spine. Clin Orthop Relat Res. 1982;10(165): 110-23.
16. White AA, Panjabi MM. Clinical Biomechanics of the Spine, 2nd edition. Philadelphia: Lippincott Williams & Wilkins; 1990. p. 752.
17. Grubb SA, Lipscomb HJ, Coonrad RW. Degenerative adult onset scoliosis. Spine. 1988;13(3):241-5.
18. Boos N, Weissbach S, Rohrbach H, et al. Classification of age-related changes in lumbar intervertebral disks: 2002 Volvo Award in basic science. Spine. 2002;27(23):2631-44.
19. Bradford DS, Tribus CB. Vertebral column resection for the treatment of rigid coronal decompensation. Spine. 1997;22(14):1590-9.
20. Hammerberg EM, Wood KB. Sagittal profile of the elderly. J Spinal Dis Tech. 2003;16(1):44-50.

JAYPEE BROTHERS

21. Smith JS, Fu K-M, Urban P, et al. Neurological symptoms and deficits in adults with scoliosis who present to a surgical clinic: incidence and association with the choice of operative versus nonoperative management. J Neurosurg Spine. 2008;9(4):326-31.
22. Tribus CB. Degenerative lumbar scoliosis: evaluation and management. J Am Acad Orthop Surg. 2003;11(3):174-83.
23. Schwab F, Dubey A, Pagala M, et al. Adult scoliosis: a health assessment analysis by SF-36. Spine. 2003;28(6):602-6.
24. Schwab FJ, Smith VA, Biserni M, et al. Adult scoliosis: a quantitative radiographic and clinical analysis. Spine. 2002;27(4):387-92.
25. Glassman SD, Berven S, Bridwell K, et al. Correlation of radiographic parameters and clinical symptoms in adult scoliosis. Spine. 2005;30(6):682-8.
26. Glassman SD, Bridwell K, Dimar JR, et al. The impact of positive sagittal balance in adult spinal deformity. Spine. 2005;30(18):2024-9.
27. Schwab F, Farcy J, Bridwell K, et al. A clinical impact classification of scoliosis in the adult. Spine. 2006;31(18):2109-14.
28. Bradford DS, Tay BK, Hu SS. Adult scoliosis: surgical indications, operative management, complications, and outcomes. Spine. 1999;24(24):2617-29.
29. Dubousset J. Three-dimensional analysis of the scoliotic deformity. In: Weinstein S (Ed). The pediatric Spine: Principles and Practices. New York: Raven Press; 1994. pp. 479-96.
30. Ames CP, Smith JS, Scheer JK, et al. Impact of spinopelvic alignment on decision making in deformity surgery in adults: a review. J Neurosurg Spine. 2012;16(6):547-64.
31. Lafage V, Schwab F, Skalli W, et al. Standing balance and sagittal plane spinal deformity: analysis of spinopelvic and gravity line parameters. Spine. 2008;33(14):1572-8.
32. Bess S, Boachie-Adjei O, Burton D, et al. Pain and disability determine treatment modality for older patients with adult scoliosis, while deformity guides treatment for younger patients. Spine. 2009;34(20):2186-90.
33. Smith JS, Shaffrey CI, Berven S, et al. Improvement of back pain with operative and nonoperative treatment in adults with scoliosis. Neurosurgery. 2009;65(1):86-93; discussion 93-4.
34. Smith JS, Shaffrey CI, Berven S, et al. Operative versus nonoperative treatment of leg pain in adults with scoliosis: a retrospective review of a prospective multicenter database with two-year follow-up. Spine. 2009;34(16):1693-8.
35. Albert T, Purtill J, Mesa J, et al. Health outcome assessment before and after adult deformity surgery: a prospective study. Spine. 1995;20(18):2002-4; discussion p. 2005.
36. Smith JS, Shaffrey CI, Kuntz C, et al. Classification systems for adolescent and adult scoliosis. Neurosurgery. 2008;63(3 Suppl):16-24.
37. Schwab F, El-Fegoun AB, Gamez L, et al. A lumbar classification of scoliosis in the adult patient: preliminary approach. Spine. 2005;30(14):1670-3.
38. Schwab F, Ungar B, Blondel B, et al. Scoliosis Research Society – Schwab adult spinal deformity classification: a validation study. Spine. 2012;37 (12):1077-82.
39. Stagnara P, De Mauroy JC, Dran G, et al. Reciprocal angulation of vertebral bodies in a sagittal plane: approach to references for the evaluation of kyphosis and lordosis. Spine. 1982;7(4):335-42.
40. Vidal J, Marnay T. [Morphology and anteroposterior body equilibrium in spondylolisthesis L5-S1]. Revue de chirurgie orthopédique et réparatrice de l'appareil moteur. 1983;69(1):17-28.
41. During J, Goudfrooij H, Keessen W, et al. Toward standards for posture. Postural characteristics of the lower back system in normal and pathologic conditions. Spine. 1985;10(1):83-7.
42. Duval-Beaupère G, Schmidt C, Cosson P. A Barycentremetric study of the sagittal shape of spine and pelvis: the conditions required for an economic standing position. Ann Biomed Eng. 1992;20(4):451-62.
43. Legaye J, Duval-Beaupère G, Hecquet J, et al. Pelvic incidence: a fundamental pelvic parameter for three-dimensional regulation of spinal sagittal curves. Eur Spine J. 1998;7(2):99-103.
44. Lafage V, Schwab F, Patel A, et al. Pelvic tilt and truncal inclination: two key radiographic parameters in the setting of adults with spinal deformity. Spine. 2009;34(17):E599-606.
45. Lenke LG, Betz RR, Harms J, et al. Adolescent idiopathic scoliosis: a new classification to determine extent of spinal arthrodesis. J Bone Joint Surg Am Vol. 2001;83-A(8):1169-81.
46. O'Brian MF, Kuklo TR, Blanke KM, et al. Spinal deformity study group radiographic measurement manual. Memphis, TN: Medtronic Sofamor Danek; 2005.
47. Terran J, Schwab F, Shaffrey CI, et al. The SRS-Schwab adult spinal deformity classification: assessment and clinical correlations based on a prospective operative and nonoperative cohort. Neurosurgery. 2013;73(4):559-68.
48. Lafage V, Schwab F, Vira S, et al. Spino-pelvic parameters after surgery can be predicted: a preliminary formula and validation of standing alignment. Spine. 2011;36(13):1037-45.
49. Lafage V, Bharucha NJ, Schwab F, et al. Multicenter validation of a formula predicting postoperative spinopelvic alignment. J Neurosurg Spine. 2012;16(1):15-21.

JAYPEE BROTHERS

50. Smith-Petersen MN, Larson CB, Aufranc OE. Osteotomy of the spine for correction of flexion deformity in rheumatoid arthritis. Clin Orthop Relat Res. 1969;66:6-9.
51. Thomasen E. Vertebral osteotomy for correction of kyphosis in ankylosing spondylitis. Clin Orthop Relat Res. 1985;(194):142-52.
52. Bridwell KH, Lewis SJ, Lenke LG, et al. Pedicle subtraction osteotomy for the treatment of fixed sagittal imbalance. J Bone Joint Surg Am Vol. 2003;85-A (3): 454-63.
53. Bridwell KH, Lewis SJ, Rinella A, et al. Pedicle subtraction osteotomy for the treatment of fixed sagittal imbalance. Surgical technique. J Bone Joint Surg Am Vol. 2004;86-A Suppl:44-50.
54. Boachie-Adjei O, Bradford DS. Vertebral column resection and arthrodesis for complex spinal deformities. J Spinal Disord. 1991;4(2):193-202.

JAYPEE BROTHERS

for detailed information on orthopedic books, visit our website www.jaypeebrothers.com, for detailed information on orthopedic books, visit our website

ADULT DEGENERATIVE SCOLIOSIS

Coronal and Sagittal Deformities: Treatment and Management

The aging population and increased number of spinal deformities have created a rapidly expanding field of degenerative scoliosis.This book has been complied due to the numerous years of experience of thought leaders in this heterogeneous discipline. Experts in both Neurological and Orthopedic Surgery have been brought together to provide their insights into optimal treatment and patient outcomes.

The *Adult Degenerative Scoliosis* book is expected to serve as a manual to readers of several disciplines on the difficult topic of degenerative scoliosis. Its aim is to provide a concise, thorough and readily available manuscript on diagnosis, evaluation and treatment of coronal deformities.



James S Harrop MD is Professor of Neurological and Orthopedic Surgery at Kimmel Medical College (formerly, Jefferson Medical College) of Thomas Jefferson University, Philadelphia, Pennsylvania, USA. He is also the Neurosurgical Director for Acute Care for the Spinal Cord Injury Center of the Delaware Valley, and Director of the Spine and Peripheral Nerve Surgery Program.

He received his medical degree from Jefferson Medical College and completed his neurosurgical residency at Thomas Jefferson University Hospital. He also completed a combined neurosurgical and orthopedic spine fellowship at the Cleveland Clinic under the direction of Dr Edward C Benzel. He is board certified by The American Board of Neurological Surgery (ABNS).

He is dedicated to education and academics where he has served on the Congress of Neurological Surgeons (CNS) executive board for the last six heads and has led the Publication Committee serving as the editor for their quarterly journal (CNSQ). In addition, he is the Chairman of the CNS Simulation Committee. He also serves on the board of the Lumbar Spine Research Society (LSRS), Cervical Spine Research Society (CSRS) and Pennsylvania Neurologic Society.

Dr Harrop is the author of more than 180 articles published in peer-reviewed journals in addition to over 60 book chapters published in medical texts.



Alexander R Vaccaro MD PhD graduated Summa Cum Laude from Boston College in 1983 with a BS in Biology. He received his MD degree from Georgetown University School of Medicine where he was promoted with "Distinction". He earned membership in the Alpha Omega Alpha (AOA) Honor Society and graduated with honors in 1987.

He completed a year of Surgical Internship at Cedars-Sinai Medical Center in Los Angeles, California and his Orthopedic Surgery Residency was at Thomas Jefferson University where he graduated in 1992. Dr Vaccaro completed a Spine Fellowship at the University of San Diego, California. He earned a PhD in 2007 in the field of Spinal Trauma.

Dr Vaccaro is Richard H Rothman Professor and Chairman, Department of Orthopedic Surgery, Professor of Neurosurgery, Co-Director, Delaware Valley Spinal Cord Injury Center, Co-Chief of Spine Surgery, Sidney Kimmel Medical Center at Thomas Jefferson University and President, Rothman Institute, Philadelphia, Pennsylvania, USA. He was the recipient of the Leon Wiltse award given for excellence in leadership and clinical research for spine care by the North American Spine Society (NASS). He is the past President of the American Spinal Injury Association and current President of the Association for Collaborative Spine Research.

He has over 560 peer-reviewed and 189 non-peer reviewed publications. He has published over 300 book chapters. He is the editor of over 47 textbooks and co-editor of OKU-Spine I and editor of OKU-8. Dr Vaccaro is the Co-Fellowship Director of the Spinal Service at Thomas Jefferson University Hospital where he instructs current fellows and residents in the diagnosis and treatment of various spinal problems and disorders.



Ahmed J Awad MD is a Postdoctoral Research Fellow in Neurosurgery. He was born in Kansas in USA, grew up in Germany, then moved with family to Palestine. He received his medical degree from An-Najah National University in Palestine, where he was awarded the University Award for Academic Excellence. Dr Awad completed his internship year at Ministry of Health Hospitals in Palestine.

Dr Awad is interested in general neurosurgery, spine and brain tumors. He has published numerous peer-reviewed journal articles, book chapters and abstracts. Additionally, he has participated in several neurosurgery medical missions.

Available at all medical bookstores
or buy online at www.jaypeebrothers.com

JAYPEE BROTHERS
Medical Publishers (P) Ltd.
www.jaypeebrothers.com

Join us on facebook.com/JaypeeMedicalPublishers

Shelving Recommendations
NEUROLOGICAL SURGERY
ORTHOPEDIC SURGERY
SPINE SURGERY

ISBN 978-93-5152-496-0

9 789351 524960