ur website **www.jaypeebrothers.com,** for detailed information on vascular surgery, visit our website **www.jaypeebrothers.com**

ATLAS OF VASCULAR & ENDOVASCULAR SURGICAL TECHNIQUES

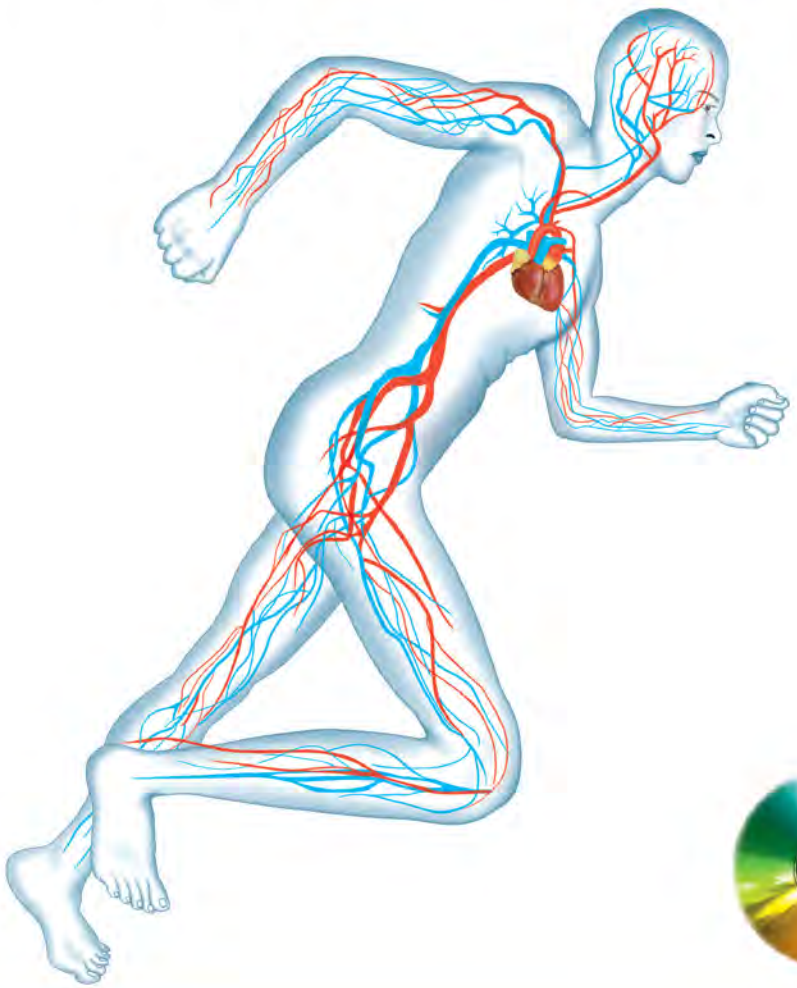



With CD-ROM

Editor-in-Chief
M Ashraf Mansour

Editors
Erica Mitchell
Murray Shames

JAYPEE

Contents

Section 1: Cerebrovascular

1. **Carotid Endarterectomy** 3
   M Ashraf Mansour
2. **Aortic Arch and Four-Vessel Cerebral Angiography** 9
   Lindsey M Korepta, Jason D Slaikeu
3. **Carotid Angioplasty and Stent** 19
   Jennifer J Watson, Christopher M Chambers
4. **Vertebral Artery Transposition** 27
   Mark D Morasch, M Ashraf Mansour
5. **Carotid—Carotid Bypass** 33
   M Ashraf Mansour
6. **Endovascular Therapy for Subclavian and Innominate Artery Stenosis** 39
   Jordan R Stern, Ross Milner
7. **Endovascular Treatment of Iatrogenic and Penetrating Subclavian Artery Injury** 45
   Michelle C Kosovec, Robert F Cuff
8. **Carotid Body Tumor Excision** 51
   Shonda Banegas, Jason D Slaikeu

Section 2: Thoracic Aorta

9. **Thoracic Aneurysm Repair** 57
   Basel Ramlawi, Michael J Reardon
10. **Thoracic Endovascular Aortic Repair for Traumatic Aortic Injury** 65
    Ali Azizzadeh, Sapan S Desai, Kristofer M Charlton-Ouw, Anthony L Estrera, Hazim J Safi
11. **Thoracic Endovascular Aneurysm Repair** 73
    Allan W Tulloch, David Rigberg
12. **Fenestration of Type B Dissection for Visceral Ischemia** 79
    S Sadie Ahanchi, Jonathan A Higgins, Jean M Panneton

Section 3: Abdominal Aorta

13. **AAA Repair: Transabdominal** 89
    Charles Bailey
14. **AAA Repair: Retroperitoneal** 99
    Charles Bailey, Murray Shames
15. **Aortobifemoral Bypass** 107
    Lindsay Gates, Jeffrey Indes
16. **Aortoiliac Artery Angioplasty** 115
    Lindsay Gates, Jeffrey Indes
17. **Endovascular Aneurysm Repair** 123
    Neil Moudgill

18. Hypogastric Artery Embolization 129
Neil Moudgill
19. Fenestrated Endovascular Aortic Repair Cook Zenith 135
Susan M Shafii, F Ezequiel Parodi
20. Obturator Bypass 141
J Westley Ohman, Patrick J Geraghty
21. Iliac Aneurysm Open Repair 147
Lindsay Gates, Jeffrey Indes
22. Endovascular Iliac Artery Aneurysm Repair 155
Lindsay Gates, Jeffrey Indes
23. Endoleak Management: Translumbar 161
Kamal Massis
24. Endoleak Management: Transarterial 167
Kamal Massis
25. Explant Aortic Endograft 175
Paul Armstrong
26. Iliac Artery Conduit 181
Paul Armstrong

Section 4: Visceral

27. Visceral Artery Bypass 189
Jason Jundt, Erica Mitchell
28. Renal Artery Bypass with Vein 197
Marcus R Kret, Greg Moneta
29. Aortorenal Endarterectomy 205
Tod M Hanover, Mark P Androes, John Eidt
30. Splenic Aneurysm Repair 217
Rachel C Danczyk, Greg Moneta
31. Endovascular Treatment of Renal Artery Aneurysm 225
John Eidt, Bruce Gray

Section 5: Peripheral Vascular

32. Diagnostic Angiography 243
Justin Hurie
33. Femoral Embolectomy 249
Michael Brewer, Karen Woo
34. Iliac Artery Angioplasty and Stenting 255
Christopher Smolock
35. Femoropopliteal Angioplasty and Stenting 265
Steven Satterly, Niten Singh
36. Open Repair of Femoral Artery Aneurysm 275
Robert Molnar, Maria Molnar

37. Popliteal Aneurysm Repair: Open **281**
Giye Choe
38. Popliteal Artery Aneurysm Repair: Endovascular **287**
James R Ballard, Erica Mitchell
39. Femoropopliteal Bypass **293**
Tina Chen, Peter Henke
40. Femoropopliteal Bypass, Reversed Vein **299**
Jean Marie Ruddy, Luke P Brewster
41. In Situ Venous Femoropopliteal Bypass **307**
Domenic R Robinson, Barend ME Mees
42. Femoropopliteal Bypass, Prosthetic and Vein Cuff **317**
Niten Singh
43. Tibial Artery Bypass **329**
Amir Azarbal
44. Arterial Thrombolysis and Mechanical Lysis **337**
Barend ME Mees, Ramon L Varcoe
45. Femorofemoral Bypass **345**
Elliot Stephenson, Greg Moneta
46. Coiling Peripheral Pseudoaneurysms **353**
Ashley K Vavra, Mark K Eskandari
47. Coiling Endoleak **359**
LeAnn A Chavez, John G Carson
48. Femoral Anastomotic Aneurysms **369**
Mitchell R Weaver, Alexander D Shepard

Section 6: Venous

49. Inferior Vena Cave Filter **379**
Neil Moudgill
50. Lower Extremity Venous Thrombolysis, Angioplasty and Stenting **385**
Bruce Zwiebel, Scott Perrin
51. Surgical and Pharmacomechanical Venous Thrombectomy **395**
Sharon Kiang, David Rigberg
52. Endovenous Therapy for Varicose Veins, RFA, and Laser **405**
Jean Marie Ruddy, Ravi K Veeraswamy
53. Deep Femoral Vein Harvest for Arterial Reconstruction **411**
Michael M McNally, Adam W Beck
54. Central Venous Port Placement **417**
Alexis Powell

Index *423*

CHAPTER 3

Carotid Angioplasty and Stent

Jennifer J Watson, Christopher M Chambers

1 PREOPERATIVE

1.1 Indications

Indications

Carotid stenosis identified on color-flow duplex scan or other imaging modality, >50% stenosis by NASCET criteria in a symptomatic patient, or >80% stenosis in an asymptomatic patient. In general, consideration for endarterectomy should be considered; however, if one or more conditions identified below are present, the patient is considered high-risk surgical candidate:

- Prior neck surgery, radiation, tracheostomy or neck immobility
- Prior open-carotid surgery with recurrent stenosis
- Pre-existing vocal cord or cranial nerve injury
- Severe cardiopulmonary comorbidities that increase the risk of general or regional anesthesia
- High lesions that are difficult to access with open surgery (at or above the level of C2)

Contraindications

- *Tortuous arch anatomy*: Tortuosity often increases with patient age and as the arch becomes more tortuous it becomes more difficult to select major vessels (Type 3 arches can be prohibitive in some cases) (Fig. 3.1).
- Extensive aortic calcification and extensive wall irregularities increase the risk of embolization and may be prohibitive in some cases.
- *Carotid artery considerations*: Heavy circumferential calcifications, tortuosity, unstable plaque, fresh thrombus, string sign, and lack of landing zone for placement of a cerebral protection device.

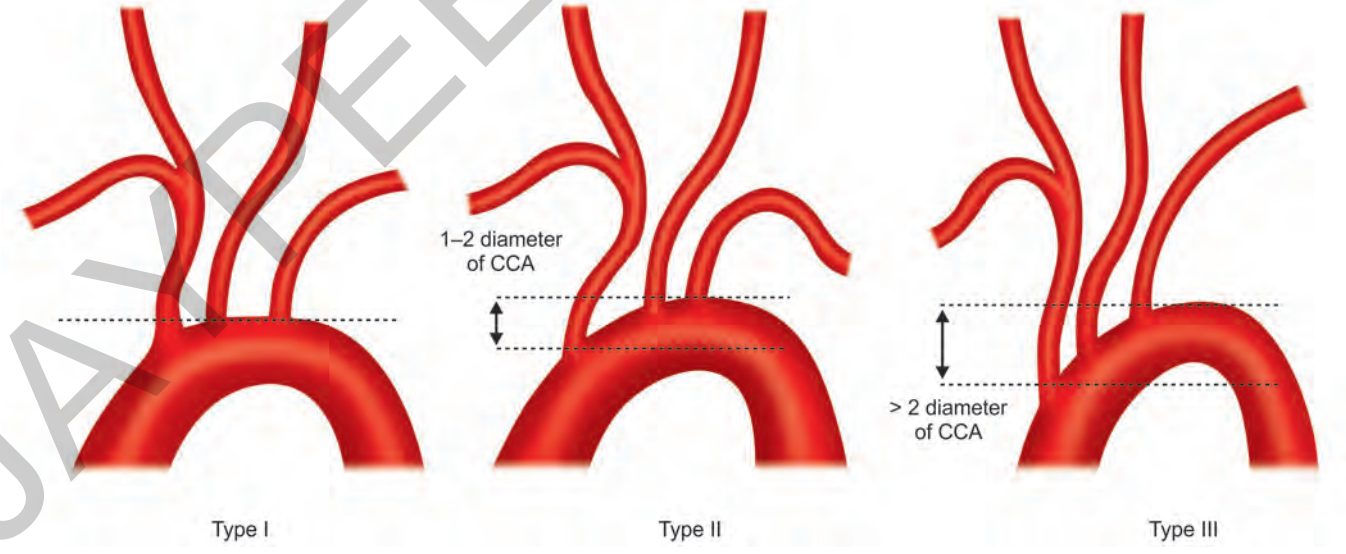

Fig. 3.1: The aortic arch is classified into three types. Type I the apex of the arch is at the same level as the take of the arch vessels. In a Type II arch one of the target vessels is below the level of the arch apex. In a Type III arch two or more of the target vessels are below the level of the arch. Type II and III arches can make cannulation and establishing a stable platform for stenting difficult.

JAYPEE BROTHERS



Fig. 3.2: Hybrid operating room.

- Inability to take clopidogrel (due to allergy or prior bleeding events) or dual antiplatelet regimen.

Relative Contraindications

- Congenital vascular anomalies that increase difficulty
- Chronic renal insufficiently (consider contrast-induced nephropathy prophylaxis)
- Contrast allergy (consider premedication with steroids and antihistamines)

1.2 Evidence

- Carotid stenting is feasible and has an acceptable complication rate when performed by experience operators in selected patients. Indications are similar to that of carotid endarterectomy with both asymptomatic (usually >80% internal carotid artery stenosis) and symptomatic (usually >50% internal carotid artery stenosis) disease being treated. In rare circumstances, dissections and ulcerated plaques with lesser degrees of stenosis have also been treated with stenting.[1]
- Carotid stenting has not been demonstrated to be superior to carotid endarterectomy. The SAPPHIRE trial results approached statistical significance (p = 0.053) for superiority with a composite endpoint of stroke, death, and myocardial infarction (MI). However, this trial has been criticized because the definition of MI was based solely on the elevation of CPK-MB, with or without symptoms or ST-T changes.[2,3]
- SPACE, EVA-3S and CREST all failed to demonstrate noninferiority for carotid stenting with the endpoint of stroke at 30 days. The periprocedural stroke rate in EVA-3, SPACE and CREST was higher in the carotid artery stenting group than in the open-surgery group making open surgery the better option for many patients.[4-6]
- In selected patients, carotid stenting has a role and is an important alternative to open surgery for patients with significant comorbid conditions such as high lesions, recurrent stenosis after open surgery, cervical spine immobility, prior neck surgery, and neck irradiation.

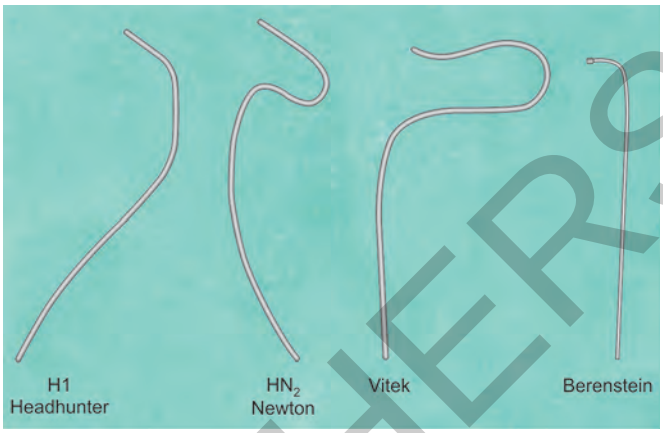

	Type 1 Arch	*Type II Arch*	*Type III Arch*
1st choice	Angled glidecath	Headhunter H1	Vitek
2nd choice	Headhunter H1	JB2	Simmons 2
3rd choice	Vertebral	Simmons 2	JB2

Fig. 3.3: This is a sample of currently available catheters for cannulation of target vessels. Selection is based on arch type and surgeon preference.

1.3 Materials Needed

- Appropriate radiographic equipment (preferably a hybrid operating room, interventional radiology suite or cardiac catheter laboratory) (Fig. 3.2)
- Access supplies (access needle, local anesthetic, knife, 5-Fr short sheath, etc.)
- Sheath 58 Fr (delivery system dependent)
- Contrast material (see chapter on carotid angiography)
- Guidewires (Benson 180-cm floppy tip 0.035 in and glidewire 260 cm, angled tip 0.035 in.)
- Flush catheters (Pigtail 100 cm 5 Fr)
- Cerebral selection catheters—Multiple options depending on arch anatomy (Vertebral, Headhunter, Simmons, Vitek, use 100–125 cm lengths) (Fig. 3.3)

JAYPEE BROTHERS

- Selected stent and deployment system (see stent selection section)
- Selected cerebral protection device (see cerebral protection device section)
- Femoral closure device if indicated

1.4 Preoperative Risk Assessment

Low risk:
- All patient undergoing carotid artery stenting will fall into the intermediate- or high-risk categories.

Intermediate risk (if two or more of the following consider the patient high risk):
- Prior MI with stable cardiac function
- Stable angina
- Controlled diabetes mellitus (DM)
- Advanced age >80 years
- Female gender

High risk:
- Ejection factor (EF) <30%, Unstable angina, poorly controlled coronary heart failure
- Poorly controlled DM
- Forced expiratory volume <30% predicted, need for home O_2
- Restenosis of prior CEA
- Renal insufficiency (creatinine >3.0).

1.5 Preoperative Checklist

Sign in:
- Patient identification via two patient identifiers, confirm surgical site.
- Confirm preoperative anticoagulation, antibiotic administration, β-blockers when indicated and contrast dye allergy prophylaxis if indicated.
- Verify necessary equipment is available and ready for use.
- Introduce all members or operating room team.

Time out:
- Final patient confirmation
- Laterality confirmation
- Review available imaging.

Sign out:
- Procedure preformed
- Patient disposition
- Postoperative concerns and postoperative anticoagulation.

1.6 Decision-Making Algorithm

Carotid artery angioplasty and stenting has not been proven to be superior to the open approach. In light of this each patient's symptoms, comorbid conditions and anatomy must be considered on an individual basis. Carotid artery angioplasty and stenting is an important part of the vascular surgeon's armamentarium and in selected cases can provide benefit.

Flowchart 3.1: Clinical decision-making algorithm.

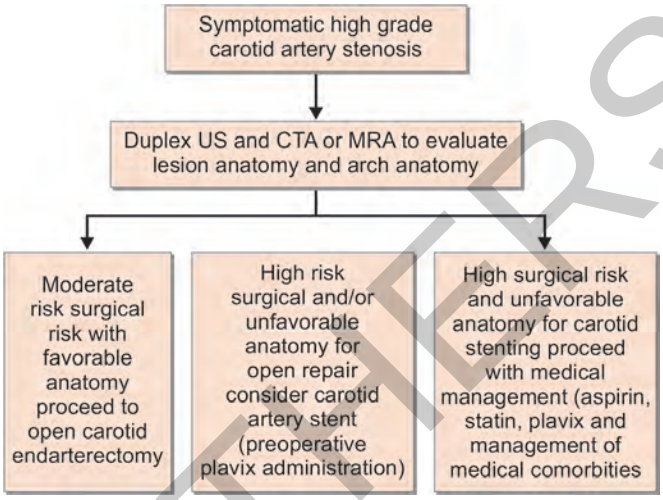

When considering endovascular carotid interventions preoperative imaging with computed tomography angiography or magnetic resonance angiography is essential to evaluate arch anatomy, severity of stenosis, type of plaque, length of target lesion, and the diameter of common and internal carotid artery for device selection. Aortic arch tortuosity increases with age and as the arch becomes more tortuous it becomes more difficult to select the major vessels. The lower the target vessels in relation to the height of the arch the more difficult cannulation will be. Extensive aortic calcification or extensive wall irregularities increase the risk of embolization and thus stroke. The anatomy of the carotid artery itself is also important with heavy circumferential calcifications, tortuosity, and unstable plaque or fresh thrombus, making stenting unfavorable. Access vessels should also be assessed by physical examination and in some cases require further imaging.

See Flowchart 3.1.

1.7 Pearls and Pitfalls

Pearls:
- *Preoperative anticoagulation*:
  - *Aspirin*: 81–325 mg daily for a minimum 4 days before the procedure unless urgent (if urgent a single dose can be given prior to surgery)

JAYPEE BROTHERS

  - *Clopidogrel*: loading dose of 300–600 mg on the day of the procedure OR 75 mg daily for 4 days before the procedure Continue aspirin and clopidogrel for a minimum of 4 weeks after procedure. Consider lifelong treatment if no contraindications
  - Consider statins in all patients
- *Preoperative considerations*:
  - Hydration and contrast premedication for renal protection.
  - Have atropine available during the procedure for carotid bulb manipulation with stent deployment and balloon angioplasty. Significant bradycardia and hypotension may occur
  - Vasodilators such as nitroglycerin should be available for direct administration into the carotid artery in the case of vasospasm.
- *Early heparinization*:
  - May reduced embolic events
  - Monitor activated clotting time to ensure systemic heparinization throughout the procedure
  - Use continuous heparin flush in the sheaths to avoid thrombus formation on the tip or in the lumen of the catheter
- *Negotiating tortuous anatomy*:
  - In cases with severe tortuosity, the 0.014 wires may not be stiff enough to allow advancement of the embolic protection device (EPD) or the stent. A "buddy wire", usually an angled glide wire is sometimes necessary to help advancing the EPD-stent.
  - It is sometimes necessary to "predilate" the stenosis to be able to deliver the stent.
- *Be prepared for potential complications*:
  - *Distal embolization*: prepare for intracranial lysis
  - EPD becomes plugged with debri and no flow seen distally: prepare for retrieval and place another filter if the stent is not deployed yet.

Pitfalls:

- Avoid unnecessary flushing into the arch or cerebral system, always back bleed sheaths and catheters before flushing.
- Avoid excessive wire manipulation which likely increases the risk of embolic events.
- "Puff" contrast to confirm the location of sheaths and catheters before pressure injection.

1.8 Surgical Anatomy

- *See* Figures 3.4A to C.

1.9 Positioning

An imaging system with the ability to achieve the appropriate fluoroscopic angles for arch and cerebral angiograms is required. We recommend the use of a hydride operating room when possible. The patient should be placed in the spine position with a squeeze toy secured in the contralateral hand. His or her arms should be tucked at the side with all lines, leads, and wires out of the fluoroscopic field. The patient's head should be comfortably extended on a support with a shoulder roll. The patient may be asked to turn his or her head to the contralateral side during portions of the procedure. At least two potential access sites should be sterilely prepped and draped (usually bilateral groin sites).

1.10 Anesthesia

- The patient should be alert enough to follow commands such as breath holding and squeezing the plastic squeeze toy in contralateral hand.
- An arterial line catheter should be inserted for blood pressure monitoring and frequent phlebotomy.
- The patient should receive preoperative β-blockers and antibiotics.
- Atropine should be available during angioplasty and stent deployment.

2 PERIOPERATIVE

2.1 Instructions

- *Access*: retrograde right common femoral percutaneous access with placement of a 5–8 Fr introducer (left common femoral access and brachial access are also options)
- Administer systemic heparin after access is achieved and prior to arch manipulation.
- Perform arch angiogram using a pigtail catheter, C-arm angled 45°–60° left arterial oblique.
- Select the common carotid artery; both sheath-based platforms and guiding catheter-based platforms are available:
  - When using a sheath-based platform a pre-shaped 5-Fr catheters (Simmons 1, Headhunter, Judkins 4, etc.) is used to select the common carotid artery and a stiff 0.035-in. guidwire is placed in the external carotid artery. A 6F 90 cm Shuttle Shealth (Cook, Inc.) is then advanced over the wire and placed in the distal common carotid artery.
  - When using a guiding catheter based platform the common carotid artery is selected with preshaped catheter (vertebral or reverse-angle Vitek catheter) and a 7–8 Fr is positioned in the common carotid artery and left in place. Intermittent heparinization of the catheter throughout the procedure is preformed via a side port.

JAYPEE BROTHERS

- Next perform a selective angiogram via the sheath or catheter. Use the optimal C-arm angle to open the angle between the external carotid artery and internal carotid artery.
- Next select the appropriate cerebral protection device. We most commonly use a distal embolic protection device. For placement, cross the internal carotid artery with a 0.014 wire and deploy the protection device just before C3/petrous portion of the internal carotid artery in a straight segment of artery.
- Consider predilatation in selected cases such as those with severe (>90%) stenosis. A 2.5–4.0 mm coronary balloon can be used at low inflation (4–6 atm).
- Take measurements based on the angiogram and pre-operative CT and select the appropriate stent. Position a self-expanding 6–10 mm, 2–4 cm length sent across the lesion. This will cross the carotid bifurcation in most cases. The stent should be size to largest portion of the common carotid artery plus 1 mm. Multiple varieties of stents are available (Fig. 3.5).
- Next postdilate with a 2-cm (5–6 mm) balloon, taking care never to exceed the diameter of the internal carotid artery. Take care to keep balloon within the stent during inflations and fully deflate the balloon prior to removal as not to disrupt the stent.
- Perform a completion angiogram and ensure flow beyond protection device.
- Remove protection device (device specific).
- Perform completion cerebral angiogram.
- Access site closures maybe preformed with a closure device or manual pressure. Systemic heparin reversal is rarely necessary.

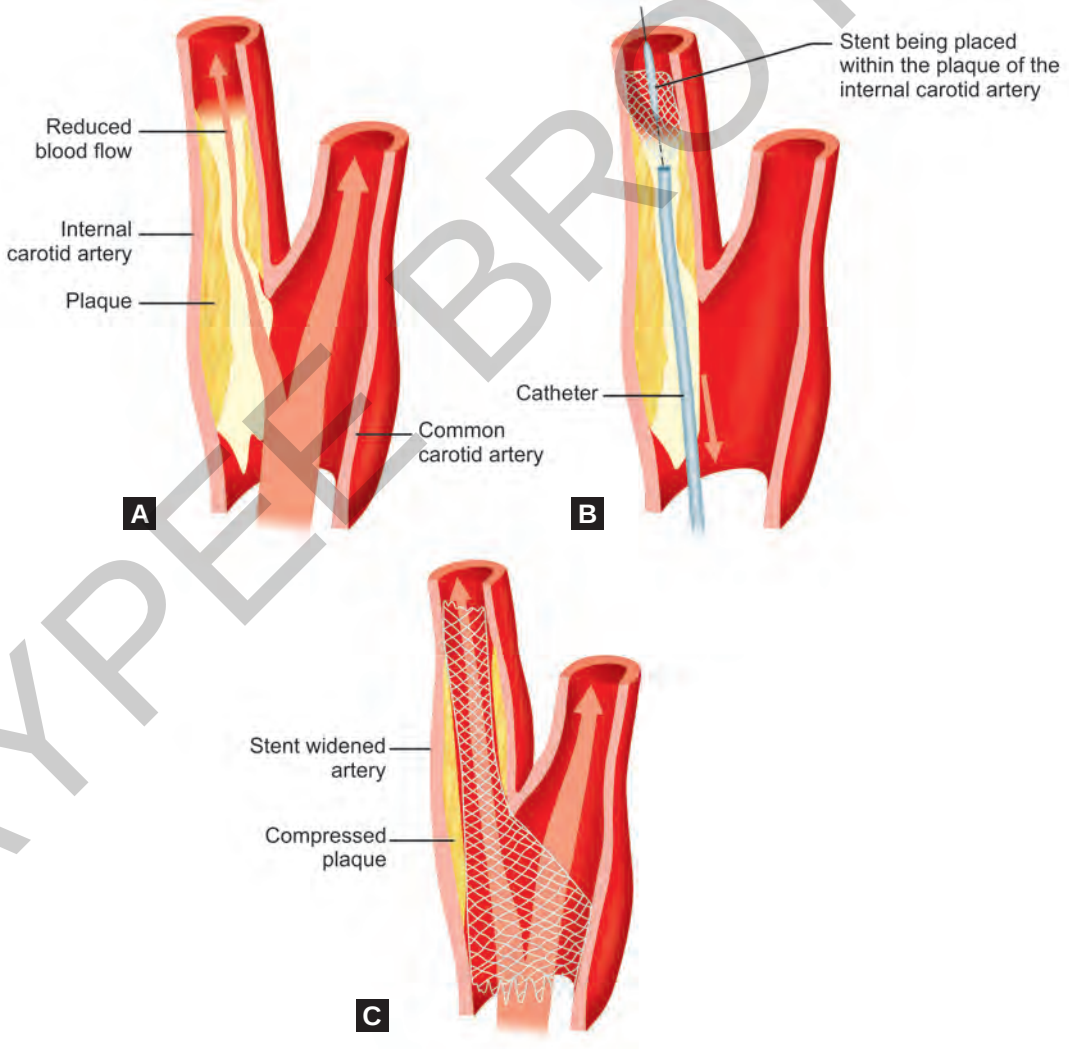

Figs. 3.4A to C: Internal carotid artery anatomy and flow dynamics.

JAYPEE BROTHERS

2.2 Cerebral Protection Devices Embolic Protection Devices (EPD)

There are three classifications of cerebral protection devices. The first in use were distal occlusion balloons. These devices are rarely the first choice today. The occlusive balloon is placed distal to lesion, inflated and frequently flushed and suctioned to remove plaque and debris. Major disadvantages include the need to cross the lesion unprotected, vasospasm, dissection or wall damage, and complete interruption of carotid flow (Figs. 3.6A and B).

The second type, distal filters, is commonly used and there are multiple types commercially available. They are umbrella like devices designed for placement in the distal internal carotid artery. These devices are mounted on a guidewire or their own delivery system. They are then retrieved at the end of the procedure using a dedicated retrieval system. Major advantages include allowing for continued flow and ease of use. While disadvantage include the need to cross the lesion unprotected, the possibility of clogging with debris, and difficultly in placement if the distal internal carotid artery lacks a straight segment.

Lastly, proximal occlusion or flow reversal device are made of two compliant balloons. One is placed in common carotid artery and one is place in the external carotid artery. Reversal of flow from the internal carotid artery occurs by continuous shunting of blood through a side post of the introducer and a separate femoral venous access. Advantages include no unprotected crossing of the lesion and disadvantages include technically difficultly, need for additional venous access and intolerance in some patients. Surgeons should select the protection device that suites their patient and with which they are most familiar.



Fig. 3.5: Sample carotid stents, tapered and nontapered.

2.3 Stent Selection

Multiple stents are commercially available with a range of sizes and configurations. They are constructed of stainless steel or nitinol and are available in open- and closed-cell designs. The open-cell design provides additional flexibility, while the closed-cell design may decrease embolic events. Hybrid configurations also exist with closed central portions and open proximal and distal portions. Tapered stents may be selected for cases with large discrepancies in proximal and distal diameters (Fig. 3.5)

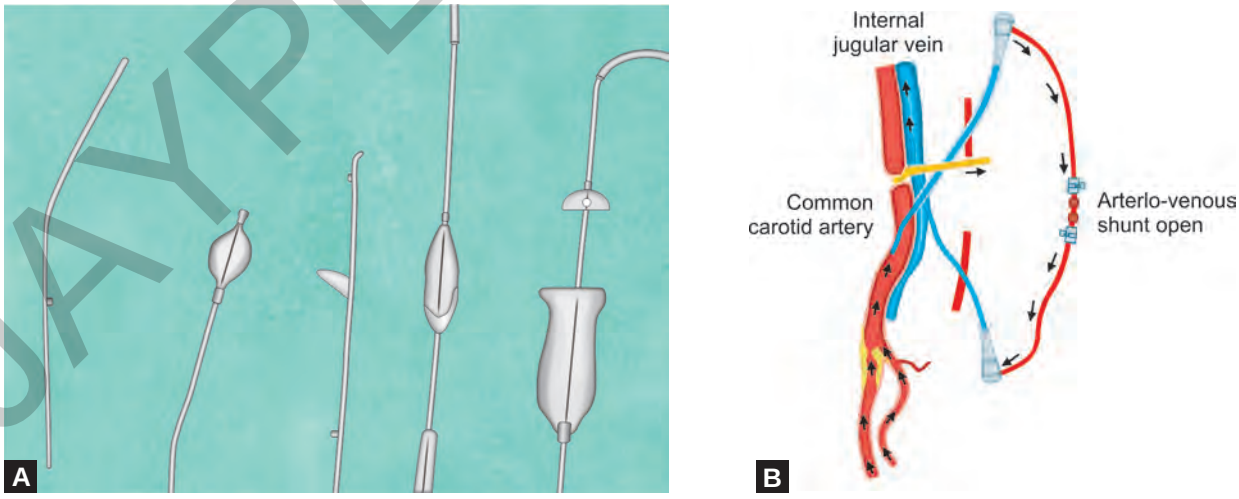

Figs. 3.6A and B: (A) Cerebral protection devices. (B) An example of flow reversal.

JAYPEE BROTHERS

3 POSTOPERATIVE

3.1 Complications

Most common complications (1–10%):

- Transient ischemic attack or ischemia stroke (at risk patients include those with difficult arch anatomy, advanced age and long lesions)
- Access site complications including bleeding, hematoma, and pseudoaneurysm (1–3%)
- Bradycardia or hypotension with carotid bulb manipulation (can be prolonged beyond 24 hours in rare cases)
- Cardiac events (ischemia, MI).

Least common complications (< 1%):

- Bleeding from arch trauma or local vessel injury
- Dissection, in the arch or carotid
- Jaw claudication (associated with coverage of the external carotid artery).

3.2 Outcomes

- Immediate postoperative hypotension, hypertension, or bradycardia requiring ICU admission is seen in approximately 10% of patients
- Average 30-day stroke rate is 2% to 5%
- 30-day combined stroke, MI, and death rate is 4–7%
- 5–15% restenosis at 2 years.

3.3 Follow-Up

- Patients should initially have 24 hours of in-hospital neurologic and cardiovascular monitoring.
- Outpatient follow-up plans differ but we suggest physical examination and duplex US imaging at 6 weeks, 6 months, 1 year, and annually thereafter
- The contralateral carotid artery may require monitoring depending on the degree of stenosis
- Consider lifelong aspirin and statin administration. Clopidogrel should be continued for 3 months postoperatively and lifelong in some cases.

3.4 E-mail an Expert

- *E-mail address:* christopher.chambers@spectrumhealth.org

REFERENCES

1. Brott TG, Hobson RW, Howard G, et al. Stenting versus endarterectomy for treatment of carotid-artery stenosis (CREST). NEMJ. 2010;363:11-23.
2. Eckstein HH, Ringleb P, Allenberg JR, et al. Results of the stent-protected angioplasty versus carotid endarterectomy (SPACE) study to treat symptomatic stenoses at 2 years: a multinational, prospective, randomised trial. Lancet Neurol. 2008;7:893-902.
3. Yadav J, SAPPHIRE investigators. Stenting and angioplasty with protection in patients at high risk for carotid endarterectomy: the SAPPHIRE trial. Circulation. 2002;106:2986-689.
4. EVA-3S Investigators. Endarterectomy vs. angioplasty in patients with symptomatic severe carotid stenosis. Cerebrovasc Dis. 2004;18(1):62-5.
5. Ederle J, Featherstone RL, Brown MM. Randomized controlled trials comparing endarterectomy and endovascular treatment for carotid artery stenosis: a Cochrane systematic review. Stroke. 2009;40(4):1373-80.
6. Yadav JS, Wholey MH, Kuntz RE, et al. Protected carotid-artery stenting versus endarterectomy in high-risk patients. NEJM. 2004;351(15):1493-501.

QUIZ

Question 1: Which of the following patients is most likely to benefit from carotid artery stenting

a. 55-year male smoker with symptomatic high grade stenosis of his internal carotid artery and a prior coronary artery bypass graft and an EF of 55%
b. 88-year female with asymptomatic 60–79% carotid stenosis and prior neck radiation
c. 60-year male with symptomatic high-grade stenosis and a prior radical neck dissection
d. 75-year female with asymptomatic high-grade stenosis and poorly controlled DM

Question 2: The best time to administer systemic heparin when performing carotid artery stenting is

a. Prior to starting the procedure
b. After gaining initial access via the common femoral artery
c. After placement of a sheath within the common carotid artery
d. Five minutes before stent deployment

Question 3: When planning to perform carotid artery stenting a preoperative CT angiogram of the neck can provide information regarding which of the following:

a. Aortic arch anatomy including grade and degree of calcifications
b. Severity of stenosis
c. Diameter of common and internal carotid artery for device selection
d. All of the above

ANSWERS: 1. c 2. b 3. d

JAYPEE BROTHERS

for detailed information on vascular surgery, visit our website **www.jaypeebrothers.com,** for detailed information on vascular sur

ATLAS OF VASCULAR & ENDOVASCULAR SURGICAL TECHNIQUES

Atlas of Vascular and Endovascular Surgical Techniques provides a practical approach to many of the most commonly performed open and endovascular procedures in 54 chapters. This book is organized into six distinct sections focusing on Cerebrovascular, Thoracic Aorta, Abdominal Aorta, Visceral, Peripheral Vascular, and Venous Conditions.

Notable features of this highly illustrated Atlas include:

- Bulleted, templated format with sections on Evidence, Materials Needed, Patient Positioning, Risk Assessment, Complications, Outcomes, and Follow-up
- Pearls & Pitfalls
- Quiz (with answers)
- CD with video clips



M Ashraf Mansour MD RPVI FACS is a leading vascular surgeon and endovascular specialist practicing in Grand Rapids, Michigan, USA. He completed his General Surgery Residency at the University of Colorado Health Sciences Center in Denver, Colorado, and Vascular Surgery Fellowship at Southern Illinois University in Springfield, Illinois, USA. Dr Mansour served in the United States Army Medical Corps. After completing his training, Dr Mansour was the Faculty at Loyola University Chicago, where he was a practicing surgeon and General Surgery Residency Program Director. He then moved to Grand Rapids where he started the Vascular Surgery Fellowship and Residency Program. In 2010, he was named the Chairman of the Department of Surgery at MSU and Spectrum Health Medical Group. Prior to that, he was the Chief of the Cardiovascular Division at Spectrum Health.

Dr Mansour has served as the Principal Investigator on several clinical trials, and has also served on the Executive Councils of several specialty societies. He has authored and co-authored over 90 peer-reviewed publications and 30 book chapters, and co-edited the textbook Vascular Diagnosis. In addition to his academic and administrative responsibilities, he continues to be a practicing vascular surgeon, board-certified in surgery, surgical critical care, and vascular surgery.



Erica Mitchell MD MEd SE FACS is Associate Professor of Surgery and Program Director for Vascular Surgery at Oregon Health and Science University (OHSU), Portland, Oregon, USA. Dr Mitchell's academic focus is surgical education, surgical skills training and competency assessment, including simulation, and her research focuses primarily on these areas. She is the Co-director for Simulation at OHSU and serves on the Steering Committee for the OHSU Interprofessional Education Initiative, a program directed towards enhancing quality and safety initiatives at OHSU. Nationally, she serves on committees for the SVS, SCVS, VESS, ACS, ACS-AEI, ASE, and APDVS, participated in the development of the Vascular Surgery Milestones, and also serves on the American Board of Surgery—Vascular Surgery Board.



Murray Shames MD RPVI FACS is vascular surgeon and endovascular specialist, and is the Director of the University of South Florida/Tampa General Hospital Aortic Center, Tampa, Florida, USA. He completed his General Surgery Residency at the University of South Florida in Tampa, and Vascular Surgery Fellowships at the University of Sydney in Australia and at Washington University in St. Louis, USA. After completing his training, Dr Shames returned to Tampa to join the faculty at USF. In 2005, he was named the Program Director at USF and in 2007 started one of the first Integrated Vascular Surgery Residency Programs in the country.

Dr Shames has served as the Principal Investigator on several clinical trials. He has also served on the Executive Councils of numerous specialty societies and has authored and co-authored over 50 peer-reviewed publications and numerous book chapters. His clinical focus is the treatment of aortic diseases, and his academic interests include AAA pathophysiology, endovascular technology, and the role of simulation in resident education.

Available at all medical bookstores
or buy online at www.jaypeebrothers.com

JAYPEE BROTHERS
Medical Publishers (P) Ltd.
www.jaypeebrothers.com

Join us on facebook.com/JaypeeMedicalPublishers

Shelving Recommendation
VASCULAR SURGERY

ISBN 978-93-5152-527-1