s, visit our website www.jaypeebrothers.com, for detailed information on ophthalmology books, visit our website www.jaypeebrothers.com

JAYPEE

Practical Retinal OCT

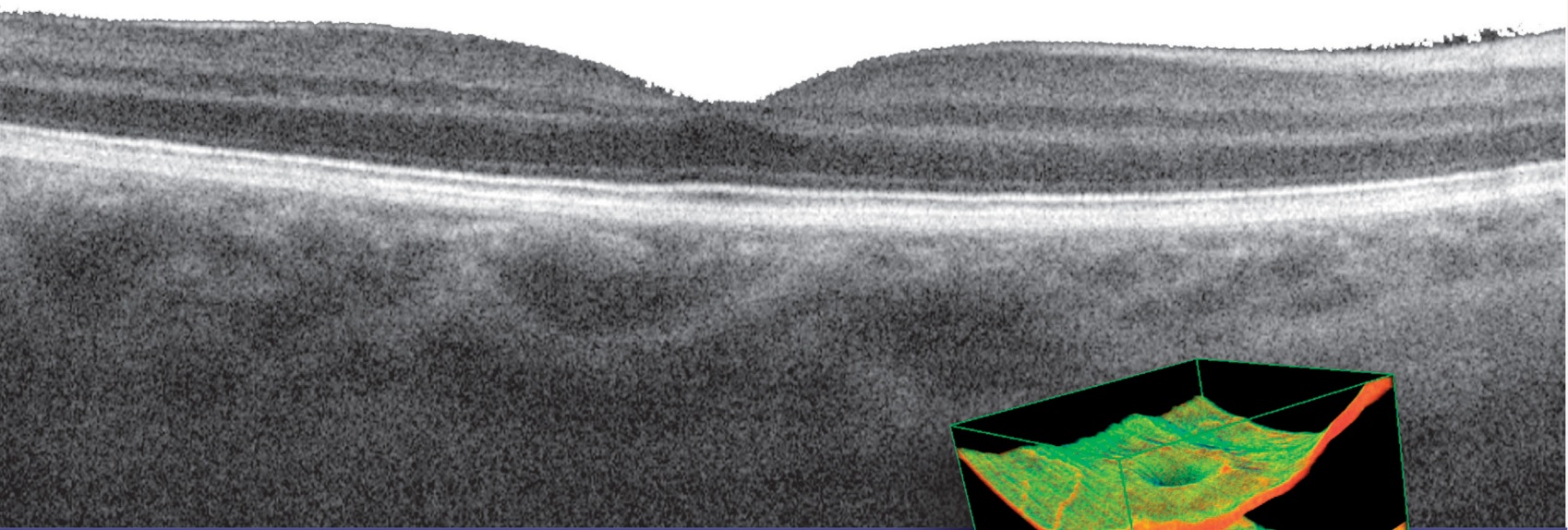



Bruno Lumbroso
Marco Rispoli

Contents

Chapter 1 OCT and Histology **1**

– Hyaloid Membrane and Vitreous *1*
– Inner Retina *1*
– Outer Retina *1*
– Photoreceptors, Cones and Rods *2*
– Retinal Support Structures *2*
– Retinal Pigment Epithelium *2*
– Bruch's Membrane *3*
– Choroid *3*

Chapter 2 Normal Chorioretinal OCT Analysis **11**

– Retina and Choroid Morphology *11*
– Retina and Choroid Structure *11*
– Infrastructure *15*
– Vertical Structures *15*
– Horizontal Structures: Retinal Layers *16*
– Segmentation *16*
– Normal Tissue Reflectivity *18*
– High Reflectivity *18*
– Low Reflectivity *18*
– Choroid *18*
– Artifacts *19*

Chapter 3 Qualitative Analysis of Pathologic OCTs **21**

– OCT Limits *22*
– OCT Imaging of Optic Disk *22*
– Morphology Study *22*
– Global Retinal Deformation *22*
– Retinal Profile and Retina Surface Deformation *23*
– Morphologic Posterior Alterations *24*
– Retinal Profile Outline *24*
– Outer Retina Outline *30*
– Retinal Structure Study: Segmentation *41*
– Structure: Segmentation *41*
– Inner Retina and Outer Retina *42*
– Outline–Segmentation *46*

– Reflectivity Study *48*
– High Reflectivity *48*
– Low Reflectivity *49*
– Abnormal Formations *55*
– Preretinal Formations *55*
– Intraretinal Formations *55*
– Posterior Formations *55*
– Shadow Areas (Screen Effect, Shadow Cone) *59*

Chapter 4 Quantitative Analysis of Pathologic OCTs 61
– Linear Measurements of Axial B-scans *61*
– Measurement of Coronal Images and “En Face” Scans *61*
– Quantitative Segmentation *62*
– Retinal Mapping *62*
– Quantitative Analysis: Thickness *63*
– Increased Thickness *63*
– Reduced Thickness *63*
– Thickness Variations of the Retinal Layers *65*
– Retinal Volume *65*
– Quantitative Choroid Analysis *66*
– Quantitative Optic Disk Analysis *66*

Chapter 5 “En Face” Imaging 67
– 3D Images: Segmentation of Chorioretinal Layers *67*
– Frontal Plane Scans *67*
– Frontal "En Face" Sections Fit to the Retinal Pigment Epithelium Concavity *68*
– Thickness of the Retinal Section *68*
– Tips and Parameters of the "En Face" Scanning Procedure *79*

Chapter 6 Synthetic Study 80

Chapter 7 Reporting 82
Reporting an OCT Test *82*
Scans *82*

Chapter 8 Glaucoma 85
– Glaucoma Scan Protocols *85*
– Glaucoma Follow-up *86*
– Ganglion Cell Complex Glaucoma Progression Report *86*
– Retinal Nerve Fiber Layer Glaucoma Progression Report *87*
– Normative Database *87*
– Glaucoma Diagnosis *87*

Index *93*

CHAPTER

3 Qualitative Analysis of Pathologic OCTs

OCT reading should be performed in two steps:

- Qualitative and quantitative analytical study
- Synthetic study.

In the* first analytical phase *we subdivide and analyze OCT various elements. To this effect we need to perform segmentation, sagittal (B-scan) and frontal ("en face") scans, studying separately morphologic alterations, structural alterations, hyperreflectivity, hyporeflectivity and quantitative alterations.

Only after these elements are studied and analyzed we can move to* second stage, the synthesis, *using the results of the physical examination, anamnesis, fluorangiography, indocyanine green fluorangiography, autofluorescence imaging. The confrontation and synthesis of all these elements will allow interpreting the OCT and reaching a diagnosis.

The analytical step, first and important step, can be subdivided in **(Table 1)**:

- **Qualitative analysis**
  - Morphology study
  - Structure study: segmentation
  - (Hyper-, hypo-) reflectivity study
  - Study of abnormal formations and deposits
  - Study of shadow areas
- **Quantitative analysis.**

OCT is easy to use and the learning curve is short; it is a reliable, sensitive test (its resolution equals 3 microns). The images thus generated can be analyzed, quantified, saved and compared to those obtained by subsequent tests, allowing one to diagnose, quantify the lesions and follow up the illness progress.

The images are reproducible with different instruments and by different operators; the scanning is fast, simple and most importantly does not require the administration of contrast media. It is a

noninvasive examination to be preferred to other more invasive examination tests that can induce complications and cause medical-legal problems.

OCT LIMITS

A good transparency of the dioptric media and a normal tear film or artificial tears are needed. The test is difficult to perform in the presence of high myopia, nubecolae or corneal edema, lens opacity, vitreous turbidity, vitreal hemorrhages.

Currently, scans can generally be performed at the posterior pole level, although today's thanks to fast technical progress there are OCT devices capable to explore the very large retina segments (XR Avanti, Optovue).

TABLE 1 **Qualitative analysis**

The qualitative analysis of pathologic OCTs includes five basic steps:

1. **Morphology study**, i.e. the study of shape and profile of retina-retina and retina-choroid interfaces, as well as the choroid-sclera interface.
2. **Structure study** (segmentation). Retina and choroid are multistratified tissues, with layers that are parallel to each other and a concave bowl-like shape within the sclera. The retinal structure also includes the transversal formations that join together the various layers.
3. **Reflectivity study** (high, low reflectivity).
4. **Study of abnormal formations and deposits**.
5. **Study of shadow areas**.

OCT IMAGING OF OPTIC DISK

The horizontal scans shows the physiological excavation in which the high reflectivity nerve fibers penetrate. The retina stops at the border with the papilla. The retinal pigment epithelium choriocapillaris is abruptly truncated, while superficial nerve fibers merge with those of optical nerve. The scleral ring can be observed.

A quantitative analysis allows one to establish the optic disk diameter and the diameter and area of excavation at various depth levels.

The subject will be dealt with in detail in the chapter "Papillary Pathology and Glaucoma".

Morphology Study

Morphology: The determination of the shape and dimension of retina and choroid or the parts thereof. Proceeding from the vitreous toward the choroid, a morphology study requires the layer evaluation of retina and choroid or any parts thereof.

GLOBAL RETINAL DEFORMATION

Concavity (myopia): OCTs highlight a marked concavity in case of strong myopia and, especially, posterior staphyloma.

Convexity: It is often seen in case of dome-like detachment of the retinal pigment epithelium, but it can be caused by a subretinal cyst or tumor. In the latter case, the convexity is more flat and encompasses the subretinal layers (epithelium and choriocapillaris), lacking the slant observed in epithelium detachment. In most cases, it is impossible to locate the tumor itself. Almost always, the neuroepithelium presents localized edema or elevations. Another possible cause is dome-shaped macula, frequently observed in myopia and generally due to scleral thickening.

A retinal localized concavity suggests scleral staphyloma in the myopic eye or scleritis outcome.

RETINAL PROFILE AND RETINA SURFACE DEFORMATION (TABLES 2 AND 3)

The disappearance of the foveal depression frequently signals a clinically significant retinal edema.

Epiretinal membranes exert vertical or horizontal traction onto the retinal surface, deforming its profile, sometimes creating intraretinal cracks. They always induce retinal folds formation.

Macular pucker produces visible surface irregularities. The retinal surface is deformed by folds and curled under the pull exerted by the epiretinal membranes. Said membranes, often visible, can be coalescent, unidentifiable from and confused with the nerve fiber layer. They induce retinal folds formation. ”En face” scans visualize well these retinal fods, which often are star-shaped or parallel waves **(Figs 1 to 6)**.

Macular pseudohole: An augmented foveal depression, caused by epiretinal membranes, simulates a macular hole in the retina. The residual retinal tissue on the depression bottom is deformed, but not decreased.

Lamellar hole: The foveal depression is increased by the disappearance of internal retinal layers. The partial presence of the retinal tissue above the retinal pigment epithelium suggests the diagnosis of lamellar hole **(Fig. 7)**.

Macular holes: The capability to identify the macular hole, classify it and measure its diameter constitutes an important progress achieved by OCTs.

According to Gass’ classification, we can observe:

- Stage 1: Disappearance of the foveal depression and formation of a small area, optically empty (cyst) below the retinal surface.
- Stage 2: The inner retina is partially fissured, the operculum still adheres to the hole’s edge and there is a slight increase in thickness.
- Stage 3: The hole has reached full retinal thickness, all the way to the retinal pigment epithelium, the operculum has lost adherence to the retina, a retinal edema is present, the retinal thickness has increased and presents a small detachment.
- Stage 4: The hole interests full retinal thickness, there is a loss of retinal tissue, a marginal retinal cystoid edema, and the margins are elevated.

These are the typical features seen when the B-scan goes through the hole center. When the scan is not perfectly centered and crosses the lesion margins, appearance can be deceptive, suggesting a pseudohole or a hole in progress.

MORPHOLOGIC POSTERIOR ALTERATIONS

The retinal pigment epithelium can present a decreased or increased thickness. Sometimes, that thickness can be irregular, due to the alteration or loss of one or two layers. Layers can appear abnormally and irregularly thickened or disaggregated.

The three retinal pigment epithelium layers can be visible and evident, or appear fused together.

Retinal drüsen generate irregularities and waves on the retinal pigment epithelium complex and the Bruch's membrane can be easily seen as a thin hyperreflective line.

The retinal pigment epithelium serous detachments deform the retinal posterior limit and forms with the choriocapillaris an angle greater than 45 degrees, whereas the serous detachments of neuroepithelium protrude less and form angles equal to or less than 30 degrees with the retinal pigment epithelium. The Bruch's membrane is visible **in case of RPE detachment (Fig. 8)**.

Retinal Profile Outline

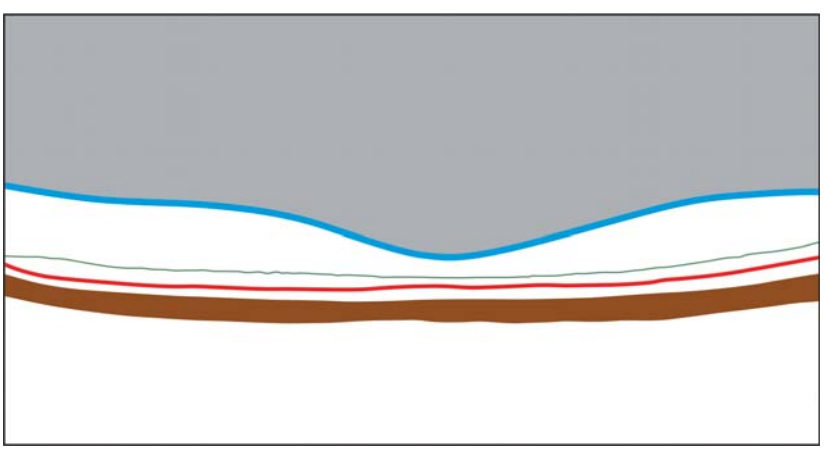

1. Normal profile.

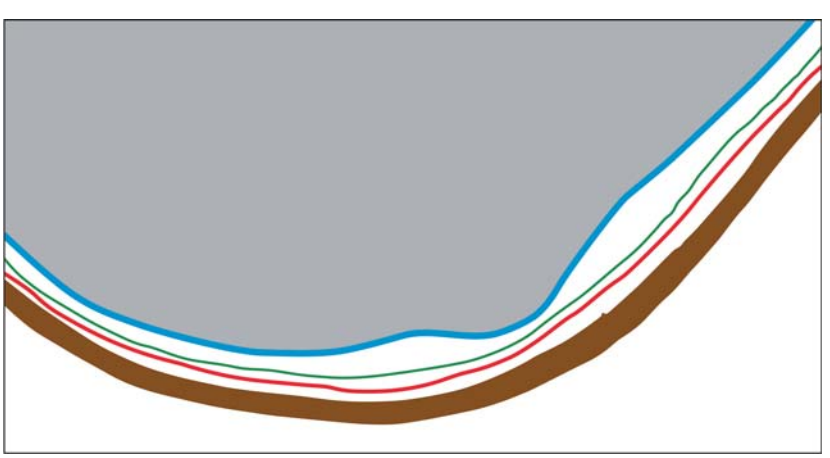

2. Full thickness deformation of the central retina; concavity in a case of strong myopia.

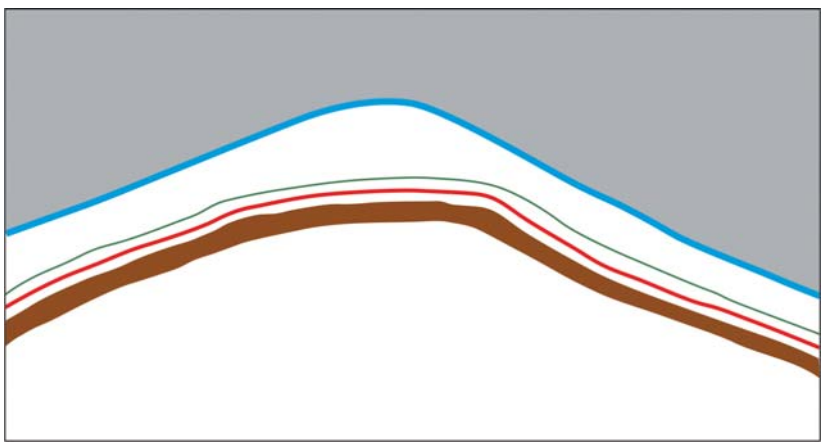

3. Full thickness deformation of the central retina; convexity is dome-shaped in a case of subretinal benign neoformation.

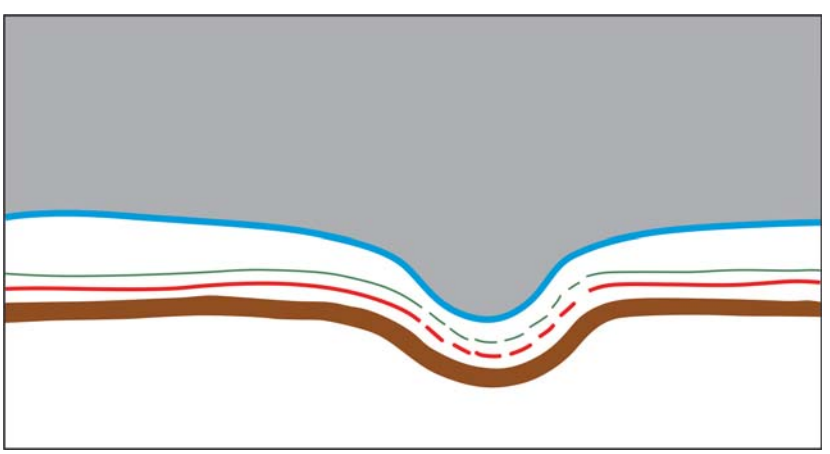

4. Full thickness retinal deformation; localized concavity in case of scleral staphyloma, as a consequence of scleritis.

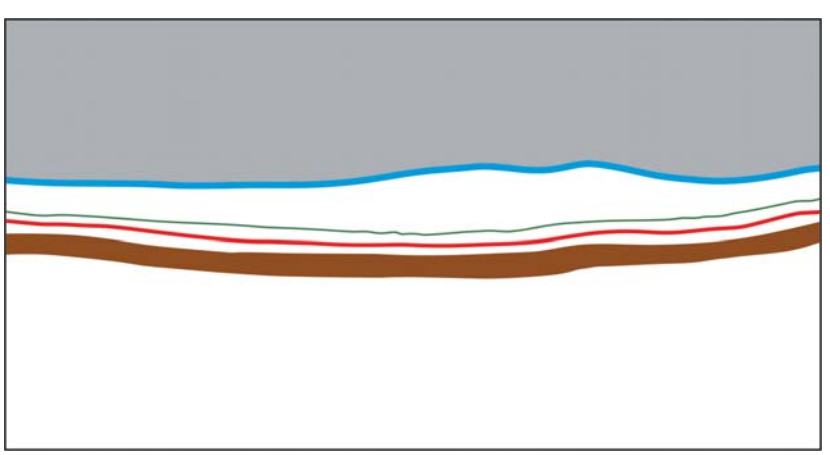

5. Foveal depression is not visible.

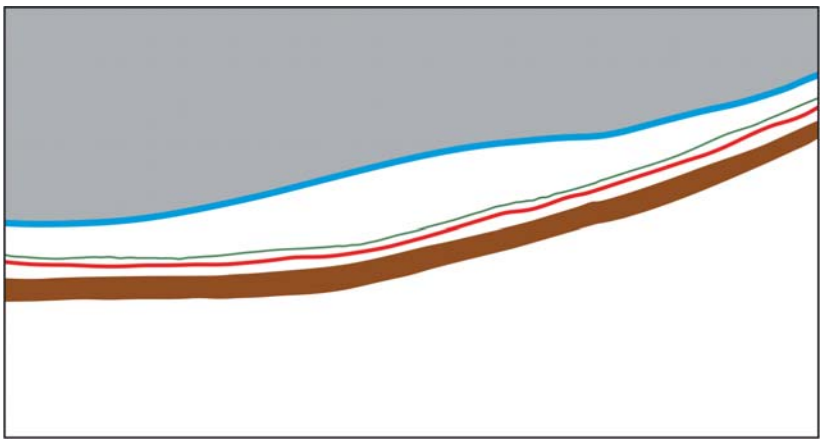

6. Convexity caused by diffuse retinal edema.

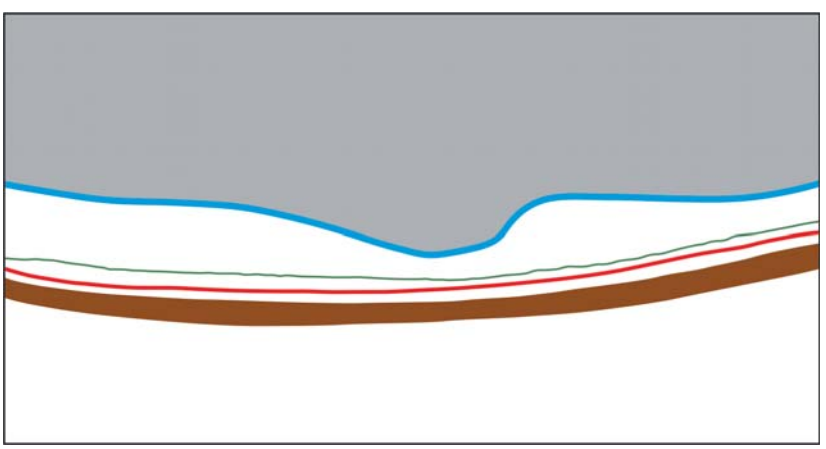

7. Asymmetrical foveal depression in localized edema.

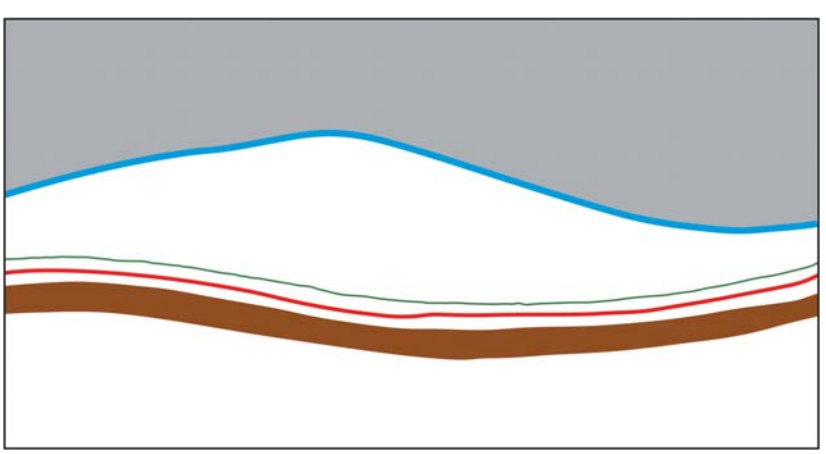

8. Marked retinal thickening with disappearance of foveal depression in a case of diffuse edema in diabetic retinopathy.

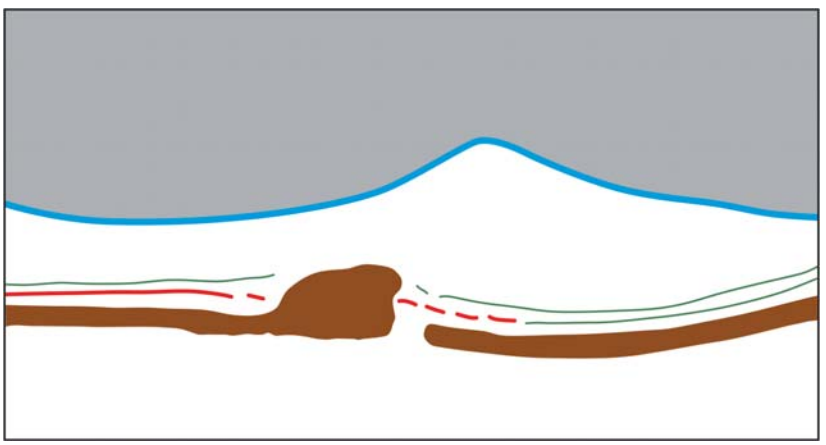

9. Convexity caused by retinal edema in a case of subretinal revascularization.

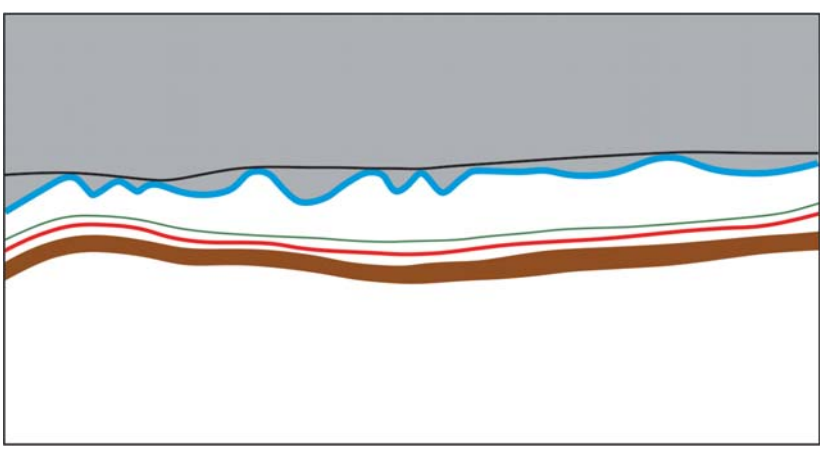

10. Retinal folds caused by horizontal traction exerted by an epiretinal membrane.

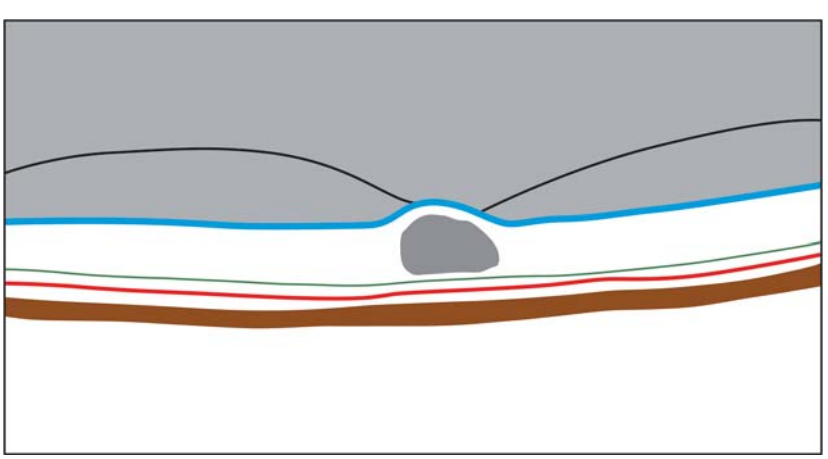

11. Retinal profile deformed by vitreoretinal traction, appearance of impending hole.

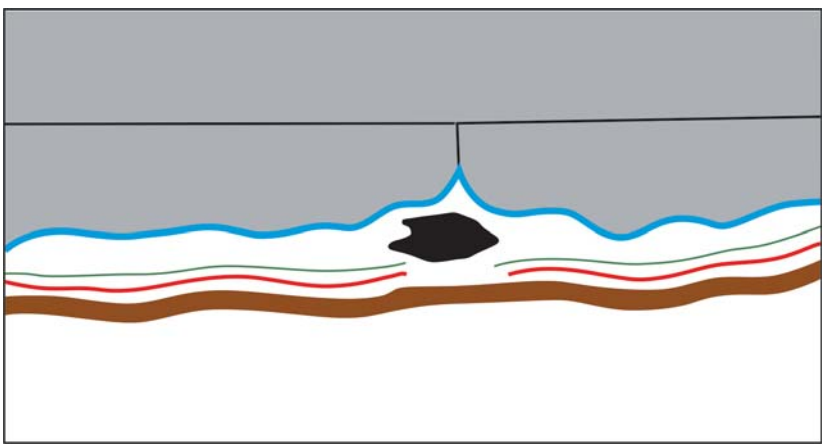

12. Vitreoretinal anteroposterior traction. Retinal profile deformed by traction. Impending hole.

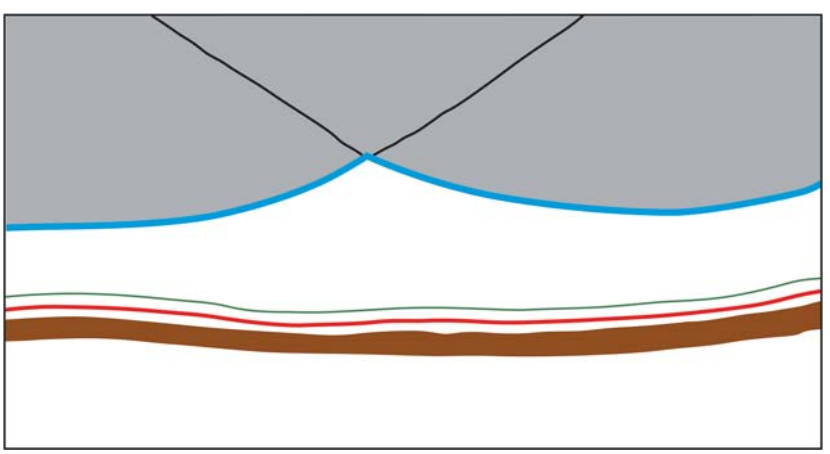

13. Retinal profile deformed by vitreoretinal traction.

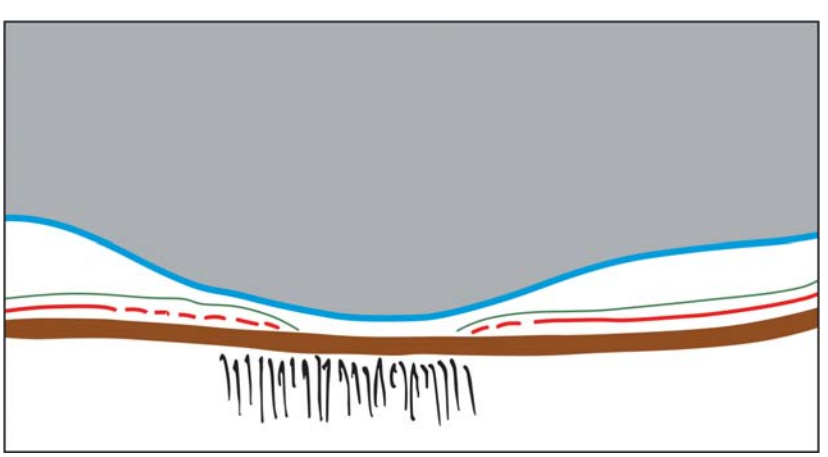

14. Widening and deepening foveal depression. Marked reduction of retinal thickness, alterations or disappearance of external limiting membrane and inner/outer photoreceptor segment junction. Deep penetration of light rays.

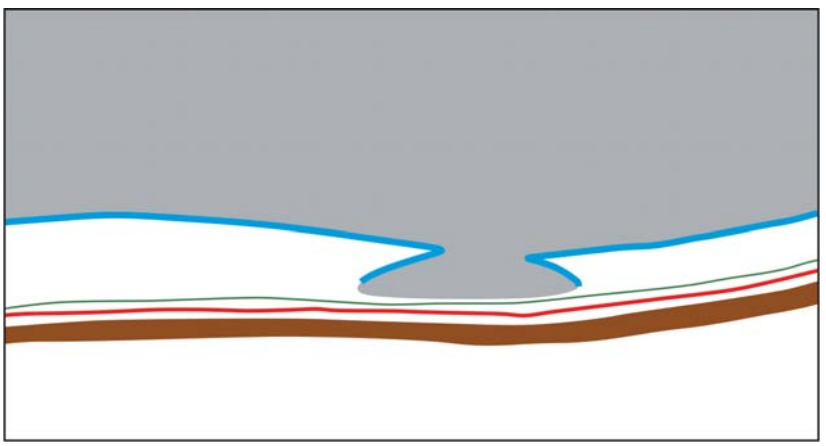

15. Lamellar hole, partial loss of retinal tissue; the posterior retinal layers, the internal limiting membrane and the inner/outer photoreceptor segment junction are intact.

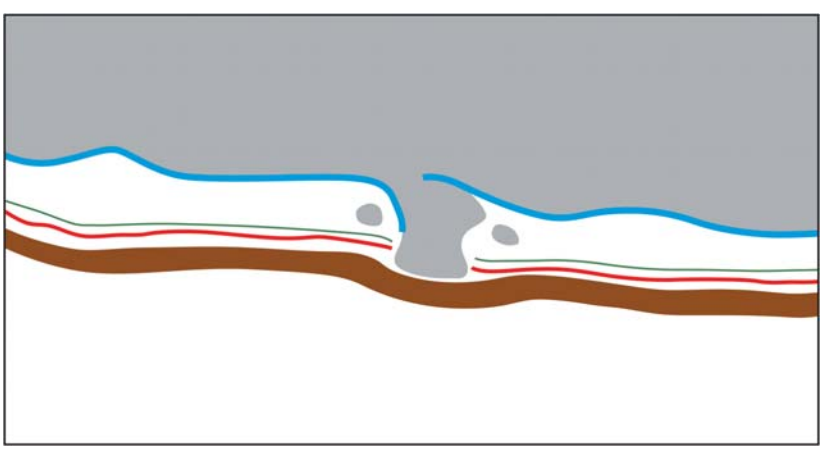

16. Hole with operculum, partial loss of central retinal tissue; the operculum is visible on the hole margin.

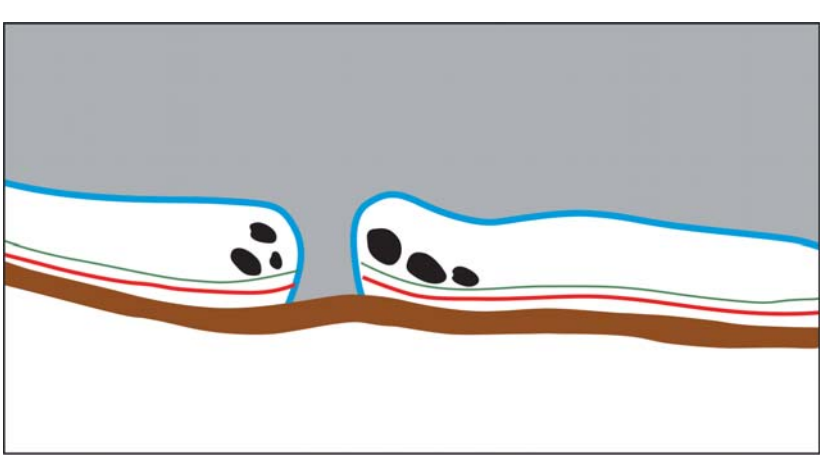

17. Full thickness retinal hole (stage IV), full thickness loss of central retinal tissue, and cystoid edema formation around the hole.

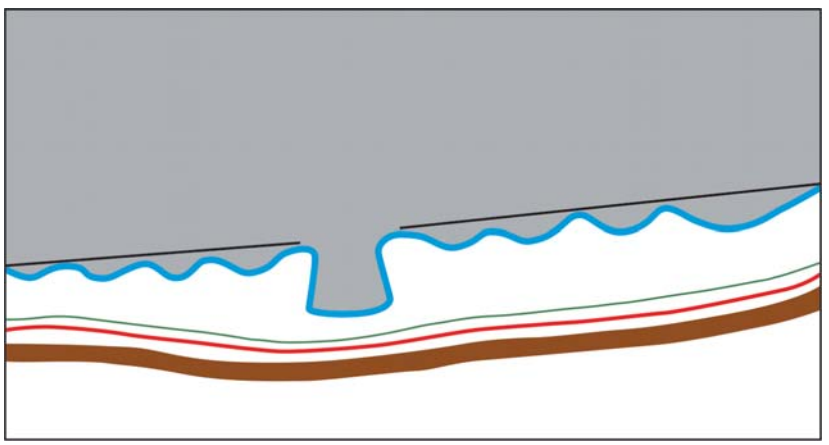

18. Retinal pseudohole. This is not a true retinal hole; there is no tissue loss; retinal tissues are preserved and deformed by tangential tractions exerted by an epiretinal membrane on the retina.

Outer Retina Outline

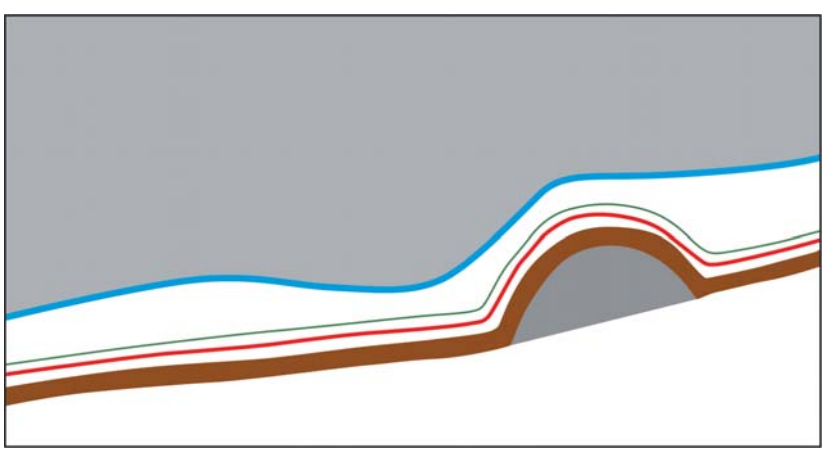

19. Retinal pigment epithelium detachment. The elevation forms an angle greater than 45 degrees with the Bruch's membrane. The external limiting membrane and the inner/outer photoreceptor segment junction are preserved.

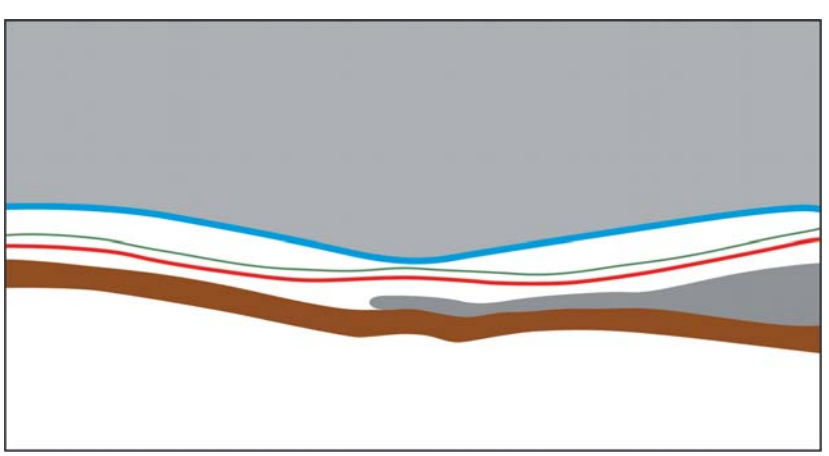

20. Serous detachment of neuroepithelium. The neuroepithelium elevation forms a lesser than 30-degree angle with the retinal pigment epithelium.

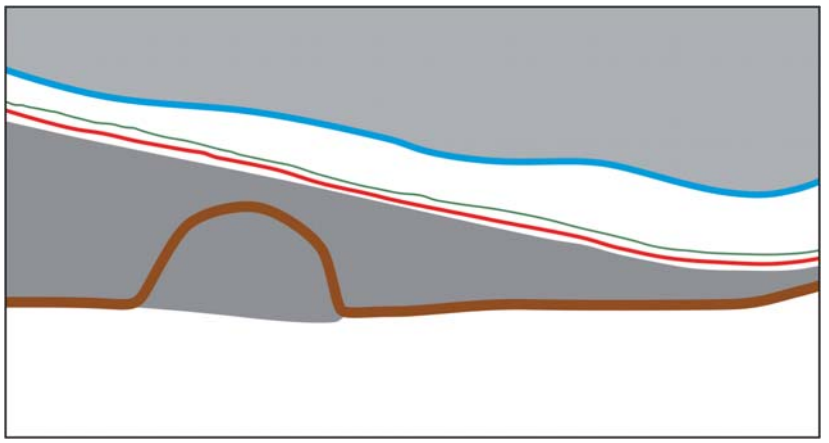

21. Serous detachment of neuroepithelium associated with retinal pigment epithelium detachment. Note how the retinal pigment epithelium elevation forms a greater than 45-degree angle with Bruch's membrane, whereas the neuroepithelium elevation forms a lesser than 30-degree angle with the retinal pigment epithelium.

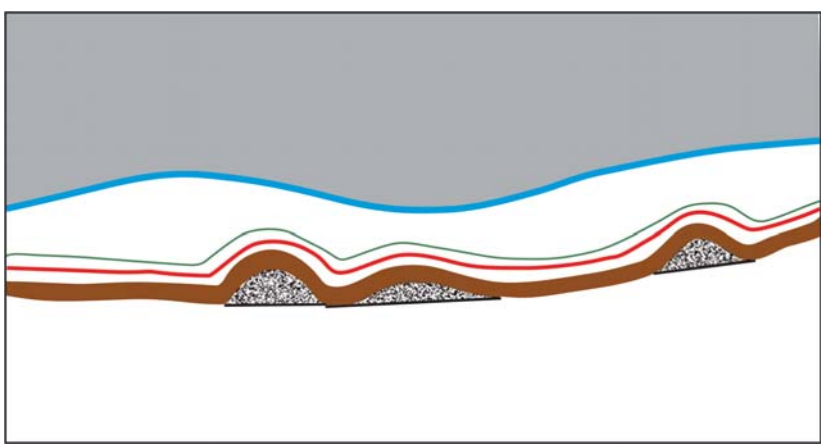

22. Retinal pigment epithelium drüsen: Three drüsen of the retinal pigment epithelium can be seen. Their contents are slightly hyperreflective. Bruch's membrane is also visible as a thin line; the external limiting membrane and the ellipsoid (inner/outer photoreceptor segment junction) are preserved.

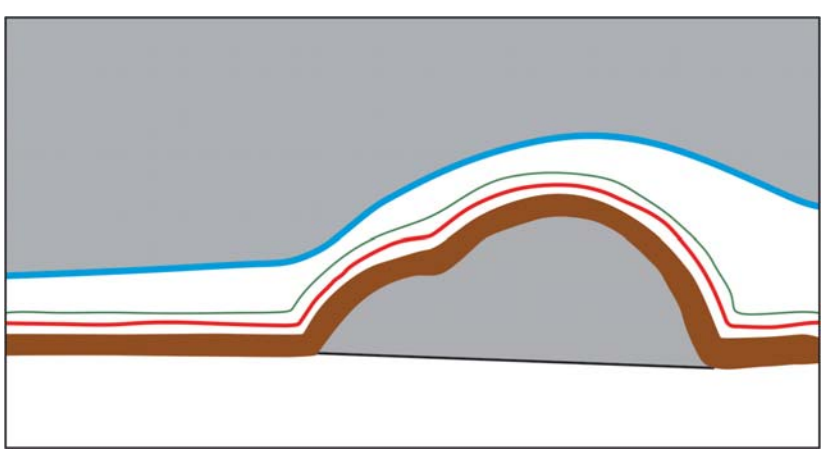

23. Drüsenoid detachment of retinal pigment epithelium. The irregular retinal pigment epithelium elevation lifts the retina as well, deforming its profile. The external limiting membrane and the ellipsoid (inner/outer photoreceptor segment junction) are preserved. The detachment contents are slightly hyperreflective; Bruch's membrane is visible as a thin line.

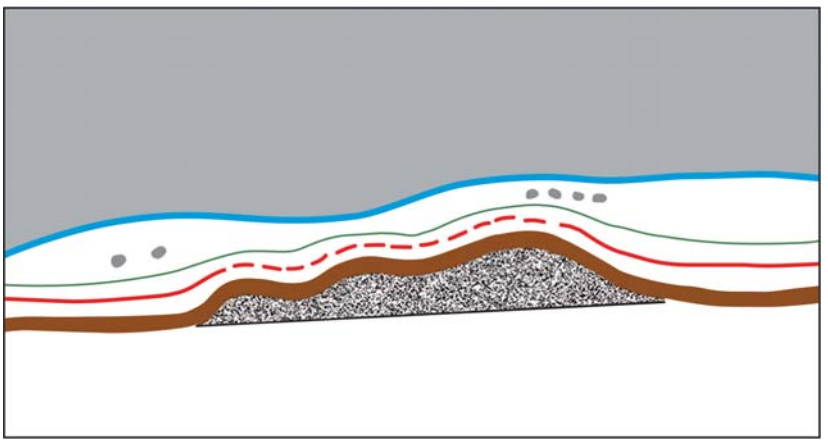

24. Retinal pigment epithelium elevation in macular degeneration with occult neovascularization. Slightly irregular retinal profile; irregular detachment of retinal pigment epithelium with non-homogeneous contents. Bruch's membrane is visible. The retinal pigment epithelium, the ellipsoid (inner/outer photoreceptor segment junction) and the external limiting membrane are altered. Rare cystoid edema cavities are present.

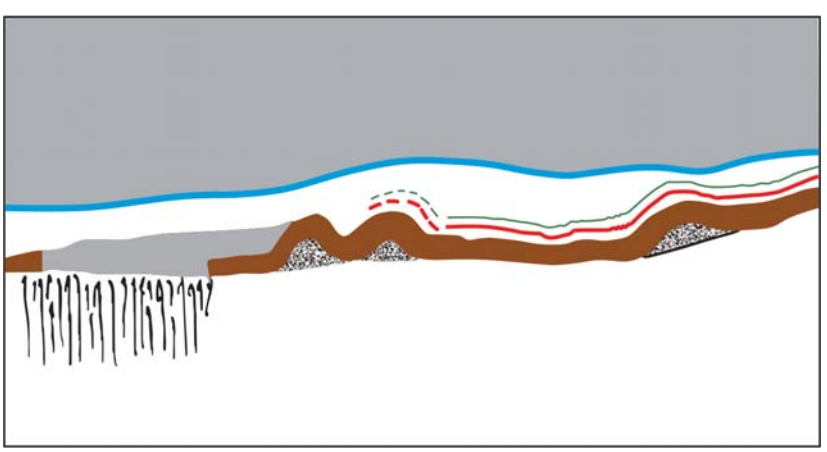

25. Retinal pigment epithelium tear: Short interruption of the retinal pigment epithelium, where, lacking a pigmented screen, the OCT shows a deep light penetration. Retraction of residual retinal pigment epithelium forming folds, localized serous neoepithelium elevation, alterations of the external limiting membrane and of the ellipsoid (inner/outer photoreceptor segment junction).

or detailed information on ophthalmology books, visit our website **www.jaypeebrothers.com,** for detailed information on ophthalmolog

Practical Retinal OCT

Practical Retinal OCT illustrates a logical and simple analysis and interpretation method of OCT imaging, clearly stating the steps required to reach a diagnosis.

OCT highlights retinal and choroidal alterations in morphology, structure and reflectivity and facilitates the study of the various retinal layers, both separately and globally.

The images presented in this manual were recorded mainly with Optovue OCT (RT Vue and XR Avanti OCT), and also with Heidelberg Spectralis. There are high resolution optical sections, in sagittal view with the choroid visible to the sclera or in frontal view, "en face", adapted the curvature of the fundus and other 3D images.

Illustrated with drawings, outlines, and sagittal and frontal (en face) OCT images, this concise manual intends to show how to read and interpret OCTs, documenting and diagnosing the most common retinal pathologies.

Simplified outlines are provided to facilitate the classification of morphological alterations. Several tables offer guidance through the most difficult diagnoses.

This manual is intended to make easier OCT interpretation to ophthalmologists, optometrists, ophthalmic technicians and orthoptists.

Bruno Lumbroso MD is the Director, Centro Oftalmologico Mediterraneo for Retinal Diseases, Rome, Italy. He has been the Head and Director, Department of Ophthalmology, Rome Eye Hospital and Professor, Libero Docente of Clinical Ophthalmology in the University of Rome La Sapienza for more than 35 years and General Secretary of the Italian Laser Society. He has written handbooks on Retinal Imaging in Fluorescein Angiography, Indocyanine Green Angiography, Microperimetry, Time Domain OCT, Spectral Domain OCT, and En Face OCT. His main interests are in logical methods of retinal imaging analysis and interpretation, and in clinical applications of OCT technology for retinal disorders.



Marco Rispoli MD is staff Ophthalmologist, Department of Ophthalmology, Ospedale Nuovo Regina Margherita, and Centro Oftalmologico Mediterraneo for Retinal Diseases, Rome, Italy. He is interested in developing ocular imaging. He has written handbooks on Retinal Imaging Interpretation of Time Domain OCT, Spectral Domain OCT and En Face OCT.



Available at all medical book stores
or buy directly from Jaypee Brothers through online shopping
at www.jaypeebrothers.com

JAYPEE BROTHERS
Medical Publishers (P) Ltd.
www.jaypeebrothers.com

Join us on facebook.com/jaypeebrothers

Shelving
Recommendation
OPHTHALMOLOGY

ISBN 978-93-5152-532-5