ur website www.jaypeebrothers.com, for detailed information on otolaryngology books, visit our website www.jaypeebrothers.com

JAYPEE

VOLUME 4

RECENT ADVANCES IN OTOLARYNGOLOGY HEAD & NECK SURGERY

ANIL K LALWANI • MARKUS HF PFISTER

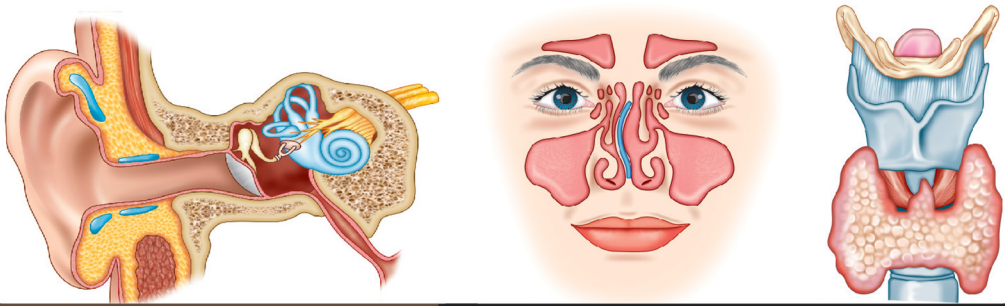

Contents

1. Face Transplantation **1**
Michael Sosin, Eduardo D Rodriguez
- Introduction and a Brief History *1*
- Defect Classification and Indications *6*
- Operative Planning and Guidance *9*
- Allograft Rejection *16*
- Outcomes of Face Transplantation *17*

2. Minimally Invasive Therapies for the Aging Face **21**
Jason A Moche, Yuna Larrabee
- Skin Photoaging *23*
- Clinical Findings *23*
- Histologic Findings *23*
- Chemical Skin Peels *24*
- General Principles of Skin Peeling *25*
- Histologic Changes Following Peeling *26*
- Superficial Peels *27*
- Medium-Depth Peels *27*
- Deep Chemical Peels *27*
- Chemical Peel Components *28*
- Side Effects and Complications *29*
- Laser Resurfacing *29*
- Ablative Nonfractionated Laser Resurfacing *30*
- Nonablative Laser Resurfacing *32*
- Platelet Rich Plasma (PRP) and Platelet Rich Fibrin Matrix (PRFM) *39*

3. Innovations in Airway Interventions in Craniofacial Surgery **47**
Scott M Rickert
- Common Craniofacial Conditions *48*
- Interventions of the Nasal Airway/Nasopharynx *54*
- Intervention of the Larynx *62*
- Intervention of the Tracheal Airway *63*

4. Microtia Repair **70**
Sivakumar Chinnadurai, Scott J Stephan, Roland D Eavey
- Costal Cartilage-Based Reconstruction *70*
- Recent Advances in Costal Cartilage Reconstruction *73*
- Alloplast Ear Reconstruction *76*
- Recent Advances in Alloplast Reconstruction *79*
- Future Directions *81*

5. Internal Nasal Valve Surgery **85**
Claus Walter, Marcus M Maassen
- Surgical Methods in the Management of the Inner Nasal Valve *85*
- Surgical Method of Our Combined Approach *88*

6. Contemporary Management of Bell's Palsy **98**
Maurizio Barbara, Edoardo Covelli, Carlo Iacolucci, Luigi Volpini, Simonetta Monini
- Clinical Presentation *99*
- Diagnosis *99*
- Management *102*
- Medical Treatment *103*
- Surgical Treatment *103*
- Physical Therapy *104*
- Proposal of a Combined Protocol (Flowchart) *106*

7. Advances Facial Nerve Testing In and Out of the Operating Room **110**
Gregory R Mannarelli, Paul R Kileny
- Anatomy *111*
- ENoG *119*
- EMG *124*
- Protocols *130*
- Future Directions *135*
- Future Research *135*

8. Surgical Rehabilitation of the Paralyzed Face **152**
Joseph C Clarke, Scott R Owen, Douglas K Henstrom
- Acute Nerve Injury *152*
- Chronic Paralysis *157*
- Upper Face *157*

- Midface *161*
- Lower Face *167*

9. Evidence in Favor of Cochlear Implantation for the Treatment of Single-Sided Deafness **173**
Jaclyn B Spitzer, George Korres, Anil K Lalwani
- Single-Sided Deafness *173*
- Advantage of Binaural Hearing *174*
- Cochlear Implantation in SSD *176*

10. Ossiculoplasty in Case of Missing Malleus: The Malleus Replacement Prosthesis **185**
Robert Vincent

11. Contemporary Management of Differentiated Thyroid Cancer **195**
Laura Y Wang, Ashok R Shaha
- Epidemiology *195*
- Evaluation *195*
- Thyroid Management *197*
- Nodal Management *199*
- Risk Stratification *200*
- Adjuvant Radioactive Iodine Therapy *201*
- Postoperative TSH Suppression *203*
- Targeted Therapies *204*

12. Robotic Surgery in Head and Neck Cancer **210**
Hamad Chaudhary, Tamer A Ghanem
- Principles *211*
- Indications and Treatment Goals *213*
- Rationale and Results *218*
- Robotic Approach to Skull Base and Nasopharynx *223*
- Robot-Assisted Thyroid Surgery (RATS) *224*
- Robot-Assisted Neck Dissection (RAND) *228*
- Limitations and Complication *229*

13. Objective Diagnostic Tools in Rhinology **234**
Gunter Mlynski, Giorgi Gogniashvili, Achim Georg Beule
- Objective Functional Diagnostic Methods *236*

- Diagnostic Procedure in Patients with Nasal Obstruction *247*
- Applications *248*

14. Allergic and Nonallergic Rhinitis—A Collaborative Approach **260**
Oliver Hausmann, Markus HF Pfister
- Nonallergic Rhinitis *261*
- Allergic Rhinitis *263*

15. Role of Topical Sinonasal Irrigation in Sinus Disease **269**
Jivianne T Lee, Alexander G Chiu
- Topical Saline Irrigations *269*
- Topical Steroid Irrigations *271*
- Topical Antibiotic Irrigations *271*
- Topical Antifungal Irrigations *278*
- Topical Additive Irrigations *283*

16. Treatment of Sinonasal Inverted Papilloma **296**
Fabio Pagella, Alessandro Pusateri, Elina Matti
- Tumor Staging *299*
- Imaging *301*
- Surgical Treatment of Sinonasal Inverted Papilloma *303*

17. Chronic Cough: What's New? **322**
Chandra M Ivey
- Anatomy and Neurophysiology *323*
- Common Identifiable Causes for Chronic Cough *327*
- Treatment of Identifiable Causes of Cough *329*
- Concept of Neuropathic Cough *331*
- Treatment of Neuropathic Cough *332*
- Proposed Mechanisms for Future Treatment *334*

18. Advances in Sepsis **339**
James A Russell, Adam Linder, David Sweet, John Boyd, Keith R Walley
- Pathophysiology and Molecular Biology of Sepsis *339*
- Other Sepsis Permeability Candidates *345*
- Identification of the Septic Patient *345*
- Overview of Management: ABCDEF *348*
- Airway and Breathing *349*
- Circulation: Fluids *350*

- Vasopressors and Inotropic Agents *355*
- Drugs: Vasopressin *357*
- Drugs: Early Antimicrobials *361*
- Drugs: Activated Protein C *362*
- Drugs: Corticosteroids *363*
- Other Therapies *364*
- Evaluate and Fix the Source of Sepsis *364*
- Prognosis *365*
- Future Directions *366*

Index *383*

Chapter

3

Innovations in Airway Interventions in Craniofacial Surgery

Scott M Rickert

JAYPEE BROTHERS

INTRODUCTION

Craniofacial patients present with many therapeutic challenges—both cosmetic and functional. Their care requires a team approach of surgeons, medical doctors, dentists, speech language pathologists, nurses, and social workers. While cosmetic issues are exceedingly important in helping correct their facial differences, the functional deficits are more insidious and more difficult to treat. Functional defects include but are not limited to visual, auditory, mastication, swallowing, speech, and breathing challenges and greatly depend on the variability of the patient's craniofacial condition.

Airway issues are among the most critical functional issues that arise in craniofacial patients. They can arise from the entire airway tract, anterior nasal cavity through to the tracheal/bronchial tree. The vast majority of issues arise from the nasopharyngeal, oropharyngeal, and hypopharyngeal part of the airway.

Each craniofacial patient must be assessed individually in a comprehensive team approach to ensure that no aspect of their craniofacial care is lacking. The airway of the craniofacial patient in particular should be thoroughly evaluated on the first encounter by an expert airway team to ensure that there is no concerning issue left unaddressed. Typically this team includes craniofacial surgery, otolaryngology, pulmonology, and speech and swallowing experts. A comprehensive history and physical examination in conjunction with an endoscopic evaluation of the upper airway is typically performed on the first visit. If there is any further concern, a sleep evaluation with an overnight sleep study may be performed to evaluate breathing issues during sleep. If the concern is more immediate and/or an office evaluation

is not enough, a direct microlaryngoscopy and bronchoscopy under anesthesia may be performed to evaluate the entire airway from nose to trachea and bronchi.

COMMON CRANIOFACIAL CONDITIONS

There are many individual craniofacial conditions that have been described in the literature and much variability within each of these craniofacial conditions. Given this wide variety of presenting symptoms, the most common conditions are described below with their typical airway concerns.

Pierre Robin Sequence

Pierre Robin sequence (Fig. 3.1) is a sequence of three distinct issues that all affect the airway of the patient. It is a relatively common craniofacial condition and has an incidence of 1:10000. The sequence begins with micrognathia. This micrognathia does not allow the tongue to properly seat in the floor of mouth effectively and causes glossoptosis. With the consequential glossoptosis, a U-shaped cleft palate is formed. It is also known as "bird facies" for the confluence of facial features. Major airway issues arise from the glossoptosis obstructing the posterior oropharynx. This can result in airway issues at birth or shortly thereafter and may even necessitate a tracheotomy if the airway is inadequately ventilated. Anesthetic interventions can also



Fig. 3.1: Pierre Robin sequence baby.

JAYPEE BROTHERS

be difficult as the combination of the micrognathia and glossoptosis may make for a difficult airway exposure and intubation. Pierre Robin sequence is associated with Stickler syndrome (collagen deficiency), velocardiofacial syndrome, and Treacher Collins syndrome.

Craniosynostosis

Craniosynostosis is an abnormal development of the cranial skeleton due to premature fusion of one or more cranial sutures, resulting in malformation of the skull. The shape of skull depends on sutures involved (Fig. 3.2). It can cause elevated intracranial pressure and developmental delay. Craniosynostosis on its own does not typically affect the airway. However, it can be associated with other craniofacial syndromes that do have significant airway issues at baseline. Craniosynostosis is an important aspect of the craniofacial patient's treatment and is frequently the presenting chief complaint from the family. Further investigation is essential in craniosynostosis patients to ensure that they do not have any airway concerns at baseline.

Syndromes associated with craniosynostosis are typically autosomal dominant inheritance, although there is variable penetrance of the severity of the symptoms. The most common syndromes associated with craniosynostosis include Crouzon, Pfeiffer, and Apert with an incidence of 1:10,000–100,000.

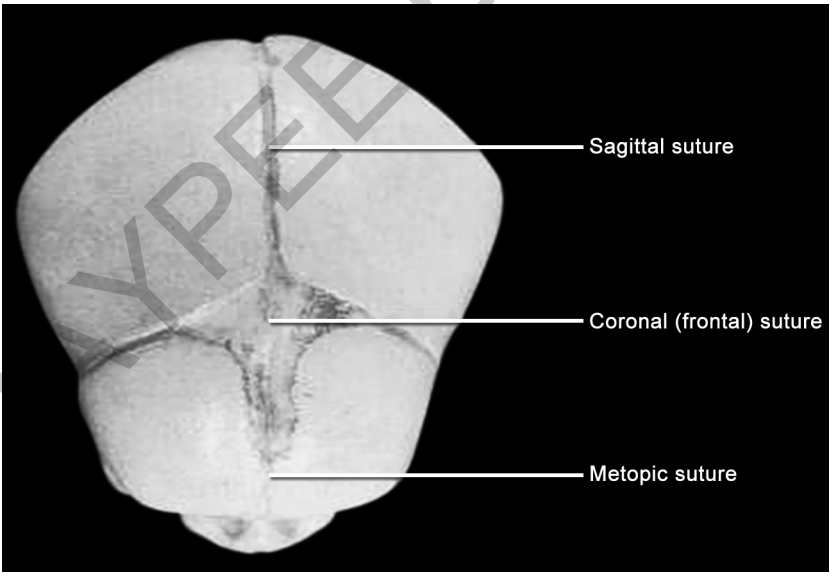

Fig. 3.2: Cranial suture lines diagram. When suture line prematurely close, it leads to craniosynostosis and further craniofacial syndromes.

JAYPEE BROTHERS



Fig. 3.3: Family with Crouzon's syndrome with underdeveloped mandible, maxillary retrusion, and shallow orbits.

Crouzon's Syndrome/Apert's Syndrome

Crouzon's syndrome, (Fig. 3.3) also known as "craniofacial dysostosis" has an incidence of 1:60000 and has normal intelligence. There is a confluence of craniosynostosis with shallow orbits and high forehead. Particular to the airway, there is an underdeveloped mandible and maxillary retrusion with a beaked nose. This narrows both the nasopharyngeal and oropharyngeal airway.

Apert's syndrome has very similar facial anatomy to Crouzon's syndrome. Airway concerns include an underdeveloped mandible and maxillary retrusion. This narrows both the nasopharyngeal and oropharyngeal airway. In addition, Apert's patients also have syndactyly of the hands and feet (Figs. 3.4A and B) and require significant functional orthopedic surgery in conjunction with their craniofacial surgery.

Pfeiffer's Syndrome

Pfeiffer's syndrome patients have slightly differing facial characteristics than Crouzon's and Apert's syndrome patients. They note to have craniosynostosis, a high protruding forehead, and shallow orbits with wide set eyes (Figs. 3.5A and B). They also have an underdeveloped mandible, frequently associated with maxillary retrusion. This affects

JAYPEE BROTHERS



Figs. 3.4A and B: Apert's syndrome baby with underdeveloped mandible, maxillary retrusion, and syndactyly of the hands.



Figs. 3.5A and B: Pfeiffer's syndrome child with high forehead, maxillary retrusion, and underdeveloped mandible.

their nasopharyngeal and oropharyngeal airways. They also note to have short and webbed fingers but no true syndactyly like Apert's syndrome patients.

JAYPEE BROTHERS



Fig. 3.6: Treacher Collins patient postmandibular distraction.

Treacher Collins Syndrome

Treacher Collins syndrome (Fig. 3.6) is an autosomal dominant syndrome with general bilateral findings. There is typically eyelid deficiency, cleft lip and/or palate, and microtia and/or atresia. Treacher Collins syndrome patients have a general zygomatic underdevelopment affecting their facial structure (Fig. 3.7). Most importantly from an airway perspective is their significant micrognathia. This is typically in combination with choanal atresia and can drastically affect the patient's nasal, nasopharyngeal, and oropharyngeal airway and particularly challenging to treat. If there is significant airway anomalies noted at birth, many Treacher Collins syndrome patients have a tracheotomy placed for airway safety with planned airway interventions as they grow.

Craniofacial Microsomia

Craniofacial microsomia (Figs. 3.8A and B) is a unilateral or bilateral condition that has an incidence of 1:2500. It is generally a new mutation and not genetically inherited and can range from very mild to very severe. Its etiology is unknown but recent theories are that there is an incidental intrauterine hemorrhage that adversely affects the growth of the child. Depending on the extent of the condition,

JAYPEE BROTHERS



Fig. 3.7: Treacher Collins syndrome baby with tracheotomy in plac.



Figs. 3.8A and B: Child with craniofacial unilateral microsomia; child with bilateral (R>L) craniofacial microsomia with ocular dermoid of the left eye (Goldenhar's syndrome).

JAYPEE BROTHERS

it can affect the eye (Goldenhar's syndrome with ocular dermoids), the ear (microtia and/or atresia), and the jaw (unilateral or bilateral mandibular underdevelopment). Airway can be or cannot be affected depending on how adversely affected the jaw is in utero.

The conditions mentioned above are the most common craniofacial conditions that have airway concerns and give a good representation of the airway concerns affecting the craniofacial population. However,

this is by no means a comprehensive list as there are many other craniofacial conditions that are more rare and have significant airway concerns. The airway of all craniofacial patients should be thoroughly evaluated on the first encounter to ensure that there is no concerning issue unaddressed.

Interventions of the airway in the craniofacial population depend on the nature of the deficit. As most of the airway anomalies are in the nasopharynx, oropharynx, or hypopharynx, the majority of the interventions are performed there. However, there are potential craniofacial airway issues all along the unified airway—from nasal cavity to trachea/bronchi.

Given the variety of potential craniofacial airway anomalies and variable penetrance of these anomalies, interventions will be described by anatomic area of the stenosis/narrowing rather than craniofacial condition itself.

INTERVENTIONS OF THE NASAL AIRWAY/NASOPHARYNX

Interventions of the nasal airway and nasopharynx are performed in particular for anterior pyriform stenosis, nasal stenosis, (Fig. 3.9A) choanal atresia, (Fig. 3.9B) and midface/maxillary retrusion. Anterior pyriform stenosis, a narrowing of the anterior nasal cavity at the level of the pyriform, is typically characterized by a midline incisor tooth (mega incisor) (Fig. 3.9C) and nasal respiratory distress. Mild anterior pyriform stenosis is almost always observed with the hope of time improving the airway as many can slowly outgrow the stenotic area with time. More significant nasal stenosis may need intervention earlier, given the need of a nasal airway in neonatal development. Repair can be performed transnasally/endoscopically, transpalatally, or more commonly sublabially (Fig. 3.9D). A drill is used to open the bony narrowing in the lateral nasal wall. Stents may be placed if there is concern for restenosis.

Nasal stenosis is particularly difficult to repair as it can involve a great deal of the nasal cavity and cause significant respiratory distress.[1] Mild nasal stenosis is almost always observed with the hope of time improving the airway. More significant nasal stenosis may need intervention earlier, given the need of a nasal airway in neonatal development. Given the complexity of the lateral nasal wall and the typical significant length of the nasal stenosis, a tracheotomy is needed initially if there is significant stenosis prior to any attempt at repair. Repair can be done transnasally, endoscopically, or transpalatally. Typical significant nasal stenosis is given time to grow as many patients do improve with time as the nasal airway improves in cross-sectional area.

JAYPEE BROTHERS

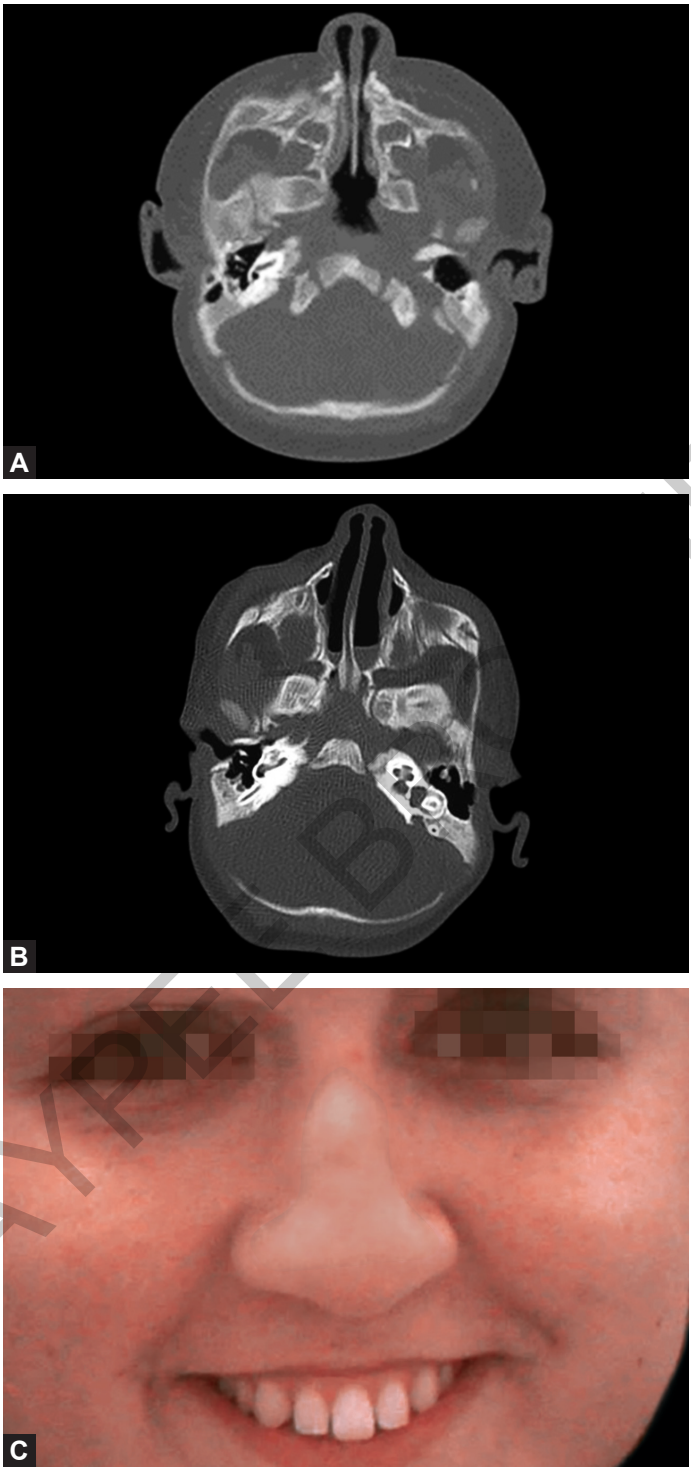

Figs. 3.9A to C

JAYPEE BROTHERS

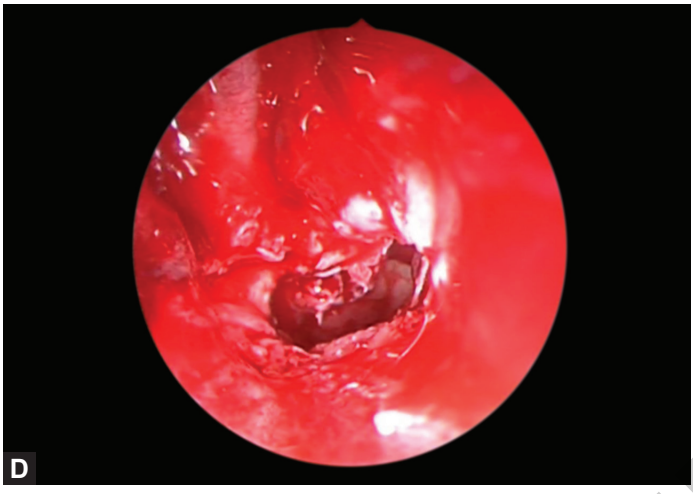

Figs. 3.9A to D: Midnasal stenosis on CT scan; bilateral choanal atresia on CT scan; midline mega incisor in anterior pyriform stenosis; choanal atresia now patent, post-repair.

Choanal atresia occurs in 1 in 5000 births[2] and may cause severe respiratory distress if it is bilateral. Choanal atresia is commonly associated with other congenital malformations such as Treacher Collins syndrome and CHARGE (coloboma, hearing deficit, choanal atresia, retardation of growth, genital defects, and endocardial cushion defect) association. Symptoms may range from chronic nasal congestion and rhinorrhea to significant respiratory distress. A tentative diagnosis is made after failure to pass a 6-Fr suction catheter at least 3.5 cm into the nose. High-resolution computed tomography (CT) in the axial plane[3] confirms the diagnosis and helps to determine the surgical approach for repair. There are a variety of surgical approaches, including transnasal, transpalatal, sublabial transseptal, and endoscopic procedures.[4] Newer innovations include endoscopic approach with CT navigation to ensure integrity of the skull base upon repair. While bilateral choanal atresia may require a tracheotomy at first before surgical intervention, unilateral choanal atresia may be relatively asymptomatic and repaired at later date when deemed beneficial. Stenting remains a controversial benefit post-surgery and may help prevent restenosis.

Midface Hypoplasia and Retrusion (RED Device)

In a number of craniofacial conditions, the midface does not develop in a child at the expected rate leading to midface hypoplasia and retrusion. The most common concern is respiratory issues secondary to the midface retrusion, nasopharyngeal stenosis, and sleep apnea. Other concerns that occur concomitantly are poor eye protection with corneal

JAYPEE BROTHERS

exposure, dysphagia due to altered anatomy at the back of the nose and throat, and poor bite (class III malocclusion). There is a general concavity in appearance on lateral view secondary to the midface hypoplasia. Midface distraction osteogenesis is a technique that is used to slowly move the midface forward, bringing the midface in its proper anatomic alignment. Three-dimensional (3D) CT craniofacial planning[5] models are typically used to provide the surgeons with the best possible planned advancement and potential areas for bone cuts. The midface is carefully separated from the rest of the skull and pins are placed using an external device (RED device) (Figs. 3.10A and B). Use approximately 0.5–1 mm turns of the apparatus were performed daily to slowly move the midface while providing time for osteogenesis to occur. Studies have shown that bone deposition does occur and fill in the gaps made by the distraction device.[6] Long-term cephalometric and clinical data show stable results concerning the skeletal and dental relations.[7]

Interventions of the Oropharynx/Hypopharynx (Macroglossia, Glossoptosis, Retrognathia, Micrognathia)

Mandibular Distraction Osteogenesis

In a number of craniofacial conditions, the mandible does not develop in a child at the expected rate leading to retrognathia or micrognathia. The most common concern is respiratory issues with oropharyngeal obstruction, glossoptosis, and sleep apnea. Other concerns that occur concomitantly are dysphagia due to altered anatomy at the back of the nose and throat, and poor bite (class II malocclusion). There is a general lack of chin point in appearance on lateral view secondary to the mandibular hypoplasia. Mandibular distraction osteogenesis is a technique that is used to slowly move the mandible forward, bringing the mandible in its proper anatomic alignment (Fig. 3.11A to D). Three-dimensional CT craniofacial planning models are essential[5] and used to provide the surgeons with the best possible planned advancement and potential areas for bone cuts along the mandible as the movement is a 3D vector to provide excellent jaw alignment along with an improved oropharyngeal airway. There can be one device if only one side is affected (craniofacial microsomia) or two devices if it is bilateral (Crouzon's and Treacher Collins syndrome).[8] Once in place, the device moves 0.5–1 mm turns of the apparatus daily to slowly move the mandible forward while providing time for osteogenesis to occur. There is general agreement in the long-term success of mandibular

JAYPEE BROTHERS

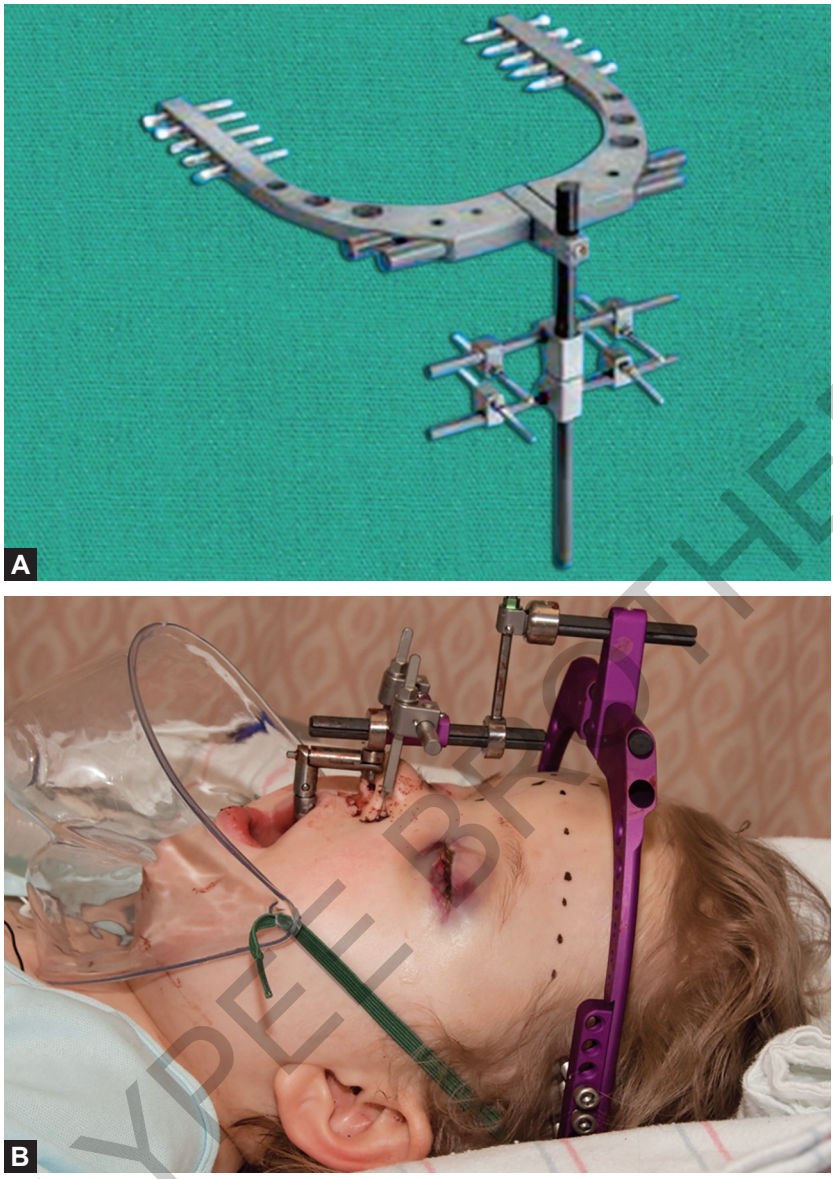

Figs. 3.10A and B: RED device; RED device installed on Crouzon's syndrome patient.

JAYPEE BROTHERS

distraction osteogenesis, and long-term cephalometric and clinical data show stable results concerning the skeletal and dental relations after distraction.

Tongue Reduction Surgery

Macroglossia (Fig. 3.12) can present in many syndromic patients, including Beckwith-Wiedemann and Down's syndrome. Typical

symptoms include drooling, dry/cracked tongue, and sleep disordered breathing or frank sleep apnea. A sleep study can be helpful to determine the level of sleep disturbance. In general, tongue reduction is done for both cosmetic reasons and functional ones. There are many differing techniques for tongue reduction surgery and the choice depends greatly on the anatomy presented. A tongue that is more protruding and out of the mouth may be more amenable to a more anterior

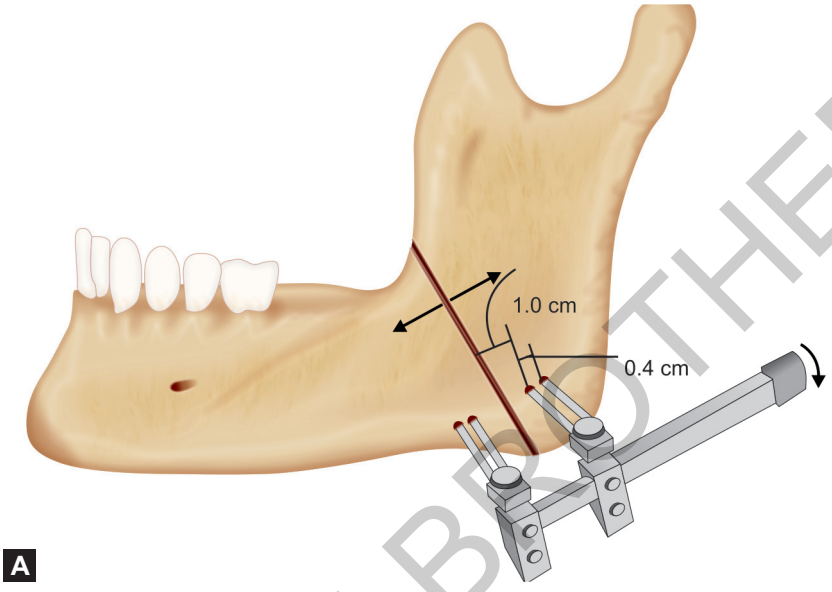

A



B

Figs. 3.11A and B

JAYPEE BROTHERS



Figs. 3.11A to D: Mandibular distractor diagram and on a doll; mandibular distractor unilaterally on craniofacial microsomia patient two views (C and D).



Fig. 3.12: Patient with macroglossia.

reduction, while a glossoptotic tongue with significant posterior base of tongue fullness may be more amenable to a posterior reduction. Generally, the reduction is performed in the central aspect of the tongue to decrease the volume of tongue while not sacrificing its function.[9]

JAYPEE BROTHERS

In determining the longer-term effects of tongue reduction surgery, one study noted that surgical reduction of the tongue had a minor influence on the subject's performance in the test of oral ability. The overall oral motor ability and the positions of the head, the cervical column, and the hyoid bone were unaffected. While the functional motion of the tongue was unaffected, the volume of the tongue was noted to significantly increase the amount of free space as expected.[10]

Tongue Suspension Surgery

Tongue suspension surgery (Figs. 3.13A and B) is used for glossoptosis, whether primary or secondary to a retrognathic mandible. It can

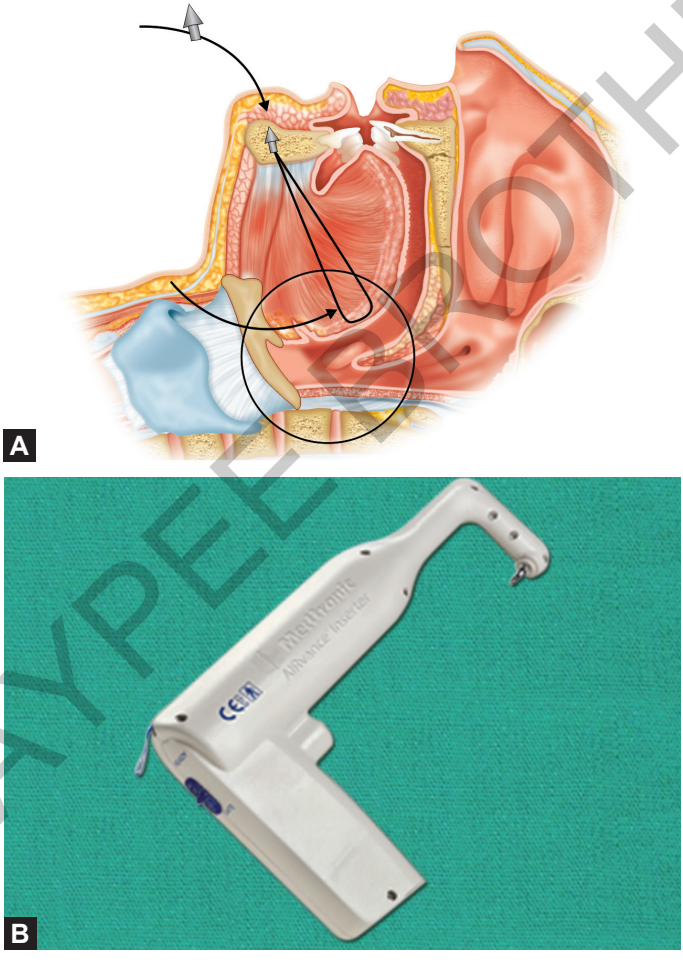

Figs. 3.13A and B: Tongue suspension suture and screw delivery device. Arrows noted insertion points of the tongue suspension suture at the inner cortex of mandible and around the base tongue musculature. (courtesy of Repose system).

JAYPEE BROTHERS

be used as a potential replacement for airway improvement over a mandibular distraction and much more easily tolerated than distraction. It is a relatively new technique that helps to suspend the base of tongue forward with the help of a long-lasting suture. This technique anchors the suture at the inner aspect of the mandible and loops through the base of tongue to secure the suspension. The success of the tongue suspension surgery greatly depends on the placement of the tongue suture and the relative pull it has to the central mandible. An endoscopic view from the nasopharynx is a useful adjunct to placement of the suture as it can measure the amount of posterior oropharyngeal airway improvement. Overall, it is a relatively mild-to-moderate improvement in airway compared to a more definitive mandibular surgical intervention.

Hyoid Suspension Surgery

In a similar fashion to the tongue suspension surgery, hyoid suspension surgery uses the hyoid as its point of suspension. In obstructive sleep apnea at the level of the oropharynx/hypopharynx, the hyoid arch and its *muscle attachments* strongly affect oropharyngeal and hypopharyngeal airway patency. By bringing the hyoid forward, the soft tissues attached to the hyoid are also brought forward to better open the posterior oropharyngeal airway. The data is mixed on the results as one study noted 75% of patients[11] with hyoid suspension surgery note significant improvement in sleep subjectively, and in another only 17% patients achieved objective improvements.[12] A secondary study notes better objective results attaching the suspension of the hyoid to the anteroinferior thyroid lamina than the inferior mandible. Hyoid suspension appears to work best in combination with a multilevel surgical approach to sleep apnea.[13]

INTERVENTION OF THE LARYNX

Laryngomalacia (Fig. 3.14) is the most common cause of stridor in neonate and can frequently cause inspiratory stridor in craniofacial patients. It is a congenital flaccid larynx with an omega-shaped epiglottis, shortened ariepiglottic (AE) folds, and prolapsing arytenoid complexes. Typically it is worse when supine, better prone. It is also worse with agitation and may present with feeding problems, gastroesophageal reflux, and most importantly respiratory issues. These can present as suprasternal retraction, subcostal or intercostal retractions. Supraglottoplasty is an alteration of these supraglottic tissues to provide greater airway and relief any collapse of the airway.

JAYPEE BROTHERS

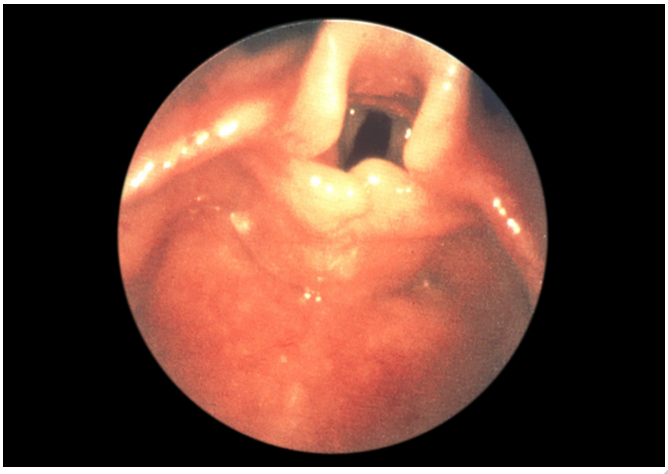

Fig. 3.14: Laryngomalacia noting shortened AE folds, arytenoid prolapse.

This can be cutting the AE folds, removing excess arytenoid tissue/bulk, and suspending the epiglottis or any combination of the above. There is usually an immediate improvement in the airway after supraglottoplasty if the appropriate areas are addressed.

INTERVENTION OF THE TRACHEAL AIRWAY

Tracheotomy provides a definitive safe airway below any oropharyngeal/hypopharyngeal obstruction. It provides an essential airway in an emergency situation and is frequently placed when there are any potential concerns for the future. It can be placed early to allow patients to grow until definitive surgery can be performed or it can be placed around the time of definitive surgery to provide a safe airway during the time of recovery.

Subglottic Stenosis Incision and Balloon Dilatation

Subglottic stenosis may be congenital or acquired through surgical intervention and subsequent narrowing of the subglottic airway (Fig. 3.15A). Multiple surgical approaches can be used to address subglottic stenosis. Newer innovations in endoscopic airway surgery have allowed for less invasive open procedure with good success. Endoscopic incision and balloon dilation of subglottic stenosis allow for controlled dilation of the airway with volume and pressure controlled balloons (Figs. 3.15B to D). These balloons are sized appropriately for the airway and allow excellent pressure within the airway without applying excessive pressure to the tracheal sidewalls, preventing excessive mucosal or tracheal damage. Typically the balloon is sized

JAYPEE BROTHERS

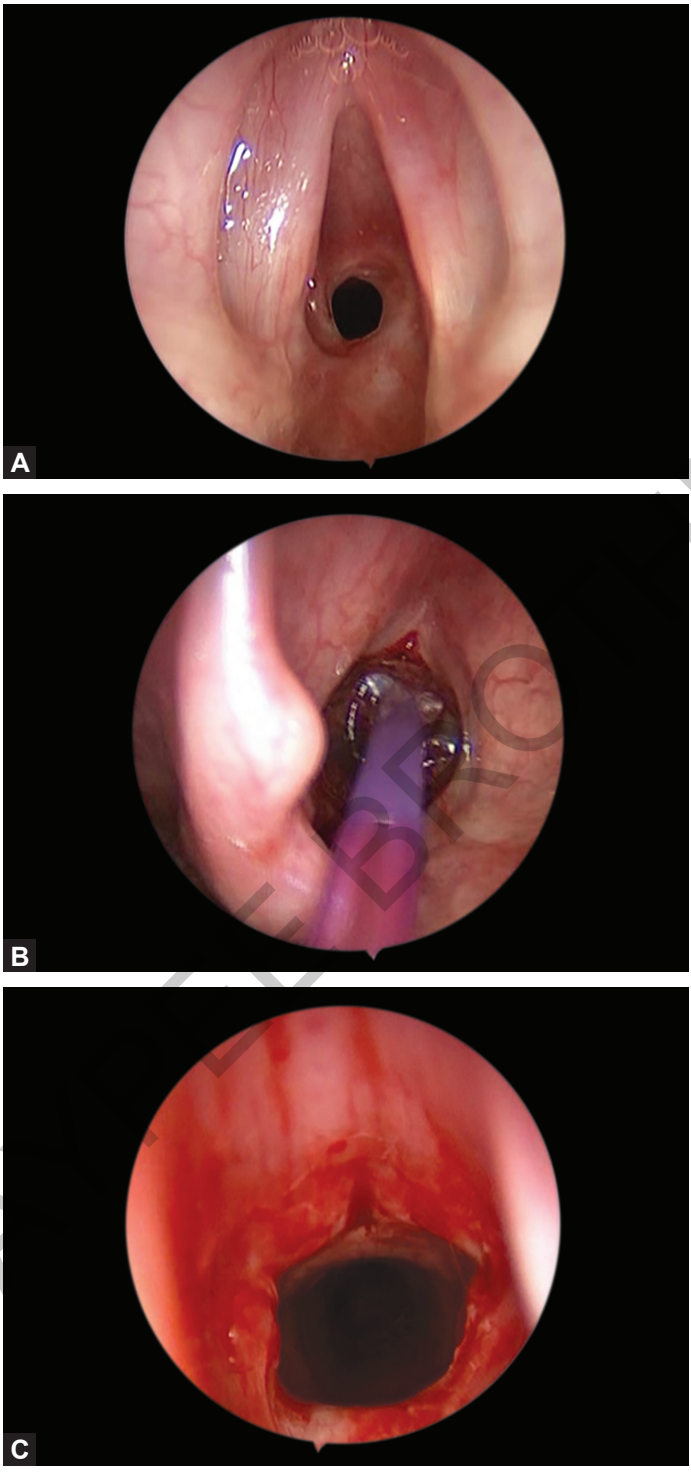

Figs. 3.15A to C



Figs. 3.15A to D: Subglottic stenosis, grade III; incision and balloon dilation of subglottic stenosis; postincision and balloon dilation two views (C and D).

to be approximate 1–2 mm larger than the desired airway to be able to apply the appropriate amount of circumferential pressure on the subglottic stenosis during dilation. They are held inflated for approximately 30 seconds if tolerated prior to deflation and removal from the airway.

Laryngotracheal Reconstruction

The mainstay definitive operation for subglottic stenosis remains laryngotracheal reconstruction or laryngotracheoplasty. It is an expansion of the cricoid cartilage and surrounding tissues to relieve subglottic stenosis (Figs. 3.16A and B). It can involve either anterior and/or posterior splitting of the cricoid cartilage with rib grafting to provide the expansion of the stenotic airway and secured with long-lasting sutures. A temporary stent is placed at the same time to ensure that the graft heals in place and sufficiently. Laryngotracheal reconstruction is either done in a single stage (where no tracheotomy remains after the surgery) or as a double stage (where the tracheotomy is left after surgery and removed at a later date).[14] It has a great deal of historical success as approximately 80% of patients who are tracheotomy dependent are able to be decannulated after laryngotracheoplasty is performed.[15]

Slide Tracheoplasty

When there is a longer segment of tracheal stenosis or complete tracheal rings, laryngotracheoplasty continues to be an option for

JAYPEE BROTHERS

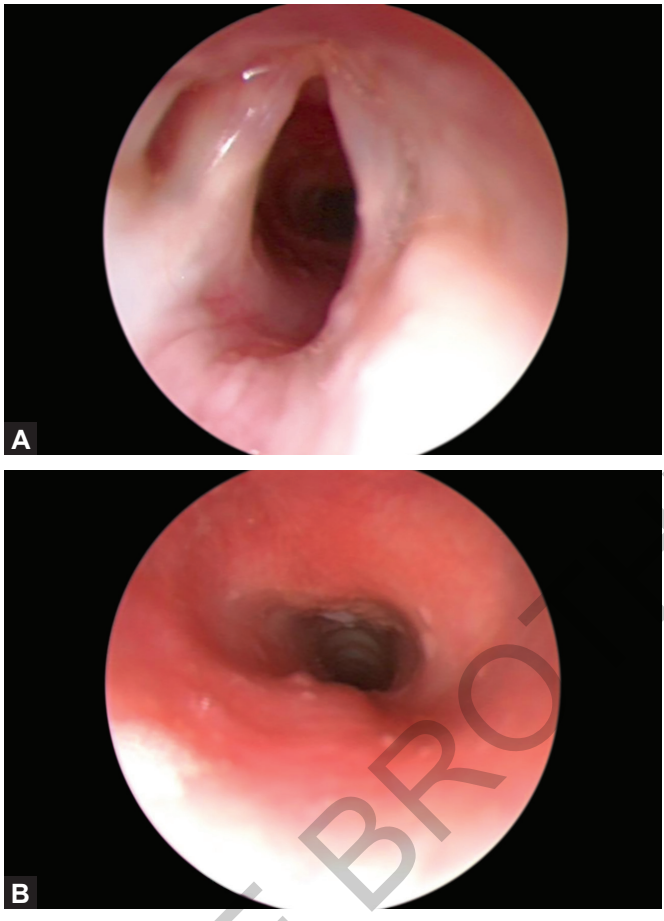

Figs. 3.16A and B: Subglottic stenosis status post-repair with laryngotracheoplasty (two views—A and B).

JAYPEE BROTHERS

treatment. However, slide tracheoplasty, a relatively new innovative procedure, may be more appropriate for certain cases (Fig. 3.17A). Tracheoplasty is performed by dividing the stenosis at midpoint, incising the proximal and distal narrowed segments vertically on opposite anterior and posterior surfaces, and sliding these together. The stenotic segment is shortened by half, the circumference doubled, and the cross-section area is quadrupled.[16,17] One can approach this through a cervical approach or with partial sternotomy. There is an attempt to leave as much viable trachea as possible, but a small amount of unusable trachea may be resected to provide for a better cross-sectional area of the trachea. It is closed with a single running suture and can be prone to a figure eight deformity upon the closure (Fig. 3.17B). Future growth of the tracheoplasty compared to nonslide

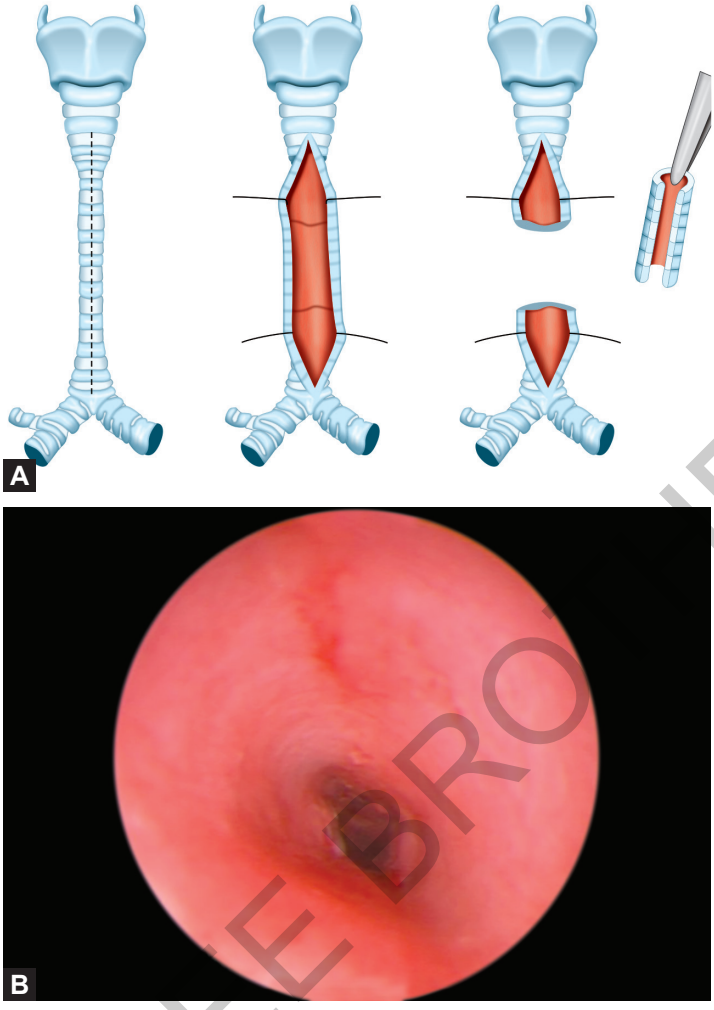

Figs. 3.17A and B: Illustration of slide tracheoplasty procedure; Slide tracheoplasty status post-repair with mild figure eight deformity secondary to suture line.

trachea was noted to be normal, as it does not compromise tracheal vascular supply and does not impair tracheal growth.[18]

CONCLUSIONS

Craniofacial patients present with multiple levels of airway obstruction and can be variable in their presentation due to the differing syndromes and variable penetrance within the individual craniofacial syndromes. Each craniofacial patient must be assessed individually in a comprehensive team approach to ensure that no aspect of their craniofacial care is lacking. The airway of the craniofacial patient

JAYPEE BROTHERS

in particular should be thoroughly evaluated on the first encounter by an expert airway team to ensure that there is no concerning issue left unaddressed. The majority presents with nasopharyngeal, oropharyngeal, or hypopharyngeal airway obstruction. Occasionally nasal and/or tracheal airway issues arise as well. A tracheotomy can be placed to ensure a safe patent airway if necessary.

There are multiple options to improve the airway at each level and the treatment should be based on the anatomic obstruction seen on exam. Close follow-up is essential as airway anatomy can change with growth or with postsurgical changes.

REFERENCES

1. Keller JL, Kacker A. Choanal atresia, CHARGE Association, and congenital nasal stenosis. Otolaryngol Clin North Am. 2000;33(6):1343-51.
2. Stankiewicz JA. The endoscopic repair of choanal atresia. Otolaryngol Head Neck Surg. 1990;103:931-7.
3. Kearns DB, Wickstead M, Choa DI, et al. Computed tomography in choanal atresia. J Laryngol Otol. 1988;102:414- 8.
4. Josephson GD, Vickery CL, Giles WC, et al. Transnasal endoscopic repair of congenital choanal atresia. JAMA Otolaryngol Head Neck Surg. 1998;124(5): 537-40.
5. Jaime G, Teichgraeber JF, Xia JJ. Three-dimensional surgical planning for maxillary and midface distraction osteogenesis. J Craniofac Surg. 2003;14 (6):833-9.
6. Jensen JN, McCarthy JG, Grayson BH. Bone deposition/generation with LeFort III (Midface) distraction. Plast Reconstr Surg. 2007;119(1):298-307.
7. Wiltfang J, Hirschfelder U, Neukam FW, et al. Long-term results of distraction osteogenesis of the maxilla and midface. Br J Oral Maxillofac Surg. 2002; 40 (6):473-9.
8. Cohen SR, Simms CRN, Burstein FD, et al. Mandibular distraction osteogenesis in the treatment of upper airway obstruction in children with craniofacial deformities. Plast Reconstr Surg. 1998;101(2):312-8.
9. Ingervall B, Schmoker R. Effect of surgical reduction of the tongue on oral stereognosis, oral motor ability, and the rest position of the tongue and mandible. Am J Orthod Dentofacial Orthop. 1990;97(1):58-65.
10. Mixter RC, Ewanowski SJ, Carson LV. Central tongue reduction for macroglossia. Plast Reconstr Surg. 1993;91(6):1159-62.
11. Riley RW, Powell NB, Guilleminault C. Obstructive sleep apnea and the hyoid: a revised surgical procedure. Otolaryngol Head Neck Surg.: Official Journal of American Academy of Otolaryngology-Head and Neck Surgery. 1994;111(6): 717-21.
12. Bowden MT, Kezirian EJ, Utley D, et al. Outcomes of hyoid suspension for the treatment of obstructive sleep apnea. Arch Otolaryngol Head Neck Surg. 2005;131(5):440-5.
13. Riley RW, Powell NB, Guilleminault C. Obstructive sleep apnea syndrome: a review of 306 consecutively treated surgical patients. Otolaryngol Head Neck Surg. 1993;108,117-25.

JAYPEE BROTHERS

14. Cotton RT. Management of laryngotracheal stenosis and tracheal lesions including single stage laryngotracheoplasty. Int J Pediatr Otorhinolaryngol. 1995;32 (Supplement):S89-S91.
15. Luft JD, Wetmore RF, Tom LWC, et al. Laryngotracheoplasty in the management of subglottic stenosis. Int J Pediatr Otorhinolaryngol. 1989;17(3):297-303.
16. Hermes CG. Slide tracheoplasty for long-segment congenital tracheal stenosis. Ann Thorac Surg. 1994;58(3):613-20.
17. Rutter MJ, Cotton RT, Azizkhan RG, et al. Slide tracheoplasty for the management of complete tracheal rings. J Pediatr Surg. 2003;38(6):928-34.
18. Mahiarini P, Dulmet E, de Montpreville V, et al. Tracheal growth after slide tracheoplasty. J Thorac Cardiovasc Surg. 1997;113(3):558-66.

JAYPEE BROTHERS

detailed information on otolaryngology books, visit our website **www.jaypeebrothers.com,** for detailed information on otolaryngolog

Recent Advances in Otolaryngology Head & Neck Surgery

The 21st century Otolaryngologist is fortunate to practice in an era of technological and technical advance unprecedented in the history of medicine. The pace of new knowledge very quickly leaves our prior training obsolete: the half-life of medical knowledge is now under five years. From the newest techniques for treatment of craniofacial disorders, facial paralysis, aging face, single-sided deafness, and inverted papilloma, to advances in ossicular reconstruction, and the emergence of facial transplantation in the treatment of facial disfigurement, the Otolaryngologist is struggling to stay abreast of innovations that directly impact patient care. *Recent Advances in Otolaryngology—Head and Neck Surgery*, 4th Volume, has been designed to meet the need of the busy practicing clinician to efficiently keep current with what is new in each of the subspecialties of Otolaryngology. All of the chapters have been contributed by leading experts in the field. Due to its rapid publication cycle, the material is current, topical, and immediately relevant to the clinician.

Key Features

- Facial Transplantation
- Minimally Invasive Therapy for the Aging Face
- Advances in Craniofacial Surgery
- Surgical Rehabilitation of the Paralyzed Face
- Cochlear Implantation for Single-Sided Deafness
- Robotic Surgery in Head and Neck Cancer

What is different in this book compared to competitions

- It covers all the subspecialties of Otolaryngology.
- Rapid publication cycle—less than 6 months from submission of manuscript to publication to ensure that content is current.
- Clear artwork rendered in color to convey new concepts and surgical approaches.
- Outstanding international editorial board.



Anil K Lalwani MD is Professor and Vice-Chair for Research in the Department of Otolaryngology at Columbia University College of Physicians and Surgeons, New York, NY, USA, where he is Director of Division of Otology, Neurotology and Skull Base Surgery, Director of the Columbia Cochlear Implant Program and Medical Director of Perioperative Services, New York Presbyterian—Columbia University Medical Center. Currently, he is also serving as President of the American Neurotology Society. Dr Lalwani's basic research has focused on two key areas: identifying genes that are critical for hearing through the use of molecular genetic and molecular biologic methods, and developing and investigating gene transfer technology for the treatment of hearing disorders. His clinical interests in otology include cochlear implantation, chronic ear disease, facial nerve disorders, cerebellopontine angle tumors (e.g. acoustic neuromas), and skull base surgery. Dr Lalwani is considered as one of the leading experts on hearing loss in children and adults and its surgical treatment. He is the author of more than 175 peer-reviewed articles, numerous book chapters, and a textbook defining the subspecialty of Pediatric Otology and Neurotology. He is currently preparing the surgical atlas for the 50 most common procedures in Otolaryngology to be published by McGraw-Hill in 2015. The 4th edition of his second book, Current Diagnosis and Treatment in Otolaryngology—Head & Neck Surgery is currently in Press.



Markus HF Pfister MD MBA is an Otolaryngologist with subspecialization in Otology and Neurotology. He has been trained at the University of Tuebingen, Germany, University of California, San Francisco and Stanford University, USA, and he is academically affiliated with the University of Tuebingen, Germany. He has been responsible for the molecular genetics unit of hereditary hearing impairment at the Department of Otolaryngology, University of Tuebingen, Germany, and has been a member of the European Work Group on Genetics of Hearing Impairment. Dr Pfister's interests include innovative approaches in the diagnosis and therapy of disorders in otolaryngology and head and neck surgery, particularly in otology and neurotology. He is considered a leading expert on hereditary hearing loss and has contributed to several international studies on hereditary hearing impairment. He is author of more than 80 peer-reviewed articles and numerous book chapters.

Available at all medical bookstores or buy online at www.jaypeebrothers.com

JAYPEE BROTHERS
Medical Publishers (P) Ltd.
www.jaypeebrothers.com

Join us on facebook.com/JaypeeMedicalPublishers

Shelving Recommendation
OTOLARYNGOLOGY

ISBN 978-93-5152-534-9