website www.jaypeebrothers.com, for detailed information on nursing books, visit our website www.jaypeebrothers.com

JAYPEE

Handbook of ANATOMY & PHYSIOLOGY for Nurses (for GNM Students)



Inderbir Singh

Contents

PART 1: INTRODUCTION TO THE HUMAN BODY

1. Learning the Language of Medicine **3**

The Subject of Anatomy 3
Main Subdivisions of the Human Body 3
Some Commonly Used Descriptive Terms 4
Structures Constituting the Human Body 7

2. A Brief Introduction to Bones, Joints and Muscles of the Body **10**

The Skeleton 10
The Skull 10
The Vertebral Column 11
Skeleton of the Thorax 13
Skeleton of the Upper Limb 14
Skeleton of the Lower Limb 15
Some Features of Joints 17
Classification of Joints 18
Some Facts about Muscles 20

3. A Brief Introduction to Organ Systems of the Body **24**

Introduction to the Respiratory System 24
Introduction to the Alimentary System 26
Introduction to the Urinary System 27
Introduction to the Reproductive System 28
Introduction to the Endocrine Glands 30
The Lymphoid Organs 31
Introduction to the Cardiovascular System 31
Introduction to the Nervous System 32
Autonomic Nervous System 35

4. Introduction to Body Functions **36**

Some Essential Body Functions 37
Modes of Communication within the Body 38

5. Essential Chemistry **39**

Atoms and Elements 39
Compounds and Molecules 41
Chemical Bonds 42
Introduction to Some Important Chemical Constituents of the Body 45

PART 2: CELLS AND TISSUES OF THE BODY

6. Cell Structure **51**

Cell Structure 51
Basic Membrane Structure 51
The Cell Membrane 54
Cell Organelles 56
The Cytoskeleton 61
Projections from the Cell Surface 62
The Nucleus 64
Chromosomes 65
Cell Division 74
Chromosomal Sex and Sex Chromatin 80
Abnormal Cell Growth and Tumours 81

7. Epithelia and Glands **82**

Classification of Epithelia 82
Glands 91

8. General Connective Tissue **94**

Introductory Remarks 94
Fibres of Connective Tissue 97
Cells of Connective Tissue 98
Adipose Tissue 102
Summary of the Functions of Connective Tissues 104

9. Cartilage and Bone **106**

Cartilage 106
Hyaline Cartilage 107
Fibrocartilage 108
Elastic Cartilage 109
Bone 110
Basic Facts about Bone Structure 111
Formation of Bone 116
Some Disorders of Bone 120

10. Muscle and Nerve Tissue 122

Muscle 122
Skeletal Muscle 123
Physiology of Skeletal Muscle 128
Chemical Processes Involved in Muscle Contraction 131
Cardiac Muscle 135
Smooth Muscle 136
Some Clinical Correlations of Muscle 138
Nervous Tissue 139
Neuron Structure 140
Some Physiological Properties of Neurons 144
Peripheral Nerves 146
Degeneration and Regeneration of Neurons 149
Peripheral Nerve Endings 149
Sensory Receptors 150
Exteroceptive Receptors 151
Proprioceptive Receptors 152
Neuromuscular Junctions 152
Ganglia 155
Neuroglia 155
Reflex Action 158

11. Blood 160

Plasma Proteins 161
Cellular Elements of Blood 162
Erythrocytes (Red Blood Corpuscles) and Related Topics 162
Haemoglobin 163
Anaemia 165
Erythrocyte Sedimentation Rate (ESR) 166
Packed Cell Volume (PCV) 167
Blood Indices 167
Blood Groups 168
Leucocytes (White Blood Corpuscles) 171
Further Facts about Lymphocytes 173
Lukaemias 175
Blood Platelets 176
Coagulation of Blood 176
Anticoagulants 178
Formation of Blood (Haemopoiesis) 178
Mononuclear Phagocyte System 180

12. Lymphoid Tissues and Immunity 182

Lymphatic Vessels 183
Lymph Nodes 183
The Spleen 187
Functions of the Spleen 189
The Thymus 190
Functions of the Thymus 192
Mucosa Associated Lymphoid Tissue 192
Defence Mechanisms and Immunity 194
Defence Mechanisms 194
Lymphocytes and the Immune System 195
Immunity 196

13. Skin and its Appendages 199

The Skin 199
Functions of the Skin 202
Appendages of the Skin 203
Regulation of Body Temperature 207
Healing of Wounds 208
Some Disorders of Skin 209

PART 3: THE ORGAN SYSTEMS

14. Cardiovascular System 213

The Heart 213
Coronary Circulation 218
Conducting System of the Heart 220
Control of Heart Rate 221
Cardiac Cycle 221
Cardiac Output 222
Pulse 222
Heart Sounds 223
Electrocardiogram (ECG) 223
Some Disorders of the Heart 225
Blood Pressure 225
Disorders of Blood Pressure 226
Effect of Exercise on Cardiovascular System 227
Blood Vessels 228
Arteries 228
Arterioles 229
Veins 230
Venules 231

Capillaries 232
Sinusoids 232
Mechanisms Controlling Blood Flow Through the Capillary Bed 232
Factors Influencing Blood Flow Through Vessels 234
Some Diseases of Blood Vessels 234

15. Respiratory System **235**

Nasal Cavity 237
The Paranasal Sinuses 239
The Pharynx 239
The Larynx 241
The Trachea 243
The Lungs 244
The Pleura 249
Some Physiological Considerations 249
Acid-Base Balance 253
Some Clinical Conditions 254

16. The Alimentary Canal **256**

The Oral Cavity and Pharynx 256
The Salivary Glands 258
The Teeth 260
The Tongue 261
The Pharynx 263
Basic Pattern of the Structure of the Alimentary Canal 265
Individual Parts of the Alimentary Canal 267
The Oesophagus 267
The Stomach 267
The Small Intestine 275
The Large Intestine 282

17. Liver and Pancreas **290**

The Liver 290
Histology of the Liver 293
Functions of the Liver 296
Extrahepatic Biliary Apparatus 298
The Gallbladder 298
The Bile Duct 299
The Pancreas 301
Histology of the Pancreas 303

18. Nutrition, Digestion and Metabolism **306**

Nutrition 306
Carbohydrates 306
Proteins 307

Fats or Lipids 308
Vitamins 309
Digestion and Absorption 310
Metabolism 312
Carbohydrate Metabolism 313
Protein Metabolism 315
Fat Metabolism 315

19. The Urinary System 317

The Kidneys 317
Functions of the Kidneys 317
Basic Structure of the Kidney 318
The Uriniferous Tubules 323
Production of Urine 332
Some Other Functions of the Kidney 336
Some Diseases of the Kidneys 337
Kidney Function Tests 339
The Ureters 340
The Urinary Bladder 342
The Urethra 344
The Male Urethra 344
The Female Urethra 346
Micturition 346

20. Male Reproductive Organs 348

The Perineum 349
The Testis and Epididymis 352
Seminiferous Tubules 353
The Ductus Deferens 356
The Spermatic Cord 356
Seminal Vesicle 358
The Penis 359
The Prostate 360
Semen 361
Testosterone 362
Some Diseases of Reproductive Organs 363
Disorders of Male Genital Tract 363

21. Female Reproductive Organs 364

Gross Anatomy and Histology of Female Reproductive Organs 364
The Ovaries 367
Oogenesis 369
The Uterine Tubes 372
The Uterus 374

The Vagina 375
The Mammary Glands 376
Menstrual Cycle 376
Hormones Influencing Ovulation and Menstruation 379
Oestrogens 380
Progesterone 381
Physiology of Pregnancy 381
Fertilization 381
Placenta 383
Physiological Changes in the Mother during Pregnancy 383
Lactation 385
Contraceptives 386
Some Diseases of Female Reproductive Organs 387

22. The Endocrine System 388

Hypothalamus 388
The Hypophysis Cerebri (Pituitary Gland) 389
Adenohypophysis (Pars Anterior) 390
Neurohypophysis (Pars Posterior) 392
The Pineal Gland 394
The Thyroid Gland 395
The Parathyroid Glands 400
Hormones Controlling Calcium Metabolism 401
The Suprarenal (Adrenal) Glands 402
The Suprarenal Medulla 404
Pancreatic Islets 405
Clinical Correlations of Endocrine Organs 406
Hypophysis Cerebri 406
Thyroid Gland 407
Parathyroid Glands 407
Pancreas 408
Suprarenal Glands 408

23. The Nervous System 409

Cranial Cavity and Vertebral Canal 409
The Spinal Cord 410
Spinal Nerves and Spinal Segments 411
Gross Anatomy of the Brainstem 414
Internal Structure of the Brainstem 417
Physiology of Pain 423
Gross Anatomy of the Cerebellum 423
Gross Anatomy of the Cerebral Hemispheres 427
Exterior of the Cerebral Hemispheres 427
Further Subdivisions of the Superolateral Surface 430
Some Structures within the Cerebral Hemispheres 435

Important Functional Areas of the Cerebral Cortex 437
White Matter of Cerebral Hemispheres 439
The Internal Capsule 439
Corpus Callosum 440
Some Important Tracts 440
Descending Tracts Ending in the Spinal Cord 442
Descending Tracts Ending in the Brainstem 444
Ascending Tracts 445
Spinocerebellar Pathways 447
Some Important Masses of Grey Matter 448
The Cerebral Cortex 448
The Thalamus 448
The Hypothalamus 449
Corpus Striatum 451
The Ventricles of the Brain 452
Cerebrospinal Fluid 455
Some Clinical Considerations 455
Disorders of Motor Function 456
Disorders of Equilibrium 457
Abnormal Movements 458
Sensory Disorders 459
Referred Pain 459
Spinal Reflexes 460
The Autonomic Nervous System 461
The Sympathetic Trunk 461

24. The Eye and Ear 463

The Eye 463
The Eyelids and Conjunctiva 463
The Eyeball 465
The Retina 469
Muscles of the Orbit 470
The Visual Pathway 473
Mechanism of Vision 473
Reflexes Related to the Eyeball 476
Some Diseases of the Eye 477
The Ear and Some Related Structures 478
The Auricle 479
External Acoustic Meatus 480
The Middle Ear 480
The Internal Ear 484
Organ of Corti and Mechanism of Hearing 488
Some Diseases of the Ear 491

PART 4: FURTHER LEARNING THROUGH PICTURES

25. Some Important Regions **495**

26. Some Important Bones **545**

The Clavicle 545
The Scapula 546
The Humerus 548
The Radius 550
The Ulan 552
Bones of the Wrist and Hand 554
The Hip Bone–1 555
The Hip Bone–2 556
The Pelvis 557
The Femur 558
The Tibia 560
The Fibula 562
Bones of the Foot 564
Typical Thoracic Vertebrae 565
Cervical Vertebrae 566
Lumbar Vertebrae 568
The Sacrum 570
The Sternum and Ribs 572
The Skull 574
Cranial Fossae 576
The Mandible 577

27. Some Important Arteries and Veins **578**

Main Arteries of the Body 579
Main Veins of the Body 580

Index *585*

CHAPTER

3

A Brief Introduction to Organ Systems of the Body

JAYPEE BROTHERS

We have seen that the body contains a number of organ systems that are essential to its working. We shall take a brief look at each system in the paragraphs that follow. Each of the organs mentioned will be studied in detail later.

INTRODUCTION TO THE RESPIRATORY SYSTEM

The respiratory system is meant, primarily, for the oxygenation of blood. The chief organs of the system are the right and left ***lungs***. Oxygen contained in air reaches the lungs by passing through a series of respiratory passages, which also serve for removal of carbon dioxide released from the blood.

The respiratory passages are shown in Figs. 3.1 and 3.2. Air from the outside enters the body through the right and left ***anterior nares*** (or ***external nares***) which open into the right and left ***nasal cavities.*** Apart from their respiratory function, the nasal cavities have olfactory areas that act as end organs for smell. At their posterior ends the nasal cavities have openings called the ***posterior nares*** (or ***internal nares***) through which they open into the ***pharynx.*** The pharynx is a single cavity not divided into right and left halves. It is divisible, from above downwards, into an upper part the ***nasopharynx*** (into which the nasal cavities open); a middle part the ***oropharynx*** (which is continuous with the posterior end of the oral cavity); and a lower part the ***laryngopharynx***. Air from the nose enters the nasopharynx and passes down through the oropharynx and laryngopharynx. Air can also pass through the mouth directly into the oropharynx and from there to the laryngopharynx. Air from the laryngopharynx enters a box like structure called the ***larynx.*** The larynx is placed on the front of the upper part of the neck. Apart from being a respiratory passage it is the organ where voice is produced. It is, therefore, sometimes called the voice box.

Inferiorly the larynx is continuous with a tube called the ***trachea.*** The trachea passes through the lower part of the neck into the upper part of the thorax. At the level of the lower border of the manubrium sterni the trachea bifurcates into the right and left ***principal bronchi***, which carry air to the

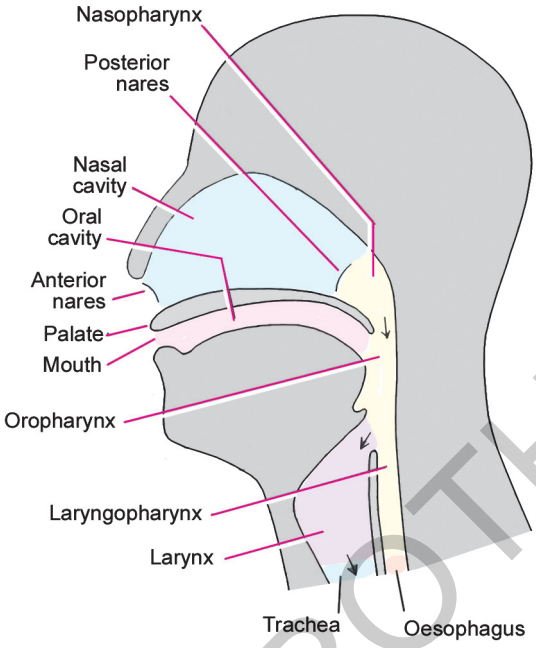

Fig. 3.1 Simplified diagram showing intercommunications between the nasal cavities, the mouth, the pharynx, the larynx and the oesophagus.

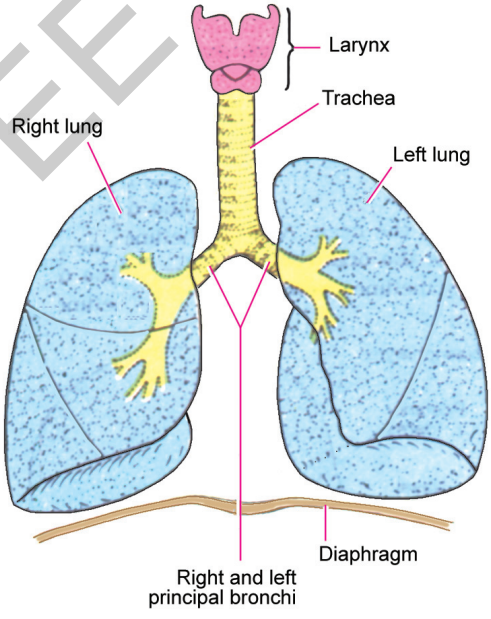

Fig. 3.2 Diagram to show the main parts of the respiratory system.

JAYPEE BROTHERS

right and left lungs. Within the lung each principal bronchus divides, like the branches of a tree, into smaller and smaller ***bronchi*** that ultimately end in microscopic tubes that are called ***bronchioles.*** The bronchioles open into microscopic sac-like structures called ***alveoli.*** The walls of the alveoli contain a rich network of blood capillaries. Blood in these capillaries is separated from the air in the alveoli by a very thin membrane through which oxygen can pass into the blood and carbon dioxide can pass into the alveolar air.

The pumping of air in and out of the lungs is a result of respiratory movements performed by respiratory muscles. The most important of these is the ***diaphragm***. The diaphragm is so called because it forms a partition between the thorax and the abdomen. Another important set of respiratory muscles are the ***intercostals muscles*** that occupy the intercostal spaces (intervals between adjacent ribs).

INTRODUCTION TO THE ALIMENTARY SYSTEM

In ordinary English the word 'alimentary' means 'pertaining to nourishment'. The alimentary (or digestive) system includes all those structures that are concerned with eating, and with the digestion and absorption of food. The system consists of an alimentary canal that starts at the ***mouth*** and ends at the ***anus***.

The external opening of the mouth is the ***oral fissure*** bounded by the upper and lower lips. Within the mouth cavity (or ***oral cavity***) there are the ***teeth*** with which food is chewed; and the ***tongue*** which helps the processes of chewing and swallowing in addition to being an organ of taste. The roof of the mouth is formed by the ***palate*** (which separates the mouth from the nasal cavities). Posteriorly, the mouth opens into the ***oral part of the pharynx***. We have already seen that this part of the pharynx is continuous, below, with the ***laryngeal part of the pharynx***. The latter becomes continuous with the ***oesophagus***. The oesophagus is a tube that descends through the lower part of the neck, and then through the entire length of the thorax, to pierce the diaphragm and reach the abdomen (Fig. 3.3). Here the oesophagus ends by joining the ***stomach***. The stomach is a large sac-like organ that acts as a store of swallowed food. After this food is partially digested in the stomach it passes into the ***small intestine***. The small intestine is in the form of a tube about 5 meters long. It is divided, (rather arbitrarily) into three parts. These are the ***duodenum***, the ***jejunum*** and the ***ileum*** (in that order). The small intestine is followed by the ***large intestine***. The large intestine is about one and a half meters long. (It is described as large because it has a wider diameter). Its main subdivisions are the ***caecum***, the ***ascending colon***, the ***transverse colon***, the ***descending colon***, the ***sigmoid*** (or ***pelvic***) ***colon***, the ***rectum*** and the ***anal canal***. These are shown in Fig. 3.3. The anal canal opens to the exterior at the ***anus***.

After food has been digested and absorbed the useless remnants that remain are passed out to the exterior as faeces.

Closely related to the alimentary canal there are several accessory organs. In the region of the mouth there are three pairs of ***salivary glands,*** which produce

JAYPEE BROTHERS

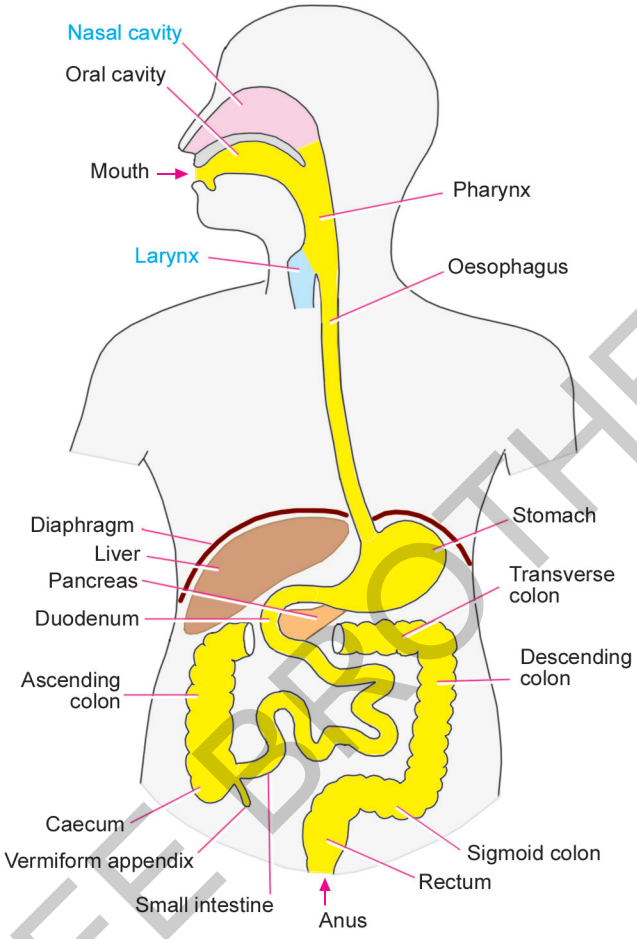

Fig. 3.3 Diagram to show the main parts of the digestive system.

a fluid the ***saliva***, that helps to keep the oral cavity moist. In the abdomen we have two large glands: the ***liver*** and the ***pancreas***. The liver occupies the upper right part of the abdomen. It is a very important organ having numerous functions. The pancreas lies transversely on the posterior wall of the abdomen. It produces digestive juices that are poured into the duodenum and help in digestion. It is also an important endocrine organ.

INTRODUCTION TO THE URINARY SYSTEM

The organs of the body that are concerned with the formation of urine and its elimination from the body are referred to as urinary organs. Urine is produced in the right and left ***kidneys,*** which lie on the posterior wall of the abdomen (Fig. 3.4). This urine passes through narrow tubes, the

JAYPEE BROTHERS

right and left ***ureters***, to reach a sac like reservoir called the ***urinary bladder***. The urinary bladder lies in the true pelvis. It is connected to the exterior by a tube called the ***urethra***.

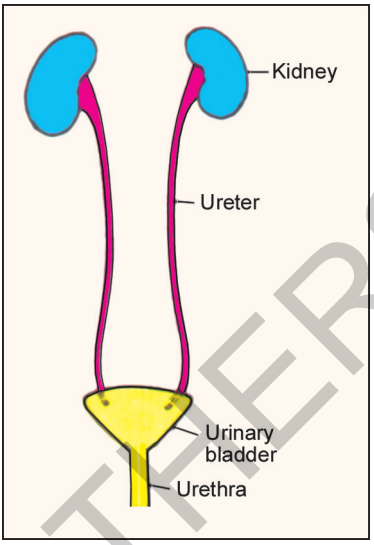

Fig. 3.4 Diagram to show the urinary organs

INTRODUCTION TO THE REPRODUCTIVE SYSTEM

Both in the male and in the female the reproductive system consists of genital organs that are concerned with the function of reproduction. These organs may be divided into the ***primary sex organs,*** or ***gonads,*** which are responsible for the production of gametes; and the ***accessory sex organs,*** which play a supporting role. The genital organs are also divided into the ***internal genital organs*** (or ***internal genitalia***) which include the gonads and those supporting organs that cannot be seen from the outside of the body; and the ***external genital organs*** (or ***external genitalia***) which are visible on the outside. In human beings (as in many other animal groups) fertilization takes place within the female body. This requires that male gametes be introduced into the female body through the process of ***copulation*** or ***coitus*** (commonly referred to as sexual intercourse). The male and female organs that are concerned with copulation are referred to as ***copulatory organs***. The region of the body where the external genitalia (and anus) are located is referred to as the ***perineum***.

Male Reproductive Organs

The male gonads are the right and left ***testes*** (singular = testis) (Fig. 3.5). They produce the male gametes, which are called ***spermatozoa*** (singular = ***spermatozoon***). From each testis the spermatozoa pass through a complicated system of genital ducts. The most obvious of these are the ***epididymis*** and the ***ductus deferens***. Near its termination, the ductus deferens is joined by the duct of the ***seminal vesicle*** (a sac like structure), to form the ***ejaculatory duct.*** The right and left ejaculatory ducts open into the urethra.

The testis, epididymis and the initial part of the ductus deferens of both sides lie in a sac like structure covered by skin: this sac is called the ***scrotum***. From here the ductus deferens passes upwards and enters the abdomen by passing through an oblique passage in the anterior abdominal wall: this passage is called the ***inguinal canal***. Here the ductus deferens is surrounded by several structures that collectively form the ***spermatic cord***.

JAYPEE BROTHERS

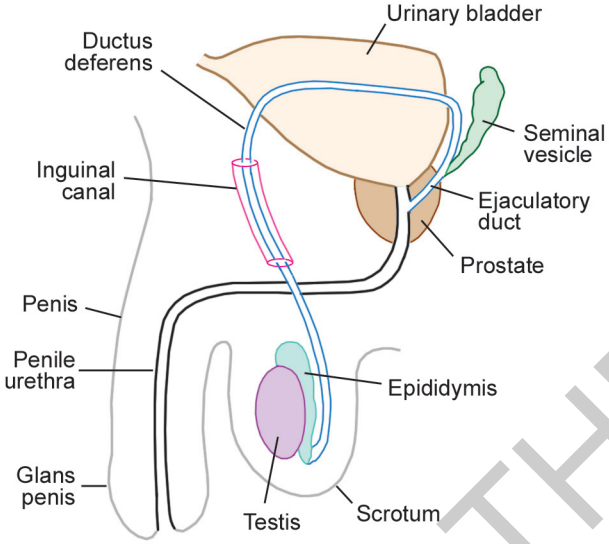

Fig. 3.5 Diagram to show the male reproductive organs

As spermatozoa pass through the genital ducts, named above, they undergo maturation. They get mixed up with secretions produced by the seminal vesicle and the prostate to form the ***seminal fluid*** or ***semen.*** The process of ejection of semen from the body is called ***ejaculation***. In this process semen is poured into the urethra and passes through it to the exterior. The male urethra is, therefore, both a urinary and a genital passage.

The ***penis*** is the male external genital organ. It is the organ of copulation. Because it is capable of becoming rigid it can be introduced into the vagina of the female, and semen can be injected into the vaginal cavity.

Female Reproductive Organs

The female reproductive organs are shown in Fig. 3.6. The female gonads are the right and left ***ovaries***. The female internal genital organs are the ***uterus***, the ***uterine tubes*** and the ***vagina***. The vagina is the female organ of copulation. It opens to the exterior through a depression in the perineum called the ***vestibule***. The female external genital organs are present around the vestibule. They are the ***labia majora,*** the ***labia minora*** and the ***clitoris***; and some deeper structures that are associated with them. The ***mammary glands*** are accessory organs of reproduction.

In a mature female one ovum is produced every month (in the right or left ovary). It travels into the uterine tube towards the uterus. Spermatozoa introduced into the vagina can travel from the vagina into the uterus to reach the uterine tube. If a spermatozoon encounters an ovum, fertilization can take place. (Fertilization normally takes place in the uterine tube). The fertilized ovum then travels to the uterus where it gets lodged and starts developing into a fetus (unborn child in the process of development).

JAYPEE BROTHERS

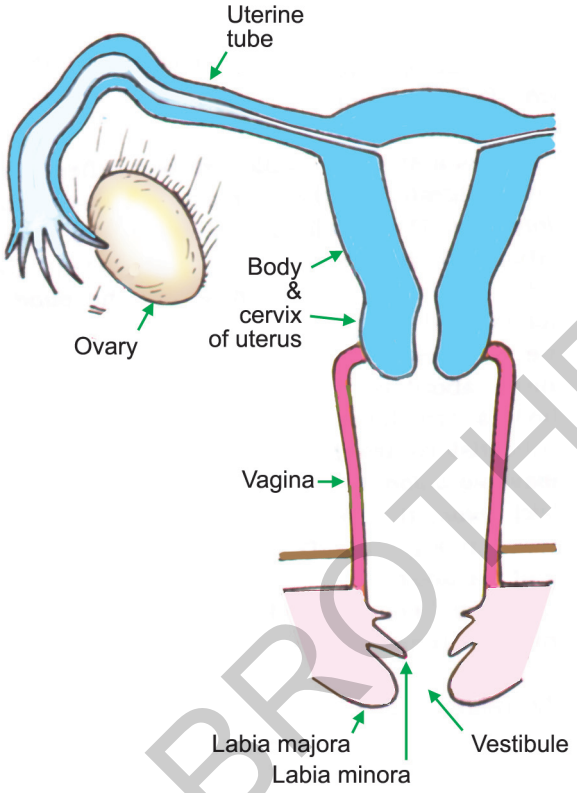

Fig. 3.6 Diagram to show the female reproductive organs.

The uterus provides the fetus with nutrition and with a suitable environment for its growth. The period during which a fetus is growing in the uterus is called ***pregnancy***. During pregnancy a fetus receives nutrition and oxygen from the mothers' blood. Transfer of these from mother to fetus takes place through an organ called the ***placenta***. The uterus enlarges greatly during pregnancy. At the end of pregnancy the fetus is expelled out of the uterus. It passes through the vagina to the exterior as a newborn infant. The process of childbirth is called ***parturition***. The mammary glands provide the newborn baby with nourishment in the form of milk.

INTRODUCTION TO THE ENDOCRINE GLANDS

Some organs of the body produce secretions. Such organs are called ***glands***. In the case of many glands the secretions produced by them pass through one or more ducts to be poured into a cavity. The salivary glands are of this type. Such glands are called ***exocrine glands***. In contrast, there are other glands that have no duct. Their secretions are poured into blood. Such glands are called ***endocrine glands***, and their secretions are called ***hormones***. Hormones can

JAYPEE BROTHERS

travel through blood to distant organs and can influence their functions. One endocrine gland may produce more than one hormone. Some hormones influence only one organ, while some can have more widespread effects. Some endocrine glands constitute independent anatomical entities. These are the ***hypophysis cerebri*** (or ***pituitary gland)*** and the ***pineal body*** located within the cranial cavity; the ***thyroid*** and ***parathyroid glands*** located in the neck; and the ***suprarenal glands*** that lie in the abdomen just above the kidneys. Other endocrine glands are present in the form of histological elements embedded within organs having other functions. There are aggregations of cells having an endocrine function in the pancreas, the testes, and the ovaries. Some cells with endocrine functions are also present in the thymus, the kidney, the gastrointestinal tract, and the placenta.

THE LYMPHOID ORGANS

We have seen that tissues contain lymph vessels, and that small rounded bodies called ***lymph nodes*** are associated with them. Within lymph nodes we find aggregations of large numbers of cells called ***lymphocytes***. Similar aggregations of lymphocytes are also present in some other organs. All these are referred to as ***lymphoid organs***.

The largest lymphoid organ is the ***spleen***. It is located in the upper and left part of the abdomen, close to the stomach.

Another, very important, lymphoid organ is the ***thymus***. It is located in the thorax just deep to the sternum.

In the lateral walls of the oropharynx we have small lymphoid organs called the ***tonsils*** (one right and one left). These are frequently inflamed (***tonsillitis***) resulting in sore throat.

Many aggregations of lymphocytes are also present in the walls of some organs including the intestines and the respiratory passages.

INTRODUCTION TO THE CARDIOVASCULAR SYSTEM

The cardiovascular system consists of the ***heart*** and ***blood vessels***. The system is responsible for the circulation of blood through the tissues of the body. The heart acts as a pump and provides the force for this circulation. Blood vessels taking blood from the heart to the tissues are called ***arteries***.

The largest artery in the body is called the ***aorta***. Arising from the heart it divides, like the branches of a tree, into smaller and smaller branches. The smallest arteries are called ***arterioles***. The arterioles end in a plexus of thin-walled vessels that permeate the tissues. These thin walled vessels are called ***capillaries***. Oxygen, nutrition, waste products etc., can pass through the walls of capillaries from blood to tissue cells and ***vice versa***. In some organs these vessels are somewhat different in structure from capillaries and are called ***sinusoids***. Blood from capillaries or sinusoids is collected by another set of vessels that carry it back to the heart: these are called ***veins.*** The veins adjoining the capillaries are very small and are called ***venules.*** Smaller veins join together

JAYPEE BROTHERS

(like tributaries of a river) to form larger and larger veins. Ultimately the blood reaches two large veins, the ***superior vena cava*** and the ***inferior vena cava***, which pour it back into the heart. This blood reaching the heart through the veins has lost its oxygen. A special set of arteries and veins circulates this blood through the lungs where it is again oxygenated. This circulation through the lungs, for the purpose of oxygenation of blood, is called the ***pulmonary circulation,*** to distinguish it from the main or ***systemic circulation.***

For further consideration of the cardiovascular system see Chapter 14.

INTRODUCTION TO THE NERVOUS SYSTEM

The nervous system may be divided into two parts.

a. The ***central nervous system*** (CNS) is made up of the ***brain*** (lying in the cranial cavity) and the ***spinal cord*** (lying in the vertebral canal).
b. The ***peripheral nervous system*** is made up nerves that arise from the brain and spinal cord.

The brain consists of the following parts (Fig. 3.7):

1. The ***cerebrum*** made of two large ***cerebral hemi-spheres***;
2. The ***cerebellum***,
3. The ***midbrain***,

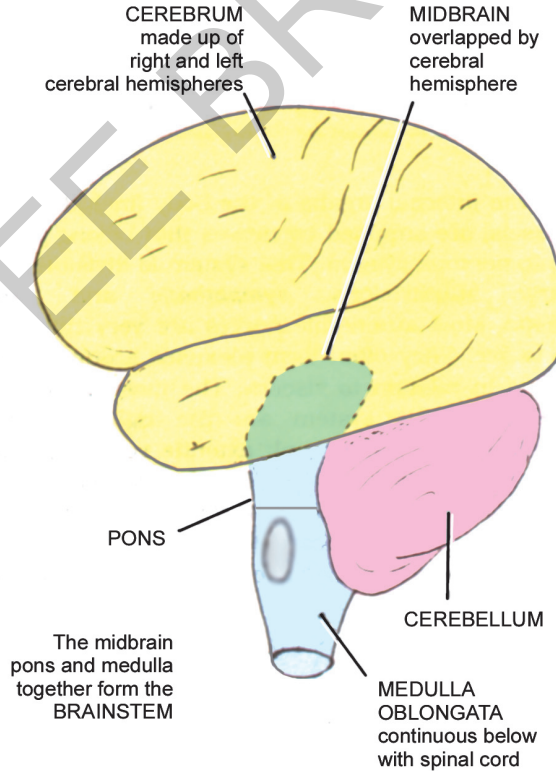

Fig. 3.7 Diagram to show the main parts of the brain.

JAYPEE BROTHERS

4. The ***pons***, and
5. The ***medulla oblongata.***

The midbrain, pons and medulla together constitute the ***brainstem***. The medulla is continuous, inferiorly, with the spinal cord.

Peripheral nerves attached to the brain are called ***cranial nerves***; and those attached to the spinal cord are called ***spinal nerves***.

The Cranial Nerves

There are twelve pairs of cranial nerves. They are identified by number and also bear names.

The **first** cranial nerve is called the ***olfactory*** nerve. It is the nerve of smell (olfaction = smell). It passes from the nose to the brain.

The **second** cranial nerve is called the ***optic nerve***. It is the nerve of sight and passes from the eyeball to the brain.

The **third** cranial nerve is called the ***oculomotor*** nerve. It supplies several muscles that move the eyeball.

The **fourth** cranial nerve is called the ***trochlear*** nerve. It is so called because it supplies a muscle (superior oblique, of the eyeball) that passes through a pulley (trochlea = pulley).

The **fifth** cranial nerve is called the ***trigeminal*** nerve because it has three major divisions. These are the ***ophthalmic division*** to the orbit, the ***maxillary division*** to the upper jaw, and the ***mandibular division*** to the lower jaw.

The **sixth** cranial nerve is called the ***abducent*** nerve because it supplies a muscle (lateral rectus) which 'abducts' the eyeball.

The **seventh** cranial nerve is the ***facial*** nerve because it supplies the muscles of the face.

The **eighth** cranial nerve is called the ***vestibulo-cochlear*** nerve because it supplies structures in the vestibular and cochlear parts of the internal ear. It is sometimes called the ***auditory*** nerve (auditory = pertaining to hearing) or the ***stato-acoustic*** nerve (stato = pertaining to equilibrium; acoustic = pertaining to sound).

The **ninth** cranial nerve is called the ***glossopharyngeal*** nerve as it is distributed to the pharynx and to part of the tongue (glossal = pertaining to the tongue).

The **tenth** cranial nerve is called the ***vagus***. It has an extensive course through the neck, the thorax and the abdomen. (The word vagus may be correlated with 'vagrant' = wandering from place to place).

The **eleventh** cranial nerve is called the ***accessory*** nerve because it appears to be a part of the vagus nerve (or 'accessory' to the vagus).

The **twelfth** cranial nerve is called the ***hypoglossal*** nerve (because it runs part of its course below the tongue before supplying the muscles in it (hypo = below; glossal = pertaining to tongue).

Spinal Nerves

We have seen that spinal nerves arise from the spinal cord. In the thoracic, lumbar and sacral regions the number of spinal nerves corresponds to that

JAYPEE BROTHERS

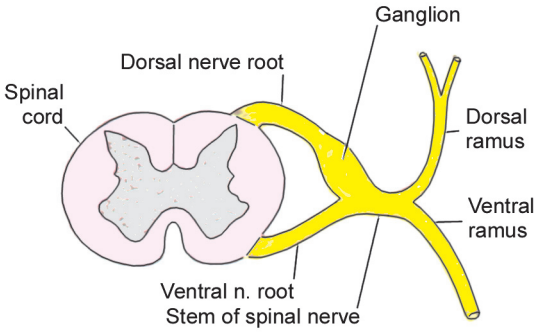

Fig. 3.8 Diagram to show the roots and main divisions of a typical spinal nerve.

of the vertebrae. On each side (right or left) there are twelve thoracic nerves, five lumbar nerves, and five sacral nerves. In the cervical region there are eight cervical nerves (but only seven vertebrae). Below the sacral nerves there is one coccygeal nerve.

Each spinal nerve arises from the spinal cord by two roots, one dorsal and one ventral (Fig. 3.8). After a very short course the spinal nerve divides into a dorsal primary ramus (ramus = branch) and a ventral primary ramus. As a rule the dorsal ramus is smaller than the ventral ramus. It passes backwards and divides into medial and lateral branches which supply the muscles and skin of the back. The ventral primary ramus passes forwards. In the thoracic region each ventral ramus remains distinct and forms an ***intercostal nerve***. In the cervical, lumbar and sacral regions the ventral rami join those of neighbouring spinal nerves to form complicated plexuses.

Branches arising from these plexuses supply muscles and skin. In the upper cervical region we have a ***cervical plexus***. In the lower cervical region there is the ***brachial plexus*** that gives origin to the nerves of the upper limb. In the lumbar region we have a ***lumbar plexus***, and in the sacral region we have a ***sacral plexus***. The lumbar and sacral plexuses send branches into the lower limb.

The cervical plexus gives off several branches to tissues in the head and neck. It also gives off the ***phrenic nerve*** which descends into the thorax to supply the diaphragm.

There are three prominent nerves in the upper limb. These are the ***median***, ***ulnar*** and ***radial*** nerves. They are all branches of the brachial plexus and are so named because of their relative position in the forearm.

There are two main nerves in the lower limb. The ***femoral nerve*** is seen in the front of the thigh. It is a branch of the lumbar plexus. The ***sciatic nerve*** is seen on the back of the thigh. It is derived from the sacral plexus. It descends to the back of the knee where it divides into the ***tibial nerve*** (which supplies the back of the leg) and the ***common peroneal nerve*** (which supplies the front and lateral side of the leg). Branches of both these nerves descend into the foot.

JAYPEE BROTHERS

Most of the nerves mentioned above supply tissues like skin and muscle. From the skin they carry impulses of touch, pain, temperature, etc. Such nerves are called ***sensory nerves***. Nerves that supply muscles are called ***motor nerves***. Nerves that contain both sensory and motor nerve fibres are ***mixed nerves***, and the large majority of nerves belong to this category.

The segment of the spinal cord that gives origin to one spinal nerve is called a ***spinal segment***. The number of spinal segments corresponds to the number of spinal nerves.

AUTONOMIC NERVOUS SYSTEM

Most internal organs of the body, (including the blood vessels), are supplied by nerves that belong to the autonomic nervous system. This system is divisible into two large subdivisions, ***sympathetic*** and ***para-sympathetic***. Most autonomic nerves are very thin and difficult to see. They often form plexuses around blood vessels and in relation to viscera. The most prominent components of this system are the right and left ***sympathetic trunks***. Each trunk extends vertically from the base of the skull (above) to the coccyx (below). The trunks lie along the sides of the vertebral column. Each trunk bears a large number of thickenings along its length. These thickenings are ***sympathetic ganglia***.

The vagus nerve provides a parasympathetic supply to many organs of the body.

JAYPEE BROTHERS

or detailed information on nursing books, visit our website www.jaypeebrothers.com, for detailed information o

Handbook of ANATOMY & PHYSIOLOGY *for Nurses (for GNM Students)*

Salient Features

- The text is accompanied by numerous illustrations to facilitate understanding.
- Provides an introduction to common diseases that affect different organs of the body. After studying these descriptions the nursing student would be able to understand most of the terms used by doctors.
- At the end of the book given a more useful selection of color plates illustrating various regions of the body.

Available at all medical book stores
or buy directly from Jaypee Brothers through online shopping
at www.jaypeebrothers.com

JAYPEE BROTHERS
Medical Publishers (P) Ltd.
www.jaypeebrothers.com

Join us on facebook.com/JaypeeMedicalPublishers

ISBN 978-93-5152-590-5