ebsite www.jaypeebrothers.com, for detailed information on anatomy books, visit our website www.jaypeebrothers.com

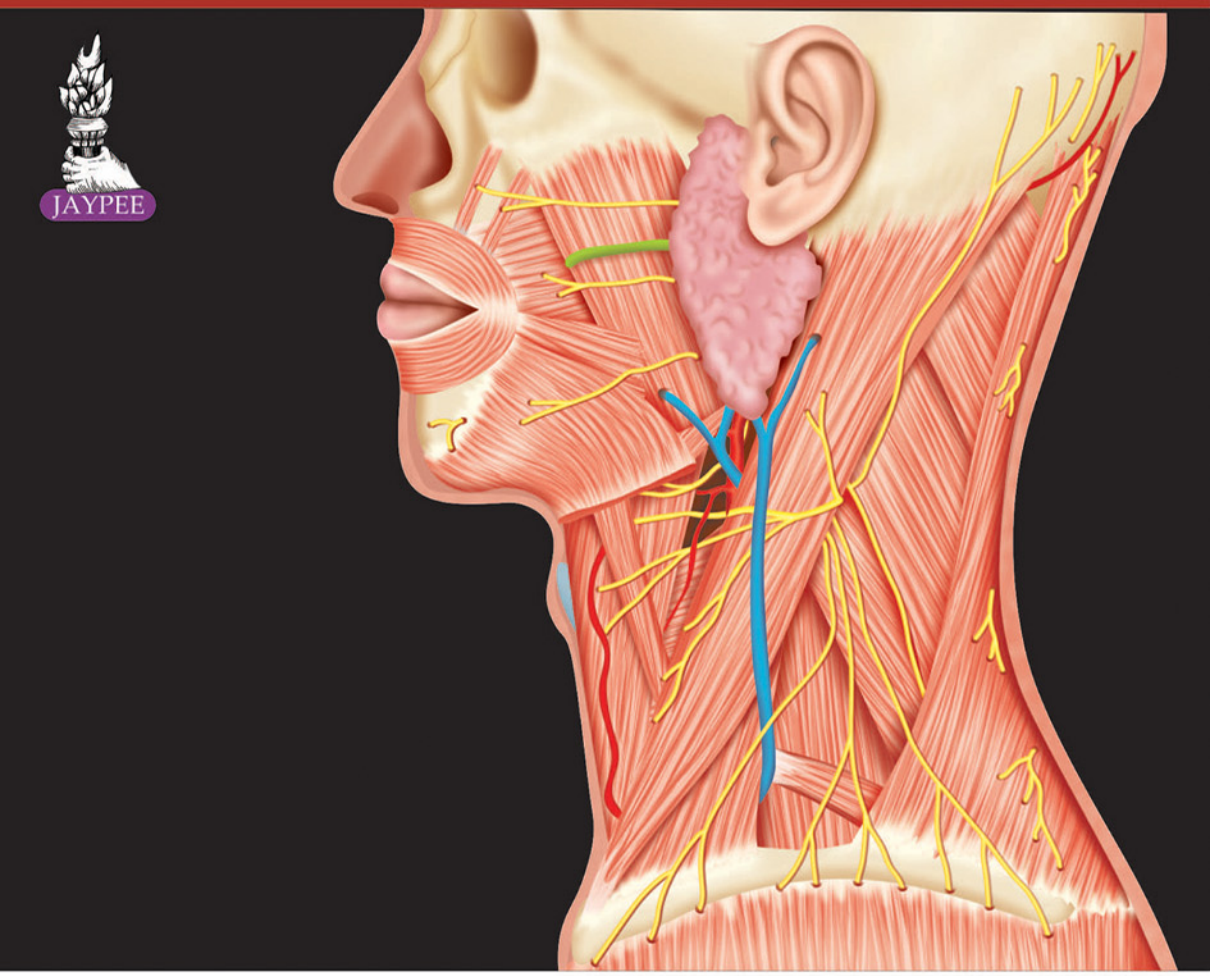

Essentials of ANATOMY for Dental Students (With Colour Atlas)

Inderbir Singh

Contents

PART 1: HEAD AND NECK

1. Colour Atlas of the Head and Neck **3**

2. Introduction to the Head and Neck **29**

An Overview of the Layout of Structures in the Head and Neck *31*
Main Arteries of Head and Neck *43*
Main Veins of Head and Neck *45*
Lymph Nodes of Head and Neck *45*
Main Nerves of the Head and Neck *46*
Endocrine Glands of Head and Neck *49*

3. Scalp, Face, Parotid Region and Lacrimal Apparatus **50**

The Scalp *50*
The Face *53*
Muscles of the Face *60*
Parotid Gland *65*
Vessels of the Face and Parotid Region *67*
Nerves of the Face *68*

4. Temporal and Infratemporal Regions **70**

Temporal Region *70*
Infratemporal Fossa *71*
Muscles of Mastication *74*
The Temporomandibular Joint *81*

5. Submandibular Region and Tongue **85**

Submandibular Region *85*
The Submandibular Gland *87*
The Sublingual Gland *90*
Suprahyoid Muscles *91*
The Tongue *95*
Muscles of the Tongue *98*
Blood Vessels, Lymphatics, and Nerves of the Tongue *101*

6. Cranial Cavity and Vertebral Canal. Joints of the Head and Neck **103**

The Meninges *104*
Intracranial Venous Sinuses *113*

Nerves and Arteries in the Cranial Cavity *114*
The Spinal Cord *117*
Joints of Head and Neck 123

7. Muscles of the Neck. Triangles of the Neck. Deep Cervical Fascia 129

Muscles of the Neck 129
Sternocleidomastoid *130*
Infrahyoid Muscles *131*
The Lateral Vertebral Muscles *134*
Anterior Vertebral Muscles (Prevertebral Muscles) *136*
Deep Muscles of the Back *137*
Triangles of the Neck 146
The Posterior Triangle *147*
Subdivisions of the Anterior Triangle *148*
Suboccipital Triangle *150*
Deep Cervical Fascia 150

8. Blood Vessels of Head and Neck 153

Arteries 153
The Common Carotid Arteries *153*
Internal Carotid Artery *155*
The External Carotid Arteries *161*
The Subclavian Arteries *172*
The Veins 183
The Internal Jugular Veins *183*
The Subclavian Veins *186*
The Intracranial Venous Sinuses *187*
Veins Draining the Eyeball and Orbit *190*
Tributaries of Internal Jugular Veins in the Neck *193*
Other Veins of the Head and Neck *195*

9. Nerves of the Head and Neck 199

Cervical Nerves *199*
The Cervical Plexus and its Branches *201*
The Cranial Nerves 208
Types of Fibres in Peripheral Nerves *209*
Cranial Nerve Nuclei *213*
The Olfactory Nerves *217*
The Optic Nerve *217*
The Oculomotor Nerve *221*
The Trochlear Nerve *224*
The Abducent Nerve *226*
The Trigeminal Nerve *226*
The Facial Nerve *242*
The Vestibulocochlear Nerve *254*
The Glossopharyngeal Nerve *258*
The Vagus Nerve *263*

The Accessory Nerve *268*
The Hypoglossal Nerve *269*
Cervical Part of Sympathetic Trunk *271*

10. Orbit, Eye and Ear **276**

The Orbit 276
Muscles of the Orbit *279*
The Lacrimal Gland *287*
The Eyeball 288
The Ear and Some Related Structures 301
The Auricle *303*
External Acoustic Meatus *304*
The Middle Ear *306*
The Internal Ear *321*

11. Oral Cavity, Nasal Cavity, Pharynx, Larynx, Trachea, Oesophagus **332**

The Oral Cavity and Some Related Structures 332
The Oral Cavity *332*
The Palate *334*
The Teeth *337*
The Nasal Cavity and Paranasal Sinuses 339
The Paranasal Sinuses *344*
The Pharynx 347
Muscles of the Pharynx *350*
The Palatine Tonsils *354*
The Larynx 357
Interior of the Larynx *361*
Muscles of the Larynx *365*
The Trachea *370*
The Oesophagus *372*

12. Endocrine Glands of the Head and Neck. Carotid Sinus and Carotid Body **373**

The Hypophysis Cerebri *373*
The Pineal Body *379*
The Thyroid Gland *381*
The Parathyroid Glands *385*
The Carotid Sinus *386*
The Carotid Bodies *386*

13. Lymphatics of the Head and Neck **388**

Lymph Nodes of Head and Neck *388*
Lymphatic Drainage of Some Regions of the Head and Neck *390*

14. Surface Marking of Some Structures in the Head and Neck **400**

Surface Marking of Some Viscera *400*
Paranasal Sinuses *401*
Arteries *402*

Veins *404*
Intracranial Venous Sinuses *404*
Nerves *405*

15. Clinical Correlations of the Head and Neck **407**

Clinical Correlations of Bones and Joints of the Head and Neck *407*
Clinical Correlations of Blood Vessels of Head and Neck *411*
Clinical Correlations of Deep Cervical Fascia *414*
The Scalp *415*
Cranial Nerves *416*
Hypophysis Cerebri *423*
Thyroid Gland *424*
Parathyroid Glands *426*
The Mouth, Teeth and Gums *426*
Harelip and Cleft Palate *427*
The Tongue *428*
Salivary Glands *429*
Tonsils *430*
Pharynx *431*
Nasal Cavity *431*
Paranasal Sinuses *432*
The Larynx and Trachea *432*
The Face *433*
Neck *433*
Meninges and Cerebrospinal Fluid *435*
Spinal Cord *435*
Eyes and Related Structures *436*
The Ear *437*
Imaging of the Head and Neck *437*

PART 2: CENTRAL NERVOUS SYSTEM

16. Colour Atlas of the Central Nervous System **441**

17. Introduction to the Central Nervous System. Internal Structure of Spinal Cord **459**

Introduction to the Central Nervous System *459*
Internal Structure of Spinal Cord *464*

18. Gross Anatomy of the Brain **469**

Gross Anatomy of the Brainstem *469*
Preliminary Review of the Internal Structure of the Brainstem *473*
Gross Anatomy of the Cerebellum *478*
Gross Anatomy of the Cerebral Hemispheres *482*
An Introduction to Some Structures within the Cerebral Hemispheres *490*

Important Functional Areas of the Cerebral Cortex *492*
White Matter of Cerebral Hemispheres *496*

19. Tracts of Spinal Cord and Brainstem. Cerebellar Connections 499

Tracts of Spinal Cord and Brainstem 499
Descending Tracts Ending in the Spinal Cord *499*
Descending Tracts Ending in the Brainstem *504*
Ascending Tracts *505*
Connections of the Cerebellum 510
Cerebellar Peduncles *511*

20. Internal Structure of Brainstem 517

The Medulla *517*
The Pons *520*
The Midbrain *521*

21. Diencephalon and Basal Ganglia, Olfactory Region and Limbic System 524

The Diencephalon 525
The Thalamus *525*
The Hypothalamus *528*
The Metathalamus *536*
The Epithalamus *537*
The Subthalamic Region *538*
The Basal Ganglia 538
The Olfactory Region and Limbic System 541
The Olfactory Region *541*
The Olfactory Pathway *542*
The Limbic System *543*

22. Internal Capsule. Commissures of the Brain 549

The Internal Capsule *549*
Commissures of the Brain *551*

23. Pathways for Special Senses 554

Visual Pathway *554*
Pathways for Taste *559*

24. The Ventricles of the Brain and Cerebrospinal Fluid 561

The Lateral Ventricles *561*
The Third Ventricle *564*
The Fourth Ventricle *567*
The Cerebrospinal Fluid *572*

25. Blood Supply of the Brain 574

Arteries that Supply the Brain *574*
Arterial Supply of the Cerebral Cortex *580*

Arteries Supplying Interior of the Cerebral Hemisphere *582*
Venous Drainage of the Brain *587*

26. Some Clinical Correlations of the Central Nervous System 591

Disorders of Motor Function *592*
Disorders of Equilibrium *593*
Sensory Disorders *595*
Spinal Reflexes *596*
Reflexes Related to the Eyeball *597*
Some Investigative Procedures Used for Neurological Diagnosis *598*

Index *601*

CHAPTER

3

Scalp, Face, Parotid Region and Lacrimal Apparatus

JAYPEE BROTHERS

In this chapter we will consider some structures that are placed at a relatively superficial level in the head. The regions to be considered will include the scalp, the face and parotid region, and some parts of the lacrimal apparatus. References will be made to blood vessels, lymphatics and nerves to be seen in the region but these will be considered in detail (and in proper continuity) in Chapters 8, 9 and 13.

Many of the structures in these regions have been briefly reviewed in Chapter 2. Beginners must read Chapter 2 before reading this chapter.

THE SCALP

The term scalp is applied to the soft tissues covering the vault of the skull. This region extends anteriorly up to the eyebrows (and, therefore, includes the forehead), posteriorly up to the superior nuchal lines, and laterally up to the superior temporal lines.

Layers of the Scalp

These are shown in Fig. 1.3B and are as follows.

1. The most superficial layer is ***skin***. Being hairy it contains numerous sebaceous glands. The skin is closely adherent to underlying tissues.
2. The ***superficial fascia*** is represented by dense connective tissue that is firmly united to the skin and to the underlying epicranial aponeurosis. Fibrous strands divide the superficial fascia into numerous small pockets.
3. The third layer of the scalp is partly muscular and partly fibrous. It corresponds to deep fascia. The greater part of this layer is formed by the ***epicranial aponeurosis*** (or galea aponeurotica). The muscular part is formed by a muscle called the ***occipito frontalis*** (see below).
4. The three layers of the scalp described above are firmly united to one another. All the three layers move together over the fourth layer which is made up of ***loose areolar tissue***. The extent of the layer of loose

connective tissue corresponds to the extent of the scalp itself. This layer is traversed by emissary veins passing from the scalp to intracranial venous sinuses.

5. The deepest layer of the scalp is the ***pericranium*** (which is the periosteum over the bones of the vault of the skull). It is important to note that at the edge of each bone of the skull the pericranium is fixed because it is attached to sutural ligaments that are present in sutures of the skull.

Occipitofrontalis

The occipito-frontalis covers the upper curved roof of the skull. (Figs. 1.2, 1.3) It consists of a posterior ***occipital part*** (or ***occipitalis***), and an anterior ***frontal part*** (or ***frontalis***). Each of these is divided into a right half and a left half. These four parts are continuous with each other through the epicranial aponeurosis.

Each ***occipital part*** arises from the occipital bone (lateral two thirds of the highest nuchal line). Laterally, the line of origin extends on to the mastoid part of the temporal bone. The fibres of the occipitalis run upwards and forwards to end in the epicranial aponeurosis. The occipital parts of the two sides are separated from each other by a part of the epicranial aponeurosis that gains attachment to the external occipital protuberance, and to the medial parts of the highest nuchal lines.

The ***frontal parts*** are attached posteriorly to the epicranial aponeurosis. Anteriorly, the fibres have no bony attachment. The medial-most fibres merge with the procerus, which is a small muscle overlying the upper part of the nose (Fig. 1.1). More laterally, the deeper fibres merge with the corrugator supercilii, which is a small muscle underlying the medial part of the eyebrow. The majority of the fibres of the frontalis merge with the upper edge of the orbicularis oculi. (The procerus, the corrugator supercilii and the orbicularis oculi are considered later in this chapter under muscles of the face).

Nerve Supply

The occipital part is supplied by the posterior auricular branch of the facial nerve, and the frontal part by the temporal branches of the same nerve.

Actions

Acting alternatively, the frontal and occipital parts can move the scalp forwards and backwards over the vault of the skull. The frontal parts raise the eyebrows (as in surprise): acting from below they produce transverse wrinkles of the forehead.

Blood Vessels and Nerves of the Scalp

The ***arteries*** that supply the scalp are seen in Fig. 1.3. These are the supratrochlear and supraorbital branches of the ophthalmic artery in front,

JAYPEE BROTHERS

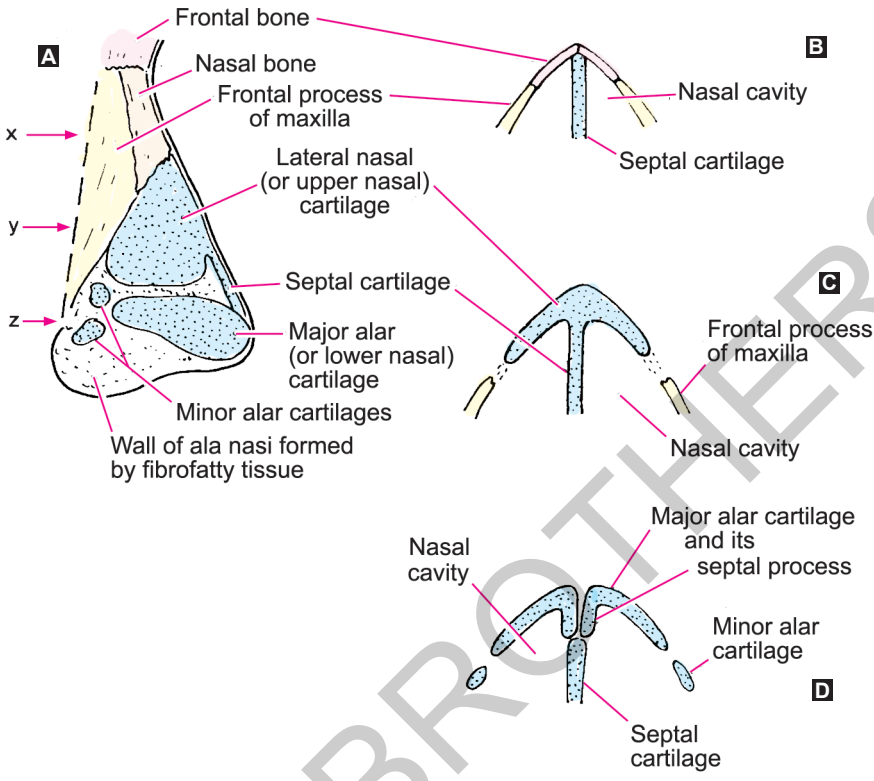

Fig. 3.1 A. Structures forming the skeleton of the external nose (lateral view). B, C, D. Transverse sections through the nose at levels x, y and z shown in Fig. A.

the anterior and posterior branches of the superficial temporal artery laterally, and the occipital artery posteriorly. The ***veins*** of the scalp accompany the corresponding arteries.

The ***nerves*** of the scalp may be divided into motor nerves that supply the occipito frontalis and sensory nerves that supply skin and other tissues of the scalp (Figs. 1.2 to 1.4).

As stated above the motor nerves are the temporal and posterior auricular branches of the facial nerve.

The sensory nerves are as follows:

1. In front there are the supratrochlear and supraorbital nerves, which are branches of the frontal nerve (which is itself derived from the ophthalmic division of the trigeminal nerve).
2. Laterally there are the zygomatico-temporal, the auriculo-temporal, and great auricular nerves.
3. Posteriorly, there are the greater occipital, lesser occipital, and third occipital nerves.

The ***lymphatic drainage*** of the scalp is described in Chapter 3.

Important ***clinical correlations*** are discussed in Chapter 5.

JAYPEE BROTHERS

THE FACE

A brief introduction to the layout of structures in the face has been given on page 734. Here we will consider some features seen on the surface of the face, and the muscles of the face. The blood vessels and nerves of the region will be considered along with those of the parotid region.

It is common knowledge that when we think of the face we visualize the forehead, the eyes, the nose, the mouth and the cheeks. The forehead is really a part of the scalp. We will begin by noting some facts about the nose, the mouth the cheeks and the eyes.

THE EXTERNAL NOSE

The prominence on the face that the layman refers to as the nose is strictly speaking the external nose. (The nasal cavities constitute the internal nose.) Certain descriptive terms applied to parts of the external nose are as follows. The upper end (where the nose becomes continuous with the forehead) is called the ***angle.*** The ridge-like free border passing downwards from the angle is called the ***dorsum nasi.*** The dorsum nasi ends below in a rounded prominence which forms the tip, or ***apex***, of the nose. On either side the external nose has lateral surfaces that are continuous behind with the cheeks. The lowest parts of the lateral surfaces are rounded and mobile: these are called the ***alae nasi.*** The upper parts of both lateral surfaces (just below the angle) together form the ***bridge*** of the nose.

The shape of the nose is maintained by the presence of a skeleton made up partly of bone and partly of cartilage. Some details of the elements forming the skeleton are shown in Fig. 3.1.

The ***external nares*** (or anterior nares) are the external openings of the nasal cavities. They are located on the inferior aspect of the nose. They are bounded laterally by the alae nasi and medially by the lowest part of the nasal septum.

LIPS AND CHEEKS

Some facts worth noting about the lips and cheeks are as follows.

The ***lips***, upper and lower, are lined on the outside by skin and on the inside by mucous membrane. The junction between the two forms the 'edge' of each lip. The substance of the lip is formed by the orbicularis oris muscle and by numerous smaller muscles that blend with it (See below under muscles of face). The points, on either side, where the upper and lower lips meet are called the ***angles of the mouth***. The deep surface of each lip is connected to the gum by a median fold of mucous membrane called the ***frenulum***.

The ***cheeks*** are, like the lips, made up of an outer layer of skin, an inner layer of mucous membrane and an intervening layer of muscle, connective tissue and fat. The muscle layer is formed chiefly by the buccinator (Fig. 1.5). The fat is specially prominent in infants and is responsible for the rounded appearance of the cheeks. Numerous glands are present in relationship to the lips and cheeks. They open into the vestibule of the mouth.

JAYPEE BROTHERS

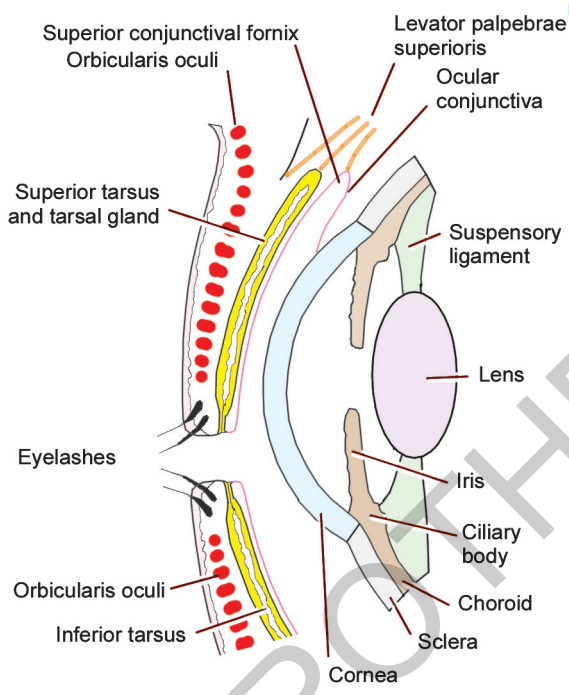

Fig. 3.2 Schematic sagittal section through the eyelids and anterior part of the eyeball.

THE EYELIDS AND CONJUNCTIVA

The basic parts of the eyeball are probably already known to you. They will be studied in detail later. The part of the eye seen on the face consists of a part that is white, and a circular area in front that looks dark. The 'white of the eye' is formed by the outermost coat of the eyeball which is called the ***sclera***. The sclera is lined by a thin transparent membrane the ***ocular conjunctiva***. The circular dark part in the centre is the ***iris*** which we see through a transparent disc like structure the ***cornea*** which covers it. At the centre of the iris there is an aperture called the ***pupil***. The pupil appears black because the interior of the eye (which we see through the pupil) is dark. When we view the 'eyes' we see only a small part of the eyeball in the interval between the upper and lower eyelids. This interval is called the ***palpebral fissure*** (Fig. 3.3).

The upper and lower eyelids (or palpebrae) protect the eyeball, specially the cornea, from injury in several ways.

Firstly, they provide protection against mechanical injury by reflex closure when any object suddenly approaches the eye. The same happens when the cornea is touched (***corneal reflex***).

Secondly, they help to keep the cornea moist as follows: When the eyelids are closed (i.e., when the upper and lower eyelids meet) a capillary space separates the posterior surfaces of the lids from the cornea and the anterior part of the

JAYPEE BROTHERS

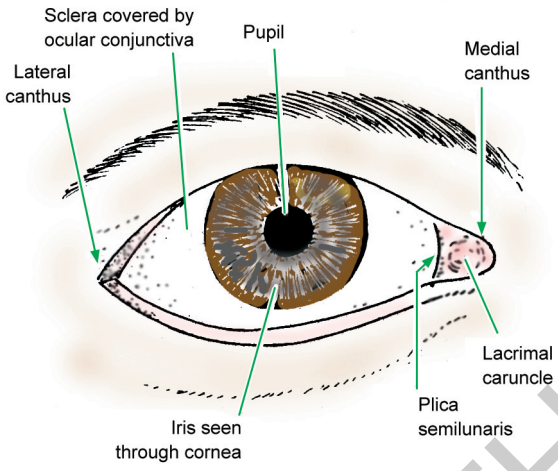

Fig. 3.3 Some features of the eye as seen on the face. The eyelashes are omitted. The interval between the two eyelids is the palpebral fissure.

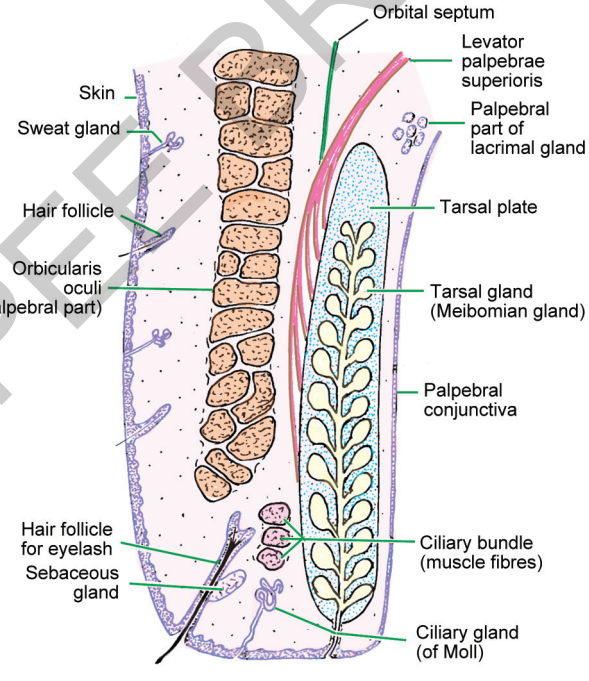

Fig. 3.4 Schematic sagittal section through the upper eyelid.

JAYPEE BROTHERS

sclera. This space is the ***conjunctival sac*** (Fig. 3.2). It contains a thin film of lacrimal fluid, which keeps the cornea and conjunctiva moist.

With the 'eyes' open the cornea has a tendency to dry up, but this is prevented by periodic, unconscious closure of the lids (blinking). Every time this happens the film of lacrimal fluid over the cornea is replenished. Thirdly, lids protect the eyes from sudden exposure to bright light by reflex closure. In bright light partial closure of the lids may assist the pupils in regulating the light falling on the retina.

We have seen above that the space separating the upper and lower eyelids is called the palpebral fissure. The medial and lateral ends of the fissure are called the ***angles*** of the eye. Each angle is also called the ***canthus*** (Fig. 3.3). The lateral canthus is in contact with the sclera. At the medial canthus the upper and lower lids are separated by a triangular interval called the ***lacus lacrimalis***. In the floor of this area there is a rounded pink elevation called the ***lacrimal caruncle***. Just lateral to the caruncle there is a fold of conjunctiva called the ***plica semilunaris*** which represents the third eyelid present in some lower animals (in whom it is called the ***nictitating membrane).*** Each eyelid has a free edge to which eyelashes are attached. Just lateral to the lacrimal caruncle each lid margin has a slight elevation called the ***lacrimal papilla***. On the summit of the papilla there is a small aperture called the ***lacrimal punctum***. It is important to note that the punctum is normally in direct contact with the ocular conjunctiva.

The basic structure of an eyelid is shown in Fig. 3.4. The various structures forming the eyelid are as follows:

1. Anteriorly there is a layer of true skin with which a few small hair and sweat glands are associated. The skin is thin.
2. Deep to the skin there is a layer of delicate connective tissue, which normally does not contain fat.
3. Considerable thickness of the lid is formed by fasciculi of the palpebral part of the orbicularis oculi muscle (described below).
4. The 'skeleton' of each eyelid is formed by a mass of fibrous tissue called the ***tarsus***, or ***tarsal plate***. The shape of the tarsi corresponds to that of the lids: they are semi-oval having a straight edge directed towards the margin of the lid and a convex margin directed towards the orbital margin (Fig. 3.5). The 'height' of the tarsus is greatest midway between the medial and lateral ends of the tarsus. It is about 10 mm in the upper lid and about 5 mm in the lower lid. The tarsi narrow down laterally and medially and become continuous with the ***lateral and medial palpebral ligaments*** through which they are attached to the walls of the orbit, just inside the orbital margin. The medial palpebral ligament is better developed than the lateral ligament. It gains attachment to the maxilla (lacrimal crest and adjoining part of frontal process). The lateral ligament is attached to the zygomatic bone. The upper and lower tarsi are attached to the corresponding part of the orbital margin by a membrane called the **orbital septum.**
5. On the deep surface of the tarsi there are a series of vertical grooves in which ***tarsal glands*** (or ***Meibomian glands***) are placed (Fig. 3.4). These glands may occasionally be embedded within the tarsal plates. Each gland has a duct that opens on the free margin of the lid. The tarsal glands are modified sebaceous glands. They produce an oily secretion a thin film of which spreads over the lacrimal fluid and delays its evaporation.

JAYPEE BROTHERS

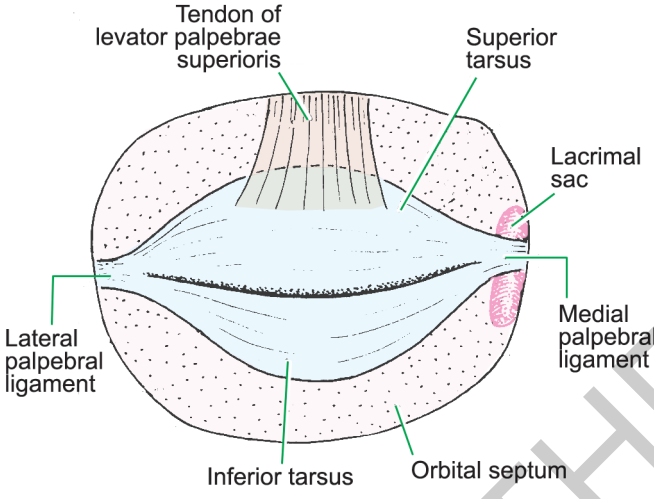

Fig. 3.5 Scheme to show the tarsal plate and the palpebral ligament as seen from the front.

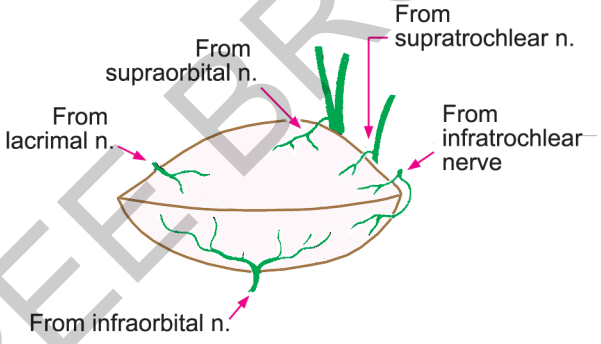

Fig. 3.6 Nerves supplying the eyelids.

In addition to tarsal glands, modified sweat glands called ***ciliary glands***, are present in the lids near their free edge.

6. The inner surface of the eyelid is lined by ***palpebral conjunctiva***. This is a thin transparent membrane continuous with the ***ocular conjunctiva*** lining the anterior part of the sclera. The sharp line of reflection (of the conjunctiva) from the lid to the sclera is called the ***conjunctival fornix*** (superior or inferior) (Fig. 3.2).

The levator palpebrae superioris extends into the upper eyelid anterior to the tarsal plate to gain insertion into it. This muscle elevates the upper eyelid, in opening the palpebral fissure. Some fibres of the muscle, which are inserted into the superior conjunctival fornix, pull the fornix up during this movement (Figs. 3.2, 3.4). The palpebral fissure is closed by contraction of the orbicularis oculi.

JAYPEE BROTHERS

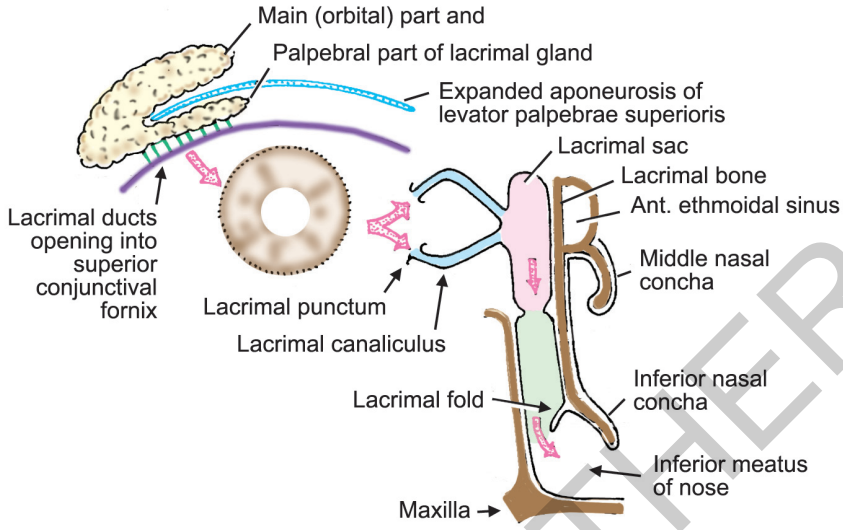

Fig. 3.7 Scheme to show the parts of the lacrimal apparatus. The pink arrows indicate the direction of flow of lacrimal fluid.

Blood Vessels of the Eyelids

The eyelids are supplied by the medial palpebral branches of the ophthalmic artery and by the lateral palpebral branches of the lacrimal artery.

Nerves Supplying the Eyelids

The upper eyelid receives branches from the lacrimal, supraorbital, supratrochlear and infratrochlear nerves (all branches of the ophthalmic division of the trigeminal nerve). The lower eyelid receives branches from the infraorbital and infratrochlear nerves (Fig. 3.6).

THE LACRIMAL APPARATUS

We have seen that the cornea is kept moist by the lacrimal fluid. The lacrimal apparatus consists of the organs concerned with the secretion and drainage of this fluid. Lacrimal fluid is secreted by the ***lacrimal gland*** and is poured into the conjunctival sac at the superior conjunctival fornix. The fluid passes downwards and medially to reach the lacus lacrimalis. Here it passes through the lacrimal puncta into narrow tubes called the ***lacrimal canaliculi***. These canaliculi open into the ***lacrimal sac.*** The lacrimal sac drains into the inferior meatus of the nasal cavity through the ***nasolacrimal duct***.

The lacrimal gland is seen in Figs. 1.20A,B. It will be described in detail when we study the orbit. For the time being note that the lacrimal gland lies in relation to the upper lateral part of the wall of the orbit. An extension of the gland, that passes into the upper eyelid, is called its ***palpebral part*** (Figs. 3.4, 3.7). The lacrimal gland drains into the superior conjunctival fornix through about twelve ducts.

JAYPEE BROTHERS

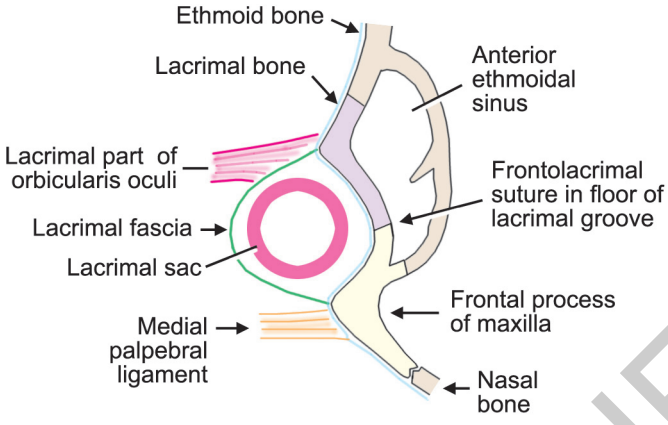

Fig. 3.8 Transverse section through lacrimal sac and some surrounding structures.

The other parts of the lacrimal apparatus are described below. To understand some of the details you will need to know some features of the bony orbit and the bony nasal cavity.

The Lacrimal Canaliculi

There are two lacrimal canaliculi, upper and lower, in relation to each eye. Each canaliculus is about 10 mm long. It is a narrow tube that starts at the lacrimal punctum and ends by joining the lacrimal sac. Note the direction of each canaliculus as shown in Fig. 3.7.

The Lacrimal Sac

The lacrimal sac lies in the lacrimal groove on the medial wall of the orbit (Figs. 3.5, 3.7).

The floor of this groove is formed by the lacrimal bone (posteriorly) and the frontal process of the maxilla (anteriorly). The groove is bounded anteriorly by the anterior lacrimal crest, and behind by the crest of the lacrimal bone.

The lacrimal sac is blind at its upper end. Inferiorly, the sac is continuous with the nasolacrimal duct. Laterally, it receives the lacrimal canaliculi near its upper end.

Some relationship of the lacrimal sac can be seen in Fig. 3.8 which is a schematic transverse section across the sac. Note the bones forming the floor of the lacrimal groove. Medially the sac is separated by a thin partition of bone from the anterior ethmoidal sinus; and lower down from the middle meatus of the nasal cavity (Fig. 3.7). Laterally the lacrimal sac is covered by lacrimal fascia which is attached to the anterior and posterior margins of the lacrimal groove. The medial palpebral ligament is placed in front of the lacrimal sac and is separated from it only by the

JAYPEE BROTHERS

lacrimal fascia (Figs. 3.4, 3.7). The lacrimal part of the orbicularis oculi muscle (see above) takes origin partly from the lacrimal fascia. Every time the muscle contracts there is pull on this fascia causing the sac to expand and helping to suck lacrimal fluid into the sac.

The Nasolacrimal Duct

The nasolacrimal duct (Fig. 3.6) is a tube about 18 mm long. It may be regarded as the downward continuation of the lacrimal sac. It is closely related to the lateral wall of the nasal cavity, and opens below into the inferior meatus of the nose. The wall of the nasolacrimal duct is made up of bone lined by mucous membrane.

The lower end of the nasolacrimal duct is separated from the inferior meatus of the nose by a fold of mucous membrane called the ***lacrimal fold***.

The bones helping to form the wall of the duct are the maxilla (laterally); and the lacrimal bone and the inferior nasal concha (medially).

MUSCLES OF THE FACE

Deep to the skin of the face there are several muscles that produce varying facial expressions (Figs. 1.1, 1.2). Many of them converge upon the mouth. These are also concerned with speech and with feeding.

The ***orbicularis oculi*** is made up of fasciculi that run concentrically round the palpebral aperture (This muscle is described in detail below). Its upper margin merges with the fibres of the ***frontalis*** (described above under the scalp). The oral aperture is also surrounded by concentrically arranged muscle bundles that constitute the ***orbicularis oris*** (This muscle is described in detail below). Underlying the eyebrows there are two muscles. The ***corrugator supercilii*** runs obliquely deep to the frontalis while the ***depressor supercilii*** consists of some muscle fibres continuous with the upper medial part of the orbicularis oculi. Over the upper part of the nose we have some vertically running fibres which constitute the ***procerus***. Lower down on the nose we have the ***nasalis*** which has a transverse (constrictor) and an alar (dilator) part. Just below the nasal septum we have the ***depressor septi***. As many as nine muscles converge on the orbicularis oris. The ***levator labii superioris alaeque nasi*** arises from the frontal process of the maxilla (Fig. 1.1). Below it divides into two slips, one for the ala of the nose, and the other to the upper lip.

As many as nine muscles converge on the orbicularis oris. The ***levator labii superioris alaeque nasi*** arises from the frontal process of the maxilla (Fig. 1.1). Below it divides into two slips, one for the ala of the nose, and the other to the upper lip. The ***levator labii superioris*** arises from the lower margin of the orbit (partly from the maxilla and partly from the zygomatic bone) and merges below with the orbicularis oris. The ***levator anguli oris*** lies deep to the foregoing muscle. It arises from the maxilla below the infraorbital foramen and

JAYPEE BROTHERS

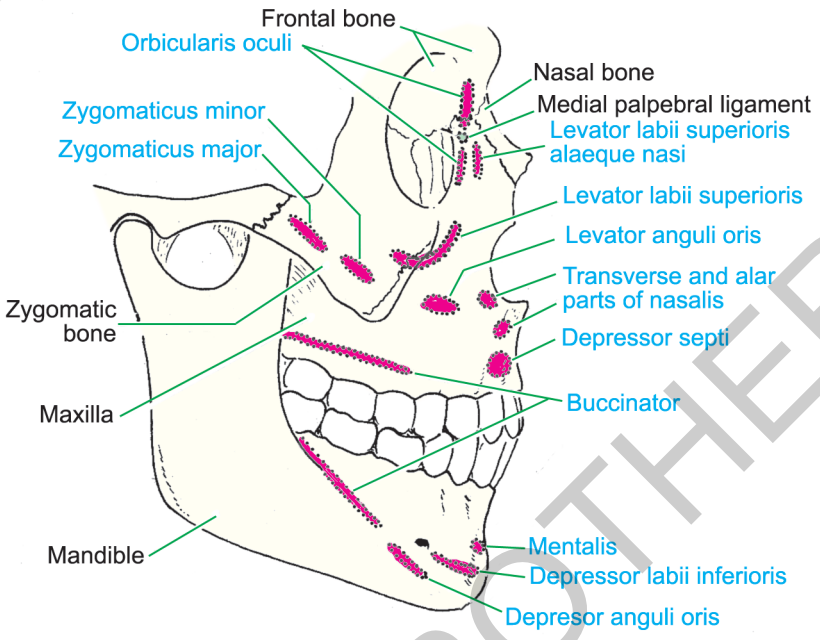

Fig. 3.9 Facial skeleton seen from the side to show some muscle attachments.

is inserted into the angle of the mouth. The ***zygomaticus major and minor*** arise from the zygomatic bone and converge on the angle of the mouth. The ***risorius*** arises from fascia overlying the parotid gland and is inserted into the angle of the mouth. It is continuous below with the ***platysma*** which extends into the neck (Fig. 1.2). The ***depressor anguli oris*** arises from the mandible and reaches the angle of the mouth. The ***depressor labii inferioris*** also arises from the mandible deep to the foregoing muscle and merges with the lower part of the orbicularis oris. The ***mentalis*** arises from the mandible just below the incisor teeth: its fibres run downwards to gain insertion into the skin of the chin.

All the muscles of the face are supplied by the facial nerve. They are derivatives of the second pharyngeal arch. The actions of most of them are indicated by their names. The corrugator supercilii produces vertical wrinkles on the forehead. The procerus produces transverse wrinkles on the bridge of the nose. The depressor septi assists the alar part of the nasalis in widening the external nares. The zygomaticus minor elevates the upper lip while the zygomaticus major draws it upwards and laterally as in laughing.

The mentalis produces wrinkles on the chin. The risorius retracts the angle of the mouth.

The areas of bony attachment of some of the muscles considered above are shown in Figs. 1.1 and 3.9.

Some further details of the orbicularis oris, the orbicularis oculi, and the buccinator are given below.

JAYPEE BROTHERS

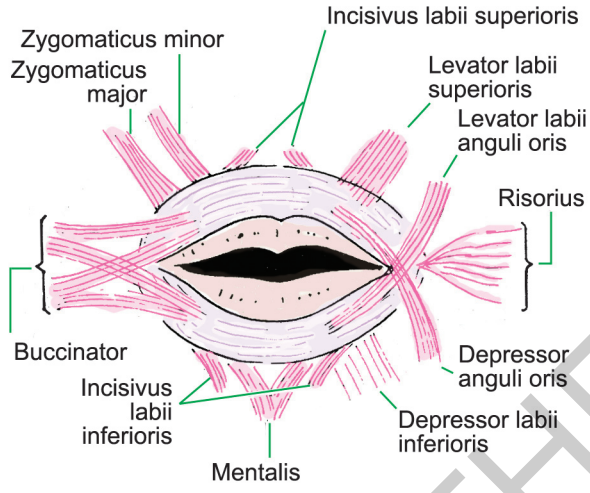

Fig. 3.10 The orbicularis oris and its relationship to vaious muscles attached to the lips.

Orbicularis Oris

The fibres of the orbicularis oris surround the opening of the mouth. They make up the muscular basis of the lips. The muscle contains three types of fibres.

a. Many of the fibres are derived from other facial muscles as shown in Fig. 3.10. At the angle of the mouth many of the fibres cross, those from above entering the lower lip, and vice versa. The middle fibres of the buccinator cross in this manner while the upper and lower fibres go into the corresponding lips.
b. The intrinsic fibres of the lips run obliquely from the skin to the mucous membrane.
c. Some fibres connect the orbicularis oris to the maxilla (opposite the lateral incisors) These fibres constitute the incisivus labii superioris. Similar fibres in the lower lip constitute the incisivus labii inferioris; they arise from the mandible just below the incisor teeth and run laterally to the angle of the mouth.

The orbicularis oris is supplied by the lower buccal and mandibular marginal branches of facial nerve. The orbicularis oris closes the lips. It is responsible for complex movements of the lips associated with speech, eating and drinking.

Orbicularis Oculi

The orbicularis oculi consists of muscle fasciculi arranged concentrically around the palpebral fissure (Fig. 1.1). The innermost rings lie within the eyelids and form the ***palpebral part*** of the muscle (Fig. 3.4). Succeeding rings surround the margin of the orbit and extend on to the temple and cheek: they constitute the ***orbital part.*** Some fibres closely related to the lacrimal sac form the ***lacrimal part.***

The orbital part consists of fasciculi that are attached to the nasal part of the frontal bone (Fig. 3.11). From here they wind above, lateral to, and then below the orbital margin to be attached to the frontal process of the maxilla. Some fibres are also attached to the medial palpebral ligament which intervenes between the two

JAYPEE BROTHERS

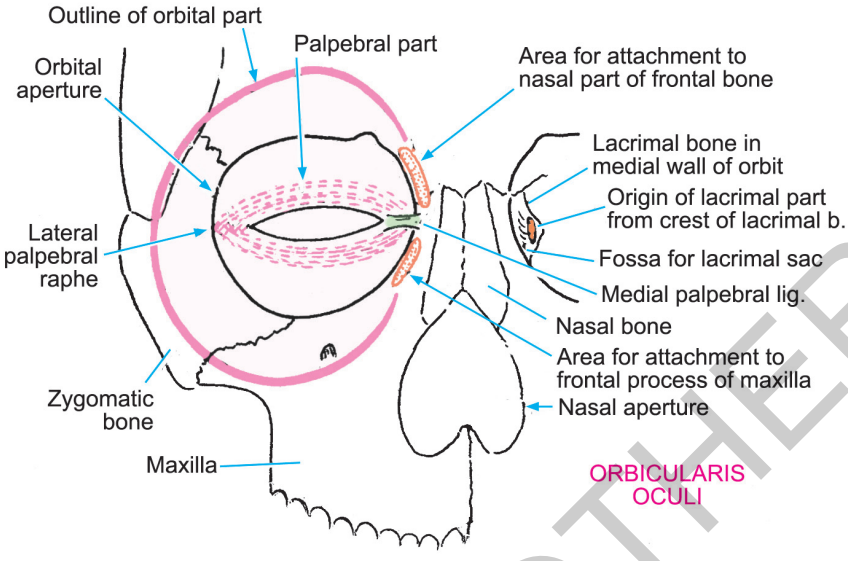

Fig. 3.11 Scheme to show the attachments of the orbicularis oculi muscle.

body attachments. The fibres of the palpebral part arise from the medial palpebral ligament (Fig. 3.11). They pass laterally through the eyelids; the upper and lower fibres then decussate to form the lateral palpebral raphe (Figs. 3.11, 3.12C). A group of fibres close to the margins of the lids form the ciliary bundle.

The lacrimal part of the muscle is attached to the lacrimal bone behind the lacrimal sac (3.12C). Some fibres are also attached to fascia covering the sac. The fibres pass laterally to join the palpebral part.

The orbicularis oculi muscle closes the palpebral fissure. The lacrimal part draws the eyelids medially. It dilates the lacrimal sac thus helping to suck lacrimal fluid into it.

The muscle is supplied by the temporal and zygomatic branches of the facial nerve.

Buccinator

Origin: The buccinator has a 'C' shaped line of origin (Fig. 3.13) from :

a. the outer aspect of the maxilla just above the three molar teeth;
b. a tendinous arch connecting the maxillary tuberosity to the pterygoid hamulus;
c. the pterygo-mandibular raphe (see below); and
d. the outer surface of the body of the mandible just below the molar teeth. At its posterior end the line of origin from the mandible passes behind the 3rd molar tooth to reach the medial side.

The pterygomandibular raphe is made up of interlacing tendinous fibres. It is attached above to the pterygoid hamulus (at the lower end of the medial pterygoid plate), and below to the posterior end of the mylohyoid line of the mandible. The raphe gives attachment anteriorly to fibres of the buccinator, and posteriorly to fibres of the superior constrictor of the pharynx.

JAYPEE BROTHERS

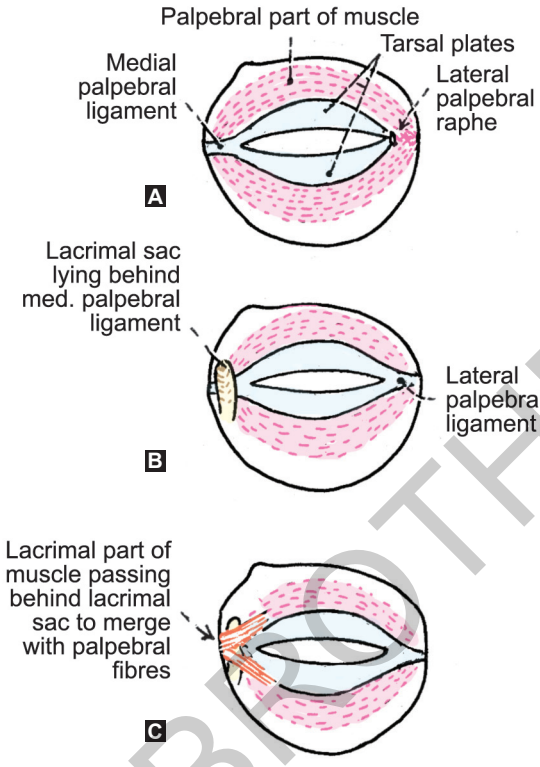

Figs. 3.12A to C Scheme to show the relationship of the lacrimal part of the orbicularis oculi to the lacrimal sac and to the medial palpebral ligament as seen from behind. A. Tarsal plates, medial palpebral ligament, and palpebral part of orbicularis oculi. The lateral palpebral ligament has been cut away to show the lateral palpebral raphe. B. Lacrimal sac lying behind the medial palpebral ligament. The lateral palpebral ligament is seen behind the lateral palpebral raphe. C. Lacrimal part of orbicularis oculi lying behind the lacrimal sac and passing laterally to blend with the palpebral part.

Insertion: The fibres of the buccinator run forwards where they are continuous with the orbicularis oris (Fig. 3.10).

Nerve Supply: The muscle is supplied by the lower buccal branches of the facial nerve.

Actions: The buccinator aids mastication by pushing food between the teeth. The muscle increases air pressure within the mouth as in blowing. (Laterally, the word buccinator means one who blows a trumpet).

Important Relations: The muscle is lined on the inside by the mucous membrane of the mouth. It is related on its outer aspect to the parotid duct which pierces it opposite the third upper molar tooth; to the superficial muscles inserted into the angle of the mouth; to the facial artery and vein; and to branches of the facial and buccal nerves (Figs. 1.2, 1.4 to 1.6).

JAYPEE BROTHERS

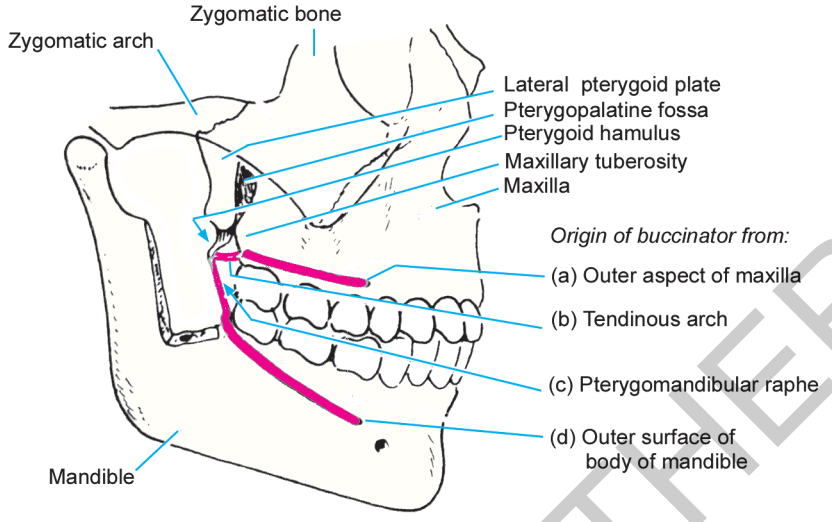

Fig. 3.13 Origin of the buccinator muscle. For insertion see Fig. 3.10.

PAROTID GLAND

The parotid gland lies on the lateral side of the face in a depression below the external acoustic meatus, behind the mandible, and in front of the sternocleidomastoid muscle (Fig. 1.2). It is roughly triangular on cross section. It has a lateral or superficial surface, an anteromedial surface, and a posteromedial surface (Fig. 3.14). At its upper end it has a small superior surface. Its lower end is rounded and is called the apex.

The superficial surface of the parotid gland extends upwards to the zygomatic arch. Its lower end (apex) lies behind and below the angle of the mandible. Anteriorly, it is prolonged forwards superficial to the masseter. Posteriorly, it overlaps the anterior margin of the sternocleidomastoid (Fig. 1.2). This surface is covered by skin and fascia. Lymph nodes of the superficial parotid group lie over it.

The superior surface of the parotid is concave and fits under the external acoustic meatus. It is also in contact with the posterior surface of the temporomandibular joint (Fig. 3.15).

The anteromedial surface is in contact with the posterior border of the ramus of the mandible (Fig. 3.14). It will be recalled that lateral to the ramus there is the masseter muscle, and deep to it there is the medial pterygoid. The anteromedial surface is related to all these structures.

The posteromedial surface is in contact, in its upper part with the mastoid process, and lower down with the sternocleidomastoid (superficially) and the posterior belly of the digastric (deep). The deepest part of the gland reaches the styloid process and the structures attached to it. These separate the gland from the internal carotid artery and the internal jugular vein (Figs. 3.14, 3.15).

JAYPEE BROTHERS

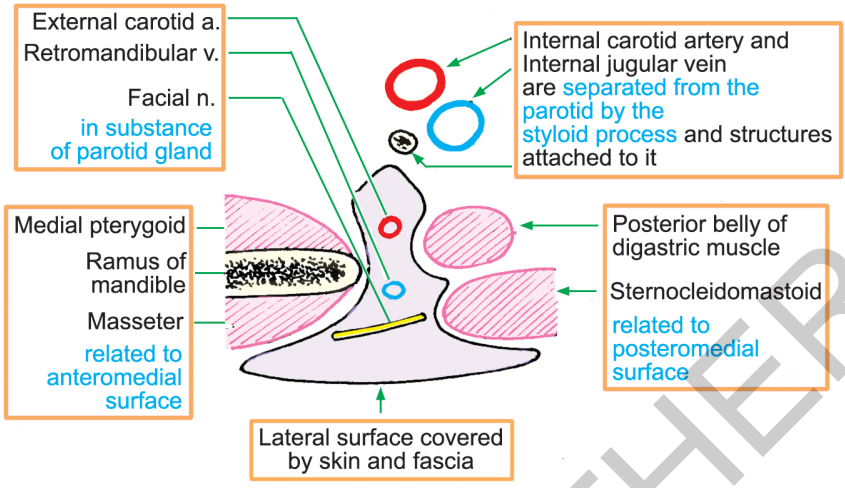

Fig. 3.14 Schematic transverse section through parotid gland to show its relations.

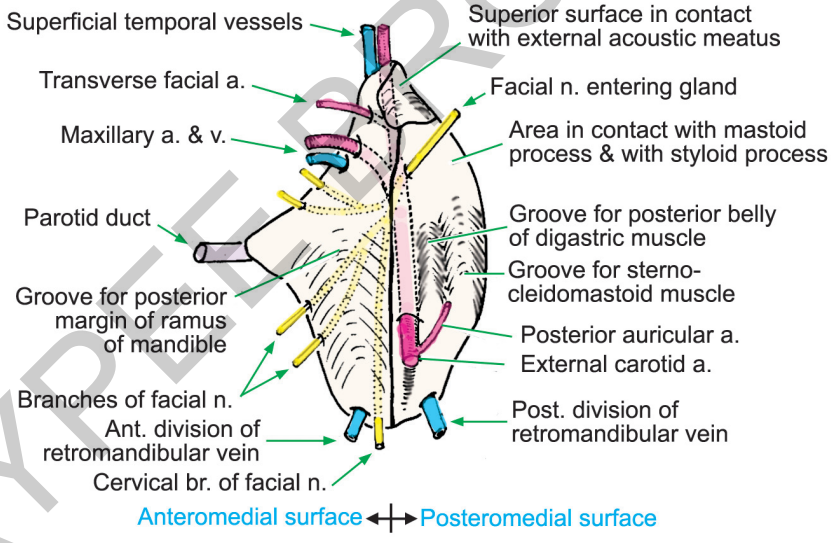

Fig. 3.15 Schematic view of parotid gland as seen from the medial side. Note the structures entering or leaving the gland.

The parotid gland is related to several nerves and vessels as follows.

1. The external carotid artery enters the lower part of the posteromedial surface (Fig. 3.13). Ascending within the substance of the gland it divides into its terminal branches (superficial temporal and maxillary) which emerge on the anteromedial surface of the gland. The posterior auricular branch of the external carotid artery arises just before the latter enters the gland. Sometimes it arises within the

JAYPEE BROTHERS

substance of the gland and emerges on the posteromedial surface. The transverse facial branch of the superficial temporal artery may arise within the substance of the gland.
2. The retromandibular vein lies in the substance of the parotid superficial to the external carotid artery (Fig. 1.4) (See below).
3. The trunk of the facial nerve enters the upper part of the posteromedial surface. Within the gland it divides into its terminal branches which emerge from the anteromedial surface near its anterior margin (Figs. 1.4, 3.15). The cervical branch of the nerve emerges from the lower end of the gland (Fig. 1.2). The facial nerve is often described as dividing the parotid gland into superficial and deep parts.
4. The auriculotemporal nerve passes laterally between the neck of the mandible and the superior surface of the gland. It gives branches to the gland. (The nerve is seen in the region of the parotid gland in Fig. 1.5. The gland has been removed).
5. The anterior (facial) branch of the great auricular nerve passes forwards over the superficial surface of the gland and supplies the overlying skin.

Secretions of the parotid gland are collected by a system of ducts which unite to form the ***parotid duct.*** This duct emerges at the anterior margin of the gland and runs forwards across the masseter (Fig. 1.2). At the anterior border of the masseter the duct turns medially and pierces the buccinator. The terminal part of the duct runs forwards deep to the mucous membrane of the cheek. It opens into the vestibule of the mouth opposite the crown of the upper second molar tooth.

A detached part of the parotid gland present just above the parotid duct is called the ***accessory part*** of the parotid gland (Fig. 1.2).

The parotid gland is enclosed in a fibrous capsule derived from the deep cervical fascia as follows. At the lower end of the gland the investing layer of the deep cervical fascia splits into two layers. One layer ascends superficial to the parotid gland to reach the zygomatic arch to which it is attached. This fascia is thick and strong and is called the ***parotid fascia.*** The other layer ascends deep to the gland. Part of this layer forms a thickened band extending from the posterior margin of the ramus of the mandible to the styloid process. This band is the ***stylomandibular ligament.*** It separates the parotid gland from the submandibular gland.

The parotid gland is supplied by small branches of the external carotid artery or of its terminal divisions. The veins drain into the retromandibular and external jugular veins. The lymph vessels from the gland drain into the deep cervical nodes after passing through the superficial parotid nodes (lying on the lateral surface of the gland) and the deep parotid nodes (lying in the substance of the gland).

Secretomotor nerves reach the gland through branches from the auriculotemporal nerve. The gland also receives sympathetic nerves.

VESSELS OF THE FACE AND PAROTID REGION

Arteries

The arteries to be seen in the face are the facial artery and the transverse facial branch of the superficial temporal artery (Figs. 1.2, 1.4). The arteries to be seen in relation to the parotid gland have been mentioned above.

JAYPEE BROTHERS

Facial artery

The facial artery runs part of its course in the neck, and in the submandibular region. It then enters the face by passing round the lower border of the body of the mandible just in front of the masseter muscle. it then runs upwards and forwards across the body of the mandible and the buccinator to reach the angle of the mouth. Finally it ascends along the side of the nose to reach the medial angle of the eye. In the face the artery gives off branches to the lower lip (inferior labial artery), the upper lip (superior labial artery), and to the nose (lateral nasal artery). The terminal part of the facial artery is called the angular artery.

The ***superficial temporal artery*** arises from the external carotid artery within the parotid gland. It runs upwards behind the temporomandibular joint and ends by dividing into frontal and parietal branches that supply the scalp. It also gives off the ***transverse facial artery*** which runs forwards across the masseter muscle.

We have seen that the external carotid artery runs through the parotid gland and gives off a number of branches in the region.

Veins

The veins to be seen in the face and parotid region are the facial vein, the superficial temporal vein, the retromandibular vein.

The retromandibular vein is formed within the upper part of the parotid gland by the union of the superficial temporal and maxillary veins. Its lower end divides, within the gland, into anterior and posterior divisions which emerge from the gland near its lower end. The posterior division, which is the main continuation of the retromandibular vein, joins the posterior auricular vein to form the external jugular vein. The anterior division joins the facial vein to form the common facial vein.

The facial vein runs downwards and backwards just behind the facial artery, and receives tributaries corresponding to branches of the artery. It end by joining the anterior division of the retromandibular vein to form the common facial vein. The common facial vein ends in the internal jugular vein.

Lymphatics

A brief introduction to the lymph nodes of the head and neck has been given on page 45.

The lymphatics of the face drain into the superficial and deep parotid lymph nodes, into the submental nodes, and also into the submandibular lymph nodes. As mentioned above the parotid gland drains into the superficial and deep parotid nodes.

NERVES OF THE FACE

The nerves seen on the face are motor and sensory. The motor nerves are terminal branches of the facial nerve. We have seen that after emerging from

JAYPEE BROTHERS

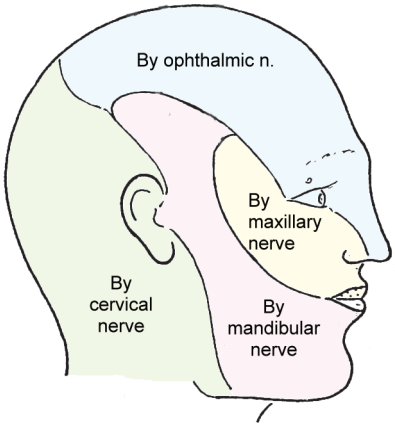

Fig. 3.16 Areas of skin supplied by the ophthalmic, maxillary and mandibular divisions of the trigeminal nerve.

the skull, the facial nerve enters the parotid gland and divides within it into several branches that emerge along the borders of the gland (Fig. 1.4).

In Fig. 1.2 note that the facial nerve gives off a temporal branch, a zygomatic branch, upper and lower buccal branches, a marginal mandibular branch, and a cervical branch. These branches supply the various muscles of the face.

The sensory nerves seen on the face are terminal ramifications of the trigeminal nerve (Fig. 1.4). Branches arising from the ophthalmic division are the supratrochlear, supraorbital, infratrochlear and external nasal nerves. Some branches are also given off to the upper eyelid.

Branches of the maxillary division of the trigeminal nerve to be seen on the face are the infraorbital nerve, the zygomaticofacial and zygomatico-temporal nerves (Fig. 1.5). Branches of the mandibular division seen on the face are the auriculotemporal, buccal (Fig. 1.5) and mental nerves. The area of skin of the face supplied by the three divisions of the trigeminal nerve are showing in Fig. 3.16.

Clinical Correlations

Clinical correlations of the scalp, of the face, and of the parotid gland are given in Chapter 15.

JAYPEE BROTHERS

for detailed information on anatomy books, visit our website www.jaypeebrothers.com, for detailed information on anatom

Essentials of ANATOMY
for Dental Students (With Colour Atlas)

Salient Features

- The emphasis of the book is on a picture memory rather than a verbal one.
- The book is divided into two sections which contains 26 chapters.
- Emphasis is on providing students some examples of clinical correlations, for which a separate chapter is devoted to clinical correlations at the end of each section.
- The book contains two color atlas, which are realistic to the extent that normal contours and relationships are maintained in the illustrations.

Available at all medical book stores
or buy directly from Jaypee Brothers through online shopping
at www.jaypeebrothers.com

JAYPEE BROTHERS
Medical Publishers (P) Ltd.
www.jaypeebrothers.com

Join us on facebook.com/JaypeeMedicalPublishers

Shelving Recommendation
ANATOMY

ISBN 978-93-5152-591-2