ur website **www.jaypeebrothers.com,** for detailed information on dental books, visit our website **www.jaypeebrothers.c**

Complete Denture Prosthodontics



Sujit Kumar Das

JAYPEE

CONTENTS

1. Introduction and Scope 1
Definition of Terms 1
Branches of Prosthodontics 1
Types of Prosthesis 2
Objectives of Complete Denture Prosthesis 2
History of Complete Dentures 3
Clinical and Laboratory Procedures of Complete Denture Prosthesis 4
Treatment Options for Edentulous Patients 5
Scope of Complete Dentures 5

2. Applied Anatomy 8
Applied Anatomy of Important Oral Structures 8
Mucosa 8
Bones 10
Surrounding Muscles 14
Salivary Glands and Saliva 19

3. Examination, Diagnosis, Treatment Planning and Prognosis 29
Definition of Diagnosis 29
Treatment Planning 29
Diagnostic Form 30
Explanation of Diagnostic Form 33
Prognosis 45

4. Retention, Stability and Support of Complete Dentures 49
Retention 49
Definition 49
Factors Affecting Complete Denture Retention 49
Stability 54
Support 57

5. Principles and Techniques of Impression Making 60
Impression 60
Complete Denture Impression 60
Anatomic Landmarks 62
Denture-bearing Areas 63
Theories of Impression Making 69
Impression Techniques 69
According to Degree of Compression 69
Mucocompressive Impression Technique 71
According to the Position of the Mouth 74

According to the Type of Impression Tray 75
Principles of Impression Making 75
Clinical Procedures of Impression Making 76
Preliminary Impressions 76
Final Impressions 85
Custom/Special Tray 85

6. Preparation of Casts, Special Trays, Denture Bases and Occlusal Rims..... 92
Model 92
Cast 92
Laboratory Preparation 93
Boxing and Pouring of Master Casts 97
Record Bases and Occlusion Rims 100

7. Articulators and Facebows 107
Articulators 107
Facebows 113

8. Jaw Relations and Methods of Registration..... 119
Jaw Relationship 119
Jaw Relationship Record 119
Importance of Maxillomandibular Relations 119
Vertical Dimension 120
Effects of Excessive Occlusal Vertical Dimension 121
Effects of Reduced Occlusal Vertical Dimension 122
Methods of Determining Vertical Dimension of Occlusion 122
Significance or Importance of Centric Relation 126
Difficulties in Recording Centric Relation 126
Contraindications of Gothic Arch Tracing Method 129
Clinical and Laboratory Procedures 130
Preliminary Vertical Dimension of Occlusion 130
Recording the Centric Relation 136

9. Artificial Tooth Selection and Arrangement 139
Anterior Tooth Selection, Arrangement and Esthetics 139
Objectives 139
Methods of Selection of Teeth 139
Number System of Artificial Teeth 146
Preliminary Arrangement of Artificial Teeth for Trial 148
Inclinations 151
Selection and Arrangement of Posterior Teeth 154
Selection of Posterior Teeth 154
General Principle of Arrangement of Posterior Teeth
Factors for Arrangement of Posterior Teeth 156
Laboratory Procedures (Arrangement of Teeth) 157
Arrangement of Teeth in Class I Relation 160
Selection and Arrangement of Teeth in Atypical Ridge Relations 163

Arrangement of Teeth in Angle's Class II, Division 1 163
Arrangement of Teeth in Angle's Class II, Division 2 163
Arrangement of Teeth in Angle's Class III 164
Arrangement of Teeth of Patient with Old Denture 164

10. Occlusion and Articulation in Complete Dentures 166
Nomenclature and Terminology of Occlusion 166
Balanced Articulation 168
Arrangement of Anatomic (Cusp) Teeth to Balanced Articulation 172
Arrangement of Nonanatomic (Cuspless) Teeth to Balanced Articulation 173

11. Try-in of Complete Dentures 177
Definition 177
Objectives 177
Instruments and Materials 177
Trial Denture Procedures 177
Postdam/Post-palatal Seal 181

12. Laboratory Procedures—Final Arrangement of Teeth, Waxing, Processing and Finishing of Dentures 185
Final Arrangement of Teeth 185
Wax Contouring (Waxing) of Complete Dentures 187
Conventional Method 188
Processing Complete Dentures 191

13. Correction of Occlusal Discrepancies 199
Causes of Occlusal Discrepancies 199

14. Delivery and Adjustments of Complete Dentures 205
Objectives 205
Instruments and Materials 205
Preparation for Insertion 206
Insertion Procedure 206
Check Record 208
Complains of Dentures 213

15. Sequelae of Wearing Complete Dentures 215
Effects of Complete Dentures on Oral Tissues 215
Residual Ridge Reduction (RRR) 216
Denture Stomatitis 217
Angular Cheilitis 217
Flabby Ridge 217
Burning Mouth Syndrome 217
Gagging 218
Control of Sequelae of Wearing Complete Dentures 218

16. Repair, Rebasing and Relining 220
Repair 220
Relining 225
Rebasing 227

17. Immediate Complete Dentures 228
Definition 228
Types of Immediate Denture 228
Requirements of Immediate Dentures 229
Advantages of Immediate Dentures 229
Disadvantages of Immediate Dentures 230
Indications 230
Contraindications 230
Treatment Planning for Immediate Dentures 230
Immediate Denture Techniques 231

18. Dental Implants 235
Dental Implants 235
Implants Treatment Course 239
Types of Implants Restoration for Edentulous Patients 242
Clinical Success for Endosseous Implant 243
Biomechanical Factors in Long-term Implant Success 243
Criteria for Implant Success 243
Complications of Implants 244

19. Overdentures 245
Definitions 245
Overlay Denture 245
Goals of Overdentures 245
Indications 245
Contraindications 246
Advantages of Overdenture 246
Disadvantages of Overdenture 246
Types of Overdentures 246
Techniques of Overdenture 247
Treatment Procedure for Overdenture 247

20. Single Complete Denture 250
Definition 250
Indications 250
Contraindications 250
Problems of Single Complete Denture 250
Fees for Single Complete Denture 251
Diagnosis and Treatment Planning 251
Tooth Modification 251
Methods Used to Obtain Balanced Occlusion 252
Occlusal Materials for the Single Complete Denture 253
Clinical Procedures for Single Complete Denture Opposing Natural Teeth 253

21. Maxillofacial Prosthetics 255
Definition 255
Objectives 255
Classification of Maxillofacial Defects 255
Types of Surgical Defects in Maxilla 255
Types of Surgical Defects in Mandible 255
Types of Maxillofacial Prosthesis 256
Cleft Palate 257
Maxillary Prosthesis 258
Clinical and Laboratory Step by Step Procedures of Fabrication of Complete Denture with Obturator 260
Treatment Prosthesis 264
Mandibular Training Flange 265
Splints 265
Stents 267
Carrier 267
Mouth Protectors 267

Index 269

Chapter 3

Examination, Diagnosis, Treatment Planning and Prognosis

JAYPEE BROTHERS

INTRODUCTION

The success or failure of complete denture treatment is usually determined at the diagnosis stage. To obtain predictable result, the dentist must apply his skill. Before applying his skill the dentist must diagnose each case of complete denture individually.

According to Devan, "The dentist should meet the mind of the patient before he meets the mouth of the patient."

DEFINITION OF DIAGNOSIS

Diagnosis is the examination of the physical state, evaluation of the mental or psychological make up and understanding the needs of each patient to ensure a predictable result.

Diagnosis in complete denture is a continuing process and is not accomplished in a short time. In many patients, the most pertinent/important finding escape the operator until the planned treatment near completion.

The diagnostic record for complete denture treatment can best be complied by using a systematic diagnostic form (Table 3.1). From this information a treatment plan and prognosis can be developed. The dentist must consider each patient as an individual. It is possible to categorize patients and anticipate certain problems, but always remember that not all patients will fit a predetermined group.

According to difficulty faced, patients can be categorized in the following types:

Group 1: Relatively easy, compromises can be made during the treatment (70%).

Group 2: Somewhat difficult, they make about 20% of all patients.

Group 3: Difficult, about 10% of the patients who have anatomical and psychological problems.

TREATMENT PLANNING

Developing a course of action that encompasses the ramification and sequelae of treatment to serve the patient's needs.

Treatment planning is a consideration of all of the diagnostic findings, systemic and local which influence the surgical preparation of the mouth, impression making, maxillomandibular relation records, occlusion to be developed, form and material in the teeth, denture base material and instruction in the use and care of dentures.

In evaluating a patient, a decision should be reached whether or not successful therapy can be instituted for that patient. This decision should be based upon the result of the examination. It should be based upon a physical examination; the patient's attitude may negate the construction of successful complete denture. On the contrary despite extremely unfavorable prognosis successful complete denture may result when patient truly desires to wear dentures. The patient's attitude is more difficult to overcome than the physical hazard of atrophic ridges.

The success of complete denture treatment depends on so many physical and mental variables. It is advisable to use a complete checklist to ensure that all the influencing conditions have been examined.

DIAGNOSTIC FORM

I. Patient Data

Name _____
Telephone no: (Home) _____ (Business) _____
Age_____ Sex_____ Occupation and social position_____ Tooth shade_____Mucosa shade_____
Cosmetic index: Class I (High), Class II (Medium), Class III (Low).
Personality: Philosophic, Exacting, Hysterical, Indifferent.

II. Medical History

General health
Major ailments (if any):
Whether under any medication:

III. Dental History

1. Chief complaint_____
2. Period of edentulousness_____

Maxilla_____Mandible_____

3. Reason for extraction_____
   Caries_____
   Periodontal diseases_____
   Others_____
4. Previous denture history—number
   Satisfactory/Unsatisfactory_____

If unsatisfactory, state the reasons_____

Existing Dentures Experience

Retention
Stability
Extension
Esthetics
Phonetics
Occlusion

IV. Extraoral Clinical Examination

1. Face form: Ovoid_____ Square_____ Tapering_____
2. Profile_____Straight (see Fig. 3.2) _____ Convex_____Concave_____
   (Class I) (Class II)
   (Class III)
3. Complexion: Fair_____ Medium_____ Dark_____
4. Lips Active_____ Flaccid _____ Normal _____
   Long _____ Medium_____ Short_____
   Thick _____ Thin _____Normal _____
5. Muscle tone: Class I (Normal)_____Class II (Slightly impaired)_____ Class III (Greatly impaired).
6. TM joint: Normal_____Cripitus_____Clicking_____ Deviation_____

JAYPEE BROTHERS

7. Neuromuscular coordination:
   Class I: (Excellent)
   Class II: (Fair)
   Class III: (Poor)

V. Intraoral Clinical Examination

1. Arch size:
   Class I: Large
   Class II: Medium
   Class III: Small
2. Arch form
   Class I: Square
   Class II: Ovoid
   Class III: Tapering
3. Shape of the ridge
   Class I: U-shaped square
   Class II: V-shaped
   Class III: Flat
   Class IV: Knife edge
4. Interarch space
   Class I: Ideal interarch space to accommodate the artificial teeth
   Class II: Excessive interarch distance
   Class III: Insufficient interarch distance
5. Ridge parallelism:
   Class I
   Class II
   Class III
6. Ridge relationship (Angle classification):
   Class I: Normal
   Class II: Retrognathic
   Class III: Prognathic.
7. Bony undercuts:
   Maxilla—Class I (None); Class II (Slight); Class III (More): Require removal
   Mandible—Class I (None); Class II (Slight); Class III (More): Require removal.
8. Tori:
   Class I (Absent)
   Class II (Mild): Surgery optional
   Class III (Large): Require surgical removal
9. Palatal throat form:
   Class I: Gentle (Large and normal in form with a relative immovable band of resilient tissue 5 to 12 mm distal to a line drawn across the distal end of the tuberosities).
   Class II: Medium (sized normal in form with immovable tissue 3 to 5 mm distal to a line drawn across the distal end of the tuberosities).
   Class III: Abrupt (drop of soft tissue 3 to 5 mm anterior to a line drawn across the palate at the distal end of the tuberosities).
10. Lateral throat form:
    Class I: Large
    Class II: Medium
    Class III: Small.
11. Mucosa condition:
    Class I: Healthy: Uniform thick and firm
    Class II: Irritated and thin
    Class III: Pathological thick and flabby

JAYPEE BROTHERS

12. Border and frenum attachments:
    Class I: High
    Class II: Medium
    Class III: Low.
13. Saliva:
    Class I: Normal quality and quantity
    Class II: Excessive saliva with much mucin
    Class III: Scanty with mucin
14. Tongue size:
    Class I: Normal
    Class II: Large
    Class III: Small.
15. Tongue position:
    Class I: Normal
    Class II: Retracted
    Class III: Retracted
16. Gag reflex.

VI. Radiographic Examination

VII. Pre-extraction Records

VIII. Treatment Plan and Prognosis

Tissue conditioning—
Preprosthetic surgery—
Tooth selection shade mould and material

Tooth selection	*Shade*	*Mould*	*Material*
Maxillary anterior			
Mandibular anterior			
Maxillary posterior			
Mandibular posterior			

IX. Prognosis

Mandibular denture

Factors	Criteria for retention Good Prognosis	Bad Prognosis

Factors	Criteria for stability Good Prognosis	Bad Prognosis

Maxillary denture

Factors	Criteria for retention and stability Good Prognosis	Bad Prognosis

JAYPEE BROTHERS

From this checklist an accurate treatment plan and prognosis is formulated by collecting and interpreting diagnostic data. The problems should be identified early and explained clearly to the patient prior to the treatment. Problems that are explained after they occur, may delay treatment, will be considered by the patient as excuses for poor dental skill. It will have an adverse effect on doctor-patient relation.

A logical approach to diagnosis begins with a patient interview, which may also include a dental and medical history, followed by radiographic and oral examinations.

So, a proper emphasis should be given in collecting, interpreting, and transferring the diagnostic information into a treatment plan.

EXPLANATION OF DIAGNOSTIC FORM

The information required to interpret the diagnostic data properly is given above. The discussion is followed to fully correlate the diagnostic findings and clinical practice.

Patient Data

Name: It is necessary for the purpose of identification and record.

Age: The age of the patient gives an indication of his ability to wear and use dentures efficiently. Young patients are generally in good health, and this is reflected in the oral tissues. In young patient, resorption of ridges is rare and all the anatomical and physiological factors are more favorable than in older patients. The young people possess more powers of accommodation or adaptability, and learn to use artificial dentures with little apparent effort. An arbitrary change point is considered to be age 40. Patients younger than 40 are usually adaptable to change, their tissues heal rapidly and offer good resistance. Patients over 40 have tissues that do not heal as quickly and have a mental attitude not to adapt to new situation. Many patients over the age of 60 years find it difficult to adapt to new situations. Tissue repair is often slow, and in many cases there was extensive destruction of denture-supporting tissues. Age is also important in the selection and arrangement of artificial teeth.

Sex: In general, women are more difficult to please with appearance of their denture than are men. They are more aware of their face and lips than are men. Any change in this part of body is readily apparent to them. Women during menopause can be difficult to treat due to psychological problems, dry mouth, burning sensation in the mouth and general vague pain.

Men tend to be more occupied with their work and less concerned with their dentures. They do accept comfort and function.

Occupational and social position: Knowing the patient's occupation and social position helps the dentist in determining what the patient expects from his dentures. In general:

- Higher the social position, more demanding the patient is about esthetics.
- A patient who speaks before group of people would be concerned about speech patterns more than one who paints for living.
- Tooth position for a musician who plays a wind instrument would be more critical than for person who does not use the mouth in making a living.
- Person who works in cafeteria is in high-risk for frequent eating.

At this time dentist should also identify discrepancy between expectations and reality before the start of treatment otherwise success will elude both dentist and patient.

Tooth shade: The preliminary shade selection should be made in the first visit without the patient participation as most patients have a wrong concept about the size and color of teeth. These require some patient education. The final selection of tooth shade and mould is usually done at third visit and patient's participation should be needed at that time.

JAYPEE BROTHERS

Mucosal shade: The color of the denture base material should match with the color of the mucosa. For proper selection of shade manufacturers, supplied color tabs may be used at chair side.

Cosmetic index: It is the esthetic expectations of the patient. The patients are classified as high, medium and low cosmetic indices.

Class I: High cosmetic index: Patients with high cosmetic indices are often exacting, appreciative and cooperative.

Class II: Moderate cosmetic index: The patients are of moderate expectations.

Class III: Low cosmetic index: The patients with low cosmetic indices are often indifferent and uncooperative.

Patient personality: Meeting the mind of the patient is essential before institution of treatment. To understand a patient the psychological assessment is required. House (1937) classified the patient as philosophical, exacting, indifferent and hysterical.

Philosophical Patients

- These patients are with best mental attitude.
- These patients are rational, sensible, calm and well adjusted in difficult situation.
- Their motivation is generalized as they desire denture for the maintenance of health and appearance and feel that having teeth replaced is a normal, acceptable procedure. Prognosis is excellent.

Exacting/Critical Patients

- These patients are methodical, precise, accurate, and immaculate in dress and appearance at times make severe demands.
- They are dissatisfied, distrust and want guarantee or remake at no additional charge.
- A firm control of these patients is essential.

Indifferent Patients

- These patients have questionable or unfavorable prognosis. These patients have little concern for their teeth or health.
- They have little appreciation for the efforts of their dentist.
- Often seek treatment because of insistence of their family.
- They will give up early if problems are encountered in new teeth.
- Their attitude can be discouraging to the dentists who treat them.
- Education programmed in dental condition is recommended treatment plan.

Hysterical/Skeptical Patients

- They are those patients who have bad results with previous treatment and, therefore, are doubtful that anybody can help them.
- They often have a recent series of personal tragedies such as loss of spouse, business problems.
- Sometimes they demand unrealistic expectation, i.e. patients demand esthetic and function equal or greater than natural teeth. They have poor prognosis.

Medical History

General health: Generally, a patient who possesses a good general health will be able to accept and adapt to a complete denture better than those in poor health. So, the dentist must know about the systemic diseases that may affect complete denture therapy, e.g. AIDS, anemia, arthritis, Bell's palsy, carcinomas, tuberculosis, diabetes, lupus erythematosus, nicotinic stomatitis, Parkinson's diseases, Pemphigus vulgaris, Paget's diseases, Plummer-Vinson syndrome, scleroderma. The medical history questions are to alert the dentist to possible medical problems in dental chair. A positive answer indicates the necessity of further investigation.

JAYPEE BROTHERS

The dentist should know what medicines the patient is taking. Some medicines have direct effect on the oral cavity. Tranquilizers and antidepressants may cause dry mouth. Hormone therapies often cause extreme sore mouth for edentulous patients. In many situations, it will be necessary to consult patient's physician before preceding with the treatment. Sometimes, a change in treatment plan will be beneficial.

Debilitating Diseases

Patients having debilitating diseases should be under medical control. Diabetes, tuberculosis and blood dyscrasias require extra instructions in oral hygiene, eating habits and rest of tissues. The patient's physician must be consulted before denture construction. The frequent recall visit is required to keep the adaptation of the denture base correct.

Diseases of Joint

Osteoarthritis of the temporomandibular joint presents a problem in complete denture construction as mandibular movements are painful. This causes jaw relation and impression procedures difficult.

Cardiovascular Diseases

In presence of cardiovascular diseases, the patient's physician should be consulted as denture appointments may be contraindicated or shortened, and along with premedication.

Neurological Diseases

Parkinson's diseases and Bell's palsy involve nerve and patients may be treated but the problems of denture retention and jaw relation records should be encountered with special attention.

Malignancies

The diagnosis of oral lesions should be done by biopsy, and treatment with surgery, and radiotherapy should be followed by denture construction only after proper healing. The clinical examination of the tissues after postinsertion of denture is essential.

Menopause

The hormonal changes cause bone changes, generalized osteoporosis. The mental changes may cause burning mouth, gagging and vague pain in the patients. Medical or psychiatric treatment may be required before dentures are constructed.

Diet: The patient should be questioned about his diet. Dentist must remember that a patient who has been edentulous may have unconsciously changed his diet due to his inability to masticate properly and if the nutritional intake of patient is found to be lacking, an adequate diet should be prescribed.

Dental History

Chief Complaint

It is the patient's reasons for seeking dental treatment or new dentures. The exact words of patient should be noted. This indicates the knowledge and patient's concern for a particular problem. The patients who seeks dentures as a result of family pressure is rarely a successful unless he is educated about denture during the treatment and supplied with written instruction for use and care of denture.

Dates of Extraction of the Teeth

This helps to ascertain the rate of resorption and gives an idea of stability of the denture-bearing tissues. The longer the patient been edentulous, the more bone resorption usually is noted. More resorption in one area than in other is difficult to treat with a complete denture. The patients who have been edentulous for a long time and did not wear artificial dentures are difficult to treat.

JAYPEE BROTHERS

Reasons for Extraction of the Teeth

The reasons for loss of natural teeth help to ascertain the rate of resorption of ridges. The rate is more expected in tooth loss due to periodontal disease. Extraction due to caries usually produces less resorbed ridges.

Previous Denture History

The denture history is very important in evaluation of the prognosis of complete denture treatment. The patient should be asked whether the dentures were satisfactory or never satisfactory, previously satisfactory but now unsatisfactory, previous denture was satisfactory new denture unsatisfactory.

The number of dentures that the patient has had and the length of time each has been worn help in evaluating the anticipated prognosis. A patient with a successful denture treatment will probably be having good prognosis again. The type of teeth—anatomic or nonanatomic, porcelain or resin—should be determined according to the previous successful denture. The reasons for satisfaction or dissatisfaction with the previous dentures (i.e. with the masticatory efficiency, retention, stability, esthetics, phonetics, comfort and occlusion) may affect the type of replacement to the patient.

The loss of retention may be due to faulty occlusion or overextension or underextension of borders. The discomfort and difficulty in chewing may be due to fault in occlusion. The altered speech may be due to error in vertical dimension, poor retention, or error in placement of teeth.

Existing or Present Dentures

The reasons for dissatisfaction with the present dentures may also affect the type of replacement to the patient. The followings should be checked:

1. Occlusion
2. Retention
3. Stability
4. Esthetics
5. Phonetics
6. Extension

Extraoral Clinical Examination

Face form: Leon Williams (1914) and House and Loop (1939) were first to consider the importance of the outline form of the anterior teeth. They classified the outline form, or shapes, of the face and selected anterior teeth in harmony with the facial form. The face form is classified by connecting points on lateral aspect of face, i.e. the forehead, zygomatic arch, and angle of the mandible. There are four basic shapes of a person— (1) square, (2) square tapering, (3) tapering, and (4) ovoid (Fig. 3.1). The shape of the maxillary central incisor should be similar to that of face when placed upside down. This method is known as geometric theory. Artificial tooth manufacturers use this theory as the basis for tooth mould classification. Although the theory is not proven (Wright found 60,7% not correlate), the harmony between face and tooth forms enhances esthetics.

Facial profile (Fig. 3.2): The incisogingival and mesiodistal curvatures of incisor teeth are similar to the profile curvature of face. So, facial profile is helpful for selection of anterior tooth.

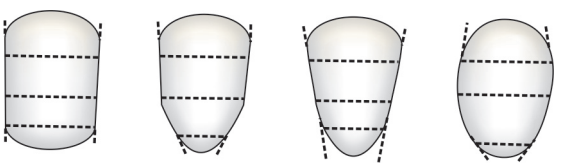

Fig. 3.1: Face form: Square, square tapering, tapering and ovoid

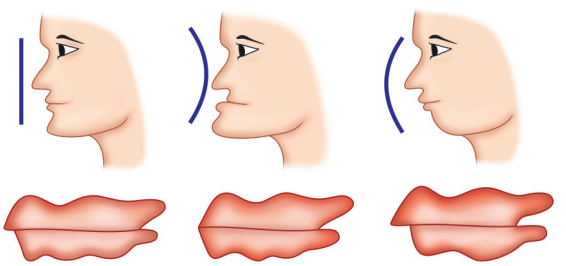

Fig. 3.2: Facial form (profile) and ridge relation (profile)
Classification according to angle:
Class I Normal | Class II Prognathic | Class III Retrognathic

JAYPEE BROTHERS

Complexion: It is important guide in the shade selection. The shade should have harmony with complexion. The relationship of color of hair or eye is questionable in shade selection.

Lips: Short lips show more tooth structure. The opposite is true for long lips. Thin lips are difficult to treat because the slight oversupport may greatly affect facial expression.

Muscle tone: Tone of muscles of facial expression is classified according to House:

Class I: The patient possesses normal tone, tension and placement of muscles. No degenerative changes have yet occurred. Only patients wearing immediate dentures have a class I muscle tone.

Class II: The patient possesses approximately normal function but slightly impaired muscle tone due to wearing of adequate dentures with correct vertical dimension of occlusion is of this type.

Class III: The patient possesses impaired muscle tone and function due to poor health and grossly inefficient dentures. This produces loss of vertical dimension of occlusion, decreased biting force and wrinkles. Excessive flaccidity reduces the ability to control the dentures. It also increases the possibility of denture base overextension. The proper tray fabrication, border moulding and impression is required for the correct extension of denture base.

Temporomandibular joint: The temporomandibular joint should be examined digitally by placing the fingers on the joints when the patient opens and closes the mouth. Any pain, clicking and crepitus or abnormal movements should be noted. Discomfort or pain has been associated with excessive increase or decrease of vertical dimension and arthritis.

Neuromuscular coordination: The mandibular movements should be coordinated. Uncontrolled movements cause difficulty in determining correct centric relation and protrusive records and forbid the use of a balanced occlusion with anatomic tooth.

Intraoral Clinical Examination

Arch Size

Class I (Large): Best for retention and stability.
Class II (Medium): Good for retention and stability.
Class III (Small): Poor for retention and stability.

Denture stability will be hampered if there is a great discrepancy between the upper and lower arch. The choice of cuspless posterior teeth will lessen the problem.

Arch Form (Figs 3.3 to 3.5)

Generally arch form is classified (House) as:

Class I (Square): The square arch is best form to prevent rotational movements and provides stability to the dentures.

Class II (Tapering): The tapering arch prevents rotational movements to a lesser degree.

Class III (Oval): The oval arch is round in shape and gives little or no resistance to rotational movements.

If the arch form is not same in the maxilla and mandible, there will be problem with tooth arrangement and stability.

Shape of the Ridge

The contour of the residual ridge determines the amount of vertical and horizontal the denture basis



Fig. 3.3: Square-shaped maxillary arch

JAYPEE BROTHERS

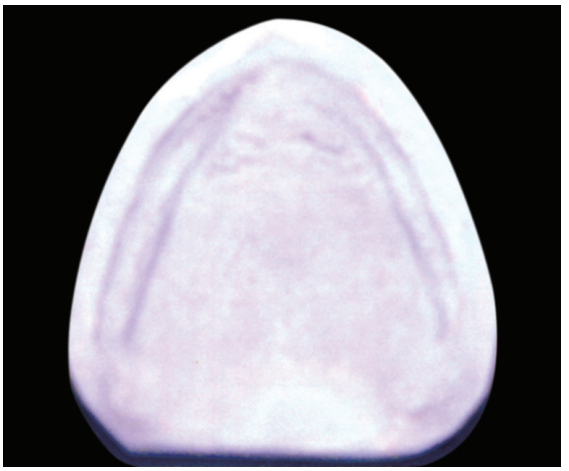

Fig. 3.4: Tapering-shaped maxillary arch



Fig. 3.5: Ovoid-shaped maxillary arch

Class I (Square): The square and is U-shaped ridges are best for denture stability and retention.

Class II (V-shaped): The V-shaped ridges are less favorable as slight pressure on the denture base causes displacement of the denture from the underlying soft tissues.

Class III (Flat): The flat ridges offer the poorest resistance to horizontal forces.

Class IV (Knife edge): The knife-edged ridges also can offer little resistance to vertical forces. The pressure on the ridges traumatizes the mucosa covering the top of the ridge and sufficient relief should be provided on it.

Interarch Space

The interarch distance between the ridges approximately parallel. In case of normal interspace the arrangement of teeth is easy and stability of the denture is good.

Excessive interarch space is usually accompanied by severe resorption and produces leverages on the denture base and decreases stability.

Insufficient interarch space creates difficulty to accommodate the artificial teeth.

Ridge Parallelism

Class I: When both the ridges are parallel, no sliding movement of the denture occurs during function.

Class II: When the mandibular ridge is divergent from the occlusal plane anteriorly one denture will slide forward.

Class III: When the maxillary ridge is divergent from the occlusal plane anteriorly or both the ridges are divergent anteriorly both the dentures will slide forward.

Ridge Relationship (Figs 3.6A to C)

Class I (Normal): The maxillary ridge crest is directly above the mandibular ridge. In this case, anterior teeth are set with an object and overbite of 1 to 2 mm. In this case, usually the posterior teeth can be set in normal position with 1 mm overjet. This is most favorable ridge relation for complete dentures and balanced occlusion is possible.

Class II (Retrognathic): The mandibular ridge is narrower and shorter than the maxillary ridge that makes the setting of posterior teeth difficult. These patients often have wide range of mandibular movement that makes the balance occlusion necessary. They frequently show habitual closure position anterior to centric relation.

JAYPEE BROTHERS

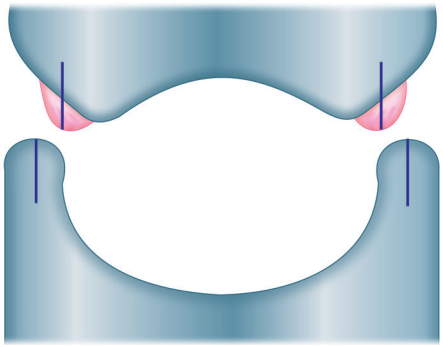

Fig. 3.6A: Normal (class I) ridge relation—posterior view

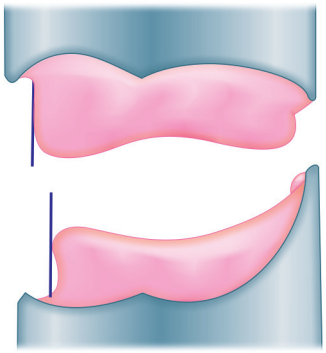

Fig. 3.6B: Normal (class I) ridge relation—buccal view

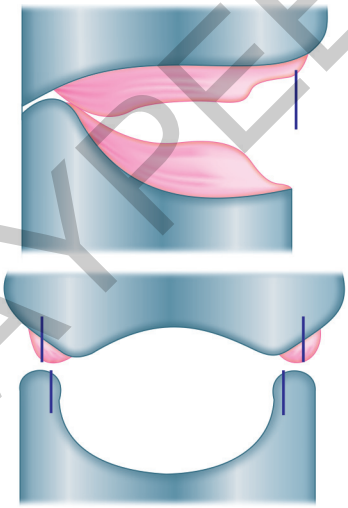

Fig. 3.6C: Prognathic (class II) ridge relation—buccal and posterior view

Class III (Prognathic): The mandible is larger and wider than maxillae. These patients show no excursive movement but only open and close hinge jaw movement. This makes balance occlusion unnecessary. These patients show a posterior, and sometimes, an anterior cross-bite.

Bony Undercuts

Bony undercuts are found on both the maxillary and mandibular ridges. On maxilla undercuts are usually present in anterior ridge and lateral to the tuberosities. Undercuts do not help in retention but cause loss of border seal. Selective relief of denture is the treatment. Surgical removal is rarely needed.

Tori (Fig. 3.7)

Small mandibular or maxillary tori usually present no problem in denture fabrication. If undercuts are present in tori, they should be removed surgically. If very thin mucosa overlies, the tori relief in denture should be provided.

Palatal Throat Form (Fig. 3.8)

According to House, classification of the soft palate is based on the degree of palatal flexure which is important to the formation of the posterior palatal



Fig. 3.7: Torus palatini

JAYPEE BROTHERS

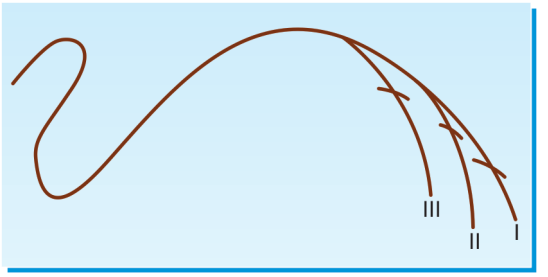

Fig. 3.8: Palatal throat form classes I, II and III

seal in the maxillary denture. The junction of hard and soft palates is marked with an indelible pencil when the patient blows through nose while holding it closed. The line of palatal flexure/vibrating line is then marked when the patient say "Ah".

Class I: Gradual flexure of soft palate 5 to 12 mm behind the junction of hard and soft palates. It is very favorable as it is wide.

Class II: Turns down approximately at an angle of 45° of tissue 3 to 5 mm behind the junction of the hard and soft palates.

Class III: Turns down abruptly at an angle of 70° just behind the hard and soft palates. It is most critical situation to locate the seal area and movement of soft palate may result in a loss of retention.

Lateral Throat Form (Retromylohyoid Space)

It is examined with a small mouth mirror placed in the space and the patient is asked to gently protrude the tongue.

Class I (Large): Mylohyoid ridge is10 mm above the floor of the mouth (Good retention).

Class II (Medium): Mylohyoid ridge is less than 10 mm from the floor of the mouth (Fair retention).

Class III (Small): Mylohyoid ridge at same level to floor of the mouth and the mirror is displaced. Retention is almost impossible for lower denture.

Mucosa Condition

Class I: Healthy

Class II: Irritated

Class III: Pathologic, e.g. papillomatous

Border and Frenum Attachments

Class I (Low): The border or frenum attachments close to the vestibule (less than 6 mm).

Class II (Intermediate): The border or frenum attachments close to the ridge crest (between 6–12 mm).

Class III (High): The border or frenum attachments high up the ridge crest (more than 12 mm).

Saliva

Class I: Amount and consistency of saliva is normal.

Class II: Excessive thin saliva containing water or thick saliva contains much mucus. Excessive saliva may cause gagging and interface with impression making.

Class III: (Xerostomia) Saliva is scanty and mucinous may reduce retention of denture.

Tongue Size (House)

Class I: normal in size

Class II: Large in size

Class III: Excessive large

The tongue gives trouble in case of large and small sizes. A large-sized tongue may displace the mandibular denture. A small tongue fails to produce border seal for the lower denture. The enlarged tongue makes the impression and jaw relation records difficult, however, once the denture is worn by the patient for several days, tongue adapts to the denture.

JAYPEE BROTHERS

for detailed information on dental books, visit our website **www.jaypeebrothers.com,** for detailed information on dental

Complete Denture Prosthodontics

The book is the outcome of author's classroom lecture notes prepared for the undergraduate students of Dr R Ahmed Dental College and North Bengal Dental College, Siliguri, West Bengal, India. Standard clinical and laboratory techniques described at the end of each chapter will help the beginners of the subject to follow and master before switching over to other techniques of operators choice. Each chapter is divided into two parts—(a) general discussions followed by (b) clinical or laboratory techniques.

Complete Denture Prosthodontics is aimed at the undergraduate dental students, the general dental practitioners with an interest in prosthodontics, and those aiming at postgraduate course in that subject. The book covers the BDS syllabus of Dental Council of India (DCI).

Key Features

- Fully covers the DCI syllabus prescribed
- Written in a comprehensive manner
- Includes over 200 full color photographs and illustrations to correlate theory with clinical practice
- Step-by-step guide to the complex subject
- Provides a new innovative technique of denture repair by FRC.



Sujit Kumar Das BDS MDS (Cal) was Principal, Professor and Head, Department of Prosthodontics and Dental Materials, Kalinga Institute of Dental Sciences, KIIT University, Bhubaneswar, Odisha, India. He was formerly Professor and Head, Department of Prosthodontics and Dental Materials, Dr R Ahmed Dental College and Hospital, Kolkata, West Bengal, India. He obtained his Bachelor's degree from Dr R Ahmed Dental College and Hospital, in 1968 and completed postgraduation from the same college, in 1988. He was involved both in undergraduate and postgraduate teaching programs for the last 30 years. He has several national publications to his credit and keeps keen interest in the recent developments. He is now associated with different Indian universities as an examiner both in undergraduate and postgraduate levels.

Available at all medical bookstores or buy online at www.jaypeebrothers.com

JAYPEE BROTHERS
Medical Publishers (P) Ltd.
www.jaypeebrothers.com

Join us on facebook.com/JaypeeMedicalPublishers

Shelving Recommendation
DENTISTRY

ISBN 978-93-5152-621-6