ww.jaypeebrothers.com, for detailed information on nursing books, visit our website www.jaypeebrothers.com

ANATOMY & PHYSIOLOGY & BIOCHEMISTRY

Made Easy for NURSES

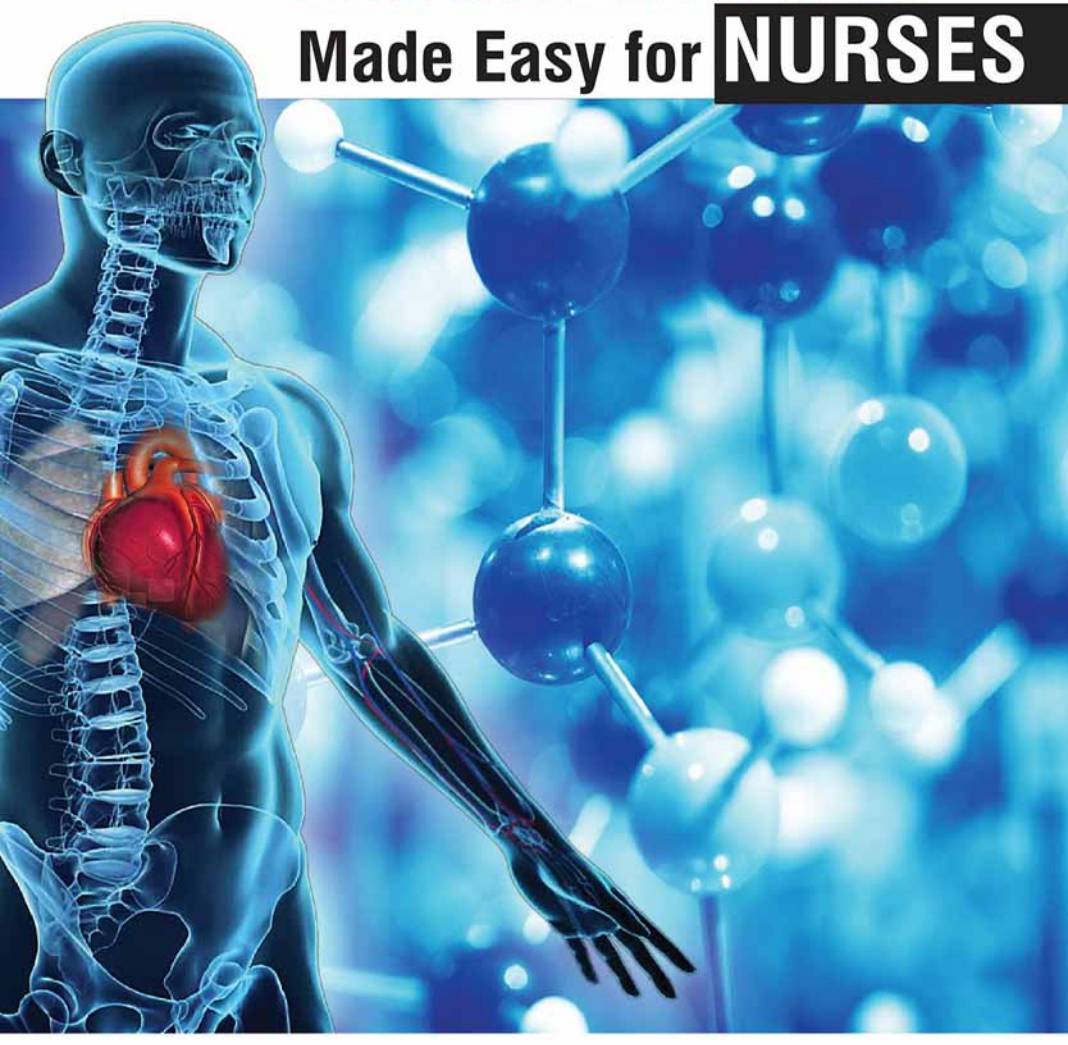

Anjula Vij

JAYPEE

Contents

ANATOMY

1. General Anatomy 3
2. Upper Limb 20
3. Lower Limb 69
4. Thorax 110
5. Abdomen 153
6. Head and Neck 254
7. Central Nervous System 317

PHYSIOLOGY

8. General Physiology 355
9. Blood and Body Fluids 365
10. Muscle Physiology 404
11. Digestive System 420
12. Renal Physiology and Excretion 437
13. Endocrinology 449
14. Reproductive System 479
15. Cardiovascular System 498
16. Respiratory System and Environmental Physiology 525
17. Nervous System 554
18. Special Senses 603
19. Skin and Body Temperature Regulation 624
20. Practical Viva in Hematology 628

BIOCHEMISTRY

21.	Biophysics	641
22.	Colorimetry	646
23.	Carbohydrates	648
24.	Lipids	683
25.	Amino Acids and Proteins	702
26.	Nucleoproteins	726
27.	Enzymes	730
28.	Biological Oxidation	733
29.	Vitamins	736
30.	Blood	746
31.	Liver Function Tests	750
32.	Detoxification	754
33.	Urine	756
34.	Water and Mineral Metabolism	761
35.	Nutrition and Energy Requirement	766
36.	Hormones	769
37.	Prostaglandins	773
38.	Important Lab Values to Remember	777

Index *787*

JAYPEE BROTHERS

CHAPTER

3

Lower Limb

BONES OF LOWER LIMB

HIP Bone (Fig. 3.1)

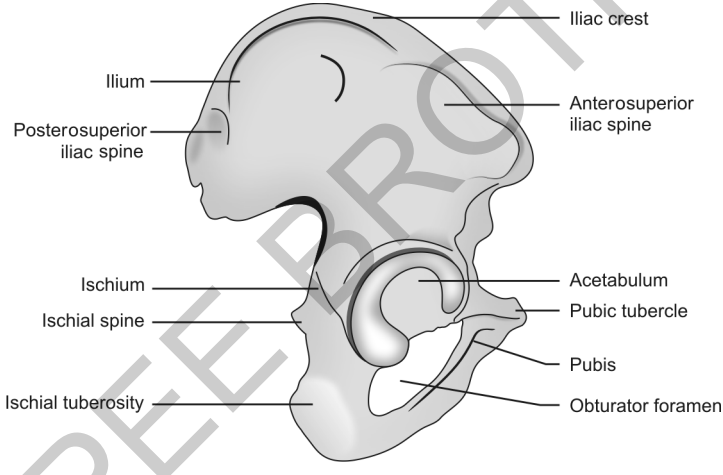

Fig. 3.1: Hip bone

Q.1. What are the different parts of a hip bone?
The hip bone is made up of three parts, the *ilium* superiorly, *ischium* posteroinferiorly and *pubis* anteroinferiorly. The three parts join to form a cup-shaped hollow articular surface, the *acetabulum.*

Q.2. How will you determine to which side the hip bone belongs?
In a hip bone, the acetabulum is directed laterally and the flat ilium forms upper part of bone, lying above the acetabulum. The obturator foramen lies below the acetabulum.

Q.3. What is the normal anatomical position of the hip bone in the body?
- Pubic tubercle and anterosuperior iliac spine lie in the same vertical plane
- The pelvic surface of the body of pubis is directed backwards and upwards
- The ischial spine and upper border of symphysis pubis lie in same horizontal plane
- Symphysis pubis lies in the median plane.

JAYPEE BROTHERS

Q.4. What is the level through which the highest point of the iliac crest passes (intercristal plane)?
The intercristal plane passes at the level of interval between the spines of L_3 and L_4 vertebrae.

Q.5. What is the clinical importance of intercristal plane?
In clinical practice, lumbar puncture is done between the L_3 and L_4 vertebrae.

Q.6. What are the structures attached to the anterosuperior iliac spine?
It provides:
- Attachment to the lateral end of inguinal ligament, and
- Origin of sartorius.

Q.7. Name the structures attached to the iliac crest.

Anterior 2/3 of iliac crest has:
- *Outer lip* which provides
  - Attachment of fascia lata
  - Origin of tensor fasciae lata
  - Insertion to external oblique muscle
  - Origin to latissimus dorsi just behind the highest point.
- *Intermediate area* provides origin to internal oblique muscle.
- *Inner lip* provides
  - Origin to transversus abdominis
  - Attachment to fascia iliaca and fascia transversalis
  - Origin to quadratus lumborum in posterior 1/3, and
  - Attachment to thoracolumbar fascia.

Posterior 1/3 segment of iliac crest has:
- *Lateral slope:* Origin of gluteus maximus
- *Medial slope:* Origin of erector spinae
- *Medial margin:* Interosseous and dorsal sacroiliac ligaments.

Q.8. Name the structures attached to anteroinferior iliac spine.
Anterior inferior iliac spine gives:
- Origin to straight head of rectus femoris in superior half
- Attachment to iliofemoral ligament in inferior half.

Q.9. Name the structures attached to posterior border of ilium.
It provides:
- Attachment to upper fibers of sacrotuberous ligament
- Origin to fibers of piriformis.

Q.10. What are the structures attached to gluteal surface of ilium?
- Gluteus medius arises between anterior and posterior gluteal lines
- Gluteus minimus arises between anterior and inferior gluteal line
- Gluteus maximus (upper fibers) arise behind the posterior gluteal line
- Below inferior gluteal line reflected head of rectus femoris arises.

Q.11. Name the structures attached to the pubic tubercle.
- Medial end of inguinal ligament
- Ascending loops of cremaster muscle.

Q.12. Name the structures attached to the crest of pubis.
- Lateral head of rectus abdominis (origin)

JAYPEE BROTHERS

- Pyramidalis (origin).
  Medial head of rectus abdominis arises from anterior pubic ligament.

Q.13. What are the structures attached to pectineal line?
The structures attached to pectineal line are:
- Conjoint tendon and lacunar ligament at medial end
- Pectineal ligament lateral to lacunar ligament
- Origin of pectineus muscle and fascia covering it, from the whole length
- Insertion of psoas minor.

Q.14. Name the structures attached to ischial spine.
The structures attached to ischial spine are:
- Sacrospinous ligament
- Origin of coccygeus and levator ani
- Origin of superior gemellus.

Q.15. What are the structures attached to ischial tuberosity?
From upper area of ischial tuberosity arise semimembranous superolaterally and semitendinosus and long head of biceps femoris superomedially.

From lower lateral area abductor magnus arise.

Q.16. What are the nerves related to hip bone?
- Sciatic nerve related to lower margin of greater sciatic notch
- Obturator nerve in the obturator canal
- Nerve to obturator internus crosses the base of ischial spine
- Pudendal nerve crosses base of ischial spine
- Nerve to quadratus femoris runs on ischium as it crosses the greater sciatic notch.

FEMUR

Q.17. What is the normal anatomical position of the femur in the body?
The head of femur is directed medially, upwards and slightly forwards and the shaft is obliquely downwards and medially, so that the two condyles at lower surface lie in same the horizontal plane.

Q.18. What is the arterial supply of the head of femur?
The medial part near fovea, supplied by medial epiphyseal arteries derived from ascending branch of medial circumflex femoral artery and posterior division of obturator artery.

The lateral part of head is supplied by lateral epiphyseal arteries derived from lateral circumflex femoral artery.

Q.19. What is the nutrient artery of the femur?
It is derived from second perforating artery.

Q.20. What is angle of anteversion?
The angle of anteversion (angle of femoral torsion) is the angle between the transverse axes of upper and lower ends of femur. It is about 15 degrees.

Q.21. Name the structures attached to intertrochanteric line of femur.
The following structures are attached to intertrochanteric line:
- Capsular ligament of hip joint
- Iliofemoral ligament
- Upper fibers of vastus lateralis and vastus medialis.

JAYPEE BROTHERS

Q.22. Which muscle is inserted into trochanteric fossa?
Obturator externus.

Q.23. Which muscle is inserted in gluteal tuberosity?
Deep fibers of gluteus maximus.

Q.24. What is the origin of popliteus muscle?
From anterior part of groove on lateral aspect of lateral condyle of femur.

Q.25. What is the importance of ossification center for lower end of femur?
The ossification center for lower end of femur appears at end of 9th month of intrauterine life (the day of birth). It is of medicolegal importance in cases of newly born child found dead to decide whether it was viable or not.

Q.26. What is characteristic of primary ossification center of femur?
It is the second long bone in body to start ossifying.

Q.27. Why the fractures of neck of femur, leads to the necrosis of the head?
Because it will interrupt the blood supply to the head which is derived from:
- Vessels travelling up from diaphysis
- Vessels in the retinacula of the hip capsule.

Q.28. Why the intracapsular fracture of the neck of the femur are more dangerous than extracapsular fracture?
The intracapsular fracture interrupts the blood supply, to the femoral head resulting in necrosis whereas in the extracapsular fracture, the blood supply to the head remains unaffected and so there is no danger of avascular necrosis.

Q.29. What is Coxa vara?
In this condition, the angle between the femoral neck and shaft is decreased, i.e. less than 160°. This results from adduction fractures.

Q.30. What is Coxa valga?
Increase in the angle between femoral neck and shaft due to abduction fractures.

Q.31. At which level fracture of shaft of femur is dangerous?
Fracture of the lower end of femur are dangerous because proximal edge of the distal fragment is tilted backwards by the gastrocnemius, which tears the popliteal artery which lies directly behind it.

TIBIA AND FIBULA

Q.32. Name the structures attached to the intercondylar area of tibia.
From before backwards, it provides attachment to:
- Anterior horn of medial meniscus
- Anterior cruciate ligament
- Anterior horn of lateral meniscus
- Posterior horn of lateral meniscus
- Posterior horn of medial meniscus
- Posterior cruciate ligament.

Q.33. What are the structures related to anterior surface of lower end of tibia?
From medial to lateral side it is related to tibialis anterior, extensor hallucis longus, anterior tibial vessels, deep peroneal nerve and extensor digitorum longus.

JAYPEE BROTHERS

Q.34. What are the structures related to the posterior surface of lower end of tibia?
From medial to lateral side it is realted to tibialis posterior, flexor digitorum longus, posterior tibial artery, tibial nerve and flexor hallucis longus.

Q.35. What is the arterial supply of tibia?
Nutrient artery to tibia is a branch of the posterior tibial artery. It is the largest nutrient artery in the body.

Q.36. Although the tibia is one of the most common sites of acute osteomyelitis but knee joint is not involved. Explain.
The knee joint is not involved because the capsule is attached near articular margins of tibia, proximal to epiphyseal line.

Q.37. The fracture of tibia is slow healing. Why?
The tibia is commonly fractured at the junction of upper 2/3rd and lower 1/3rd of its shaft, where it is most slender and this site is poorly supplied by blood vessels.

Q.38. How will you determine the side to which the fibula belongs?
The head is slightly expanded in all directions and lateral malleolus is expanded anteroposteriorly and is flattened from side to side. The medial side of lower end bears a triangular articular facet anteriorly and malleolar fossa posteriorly.

Q.39. Which structure lies between two heads of origin of peroneus longus?
Common peroneal nerve.

Q.40. Name the structures attached to malleolar fossa.
Malleolar fossa provides attachment to posterior talofibular and posterior tibiofibular ligament.

Q.41. Fibula violates the general rule of ossification. Explain.
Normally in a long bone, growing end of a long bone ossifies first and unites with the shaft last while the non-growing end ossifies last and fuses with the shaft first. But in fibula, the ossification center for nongrowing end, i.e. lower end appears first but does not fuse last. This occurs because:
- The upper epiphysis (fuses last) is the growing end of the bone
- Center for lower end appears first because it is a pressure epiphysis.

Q.42. What are the functions of fibula?
- It provides origin to muscles
- It acts as a pulley for the tendons of peroneus longus and brevis
- It forms a part of the ankle joint
- It helps to increase the stability of ankle joint by lateral malleolus and ligaments attached to it.

PATELLA

Q.43. What is the function of patella?
The patella improves the leverage of the quadriceps femoris by increasing the angulation of the line of pull on the leg.

Q.44. How the stability of the patella is increased?
Due to outward angulation between long axes of thigh and leg. The patella has a tendency to dislocate outwards. This is prevented by:
- *Muscular factor:* Insertion of vastus medialis on medial border of patella extends of a lower level than that of the vastus lateralis laterally

JAYPEE BROTHERS

- *Bony factor:* Lateral edge of patellar articular surface of femur is deeper than medial edge.

Q.45. What are the different sesamoid bones present in the lower limb?
The following sesamoid bones are present in the lower limb:
- Patella, articulates with femur
- Two small sesamoid bones in the tendons of flexor hallucis brevis, articulate with the head of the first metatarsal bone
- One in the peroneus longus tendon, articulates with cuboid
- Others may be present in the tendons of tibialis anterior, lateral head of gastrocnemius and gluteus maximus.

Q.46. What is 'Febella'?
It is a small, rounded sesamoid bone present in the lateral head of gastrocnemius. It articulates with the posterior surface of the lateral condyle of femur.

BONES OF FOOT

Q.47. Name the tarsal bone of foot.
- *Proximal row:* Talus, calcaneum
- *Distal row:* Cuboid and medial, intermediate and lateral cuneiform. Navicular is interposed between the two rows.

Q.48. Name the structures attached to medial tubercle of calcaneum.
Medially:
- Origin of abductor hallucis
- Flexor retinaculum.

Anteriorly:
- Origin of flexor digitorum brevis
- Plantar aponeurosis.

Q.49. Name the structures attached to lateral tubercle of calcaneum.
Origin of abductor digiti minimi.

Q.50. Name the tendons related to peroneal trochlea of calcaneum.
Above: Tendon of peroneus brevis.
Below: Tendon of peroneus longus.

Q.51. What are the structures attached to sustentaculum tali?
To its medial margin are attached:
- Spring ligament, anteriorly
- Slip from tibialis posterior, in middle
- Superficial fibers of deltoid ligament, along its whole length
- Medial talocalcaneal ligament, posteriorly.

Q.52. What is the structure attached to tuberosity of navicular bone?
Insertion for tibialis posterior.

Q.53. Name the structures related to plantar groove of cuboid.
- Through groove pass tendon of peroneus longus
- To posterior ridge, deep fibers of long plantar ligament.

JAYPEE BROTHERS

Q.54. At what time the ossification center for cuboid appears?
Just before or after birth.

Q.55. What are the differences between metacarpal and metatarsal?

Metacarpal	*Metatarsal*
Head and shaft: Prismoid	Flattened from side to side
Shaft: Uniform thickness	Tapers distally
Dorsal surface of shaft:	Elongated, flat triangular area Uniformly convex
Base: Irregular	Cuts sharply and obliquely

Q.56. What are the "accessory bones"?
These are separate small pieces of bone which have not fused with the main bone, e.g.
- Os trigonum (posterior tubercle of talus)
- Os vesalianum (tuberosity of fifth metatarsal).

Q.57. What is 'bunion'?
It is inflamed adventitial bursa over the head of first metatarsal bone.

JOINTS OF LOWER LIMB

HIP Joint (Fig. 3.2)

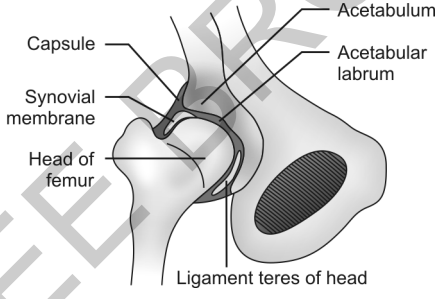

Fig. 3.2: Hip joint

Q.58. What is the type of hip joint?
Hip joint is a ball and socket type of synovial joint.

Q.59. What are the factors which increase the stability of the hip joint?
The stability of hip joint is increased by the following factors:
- Depth of acetabulum with a narrow mouth, made by acetabular labrum
- Tension and strength of ligaments
- Strength of the surrounding muscles
- Length and obliquity of neck of femur.

The wide range of mobility depends upon the neck of femur which is narrower than the equatorial diameter of the head.

Q.60. What is the attachment of ligament of the head of femur?
It is attached laterally to fovea on head of femur and medially to two ends of acetabular notch and to transverse ligament.

JAYPEE BROTHERS

Q.61. What are the ligaments strengthening the capsule of hip joint?

- Iliofemoral ligament: Strongest, Y-shaped ligament
- Pubofemoral ligament
- Ischiofemoral ligament (Figs 3.3A and B).

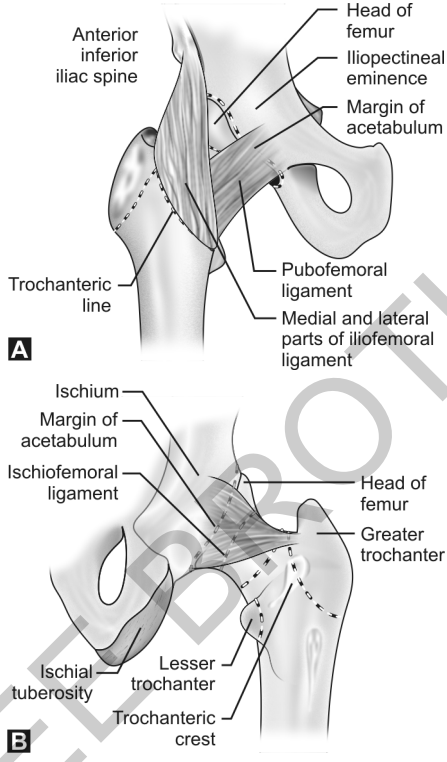

Figs 3.3A and B: Hip joint, A. Anterior aspect. B. Posterior aspect. The capsular attachments (blue) and epiphyseal lines (magenta) are shown

Q.62. What are the relations of the hip joint?

The relations of the hip joint are:

- *Anteriorly:* Lateral fibers are pectineus, iliopsoas, straight head of rectus femoris
- *Posteriorly:* Quadratus femoris covering obturator externus and ascending branch of medial circumflex femoral artery, the piriformis, obturator internus with two gemelli separate the sciatic nerve from the nerve to quadratus femoris
- *Superior:* Reflected head of rectus femoris covered by gluteus minimus
- *Inferior:* Lateral fibers of pectineus and obturator externus.

Q.63. What is the blood supply to the hip joint?

The hip joint is supplied by the medial circumflex femoral and the lateral circumflex femoral vessels (Fig. 3.4). There also may be contribution by the acetabular branch of femoral artery.

JAYPEE BROTHERS

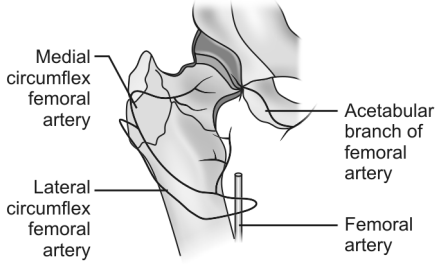

Fig. 3.4: Blood supply of hip joint

Q.64. What are the axes of different movements of hip joint?
- For rotation, vertical axis passing through the center of head of femur and its lateral condyle
- Extension and flexion, occur around a transverse axis
- Adduction and abduction, occur around an anteroposterior axis.

Q.65. What are the range of movements at the hip joint?
Flexion is limited by contact of thigh with anterior abdominal wall.

Adduction is limited by contact with opposite limb.

Range of other movements: Lateral rotation 60°, medial rotation 25°, abduction 50° and extension 15°.

Q.66. What are the nerves supplying the hip joint?
The hip joint is supplied by:
- Femoral nerve, through nerve to rectus femoris
- Anterior division of obturator nerve
- Accessory obturator nerve
- Nerve to quadratus femoris
- Superior gluteal nerve.

Q.67. What are the different muscles producing extension of the hip joint?
Gluteus maximus and hamstrings.

Q.68. Which muscles produce abduction of the hip joint?
Chief muscles: Gluteus medius and minimus.
Accessory muscles: Tensor fasciae latae and sartorius.

Q.69. What is Trendelenburg test?
This test is employed for testing the stability of the hip joint. A positive test indicates a defect in osseomuscular stability, especially abductors of hip joint and the patient has a "lurching" gait. If the patient is asked to stand on one leg. If the abductors of thigh are paralyzed on that side, they will be unable to sustain the pelvis against the body weight and pelvis tilts downwards on unsupported side.

Q.70. Name the adductors of hip joint.
- Adductor longus
- Adductor magnus
- Pectineus.
- Adductor brevis
- Gracilis

JAYPEE BROTHERS

Q.71. Name the medial rotators of hip joint.
Gluteus medius and minimus:
- Tensor fasciae latae
- Adductor longus, brevis and magnus.

Q.72. Name the flexors of hip joint.
Mainly: Psoas major, iliacus, rectus femoris
Accessory muscles: Adductors are also flexors of hip joint.

Q.73. What is the cause of Weaver's bottom?
Inflammation of bursa over ischial tuberosity.

Q.74. In which injury of the hip joint sciatic nerve is likely to be damaged?
It is likely to be injured in the posterior dislocation of the hip joint associated with fracture of the posterior lip of the acetabulum, to which the nerve is closely related.

KNEE JOINT

Q.75. What is the function of anterior and posterior cruciate ligament?
- *Anterior cruciate ligament:* Prevents hyperextension of knee joint.
- *Posterior cruciate ligament:* Prevents hyperflexion of knee joint.

Q.76. What is compartment syndrome?
It is an increase in fluid pressure (> 30 mm) within an osseofascial compartment and lead to muscle and nerve damage. Usually occur in anterior compartment of thigh as a result of crush injury can also occur in anterior compartment of leg due to fracture of the tibia.

Q.77. What is Legg-Perthes disease?
It is characterized by idiopathic avascular necrosis of the head of femur. Caucasian boys are more commonly affected and it is usually characterize by unilateral hip pain external rotation (slight) and a limp.

Q.78. What type of joint is the knee joint?
Compound synovial joint, having:
- *Condylar synovial joint:* Between the condyles of femur and tibia
- *Saddle synovial joint:* Between femur and patella (Fig. 3.5).

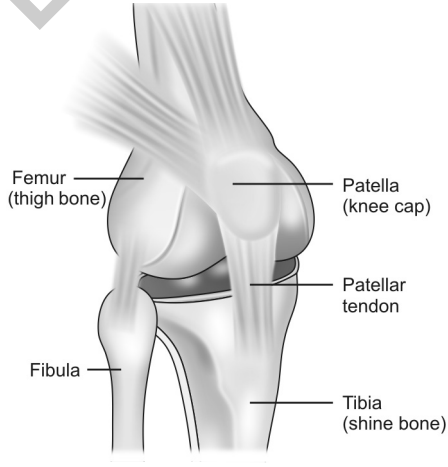

Fig. 3.5: The knee joint

JAYPEE BROTHERS

Q.79. What are the articular surfaces in knee joint?
Condyles of femur:
- Condyles of tibia
- Patella.

Q.80. What are the bony landmarks in the region of the knee?
Adductor tubercle: It is felt just above the medial condyle of the femur.
Head of the fibula: It is felt at posterolateral aspect of the knee. Lies 1.5 cm below the level of the knee joint.
Tibial tubercle: It is felt in front of the knee in upper part of the tibia.
Tibial condyles: They are felt on each side of the lower part of the ligamentum patellae.

Q.81. Name the ligaments of knee joint.
- Fibrous capsule
- Ligamentum patellae
- *Collateral ligaments:* Tibial and fibular
- *Popliteal ligaments:* Oblique and arcuate
- *Cruciate ligaments:* Anterior and posterior
- *Meniscus:* Medial and lateral
- Transverse ligament (Figs 3.6A and B).

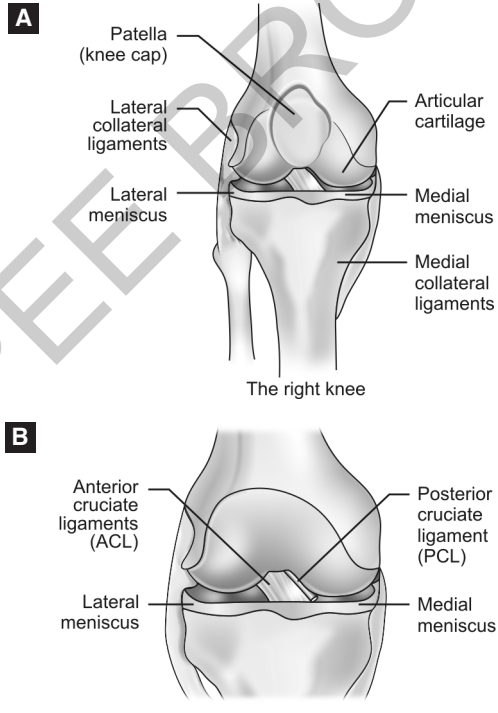

Figs 3.6A and B: Ligament of the knee joint

Q.82. What is coronary ligament?
It is the part of fibrous capsule lying between the menisci and tibia.

JAYPEE BROTHERS

Q.83. What are the openings in the fibrous capsule of knee joint?
1. For suprapatellar bursa.
2. For the exit of tendon of popliteus with its synovial bursa.

Q.84. What are the attachments of arcuate popliteal ligament?
It passes from the head of fibula to the posterior margin of the intercondylar area of tibia.

Q.85. What are the attachments of oblique popliteal ligament?
It arises as an expansion from the tendon of semimembranous. It blends with the posterior surface of fibrous capsule. It is attached to the intercondylar line and lateral condyle of femur and posterior aspect of medial condyle of tibia.

Q.86. Name the structures piercing oblique popliteal ligament.
1. Posterior division of obturator nerve
2. Middle genicular nerve and vessels.

Q.87. What are menisci and what are their functions?
These are two fibrocartilaginous structures, semilunar in shape, which make the tibial articular surface deeper and divide the joint cavity partially into upper and lower compartment (Fig. 3.7).

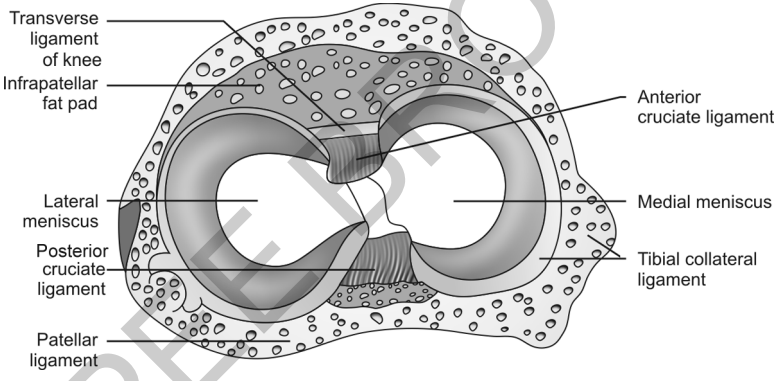

Fig. 3.7: Knee menisci

Functions:
- They act as shock absorbers
- They make the articular surfaces more congruent. They can adapt to varying curvatures of different parts of femoral condyles.

Q.88. What are the arterial supplies of knee joint?
- Genicular branches of popliteal artery
- Descending genicular branch of femoral artery
- Descending branch of lateral circumflex femoral artery
- Recurrent branches of anterior tibial artery
- Circumflex fibular branch of posterior tibial artery.

Q.89. Name the arteries forming the anastomosis around the knee joint.
Medially:
- Descending genicular

JAYPEE BROTHERS

- Superior medial genicular
- Inferior medial genicular

Laterally:

- Descending branch of lateral circumflex femoral
- Superior lateral genicular
- Inferior lateral genicular
- Anterior lateral recurrent
- Posterior lateral recurrent
- Circumflex fibular (Fig. 3.8).

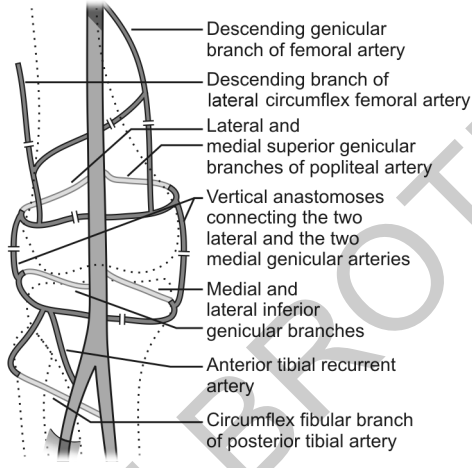

Fig. 3.8: Anastomoses around the knee joint

Q.90. What are the nerve supplies of knee joint?

1. Femoral nerve
2. Genicular branches of tibial and common peroneal nerves
3. Posterior division of obturator nerve.

Q.91. What are the movements possible at knee joint?

- Flexion
- Extension
- Medial and lateral rotation.

Q.92. What is 'conjunct' and 'adjunct' rotation?

- *Conjunct rotation:* Rotation of knee joint combined with flexion and extension
- *Adjunct rotation:* Rotation of knee joint occurring independently in a partially flexed knee.

Q.93. What are the changes in the axis of movement of the knee joint with flexion and extension?

The flexion and extension of the knee joint takes place on a transverse axis which shifts along with the movements. Because of the spiral profiles of the femoral

JAYPEE BROTHERS

For detailed information on nursing books, visit our website **www.jaypeebrothers.com,** for detailed information

ANATOMY, PHYSIOLOGY and BIOCHEMISTRY

Made Easy for Nurses

Salient Features

- An exclusive viva voce paper-oriented text for nursing students
- Provides over 5,000 questions with to-the-point answers on Anatomy, Physiology and Biochemistry
- Presents the text in simple and easy-to-grasp format, adequately equipped with appropriate illustrations, tables, charts, etc.
- Meant for aid and assistance to the nursing examination and for removing all the fears from the students' mind
- Helpful in quick revision in viva voce as well as short-answer theory papers.

Anjula Vij is graduated from Ramaiya Medical College, Bengaluru, Karnataka, India. She is a very keen writer and currently settled and working in a hospital at St Louis, USA.



Available at all medical bookstores or buy online at www.jaypeebrothers.com

JAYPEE BROTHERS
Medical Publishers (P) Ltd.
www.jaypeebrothers.com

Join us on facebook.com/JaypeeMedicalPublishers

ISBN 978-93-5152-622-3