ers.com, for detailed information on orthopedic books, visit our website www.jaypeebrothers.com, for detailed information on orthopedic books

Dhiren Mahida

Handbook on Flaps in CRUSH INJURIES of the HAND

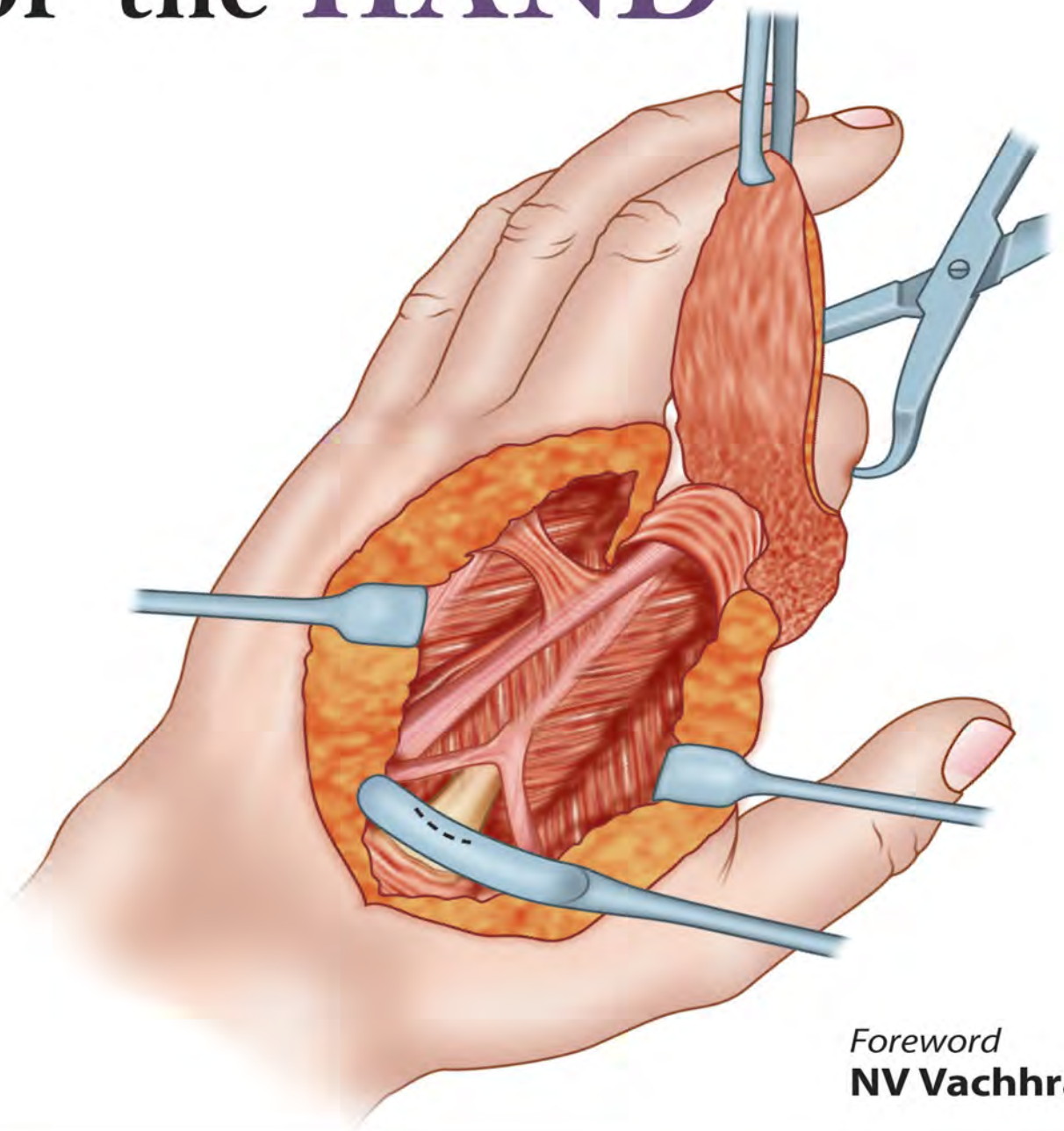

Foreword
NV Vachhrajani

CONTENTS

1. Introduction **1–6**
Terminology *1*
Aims of Management in Hand Injuries *3*
Assessment of Injury *4*
Surgical Procedures/Options Available *4*

2. Debridement **7–8**
Method *7*

3. Healing by Secondary Intention **9–12**

4. Fasciotomy **13–17**
Signs and Symptoms *13*
Clinical Features *13*
Persistent Pain, that is Progressive and Unrelieved by Immobilization and Increased by Passive Stretching, is the Hallmark of a Developing Compartment Syndrome *13*
Other Investigations *14*
Treatment *14*

5. Free Skin Grafts **18–20**
Split Thickness Graft *18*
Full thickness Graft *20*

6. Vacuum-assisted Closure **21–22**

7. Local Flaps (Principles and Techniques) **23–107**
Principles and Techniques in Flap Coverage *23*
Rotation and Transposition Flap *23*
Lateral Digital Flap *27*
Advancement Flap *27*
Rhomboid Flap of Limberg *28*
Dufourmental Flap *30*
Dorsal Digital Advancement/Regression *31*
The Dorsal Reverse Adipofascial Flap for Fingertip Reconstruction *32*
Z-Plasty Techniques *35*
Simple Z-Plasty of Thumb Web Space *36*
Hueston Flap *38*
Souquet Flap *40*
V-Y Advancement *41*
Bilateral Kutler's V-Y Plasty *43*
Venkataswami-Subramanian Flap *45*
Palmar Bipedicle Advancement Flap *47*
Joshi's Dorsolateral Neurovascular Island Flap *49*
Palmar Digital Monopedicle Flap *52*
Distally Based Digital Island Flap *55*
Annular flap *58*
Local Flaps (Flaps From Adjacent Fingers/Hand/Forearm) *59*
The Cross-Finger Flap *59*
Classical Laterally Based Flap *59*
Distally Based Cross-Finger Flap *63*
Proximally Based Cross-Finger Flap (Flag-Flap Variant) *65*
Reverse Cross-Finger Flap *66*
Radial Sensory Nerve Innervated Cross-Finger Flap *68*
Innervated Cross-Finger Flap *71*

Dual Innervated Cross-Finger Flap *72*
Turkish Flap (C-Ring Cross-Finger Flap) *74*
Cross Finger Flap Over-Riding A Cross Finger Flap *75*
Flap on a Flap on a Flap *76*
Dorsal to Dorsolateral Coverage (Dorsal Middle Phalangeal Artery Flap) *80*
Results of Cross-Finger Flap *84*
Dorsal Metacarpal Artery-Based Flaps *85*
Flag Flap *85*
Kite Flap *87*
Dorsal Metacarpal Flaps: Distally Based 2nd Dorsal Metacarpal Artery Flap *92*
Variations Of Dorsal Metacarpal Artery/Flag Flap *95*
Reverse Ulnar Parametacarpal Artery Flap *96*
Thenar Flaps *97*
Reversed Radial Artery Forearm Flap (Chinese Flap) *100*
Ulnar Artery Forearm Flap *104*
Posterior Interosseous Artery Flap *105*

8. Distant Flaps **108–124**
Types *108*
Random Pattern Distant Flaps *108*
Reversed Deltopectoral Flap *108*
Deltopectoral Flap *111*
Groin flap *113*

9. Flaps Using Dead Bone as Graft **125–128**
Composite grafting *125*

10. Interesting Clinical Cases **129–140**
Case 1 129
Case 2 131
Case 3: Crushed hand with Extensive Devitalization *134*
Case 4: Crush injury of Middle, Ring and Little Finger *136*
Case 5 *137*

11. Amputations **141–158**
Indications *141*
Principles and Goals of Amputation *141*
Digital Tip Amputations *142*
Metacarpal Ray Amputation *143*
Reconstruction in Amputation *148*
Fillet Flaps *148*
Phalangization of Metacarpal by Web Space Deepening *149*
Phalangization of the Metacarpal Head (Modified) *150*
Pollicization of an Index Finger Stump *152*
The Gilles Cocked-Hat Flap *157*

12. Splints and Fixtures in Crush Injuries **159–163**
Splints *159*
JESS Fixtures *159*

13. Microvascular Techniques **164–166**
Indications *164*
Relative Contraindications *164*
Patient Selection *164*
Transport of Amputated Part/Preservation *164*
Instruments *164*
Surgeon Requirements *164*
Techniques *165*
Other Practical Methods *166*
Measures to Salvage a Failing Flap *166*

Bibliography *167–169*
Index *171–174*

Fasciotomy

4

Fasciotomy is an armament that has to be frequently and judiciously used in hand and upper limb surgeries following compartment compression syndrome.

Compartment syndrome is a group of symptoms and signs that result from increased pressure within a limited space compromising the circulation and function of tissues in that space.

The following types can be described:

1. Acute compartment syndrome.
2. Subacute compartment syndrome.
3. Recurrent or chronic compartment syndrome.
4. Crush syndrome.
5. Volkmann's ischemic contracture (sequel of compartment syndrome).

Acute compartment syndrome has signs and symptoms associated with compartment syndrome.

Subacute compartment syndrome does not have the signs and symptoms normally associated with a compartment syndrome but the sequel of syndrome will appear subsequently, e.g. progressive muscle contracture in the absence of pain.

Recurrent or chronic compartment occurs in athletes who experience pain and tight compartment with a particular exercise.

Volksmann contracture is the end-point/sequel of the above with contracted functionless ischemic or dead muscles and insensate paralyzed nerves.

SIGNS AND SYMPTOMS

A high degree of suspicion and alertness must be kept to diagnose compartment syndrome.

Muscles can tolerate ischemia for 4 hours, by 6 hours the effect is uncertain and by 8 hours irreversible changes occur.

Peripheral nerves can conduct impulses for 1 hour; can survive 4 hours with only neuropraxic damage and after 8 hours irreversible changes occur.

CLINICAL FEATURES

1. **Pain on passive stretching**. This is the most reliable indicator of a compartment syndrome because spontaneous pain may be modified by analgesics or long-acting nerve blocks.
2. **Diminished sensation** is the second reliable indicator of nerve ischemia.
3. Weakened and/or diminished muscle function, that is progressive, is an important indicator.
4. Tense and tender compartment on palpation are indicative of developing compartment compression syndrome.

PERSISTENT PAIN, THAT IS PROGRESSIVE AND UNRELIEVED BY IMMOBILIZATION AND INCREASED BY PASSIVE STRETCHING, IS THE HALLMARK OF A DEVELOPING COMPARTMENT SYNDROME

Differential Diagnosis

1. Compartment syndrome
2. Nerve injury
3. Arterial injury.

Documentation of compartment pressure is important in the patients having communication problems, head-injury patients, where vascular injuries produce tissue ischemia and, at the same time, appear to have compartment syndrome. This method must not take precedence over clinical signs and symptoms of compartment because there are many limitations and scope for errors in these measurement techniques.

Techniques

1. Infusion technique of Whitesides
2. Slit catheter technique of Mubarak
3. Continuous monitoring technique of Matsen
4. Intracompartmental pressure monitoring systems.

Indications for Fasciotomy

Fasciotomy is indicated/recommended in:

- Normotensive patients with positive clinical findings with intracompartmental pressure greater than 30 mm Hg and when duration of increased pressure is unknown or thought to be less than 8 hours
- Uncooperative or unconscious patients with compartment pressure greater than 30 mm Hg for less than 8 to 10 hours
- Patients with low blood pressure where compartment pressure is 20 mm Hg below diastolic blood pressure and the duration of increased pressure is less than 8 to 10 hours.

OTHER INVESTIGATIONS

1. *Intrinsic muscle compartment pressure normally* is less than 15 mm Hg. Measurement is not usually reliable.
2. *Direct nerve stimulation:*
   Nerve stimulation of a viable muscle produces a muscle response ischemic muscle will not contract, whereas paralyzed muscle will contract.
3. *Arteriography:*
   Helps in the evaluation of arterial injury and blockage. It is of no value in the diagnosis of compartment syndrome.
4. *Doppler study:*
   Good blood flow and compartment syndrome can coexist and so this study can mislead in the diagnosis of compartment syndrome.
5. *Computed tomography:*
   It is of no value in diagnosing acute compartment syndrome. It can tell the extent of necrosis in an established case but not in an acute setting.
6. *Magnetic Resonance Imaging* cannot measure intracompartmental pressure and can only reveal muscle status.
7. *Pulse oxymetry:*
   This is not useful in the diagnosis of compartment syndrome except to know whether the tissues are being perfused or not.

TREATMENT (FIGURES 4.1 AND 4.2)

Immediate fasciotomy is the treatment of choice in acute compartment syndrome. Ice application, elevation and sympathetic block have no place in the management because maximum vasodilatation is already present.

The releasing incision starts as a carpal tunnel incision, follows the crease of the wrist to the ulnar side of the forearm and then upward toward the elbow in a curvilinear or zig-zag manner. Median nerve is released at the carpal tunnel through a palmar incision in the valley between the thenar and hypothenar eminence, avoiding the palmar cutaneous branch of the median nerve by curving the incision ulnarward at the wrist. Release the ulnar nerve at the Guyon's tunnel through this incision. Moving proximally curve the incision radially and finally again curve towards the ulna at the elbow. At the elbow, the incision is just radial to the medial epicondyle. This incision avoids cutaneous nerves; helps release both the nerves and prevents contracture at the elbow and wrist. Four interconnected compartments are released: (i) The superficial volar; (ii) the deep volar; (iii) the mobile wad of Henry (brachioradialis and extensor carpiradialis longus and brevis); and (iv) dorsal compartment.

The dorsal compartment is released through a straight linear incision.

The dorsal and volar interosseous muscles are released through two longitudinal incisions on the dorsum of the hand over the second and fourth metacarpals.

Fasciotomy in the finger is now done, if deemed necessary, by releasing incisons on the nondominant side of fingers. This is usually the ulnar side of index, middle, and ring fingers and the radial side of little finger and thumb. A midaxial lateral incision, along the white line, dissection is superficial to the flexor tendon, releasing all the vertical bands.

Following the release, the median nerve is covered by tacking the radially based wrist flap over the median nerve. Depending on the severity of swelling, split-thickness skin grafting or delayed closure can be considered.

Proper compressive dressing, wrist dorsiflexion, and splintage in functional position of hand are essential.

Elevation of limb above the level of the heart postoperatively is helpful in reducing swelling and promoting drainage. But remember that elevation of a nondecompressed arm reduces perfusion and increases tissue hypoxia and, hence, **elevation preoperatively before decompression should not be done**.

Postoperative scars are hypertrophic and have to be treated appropriately but this is a small price to pay for the preservation of hand function.

Incision can be curved on the mid-forearm as depicted in Figure 4.2A. instead of using only ulnar incision.

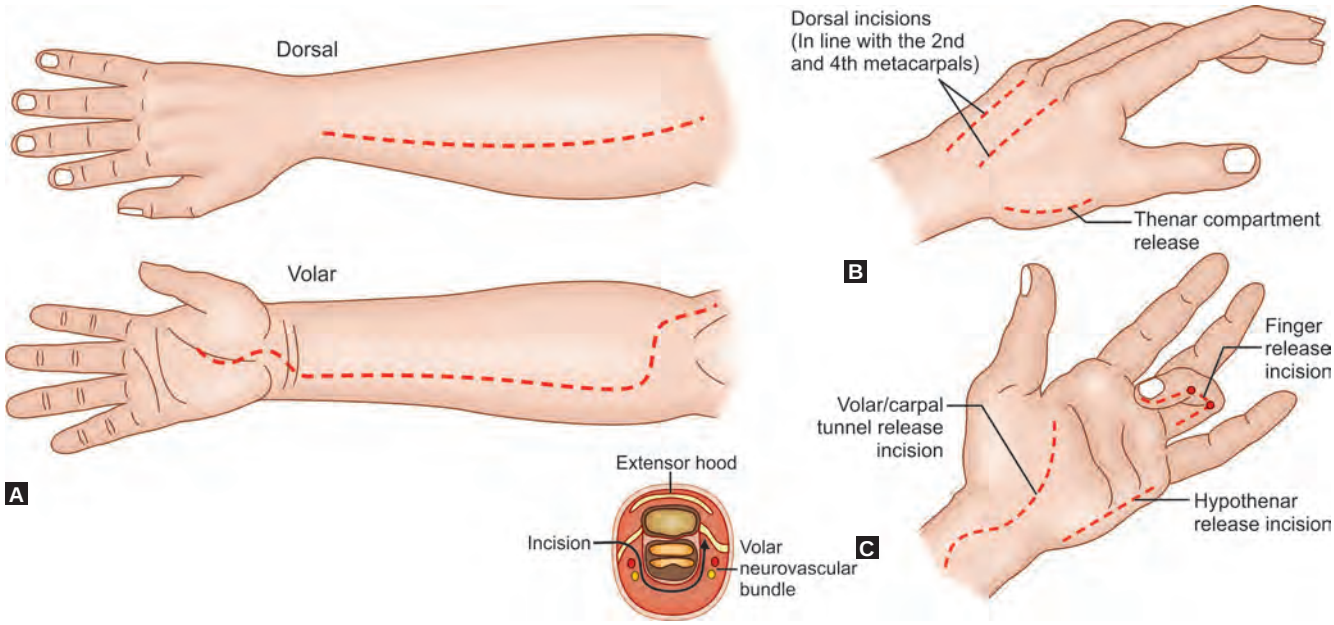

Figs 4.1A to C: (A) Forearm fasciotomy incisions; (B) Dorsal incisions; (C) Finger/hand compartment release

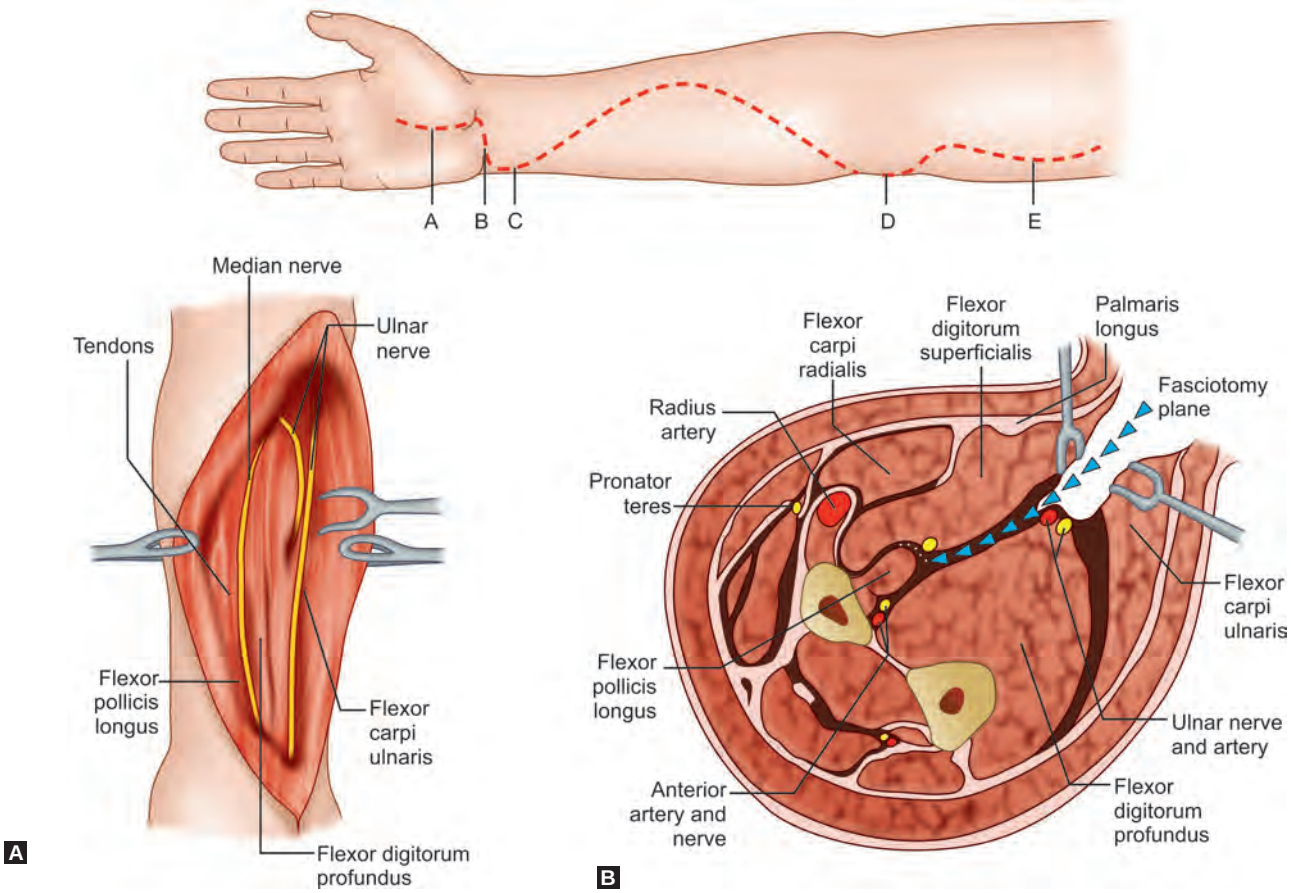

Figs 4.2A and B: (A) Mid-forearm incision; (B) Cross section of arm

Example 1 (Figs 4.3A to E): It depicts how, on releasing the compartments, soft tissues expand and regain their vascularity. Delayed split thickness grafting was done after two days once the soft tissue viability was clearly demarcated.

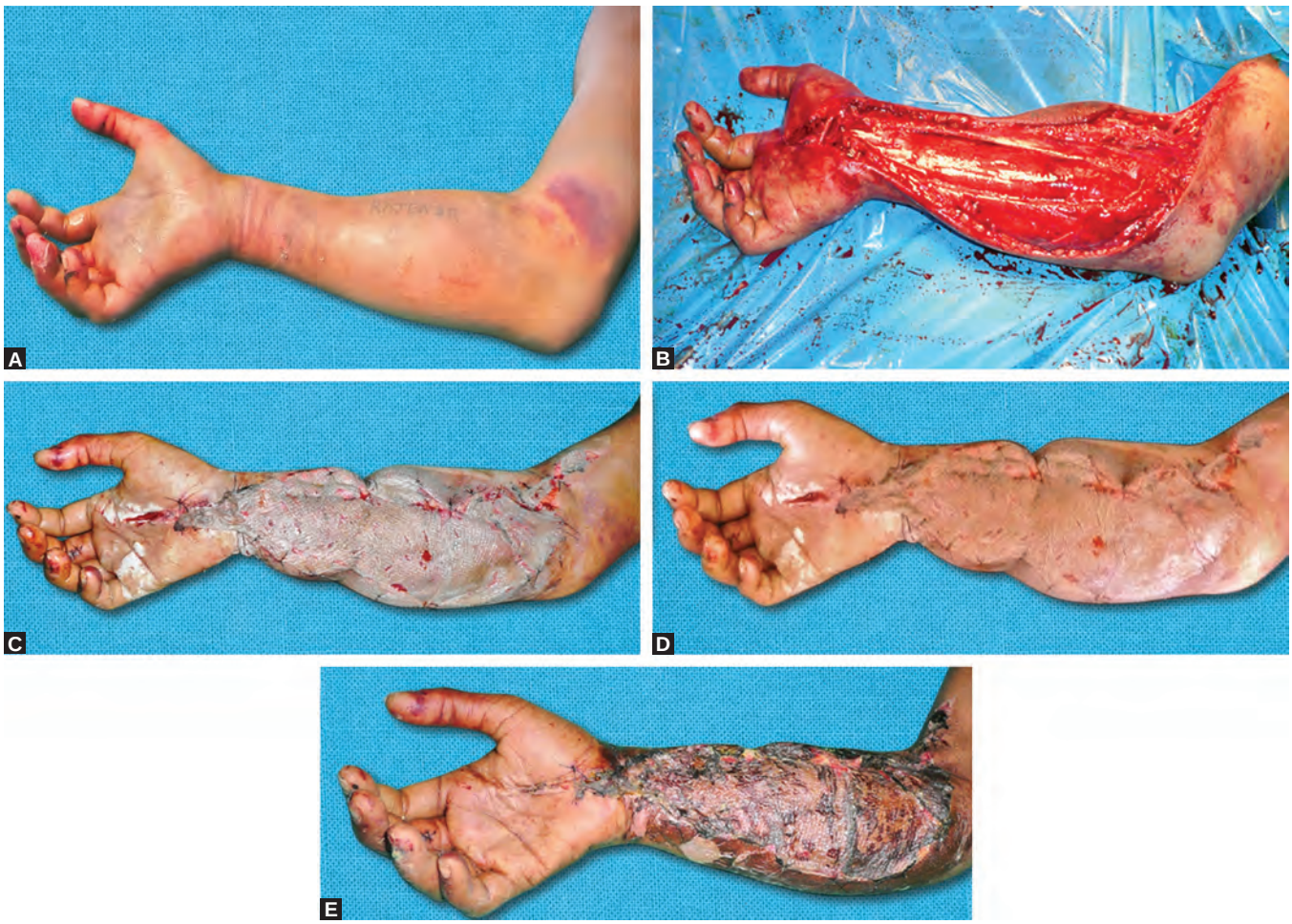

Figs 4.3A to E: (A) Injury with tense compartment compression syndrome; (B) Immediate postoperative status after fasciotomy; (C) Primary split thickness graft done as wound was clean and healthy; (D) Status after one week; (E) Status two weeks after surgery showing graft incorporation and resolving soft tissue swelling with preserved hand function

Example 2 (Figs 4.4A to F)

Compression injury with developing compartment compression syndrome with thermal burns that are commonly encountered in industrial crush injuries in textile industries.

Extensive fasciotomy extending from the wrist to the elbow along with excision of dead non viable tissues and primary skin grafting was done. Primary skin grafting used selectively and judiciously gives the best result because graft have chance for incorporation before bacterial colonization occurs.

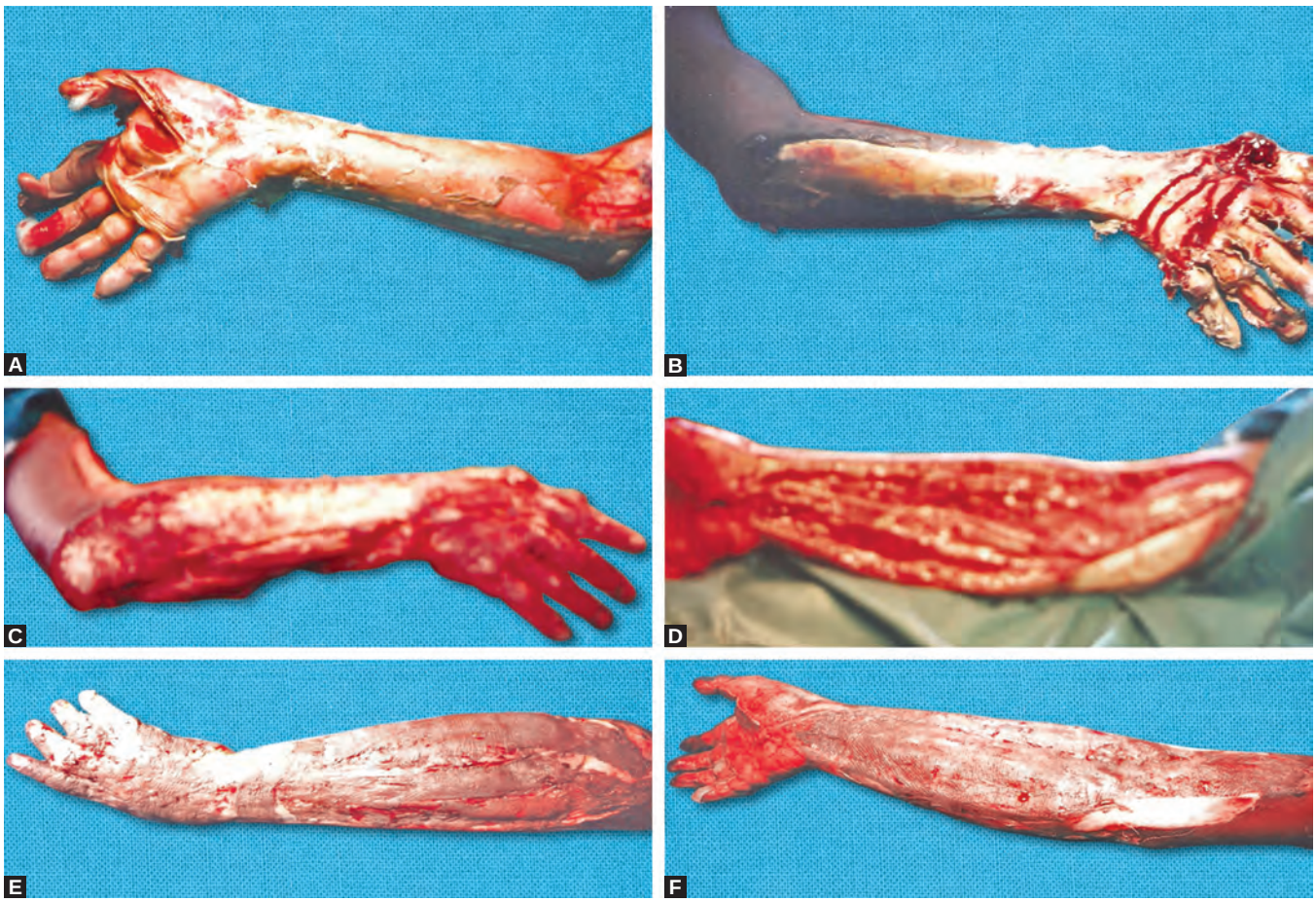

Figs 4.4A to F: (A and B) Depict extensive compression injury along with thermal burns following entrapment of hand and forearm in roller machine that also generated heat that led to acute compartment syndrome in volar and dorsal compartments; (C and D) Reveal state after radical debridement and fasciotomy as well as carpal tunnel release; (E and F) Reveal immediate postoperative status following primary split thickness grafting

or detailed information on orthopedic books, visit our website www.jaypeebrothers.com, for detailed information on orthopedic books, visit our we

Handbook on Flaps in Crush Injuries of the Hand

Salient Features

- Seeks to provide to the trauma surgeon; an easy stepwise reference to various treatment options available in the treatment of avulsion, degloving and crush injuries of the hand.
- Cases illustrated are those encountered by the trauma surgeon, in his day-to-day practice.
- Endeavors to arm the young and new entrants to hand trauma with a ready reckoner on the options available in the treatment of acutely traumatized hand.



Dhiren Mahida MS (Ortho) is practising as an orthopedic surgeon at Pooja Hospital, Udhana, Surat, Gujarat, India. He passed his MBBS in 1986 securing two gold medals in surgery from Government Medical College, Surat, Gujarat. He obtained his postgraduate (MS Ortho) degree from the same institute in 1990.

Practising in an industrial hub aroused his interest in the management of industrial crush injuries.

His paper on the cross finger flap was shortlisted in the best paper category at the Western India Regional Orthopedic Conference (WIROC), Mumbai, 1999 and also at the Indian Orthopedic Association (IOA) Annual Conference at Jaipur, 2000.

His paper—The Degloved Hand—A Limb Saving Attitude—won the best paper of the conference at WIROC, 2003.

He has a deep interest in rehabilitation of the amputees and has established an artificial limb-fitting center in his hospital that has provided amputees with a Jaipur limb at a minimum token cost.

He is active in various social and educational organizations and has organized and participated in various relief activities such as camps in earthquake-hit areas, blood donation camps and polio surgical camps.

Available at all medical bookstores
or buy online at www.jaypeebrothers.com

JAYPEE

JAYPEE BROTHERS
Medical Publishers (P) Ltd.
www.jaypeebrothers.com

Join us on facebook.com/JaypeeMedicalPublishers

Shelving
Recommendation
ORTHOPEDICS

ISBN 978-93-5152-641-4

9 789351 526414