cardiology books, visit our website www.jaypeebrothers.com, for detailed information on cardiology books

JAYPEE

ECG

for Beginners

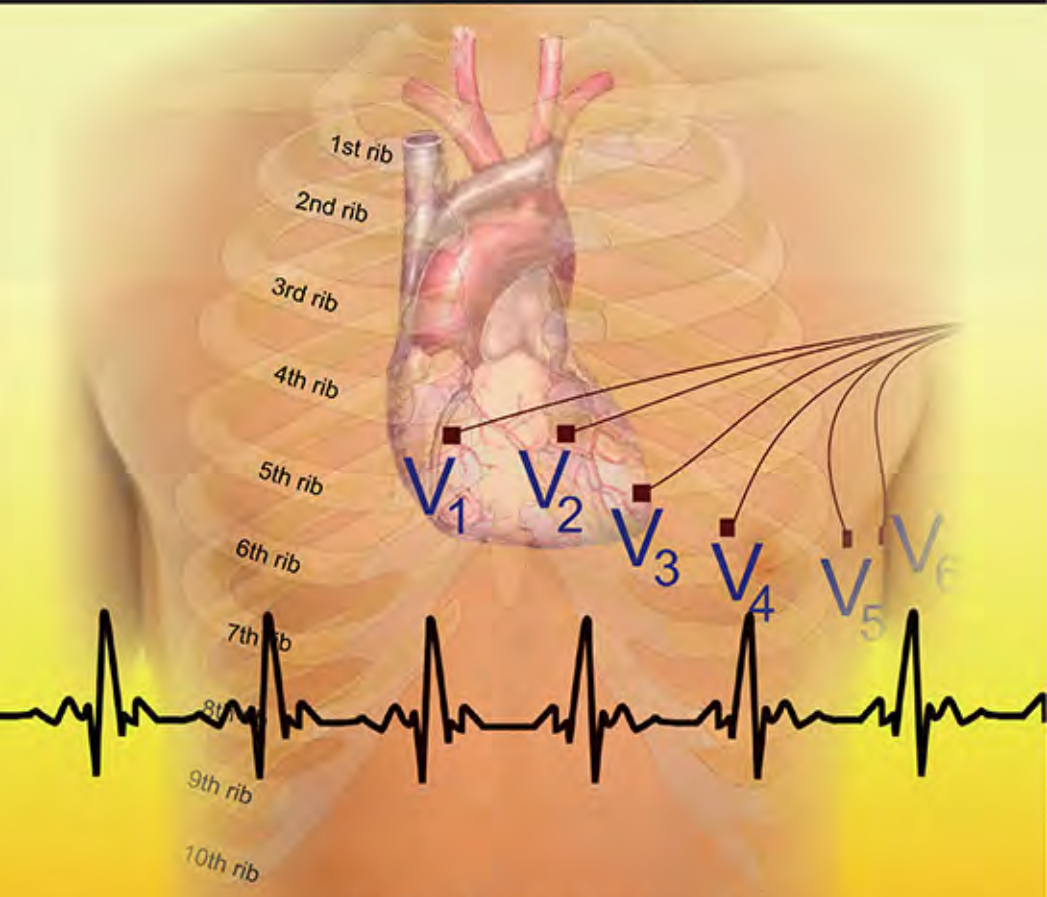

Anandaraja Subramanian
Raja J Selvaraj

Contents

1. **Basics of ECG** 1
   Conduction System of the Heart 2; Leads 3; Uses 5
2. **Heart Rate** 6
   Regular Rate 6; Irregular Rate 6; Derivation of the Short-Cut Method 7
3. **P Wave** 13
4. **QRS Complex** 22
   Calculation of Electrical Axis 23
5. **T and U Waves** 39
   T Wave 39; U Wave 39
6. **ST and PR Segments** 45
   ST Segment 45; PR Segment 45
7. **PR and QT Intervals** 51
   PR Interval 51; QT Interval 51
8. **Ectopic Beats, Escape Beats and Rhythms** 60
   Ectopic (Premature) Beats 60; Supraventricular Ectopic Beats 60; Ventricular Ectopic Beats 61; Wide QRS Complex Beats 61; Pre-excited Beats 61; Bundle Branch Block 62; Ventricular Paced Beat 63; Escape Beats and Rhythms 63
9. **Chamber Enlargement and Hypertrophy** 72
   Atrial Enlargement 72; Ventricular Enlargement 73
10. **Coronary Artery Disease** 82
11. **Heart Blocks** 92
    Atrioventricular Block 92; First Degree Block 92; Second Degree Block 92; Third Degree Block 93; Bundle Branch Blocks 93; Right Bundle Branch Block 93; Left Bundle Branch Block 94; Fascicular Blocks 94; Left Anterior Fascicular Block 94; Left Posterior Fascicular Block 94; Bifascicular and Trifascicular Blocks 94; Sinus Pause and Sinoatrial Block 95
12. **Arrhythmias** 106
    Narrow Complex Tachycardia 106; Irregular Rhythm 106; Regular Rhythm 107; Wide Complex Tachycardia 108; Ventricular Tachycardia 109; WPW Syndrome and Pre-excitation 109

13. Miscellaneous Conditions **120**

14. Synopsis
Basics 127; Leads 127; Wavefoms 127; Uses 128; Heart Rate Calculation 128; P Wave 128; QRS Complex 128; T Wave 129; U Wave 129; PR Interval 129; QT Interval 130; PR Segment 130; ST Segment 130; Ectopic Beats 130; Escape Beats and Rhythms 131; Wide Complex Beats 131; Chamber Enlargement/Hypertrophy 132; Coronary Artery Disease 132; Arrhythmias: Bradyarrhythmias 133; Atrioventricular Block 133; Bundle Branch and Fascicular Block 133; Sinus Node Disease 134; Arrhythmias: Tachyarrhythmia 134; Miscellaneous 136

15. Appendix **137**
Tachycardia 137; Bradycardia 137; Tall P Waves 137; Wide P Waves 137; Absent P Waves 138; Inverted P Waves (Leads II, III and aVF) 138; Inverted P Waves (Leads I and aVL) 138; Varying Morphology of P Waves 138; Wide QRS 138; RBBB 139; LBBB 139; LAHB 139; LPHB 139; Early Progression of QRS 139; Late Progression 139; Left Axis Deviation 140; Right Axis Deviation 140; Northwest/Extreme Axis Deviation 140; Low-Voltage QRS 140; High-Voltage QRS 140; Tall T Waves 141; Inverted T Waves 141; Broad T Waves 141; Prominent U Waves 141; Inverted U Waves 141; Short PR Interval 141; Long PR Interval 142; Long QT Interval 142; Short QT Interval 142; Elevated PR Segment 142; Depressed PR Segment 142; Elevated ST Segment 143; Depressed ST Segment 143; Irregular Rhythm 143; Pauses 143; Early Beat 143

Index *145*

Chapter

4 QRS Complex

The QRS complex is the recording of electricity produced by activation of the ventricular myocardium. 'Q' refers to the first negative wave, 'R' to the first positive wave and 'S' to the negative wave after 'R'. While all 12 leads record the QRS complex, the configuration of the QRS complex varies from one lead to another. Some leads record all the three components (Q, R and S), while some of them record only two components (QR, qR, RS, rS, Rs) and still some will record only one component (Q or R). The difference in configuration is due to the difference in orientation of the 12 leads. Irrespective of the number of components seen, all of them are generally referred to as QRS complex. Q waves are normally seen in lead III and lead aVR. Presence of any Q wave is abnormal in leads V1–V3. Q waves of more than one small square are abnormal in other leads.

The normal duration of the QRS complex is 80–100 ms (two to two-and-half small squares). One has to consider all the twelve leads in measuring the duration of the QRS complex. Amplitude of the QRS is measured from the peak (R wave) to the nadir (q or S wave) of the complex. Normally, the amplitude of the QRS complex is more than 5 mm in the limb leads and more than 10 mm in the chest leads. Values less than this are abnormal. There is no cut-off level for upper limit of QRS voltage. It varies with age, build of subject and myocardial mass. It has to be seen in the clinical context and we will discuss more about QRS voltages in a later chapter (Chamber Enlargement). In the precordial leads, the QRS complex shows progression. Beginning with a small R wave and deep S wave, there is a gradual increase in R wave amplitude and decrease in S wave amplitude from V1–V6. Leads V3 or V4 may record complexes with equal amplitude of R and S waves (equiphasic complex). Prominent R in lead V1 or V2 is called early progression. Absence of equiphasic complex by lead V4 is called late progression.

Normally, the QRS is inscribed as smooth strokes of the individual components. This indicates a rapid spread of depolarization wave

JAYPEE BROTHERS

and activation of the ventricles by the His-Purkinje fibers. When conduction is not occurring via the Purkinje fibers or when the conduction system is damaged, there will be a delay in the activation of the myocardium. This will be reflected in the ECG by widening of the QRS complex and presence of abnormal notches/slurs in the QRS.

CALCULATION OF ELECTRICAL AXIS

During electrical activation of the heart, there is an electric current in all directions produced by the moving activation wavefront. Electrical axis of the heart refers to the mean direction of activation (algebraic sum of all activation) of the heart. We can calculate the mean direction of activation of the atria (P waves) or the ventricles (QRS). Most commonly electrical axis of the ventricles in the frontal plane is calculated. Normally, the mean direction of activation of both the atria and ventricles is from right superior to left inferior in the frontal plane. The 6 leads that are in the frontal plane are I, II, III, aVR, aVL and aVF. These are oriented around the heart forming a hexaxial reference system in the frontal plane. The positive end of lead I (left arm) is designated zero and the negative end 180 degrees. The activation of the heart occurs along the direction of lead II (60 degrees). However, there is considerable variation in the axis and the normal range is from –30 (aVL) to +90 degrees (aVF). Axis between –30 and –90 is called leftward axis and between +90 and +180 is designated as rightward axis. Northwest axis is between +180 and –90 degrees.

A short-cut method to calculate the electrical axis of QRS is to look at leads I and II. If both show predominantly positive QRS, then the axis is normal. If QRS is positive in lead I and negative in lead II, then the axis is leftward. If the QRS is negative in lead I and positive in lead II, then the axis is rightward. If both leads I and II show predominantly negative QRS, then the axis is northwest.

The traditional method is to look for the lead showing equiphasic QRS complex, i.e. waveform showing equal R and S waves or Q and R waves. This means that the activation front is traveling perpendicular to that lead. Now look at the lead perpendicular to it. A predominant positive deflection means the axis is along the positive pole of the lead. The axis will be equal to the designated number assigned to the positive pole. A negative or predominant negative deflection means the axis is towards the negative pole of that lead.

JAYPEE BROTHERS

1. A 52-year-old male was seen in the cardiology OPD for occasional episodes of palpitations. ECG taken during this visit is shown. What is the QRS axis?

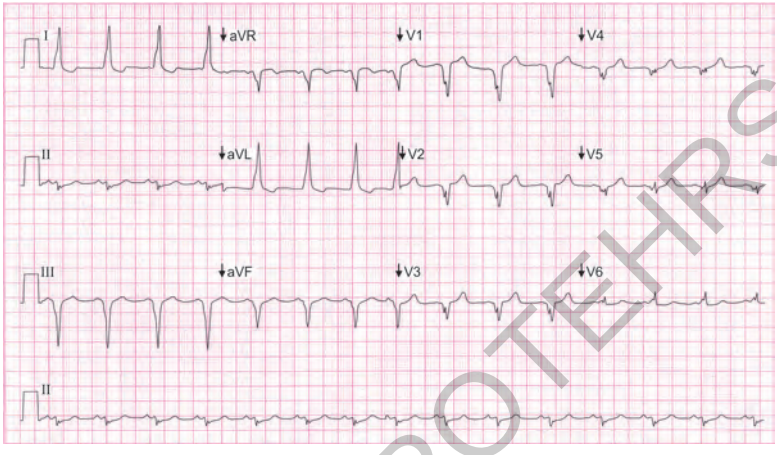

(a) Normal
(b) Leftward
(c) Rightward
(d) Northwest

Here lead I shows a positive QRS deflection and lead II is showing a predominant negative QRS deflection. Based on the short-cut method for calculation of the QRS axis, the axis is leftward. If we apply the traditional method, lead II shows the most equiphasic complex (though more negative), so the QRS vector will be perpendicular to lead II and parallel to lead aVL. Lead aVL shows a positive deflection. So the QRS axis will be around –30 degrees. Hence the QRS axis is leftward.

JAYPEE BROTHERS

2. A 40-year-old man was detected to have ECG abnormalities during preoperative work-up. The patient is otherwise asymptomatic. What is the QRS axis in the ECG?

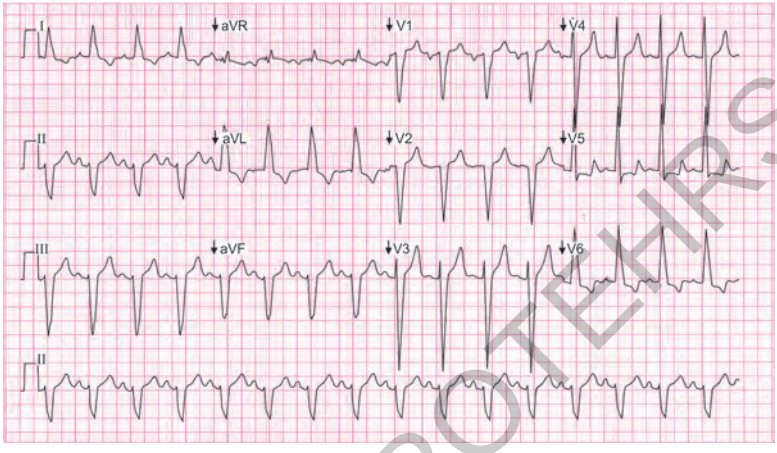

(a) Normal
(b) Leftward
(c) Rightward
(d) Northwest

In this ECG, lead I shows a positive QS complex and lead II shows a negative QRS complex. Hence, by applying the short-cut method, the QRS axis will be leftward.

JAYPEE BROTHERS

3. A 48-year-old lady complained of pricking left-sided chest pain of 2 days' duration. She is a diabetic and her elder sister had sustained myocardial infarction. An ECG was obtained. What is the QRS axis?

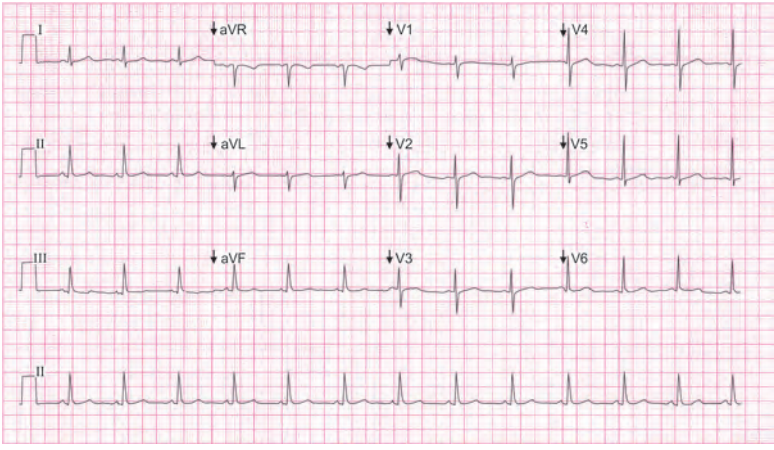

(a) Normal
(b) Leftward
(c) Rightward
(d) Northwest

In this ECG, both lead I and lead II are showing positive QRS complexes. So, the QRS axis is normal.

4. A 12-year-old boy was referred for evaluation of a cardiac murmur. Parents give a history of recurrent respiratory infections in childhood and failure to thrive. An ECG was taken. What is the QRS axis?

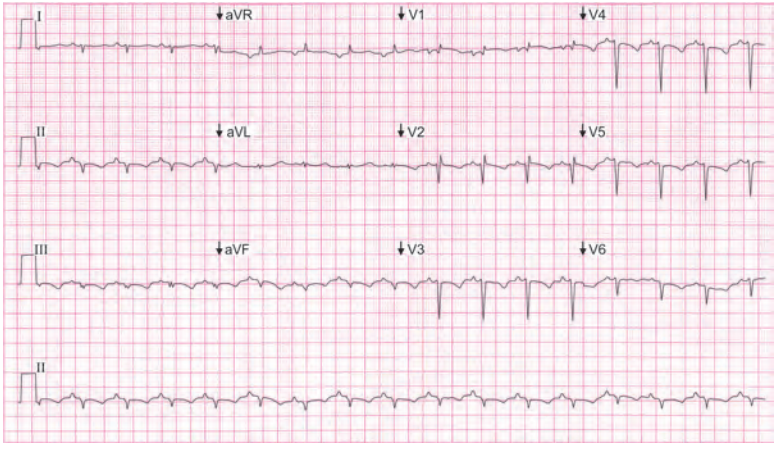

(a) Normal
(b) Leftward
(c) Rightward
(d) Northwest

In this ECG, both the lead I and lead II are showing negative QRS complexes. So, the QRS axis will be northwest.

5. A 50-year-old male underwent 12 lead ECG for the evaluation of atypical chest pain. What is the QRS axis?

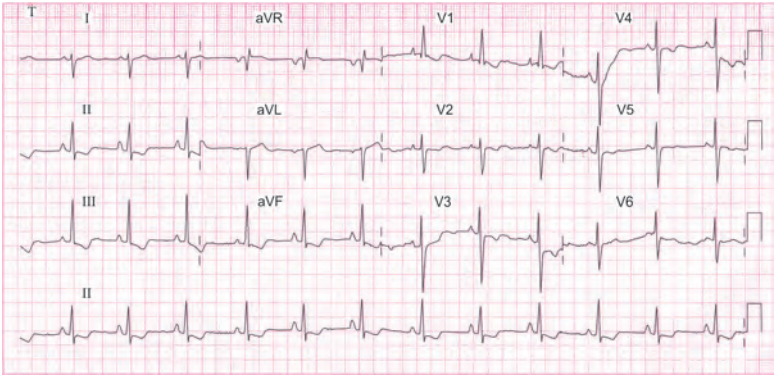

(a) Normal
(b) Leftward
(c) Rightward
(d) Northwest

In this ECG, lead I shows predominant negative deflection and lead II shows positive QRS complex. So, the axis of the QRS will be rightward. If we apply the traditional method, the most equiphasic complex is seen in lead aVR. So, the QRS vector is perpendicular to lead aVR and parallel to lead III. Lead III shows a positive deflection, meaning the vector is traveling towards the positive pole of lead III, which is +120 degrees. Thus, there is right axis deviation of the QRS complex.

6. A 40-year-old man complains of left-sided pricking constant chest pain of 3 days' duration. He smokes two packs of cigarettes a day and his elder brother had undergone coronary artery bypass surgery. Clinical examination was within normal limits. What is the abnormality in the QRS complex?

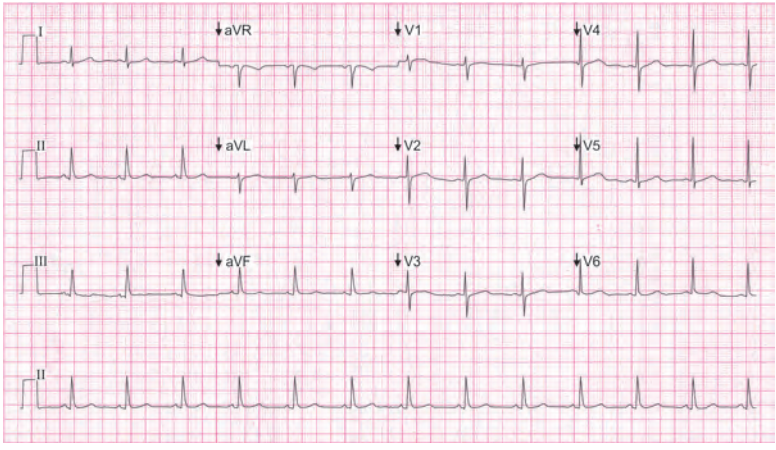

(a) Normal
(b) Wide QRS
(c) Early progression
(d) Late progression

In the ECG shown the duration of the QRS complex is normal and there is gradual increase in the amplitude of R wave from V1 to V6 indicating normal progression. So the QRS is normal.

7. A 22-year-old lady complains of recurrent episodes of palpitations associated with sweating and giddiness. The episodes terminate spontaneously. A resting 12 lead ECG was recorded. What is the abnormality in the QRS complex?

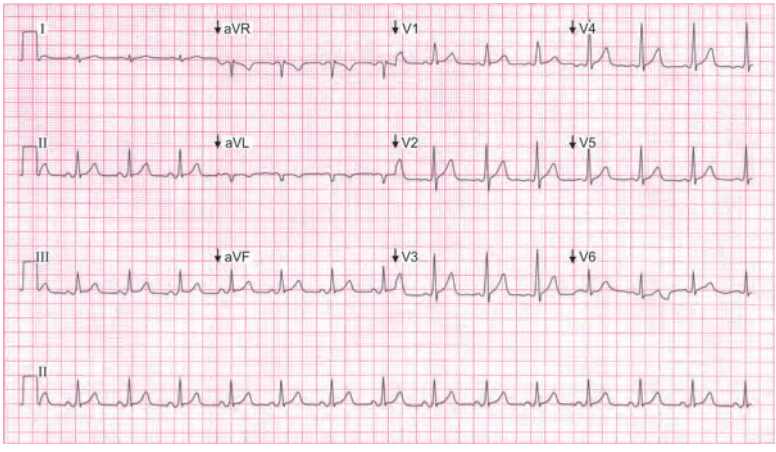

(a) Normal
(b) Wide
(c) Early progression
(d) Late progression

In this ECG, the QRS complexes in all the precordial leads show a positive deflection starting from lead V1. This is an example of early progression of the QRS complex.

8. A 56-year-old man was admitted to the intensive care unit for acute respiratory infection. He is a heavy smoker with chronic bronchitis. He complained of chest pain and an ECG was recorded. What is the abnormality in the QRS complex?

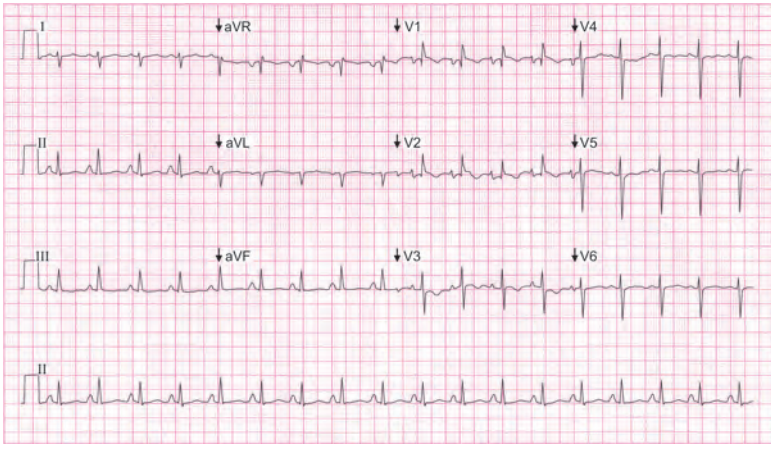

(a) Wide
(b) High amplitude
(c) Early progression
(d) Late progression

In this ECG, again there is predominant positive deflection in lead V1. Therefore, the abnormality seen is early progression.

9. A 64-year-old man complains of breathlessness on exertion for the past 6 months, which has been progressively increasing. Cardiovascular examination was significant for a third heart sound. Chest X-ray showed cardiomegaly. What is the abnormality of the QRS complex in the ECG?

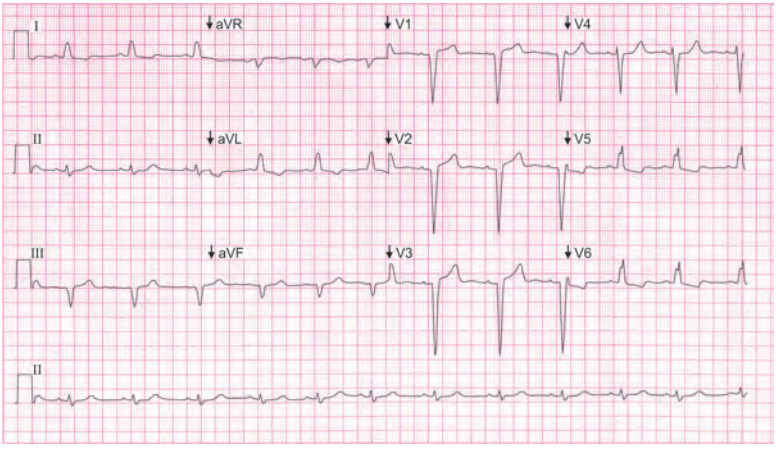

(a) Normal
(b) Low amplitude
(c) Early progression
(d) Late progression

In this ECG, there is predominant R wave of the QRS only in leads V5 and V6. This is an example of late progression of the R wave.

10. A 46-year-old man underwent general health check-up and was noticed to have some abnormality in the ECG. What is the abnormality seen in the QRS complex?

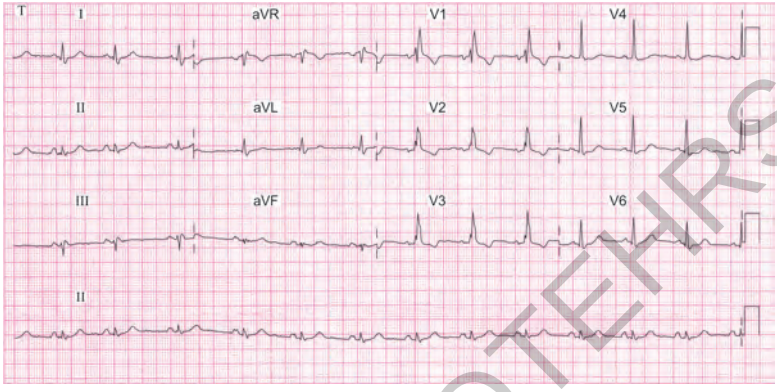

(a) Wide
(b) Wide and notched
(c) Late progression
(d) Low amplitude

The ECG shows QRS complexes that are wide (>120 ms) and are notched, which is better seen in leads V1-V3. QRS complex is produced by activation of the ventricles. Normal activation of the ventricles occurs by way of the His-Purkinje system (HPS). The conduction is very fast in the HPS and results in a normal (narrow) QRS complex. When there is conduction delay in HPS or abnormal activation of the ventricles, the QRS will be prolonged (wide) and will show notches.

JAYPEE BROTHERS

for detailed information on cardiology books, visit our website www.jaypeebrothers.com, for detailed info

ECG for Beginners

Salient Features

- Highlights the concepts in interpretation of ECG with practical examples
- Unique presentation of ECG concepts
- Illustrates by real-life ECGs for all examples
- Reinforces the basic concept by practical case-based examples
- Useful for Medical, Nursing and allied medical professional students as a basic ECG book
- Includes synopsis that has a summary of all basic concepts and serves as a quick reference



Anandaraja Subramanian is currently working as a Consultant, Department of Cardiology, Indira Gandhi Government General Hospital and Postgraduate Institute, Puducherry, India. He underwent cardiology training at All India Institute of Medical Sciences (AIIMS), New Delhi, India, and training in Cardiac Electrophysiology at the University of Toronto, Canada. He has a number of national and international publications to his credit in peer-reviewed journals. He is also a Section Editor, the Indian Pacing and Electrophysiology Journal. He has the immense experience in teaching ECG to undergraduates and postgraduates.



Raja J Selvaraj is an Associate Professor, Department of Cardiology, Jawaharlal Institute of Postgraduate Medical Education and Research, Puducherry, India. He underwent cardiology training at Southern Railway Hospital, Chennai, Tamil Nadu, India and subsequently completed a Fellowship in Cardiac Electrophysiology, University of Toronto, Canada. He is a Section Editor, the Indian Pacing and Electrophysiology Journal and is an author of numerous publications.

Available at all medical bookstores
or buy online at www.jaypeebrothers.com

JAYPEE BROTHERS
Medical Publishers (P) Ltd.
www.jaypeebrothers.com

Join us on facebook.com/JaypeeMedicalPublishers

Shelving
Recommendation
CARDIOLOGY

ISBN 978-93-5152-660-5