for detailed information on surgery books, visit our website **www.jaypeebrothers.com,** for detailed information on surgery books

Clinical Surgery

A Text and Atlas

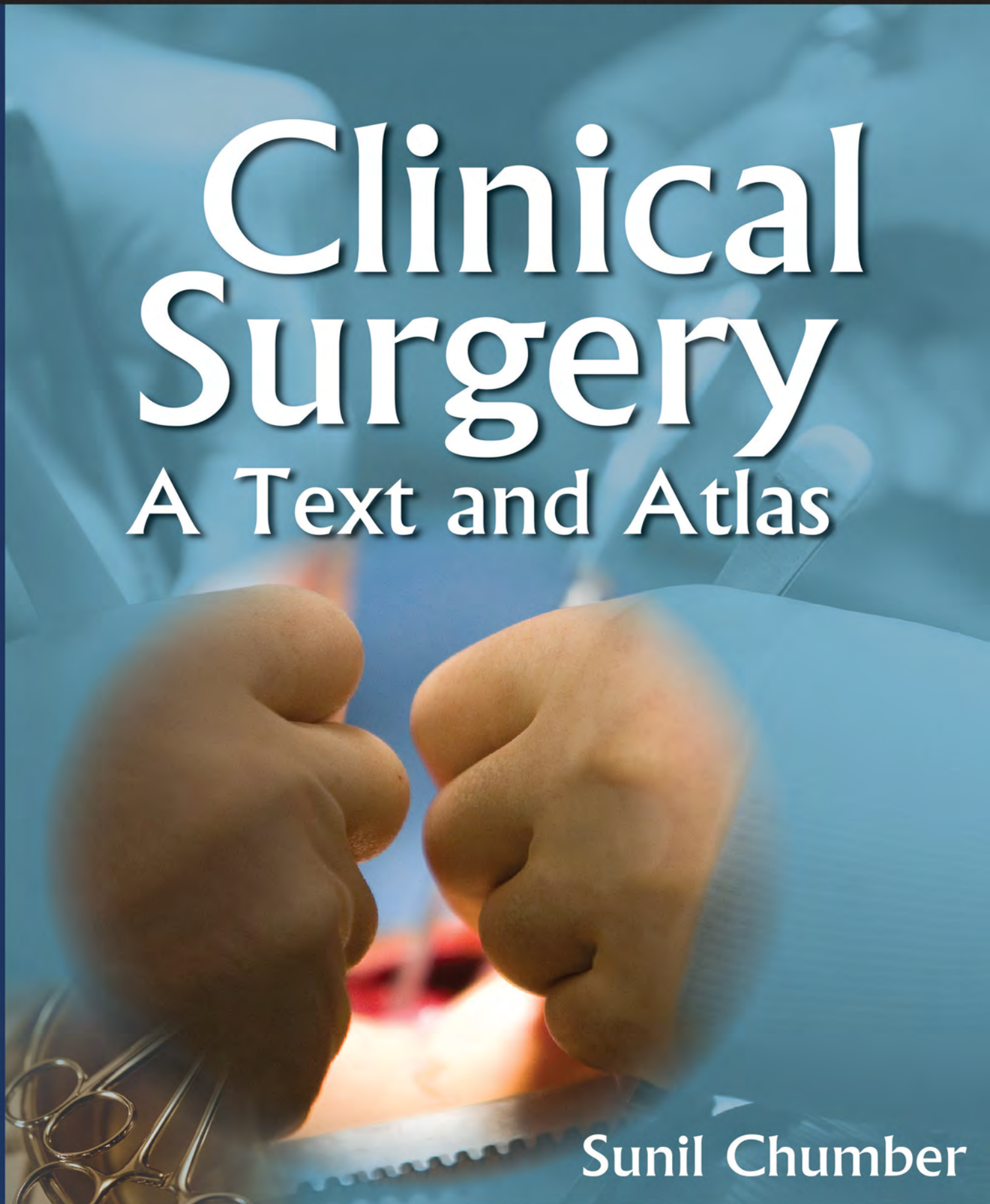

Sunil Chumber

JAYPEE

Foreword
Rani Kumar

Contents

Section 1: HISTORY, SIGNS AND SYMPTOMS

1. History of the Patient 3
Anurag Srivastava, Maneesh Singhal, Sunil Chumber

- First Contact with a Patient *3*
- Taking a History *3*
- Physical Examination *7*
- General Examination *7*
- Systemic Examination *11*
- Local Examination *12*
- Provisional Diagnosis *13*
- Investigations *13*
- Complete Diagnosis *13*
- Management *13*
- Treatment *13*
- Discharge of the Patient *13*
- Follow-up Visit *14*
- Last Point *14*

2. Symptoms and Signs 15
Anurag Srivastava, Maneesh Singhal, Sunil Chumber

- Symptoms *15*
- Signs *20*

3. Lump, Ulcer, Sinus and Fistula 25
Anurag Srivastava, Sushma Sagar, Sunil Chumber

- Lump *25*
- Ulcer *41*
- Sinus and Fistula *52*

Section 2: VESSELS, LYMPHATICS, LYMPH NODES AND NERVES

4. Arteries 59
Varinder Bansal, Rakesh Mahajan, Krishna Asuri, Sunil Chumber

5. Veins 76
Rakesh Mahajan, Varinder Bansal, Aloy Mukherjee, Krishna Asuri, Sunil Chumber

- Varicose Veins *76*
- Deep Vein Thrombosis *81*

6. Lymphatics 85
Varinder Bansal, Rakesh Mahajan, Krishna Asuri, Sunil Chumber

7. Lymph Nodes **91**
Mahesh Chander Misra, Krishna Asuri, Sunil Chumber

8. Nerves **108**
Maneesh Singhal, Sunil Chumber

Section 3: BONES, JOINTS AND SKIN

9. Bone **123**
Hira Lal Nag, Kamran Farooque, Sunil Chumber

10. Joints, Muscle, Tendon and Fascia **138**
Hira Lal Nag, Ravi Mittal, CS Yadav, Sunil Chumber

- Joints *138*
- Shoulder Joint *140*
- Elbow Joint *143*
- Wrist and Hand *145*
- Hip Joint *146*
- Knee Joint *153*
- Ankle and Foot *157*
- Muscle, Tendon and Fascia *159*

11. Hand and Foot **162**
Vijay Sharma, Sunil Chumber

- Hand *162*
- Foot *169*

12. Spine **176**
Arvind Jaiswal, Budhdev Choudhary, Sunil Chumber

- Sacroiliac Joint *181*

13. Skin, Hair and Nails **186**
Garima Beri, Kaushal Kishore Verma, Rakesh Kumar, Sunil Chumber

- Skin *186*
- Mucous Membranes *193*
- Hair *194*
- Nails *194*
- Peripheral Nerves *196*

Section 4: HEAD AND NECK

14. Eyes **205**
Puneet Agarwal, Jeevan Singh Titiyal

15. Face and Head 217
Pradeep Subramaniam, Padma MV Srivastava, Ashish Suri, Sumit Sinha, Sandeep Agarwala, Sunil Chumber

- Face *217*
- Head *222*

16. Teeth, Jaws and Temporomandibular Joint 243
Ritu Duggal, Ajoy Roychoudhary

- Teeth *243*
- Jaws *244*
- Temporomandibular Joint *250*

17. Mouth 253
SVS Deo, Anurag Srivastava, Sudipto Saha, Sunil Chumber

- Lips *255*
- Tongue *255*
- Lingual Tonsil *257*
- Gums *257*
- Cheek *258*
- Floor of Mouth (FOM) *259*
- Palate *259*
- Retromolar Trigone (RMT) *260*
- Tonsils *260*

18. Salivary Glands 267
Arun Kumar, Sudipto Saha, Anurag Srivastava, Sunil Chumber

- Parotid Gland *267*
- Submandibular Gland *269*
- Minor Salivary Glands *271*

19. Ear, Nose and Throat 276
Kumud Kumar Handa, Ameet Kishore

- Ear *276*
- Nose *280*
- Head, Neck and Larynx *282*

20. Thyroid 285
Rajesh Khadgawat, Nikhil Tandon, Vishwanath S, Sudipto Saha, Sunil Chumber

- Parathyroids *302*

21. Neck 305
Subodh Garg, Sudipto Saha, Sunil Chumber

Section 5: BREAST, CHEST AND HEART

22. Breast 317
Anurag Srivastava, SVS Deo, V Seenu, Sunil Chumber

- Male Breast *325*

23. Chest 337
Sanjeev Sinha, Subodh Garg, Ravinder K Dewan, R Ramchandani, Sunil Chumber

24. Heart 354
Rajiv Narang, AK Bisoi, Aditya Prakash Sharma

- Clinical Evaluation of Patients with Heart Disease *354*
- Investigations *360*
- Brief Description of Common Cardiac Diseases *371*

Section 6: ABDOMEN AND HERNIA

25. Esophagus 379
TK Chattopadhyay, Rajinder Prashad, Sandeep Agarwala, Sunil Chumber

26. Abdomen 389
Shaji Thomas, Manoj Kumar, Nitin Agarwal, Nihar Ranjan Dash, MS Ansari, Anoop Saraya, Sandeep Agarwala, Amlesh Seth, Sunesh Kumar, Sunil Chumber

- Acute Abdomen *389*
- Child with Acute Abdomen *397*
- Chronic Abdomen *406*
- Abdominal Lump *428*
- Urologic Problems *472*

27. Rectum and Anus 493
Sudipto Saha, Nitin Agarwal, Sujoy Pal, Sunil Chumber

28. Hernia 503
Mahesh Chander Misra, Krishna Asuri, Sudipto Saha, Sunil Chumber

- Groin Hernias *503*
- Incisional Hernia *510*
- Epigastric Hernia *514*
- Rare Hernias *514*

29. Male Genitalia 520
Nitin Agarwal, Lalit Aggarwal, Sunil Chumber

- Scrotum *520*
- Testis *524*
- Penis *525*

Section 7: SPECIAL GROUPS

30. Preanesthetic Evaluation 539
V Darlong, Mandeep Singh

31. Psychiatric Evaluation 546
Hemraj Pal, Amardeep Kumar, Pratap Sharan

32. Female Patient **552**
Ashok Kumar, Minu Basra, Sunesh Kumar, Sunil Chumber
- Gynecological Assessment *552*
- Obstetric Assessment *566*

33. Child and Newborn **573**
M Raghavan, Minu Bajpai, Sunil Chumber
- Newborn *577*

34. Elderly Patient **581**
AB Dey

Section 8: TRAUMA AND MEDICOLEGAL NEGLIGENCE

35. Patient with Trauma **599**
Amit Gupta, Mahesh Chander Misra, CS Yadav, Budhdev Choudhary, Pradeep Subramanian, Sunil Chumber
- Head Injury *606*
- Maxillofacial Injuries *614*
- Chest Injuries *616*
- Abdominal Injuries *619*
- Spinal Injuries *625*
- Musculoskeletal Trauma *630*
- Pelvis and Perineum *644*

36. Death **647**
Amit Gupta, Sajal Haldar, Sunil Chumber

37. Doctor–Patient Relationship and Medicolegal Negligence **650**
Amit Gupta, Sajal Haldar, Sunil Chumber

38. Laboratory Investigations **653**
Sukhbir Singh Badhal, M Irshad, Sunil Chumber

Appendix *677*
Index *683*

3

Lump, Ulcer, Sinus and Fistula

Anurag Srivastava, Sushma Sagar, Sunil Chumber

JAYPEE BROTHERS

Lump

A *lump* refers to a *mass* of tissue. It may be either *normal* or *abnormal* tissue. In clinical practice, both these terms are used interchangeably to denote the same thing **(Figs 3.1 and 3.2)**.

Swelling is another term commonly used to denote an enlargement or protuberance in the body. This may include several types of swellings as well as tumors. The types of swellings encountered in practice are congenital, traumatic, inflammatory, neoplastic (tumors) and other miscellaneous conditions.

A *tumor* is a growth arising from native cells that undergo autonomous proliferation. Tumors are of two types—*benign* and *malignant*. Benign tumors are slow to proliferate while malignant tumors proliferate rapidly with invasion of adjacent structures.



Fig. 3.1: Lipoma over the left scapula



Fig. 3.2: Lipoma in left groin

HISTORY

When obtaining the history in a patient with a lump, the following should be enquired:

Duration

The examiner must ask for how long the lump has been present or when was it first noticed.

Congenital swellings are present from birth—a cystic hygroma or a meningocele **(Fig. 3.3)**. Painful and recent lumps (acute lumps) are mostly inflammatory, whereas those lumps that are painless and present for years (chronic lumps) are more likely to be benign neoplasms. Sometimes, chronic abscesses may be present for a long time and are painless.

A lump present for a short duration and rapidly increasing in size is more likely to be a malignant lump. It must be remembered that a painless lump may be present in a patient for a long time before he actually notices it.



Fig. 3.3: Meningomyelocele



Figs 3.4A and B: Lipoma over the neck

Sometimes, trauma brings a lump to the notice of the patient when he may assume that trauma has resulted in the lump, e.g. scrotal trauma and testicular tumor.

Onset

A lump may appear spontaneously, e.g. an abscess (painful) or a neoplasm (painless) or it may appear after trauma, e.g. hematoma. Occasionally, the swelling may be noticed by the patient during bathing, e.g. a lump in the breast or testicular tumor or a relative may bring to the notice of the patient a swelling in the neck, e.g. a thyroid nodule **(Figs 3.4A and B)**. Rarely, swellings may arise in pre-existing lesions, e.g. malignancy arising in a chronic scar—Marjolin's ulcer.

Location

The site or exact location of the swelling is usually obvious but, sometimes in a huge swelling, it may be difficult to make out where it is arising from **(Fig. 3.5)**.

Other Symptoms

Pain is the most important symptom associated with the lump. Other symptoms associated with the lump may be due to the compression caused by the lump, e.g. tracheal compression resulting in difficulty in respiration or esophageal compression causing difficulty in swallowing **(Fig. 3.6)**. A lump may also result in restriction of movement of joints, e.g. a bone or a soft tissue tumor.



Fig. 3.5: Lipoma over the back

JAYPEE BROTHERS



Fig. 3.6: Axillary abscess



Fig. 3.7: Soft tissue sarcoma of back

Pain

Pain is almost always present in traumatic or inflammatory swellings but is rare in neoplasm. In presence of pain with a lump, the following should be enquired into:

Onset

In inflammatory swellings, pain always appears before the onset of the swelling. However, in tumors, the swelling appears long before onset of the pain. Generally, malignant swellings are painless to start with; pain in tumors may result from invasion of the nerves, deeper structures, ulceration, fungation or associated inflammation **(Fig. 3.6)**.

Site

The pain is usually localized to the swelling but may be referred to another site, e.g. in acute cholecystitis with a gallbladder lump in the abdomen, the pain may be referred to the shoulder.

Nature

Throbbing pain is suggestive of formation of pus in an inflammatory lump or necrosis in a malignant lump.

Fever

Fever or an elevated temperature of the body is usually present in an inflammatory lump or an abscess, e.g. breast abscess, axillary abscess, gluteal abscess, ischiorectal abscess and intra-abdominal abscess. Fever may also be present in patients with neoplasms—renal cell carcinoma or in Hodgkin's disease.

Loss of Weight

Loss of weight in the patient is usually seen in malignant swellings. Uncommonly, tubercular abscesses may also be associated with weight loss and debilitation.

Progression of Lump

Inflammatory swellings like abscesses will burst to discharge pus in a short time **(Fig. 3.6)**. Benign tumors grow in size slowly and may remain static for a long time **(Fig. 3.7)**. On the other hand, malignant tumors grow rapidly. Sometimes, a benign swelling that has been static for a long period suddenly increases in size due to a malignant transformation. A swelling that decreases in size is invariably an inflammatory swelling. Malignant swellings do not decrease in size **(Fig. 3.8)**.

Other Lumps

Other similar lumps may be present in patients with multiple neurofibromatosis, lipomatosis and diaphyseal aclasis. Lymphadenopathy may be seen at multiple sites in patients with lymphomas **(Figs 3.9A and B)**.

Impairment of Function

This may be noted in swellings near the joints or the spine.

Secondary Changes in the Lump

Secondary changes seen in lumps or swellings include softening, ulceration, fungation and inflammation.

JAYPEE BROTHERS

Recurrence of the Lump

A lump or swelling may recur following excision—this may be seen in both benign and malignant lumps. A fibroadenoma in the breast may recur, if it is incompletely excised, similarly, a sebaceous cyst may recur if the cyst wall is incompletely excised. Liver hydatids can recur following operation, if there is a spill of the hydatid-fluid. Malignant lumps are known to recur frequently, even after excision.

Past History

The patient may give history of similar swellings in the past or that similar swelling has been excised and has recurred. Similarly, a patient with a cold abscess may give a history of having been treated with drugs for tuberculosis.



Fig. 3.8: Gasping for air due to compression of trachea in cancer of thyroid

Personal History

A detailed personal history may shed light on the cause of the swelling, especially when malignant. *Pan*-chewers and smokers are at increased risk of developing malignant growths in the mouth, tongue, cheek or lip.

Family History

Several malignancies may be seen in certain families, e.g. medullary carcinoma of thyroid. Similarly, von Recklinghausen's disease may be seen in other members of the family. Sometimes, tuberculosis may occur in other family members.

PHYSICAL EXAMINATION

A patient with disseminated malignancy or tuberculosis may show cachexia. The patient may show toxemia with fever and tachycardia in a localized abscess. Deformities are often noted in swellings in relation to long bones and joints.

LOCAL EXAMINATION

Inspection

Site

The examiner should identify the exact site or location of the swelling. Dermoid cysts are mostly seen in the midline of the body (*midline dermoids*) or in the line of fusion of embryonic processes (*lateral dermoids*), e.g. at the outer canthus of the eye. Similarly, when examining the abdomen, define the exact location of the lump, whether extraperitoneal, intraperitoneal or retroperitoneal—this may be the only clue of its etiology.

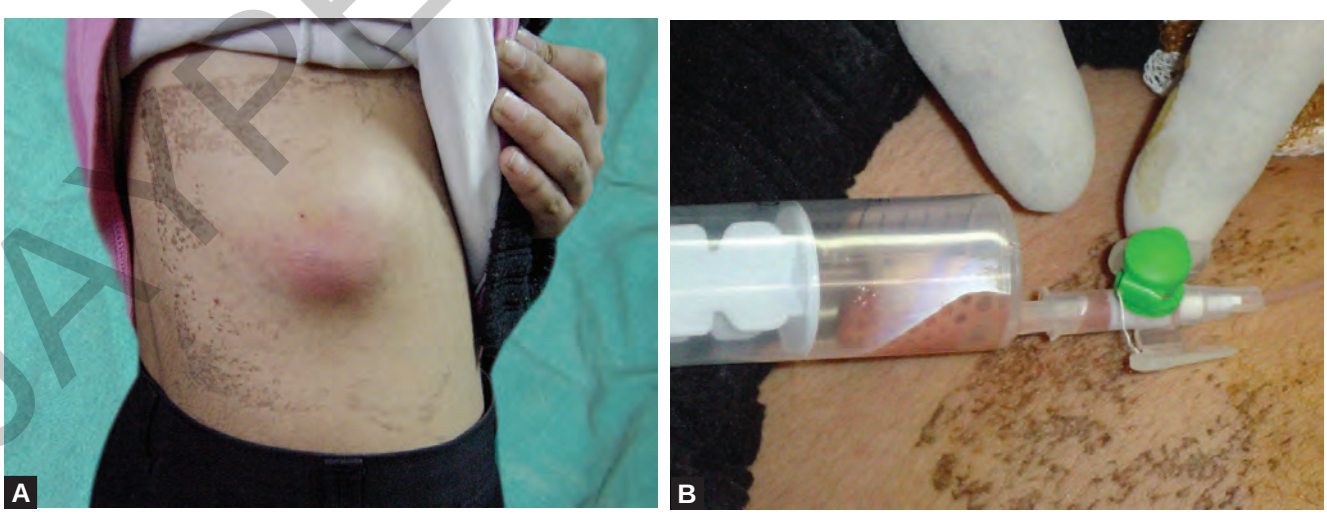

Figs 3.9 A and B: (A) Acute abscess in the right flank; (B) Aspiration with a cannula has yielded frank pus

JAYPEE BROTHERS

Size

The size of the swelling must be clearly mentioned as an *approximate* to be confirmed later at palpation.

Shape

The shape of the swelling may be distinct and described as ovoid, spherical, pear-shaped, or (bean) kidney-shaped or irregular.

Color

Melanomas are often black in color. Red or purple color is commonly seen in hemangiomas whereas a ranula has a bluish color.

Surface

A cyst has a regular smooth surface whereas a cauliflower surface is seen in fungating malignancy. An irregular surface with numerous branches is seen in a papilloma **(Fig. 3.10)**.

Edge

The edge of the swelling may be *well-defined* or *ill-defined*.

Pedicle

The swelling may be pedunculated or sessile.

Number

Dermoids, sebaceous cysts and lipomas are generally solitary. Rarely, lipomas may be multiple. Other multiple swellings are seen in neurofibromatosis, diaphyseal aclasis and lymphadenopathy at multiple sites **(Fig. 3.11)**. Cysticercosis may be multiple.



Fig. 3.10: Parietal abscess oozing pus. Neem leaves are commonly applied as local remedy



Fig. 3.11: Multiple metastatic cutaneous nodules

Pulsation

These are noted in swellings that either arise from the artery, e.g. aneurysms or lie in close association to one, e.g. carotid body tumor. The former shows *expansile* pulsations whereas the latter will show *transmitted* pulsations.

Peristalsis

These are seen in abdominal swellings, e.g. visible gastric peristalsis in congenital hypertrophic pyloric stenosis or intestinal peristalsis in an ileocecal lump in intestinal obstruction.

Expansile Cough Impulse

This is seen in a swelling that communicates with the abdominal or pleural cavity. It may also communicate with the spinal or, rarely, cranial cavity.

When the patient is asked to cough, the swelling enlarges and becomes tense.

Movements

The swelling may show movement in relation to a natural act.

Deglutition

A swelling that is fixed to the larynx or trachea or the pretracheal fascia moves during deglutition, e.g. thyroid swellings, subhyoid bursitis and pre- or paratracheal lymph nodes, when enlarged.

Protrusion of Tongue

A thyroglossal cyst ascends up in the neck on protrusion of the tongue. This is due to the persistence of a thyroglossal tract.

JAYPEE BROTHERS

Respiration

Abdominal swellings that arise from the upper abdominal viscera move with respiration. These swellings arise from liver, spleen, stomach, gallbladder, hepatic and splenic flexures of the transverse colon and in relation to stomach.

Pulse

Swellings in relation to arteries may show transmitted pulsations, e.g. carotid body tumor.

Skin Changes

A scar may be present indicating the site of a previous injury (regular scar), operation (linear scar with suture marks) or infection (broad and irregular scar).

A black punctum over a swelling indicates an underlying sebaceous cyst. Black pigmentation of the skin is present in nevi or melanomas. A darkish-coloration of skin may be seen after radiotherapy. The skin is tense and shiny in an inflammatory swelling. The skin is tense and shiny with prominent veins in a sarcoma also.

Sometimes, the skin over a growth in the breast looks like an *orange-peel* also called as *peau-de-orange* due to edema resulting from blockage of cutaneous lymphatics. Orange-peel appearance may also be seen in other tumors as well as in inflammation **(Fig. 3.12)**.

Rarely, an ulcer may be present over the skin. This is discussed later.

Pressure-effects

In a swelling located in the limb, the examiner should determine the state of limb distal to the swelling. An axillary swelling may lead to distal edema of the upper limb or a groin swelling to distal edema of the lower limb. Wasting of the distal limb indicates compression of the nerves. A retrosternal thyroid swelling may lead to obstruction of veins in the neck—the superior vena cava syndrome.



Fig. 3.12: 'Orange-peel' appearance in inflammatory and malignant conditions

Palpation

Palpation will confirm the findings of inspection. Palpation should be performed in a gentle manner so as not to hurt the patients. Deep palpation in a patient with a pheochromocytoma may lead to a hypertensive crisis! Rarely, rough handling of a tumor may lead to dissemination of the malignancy.

Temperature

This part of examination must be performed first. The temperature of the swelling may be elevated in localized infection. The local temperature may also be elevated in malignant soft tissue tumors. However, repeated manipulation may itself lead to an increase in the temperature of the swelling along with redness.

Tenderness

If on touching the swelling, the patient complains of pain, the swelling is said to be *tender*. Pain is a *symptom* complained of by the patient but tenderness is a *sign* elicited by the examiner. During palpation, one must watch the facial expression of the patient to note, if this gives rise to pain.

One must be gentle when eliciting tenderness so as to cause the least possible pain—however, one learns this only by years of practice—or maybe not even then! Generally, inflammatory swellings are tender, only sometimes are neoplastic swellings.

Surface

The surface of the swelling may be smooth and tense in cyst, lobular in a lipoma, nodular in a mass of lymph nodes or irregular in carcinoma. Rarely, the surface of the swelling may be varying in form, e.g. multinodular goiter or liver with secondaries.

Size, Shape and Extent

Palpation will confirm the *exact* dimensions of the swelling, especially the deeper dimensions. The dimensions of the swelling should be mentioned in centimeters or inches. A diagram of the swelling should be made in the clinical notes indicating the site and shape and dimensions of the swelling.

Sometimes, a part of the swelling disappears behind a bone, e.g. behind the clavicle or deep into the pelvis and the whole swelling may not be available for examination **(Table 3.1)**.

JAYPEE BROTHERS

Table 3.1: Lipoma versus cyst

	Lipoma	*Cyst*
Edge	Well-defined	Well-defined
Slipping margin	Present	Absent
Yielding margin	Absent	Present

Edge

The edge of the swelling can be well-defined or *distinct*, when it is palpable all around the swelling or ill-defined or *indistinct*, when it merges into the adjacent tissues. Generally, both benign and malignant neoplasms have a distinct margin. Benign neoplasms have *regular* edge whereas malignant growths invariably have an irregular edge. Sometimes, chronic inflammatory swellings may also have well-defined edges, e.g. chronic breast abscess, but acute inflammatory swellings generally have ill-defined edges. Congenital cutaneous lesions often have ill-defined edge.

The edge is palpated by the tips of the fingers. A swelling with a well-defined edge tends to slip away from the finger. Benign tumor such as lipoma is often confused with a cyst **(Figs 3.13A and B)**.

Consistency

The consistency of a lump depends on its constituents.

Uniform Consistency

This is seen in a lipoma, fibroma, cysts or chronic abscesses. Uniformly hard swellings are osteomas, chondromas or carcinomas.

Variable Consistency

This is usually seen in malignancy—carcinoma or sarcoma. This may also be seen in gas gangrene or surgical emphysema where an examining hand will elicit crepitus.

Fluctuation

Fluctuation is the movement of fluid on transmission of pressure impulses in a swelling. A swelling is fluctuant when it contains liquid or gas.

Method of Testing for Fluctuation

When a swelling is small in size, fluctuation is elicited by fixing the swelling with the index finger and thumb of the left hand and by indenting the center of the swelling.

If the swelling is large, it may be fixed with both the hands. Sudden pressure when applied to one end of the swelling will lead to separation of the fingers of the other hand. This results from the increase in pressure within the swelling being transmitted uniformly to all the walls.

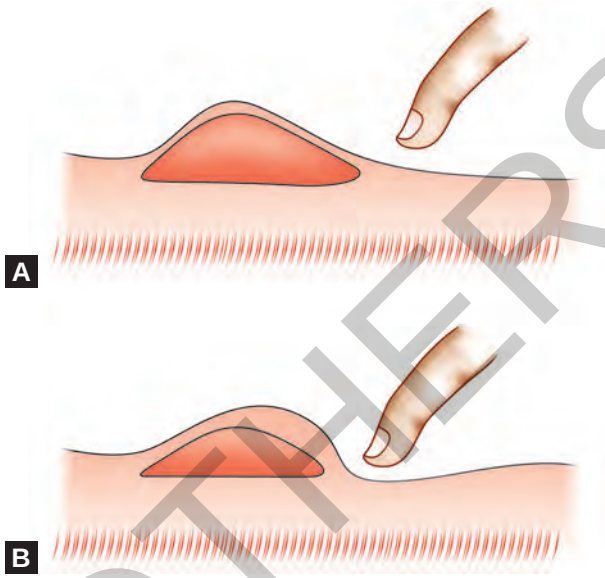

Figs 3.13A and B: Slipping margin in lipoma

Fluctuation should be elicited in *two planes* at right angles to each other. Fluctuation may also be seen in muscles, or lipoma.

Fluid-thrill

When a swelling contains fluid, it can be momentarily compressed or tapped to generate a fluid wave. When this wave is felt by the fingers, it is called a fluid-thrill.

In a large swelling, it may be tapped on one side and the percussion wave felt on the other end. However, in a small swelling, the *three finger test* is employed. Three fingers are placed on the swelling. When the middle finger is tapped with a finger of the other hand, a fluid wave is felt by the other two fingers on each side.

Translucency

A swelling containing clear-fluid transmits light through it. A translucent swelling contains clear fluids like water, serum, lymph or plasma. Frank-blood is not translucent. The contents of dermoid cysts and sebaceous cysts are opaque. A swelling containing fluid may be fluctuant but need not be translucent!

Transillumination should be tested in a darkened room. In the wards, a rolled up X-ray film may be used to achieve the same purpose. A pencil-torchlight may be kept to one side of the swelling to project the light. Only a translucent swelling will transmit light **(Fig. 3.14)**.

Expansile Cough Impulse

On palpation, a swelling may be expansile on coughing. An expansile cough impulse is noticed in swellings that are in

JAYPEE BROTHERS

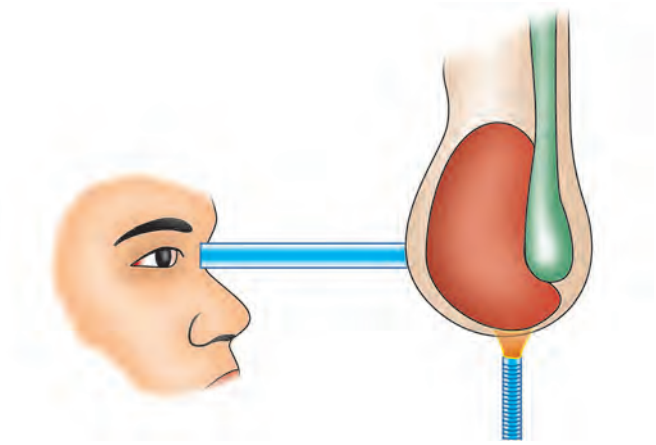

Fig. 3.14: Testing for transillumination. A torch is applied to the scrovery. A rolled-up X-ray acts as a transilluminoscope. When the eye is applied, then hydrocele seen as a brilliant orange swelling

continuity with the abdominal cavity, e.g. hernia, and rarely, psoas or lumbar abscesses. A swelling in continuity with the pleural cavity also shows a cough impulse, e.g. in *empyema necessitans*. Swellings in continuity with the spinal cord, e.g. spinal or cranial meningocele too show an expansile cough impulse.

An expansile cough impulse is tested by holding the swelling in one hand and asking the patient to cough. An impulse is immediately felt by the grasping hand due to a rise in the pressure in the abdominal, pleural, spinal and cranial cavities.

Reducibility

A swelling that decreases in size on applying pressure over it and ultimately disappears is called a reducible swelling. This is most commonly seen in hernia. Other swellings that reduce spontaneously or reduce on pressure are varicocele, *saphena varix*, meningocele and *lymph varix*. These swellings are either partly reducible or completely reducible.

Compressibility

A swelling that can be compressed and made to reduce in size but does not completely disappear is called a compressible swelling.

Compressible swellings are fluid-filled swellings and include hemangiomas and other vascular malformations. Lymphangiomas too are partly compressible. These swellings do not have any communications with the body cavities, viz abdominal, pleural, spinal or cranial.

The important differentiating features between a compressible and reducible swelling are shown in **Table 3.2** (*see* **Fig. 3.9**).

Table 3.2: Reducible versus compressible swellings

S.No.	*Reducible swelling*	*Compressible swelling*
1.	Swelling completely disappears	Swelling does not disappear completely
2.	Contents get reduced into body cavities	Contents are only displaced
3.	Swelling reappears on coughing	Swelling reappears when pressure is removed

Response to Pressure

Sometimes, a swelling can be molded on pressure, when the contents are putty-like or pultaceous. This is seen in sebaceous cysts or dermoid cysts. Fecal masses in the colon can too be indented on pressure.

An inflammatory swelling with edema will also show some pitting on pressure.

Pulsatility

A swelling is pulsatile, if it shows pulsations, i.e. it increases and decreases in size, synchronous with the arterial pulse. A swelling that arises from an artery shows *expansile* pulsations with true expansion with the pulse. A swelling close to an artery too may show pulsations. These are called *transmitted* pulsations, being transmitted from the artery. Rarely, pulsations may be seen in a swelling if it is very vascular, e.g. sarcoma located on the limbs. Secondary deposits from follicular carcinoma of thyroid, especially on the skull also show pulsations.

Testing for pulsatility is indeed simple. Both the index fingers are placed on the swelling as far apart as possible. Next, the fingers are observed with each pulse. If the fingers remain in the same position, the swelling does not show pulsations. If the fingers only *move with the pulse*, it is due to transmitted pulsations. If the fingers *move-apart with the pulse*, then expansile pulsations are present.

Testing for pulsations must be performed before subjecting a swelling to incision and drainage thinking it to be an abscess!

In the abdomen, when a tumor lies in front of the aorta, it will give rise to transmitted pulsations. Expansile pulsations are seen in an abdominal aortic aneurysm. If the patient is placed in the knee-chest position, the transmitted pulsations of the tumor will cease but those due to the aneurysm will be present.

Fixity

Skin

The swellings that arise from components of the skin are fixed to it and move along with the skin, e.g. sebaceous cyst. Fixity

JAYPEE BROTHERS

to underlying structures is seen in malignant infiltration. Fixity to the skin is tested by:

Moving the Skin over the Swelling

If the swelling is fixed to the skin, then the skin will not move separately.

Pinching the Skin off the Swelling

When the swelling is not fixed to the skin, then the skin may be pinched-up. This is not possible when the skin is fixed to the swelling.

Underlying Structures

Tumors in the subcutaneous tissues are extremely mobile, but those arising from the deep fascia show less mobility. When a tumor arises from the muscle, it can be moved only when the muscle is relaxed. When the muscle is contracted, the tumor gets fixed. Rarely, a tumor that is adherent to or infiltrating the deeper structures may continue to show some mobility, e.g. a tumor fixed to the deep fascia or muscle can still be moved sideways. However, if the underlying muscle is made to contract against resistance, the tumor will seem to get fixed.

A subcutaneous tumor may infiltrate the muscle and becomes fixed and more prominent on contracting the muscle. Such a tumor is mobile only when the muscle is relaxed.

A tumor arising from the muscle becomes fixed and less prominent when the muscle is contracted. A ruptured muscle will manifest as a swelling or lump only when the muscle is contracted. When a swelling arises from a bone, it will be fixed even when the muscle is relaxed.

A swelling arising from the vessels or nerves may show some mobility at right angles to the course of the vessel or nerve, but no mobility along the course of the vessel or nerve.

Adjacent Structure

It is important to determine relationship of the swelling to the adjacent structures. Tumors arising from deeper structures are usually not adherent to the skin. Sometimes, a tumor may develop fixity to skin due to infiltration of dermal fibrous strands, e.g. in cancer of breast. Benign tumors may too be adherent to fibrous strands in the skin and seem in separable from it, e.g. lipoma.

Adjacent Joints

The joints adjacent to a swelling must be examined for any restriction of movements. Restriction of movement of adjacent joints may be observed in local infiltration or effusion into the joint or by compression of nerves or vessels.

Pressure Effects

A swelling will exert pressure on adjacent tissues. In the limbs, compression of veins gives rise to venous congestion and varicose veins. Compression of arteries may lead to ischemia of the distal limb. Compression of nerves will lead to sensory and motor loss with paresis or paralysis of the muscles. Erosion of the bone may occur in a long-standing swelling.

Percussion

A superficial swelling may not yield much information on percussion; however, it has an important role in deeper intra-abdominal swellings. A superficial hernia may demonstrate a resonant note on percussion. Sometimes, a large hydatid cyst of liver may show a hydatid-thrill on percussion. This is discussed later.

Auscultation

Auscultation should be performed over all pulsatile swellings and intra-abdominal lumps. It should also be performed over swellings that lie in the course of the vessels. Auscultation will help to pick up any bruits or murmurs over the swellings. A *machinery murmur* is auscultated over an aneurysm.

Measurements

Relevant measurements should be recorded during the examination of a swelling at fixed distances from bony points. This will help to record the correct size of the swelling and also confirm any distal wasting owing to compression.

Regional Lymph Nodes

An examination of a swelling or lump remains incomplete till the regional lymph nodes have been examined. When the regional lymph nodes are enlarged, it is essential to examine all other lymph node groups to determine whether lymphadenopathy is *localized* or *generalized*.

SYSTEMIC EXAMINATION

The general physical examination must be performed in a malignant swelling. This may reveal the site of the primary lesion or other sites of metastasis.

Chest

Presence of cough, hemoptysis or chest pain are indicative of metastasis to lungs. The examination of the chest may be entirely normal or may suggest presence of consolidation and pleural effusion.

JAYPEE BROTHERS

Abdomen

Jaundice may be seen in a patient with metastasis to the liver. The examination of the abdomen may reveal a nodular hepatomegaly, or peritoneal metastasis.

Long-bones and Spine

Presence of bone pain is suggestive of bony metastasis. The spine, the pelvis, the femurs and the skull are common sites of metastasis.

Other Lymph Nodes

If the swelling is an enlarged lymph node, other lymph node groups should be examined to rule out the presence of lymphoreticular malignancy or disseminated tuberculosis.

INVESTIGATIONS

Laboratory

Hemogram

This is an examination of the blood and includes hemoglobin (Hb), total leukocyte count (TLC), differential leukocyte count (DLC) and erythrocyte sedimentation rate (ESR). Leukocytosis is commonly seen in an inflammatory swelling (raised TLC) and increased number of polymorphs in DLC. Raised ESR may be present in a chronic inflammatory swelling and rarely, in a malignant swelling. Hemoglobin may be low (anemia) in a malignant or chronic swelling.

Chemistry

Blood sugar must be tested in a patient with recurrent furuncles, abscesses or carbuncles, to exclude the presence of diabetes mellitus.

Urinalysis

Urine sugar excretion is also increased in diabetes mellitus.

Serology

Indirect hemagglutination assay (IHA) becomes important in suspected hydatid disease.

Culture and Sensitivity

Any material that has been aspirated from an inflammatory swelling should be examined microscopically and also sent for culture and sensitivity. Cytology should be performed on suspected malignant swellings.

Radiology

Plain X-ray

Plain X-rays are required to know the relationship of the swelling to an adjacent bone. Invasion of bone may be present in a malignant lump whereas erosion of bone is seen in an aneurysm or a dermoid cyst.

A chest X-ray should be performed to look for presence of a focus of tuberculosis in a patient with chronic swellings. Multiple lung metastasis may be present in a patient with a malignant lump.

Ultrasonography

It is noninvasive and avoids risk of radiation, moreover, it is inexpensive and simple to perform.

High frequency sound waves greater than 20,000 cycles per second are produced by a piezoelectric crystals housed in a transducer. As the ultrasonic beam passes through the body, it is attenuated in intensity due to reflection of the beam at the tissue interfaces. The reflection is received back by the transducer as echoes and displayed on a monitor as an image.

The advantages of ultrasound are its safety in fetus and tissues and is the screening procedure in obstetrics and gynecological conditions as well as in cardiac evaluation. It is painless and can be used for several interventions, diagnostic and therapeutic thus avoiding operation.

One of the main disadvantages is the requirement of a trained person for performing an ultrasound, as it is an operator dependent. For most evaluations by ultrasound, some form of preparation is required, e.g. fasting for evaluation of gallbladder, a full bladder for pelvic ultrasound. The ultrasound is particularly useful to define a lump as *soild*, *cystic* or *mixed* and its *relationship* to other organs.

Computed Tomography Scan

A computed tomography scan (CT scan) uses an X-ray beam that rotates 360 degrees around the patient. The image so produced is usually in the form of a gray scale. A computer analyses the information from the scan by calculating the absorption coefficient of each small block of tissues (stored as pixels). The information of precise tissue absorption is displayed in numerical form and called *attenuation value* of the tissue. Thus, in a lipoma, a CT shows a solid mass with attenuation values of fat (–50 to –100 HU). Cystic masses show fluid with low attenuation (0–10 HU). The major advantage of CT is that it can distinguish differences between various soft tissues, e.g. in head, it can distinguish CSF, blood and brain substance.

Computed tomography scan is most useful to evaluate the head, chest, abdomen and bones. Advances in CT

JAYPEE BROTHERS

technology have produced three-dimensional images (3D CT Scan). Fast and multiple cuts may also be obtained (*spiral* CT).

Magnetic Resonance Imaging

Magnetic resonance imaging (MRI) is noninvasive and does not expose the patient to radiation. This is an advanced method of diagnostic imaging based on the density of hydrogen present in water in the body. These hydrogen nuclei are made up of single protons that spin and generate a small magnetic field. When magnetized, hydrogen nuclei can undergo resonance when exposed to certain radiowaves. When a body is exposed to radiowaves, resonance occurs and detectable radiowaves are radiated by the body. The frequency of signals emitted reflects the strength of net magnetic field. The quality of images can be improved with use of contrast agents like intravenous Gadolinium. MRI is useful for imaging of brain and soft tissues and bones and angiography. However, patients with metallic implants cannot undergo MR imaging **(Fig. 3.15)**.

Angiography

Angiography involves the opacification of blood vessels by intravascular injection of iodinated contrast agents. Conventional angiography uses flexible catheters that are placed in the arterial system, usually via puncture of the femoral artery in the groin. Following intravascular contrast injection, a series of rapid images are acquired depicting contrast flow through the vessel injected.

Digital Subtraction Angiography

It has virtually replaced conventional angiography. The principle of digital subtraction angiography (DSA) is to digitally subtract the background density due to bones, bowel gas or soft tissue from an image to show only the blood vessels containing radiographic contrast medium. Computer-subtracted images are displayed requiring less amount of contrast with better evaluation of vascular structures otherwise obscured by bones and bowel gas. CT and MR angiography are other modalities currently available. Such investigations are most suitable for swellings in relation to blood vessels and in peripheral vascular disease.

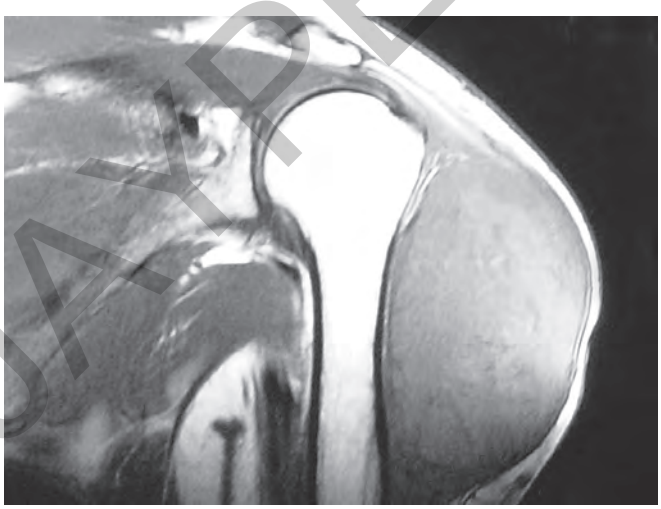

Fig. 3.15: MRI showing of soft tissue tumor of shoulder

Pathology

Fine Needle Aspiration Cytology

Fine needle aspiration cytology (FNAC) is used most often to sample lumps of the breast, lymph nodes, thyroid and salivary glands or in other locations. Aspiration of the lesion is performed using a fine needle attached to a special aspiration gun or disposable plastic syringe. The palpable lump is fixed with the left-hand, while the lesion is aspirated in several directions by the right-hand **(Fig. 3.16)**. The aspirate is smeared on a slide, dried and fixed in absolute alcohol before staining. Sampling of intra-abdominal, mediastinal or thoracic lesions requires ultrasound or CT scan guidance to ensure proper needle placement. The main advantages of FNAC are its cost-effectiveness, safety, speed and accuracy. Diagnostic FNAC has enabled many people to be spared from surgery. Further, when surgery in indicated, the preoperative FNAC diagnosis may help direct the extent of the surgical procedure.

Exfoliative Cytology

In this technique, the cells shed from the tumor in a hollow viscus is examined for abnormal cells. Diagnostic material for exfoliative cytology includes sputum, urine, serous fluids (pleural, peritoneal), bronchoalveolar lavage (BAL) specimen and cervicovaginal smears. Cervicovaginal



Fig. 3.16: Fine needle aspiration cytology (FNAC) form a thyroid nodule

JAYPEE BROTHERS

smears stained by Papanicolau stain is important in screening and detection of cervical cancer in women.

Biopsy

Biopsy involves the removal of a piece of tissue for the histological examination. It is the final tool in establishing the diagnosis in most surgical conditions.

Open biopsy is obtained during surgery. *Incisional biopsy* involves the removal of a wedge of the lesion with adjacent normal margin. An *excisional biopsy* involves the removal of the entire lesion with surrounding rim of normal tissue. Small lesions should be excised completely whereas *incisional* biopsy is preferable for large lesions. *Endoscopic biopsy* is a commonly performed during rigid and flexible endoscopy. *Percutaneous biopsy* involves the removal of a core of tissue by use of special needles. Percutaneous biopsy may be *blind*, as in percutaneous liver biopsy, or *guided* by fluoroscopy, CT, ultrasound or laparoscopy. Menghini needle for liver biopsy and Tru-cut needles are the commonly used devices. A *drill biopsy* is performed with a small sharp cannula attached a high speed compressor air drill.

Others

Tuberculin Test

It is performed to determine if the patient has been exposed to tuberculosis. A positive test in infants and young children suggests a tubercular lesion. If the test is negative, it may exclude tuberculosis or indicates an overwhelming illness or anergy.

DIAGNOSIS OF A SWELLING

When confronted with a swelling, the student must determine as below:

Anatomical Diagnosis

Whether the particular swelling is arising from skin, subcutaneous tissue, muscles, blood vessel, nerve or bone.

Etiological Diagnosis

Whether the swelling is congenital, traumatic, inflammatory or neoplastic. Congenital swellings are usually present since birth, but may present later in life, e.g. branchial cyst or thyroglossal cyst. Traumatic swellings develop immediately after a trauma, e.g. hematoma. Inflammatory swellings arise in relation to a focus of infection. Neoplastic swellings arise spontaneously in any location and may be *benign* or *malignant*.

Pathological Diagnosis

Whether the swelling is due to a particular tumor, e.g. papillary thyroid cancer in neck, fibromatosis of the abdominal wall, adenocarcinoma of the colon or hydatid cyst of the right lobe of liver.

Acute Inflammatory Swellings

These are usually sudden in onset and present with redness (*rubor*), pain (*dolor*), heat (*calor*), swelling (*tumor*) and impairment of function (*functio lasea*). When an inflammatory swelling undergoes internal necrosis, it may form pus giving rise to fluctuation in the swelling **(Figs 3.17 and 3.18)**.

The draining lymph nodes are enlarged and tender indicating acute lymphadenitis. Rarely, rapidly growing soft tissue tumors or sarcomas may mimic an acute inflammatory swelling. However, the swelling is often present long before onset of pain and fever is not a marked symptom. Leukocytosis is a constant feature of acute inflammation, which is absent in a sarcoma.



Fig. 3.17: Abscess near a scar



Fig. 3.18: Pyogenic abscess that has burst

JAYPEE BROTHERS

Table 3.3: Difference between benign and malignant swellings

S.No.	Feature	Benign	Malignant
1.	Age	Commonly occurs in the young	Commonly seen in older patients above 40 years, uncommon in young
2.	Duration	Slow growing	Rapidly growing
3.	Pain	Usually absent	Become painful in advanced stages
4.	Loss of weight	Usually absent	Common feature of most malignant growths
5.	Loss of function	Usually not seen	Occurs early in disease
6.	Cancer cachexia	Absent	Usually present
7.	Consistency	Uniform	hard or of varying consistency
8.	Surface	Smooth	Irregular
9.	Margins	Smooth and well-defined	Irregular and ill-defined
10.	Mobility	Freely mobile	Fixity due to infiltration
11.	Regional lymph nodes	Not enlarged	Early involvement and enlarged
12.	Distant metastasis	Never	Characteristic of malignant growth
13.	Pressure effects	Uncommon	Often present
14.	Secondary changes	Uncommon	Often present
15.	Recurrence	Rarely recurs after excision	Often recurs after excision

Chronic Inflammatory Swellings

They are gradual in onset and have been present for longer than six weeks. The symptoms and signs of acute inflammation are present but not as marked. The symptoms of pain, fever and redness are subdued but swelling may be more marked. Induration and brawny edema are absent.

Sometimes, a chronic swelling may mimic a malignancy. Rarely, fever and raised temperature may be present in a malignant swelling along with tenderness and fixity of lymph nodes. The size of a malignant swelling may remain static for a long time or increase rapidly but an inflammatory swelling will usually show some decrease in size.

Benign Tumors

Benign tumors are encapsulated, slow growing and freely mobile, e.g. fibroadenoma of the breast or a subcutaneous lipoma. Such tumors do not infiltrate the surrounding tissues and do not metastasize to the regional lymph nodes or to distant organs. Rarely, these tumors may undergo secondary changes like ulceration, bleeding or malignant transformation.

Malignant Tumors

Malignant tumors that arise from epithelial cells are carcinomas or those that arise from connective tissues are sarcomas. Malignant tumors grow rapidly, infiltrate local tissues and show metastasis to the regional lymph nodes or to distant organs. Secondary changes like ulceration, bleeding and degeneration are common. Surprisingly pain is absent in a malignant growth. Rarely, pain may precede the swelling in an osteosarcoma. Malignant growths are more common in the older patient—carcinoma affects the old and sarcomas affect the young. The characteristics of benign and malignant growths are shown in **Table 3.3**. Other differences noted between benign and malignant swellings at histology are given in **Table 3.4**.

Table 3.4: Pathology of benign and malignant swellings

S.No.	Feature	Benign	Malignant
1.	Cellular differentiation	Present well-encapsulated	Undifferentiated cells
2.	Capsule		do not have a capsule and local infiltration is present
3.	Anaplasia	Absent	Characteristic of malignant growth
4.	Nuclear structure	Same as normal cell	Large nucleus with mitosis

Malignant Transformation in a Benign Swelling

Rarely, a long-standing benign swelling may turn into a malignant growth. The features of this malignant transformation are:

- Appearance of pain, itching or other symptoms
- Increase in the size over a short period
- Increased vascularity of the tumor
- Fixity of the lump to skin or deeper muscles
- Infiltration of adjacent tissues like arteries, veins, nerves or other structures, e.g. malignant change in multinodular goiter is suspected when there is hoarseness of voice due to involvement of recurrent laryngeal nerve, dyspnea due to involvement of the trachea or dysphagia due to involvement of esophagus.
- Involvement of regional lymph nodes
- Appearance of distant metastasis
- Secondary changes in the swelling, i.e. ulceration, bleeding or increase in pigmentation in a mole.

JAYPEE BROTHERS

for detailed information on surgery books, visit our website **www.jaypeebrothers.com,** for detailed information on surgery books

Clinical Surgery
A Text and Atlas

Salient Features

- A complete textbook both for the curious students who have started learning the basics of clinical evaluation as well as a complete guide for the senior surgeons teaching clinical methods to the students
- The entire text is spread over 9 major sections and includes 38 chapters in specific areas pertaining to surgery as well as allied specialties. Each chapter is divided into different parts for the ease of the student to learn history taking, conduct of physical examinations, planning and ordering investigations as well as formulating the differential diagnoses to reach the correct diagnosis
- The book is amply illustrated with color photographs, X-rays, diagrams and charts for easier understanding and long-term retention in memory.
- The various academic materials are all complied by both senior authors as well as new surgeons, all of whom have been associated with the premier All India Institute of Medical Sciences (AIIMS), New Delhi, India.



Sunil Chumber completed his MBBS and MS in General Surgery from AIIMS, New Delhi. Presently, he is Professor of Surgery, Department of Surgical Disciplines, AIIMS, New Delhi, India. He is devoted to Endocrine-Surgery and has a large experience in diseases of the thyroid, parathyroid and the adrenal glands. He is also devoted to teaching of graduates and postgraduates and actively participates in the field of Medical Education and Ethics. He has also been the Sub-Dean of Academics, AIIMS and has several research papers to his credit in both national and international journals. He is also an Editor-cum-author of textbook entitled *Essentials of Surgery* for students and a monograph, *Thesis and Dissertation* for postgraduates.







Available at all medical bookstores
or buy online at www.jaypeebrothers.com

JAYPEE BROTHERS
Medical Publishers (P) Ltd.
www.jaypeebrothers.com

Join us on facebook.com/JaypeeMedicalPublishers

Shelving
Recommendation
SURGERY

ISBN 978-93-5152-679-7