tailed information on obstetrics & gynecology books, visit our website www.jaypeebrothers.com

JAYPEE

INCLUDES INTERACTIVE DVD-ROM

A Manual of Minimally Invasive Gynecological Surgery

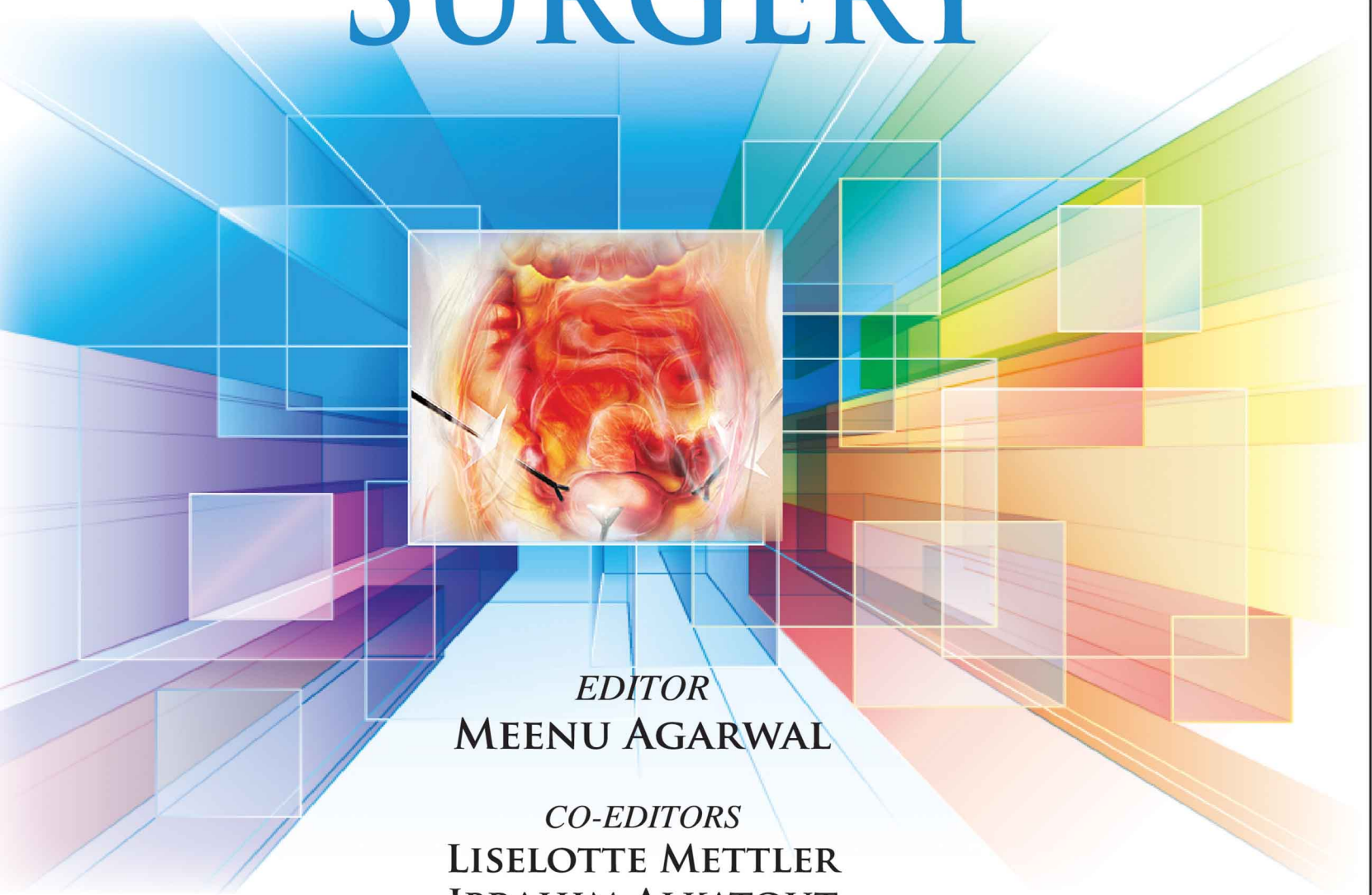

EDITOR
MEENU AGARWAL

CO-EDITORS
LISELOTTE METTLER
IBRAHIM ALKATOUT

Forewords
Liselotte Mettler • Ibrahim Alkatout • Prashant Mangeshikar

CONTENTS

SECTION 1

To Know Your Basics

CHAPTER 1 EQUIPMENT IN LAPAROSCOPIC SURGERY **03-12**
Helder Ferreira

Laparoscopy versus Open Surgery 3
Imaging Devices 4
Co_2 Gas Insufflator 6
Ports of Entrance in Abdominal Cavity 6
Instruments 7

CHAPTER 2 PERITONEAL ACCESS IN LAPAROSCOPY **13-36**
Artin Ternamian

Laparoscopic Peritoneal Port Fundamentals 14
Classification of Laparoscopic Access Methods 17
Closed Conventional Laparoscopic Access Method 17
High Pressure Laparoscopic Access Method 18
Radially Expanding Laparoscopic Access Method 19
Direct Laparoscopic Access Method 20
Open Laparoscopic Access Method 21
Visual Laparoscopic Access Method 23
Single-port Laparoscopic Access with the Threaded Visual Cannula Endocone™ 28
Laparoscopic Access Sites 30
Laparoscopic Access Instruments 30

CHAPTER 3 PORT PLACEMENT IN LAPAROSCOPY **37-59**
Ibrahim Alkatout, Liselotte Mettler

Counseling and Informed Consent 37
Extra-abdominal Relevant Anatomy 37
Intra-abdominal Relevant Anatomy through the Eye of the Trocar 40
Ports and Trocars 40
Entry Techniques 43
Vaginal Instruments 50
Advancements in Laparoscopic Entries 52
Alternative Entry Sites 52
Trocar Placement 53
Termination of the Laparoscopic Procedure 54
Complications in Port Placement 55
Future Perspective 58

SECTION 2

The Learning Curve

CHAPTER 4 GRAY'S ANATOMY OF FEMALE PELVIS AS SEEN THROUGH THE LAPAROSCOPE **63-68**
Shailesh Puntambekar

Pelvis Boundaries 63
Organs in the Pelvis 63
Ligaments/Supports of the Uterus 63
Bones and Muscles 63
Vascular Anatomy 64
The Spaces 66
Ureteric Anatomy 67
Nerves 67

CHAPTER 5 PRINCIPLE AND USE OF ELECTROSURGERY IN LAPAROSCOPY **69-77**
Helder Ferreira, Carlos Ferreira

History 69
Nomenclature 70
Biophysical Principles 70
Electrosurgery: Monopolar or Bipolar Modality 71
Tissue Effects 71
Bipolar Instruments 73
Current Uses of Electrosurgery in Minimally Invasive Procedures in Gynecology 74
Undesirable Effects or Accidents and its Prevention 74

CHAPTER 6 LAPAROSCOPIC SUTURING **78-87**
Meenu Agarwal

Methodology 78
Equipment 78
Knots 81
Suturing Technique 83
Erogonomics and Port Placement 85
Suturing in a Vertical Zone 86

CHAPTER 7 TISSUE RETRIEVAL **88-92**
Namita Joshi

Tissue Retrieval through 5 mm Port 88
Replacing 5 mm Port by 10 mm Port 88
Endobags for Tissue Retrieval 88
Morcellation for Tissue Extraction 88
Endoscopic Knife for Tissue Morcellation 91
Colpotomy 91

CHAPTER 8 ANESTHESIA IN LAPAROSCOPY **93-104**
Manisha Bijlani

Trocar Insertion 93
Insufflation 93
Changes due to Carbon Dioxide (Co_2) 93
Ventilatory and Respiratory Changes and Complications 95

Pneumothorax, Pneumomediastinum and Pneumopericardium 96
Hemodynamic and Cardiovascular Changes and Complications 97
Other Systemic Changes 97
Anesthetic Management 99

SECTION 3

Laparoscopy

CHAPTER 9 DIAGNOSIS AND TREATMENT OF ECTOPIC PREGNANCY 107-120
Ibrahim Alkatout, Ulrich Honemeyer, Liselotte Mettler

The Implantation Window 108
Diagnostics—Pretreatment Assessment of Ectopic Pregnancies 108
Differential Diagnosis 109
Treatment of Ectopic Pregnancies 110
Complications 118

CHAPTER 10 LAPAROSCOPIC HYSTERECTOMY 121-127
Linda Shiber, Thomas Lang, Resad Pasic

Indications 121
Informed Consent 121
Preoperative Management 121
Positioning and Preparation 122
Trocar Placement 122
Procedure 122
Postoperative Management 126
Follow-up 126

CHAPTER 11 LAPAROSCOPIC MYOMECTOMY 128-133
Thomas Lang, Linda Shiber, Resad Pasic

Preoperative Considerations 128
Intraoperative Considerations 129
Postoperative Considerations 133

CHAPTER 12 ADENOMYOSIS—MANAGEMENT AND LAPAROSCOPIC SURGERY 134-143
Grigoris Grimbizis, Themistoklis Mikos

Recent Guidelines and Management 135
Fertility Sparing Laparoscopic Surgery in Adenomyosis 136

CHAPTER 13 LAPAROSCOPIC MANAGEMENT OF ENDOMETRIOSIS 144-150
Stephan Gordts

Pathogenesis 144
Diagnosis 145
Peritoneal and Ovarian Endometriosis 145

CHAPTER 14 LAPAROSCOPIC COLPOSUSPENSION 151-155
Guenter K Noé

Indication 151
Preoperative Treatment 151
Postoperative Treatment 154

SECTION 4

Special Situations for Minimally Invasive Approach

CHAPTER 15 LAPAROSCOPIC SUBTOTAL HYSTERECTOMY **159-189**
Ibrahim Alkatout, Liselotte Mettler

Etiology 160
The Genetics of Fibroids, Genotype and Phenotype 160
Microscopic Facts and Fibroid Viability 160
Costs of Fibroids 161
Will the Ovaries be Removed or Left in Place? 161
Resection of Fallopian Tubes in Cases of Hysterectomy 161
Total Versus Subtotal (Supracervical) Hysterectomy 162
Comparison to LTH 168

CHAPTER 16 LAPAROSCOPY IN PREGNANCY **190-196**
Pranay Shah

Physiologic Changes in Pregnancy 190
Diagnosis and Workup 190
Patient Selection 192
Anesthesia 192
Patient Positioning 192
Initial Port Placement 192
Insufflation Pressure 192
Venous Thromboembolic Prophylaxis 192
Hemostatic Techniques 193
Adnexal Masses 193
Cervical Incompetence 193
Heterotopic Pregnancy 193
Appendicitis 194
Gallbladder Disease 194
Solid Organ Resection 194
Perioperative Care 194

CHAPTER 17 NON-DESCENT VAGINAL HYSTERECTOMY **197-201**
JP Rath

Natural Orifice Hysterectomy 197
Indications 197
Contraindications 197
Caution 197
Anesthesia 197
Position 198
Instruments 198
Sutures 198
Method 198
Postoperative Care 200
Advantages 200
Special Cases 200
Complications 201

SECTION 5

Complications

CHAPTER 18 DIAGNOSIS AND MANAGEMENT OF LAPAROSCOPIC COMPLICATIONS 205-210
Shailesh Puntambekar, Seema Puntambekar, Geetanjali Joshi, Nandan Purandare

Complications 205

CHAPTER 19 MEDICOLEGAL CASES 211-249
Dilip Walke

Case No. 1 211
Case No. 2 229
Case No. 3 231
Case No. 4 235
Case No. 5 238
Case No. 6 242
Case No. 7 246

SECTION 6

Hysteroscopy

CHAPTER 20 INSTRUMENTATION IN HYSTEROSCOPY 253-259
Meenu Agarwal

Room Setup 253
Systems used for the Flow Rate and Irrigation Pressure 254
Cold Light Source 255
Imaging System 255
Telescopes 256
Office Hysteroscopy 256
Mechanical Instruments 257
Electrical Instruments 257
High Frequency Electrosurgical Units 258
Advantages of Bipolar Energies Over Monopolar 258
Maintenance and Sterilization of Instruments 258
Future of Hysteroscopic Instrumentation 259

CHAPTER 21 HYSTEROSCOPIC SEPTUM RESECTION 260-269
Madhuri Kashyap

Embryological Antecedents of the Septum 260
Spectrum of Reabsorption Failure 260
Role of the Septum in Infertility and Repeated Pregnancy Losses and Indications for Treatment 261
Clinical Presentation 262
Clinical Examination 262
Diagnostic Modalities 262
MRI 265
Preoperative Evaluation 265
Hysteroscopic Resection or Metroplasty 265

Cervical Septum 268
Vaginal Septum 268
Postoperative Management 268
Complications 268
Surgical Results and Guidelines 268

CHAPTER 22 OFFICE HYSTEROSCOPY 270-275
Meenu Agarwal

Definition 270
Indications 270
Technique 272
Contraindications 275
Success Rates 275
Advantages 275

CHAPTER 23 HYSTEROSCOPIC CANNULATION OF PROXIMAL TUBAL BLOCK 276-278
Nalini Bagul

Anatomy of Proximal Tube 276
Pathology 276
Classification of Proximal Tubal Occlusion 276
Mechanism of Restoring Fertility 276
Surgical Methods of Removal Of Proximal Tubal Occlusion 276

CHAPTER 24 HYSTEROSCOPIC MYOMECTOMY 279-300
Nagendra Sardeshpande

Submucous Fibroids 279
Diagnosis of Leiomyomas 280
Investigations for Uterine Fibroids 280
Contraindications to Hysteroscopic Myomectomy 285
Preoperative Investigations 285
Preoperative Preparation 286
Surgical Procedures 286
Hysteroscopic Morcellation 291
Hysteroscopic Resection of Intramural Myomas 293
Postoperative Adhesion Prevention 294
Complications 294
Training in Hysteroscopic Myomectomy 297

CHAPTER 25 COMPLICATIONS IN HYSTEROSCOPIC SURGERY—PREVENTION AND MANAGEMENT 301-311
Vivek Salunke, Shinjini Pande

Preoperative Precautions 301
Classification of Complications 302
Entry-related Mechanical Causes 302
Method-related Complications 303
Vasovagal Reaction/Syncope 309
Gas Embolism 309
Electrosurgical Complications 310
Postoperative And Late Complications 310

CHAPTER 4

Gray's Anatomy of Female Pelvis as Seen through the Laparoscope

Shailesh Puntambekar

JAYPEE BROTHERS

INTRODUCTION

The pelvic anatomy is fairly constant with very few variations. Therefore, it easy to understand and master the anatomy. The knowledge of anatomy is more relevant when one has a limited view as in laparoscopy. Better understanding will lead to better surgery. This anatomy is beneficial to surgeons, gynecologist, urologist and any other surgeon who wishes to do pelvic surgery.

The book has described the following structures:

- Organs in the pelvis
- Attachments and ligaments
- Bones and muscles in the pelvis
- Vascular anatomy
- Spaces in the pelvis
- Ureteric anatomy
- Nerves in the pelvis
- Lymphatic drainage.

The description is as per the anatomy and its applications in the surgery.

PELVIS BOUNDARIES

The pelvic cavity starts at the level of sacral promontory and is bounded by bony structures laterally. The caudal limit is the pelvic floor. The structures included are the uterus with adnexa, ureters, urinary bladder, rectum and prostate in males. The anatomy defers in males and females only in the region of the prostate. The pelvic organs are the uterus, bladder and the prostate. The rectum and ureters enter the pelvis from the upper abdomen. With the exception of the ovaries, the blood supply of the organs entering the pelvis arises from above the pelvis. The blood supply of the pelvic organs comes from the lateral side traversing quite a distance from their origin before reaching the organ. This understanding is important.

Relevance: Thus, there is enough length of the vessels available for ligation.

ORGANS IN THE PELVIS

- Uterus
- Ovaries
- Tubes
- Bladder
- Rectum.

LIGAMENTS/SUPPORTS OF THE UTERUS

The uterosacrals, the cardinal ligaments and the paracolpos form a continuous fan-shaped structure. Medially is the rectum, laterally is the internal iliac artery and caudally is the levator ani muscle. The ligaments go from the uterus to the sacrum traversing pararectal and paravesical spaces. The ureter lies on the ligaments and hence has to be retracted laterally to go to the insertion of the ligament into the pelvic wall. The lymphatics and the veins traverse through these ligaments while the uterine artery traverses above the ureter and does not lie in the ligaments.

BONES AND MUSCLES

The psoas muscle is the lateral most structure in the pelvis. The external iliac artery rests on the muscle. The levator ani and the obturator internus muscle form the base of

the pararectal space; they are covered by the endopelvic fascia.

- This is a tough fascia. This fascia forms an important landmark for all pelvic floor repairs
- The pubic bone is exposed as the lateral most boundary during the ileo-obturator lymphadenectomy
- The circumflex iliac vein is in close proximity to this bone. This vein forms the distal limit of the lymphadenectomy
- Anteriorly the pubic symphysis is visualized during the exenteration and pelvic floor repairs.

Thus, the bony boundaries of the pelvic cavity are:

- Superiorly sacral promontory
- Laterally the ala of the pelvic bone
- Posteriorly sacrum
- Inferiorly pubic symphysis.

VASCULAR ANATOMY

The vascular anatomy has been described from the bifurcation of the aorta. *The bifurcation of the common iliac is at the level of sacral promontory.*[1,2] This is an important anatomical landmark. The line of small bowel mesentery crosses at the level of sacral promontory on its way to the right sacroiliac joint. Thus, the pelvic organs can be separated at this level from the upper abdominal organs. There are no vessels (branches) arising from the major vessels at this level anteriorly. *Thus, the organs anterior to the bifurcation can be easily separated from the great vessels*. It is important to recognize these fascial planes. Unless there is inflammation, the loose areolar planes can be easily dissected. In the presence of any branches of aorta or vena cava, this would not have been possible. These planes are essential in the surgeries of the rectum and the vault suspension in females.

The bifurcation of aorta is always at the level of sacral promontory, and it can be considered as the upper boundary of the pelvis.

The only structure of importance is the hypogastric plexus, which is formed at this level. This has been described in details later.

The aorta divides into the common iliac vessels on either side. The division of inferior vena cava is at the lower level and to the left of the aorta.[3]

The veins are in close proximity to the arteries, posteriorly, and hence, the lymphatic clearance anterior to the arteries can be easily achieved without the fear of damaging the veins. *The common iliac, external and internal iliac arteries and veins have no branches or tributaries on the anterior or lateral region. This is important to understand, as this is the reason the lymph node dissection can be done by sweeping all the fibro-fatty tissues. Any branch would have prevented this from happening. These fibro-fatty tissues are outside the fascial covering of the vessels. Knowledge of this plane is important for the lymph nodal dissection.*

The ureter crosses the common iliac artery from the lateral to the medial side at this level.[4,5] The ureter thus continues to be medial to the artery in the pelvis. This should take out the misconception that the ureter has segmental supply, as there is no direct branch of internal iliac supplying the ureter. *This also ensures that the ureter can be completely separated from the major vascular structures thus enabling major cancer surgery to be performed.*

The common iliac then divides into the external and internal iliac arteries.[6,7]

The external iliac artery travels along the iliopsoas muscle on its way to the lower limbs. The external iliac vein lies posteromedial to the artery.[8] Both the external iliac artery and vein are devoid of any branches till they reach the inguinal ligament. At this level, the inferior epigastric artery arises from the anteromedial aspect of the external iliac artery.[9] This artery then ascends on the posterior aspect of the transversalis fascia extraperitoneally and goes cranially to supply the lower abdominal muscles. The origin of inferior epigastric artery is the distal limit of ileo-obturator nodal dissection.

Important Aspects of Inferior Epigastric Artery and Vein

The inferior epigastric vein also drains into the external iliac vein on the anteromedial aspect. Both the vein and artery are closely approximated and are on the medial side of internal inguinal ring. *The inferior epigastric artery is close to the position of inferior ports and has to be visualized before the port insertion, as it is likely to be damaged.* These vessels are the dividing line of direct and indirect inguinal hernias.

- They are extraperitoneal
- They are the only branches of external iliac artery and vein in the pelvis
- They lie on the medial aspect of deep inguinal ring and form the boundaries for classifying hernias either into direct or indirect hernias.

The only tributary of external iliac vein is the deep circumflex iliac vein and it hugs the pelvic bone.

JAYPEE BROTHERS

Arteries

Internal Iliac Artery

The internal iliac artery arises from the common iliac artery at the level of sacral promontory.[10] It courses downward and medially and divides into two divisions: The anterior and the posterior. This division takes place about 2–3 cm distal to the division of common iliac. The posterior division dips into the presacral fascia to supply the gluteal vessels.[11] *The anterior division of internal iliac artery should be ligated distal to the posterior division otherwise, there is claudication in the gluteal region.*[12]

The anterior division continues downward toward the iliac bone and is the main source of supply to the pelvic organs. The first branch arises about 5–6 cm distal to the division of common iliac artery. Thus, enough length of internal iliac is available for ligation before it gives its first branch. This is the most important anatomical landmark. *The internal iliac vein closely hugs the artery posteriorly, and hence, care should be taken while ligating the artery as during emergency situations; the vein can be damaged.*

The first branch of the anterior division of internal iliac is the uterine artery in females and the superior vesicle artery in males. Both, the uterine as well as superior vesicle traverse a long distance through the pararectal space before they supply the organs. Both the vessels cross the ureter anteriorly and supply the ureter through a small branch. *Thus, there is enough length of these vessels available for the surgeon from its origin to its insertion.*[13] *In case of bleeding from the organ, one can go laterally and be sure that there is enough length of artery available for ligation. Also, one has to differentiate between the arterial and venous bleeding. If it is arterial bleeding then one should depress the ureter posteriorly and go lateral to the ureter, while if it venous bleeding, one should retract the ureter upward and go lateral because the vein comes from below the ureter.*

Lateral vascular control can be easily achieved once this anatomy is understood. The easiest way of achieving this lateral control is to open the peritoneum at the level of sacral promontory and identify the ureter as it crosses the common iliac from lateral to medial and then open the plane parallel to the ureter in the direction from cranial to caudal.[14] This opens the pararectal space and the first structure, which crosses transversally, is the artery that can be ligated. *The main trick is remaining lateral and parallel to the ureter.*[15]

After giving the first branch, the anterior division continues caudally and gives two branches in females and one branch in males and then continues as obliterated hypogastric artery and ends by entering into the bladder at the level of the urethra. The two branches in females are superior and inferior vesicle while in males, it is the inferior vesicle. Since the bladder lies anterior to the uterus, the superior vesicle also arises at a plane higher than the uterine artery. *This allows the preservation of superior vesicle during radical surgeries of the uterus.*

The middle rectal artery, which is considered as a branch of anterior division of the internal iliac is absent in 30% of patients. *Thus, during the rectal surgery for cancer, this artery may not be visualized.* The area lateral to the obliterated artery is vascular and harbors the lymph nodes. *Thus, if one stays medial to the artery, the risk of damaging the obturator nerve or external vessels is minimal.*

Salient points of surgical anatomy of internal iliac artery:

- There is 6 cm length of internal iliac artery available for ligation before it gives its first branch
- The uterine artery and the superior vesicle traverse a long distance before they enter the organs
- Obliterated hypogastric artery divides the vascular and avascular spaces
- The internal iliac artery forms the lateral boundary of paravesical and pararectal spaces. The only structures that cross these spaces transversally are the arteries on their entrance to the organs
- The internal iliac vein is closely hugging the artery posteriorly
- The middle rectal artery is inconsistent.

Uterine Artery

The artery originates as the first branch of anterior division of internal iliac artery. It is tortuous and traverses a long distance transversely in the pararectal space to reach the uterus. This course allows it to be accommodated in during the enlargement of uterus.

The artery crosses the ureter anteriorly on its way to uterus. It gives a branch to the ureter. This branch needs to be separated to free the ureter. During surgery, the artery needs to be cut with scissors as any energy source will cause thermal damage to the ureter.

The artery enters the uterus at the level of internal os. It then divides into ascending and descending branches. The descending branch is called as cervical branch and supplies the cervix and upper vagina. The ascending branch runs paracervically upward for some distance before entering the uterus. This allows the surgeon to clamp the uterine in the parcervical region easily. The descending cervical can be avoided by staying medial to the uterine artery after cutting.

The main supply to the uterus comes from the ascending branch and hence all the fibroids grow in the upward direction. The arterial supply thus comes from

JAYPEE BROTHERS

below. This allows the entire separation of the myoma till the base. Had there been supply coming from all around the myoma, separation would not have been possible. Also, the blood supply coming from the base, the depth of the cavity needs to be closed carefully to avoid secondary hemorrhage.

In a radical hysterectomy, the stump of the uterine has to be carefully reflected medially to lateralize the ureter.

Superior Vesicle Artery

The superior vesical artery is the first branch of anterior division of internal iliac artery in males. It crosses the ureter anteriorly to reach the bladder.

In females, it is the second branch and arises at an anterior plane than the uterine artery (due to the fact that the bladder is anterior to the uterus). It, therefore, does not cross the ureter. Thus, it can be avoided when opening the pararectal space.

Obliterated Hypogastric Artery

The anterior division of the internal iliac artery ends as the obliterated hypogastric artery. This forms the medial umbilical ligament on the either side of the bladder. It ends by entering the bladder at the level of urethra. The paravesical space lies medial to it. The obturator fossa lies lateral to it. To avoid damage to the obturator vessels and nerves, the dissection should remain medial to the artery.

Obturator Artery

The obturator is the only medial branch of the internal iliac artery. It runs parallel and posterior to the obturator nerve in the obturator fossa. Thus, it can be damaged during lymph node dissection. The plane of dissection should always be superficial and parallel to the nerve and artery.

Inferior Epigastric Artery

This is already described in the text.

Veins

Common Iliac Vein

The common iliac vein divides into the internal and external vein at caudal to the division of common iliac artery. The veins essentially lie medial or posterior to the main arteries as surrounded by some free space. This is due the reason that the veins have to adjust the diameter as per the venous blood while the arteries can accommodate the increased volume without increasing the diameter. There are no tributaries of common iliac vein. It is closely approximated to the presacral fascia, and thus rarely damaged during surgery.

Internal Iliac Vein

This is closely applied to the anterior branch of internal iliac artery and is posterior to it. It drains the veins of pelvic organs. This can be damaged during the artery if care is not taken. The presacral veins also drain into this. Hence, damage to the presacral veins is difficult to control as the tributaries retract. The parasympathetic fibers arise medial to the vein on their way to the pelvic organs.

External Iliac Vein

The external iliac vein runs medial to the artery and continues as femoral vein. The only tributaries are inferior epigastric and circumflex iliac.

Uterine Vein

The uterine vein is either single or double as it enters the internal iliac vein. It passes underneath the ureter. At its origin, it is closely in association with the parasympathetic fibers. Thus, it is an important landmark in nerve sparing radical hysterectomy. The veins should be ligated medial to the hypogastric nerve so as to preserve the inferior hypogastric plexus.

If there is venous bleeding during surgery one should lift up the ureter anteriorly to visualize and control the bleeding

THE SPACES

Pouch of Douglas or the Rectovaginal Space

The pouch of Douglas is bounded by cardinal and uterosacral ligaments on either side, the uterus anteriorly and rectum posteriorly.

There are two layers of Denonvilliers' fascia. One layer covers the rectum completely while the other lies on the posterior vaginal wall.

Pararectal Space

This is the most important space for the pelvic surgeon. It is a potential space lateral to the ureter. It needs to be exposed surgically, and this can be achieved by opening the peritoneum at the level of sacral promontory. The boundaries of pararectal space are ureter medially, and internal iliac artery. It is a pyramidal space, the apex of

JAYPEE BROTHERS

which is at the level at which the ureter crosses the common iliac and the base is formed by the levator ani muscle, with its covering endopelvic fascia. The space is traversed by the uterine vessels and superior vesicle vessels in females and males, respectively. The parasympathetic nerves from S2, S3 and S4 also traverse this space on their way to the pelvic organs. All the supports of uterus and bladder also traverse this space. The space is opened by remaining parallel and lateral to the ureter. This space dissection helps to expose the entire vascular anatomy. The uterosacral ligament and the hypogastric nerves lie on the medial side of the ureter while the deeper (dorsal) part, Mackenrodt, goes underneath the ureter and carries the uterine vein and the lymphatics. Thus to achieve a good oncological clearance one has to cut the Mackenrodt as lateral as possible.

Paravesical Space

The paravesical space lies lateral to the urinary bladder, and the boundaries are: laterally—the obliterated hypogastric artery, medially—the urinary bladder, inferiorly—pubic bone and superiorly—the pararectal space. Both these spaces are connected to each other and hence the entire vascular structures can be separated from the solid organs. During the radical surgeries, this space needs to be opened to reach the lateral side wall and achieve an optimum oncological clearance. The obliterated hypogastric artery is also called as the lateral umbilical ligament (Hernia surgery—transperitoneal).

Prevesical Space

The prevesical space lies anterior to the urinary bladder and is bounded by pubic symphysis anteriorly and bladder neck and urethra posteriorly. It is continuous space that communicates with the paravesical spaces on the either side. The base is formed by the levator ani muscles.

This space is important during the extraperitoneal as well as transperitoneal hernia surgery. The opening of this space ensures the safety of bladder and the mesh is placed in this space.

This space is also opened selectively in Burch repair and radical prostatectomy. The space can be opened by taking a peritoneal on the urachus and then dissecting the space bluntly as this space is completely avascular.

URETERIC ANATOMY

The ureteric anatomy is probably the most important consideration in pelvic surgery. The ureter crosses the common iliac at the level of sacral promontory from lateral to medial side. The ureter travels in its own endopelvic fascia. It travels in between the fork of the uterine artery and the uterine vein. It then turns medially and anteriorly to pass on the anterolateral aspect of the upper third of the vagina toward the bladder in its own "tunnel" of the endopelvic fascia. This commonly known as the ureteric tunnel is actually the uterovesical ligament. This ligament consistently contains two veins. The ureters enter the bladder at the corners of the trigone approximately 2.5 cm apart.

Blood Supply

The blood supply of the ureter is divided into upper third, middle third and lower third.

- The upper segment is supplied by branches of the renal, gonadal or adrenal arteries
- The middle portion receives small peritoneal twigs and branches from the arteries of the posterior abdominal wall
- The lower segment is the pelvic ureter, which is supplied by branches of common iliac artery or internal iliac artery and its branches.

All these vessels run up and down the ureter to form an anastomotic plexus in the adventitial coat of the ureter.

This anastomosis is deficient in some individuals, hence excessive mobilization of the ureter can lead to necrosis.

Remember: The blood supply of the ureter is parallel to its course. This can be seen as a separate mesentery. This ureteric mobilization when done, should be done along with its mesentery. This avoids the ureteric denudation and avascular fistula at a later date. The presence of mesentery also allows the complete ureteric mobilization from the sacral promontory up to the uterovesical junction, thus, allowing type III radical hysterectomy to be performed.

The ureter seems to be attached to the paracolpos by small fibrous bands, which have to be cut to reach the uterovesical junction.

The ureter is vulnerable for injury at the entry into the bladder, which is the narrowest part of the ureter, and at the point where the uterine artery crosses the ureter.

NERVES

There are four nerves in the pelvic area.

JAYPEE BROTHERS

Genitofemoral Nerve

It lies lateral to the external iliac artery on the psoas muscle. The nerve should be protected during pelvic lymphadenectomy. It runs parallel till it dips down into the muscle.

Obturator Nerve

It lies in the bifurcation between the iliac arteries. The obturator artery and the veins run parallel to the nerve. The vein drains directly into the presacral veins. Thus, the plane of dissection during obturator lymphadenectomy should be superficial to the nerve.

Hypogastric Nerve

It arises from the superior hypogastric plexus, which lies at the bifurcation of the aorta. They carry the postganglionic sympathetic fibers from L1–3. The hypogastric nerves then traverse posterolaterally on the either side of the rectum on their way to the bladder and the pelvic floor. At the level of the uterine vein, this is joined by pelvic splanchnic nerves S2–4. These carry the parasympathetic supply. The hypogastric nerve is identified medial to the ureter at the level of the uterosacral. It lies in the space between the ureter and the uterosacral. The branches of these nerves, which arise medially, supply the rectum, uterus and part of cervix. These branches have to be sacrificed to achieve a nerve sparing radical hysterectomy.

Pelvic Splanchnic Nerve

They arise from S2–4 sacral nerves; they run parallel to the uterine vein on their way to join the hypogastric nerve from the lateral side. Thus, the distal part of the uterine vein becomes an important landmark to identify and preserve these nerves.

Lymphatics

The lymphatics from the uterus travel along the infundibulopelvic ligament and drain into the para-aortic group of nodes. Lymphatics from cervix and upper vagina go along the paracolpos and cardinal ligament, and drain into the ileo-obturator nodes. The obturator node is the first echelon of spread from the cervical cancers.

The ileo-obturator nodal region is defined from the obliterated hypogastric artery medially, to the fascia of obturator internus muscle laterally, and from the external iliac vein above to the obturator nerve below. The contents of this space are the obturator nerve, which is covered with the endopelvic fascia and fatty areolar tissue. During dissection, the nerve is easily exposed by gently sweeping away the areolar tissue over it.

Ten Commandments/"Mantras"

1. The uterine artery arises 6 inches beyond the bifurcation of the common iliac artery. Six inches of internal iliac artery is available for ligation.
2. The uterine artery and vein cross the pararectal space. The ureter lies in the fork between the artery and vein.
3. The pararectal and paravesical spaces are potential spaces that can be dissected easily.
4. The Denonvilliers' fascia consists of two layers, one layer over the cervix and vagina, and the second layer over the rectum.
5. The uterosacral ligaments, the cardinal ligaments and the paracolpos form a continuous fan-shaped structure.
6. The ureteric tunnel is a condensation of pelvic fascia and is vascular. Strands of endopelvic fascia fix the ureter to the vagina.
7. The vesicouterine ligament always has two veins.
8. The hypogastric nerves are medial to the ureter and lateral to the uterosacral ligament.
9. The uterine vein is an anatomical landmark for identification of the pelvic splanchnic nerves.
10. The anatomical variations of the vascular structures and the nerves of the pelvis are uncommon in females.

JAYPEE BROTHERS

for detailed information on obstetrics & gynecology books, visit our website www.jaypeebrother

A Manual of Minimally Invasive Gynecological Surgery

This book is meant for fellows and residents in gynecological endoscopy as well as for practicing gynecologists. The multinational authorship gives it the global view on various aspects of minimally invasive gynecological surgery, and covers both the basic and advanced endoscopic surgeries.

The book has been co-edited by none other than Prof Liselotte Mettler and Dr Ibrahim Alkatout, making it the first-ever published book with an Indo-German collaboration.



Meenu Agarwal MBBS DGO DNB is an eminent Endoscopic Surgeon and Infertility Specialist at Morpheus Bliss Fertility Centre, Pune, Maharashtra, India. She is an alumna of Armed Forces Medical College, Pune, Maharashtra, where she received specialized training in obstetrics and gynecology. She pursued her dream of super-specialization in endoscopy and ART which many a times meant sacrificing the family time with two lovely boys and a loving husband.

Dr Meenu Agarwal has been a trainee and a faculty at the Kiel School of Gynecological Endoscopy, Campus Kiel, Germany. Presently, she is a Consultant Gynecologist at Ruby Hall Clinic and Grant Medical Foundation, Pune, Maharashtra, India. She is also a teacher for the postgraduate students at her Ruby Hall Clinic, and her center is a teaching institute for FOGSI recognized fellowships in endoscopy and ART. Her mission in life is to bring world class technology and skill to her patients. She is an inspiration to her juniors and colleagues.



Liselotte Mettler MD PhD studied medicine in Tübingen, Kiel, Germany, and Vienna, Austria, and pursued her academic career under Kurt Semm. In 1976, she became Senior Consultant and subsequently Professor and Deputy Director of the Department of Obstetrics and Gynecology, University Hospitals Schleswig-Holstein, Campus Kiel, Germany. From 1990 until 2007, she was Head of the Kiel School of Gynecological Endoscopy and Reproductive Medicine. Presently, she is Professor Emeritus, Honorary Patron of the Kiel School of Gynecological Endoscopy and Visiting Professor at the German Medical Center in Dubai. She is president of the 16th World Congress on Human Reproduction in Berlin, Germany from March 18th–21st, 2015.



Ibrahim Alkatout MD PhD MA studied medicine and medical ethics in Marburg, Dresden and Kiel, Germany. He was a resident in the Kiel Institute of Pathology from 2005 to 2007 and in the Kiel University Department for General Surgery from 2007 to 2009. Since 2009, he has been working in the Department of Obstetrics and Gynecology, University Hospitals Schleswig-Holstein, Campus Kiel, Germany. In 2013, he was appointed as the Senior Consultant in Obstetrics and Gynecology with the subspecialty Endoscopic Surgery. In 2014, he became the Head of the Kiel School of Gynecological Endoscopy and was appointed as the University Lecturer.

Available at all medical bookstores
or buy online at www.jaypeebrothers.com

JAYPEE BROTHERS
Medical Publishers (P) Ltd.
www.jaypeebrothers.com

Join us on facebook.com/JaypeeMedicalPublishers

Shelving Recommendation
OBSTETRICS & GYNECOLOGY

ISBN 978-93-5152-766-4