tion on otorhinolaryngology books, visit our website **www.jaypeebrothers.com,** for detailed information on otorhinolaryngology books

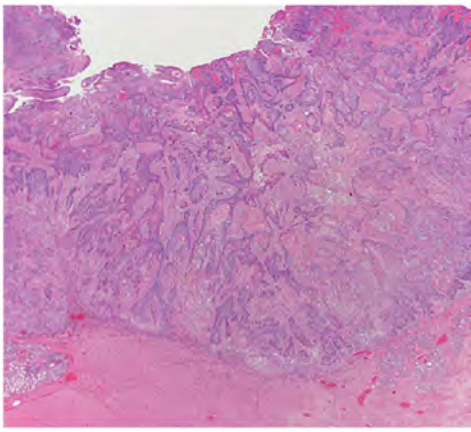

RHINOLOGY HANDBOOK

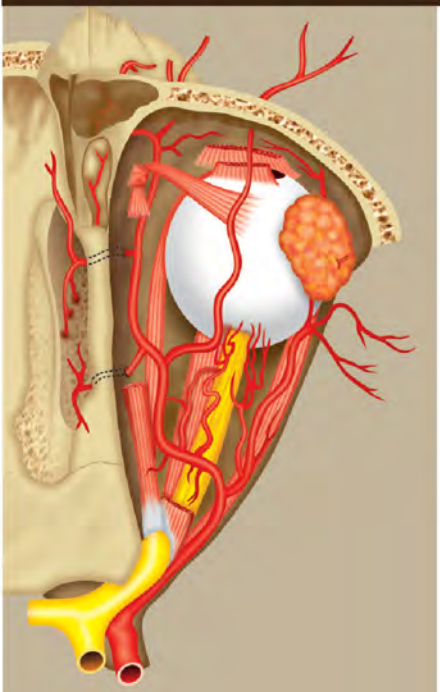

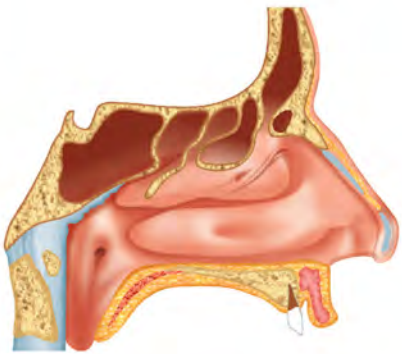

Ashutosh Kacker

Contents

1. Anatomy and Physiology of the Nose, Paranasal Sinuses, and Olfaction **1**
Angela Donaldson, Roheen Raithatha
- Anatomy of the Olfactory System *1*
- Sinonasal Physiology *6*
- Embryology of the Nose and Paranasal Sinuses *8*
- Anatomy of the Nose and Paranasal Sinuses *9*

2. Acute Rhinosinusitis **25**
Abtin Tabaee
- Pathophysiology *25*
- Clinical Presentation and Diagnosis *27*
- Therapy *31*
- Complications *33*

3. Chronic Rhinosinusitis **39**
Patrick Stevens, Belachew Tessema, Seth M Brown
- Epidemiology *39*
- Pathogenesis *40*
- Clinical Presentation, Evaluation and Diagnosis *43*
- Subtypes of Rhinosinusitis *46*
- Management *48*
- Complications of Rhinosinusitis *51*

4. Nasal Obstruction **57**
Qasim Husain, Ashutosh Kacker
- Objective Nasal Obstruction *57*
- Subjective Nasal Obstruction *81*
- Approach to the Patient with Nasal Obstruction *84*

5. Nasal Neoplasms **97**
Valeria Silva Merea, Ashutosh Kacker
- Benign Nasal Neoplasms *98*
- Malignant Nasal Neoplasms *101*

6. Epistaxis **109**
James Foshee, Alfred Marc Iloreta
Gurston G Nyquist, Marc R Rosen
- Epidemiology *109*
- Anatomy *110*
- Management *111*
- Anterior Epistaxis *112*
- Posterior Epistaxis *117*

7. Common Nasal and Sinus Pathologies in Children **125**
Karin PQ Oomen, Ashutosh Kacker
- Sinusitis *125*
- Epistaxis *128*

Index *131*

Chapter

3

Chronic Rhinosinusitis

Patrick Stevens, Belachew Tessema, Seth M Brown

INTRODUCTION

Chronic rhinosinusitis (CRS) is a disorder of the nasal cavity and sinuses that has a significant effect on both the health of patients and their quality of life.[1,2] A distinction between acute, subacute, chronic and recurrent acute rhinosinusitis should be made. Inflammation or infection of the paranasal sinuses is commonly referred to as sinusitis; however this term has largely been replaced by rhinosinusitis, as inflammation of the nasal cavity is concurrently associated with inflammation of the paranasal sinuses. CRS symptoms consist of nasal obstruction, facial congestion/pressure/fullness, discolored nasal drainage and/or hyposmia/anosmia in the setting of nasal and sinus mucosa inflammation that persists for at least 12 consecutive weeks.[3] Patients with CRS can have periods of sudden worsening symptoms referred to as an acute exacerbation of CRS. These patients will have a return to baseline nasal symptoms following treatment.

EPIDEMIOLOGY

Chronic rhinosinusitis is one of the most common chronic health problems in the United States, affecting an estimated 14.1% of the adult population.[4] This results in approximately 500,000 paranasal sinus procedures performed each year in the United States.[5] According to the American Academy of Otolaryngology, sinusitis results in 18–22 million US physician office visits annually with an estimated direct healthcare cost upward of $3.4–5 billion per year.[6] The overall prevalence of CRS in the United States is 146 per 1,000 population.[4] Sinusitis is the fifth most common disease treated with antibiotics.[7] CRS is a common disease worldwide, particularly in areas with high levels of air pollution. Damp temperate climates along with higher concentrations of pollens are associated with a higher prevalence of CRS.[8]

JAYPEE BROTHERS

PATHOGENESIS

Chronic rhinosinusitis development is multifactorial and the term actually may refer to a spectrum of diseases arising from various causes that have a similar constellation of symptoms. There has been a change in nomenclature from sinusitis to rhinosinusitis representing a change in the understanding that inflammation of the nasal cavity plays a role in the pathogenesis of sinus infections. Inflammation of the nasal mucosa results in blockage of the normal drainage pathways of the paranasal sinuses resulting in both acute infections as well as leading to chronic inflammation of the sinuses themselves. Environmental factors such as pollution, allergens, viruses, bacteria and molds all play a role in the development of sinonasal inflammation (Flowchart 1).

A separate etiology that may predispose patients to the development of CRS is anatomical abnormalities that prevent proper drainage from sinus ostia. Anatomic variations can result in compromise of the osteomeatal complex which is the common drainage pathway for the frontal, anterior ethmoid and maxillary sinuses located inferolaterally to the middle turbinate. A deviated septum and a septal spur can block the osteomeatal complex resulting in decreased drainage from the paranasal sinuses on that side which leads to chronic inflammation and chronic infection of one or more sinuses (Fig. 1). An air containing middle turbinate, referred to as a concha bullosa, may act in a similar fashion by blocking natural drainage pathways particularly of the maxillary sinus. The osteomeatal complex can be narrowed by various other anatomical abnormalities including a maxillary cell known as a Haller cell, a prominent ethmoidal bulla and pneumatization or inversion of the uncinate process. A prominent agger nasi cell, the anterior most

Flowchart. 1: Pathophysiology of chronic rhinosinusitis.

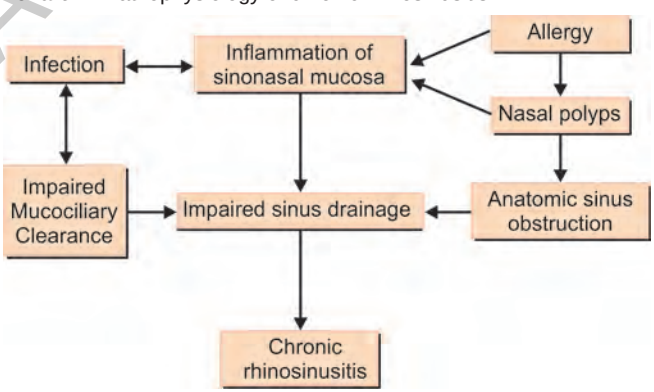

JAYPEE BROTHERS

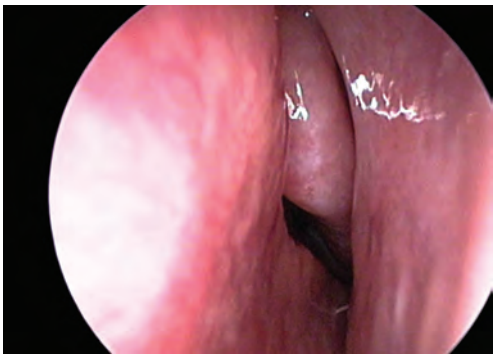

Fig. 1: Deviated nasal septum in the left nasal cavity of a patient.

ethmoid cell, can limit drainage from the frontal sinuses in a similar fashion. These anatomic abnormalities in conjunction with mucosal inflammation result in limitation of drainage from the surrounding sinus. Anatomical variations can be diagnosed with nasal endoscopy or computed tomography (CT) in most cases. Patients with these abnormalities will have continued difficulty with the affected sinus and many will ultimately need surgery to correct the underlying anatomy to prevent future sinus infections.

The sinus passages are lined with ciliated respiratory epithelium. Mucociliary clearance is the process by which cilia transport the mucus blanket overlying respiratory mucosa. The mucus of the paranasal sinuses is directed toward the nasal cavity allowing for removal of irritants and microbes. Disease states that compromise normal cilia function result in impaired clearance of infectious pathogens and ultimately recurrent sinopulmonary infections. Cystic fibrosis is an autosomal recessive disorder caused by a single gene mutation resulting in a defective chloride channel (cystic fibrosis transmembrane regulator). The lack of proper chloride transport results in viscous mucus and impaired mucociliary clearance. Primary ciliary dyskinesia, which includes Kartagener syndrome, is an inherited disorder manifesting in severely impaired mucociliary clearance. Upper respiratory tract infections, inflammation and mucosal swelling may also disrupt normal mucus composition, or the mucociliary clearance flow pattern, know as an acquired ciliary dyskinesia. Various pathogens can alter the normal mucociliary clearance system (discussed below).

Allergic rhinitis (nasal allergies) can also play a role in the pathogenesis of CRS and is present in 25–30% of CRS patients.[9] There is an increased prevalence of allergic rhinitis and atopy in patients with CRS, with one recent survey revealing that 56.7% of patients

JAYPEE BROTHERS

with the diagnosis of CRS also report having allergies.[10] Allergic rhinitis results in increased swelling of the nasal mucosa resulting in impairment of mucociliary clearance. Histopathological studies of ethmoidal tissue and nasal polyp tissue have demonstrated that allergic patients with CRS have chronic allergic inflammation including increased plasma cells and immunoglobulin E (IgE) levels.[11,12]

Nasal polyps are a common feature of CRS. Polyps are inflammatory outgrowths of the sinonasal mucosa and typically arise from the middle meatus and ethmoid region. They usually appear as semitranslucent, pale growths in the nasal cavity. Patients with polyps typically present with perennial nasal congestion, obstruction and anosmia or hyposmia. Often the symptoms worsen with an acute upper respiratory infection. The etiology of nasal polyps is unknown and may be a result of a wide variety of disorders all of which have an effect on mucosal inflammation.[8] Twenty percent of patients with CRS will have nasal polyps.[13] Children and patients with unilateral polyposis often require further workup. In children with nasal polyps, further workup is often indicated to evaluate for cystic fibrosis. Patients with unilateral disease should at the least undergo imaging and often a biopsy to rule out a malignancy or a benign growth such as an inverted papilloma. These conditions can look very similar to polyposis on an exam. Other coexisting disorders which may present with nasal polyposis include: Churg-Strauss syndrome, ciliary dyskinesia and Samter's triad (the constellation of nasal polyps, asthma and aspirin sensitivity). Overall, patients with CRS and nasal polyps should be considered separately from patients without nasal polyposis as treatment regimens may differ (Fig. 2).



Fig. 2: Nasal polyp in left middle meatus of a patient with chronic rhinosinusitis with polyposis.

JAYPEE BROTHERS

CLINICAL PRESENTATION, EVALUATION AND DIAGNOSIS

The symptomatology of patients with CRS varies from patient to patient but includes the following[14] (Table 1):

By definition symptoms must be present for a period of at least 12 weeks to qualify for a diagnosis of CRS. This differentiates CRS from acute (symptoms less than 4 weeks) and subacute (symptoms of 4–12 weeks). While there are numerous similarities between the presentations of acute and CRS, the symptoms of CRS tend to be less severe.

The nasal cavity should be examined using a nasal speculum and a headlight if possible, or at the very least with an otoscope. Assessment should involve examining the floor of the nose as well as the middle meatus for any evidence of purulence or polypoid change to the mucosa. The differential diagnosis includes sinonasal

Table 1: Diagnosis of chronic rhinosinusitis.

Major factors
• Facial pain, pressure or fullness
• Facial congestion or fullness
• Nasal obstruction or blockage
• Nasal discharge, purulence or discolored postnasal drainage
• Hyposmia or anosmia
• Purulence in the nasal cavity
Minor factors
• Headache
• Fever
• Halitosis
• Fatigue
• Dental pain
• Cough
• Ear pain, pressure or fullness

tumors which will require further workup and a tissue diagnosis. Patients should be referred for an otolaryngology evaluation if they present with any of the following symptoms: unilateral only symptoms, bleeding or bloodstained drainage, cacosmia (foul smelling drainage), proptosis, diplopia, epiphora, neurological changes and symptoms refractory to medical management that might require an evaluation for surgical intervention.

JAYPEE BROTHERS

In most cases a diagnosis of CRS is made based on symptoms alone; however the American Academy of Otolaryngology-Head and Neck Surgery (AAO-HNS) recommends that a diagnosis of CRS be confirmed with diagnostic evaluation.[14] Nasal endoscopy, CT and allergy and immunological testing are the three main diagnostic tests that are often utilized in evaluating CRS. Purulent mucus, edema of the middle meatus and ethmoid sinuses and the presence of nasal polyps support a diagnosis of CRS. One prospective study found that nasal endoscopy improved the quality of diagnosis and can be used to visualize features such as nasal polyps or discharge (Figs. 3 and 4).[15]

A CT scan without intravenous (IV) contrast is the gold standard for evaluating the paranasal sinuses for evidence of chronic inflammation. Imaging, however, is not necessary for every patient and CT scans should be reserved for patients in the following circumstances.

- Patients who have failed medical therapy—to evaluate for anatomic abnormalities and continued infection/inflammation.
- Rhinosinusitis with suspected orbital or intracranial complication (should be ordered with and without contrast).



Fig. 3: Office video tower.

JAYPEE BROTHERS

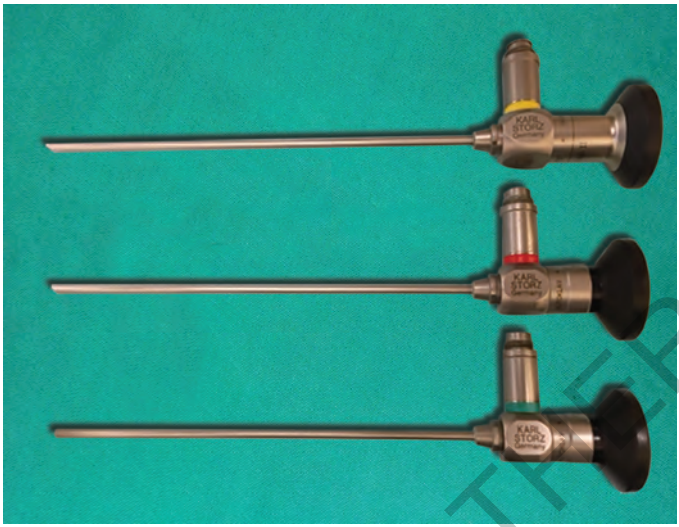

Fig. 4: Rigid endoscopes.

- Nasal mass that is suspicious for malignancy (should be ordered with and without contrast).

It should be noted that the severity of symptoms is not often correlated with the radiographic findings on CT.

A diagnosis of CRS requires of two of the following symptoms:

- Endoscopic evidence of mucosal inflammation—purulent mucus or edema in middle meatus or ethmoid region
- Polyps in nasal cavity or middle meatus
- Radiographic evidence of mucosal inflammation

Allergy and/or immunologic studies are indicated for patients who fail to improve or who have symptoms consistent with either seasonal or environmental allergic rhinitis. Allergy testing via skin prick or intradermal injection is adequate. Radioallergosorbent (RAST) testing, an in vitro allergen-specific immunoassay, is a viable alternative to skin testing if the patient has a strong history of anaphylaxis. However, RAST testing is less sensitive relative to skin testing[16] and can become expensive quickly when testing a number of antigens. For patients who continue to fail aggressive medical and surgical management, immunodeficiency may be present. Selective IgA deficiency, common variable immunodeficiency and hypogammaglobulinemia are the most common humoral immunodeficiencies related to CRS. Also HIV should be considered in refractory patients as up to 64% of patients with AIDS will develop CRS.[17]

JAYPEE BROTHERS

SUBTYPES OF RHINOSINUSITIS (TABLE 2)

Viral

Rhinosinusitis associated with a viral infection is typically self-limiting and symptoms usually last less than 10 days. There is little evidence to show that viral infection leads to ongoing CRS symptoms or mucosal inflammation. Samples of mucosa taken from patients with CRS symptoms undergoing sinus surgery failed to show any respiratory viruses DNA (deoxyribonucleic acid).[18]

Bacterial

Bacteria are believed to play a role in most cases of CRS.[19] *Staphylococcus aureus*, *Staphylococcus epidermidis*, anaerobic Gram-negative bacilli and aerobic Gram-negative enteric rods are common in CRS.[20,21] Polymicrobial infection is also common in CRS.[22] Bacteria may also contribute to the formation of biofilms adherent to the mucosa. Biofilm presence is correlated with more severe preoperative disease based on radiologic and nasal endoscopic scoring as well as persistent postoperative mucosal inflammation.[23,24]

Common bacterial pathogens such as *Hemophilus influenzae*, *Streptococcus pneumoniae*, *Staphylococcus aureus*, and *Pseudomonas aeruginosa* produce specific toxins to impair ciliary motion and coordination.[1,25] In particular, *Staphylococcus aureus* frequently colonizes the nostrils. In patients with CRS with nasal polyposis, *Staphylococcus aureus* rates can be as high as 67%.[26] Enteroxins secreted by certain *Staphylococcus aureus*, known as superantigens activate T cells, eosinophils and B cells resulting in a cytokine storm locally in the tissue and generating a strong inflammatory response.[27,28]

Table 2: Subtypes of chronic rhinosinusitis (CRS).

• Viral	• Typically acute, can exacerbate CRS
• Recurrent acute	• Episodic acute sinusitis with periods of no symptoms between episodes
• Bacterial	• Multiple pathogens, can lead to biofilm formation
• With polyposis	• Allergic patients, aspirin exacerbated respiratory disease, cystic fibrosis
• Noninvasive fungal	• Allergic fungal rhinosinusitis, sinus fungal ball, saprophytic fungal infestation
• Invasive fungal	• Invasive fungal hyphae and necrotic tissue with minimal inflammatory response

JAYPEE BROTHERS

Fungal

Fungal sinusitis can be divided into noninvasive and invasive. Allergic fungal sinusitis is a noninvasive fungal infection of the sinus with evidence of an IgE-mediated allergy to fungus. Persistent opacification of one or more sinus despite extensive medical therapy is common. CT findings include a rim of hypodensity with hyperdense central material. Allergic skin testing or in vitro immunoassays will usually show an allergy to more than one type of fungus. The disease process is typically unilateral and can result in dramatic bony expansion of the paranasal sinuses or erosion of the surrounding bone of the orbit or skull base. There tends to be a high association in atopic patients. Establishing a diagnosis almost always requires surgery to confirm the presence of allergic mucin (Charcot-Leyden crystals), which is thick, inspissated and light tan to brown to dark green in color. The presence of fungi and degranulating eosinophils should be seen in staining and pathology. Dematiaceous fungi (alternaria, bipolaris, curvularia, cladosporium and drechslera) are typically the offending pathogen. Treatment of allergic fungal sinusitis is initially surgical but the use of steroids tends to help control the disease.

Various terms have been used to describe the sinus fungus ball including mycetoma, aspergilloma, and chronic noninvasive granuloma. The disease is defined as the presence of noninvasive accumulation of dense fungal concretion in sinus cavities.[29] Typically it is an aspergillus infection of an isolated paranasal sinus in an immunocompetent patient. There is no invasion of surrounding mucosa. Patients may present with pain over the involved sinus. The only efficacious treatment is surgical removal.

Acute invasive fungal sinusitis, also referred to as acute fulminant fungal rhinosinusitis, is a fungal infection that invades the sinonasal mucosa. Patients typically are immunocompromised with uncontrolled diabetes, HIV, current chemotherapy or transplant patients on immunosuppressants. Symptoms include a painless nasal ulcer or eschar, periorbital or facial swelling and ophthalmoplegia. The fungal infection does not limit itself at the mucosa but can spread to the surrounding bone and soft tissues resulting in thrombosis of surrounding vessels and necrotic tissue. The time course is sudden with rapid progression and can spread to surrounding structures including the eye or brain. Although multiple organisms can be responsible, mucormycoses or aspergillus are most common. An otolaryngologist should be involved with diagnosis for any patient with suspected acute invasive fungal sinusitis to endoscopically examine the patient and biopsy any suspicious

JAYPEE BROTHERS

areas.[30] Treatment is aggressive surgical debridement, systemic antifungals but most importantly a correction of the underlying immunosuppressed state. Overall, invasive fungal sinusitis has a poor prognosis and reversing the underlying immunodeficiency is of the utmost importance.

MANAGEMENT

The medical management of CRS can be confusing due to the spectrum of disease and multiple underlying host and environmental factors. A clinician should base medical management based on the individual patient's symptoms and underlying etiology (Table 3).

Corticosteroids

Both topical and systemic steroids are used in the treatment of CRS. They function to reduce mucosal eosinophil chemotaxis and increase eosinophil apoptosis. Corticosteroids also decrease white blood cell migration, production of inflammatory mediators, antibody production, histamine release and swelling through a variety of mechanisms.[31] One of the first-line treatments of CRS is topical nasal steroids. Long-term treatment with topical nasal steroid sprays has been shown to reduce sinus and nasal inflammation and improve symptoms associated with CRS.[32,33] Several studies have demonstrated benefit with small to medium sized polyps and for rhinitis symptoms.[34,35] There is a minimal side effect profile associated with the daily use of topical steroid sprays.[36]

Table 3: Management options for chronic rhinosinusitis.

• Nasal saline irrigation	• Mechanical washing of sinonasal cavities
• Nasal decongestants	• Reduces nasal mucosa bulk, can temporarily alleviate obstruction
• Topical steroid nasal sprays	• Delivers topical steroids without systemic effects. Can reduce reaction to allergens and decrease polyposis
• Antihistamines	• Reduces inflammation secondary to allergens
• Immunotherapy	• Reduces inflammation secondary to allergens and can decrease need for antihistamines and topical steroids
• Antibiotics	• Decreases bacterial load and maximizes anti-inflammatory treatments. Should be culture driven when possible
• Oral steroids	• Decrease sinonasal inflammation. Reduces polyp size and load
• Endoscopic sinus surgery	• Reserved for anatomical obstruction and cases that are refractory to medical management

JAYPEE BROTHERS

Oral steroids are effective in reducing nasal polyposis and treating allergic rhinitis.[37,38] Acting in the same fashion as topical steroids they are typically more efficacious however have an increased side effect profile, thus long-term systemic steroid treatment is seldom employed. A tapered dose of oral steroids is reserved most commonly for an acute exacerbation of symptoms of CRS and in patients with nasal polyposis.

Nasal Saline Irrigation

Nasal saline irrigation has been thoroughly reviewed as a supplement therapy for CRS.[39] It has been shown to improve endoscopic findings and quality of life as well as an overall improvement of symptoms.[40] It works by mechanically removing irritants and mucus from the sinonasal cavity thereby reducing inflammation, increasing mucociliary clearance and ultimately decreasing the swelling of the sinonasal mucosa. Isotonic saline rinses tend to be the most popular, however, hypertonic saline solutions have been shown to improve mucociliary clearance in patients with CRS as well.[41]

Contamination of nasal saline irrigation delivery devices might perpetuate CRS. Care must be taken to explain the importance to patients of rigorously cleaning these devices between uses in conjunction with the use of distilled water. Nasal saline irrigation devices should be disposed of at regular intervals as a prospective study showed 97% contamination of irrigation bottles by 4 weeks' time[42] (Figs. 5A and B).

Decongestants

Decongestants cause vasoconstriction of nasal vasculature through activation of sympathetic nerves causing the quick relief of nasal congestion. They are either administered as a nasal spray or a pill as an oral decongestant. There are no studies to date which have demonstrated quicker resolution of sinusitis. Topical decongestants are associated with rebound nasal congestion and rhinitis medicamentosa and should not be used continuously for more than three days.

Antibiotics

Antibiotic therapy should provide broad-spectrum coverage to include the organisms discussed above. Antibiotics reduce bacterial load or treat acute bacterial infections in CRS patients. However, bacteria cultured from patients with CRS demonstrate increased

JAYPEE BROTHERS



Figs. 5A and B: (A) NeilMed sinus irrigation bottle and (B) Neti pot

antibiotic resistance. Commonly used agents include amoxicillin, amoxicillin-clavulanate, clindamycin, sulfamethoxazole/trimethoprim and levofloxacin. The role of antibiotics in CRS is to return symptoms to baseline during an acute exacerbation.[43] Antibiotics are typically used for 3–4 weeks to decrease bacterial load and maximize the anti-inflammatory effect.[44] Culture driven antibiotic therapy can be employed in patients with CRS to narrow the spectrum of treatment and to localize the offending bacteria. This is also important as there has been an increasing predominance of methicillin-resistant *Staphylococcus aureus* in community acquired rhinosinusitis. A meta-analysis reviewing endoscopic middle meatal cultures found results similar to maxillary sinus aspirates.[45] This is a relatively easy procedure, done in the otolaryngologist's office that can assist in guiding antibiotic selection.

Antihistamines and Immunotherapy

Allergy treatments are helpful for patients with allergic rhinitis and CRS as it will reduce mucosal inflammation. Oral antihistamines are first-line treatment for atopic patients. Allergy testing is usually recommended in patients with chronic nasal congestion refractory to medical management. Immunotherapy may be useful in decreasing allergic rhinitis symptoms ultimately decreasing CRS symptoms.

Surgical Intervention

Surgical therapy is reserved for a small percentage of patients with CRS. These are patients who fail medical management or have

JAYPEE BROTHERS

r detailed information on otorhinolaryngology books, visit our website **www.jaypeebr**otorhinolaryngology **others.com,** for deta

RHINOLOGY HANDBOOK

Rhinology Handbook addresses in seven concise chapters disorders of the ear, nose, and throat that are highly prevalent in the primary care setting and that can have a substantial impact upon quality of life. With an intensifying shortage of otolaryngologists, an aging and expanding population, and increasing healthcare coverage under the Affordable Care Act, primary care providers will take on greater roles in managing these illnesses. This text familiarizes primary care physicians, medical students, residents, physician assistants, nurse practitioners, and other healthcare professionals with common rhinologic conditions.

The comprehensive knowledge described in Rhinology Handbook will be invaluable to primary care providers, allowing them to effectively diagnose and treat disorders and refer patients to the appropriate otolaryngologist for complicated problems that require more sophisticated diagnostic tools and potential surgical interventions.

Ashutosh Kacker MD is a Professor of Clinical Otolaryngology at Weill Medical College of Cornell University in New York, NY, USA, where he has been for the last 16 years. He is an attending physician at New York–Presbyterian Hospital in New York, NY, USA, and has been awarded the Maxwell Abramson Memorial Teaching and Service Award and has been voted one of the Best Doctors in the New York City Metro Area.



Available at all medical bookstores or buy online at www.jaypeebrothers.com or www.jpmedpub.com

JAYPEE BROTHERS Medical Publishers (P) Ltd.
www.jaypeebrothers.com
Join us on facebook.com/JaypeeMedicalPublishers

Shelving Recommendation
OTORHINOLARYNGOLOGY/ RHINOLOGY

ISBN 978-93-5152-775-6
9 789351 527756