hthalmology books, visit our website **www.jaypeebrothers.com,** for detailed information on ophthalmology books

VOLUME 12

OPHTHALMOLOGY



Recent Advances in OPHTHALMOLOGY

Editors
HV Nema
Nitin Nema

Contents

Editorials

The Femtosecond Laser: A Transformative Technology in Ophthalmology **xvii**
William F Wiley

Surgical Approaches to Posterior Polar Cataract **xx**
Abhay R Vasavada

Pitfalls in the Diagnosis of Angle-closure Glaucoma **xvii**
Rajendra K Bansal

1. **Femosecond Laser-assisted Cataract Surgery** **1**
   Soumya Ganesh Nanaiah, Sudeep Das, Mathew Kurian Kummelil, Rohit Shetty
   - *Basic Science 1*
   - *Nomenclature 1*
   - *Preoperative Evaluation 2*
   - *Planning 4*
   - *Technique 5*
   - *Contraindications 7*
   - *Complications Unique to FLACS 8*
   - *Advantages 9*
   - *Disadvantages 9*
   - *Comparison of Femtosecond Laser-assisted Capsulotomy with Manual Capsulorhexis 10*
2. **Present Status of Phakic Intraocular Lenses in Modern Refractive Surgery** **14**
   Jorge L Alió, Jaime Javaloy
   - *Introduction: What is the Role of Phakic Intraocular Lenses in Today's Refractive Surgery? 14*
   - *Diagnostic Methods for a Modern Phakic IOL Indication as a Surgical Proposal 17*
   - *Phakic IOL Types Available on the Market 25*
3. **Posterior Polar Cataract** **50**
   Arup Chakrabarti, Meena Chakrabarti
   - *Pathogenesis 50*
   - *Inheritance and Genetics 51*
   - *Classification 51*
   - *Clinical Features 52*
   - *Differential Diagnosis 54*
   - *Management 55*

4. Posterior Capsular Opacification **70**
Vijay Kumar Sharma, Neelam Runda, Rajesh Sinha
- *Incidence 70*
- *Risk Factors 70*
- *Types and Mechanism of PCO Development 71*
- *Quantification and Grading 73*
- *Management 73*
- *Prevention 75*
- *Surgical Technique 75*

5. Laser-assisted in Situ Keratomileusis **79**
Frank Joseph Goes
- *Change in Corneal Curvature 79*
- *Personal Experience 80*
- *Birth of LASIK 80*
- *LASIK Complications 86*
- *Retreatment 88*
- *Customized Excimer Laser Treatment 89*
- *Indications and Limitations of LASIK 90*
- *Femtosecond Laser 91*
- *Alternatives 92*

6. Contact Lens-assisted Collagen Cross-linking for Thin Keratoconic Corneas **95**
Soosan Jacob
- *Role of Corneal Thickness 95*
- *Cross-linking in Corneas with Minimum Thickness Less than 400 Microns after Epithelial Removal 96*
- *Technique 96*
- *Complications 99*

7. Biologicals in the Treatment of Noninfectious Uveitis **101**
Parthopratim Dutta Majumder, Jyotirmay Biswas
- *Monoclonal Antibodies 101*
- *Fusion Proteins 102*
- *TNF-α Blocker 104*
- *Lymphocyte Inhibitor 109*
- *Anti-interleukin Antibodies 110*
- *Specific Receptor Antibodies 112*
- *Interferons 112*

8. Pitfalls in the Diagnosis of Angle-closure Glaucoma **117**
Shibal Bhartiya, Parul Ichhpujani, Monica Gandhi, Oscar Albis-Donado
- *Classification 117*
- *Mechanisms 119*
- *Secondary Causes 120*
- *Strong Index of Suspicion: Risk Factors and History 120*
- *Clinical Examination and Pitfalls 121*
- *Slit-lamp Findings 121*
- *Gonioscopy 123*
- *Intraocular Pressure and Fluctuation 125*
- *Anterior Segment Optical Coherence Tomography 128*

- *Ultrasound Biomicroscopy 128*
- *Visual Fields 131*

9. Traumatic Glaucoma 135
Lakshmi P Moorthy, R Ramakrishnan
- *Prevalence and Incidence 135*
- *Mechanism of Glaucoma following Trauma 136*
- *Pathogenesis of Closed Globe Injury 136*
- *Early Onset Glaucoma 137*
- *Late Onset Glaucoma 137*
- *Symptoms 137*
- *Signs 137*
- *Lens-induced Glaucoma 141*
- *Phacomorphic Glaucoma 143*
- *Phacolytic Glaucoma 143*
- *Lens Particle Glaucoma 143*
- *Angle Recession 143*
- *Ghost Cell Glaucoma 144*
- *Glaucoma following Penetrating Injury 145*
- *Glaucoma following Ocular Surgery 147*
- *Management 148*

10. Neovascular Glaucoma 152
Rathini Lilian David, Ronnie Jacob George
- *History 152*
- *Risk Factors of Rubeosis Iridis 152*
- *Pathogenesis 152*
- *Clinicopathologic Course 154*
- *Common Causes of Neovascular Glaucoma 155*
- *Clinical Presentation 158*
- *Management of Neovascular Glaucoma 159*
- *Anti-vascular Endothelial Growth Factor 161*
- *Surgical Management 162*
- *Trabeculectomy 162*
- *Glaucoma Drainage Devices 162*
- *Cyclodestructive Procedures 163*

11. Recent Advances in the Diagnosis and Management of Ocular AIDS 167
Sudharshan S, Sharanaya Abharam
- *Ocular Lesions in AIDS 167*
- *Diagnosis and Management in the HAART Era 168*
- *Anterior Segment Lesions 169*
- *Posterior Segment Manifestations 174*

12. Choroidal Imaging with Enhanced Depth Imaging and Swept-source Optical Coherence Tomography 190
James A Eadie, Suresh R Chandra
- *Imaging of the Normal Choroid 191*
- *EDI and SS-OCT Imaging in Glaucoma 193*
- *Choroidal Imaging in Central Serous Chorioretinopathy 193*
- *Choroidal Imaging in Uveitis 195*
- *Choroidal Imaging in Age-related Macular Degeneration 196*

- *Choroidal Changes in Retinal Vein Occlusions 196*
- *Choroidal Imaging in Myopic Eyes 197*
- *Choroidal Changes in Inherited Retinal Degenerations 198*
- *Retinal and Choroidal Tumors Imaged with OCT 198*

13. Fundus Autofluorescence: Overview and Applications in Retinal Practice **205**

Anand Rajendran, Vinay PG, Vishal Chowdhary

- *Demonstration of Fundus Autofluorescence 205*
- *Fundus Autofluorescence Imaging Modalities 206*
- *Differences between the Autofluorescence Images taken with a cSLO and a Fundus Camera 207*
- *Assessing the Fundus Autofluorescence Image 207*
- *Causes for a Reduced FAF Signal 208*
- *Causes for an Increased FAF Signal 209*
- *Clinical Applications of Autofluorescence 209*
- *FAF Findings in Late-stage CNV 214*
- *FAF Findings Based on CNV Classification 214*
- *Idiopathic Macular Telangiectasia 215*
- *Chorioretinal Inflammatory Disorders 216*
- *Acute Posterior Multifocal Placoid Pigment Epitheliopathy 217*
- *Acute Syphilitic Posterior Placoid Chorioretinitis 218*
- *Multifocal Choroiditis and Panuveitis 218*
- *Acute Zonal Occult Outer Retinopathy 218*
- *Birdshot Chorioretinopathy 218*
- *Perspectives in Imaging Technologies 218*

14. Use and Abuse of Intravitreal Avastin **221**

Dhananjay Shukla

- *Evolution of Usage 221*
- *Standard Indications 222*
- *Avastin as Second-line Treatment 225*
- *Other Indications of Avastin 226*
- *Where Avastin is Not Good? 227*

15. Microincision Vitrectomy Surgery **239**

Lingam Gopal, Mohammed Naseer, Tengku Ain Kamalden

- *Relevant Anatomy 239*
- *History of Evolution of Vitreous Instrumentation 240*
- *Instrumentation and Fluidics in MIVS 240*
- *Advantages of MIVS 244*
- *Limitations of MIVS 244*
- *Problems with Small Gauge Vitrectomy 245*

16. Cerebrovascular Occlusive Disorders **250**

Ambika S

- *Mechanisms 250*
- *Symptoms and Signs 251*
- *Vertebrobasilar Insufficiency 251*
- *Carotid System Occlusion 251*
- *Vertebrobasilar System Occlusions 256*
- *Diagnosis 258*
- *Treatment 258*

Index *261*

CHAPTER

4

Posterior Capsular Opacification

Vijay Kumar Sharma, Neelam Runda, Rajesh Sinha

INTRODUCTION

Posterior capsular opacification (PCO) is the most frequent complication of cataract surgery and develops from residual lens epithelial cells that undergo proliferation, migration, metaplasia and differentiation in the capsular bag after cataract surgery.[1-3] Advances in the surgical technique and development of newer intraocular lens designs and materials have significantly contributed to reduction in PCO rates but it is still a significant problem. Goulden *et al* described the various types of opaque capsule membranes or after cataract in 1948 and described the different methods of its treatment and the complications associated with it.[4] Subsequently, Apple *et al.* described two clinically distinguishable morphological forms PCO: Fibrosis-type PCO and Elschnig-pearl type.[5]

INCIDENCE

The incidence of PCO varies from 18% to 50% in adults; whereas in infants and young children, the rate was found to be about 44% at three months and approaching 100% at two years follow-up.[6,7]

RISK FACTORS

Predisposing factors could be patient related such as age, type of cataract and ocular diseases or surgeon related. Poor hydrodissection and delineation, incomplete cortical clean-up and design, material and surface modifications of IOLs (Fig. 4.1).

Age: Infants and younger children have very high rates of PCO compared to adults obscuring the visual axis and is a significant cause of amblyopia.[8] This higher rate of PCO in young children reflects greater tissue reactivity of lens epithelial cells (LECs).[9]

JAYPEE BROTHERS

Surgical technique: Conventional ECCE has shown higher PCO rates compared to phacoemulsification. Incomplete hydrodissection/hydrodelineation, poor cortical clean-up lead to increased PCO rates. Visually significant PCO was significantly less in eyes within the bag IOL fixation than in those with one haptic in bag and one in sulcus or both haptics in sulcus.[10,11] Polishing has not shown significant reduction in PCO in some clinical studies. Although anterior capsular polishing removes many LECs, but it does not decrease residual cell growth and, conversely may lead to enhanced cell proliferation in capsular bag cultures.[12]

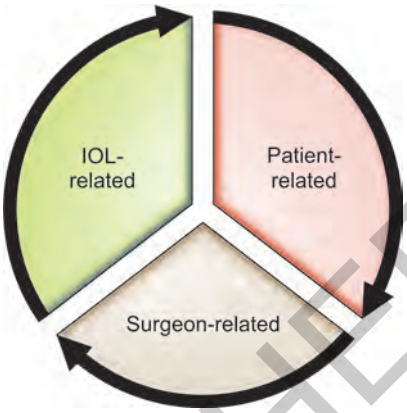

FIG. 4.1: Risk factors of PCO

IOL material: The PCO rate has been reported to be significantly less with acrylic lenses, compared to silicone lenses.[13] Hydrophilic lenses are more biocompatible and may support LECs adhesion, migration and proliferation leading to more PCO compared to hydrophobic acrylic lenses. There was no difference in PCO development between 3-piece and 1-piece acrylic hydrophobic IOLs over two years.[14]

IOL design: Various modifications have been done in the IOL design to reduce proliferation and migration of LECs by creating a mechanical barrier effect. IOLs with a sharp edge or continuous 360-degree square edge have significantly decreased PCO.

Type of cataract: It was observed that senile complete cataracts (mature cataracts) had a significantly lower tendency to produce PCO than other cataract types (nuclear, cortical, posterior subcapsular).[15]

Coexisting disease: Patients with diabetes mellitus (DM) who undergo cataract surgery have been found to have higher PCO rates compared to patients without DM.[16] Axial myopia does not affect PCO rates after cataract surgery as was suggested by some previous studies.[17]

TYPES AND MECHANISM OF PCO DEVELOPMENT

In extracapsular cataract extraction, posterior capsule and part of anterior capsule are left in situ. Despite the modern irrigation and aspiration devices, some residual lens epithelial cells (LECs) are left behind which undergo proliferation, migration, epithelial to mesenchymal transition (EMT), collagen deposition and lens fiber regeneration leading to posterior capsular opacification. Clinically, there are two morphological types of PCO: (1) Fibrosis type and (2) Elschnig's pearls type. Both types are visually significant.

JAYPEE BROTHERS

Fibrosis type: In this type, PCO is caused by proliferation and migration of LECs which undergo epithelial to mesenchymal transition leading to metaplasia and causing posterior capsular folds and wrinkles, leading to significant visual disturbances. If LECs become trapped between two layers of the capsule and continue producing lens fibers resulting in formation of a dense ring behind the iris which is usually not visually significant as it lies outside the visual axis. This is called the *ring of Sommerring* (Fig. 4.2). Although, sometimes, it may get dislocated in to anterior chamber and may cause visual problems.

Elschnig's pearls type: In this type, subcapsular cells in the len's equatorial region proliferate and develop in to large balloon-like cells instead of forming lens fibers. They migrate over the posterior capsule into the visual axis.

Histological features of PCO are well understood but molecular mechanisms are still poorly understood. Various cytokines and growth factors have been found to have important role in the pathogenesis of PCO. Transforming growth factor β (TGF-β) and fibroblast growth factor 2 (FGF-2) act as stimulators of myofibroblastic differentiation and attachment of LECs to the underlying posterior capsule leading to development of PCO.[18] During PCO formation, the TGF-β activated pathway is influenced by SPARC (secreted protein, acidic, and rich in cysteine) matricellular protein which is a potent cell-cycle inhibitor that arrests cells in mid-G1 phase.[19] Matrix metalloproteinase-2 (MMP2) also plays a critical role in TGF β2-mediated matrix contraction, which appears to be independent of MT1-MMP suggesting that MMP2 inhibition may provide a novel strategy for the treatment of PCO.[20] Exogeneous hyaluronic acid (HA) can induce lenticular migration and CD44 expression and, hence, the use of surgical viscoelastics that contained HA may result in increased rates of ex vivo PCO suggesting judicious selection and use of viscoelastic material during cataract surgery.[21]

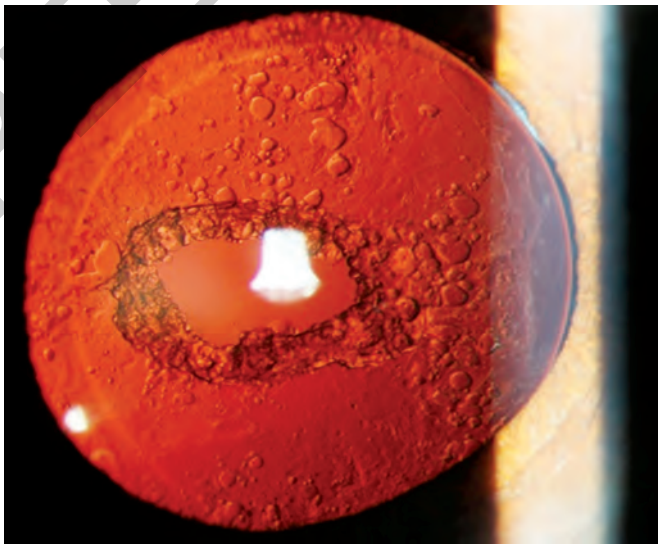

FIG. 4.2: Elschnig's pearl

JAYPEE BROTHERS

QUANTIFICATION AND GRADING

Various attempts have been made to quantify and grade PCO in the past. Some of the methods used include objective automated quantification of after-cataract (AQUA); the subjective evaluation of posterior capsular opacification (EPCO) system and posterior capsule opacification software (POCO). Although analysis of the various systems of PCO grading published in literature shows that no single system is gold standard and it is difficult to comment on the advantages of one system over another.[22]

MANAGEMENT

Understanding of the pathogenesis of PCO development has given opportunities to improve surgical technique and modification of IOL designs and materials. These measures have decreased rates of PCO but have not eradicated it and it is still a commonest complication of cataract surgery. The treatment of PCO is typically neodymium: YAG (Nd: YAG) laser posterior capsulotomy (Fig. 4.3). This is a simple procedure in most cases, but may lead to many complications which include IOL damage, IOL subluxation or dislocation, retinal detachment, and secondary glaucoma.[23]

The management of PCO in a child (Fig. 4.4) is difficult. The efficacy of Nd: YAG laser capsulotomy in the children largely depends upon the density of the membrane and the cooperation of the child. A pars plana membranectomy (Fig. 4.5) may be needed, if the visual axis is occluded by secondary membrane. Some authors advocate a Nd: YAG laser capsulotomy at 3 weeks after surgery in children.[24] A longer follow-up of pseudophakic children who have undergone Nd: YAG laser capsulotomy is required to evaluate the long-term effects.

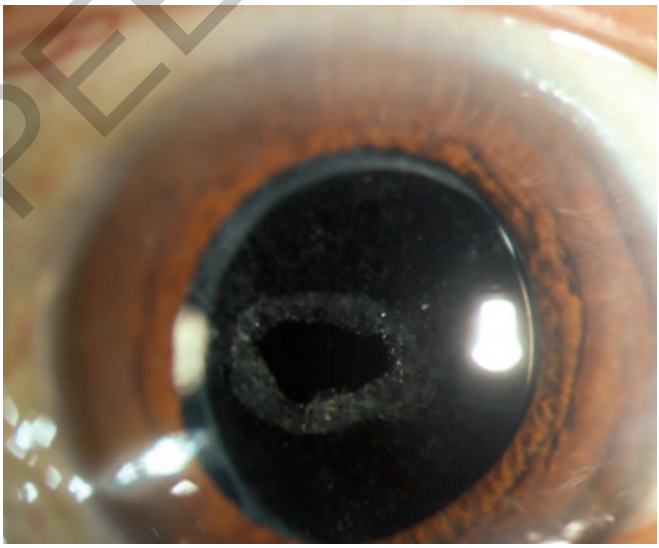

FIG. 4.3: Nd: YAG capsulotomy

JAYPEE BROTHERS

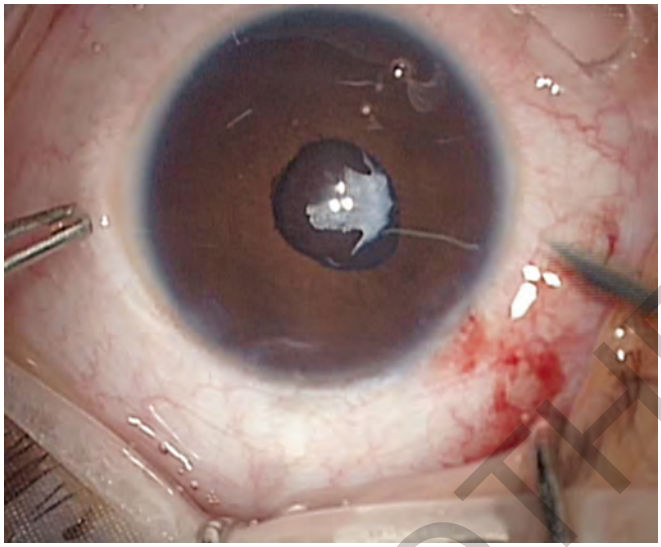

FIG. 4.4: Nine months old child with thick PCO

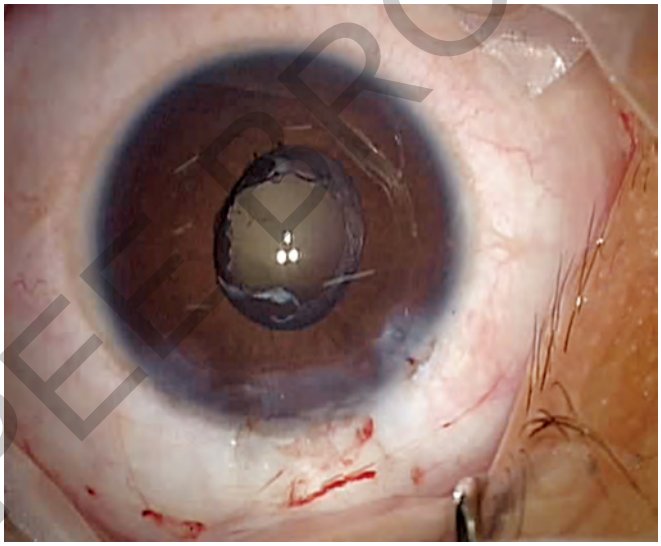

FIG. 4.5: Same child after membranectomy

Also, recurrence of opacification of visual axis has been noted following Nd: YAG capsulotomy in young children. Thus, prevention of PCO is highly desirable in children. In children, surgical technique has been modified which involves creating an opening in the posterior capsule by posterior continuous curvilinear capsulorhexis (PCCC), a limited anterior vitrectomy with or without optic capture.[25] Optic capture provides better IOL centration, but tends to predispose to an increased uveal inflammatory response and is technically more demanding. Opacification of the visual axis has been reported following optic capture without anterior vitrectomy.[26]

JAYPEE BROTHERS

PREVENTION

Development of PCO is multifactorial, and its prevention depends on the quality of the surgery, as well as on the quality of the IOL implanted. Each factor does not act in isolation and it is the interaction of several factors that produces the best results in prevention of PCO (Fig. 4.6).

SURGICAL TECHNIQUE

- Hydrodissection enhanced cortical clean-up
- Capsulorhexis size slightly smaller than IOL optic size
- Polishing the posterior and remnant anterior capsule
- In the bag IOL implantation
- PCCC and limited anterior vitrectomy in infants and young children.

IOL design and material

- Acrylic IOLs have less PCO rates compared to silicone lenses. Hydrophobic IOLs have less PCO rates compared to hydrophilic lenses
- Three piece acrylic IOLs and one piece acrylic IOLs have no difference in PCO rates
- Enhancement of the contact between the IOL optic and the posterior capsule reduces PCO
- An IOL with a square truncated optic edge that provides mechanical barrier effect and decreases PCO
- Various surface modifications of IOLs have been tried with heparin, polytetrafluoroethylene and recently plasma and polyethylene glycol.[27-31] These inhibit cell and protein adhesion and decrease PCO.

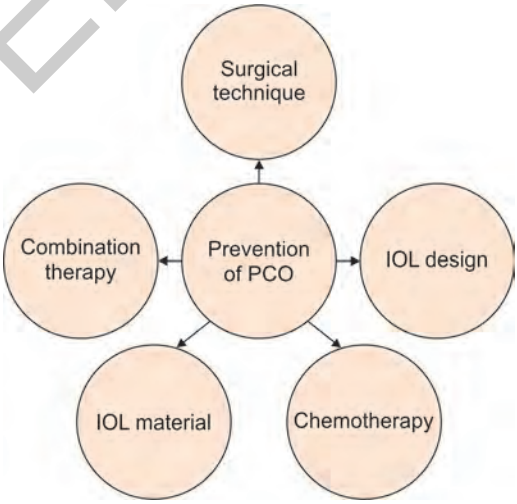

FIG. 4.6: Factors that may prevent PCO

JAYPEE BROTHERS

Chemotherapy

Chemotherapy involves intraocular application of pharmacological agents to prevent PCO and commonly studied methods include direct injection into the anterior chamber, addition to the irrigating solution, or impregnation of the IOL. Pharmacological agents such as thermosetting plastic prepared with phenol formaldehyde resins, methotrexate, mitomycin, daunomycin, and fluorouracil have been shown to be effective in preventing PCO in vitro, but in vivo studies have shown their toxicity to corneal endothelial cells, iris, ciliary body epithelial cells, and retina.[32-34] Various studies showed promise for finding medical treatment of PCO by targeting the survival, adhesion, proliferation, migration, and transdifferentiation of residual LECs, but the risk of their toxic effects on surrounding intraocular tissues has restricted their clinical use. The perfect capsule device (Milvella Ltd. Sydney, Australia), used by Maloof et al. permits cytotoxic agents to be delivered selectively to the capsular bag, selectively targeting residual LECs and also allows cytotoxic agents to be removed after treatment during the cataract surgery procedure, may be a way ahead in the prevention of PCO.[35]

CONCLUSION

Our understanding of mechanisms of PCO development has increased significantly in recent times, nevertheless, PCO remains yet the most common unresolved complication of cataract surgery, especially in young adults and children. Therefore, research aimed at improving surgical techniques to eliminate almost all LECs from the capsular bag at the time of surgery, optimizing IOL biocompatibility, minimizing postoperative inflammatory reaction, and targeting residual LECs by therapeutic agents that have minimal or no effect on other ocular tissues, is highly desirable. Also further research on the prevention of any form of opacification or fibrosis within the capsular bag is increasing in importance, especially with the advent of specialized IOLs such as accommodative lenses, the functionality of which will likely require elasticity of the capsular bag and the long-term transparency.

REFERENCES

1. Thompson AM, Sachdev N, Wong T, Riley AF, Grupcheva CN, McGhee CN. The Auckland Cataract Study: 2 year postoperative assessment of aspects of clinical, visual, corneal topographic and satisfaction outcomes. Br J Ophthalmol. 2004; 88:1042-8.
2. Apple DJ, Solomon KD, Tetz MR, Assia EI, Holland EY, Legler UF, et al. Posterior capsule opacification. Surv Ophthalmol. 1992;37:73-116.
3. Kappelhof JP, Vrensen GF. The pathology of after cataract. A minireview. Acta Ophthalmol Suppl. 1992;205:13-24.
4. Goulden C. The capsular complications of cataract extraction. Proc R Soc Med. 1948;41(5):271-80.
5. Apple DJ, Solomon KD, Tetz MR, Assia EI, Holland EY, Legler UF, et al. Posterior capsule opacification. Surv Ophthalmol, 1992;37:73-116.

JAYPEE BROTHERS

6. Buckley EG, Klombers LA, Seaber JH, Scalise-Gordy A, Minzter R. Management of the posterior capsule during pediatric intraocular lens implantation. Am J Ophthalmol. 1993;115:722-8.
7. Apple DJ, Solomon KD, Tetz MR, Assia EI, Holland EY, Legler EF. Posterior capsular opacification. Surv Ophthalmol. 1992;37:73-116.
8. Basti S, Ravi Shankar U, Gupta S. Results of a prospective evaluation of three methods of management of pediatric cataract. Ophthalmology. 1996;103:713-20.
9. Buckley EG, Klombers LA, Seaber JH, Scalise-Gordy A, Minzter R. Management of the posterior capsule during pediatric intraocular lens implantation. Am J Ophthalmol. 1993;115:722-8.
10. Ram J, Pandey SK, Apple DJ, Werner L, Brar GS, Singh R, et al. Effect of in-the-bag intraocular lens fixation on the prevention of posterior capsule opacification. J Cataract Refract Surg. 2001;27(7):1039-46.
11. Vilhjalmsson GA,[1] Lucas BC. Incidence of secondary cataract in sulcus versus capsular bag fixation of posterior chamber lenses. Klin Monbl Augenheilkd. 1992; 200(3):167-70.
12. Liu X, Cheng B, Zheng D, Liu Y, Liu Y. Role of anterior capsule polishing in residual lens epithelial cell proliferation. J Cataract Refract Surg. 2010;36(2):208-14.
13. Hollick EJ, Spalton DJ, Ursell PG, Pande MV, Barman S, Boyce J, et al. The effect of polymethylmethacrylate, silicone and polyacrylic intraocular lenses on posterior capsular opacification 3 years after cataract surgery. Ophthalmology. 1999;106:49-55.
14. Zemaitiene R, Jasinskas V, Auffarth GU. Influence of three-piece and single-piece designs of two sharp-edge optic hydrophobic acrylic intraocular lenses on the prevention of posterior capsule opacification: a prospective, randomised, long-term clinical trial. Br J Ophthalmol. 2007;91(5):644-8.
15. Argento C, Nuñez E, Wainsztein R. Incidence of postoperative posterior capsular opacification with types of senile cataracts. J Cataract Refract Surg. 1992;18(6):586-8.
16. Ebihara Y, Kato S, Oshika T, Yoshizaki M, Sugita G. Posterior capsule opacification after cataract surgery in patients with diabetes mellitus. J Cataract Refract Surg. 2006;32(7):1184-7.
17. Vasavada AR, Shah A, Raj SM, Praveen MR, Shah GD. Prospective evaluation of posterior capsule opacification in myopic eyes 4 years after implantation of a single-piece acrylic IOL. J Cataract Refract Surg. 2009;35(9):1532-9.
18. Meacock WR, Spalton DJ, Stanford MR. Role of cytokines in the pathogenesis of posterior capsule opacification. Br J Ophthalmol, 2000;84:332-6.
19. Gotoh N,[1] Perdue NR, Matsushima H, Sage EH, Yan Q, Clark JI. An in vitro model of posterior capsular opacity: SPARC and TGF-beta2 minimize epithelial-to-mesenchymal transition in lens epithelium. Invest Ophthalmol Vis Sci. 2007;48(10):4679-86.
20. Eldred JA, Hodgkinson LM, Dawes LJ, Reddan JR, Edwards DR, Wormstone IM. MMP2 activity is critical for TGFβ2-induced matrix contraction-implications for fibrosis. Invest Ophthalmol Vis Sci. 2012;53(7):4085-98.
21. Chandler HL, Haeussler DJ Jr, Gemensky-Metzler AJ, Wilkie DA, Lutz EA. Induction of posterior capsule opacification by hyaluronic acid in an ex vivo model. Invest Ophthalmol Vis Sci. 2012;53(4):1835-45.
22. Aslam TM, Dhillon B, Werghi N, Taguri A, Wadood A. Systems of analysis of posterior capsule opacification. Br J Ophthalmol. 2002;86(10):1181-6.
23. Charles S. Vitreoretinal complications of YAG laser capsulotomy. Ophthalmol Clin North Am. 2001;14:705-10.

JAYPEE BROTHERS

24. Atkinson CS, Hiles DA. Treatment of secondary posterior capsular membranes with the Nd:YAG laser in a pediatric population. Am J Ophthalmol. 1994;15:118:496-501.
25. Gimbel HV. Primary continuous curvilinear capsulorhexis and optic capture of the intraocular lens implant to prevent secondary opacification in pediatric cataract surgery. J Cataract Refract Surg. 1997;23:652-6.
26. Vasavada AR, Trivedi RH. Role of optic capture in congenital cataract and intraocular lens surgery in children. J Cataract Refract Surg. 2000;26:824-31.
27. Yuan Z, Sun H, Yuan J. A 1-year study on carbon, titanium surface-modified intraocular lens in rabbit eyes. Graefes Arch Clin Exp Ophthalmol. 2004; 242(12):1008-13.
28. Larsson R, Sele´n G, Björdklund H, Fagerholm P. Intraocular PMMA lenses modified with surface-immobilized heparin: Evaluation of biocompatibility in vitro and in vivo. Biomaterials. 1989;10(8):511-6.
29. Werner L, Legeais JM, Nagel MD, Renard G. Evaluation of teflon-coated intraocular lenses in an organ culture method. J Biomed Mater Res. 1999;46(3):347-54.
30. Yuen C, Williams R, Batterbury M, Grierson I. Modification of the surface properties of a lens material to influence posterior capsular opacification. Clin Experiment Ophthalmol. 2006;34(6):568-74.
31. Bozukova D, Pagnoulle C, De Pauw-Gillet MC, et al. Improved performances of intraocular lenses by poly (ethylene glycol) chemical coatings. Biomacromolecules. 2007;8(8):2379-87.
32. Nishi O. Posterior capsule opacification, part 1: Experimental investigations. J Cataract Refract Surg. 1999;25(1):106-17.
33. Biswas NR, Mongre PK, Das GK, Sen S, Angra SK, Vajpayee RB. Animal study on the effects of catalin on after cataract and posterior capsule opacification. Ophthalmic Res. 1999;31(2):140-2.
34. Power WJ, Neylan D, Collum LM. Daunomycin as an inhibitor of human lens epithelial cell proliferation in culture. J Cataract Refract Surg. 1994;20(3):287-90.
35. Maloof A, Neilson G, Milverton EJ, Pandey SK. Selective and specific targeting of lens epithelial cells during cataract surgery using sealed-capsule irrigation. J Cataract Refract Surg. 2003;29(8):1566-8.

JAYPEE BROTHERS

r detailed information on ophthalmology books, visit our website **www.jaypeebrothers.com,** for detailed informatio

Recent Advances in OPHTHALMOLOGY–12

Salient Features

- Contains 16 selected chapters, and 3 editorials
- Latest innovation in the management of cataract—femtosecond laser-assisted cataract surgery
- Present status of phakic IOLs and LASIK
- Use of immunomodulatory agents in the treatment of noninfectious uveitis
- Common pitfalls in the diagnosis of angle-closure glaucoma
- Choroidal imaging using enhanced depth imaging and swept-source optical coherence tomography that provides insight into pathogenesis of many chorioretinal disorders
- Noninvasive imaging of retina using fundus autofluorescence for clinical and research purposes
- Small gauge vitrectomy surgery that has revolutionized the vitreoretinal surgery.



HV Nema MS has a distinguished academic career and is well known for teaching, researches and publications. He has served as a Consultant Editor/Advisory Editor to Indian Journal of Ophthalmology, Afro–Asian Journal of Ophthalmology and Indian Journal of Optometry. He has published more than 6 dozen papers in the national and international journals. He is an established author in the field of ophthalmology. *Ophthalmic Syndromes* (Butterworth, London, UK, 1973) and *Textbook of Ophthalmology* (6th edn, 2012, Jaypee Brothers Medical Publishers, New Delhi, India) are some of his popular books. He has edited 11 volumes of *Recent Advances in Ophthalmology* and 3 editions of *Diagnostic Procedures in Ophthalmology*, which were well received by readers and favorably reviewed in Indian and international journals. He has delivered guest-lectures in many universities.



Nitin Nema MS DNB is an experienced Phaco and Vitreoretinal Surgeon. He did his Fellowship from Aravind Eye Hospital, Madurai, Tamil Nadu, India. He gained clinical and research experience from the University of Illinois at Chicago, and the University of Wisconsin at Madison in the USA. He was awarded a Fellowship by the All India Ophthalmological Society to work on a Project on Uveitis at Sankara Nethralaya, Chennai, Tamil Nadu, India. He was awarded Dr Mohan Lal Gold Medal for the best paper. He had authored (in collaboration with Dr HV Nema) 2 textbooks: *Anatomy of the Eye and Adnexa* (3rd edition) and *Textbook of Ophthalmology* (6th edition), and edited 10 volumes of *Recent Advances in Ophthalmology*, and 3 editions of *Diagnostic Procedures in Ophthalmology.*

Available at all medical bookstores
or buy online at www.jaypeebrothers.com

JAYPEE BROTHERS
Medical Publishers (P) Ltd.
www.jaypeebrothers.com

Join us on facebook.com/JaypeeMedicalPublishers

Shelving
Recommendation
OPHTHALMOLOGY

ISBN 978-93-5152-790-9