t our website **www.jaypeebrothers.com,** for detailed information on surgery books, visit our website **www.jaypeebrothers.com**

Step by Step Manual of Laparoscopic Surgery

Laparoscopic Hernia Surgery

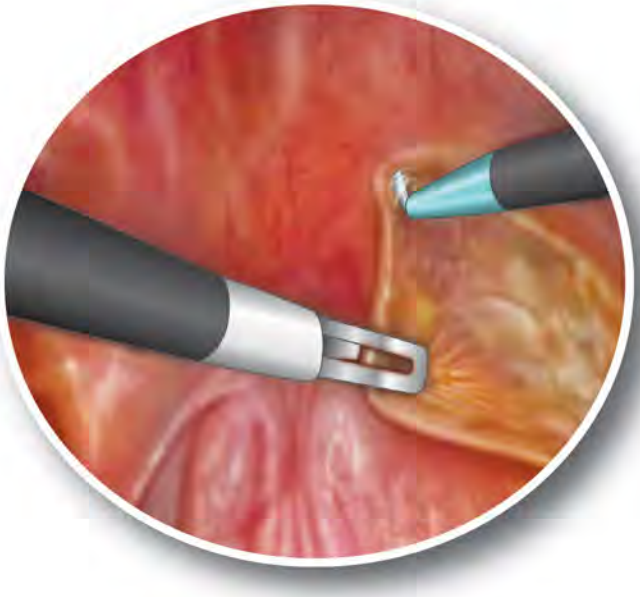

Series Editors
JS Rajkumar
Neha Shah



Includes Interactive DVD-ROM
Containing 4 Videos
Duration 43 minutes

Volume 4

JAYPEE

Foreword
CMK Reddy

Contents

1. Endoscopic Anatomy of Inguinal Region **1**

- Hesselbach's Triangle *2*
- Myopectineal Orifice of Fruchaud *2*
- Fossae *4*
- Preperitoneal Space *4*
- Other Veins *9*

2. Total Extraperitoneal Repair **14**

- Indications *14*
- Positions *14*
- Principle *14*
- Mesh Details *14*
- Anesthesia *15*
- Technical Steps *15*

Laparoscopic TEP

3. Transabdominal Preperitoneal Prosthesis **25**

- Indications *25*
- Principle *25*
- Mesh Details *25*
- Technical Details *25*

Laparoscopic TAPP

4. Decision Making—Open or Laparoscopic Ventral Hernia Mesh Plasty **38**

- Patients Undergoing Other Surgeries Laparoscopically—Can They Have Laparoscopic Ventral Hernia Repair? *42*

5. The Physics of Laparoscopic Ventral Hernia Repair **43**

- The Physics Basis of the Ventral Hernia Mesh Plasty *43*
- Laparoscopic Ventral Hernia Mesh Plasty Rationale *44*

Laparoscopic Para umbilical hernia

6. Incisional Hernia **46**

- Technique *46*
- Taking the Mesh Inside for Application *50*

Laparoscopic Incisional hernia

7. Meshes and Fixation Devices in Laparoscopic Ventral Hernia Repairs **62**

- Some Properties of Meshes *62*
- Types of Meshes *63*

8. Spigelian Hernia **69**

- Pathophysiology *69*
- Spigelian Hernia Belt *69*
- Repair of Spigelian Hernia *70*
- Laparoscopic Intraperitoneal Onlay Mesh Plasty *70*
- Laparoscopic TAPP Technique *74*

Index *75*

DVD Contents

Chapter 2 video: Laparoscopic TEP
Chapter 3 video: Laparoscopic TAPP
Chapter 5 video: Laparoscopic Para umbilical hernia
Chapter 6 video: Laparoscopic Incisional hernia

Chapter

3

Transabdominal Preperitoneal Prosthesis

Transabdominal preperitoneal prosthesis (TAPP) which indicates entry into the preperitoneal space through the abdominal cavity.

INDICATIONS

- All direct and indirect inguinal hernias can be repaired with this technique.
- It is preferred over the total extraperitoneal prosthesis (TEP) in the case of large indirect inguinal hernias and irreducible inguinal hernias.
- Patients who are undergoing another intraperitoneal procedure, such as ovarian cystectomy, splenectomy, etc. can have a TAPP if they also have an inguinal hernia.

We recommend that surgeons starting laparoscopic inguinal hernia repair may begin with the TAPP technique, which permitting familiarization with the complex inguinal anatomy, before proceeding to the TEP type of repair.

PRINCIPLE

The anchor of the TAPP procedure is the access to the preperitoneal plane from the peritoneal cavity. This is the same plane that has been described in chapter 2 "Total Extraperitoneal Repair". Once this plane has been reached and widely dissected out, deployment of the mesh is done to cover the posterior inguinal wall completely.

MESH DETAILS

Discussed in chapter 2 "Total Extraperitoneal Repair".

TECHNICAL DETAILS

Anesthesia: Unlike the TEP technique, this procedure is always performed under general anesthesia as it always entails a pneumoperitoneum.
Position: Supine with both the arms abducted to 90°.

JAYPEE BROTHERS

We use a standard Veress needle to initiate pneumoperitoneum and insufflate an initial 2 L of carbon dioxide.

The first port (11 mm) is inserted immediately below the umbilicus through a vertical or transverse cut. This is the optical port.

A 10 mm 30° telescope is inserted through the optic port. The telescope faces upward, i.e. to look up at the anterior abdominal wall (Fig. 3.1).

The next two ports are along the right and left midclavicular lines 1 cm below the level of the optical port so as to form a gentle optical triangle. Both these ports are 5 mm (Fig. 3.2).

The patient is tilted into the head down position with a rotation so as to bring the side of surgery above, e.g. right up position for a right inguinal

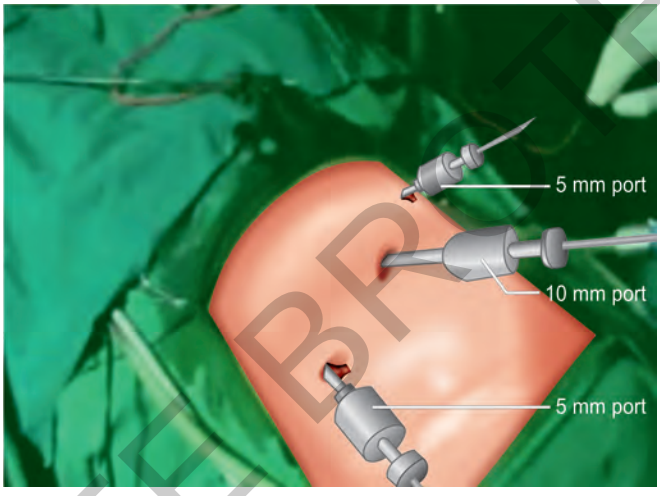

Fig. 3.1: Port placement for left inguinal hernia repair.

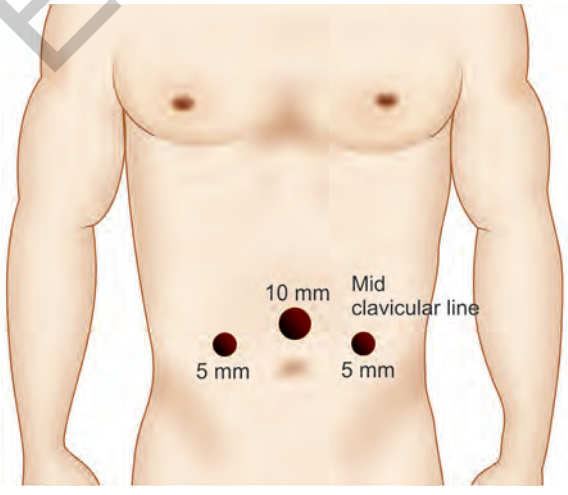

Fig. 3.2: Port placement for bilateral TAPP.

JAYPEE BROTHERS

hernia. A Maryland's forceps is inserted into the left 5 mm port and an L-hook is inserted into the right port (the rest of the description continues for a right inguinal hernia) (Fig. 3.3).

At this point, the anatomy of the inguinal canal is noted:

- In the midline, the median umbilical ligament runs from the apex of the bladder to the umbilicus (contains the obliterated urachus). Further laterally, the medial umbilical ligament runs at the apex of a peritoneal fold from the medial aspect of the inguinal canal up to the umbilicus carrying the obliterated umbilical artery. Still more laterally, the lateral umbilical ligament is the fold of peritoneum that is raised by the inferior epigastric artery and vein (Fig. 3.4).
- At the lower end of the lateral umbilical ligament, the deep inguinal ring is found into which the testicular vessels run from the lateral side and the vas deferens runs in from the medial side (Fig. 3.5).

The triangle between the vas deferens and the testicular vessels is known as the "triangle of doom", and it refers to the underlying iliac artery and vein.

The iliopubic tract is a thickened band of tendinous fascia that runs from the anterior superior iliac spine to the pubic tubercle. The triangle between the peritoneal edge, the testicular vessels and the iliopubic tract is known as the "triangle of pain" as it houses four nerves that run on the iliopsoas, viz. the lateral cutaneous nerve of thigh, the femoral nerve and the femoral and genital branches of the genitofemoral nerve, from lateral to medial.

The corona mortis or "the circle of death" refers to the anastomotic network between the pubic branch of the cremasteric vessels and the pubic branch of the obturator. These vessels run on the posterior aspect of the pubic ramus and on Cooper's ligament.

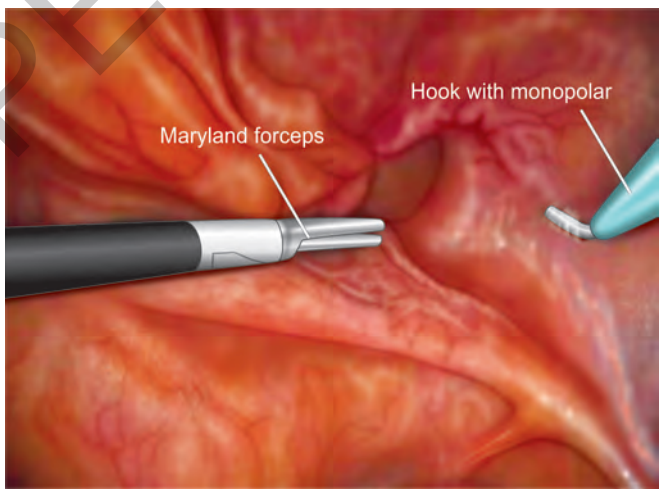

Fig. 3.3: Opening the peritoneum with monopolar hook.

JAYPEE BROTHERS

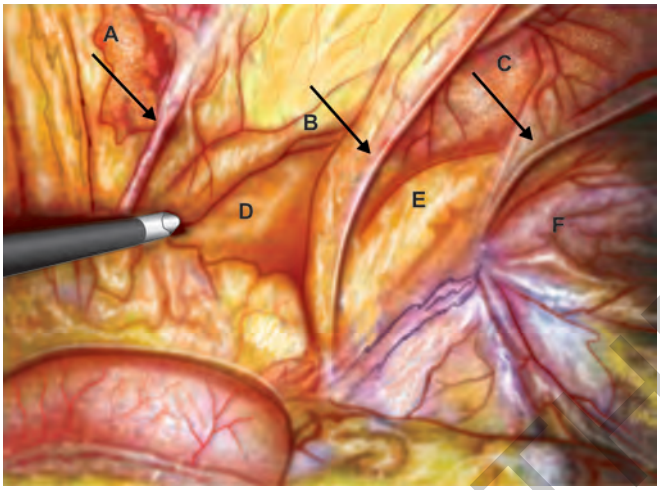

Fig. 3.4: Laparosopic view of normal pelvic anatomy on the right side (before peritoneal reflection).
Keys: A, median umbilical ligament; B, medial umbilical ligament; C, lateral umbilical ligament; D, supravesical fossa; E, medial fossa; F, lateral fossa.

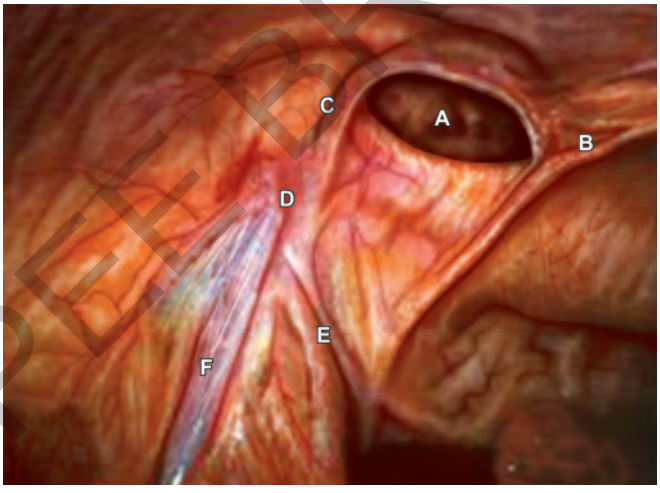

Fig. 3.5: Left direct hernia before peritoneal reflection.
Keys: A, direct defect; B, medial umbilical ligament; C, lateral umbilical ligament; D, internal ring; E, vas deference; F, spermatic vessels.

The Cooper's ligament is a thick tendinous structure running from the pubic tubercle posteriorly and parallel to the iliopubic tract. This offers the best place to fix the mesh inferomedially.

With the Maryland's forceps lifting up the peritoneum, the L-hook faces forward and a gentle diathermy burn is made to cut open the peritoneum

JAYPEE BROTHERS

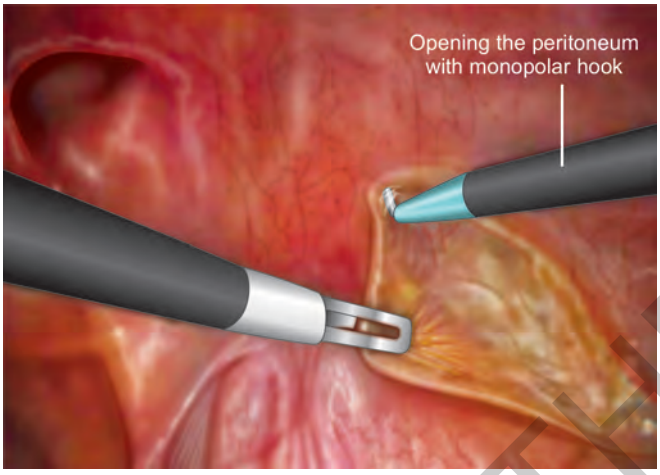

Fig. 3.6: Capno-dissection.

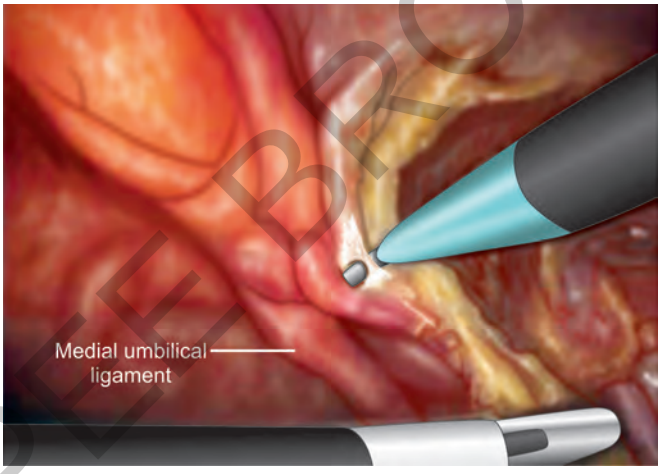

Fig. 3.7: Opening peritoneum till medial umbilical ligament.

at a point 2 cm medial and 2 cm inferior to the anterior superior iliac spine. The burn is made after the point is confirmed by external palpation (Fig. 3.6).

After the peritoneum is opened, the pneumoperitoneum is permitted to enter the subperitoneal space (capno-dissection).

The hook is inserted into the space facing medially, and the peritoneal edge is cut from lateral to medial, skirting the deep inguinal ring by at least 5 mm (in order to avoid the genital branch of the genitofemoral nerve).

The peritoneal cut is taken across and superficial to the inferior epigastric vessels (the lateral umbilical ligament), and further medially until the medial umbilical ligament is reached (Fig. 3.7).

JAYPEE BROTHERS

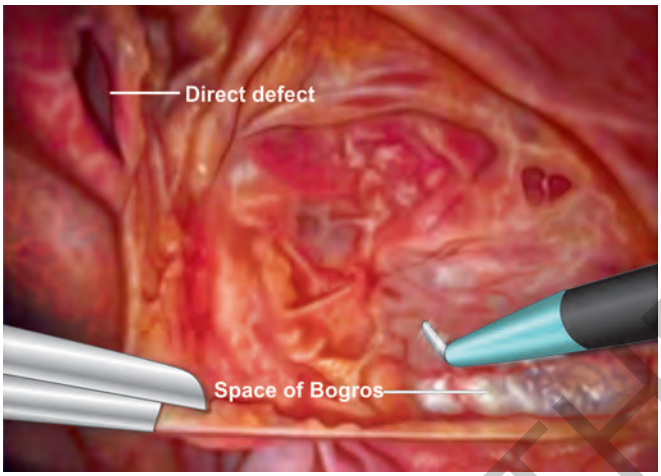

Fig. 3.8: Reflecting the peritoneum.

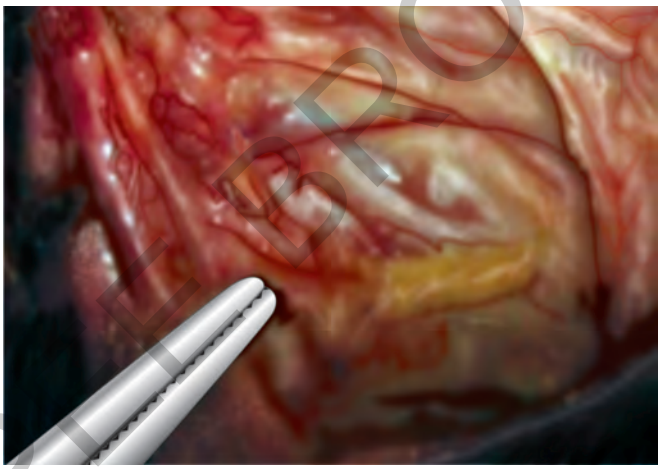

Fig. 3.9: Space of Bogros.

The lower edge of the peritoneal flap is grasped with the Maryland's forceps and the flap is raised, pushing aside the testicular vessels, which will be seen in the lateral aspect of the flap. The object of the dissection is to hold onto the peritoneum alone and to parietalize all other structures (Fig. 3.8).

In the lateral aspect of the dissection, the iliopsoas muscle with its overlying fascia is seen. The nerves run deep to the fascia and on the surface of the muscles. It is important not to dissect out the fascia and expose the nerves otherwise the mesh may get adherent to the nerves and cause chronic pain. Attention is then given to the medial aspect of the dissection

JAYPEE BROTHERS

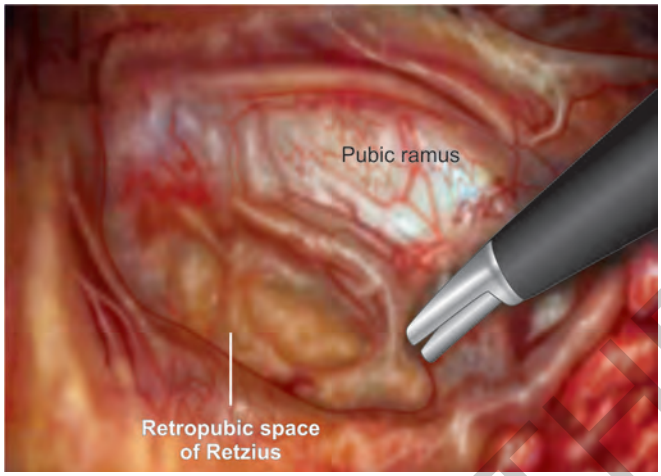

Fig. 3.10: Space of Retzius.

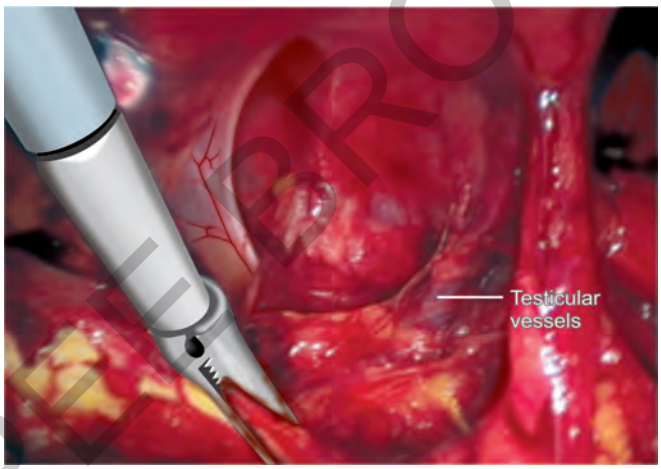

Fig. 3.11: Dissection of cord structures.

(Fig. 3.9). If the peritoneal cut extends too medially up to the median umbilical ligament, there is a danger of damage to the bladder.

The dissection is deepened under the medial umbilical ligament until the glistening white periosteum of the pubic ramus is seen (Fig. 3.10).

Now the peritoneal area between the medial and lateral dissection is extended and the direct or indirect sac will be dealt with accordingly.

Direct sac: If a direct sac is found (medial to the inferior epigastric vessels), the peritoneal cut is extended above the upper border of the sac to join the medial dissection (Figs. 3.11 and 3.12).

JAYPEE BROTHERS

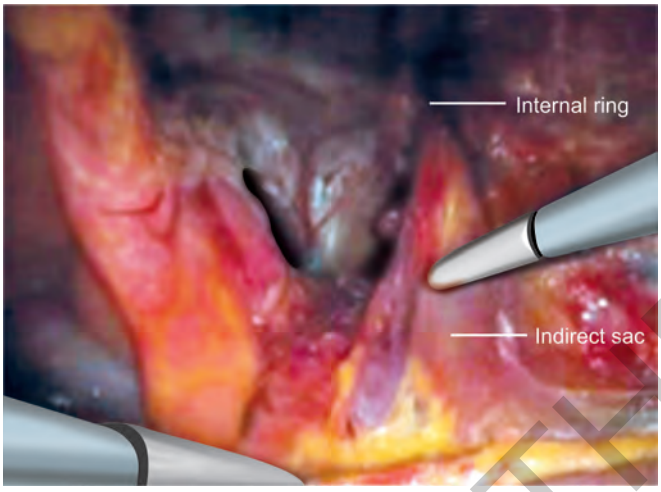

Fig. 3.12: Dissecting indirect hernia.

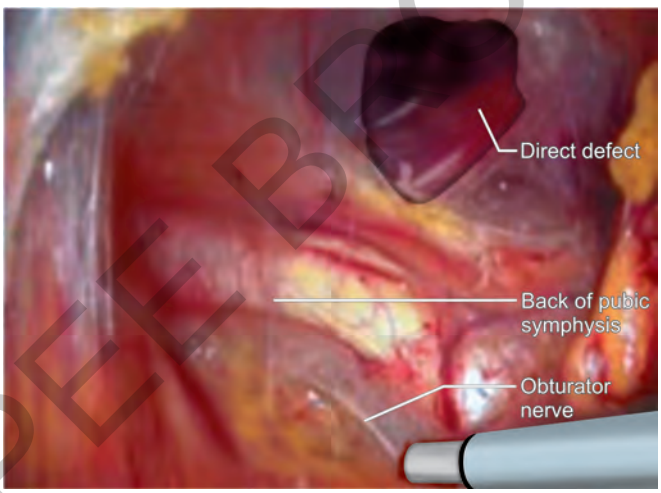

Fig. 3.13: Obturator nerve.

Then the sac edge is grasped with the Maryland's forceps and, with gentle hook dissection, the peritoneum is peeled off the defect, thus exposing the pseudo sac underneath (Fig. 3.13).

The pseudo sac is allowed to go anteriorly to the defect. Some workers tack the pseudo sac to the Cooper's ligament in order to lessen the incidence of seroma. But, we leave the pseudo sac alone.

Indirect sac: Indirect sac is seen entering the inguinal canal lateral to the inferior epigastric vessels and through the deep ring. This is dealt with in one of two ways: the cut edge of the peritoneum is held with the Maryland's

JAYPEE BROTHERS

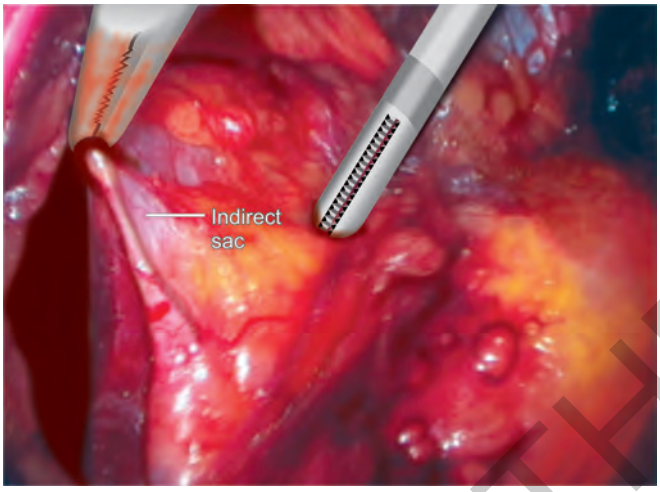

Fig. 3.14: Indirect sac.

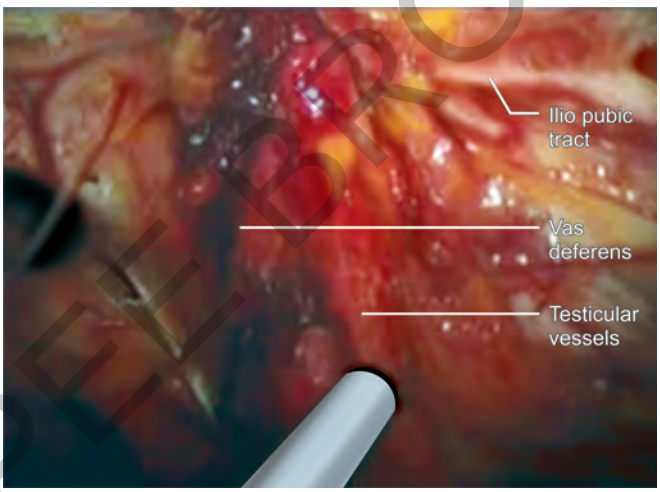

Fig. 3.15: Testicular vessels.

forceps and traction is given to deliver the sac proximally (Figs. 3.14 and 3.15). This is done after any contents are reduced.

The other technique is to extend the peritoneal cut across the sac and leave the distal portion inside the canal.

The last important step before mesh deployment is to parietalize the cord structures. This is done by peeling off the lower edge of the peritoneum from the underlying vas and testicular vessels (Fig. 3.16).

This parietalization should proceed for a distance of at least 5–6 cm from the edge of the internal ring or at least until the vas and testicular vessels are found to diverge from each other (Fig. 3.17).

JAYPEE BROTHERS

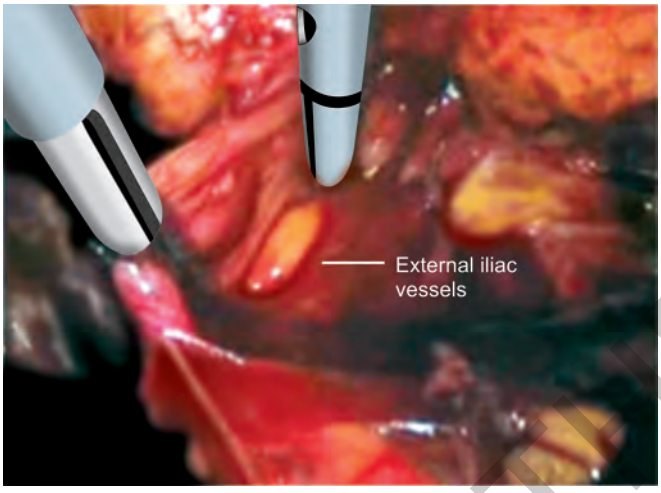

Fig. 3.16: External illiac vessels.

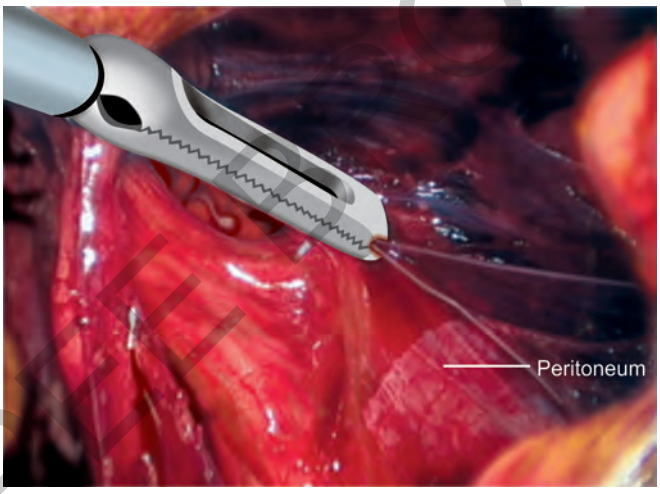

Fig. 3.17: Peritoneum reflected back.

The parietalization is complete when the entire posterior wall structures are exposed.

Now the mesh is cut to a 15 cm × 12 cm size, rolled and taken in with a new toothed grasping forceps through the 10 mm port (Fig. 3.18).

It is then held and aligned so that the lower medial portion is tucked under the medial umbilical ligament. This edge is preferably rounded off with the scissors to avoid possible prostate irritation postoperatively (Fig. 3.19).

As the lower medial edge is tucked in along the pubic ramus, the upper edge is held up to the rectus muscle and a 5 mm tacker device is deployed

JAYPEE BROTHERS

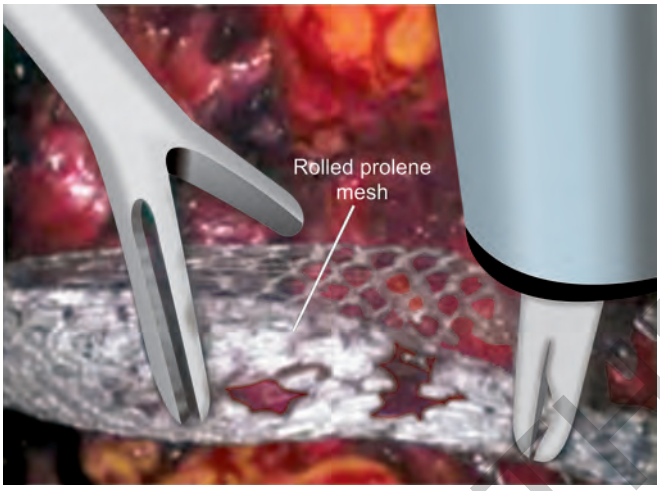

Fig. 3.18: Mesh introduction.

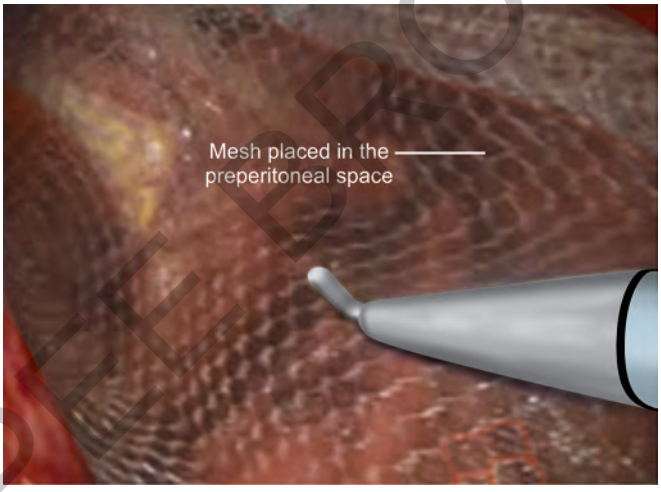

Fig. 3.19: Light weight prolene mesh placed in the preperitoneal plane.

to fix the superomedial and the inferomedial corners of the mesh with the rectus muscle and the Cooper's ligament respectively (Fig. 3.20).

The tacker is used to palpate the bone medially and is then displaced laterally until the yielding feel of the Cooper's ligament is reached. Care is taken to avoid any of the vessels of the corona mortis in this area.

The superolateral corner of the mesh is tacked against the body wall muscles laterally just below and medial to the anterior superior iliac spine.

The inferolateral corner of the mesh is not tacked, but only smoothed over the iliopsoas fascia.

JAYPEE BROTHERS

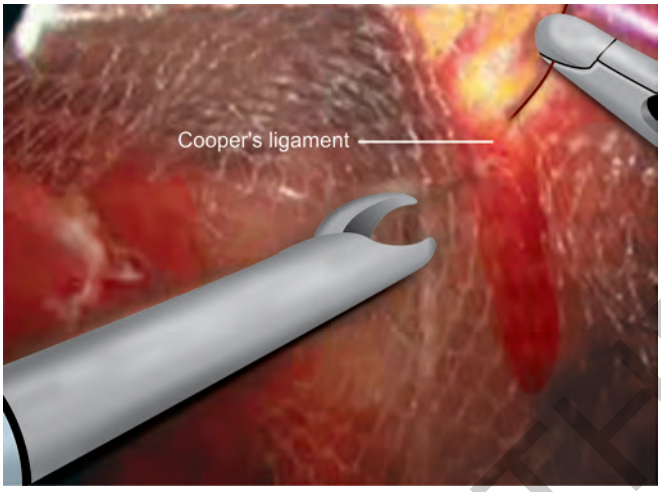

Fig. 3.20: Mesh sutured to Cooper's ligament.

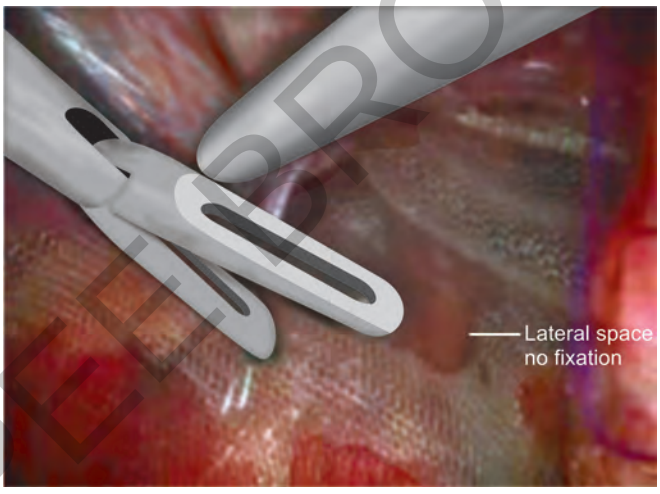

Fig. 3.21: Mesh in the lateral space.

The upper and lower edges of the mesh are tucked under the corresponding peritoneal flaps.

A 25 cm 2-0 polypropylene suture is back loaded into a 10-5 mm reducer and then inserted through the subumbilical cannula into the peritoneal cavity. Curved needle holders are inserted into the right and left working ports (Fig. 3.21).

The needle is grasped and the first suture is performed at the medial end of the peritoneal incision. The suture is completed and the peritoneal flap approximated from medial to lateral (toward the suturing instrument) by a series of running bites (Fig. 3.22).

JAYPEE BROTHERS

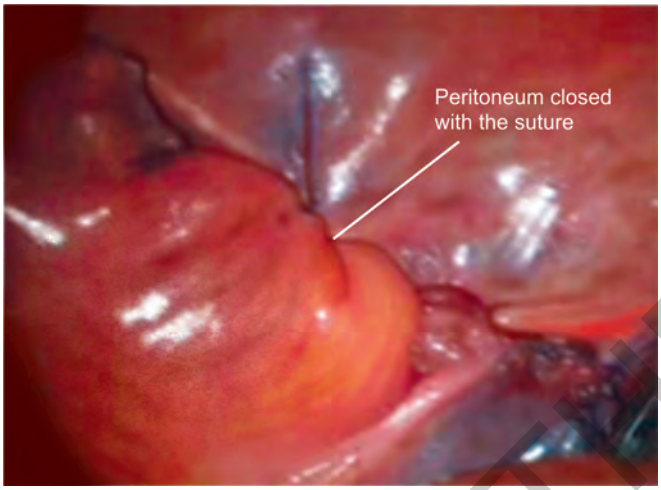

Fig. 3.22: Peritoneum closed with the suture.

As the suturing is done, the intraperitoneal pressure is dropped to facilitate peritoneal approximation (from 12 mm down to 9 mm).

One must be careful not to include the underlying mesh in the suture line as this would unroll the mesh and cause a recurrence. The suture is completed laterally and is cut with the scissors from the left hand working port.

The needle and suture are removed along with the cannula of the right hand working port.

Pneumoperitoneum is desufflated, the ports closed with 2-0 polyglactin 910 and the skin closed with 3-0 poliglecaprone.

JAYPEE BROTHERS

for detailed information on surgery books, visit our website **www.jaypeebrothers.com,** for detailed information on surgery boo

Step by Step Manual of Laparoscopic Surgery

Laparoscopic Hernia Surgery

When we planned to write a book in *Laparoscopic Hernia Surgery*, we did not want a large dry theoretical ocean of facts in a book. We wanted a purely technical handbook—a manual which will, hopefully, bridge the gap between the theory of minimal access surgery and the practice thereof for several years.

In this series of *Step by Step Manual of Laparoscopic Surgery: Laparoscopic Hernia Surgery* technical books, we have put ourselves adjacent to the practicing young surgeons who want to embark into the sea of minimal invasive surgery. Just as we would stand by them, look over their shoulder, and guide them in terms of trocar placement, or ergonomics of instrumentation, or method of dissection, we have done the same through the medium of line diagrams and pictures in this book. We have tried not to have too many operative pictures, and to have more line diagrams, so that the explanations will be very simple and structured.

We hope that this book is more useful than the previous one to the discerning readers in the academic population of India and abroad.

This little series of book is our token—a return gift, if you like, for that bountiful affection that we have felt from students and colleagues alike over the past 20 years. Our efforts would truly have attained fruition if the book is received as warmly as we have.

Salient Features

- This book helps every aspiring student of surgery to easily understand laparoscopic surgery
- Richly illustrated with line diagrams which easily demonstrate inguinal hernia and ventral hernia anatomy
- Clearly explains the fundamental principles that govern endoscopic hernia surgery
- Explains the logic of bringing down the cost of hernia surgery, making it accessible to common man
- This book will be very useful to practicing surgeons as it details economic laparoscopic hernia surgery.



JS Rajkumar MS FICS Dip NB (Surg) FRCS (Eng) FRCS (Edin) FRCS (Glasgow) FRCS (Ireland) FIMSA FAIS FRSM (London) FAGE (Gastro) FACG (USA) FICA (USA) FIAGES Dip. MIS (France) AMMC FMAS is a pioneer in laparoscopic surgery, has lectured, operated and demonstrated across the country as well as internationally. He picked up all the Royal College of Surgeons Degrees in the UK. He is the first surgeon in South India to perform the Laparoscopic Roux-en-Y Gastric Bypass.

He published his articles in various National and International journals; has coauthored a very popular textbook "Short Cases in Surgery". He received numerous awards, like Vaidya Ratna Award, Vocational Excellence Award, Dr KS Sanjivi Award, Dr V Chandrasekhar Gold Medal Endowment, Seva Ratna Award, Rotary's Lifetime Achievement Award.



Neha Shah MS FIAGES FMAS FMIS FAIS FALS is a dynamic laparoscopic surgeon, finished her graduation and postgraduation from Government Medical College, Surat, Gujarat, India. With more than 15 years of experience in Minimal Invasive Surgery, presently taking care of Department of Bariatric and Metabolic surgery with Apollo Spectra Hospitals, Chennai, Tamil Nadu, India.

She is the only female bariatric surgeon in Tamil Nadu and is the youngest surgeon to have received "Gem Awards" and "Sundaram Award" from ASI.

She is the founder and Managing Director of MISTI (Minimal Invasive Surgery Training Institute), which trains the surgeons in Laparoscopic procedures. She has trained more than 200 surgeons so far and a teaching faculty at the Ethicon Institute of Surgical Education.

She has published and presented several papers in medical journals/conferences and have organized various National level workshops.

Available at all medical bookstores
or buy online at www.jaypeebrothers.com

JAYPEE BROTHERS
Medical Publishers (P) Ltd.
www.jaypeebrothers.com

Join us on facebook.com/JaypeeMedicalPublishers

Shelving Recommendation
SURGERY

ISBN 978-93-5152-892-0

9 789351 528920