t our website www.jaypeebrothers.com, for detailed information on otolaryngology books, visit our website www.jaypeebrothers.com

INCLUDES INTERACTIVE DVD-ROM

ROBOTIC SURGERY IN OTOLARYNGOLOGY

HEAD & NECK SURGERY

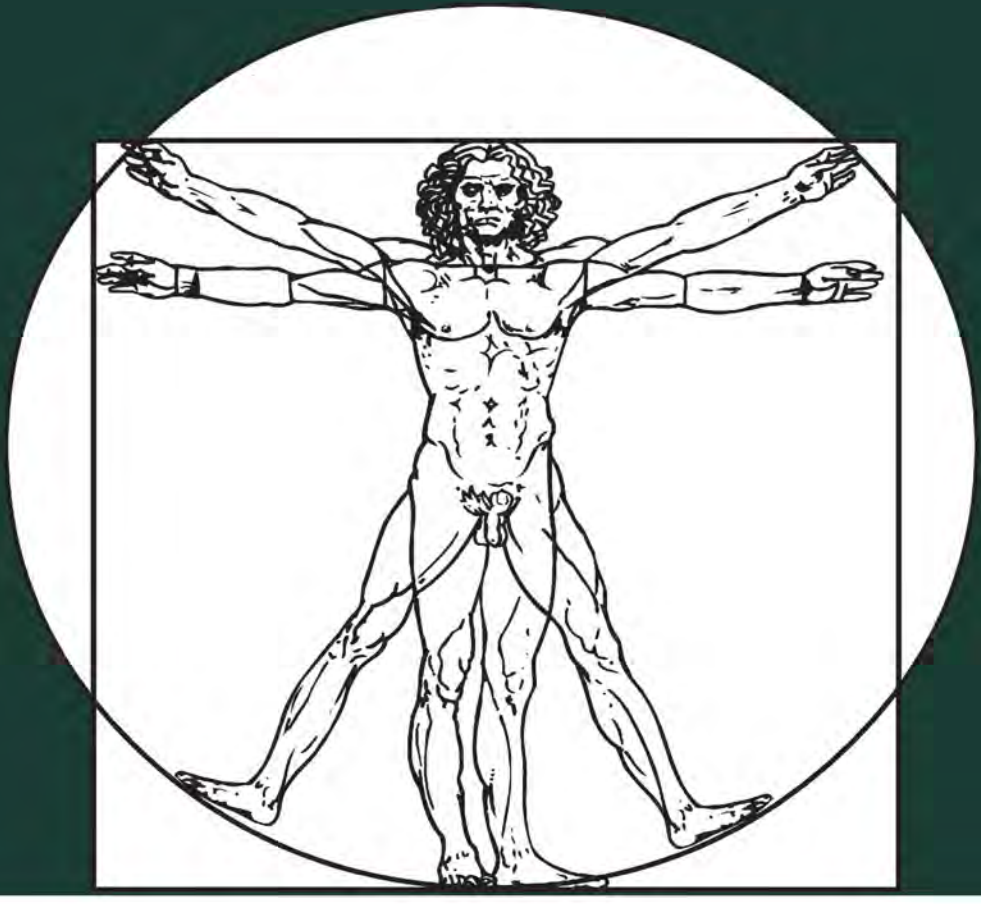

Editor
NILESH R VASAN

Foreword
Jesus E Medina

JAYPEE

Contents

Section 1: Transoral Robotic Surgery (TORS)

1. Transoral Robotic Surgery for Tonsil Cancer **3**
Julia A Crawford, Hilliary N White, J Scott Magnuson
- Rationale for Procedure *3*
- Applied Anatomy–Radical Tonsillectomy *4*
- Indications and Contraindications *4*
- Preoperative Assessment *5*
- Instrumentation *5*
- Operative Setup *6*
- Operative Technique *6*
- Early Postoperative Considerations *7*
- Management of the Neck *8*
- Management of Complications *8*
- Follow-up *8*
- Results *8*
- Future Directions *9*

2. Transoral Robotic Surgery for Base of Tongue Tumors **12**
Umamaheswar Duvvuri, Vikas Mehta
- History *13*
- Physical Examination *13*
- Postoperative Care *17*
- Complications *17*
- Results *18*

3. Transoral Robotic Surgery—Hypopharynx **20**
Eric M Genden, Eitan Prisman
- Results *26*
- Future Directions *27*

4. Transoral Robotic Supraglottic Laryngectomy (TORS-SGL) **29**
Peter T Dziegielewski, Enver Ozer
- Rationale for Procedure *29*
- Applied Anatomy *29*
- Patient Selection *30*
- Preoperative Workup *31*
- Instrumentation *32*
- Operative Setup *32*
- Operative Technique: TORS-SGL *33*
- Postoperative Care *36*
- Complications and their Management *36*
- Expected Outcomes *38*
- Choosing an SGL Approach *38*
- Future Directions *38*

5. Transoral Robotic Surgery for Obstructive Sleep Apnea 40
Chelsey J Smith, Nilesh R Vasan
- Rationale for Procedure *40*
- Applied Anatomy *40*
- Indications and Contraindications *41*
- Preoperative Workup *43*
- Instrumentation *44*
- Operative Setup *44*
- Operative Technique *46*
- Complications and their Management *47*
- Follow-up *49*
- Results *49*
- Future Directions *50*

Section 2: Thyroid

6. Transaxillary Robotic Thyroidectomy 53
Jandee Lee, Woong Youn Chung
- Rationale for Procedure *53*
- Applied Anatomy for Robotic Thyroid Surgery *54*
- Indications and Contraindications for Robotic Thyroidectomy with or without Radical Neck Dissection *54*
- Instrumentation *55*
- Operative Setup with Robot *55*
- Operative Technique *60*
- Present Status of Robotic Thyroid Surgery *62*
- Questions and Solutions *64*
- Future Directions *65*

7. Robotic Thyroidectomy for American (Western) Patients 67
Salah E Mohamed, Emad Kandil
- Robotic Thyroidectomy *68*
- Indication and Patient Selection *70*
- Complications *72*

8. Robotic Thyroidectomy—Facelift Approach 75
William S Duke, David J Terris
- Rationale for Procedure *75*
- Applied Anatomy (for Robotic Surgery) *75*
- Indications and Contraindications *76*
- Preoperative Workup *76*
- Instrumentation *76*
- Operative Setup with Robot *77*
- Operative Technique *77*
- Complications and their Management *81*
- Follow-up *81*
- Results *82*
- Future Directions *82*

Section 3: Head and Neck Reconstruction

9. Transoral Robotic Surgery in Head and Neck Reconstruction 87
Anya Joyce Miller, Tamer Abdel-Halim Ghanem
- Rationale for Procedure 87
- Applied Anatomy *87*
- Indications *87*
- Contraindications *88*
- Preoperative Workup *88*
- Instrumentation *89*
- Operative Setup with Robot *89*
- Operative Technique *90*
- Complications and their Management *92*
- Follow-up *92*
- Results *92*
- Future Directions *92*

Section 4: Robotic Procedures in Evolution

10. Robot-Assisted Neck Dissection via a Modified Facelift or Retroauricular Approach 97
Yoon Woo Koh, Eun Chang Choi
- Rationale for Procedure *97*
- Applied Anatomy *97*
- Indications *98*
- Contraindications *98*
- Preoperative Workup *98*
- Instrumentations *99*
- Operative Techniques *100*
- Complications and their Management *106*
- Follow-up *109*
- Results *109*
- Future Directions *109*

11. Robotic-Assisted Skull Base Surgery 111
Michael E Kupferman, Ehab Hanna
- Techniques *111*
- Skull Base Reconstruction *114*
- Optical Limitations *116*
- Ergonomic Limitations *116*
- Dissection Limitations *116*
- Reconstructive Limitations *116*

12. Robotic-Assisted Surgery for Nasopharyngeal Tumors 119
Raymond K Tsang, William I Wei
- Rationale for Procedure *119*
- Applied Anatomy *120*
- Indications and Contraindications *120*
- Preoperative Workup *121*
- Instrumentation *121*

- Operative Setup and Operative Technique *122*
- Postoperative Care *125*
- Complications *125*
- Follow-up *126*
- Results *126*
- Future Directions *127*

13. Robot-Assisted Otologic and Neurotologic Surgery **128**

Betty S Tsai Do

- Rationale for the use of Robotics in Surgery of the Temporal Bone *128*
- Potential Applications in Otologic and Neurotologic Surgery *128*
- Indications and Contraindications *132*
- Preoperative Workup *132*
- Complications *133*

Index *137*

Chapter 3 Transoral Robotic Surgery—Hypopharynx

Eric M Genden, Eitan Prisman

INTRODUCTION

Background

Hypopharyngeal squamous cell carcinoma (SCC) is a relatively rare but aggressive malignancy associated with a poor prognosis. It accounts for 3–5% all of head and neck SCC and often presents at an advanced stage.[1] The pyriform sinus is the most common subsite involved, accounting for >85% of hypopharynx SCC.[2] Most patients are of male gender, over the age of 65 with 90% of patients presenting with a significant smoking history and 50% with associated alcohol misuse.[3,4] Not surprisingly, the rate of synchronous lesions in this subset of patients approaches 8%.[3] Due to a lack of significant symptoms in early stage disease, over 50% of patients present with advanced (stage IV) disease.[4] The rich lymphatic drainage accompanying the hypopharynx contributes to a rate of ipsilateral nodal disease in the range of 60–80%,[5] and up to 40% presenting with contralateral disease.[6] In an apparent clinically negative neck, the rate of occult ipsilateral and contralateral neck disease can be as high as 36% and 27%, respectively.[4,6] Hypopharyngeal SCC is associated with a particularly poor prognosis. Of nearly 3,000 hypopharyngeal SCC diagnosed from 1980 to 1985 and from 1990 to 1992, the 5-year disease-specific survival was 63.1%, 57.5%, 41.8% and 22% for stages I–IV, respectively.[3] Despite advances in surgical therapies, chemotherapeutic options and radiation technology, the overall prognosis in hypopharynx SSC has not significantly improved.[7]

The paradigms in treatment of hypopharynx SCC have changed several times over the past few decades. In the 1960s, laryngopharyngectomy replaced radiation therapy as the primary modality of therapy for hypopharynx SCC of the 1940s and 1950s. Primary surgery or radiation remained the primary modality in the treatment of hypopharynx SCC until the introduction of platinum-based chemotherapeutics in the 1980s and its application to the treatment of laryngeal SCC.[8,9]

Due to the trends in organ preservation, applied from the experience gained in laryngeal carcinoma, concurrent chemoradiotherapy has gained significant momentum as the primary modality of treatment for hypopharynx carcinoma. However, unlike in laryngeal carcinoma, there is a scarcity of evidence to support this treatment modality in the hypopharynx. The only randomized control trial of hypopharynx carcinoma that included a surgical arm was performed in 1996. Induction chemotherapy followed by radiation therapy (in responders) was compared with surgery followed by postoperative radiation therapy. This study found no significant difference in survival or recurrence, with a larger percentage of patients in the induction arm retaining a functioning larynx.[10] However, all patients in the surgical arm had total laryngectomy with partial pharyngectomy and not partial laryngopharyngectomies or the minimally invasive procedure that are available today. Furthermore, combined chemotherapy and radiation therapy increase toxicity to the aerodigestive tract and are associated with a likely underreported rate of detrimental effects on swallowing function.[11] The treatment options are further complicated when reviewing the results of concurrent chemotherapy versus induction chemotherapy.[9,12,13] The North American laryngeal literature suggests that as concurrent chemotherapy became the more common treatment for larynx carcinoma, the associated overall survival had decreased.[14,15] However, this suggestion is controversial as contrary results were found in similar European trials.[16]

While there have been significant technical improvements in partial laryngopharyngectomies including combined suprahyoid and lateral pharyngectomy, as well as advances in reconstructive techniques, laryngopharyngectomy with reconstruction remains associated with a significant functional impairment. Nevertheless, in advanced disease, including infiltrating tumors and those associated with significant cartilage involvement, initial radical surgery followed by adjuvant therapy, as opposed to concurrent chemoradiotherapy, is often advocated.[8,17,18] However, the optimal management remains controversial.

JAYPEE BROTHERS

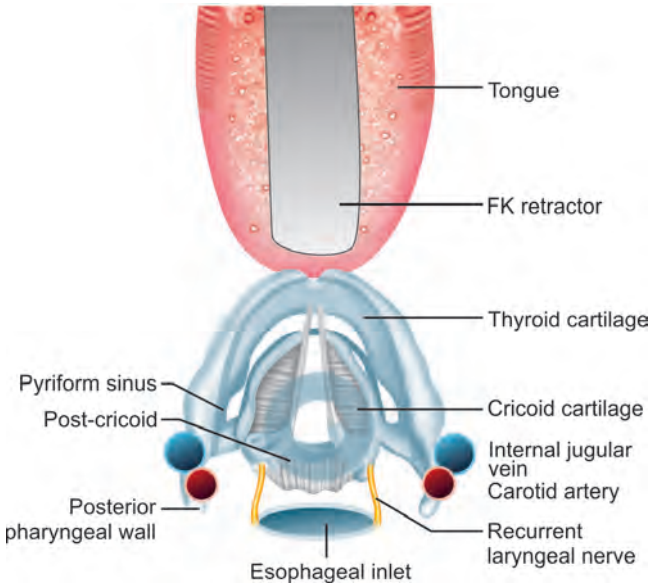

Fig. 3.1: Schematic diagram of the endoscopic hypopharyngeal anatomy from the surgeons perspective after assembling the FK retractor.

Rationale for Procedure

Over the past four decades, the surgical arena has witnessed significant advancements in the field of minimally invasive surgery. In the 1970s, transoral endoscopic laser microsurgery (TLM) was developed and soon thereafter was applied to the treatment of hypopharynx SCC.[19] In addition, the more recent development of transoral robotic surgery (TORS) presents an additional technique that has provided equivalent locoregional control without the collateral functional impairment of traditional surgery.[9,20] This is particularly true for early stage and a select group of advanced stage, hypopharynx SCC and is the focus of this chapter.

Transoral laser surgery was applied to the hypopharynx with equivalent oncological outcomes to both open surgery and organ preservation concurrent chemoradiation therapy protocols with a low rate of postoperative morbidity.[21,22] The relative advantage of TLM is the ability to gain exposure to the hypopharynx, without the need to disrupt the laryngeal framework and the inherent functional impairment associated with those traditional open approaches. Furthermore, resurfacing of the wound can take place by secondary intention, negating a bulky reconstruction.[21,23,24] However, TLM resection may be limited by the line of sight of the microscope.[25] The inherent advantages of robotic-assisted surgery, in terms of improved tissue manipulation and visualization as well as relative degrees of freedom, have provided a potentially superior technique in the treatment of hypopharynx SCC.

Applied Anatomy

The hypopharynx comprises the inferior segment of pharynx that is bounded above by the plane of the superior border of the hyoid and extends inferiorly to the plane corresponding to the lower border of the cricoid. It includes three subsites: the left and right pyriform sinuses, the posterior and lateral pharyngeal wall and the postcricoid region. The postcricoid region joins superiorly with the left and right pyriform sinuses and posteriorly with the posterior pharyngeal wall to form a circumferential segment of pharynx whose inferior border defines the esophageal inlet (Fig. 3.1).

Indications and Contraindications

Tumor Characteristics

We consider T1–T3 pyriform sinus and posterior pharyngeal wall lesions as potential candidates for TORS, provided there is at least one intact arytenoid with normal vocal cord mobility. However, we exclude lesions with significant posterior cricoid involvement or those that involve the apex of the pyriform sinus or with vocal cord fixation. Furthermore, we exclude advanced T4 stage disease and in particular those that have thyroid cartilage or prevertebral fascia involvement and those with unresectable nodal disease or carotid artery invasion.

Patient Characteristics

Particular attention to the common variables routinely applied in the anesthesiology literature to identify patients who are potentially difficult intubation is important. These variables include an interincisal distance < 4 cm, neck circumference > 40 cm, hyomental and sternomental distance < 6.05 and 13.9 cm, respectively as well as Mallampati score.[29] Furthermore, the size of the tongue and tongue base should be assessed and have been shown to predict those patients with difficult access during TORS of hypopharynx SCC.[28] This assessment will aid in identifying suitable patients for TORS. We exclude patients who have medical contraindications to general anesthesia, those who have poor pulmonary reserve as determined based on preoperative pulmonary function test and those

JAYPEE BROTHERS

with preoperative radiation to the larynx/hypopharynx. It is critical to select out patients with adequate access. Those patients who on diagnostic panendoscopy have only a "fair view," as defined above, or those with advanced C-spine pathology are excluded.

Table 3.1: Inclusion and exclusion criteria for TORS

- Inclusion
  - T1–T3 pyriform sinus or posterior pharyngeal wall
  - At least one intact arytenoid with normal vocal cord mobility
- Exclusion
  - Involvement of posterior cricoid apex of the pyriform sinus
  - T4 stage disease
  - Involvement of thyroid cartilage or prevertebral fascia
  - Unresectable nodal disease or carotid artery invasion
  - Medical contraindication to general anesthesia
  - Poor pulmonary reserve
  - Preoperative radiation to larynx/hypopharynx
  - Inadequate exposure

Preoperative Workup

Investigations

Pulmonary function tests serve as an objective value of pulmonary function when a thorough history and physical examination suggests a compromised pulmonary function, and help predict patients who are at higher risk from surgical intervention.

Radiology

High-resolution computed tomography (CT) is useful to determine extent of disease including paraglottic extension and cartilage involvement.[30] Positron emission tomography CT (PET-CT) is becoming increasingly useful to rule out metastatic disease and to help in identifying potential suspicious lymph node metastases.[30] In the setting where PET-CT is not available, the lung should be imaged at least with a chest X-ray. While breathing and swallowing confound magnetic resonance imaging (MRI), it does provide superior soft tissue delineation in terms of extent of submucosal spread and prevertebral fascia involvement. When there is suspicion of submucosal spread, which can be common in hypopharyngeal carcinoma,[31] a dedicated MRI should be considered. Traditionally, barium swallow was used to image these lesions;[32] however, we do not routinely order this investigation.

Panendoscopy

In addition to obtaining tissue diagnosis, a preoperative panendoscopy provides an opportunity to determine eligibility for TORS and is highly recommended.[28] The larynx and hypopharynx are carefully examined to determine arytenoid mobility and to characterize the tumor in terms of size, subsite involvement and lateral extension. Equally important is to determine whether adequate exposure can be obtained. To this end, the pharyngolaryngoscope Feyh-Kastenbauer (FK) Retractor (Gyrus Medical Inc., Maple Grove, MN) is assembled. Exposure can be assessed based on a recent description by De Virgilio et al.[28] In particular, "good exposure" is defined as full vision of the supraglottis and an unfolded pyriform sinus; "Fair vision" as full vision of the supraglottis and a folded pyriform; while "poor vision" is defined as a limited view of the supraglottis and folded pyriform sinuses. While the 30° endoscope usually provides the most optimal view, in a select group of patients with an interincisal distance of < 4 mm, it is difficult to obtain the necessary angle to view the lesion with a 30° endoscope. In these cases, a 0° telescope may be applied with laryngeal compression as discussed below.

Instrumentation

The instrumentation can be divided into three parts based on the three steps of the procedure, namely exposure, ablation and reconstruction.

Exposure

- Pharyngolaryngoscope FK retractor (Gyrus Medical Inc., Maple Grove, MN)
- 2-0 tapered silk suture
- da Vinci Si surgical robotic system (Intuitive Surgical Inc., Sunnyvale, CA)
- 8-mm 30° and 0° da Vinci Endoscope (Intuitive Surgical Inc., Sunnyvale, CA).

Ablation

- 5-mm EndoWrist monopolar spatula cautery (Intuitive Surgical Inc., Sunnyvale, CA)
- 5-mm EndoWrist Maryland forceps (Intuitive Surgical Inc., Sunnyvale, CA)
- Hand-held Yankauer suction.

Reconstruction

- Two 5-mm EndoWrist Needle Drivers (Intuitive Surgical Inc., Sunnyvale, CA)
- 4-0 Vicryl (Ethicon, Inc., Somerville, NJ).

JAYPEE BROTHERS

Operative Setup with Robot

Anesthesia and Intubation

Nontraumatic nasotracheal intubation is essential to maintain the anatomic delineation of the primary malignancy and prevent unwarranted edema. At our institution, we advocate awake fiberoptic nasotracheal intubation after application of topical anesthetic. General anesthesia is then induced and an appropriate dose of induction dexamethasone is administered to limit laryngeal edema and, secondarily, postoperative nausea. An appropriate dose of muscle relaxant is essential to optimize access.

Tracheotomy

Tracheotomy at the first or second intercartilaginous space is performed through a 2-cm incision in a standard fashion. This is usually performed prophylactically prior to the TORS resection in order to optimize visualization. A decision of whether or not to decannulate is made at the end of the ablative portion based on the extent of ablation, the degree of edema as well as the patient characteristics.

Setup

The operating room and da Vinci robot are set up in the usual fashion, with the foot of the da Vinci robot at 30° to the surgical bed, in order to optimize access of the endoscope and the two arms into the surgical field. A 30° endoscope is calibrated and balanced. While there is evidence that compared to monopolar cautery, the CO_2 laser causes less thermal damage and associated edema to adjacent structures, we have applied both techniques with equivalent results.[27] A foam doughnut is placed under the patient's head without a shoulder roll (Fig. 3.2).

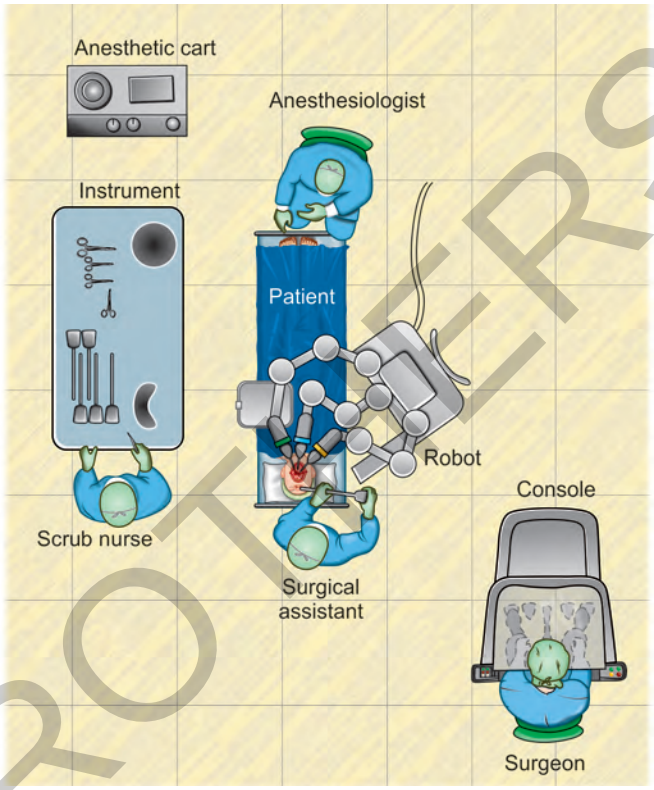

Fig. 3.2: A schematic overhead diagram of the operating room setup. Note the Robot is docked at 30° to the patient bed.

Operative Technique

Optimizing Access

A 2-0 silk suture is placed in the anterior tongue, and anterior traction is applied while an appropriate blade is inserted in the FK retractor. Both the laryngeal and tongue blades should be inserted into the FK retractor to determine which one provides the most optimal exposure. In our experience, similar to that reported in the literature, the tongue blade is most useful in accessing the pyriform sinuses.[28] While some have advocated the FK-WO retractor to allow a wider lateral working space, we have successfully used the standard FK retractor.[25] It is essential that sufficient anterior traction be applied to the 2-0 silk suture in order to pull the base of tongue anteriorly, thereby extending the epiglottis and optimizing the view of the supraglottis and hypopharynx. The 12-mm sized 30° endoscope is inserted face up, followed by a 5-mm spatula monopolar cautery ipsilateral to the tumor and a 5-mm Maryland forceps to the contralateral side. In those patients with a limited view anteriorly, manual posterior compression of the larynx can be applied to improve visualization. In select patients with an enlarged or flaccid epiglottis obstructing the surgical view, a partial ipsilateral epiglottectomy has been successfully applied to aid in visualization. This is particularly useful to access the pyriform sinus and has been applied in half of pyriform sinus SCC treated with TORS[28] (Fig. 3.3).

Pyriform Sinus

The goal of surgical excision is to remove the tumor with a clear margin with minimal morbidity in terms of airway and deglutition. Transoral robotic surgery excision of a

JAYPEE BROTHERS

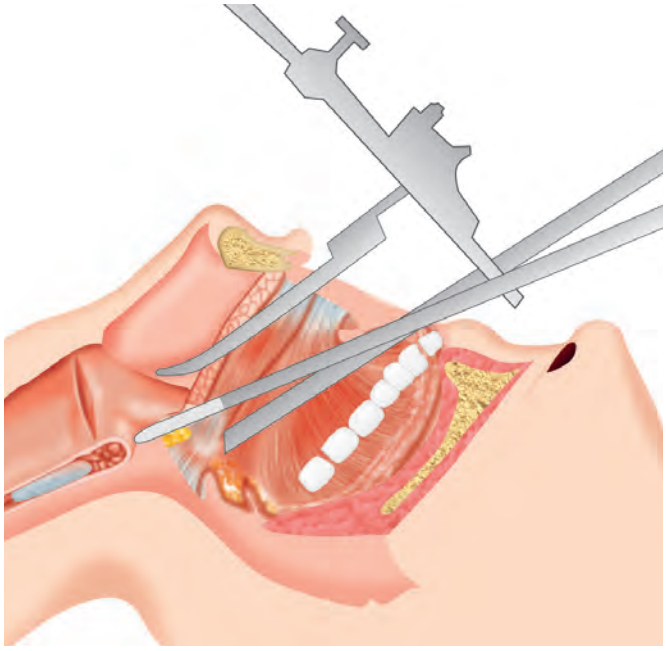

Fig. 3.3: Schematic representation of FK retractor with endoscope.

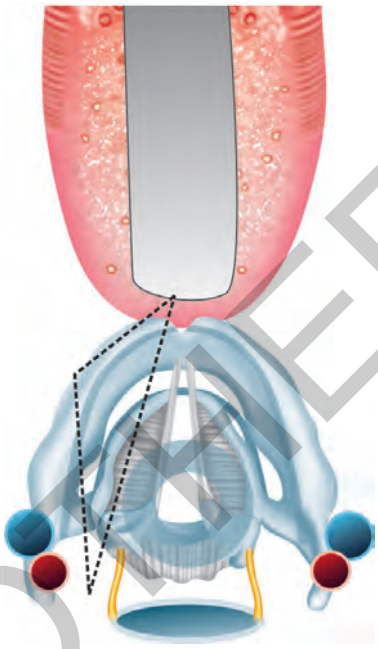

Fig. 3.4: Schematic representation of a cone resection of the left pyriform sinus as outlined but the dotted line.

pyriform sinus tumor is achieved by performing a cone-shaped resection of the pyriform, bounded superiorly at the vallecula and extending down to the apex of the cone just below the apex of the pyriform. This cone-shaped excision includes the aryepiglottic fold medially and the perichondrium of the thyroid cartilage laterally. The dissection is begun medially at the anterior aryepiglottic fold and proceeds in a posterior direction. Care is taken to preserve the integrity of the arytenoid and its vocal and muscular processes in order not to compromise laryngeal function. The dissection is then advanced laterally along the aryepiglottic fold towards the thyroid cartilage. An incision is made laterally through the perichondrium and onto the thyroid cartilage. The perichondrium is then carefully peeled inferiorly, while the cartilage remains intact. The dissection then proceeds posteriorly to posterior pharyngeal wall, where the posterior margin includes the inferior constrictor (📹 3.1). Careful dissection in the posterolateral segment is essential to prevent inadvertent injury to the great vessels. The specimen is then pedicled on the apex of the pyriform sinus and can be removed en bloc (Figs. 3.4 and 3.5). When a large ablative defect remains in the hypopharynx, especially in the setting of prior chemoradiation therapy, primary closure of the pyriform can be accomplished with interrupted 3-0 Vicryl (Figs. 3.6A to I).

Posterior Pharyngeal Wall

Dissection of a posterior pharyngeal wall lesion is less complicated and has a similar setup as for a pyriform sinus lesion. The 30° face up telescope is used. The advantage of the robotic system is particularly appreciated during the dissection of the inferior portion of the lesion where, as opposed to the TLM, the dissection plane remains in view. The lesion is circumferentially resected with a 5 mm clear margin. The dissection is initiated superiorly, where an incision is made through the mucosa and down to the prevertebral fascia. The appropriate plane of dissection is just anterior to the prevertebral fascia. The inferior dissection is then carried out and the lesion is then approached in a circumferential pattern (Figs. 3.7A to G). These defects can be left to granulate secondarily with early initiation of oral deglutition.

Neck

The reported incidence of occult nodal metastasis is > 20% and therefore ipsilateral selective neck dissection including levels II–IV is commonly indicated.[4]

Bilateral selective neck dissection should be performed for midline tumors of the posterior pharyngeal wall or postcricoid area, as well as tumors involving the medial wall of the pyriform sinus and those that cross the midline. We also consider contralateral neck dissection in

JAYPEE BROTHERS

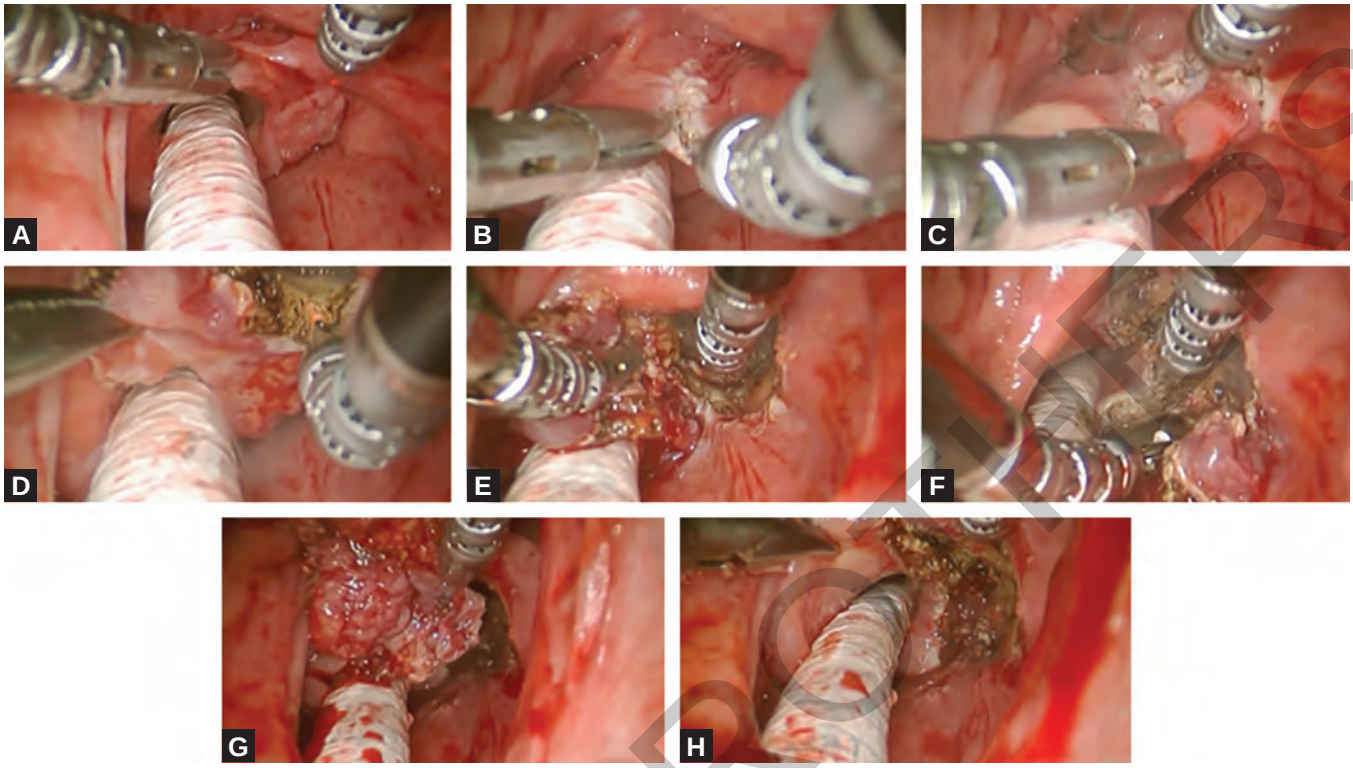

Figs. 3.5A to H: Sequential resection of a right pyriform sinus squamous cell carcinoma (A), with dissection begun medially along epiglottis (B) and continued anteriolaterally to the inner thyroid perichondrium (C to E). The specimen is then pedicled medially and removed (F) and orientation and margins are confirmed (G) and the remaining ablative defect is left to heal by secondary intention (H).

those patients with palpable ipsilateral disease or those patients presenting with advanced disease.[8] We perform all neck dissection concurrent with the TORS ablation. In advanced disease we occasionally include a level VI dissection when indicated.[33]

Complications and their Management

Careful selection of patients is integral to successful oncological and functional outcomes. The preoperative history and physical examination is essential to select out these patients. When possible, assembling the FK retractor during a diagnostic panendoscopy is useful to identify patients with adequate exposure. Maneuvers to improve exposure include anterior tongue traction, posterior laryngeal pressure and partial epiglottectomy. During surgical excision care should be taken in the posterior lateral compartment to prevent injury to the great vessels. Careful attention to tumor margins is essential, especially at the anterior lateral compartment of the pyriform, which is a particularly difficult area to obtain a clear margin. A low threshold for keeping a tracheostomy in place is important especially as one gains experience treating this disease entity. Most patients will remain with tracheostomy and nasogastric feeding tube during their postoperative recovery. It is essential to properly consent patients for this recovery period. In the case series reported to date the average time to decannulation and return to deglutition are approximately 6 and 8 days, respectively.[7] Adherence to careful patient selection and optimizing surgical access allow these results to be realistically achieved.

Follow-up

Postoperatively, patients are assessed by a formal swallow assessment prior to initiation of an oral diet. Those patients requiring a tracheostomy intraoperatively are managed postoperatively in the usual fashion with downsizing to a noncuffed tracheostomy tube on postoperative day 3 and decannulation following a successful 24-hour trial of capping. Patients are revaluated in a multidisciplinary setting at 1 week post-discharge by both the primary surgeon and a speech language pathologist. Subsequent follow-ups correspond with the National Comprehensive Cancer Network guidelines.

JAYPEE BROTHERS

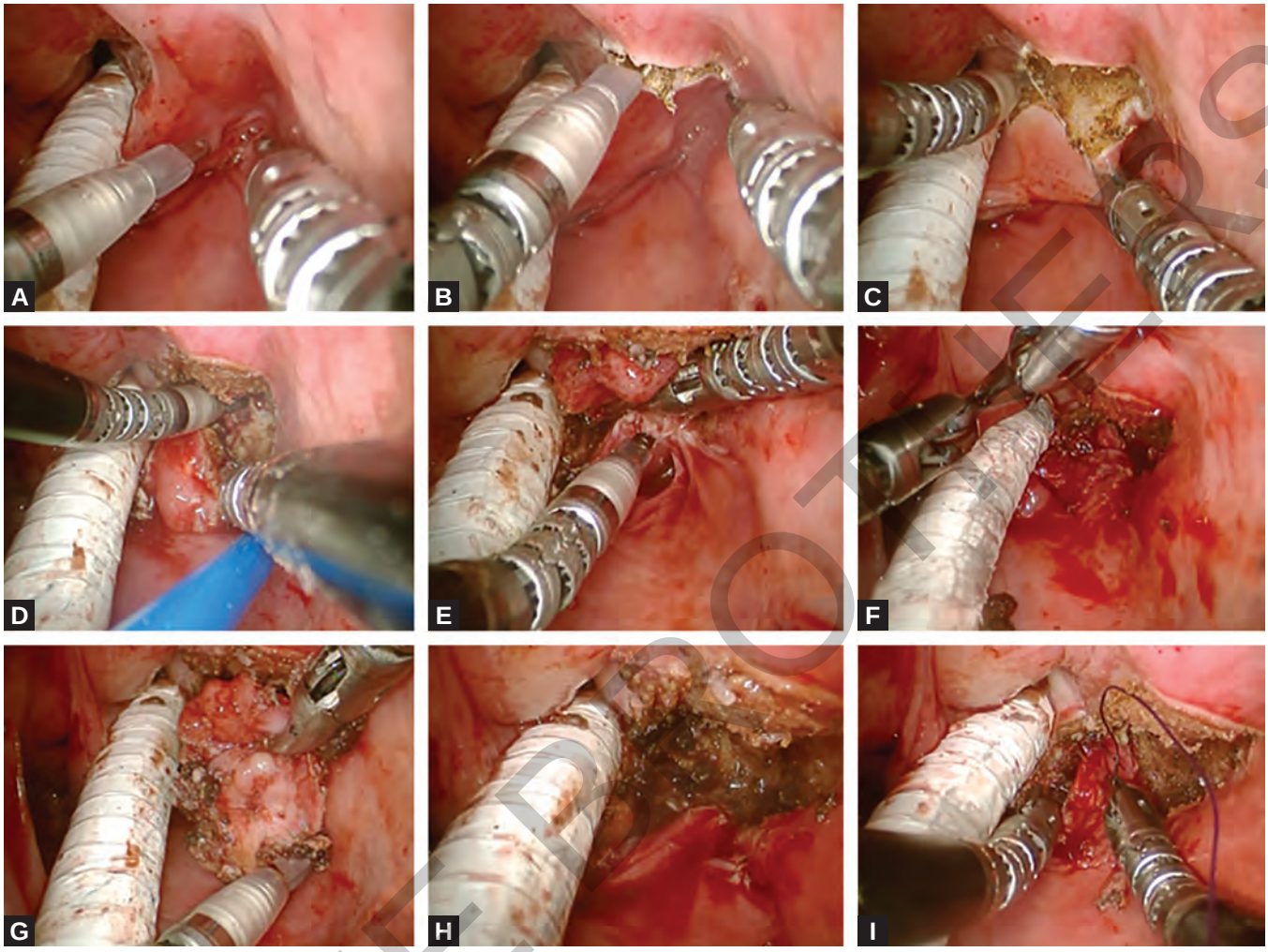

Figs. 3.6A to I: Sequential resection of a recurrent right pyriform sinus squamous cell carcinoma postchemoradiation therapy. The ablative defect is closed primarily using interrupted 3-0 Vicryl, to maintain a sensate mucosa and prevent aspiration.

RESULTS

Several early case series have reported on the successful application of TORS to the treatment of upper aerodigestive tract malignancies in terms of completeness of resection and postoperative morbidity.[26,27] Certainly, the greatest challenge in the application of TORS to treatment of the larynx and hypopharynx is access, with up to 25% of carefully selected patients having difficult exposure.[28] However, this can be overcome with maneuvers discussed below. Focusing on the hypopharynx, a prospective case series included 10 T1 or T2 pyriform sinus or posterior pharyngeal wall SCC treated successfully with TORS hypopharyngectomy were reported. All patients had clear margins without significant perioperative complications. Patients received prophylactic intraoperative tracheotomy with an average time to decannulation of 6.3 days, and a return of swallowing function within 8.3 days after surgery. These results suggested that TORS hypopharyngectomy was a feasible option with favorable morbidity.[7] In a larger prospective study of 23 patients with hypopharynx SCC, designed to determine oncological outcomes, the 3-year overall survival and disease-free survival of 89% and 84%, respectively, compared favorably to both open surgical techniques and concurrent chemotherapy. Functional outcomes of voice and swallow were objectively assessed with favorable results.[25] While these series are limited by a selection bias, they nonetheless suggest that TORS is a feasible and oncological valid option in a carefully selected group of patients.

JAYPEE PROOFS

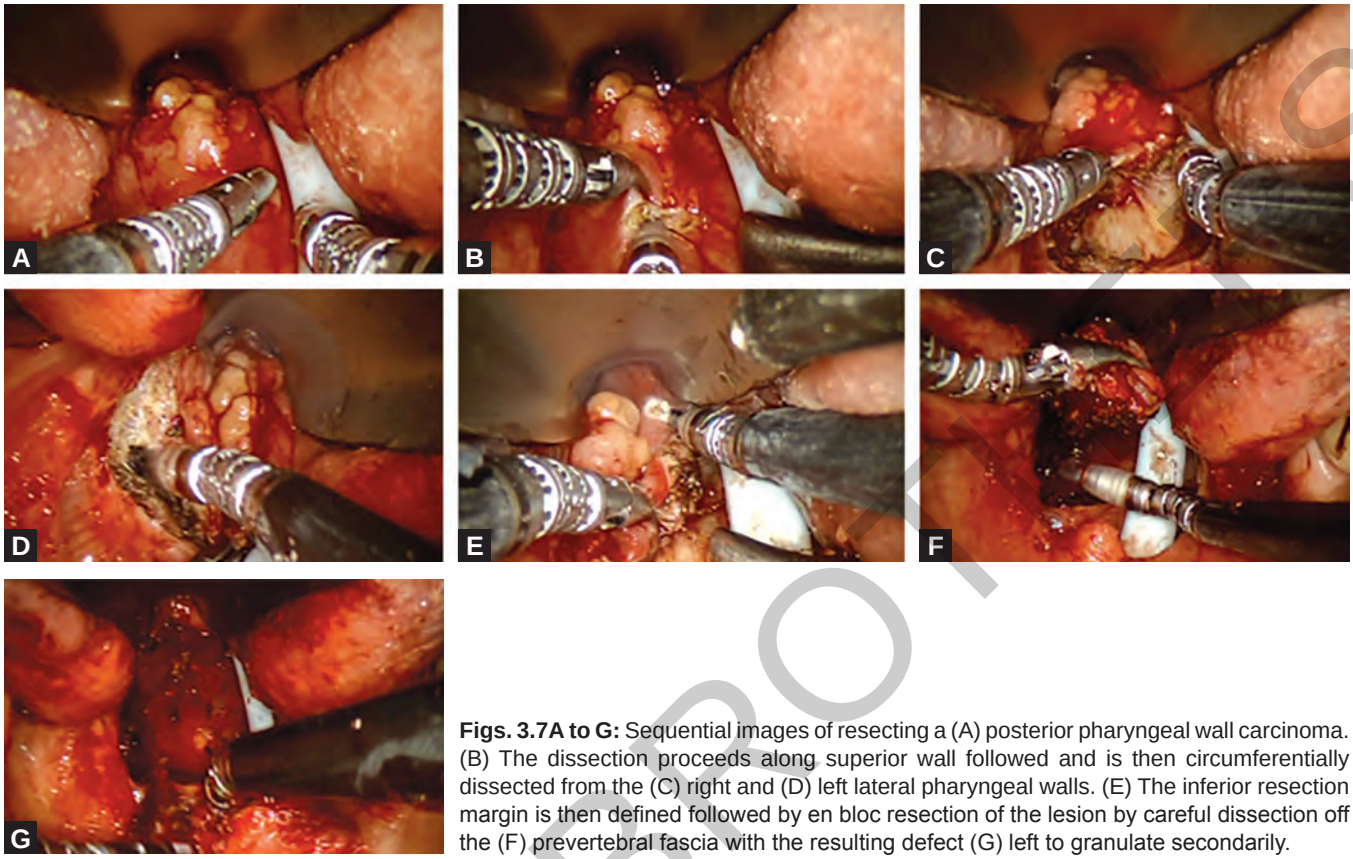

Figs. 3.7A to G: Sequential images of resecting a (A) posterior pharyngeal wall carcinoma. (B) The dissection proceeds along superior wall followed and is then circumferentially dissected from the (C) right and (D) left lateral pharyngeal walls. (E) The inferior resection margin is then defined followed by en bloc resection of the lesion by careful dissection off the (F) prevertebral fascia with the resulting defect (G) left to granulate secondarily.

FUTURE DIRECTIONS

Transoral robotic surgery is minimally invasive, safe and offers sound oncologic surgical technique, with improved functional outcomes. Careful patient selection, based on a comprehensive physical examination and preoperative imaging, is essential to obtain successful outcomes. Adequate exposure is a critical component of this technique that facilitates clear margins with minimal postoperative morbidity. Further prospective trials are required to more clearly identify patients who are better served with this technique. Certainly, TORS has emerged as a viable treatment option in the armamentarium of organ preservation therapies for hypopharynx SCC.

VIDEO LEGEND

Video 3.1: Right hypopharyngeal transoral robotic surgery.

REFERENCES

1. Cooper JS, et al. National Cancer Database report on cancer of the head and neck: 10-year update. Head Neck. 2009;31(6):748-58.
2. Kirchner JA. Pyriform sinus cancer: a clinical and laboratory study. Ann Otol Rhinol Laryngol. 1975;84(6):793-803.
3. Hoffman HT, et al. Hypopharyngeal cancer patient care evaluation. Laryngoscope. 1997;107(8):1005-17.
4. Hall SF, et al. The natural history of patients with squamous cell carcinoma of the hypopharynx. Laryngoscope. 2008;118(8):1362-71.
5. Gourin CG, Terris DJ. Carcinoma of the hypopharynx. Surg Oncol Clin North Am. 2004;13(1):81-98.
6. Buckley JG, MacLennan K. Cervical node metastases in laryngeal and hypopharyngeal cancer: a prospective analysis of prevalence and distribution. Head Neck. 2000; 22(4):380-5.
7. Park YM, et al. Feasibility of transoral robotic hypopharyngectomy for early-stage hypopharyngeal carcinoma. Oral Oncol. 2010;46(8):597-602.
8. Chan JY, Wei WI. Current management strategy of hypopharyngeal carcinoma. Auris Nasus Larynx. 2013;40(1):2-6.
9. Lefebvre JL. Surgery for laryngopharyngeal SCC in the era of organ preservation. Clin Exp Otorhinolaryngol. 2009; 2(4):159-63.
10. Lefebvre JL, et al. Larynx preservation in pyriform sinus cancer: preliminary results of a European Organization for Research and Treatment of Cancer phase III trial. EORTC Head and Neck Cancer Cooperative Group. J Natl Cancer Inst. 1996;88(13):890-9.

JAYPEE BROTHERS

11. Levendag PC, et al. Dysphagia disorders in patients with cancer of the oropharynx are significantly affected by the radiation therapy dose to the superior and middle constrictor muscle: a dose-effect relationship. Radiother Oncol. 2007;85(1):64-73.
12. Forastiere AA, et al. Concurrent chemotherapy and radiotherapy for organ preservation in advanced laryngeal cancer. N Engl J Med. 2003;349(22):2091-8.
13. Forastiere AA, et al. Long-Term Results of RTOG 91-11: A Comparison of Three Nonsurgical Treatment Strategies to Preserve the Larynx in Patients With Locally Advanced Larynx Cancer. J Clin Oncol. 2013;31(7):845-52..
14. Hoffman HT, et al. Laryngeal cancer in the United States: changes in demographics, patterns of care, and survival. Laryngoscope. 2006;116(9 Pt 2 Suppl 111):1-13.
15. Chen AY, Halpern M. Factors predictive of survival in advanced laryngeal cancer. Arch Otolaryngol Head Neck Surg. 2007;133(12):1270-6.
16. Arbyn M, et al. Trends of cervical cancer mortality in the member states of the European Union. Eur J Cancer. 2009;45(15):2640-8.
17. Godballe C, et al. Hypopharyngeal cancer: results of treatment based on radiation therapy and salvage surgery. Laryngoscope. 2002;112(5):834-8.
18. Hall SF, et al. Radiotherapy or surgery for head and neck squamous cell cancer: establishing the baseline for hypopharyngeal carcinoma? Cancer. 2009;115(24):5711-22.
19. Steiner W. [Therapy of hypopharyngeal cancer. Part III: The concept of minimally invasive therapy of cancers of the upper aerodigestive tract with special reference to hypopharyngeal cancer and trans-oral laser microsurgery]. HNO. 1994;42(2):104-12.
20. Iseli TA, et al. Functional outcomes after transoral robotic surgery for head and neck cancer. Otolaryngol Head Neck Surg. 2009;141(2):166-71.
21. Rudert HH, Hoft S. Transoral carbon-dioxide laser resection of hypopharyngeal carcinoma. Eur Arch Otorhinolaryngol. 2003;260(4):198-206.
22. Steiner W, et al. Organ preservation by transoral laser microsurgery in piriform sinus carcinoma. Otolaryngol Head Neck Surg. 2001;124(1):58-67.
23. Martin A, et al. Organ preserving transoral laser microsurgery for cancer of the hypopharynx. Laryngoscope. 2008;118(3):398-402.
24. Bernal-Sprekelsen M, et al. [Complications of transoral laser surgery for malignant tumors of the larynx and hypopharynx]. Laryngorhinootologie. 2009;88(1):28-34.
25. Park YM, et al. Transoral robotic surgery for hypopharyngeal squamous cell carcinoma: 3-year oncologic and functional analysis. Oral Oncol. 2012;48(6):560-6.
26. Boudreaux BA, et al. Robot-assisted surgery for upper aerodigestive tract neoplasms. Arch Otolaryngol Head Neck Surg. 2009;135(4):397-401.
27. Genden EM, Desai S, Sung CK. Transoral robotic surgery for the management of head and neck cancer: a preliminary experience. Head Neck. 2009;31(3):283-9.
28. De Virgilio A, et al. How to optimize laryngeal and hypopharyngeal exposure in transoral robotic surgery. Auris Nasus Larynx. 2013;40(3):312-9.
29. Crosby ET, et al. The unanticipated difficult airway with recommendations for management. Can J Anaesth, 1998;45 (8):757-76.
30. Rumboldt Z, et al. Imaging in head and neck cancer. Curr Treat Options Oncol. 2006;7(1):23-34.
31. Harrison DF. Pathology of hypopharyngeal cancer in relation to surgical management. J Laryngol Otol. 1970;84(4):349-67.
32. Gedgaudas-McClees RK, McClees EC. The value of the barium-swallow technique in the evaluation of the hypopharynx. Mt Sinai J Med. 1984;51(4):455-9.
33. Harrison DF. Surgical pathology of hypopharyngeal neoplasms. J Laryngol Otol. 1971;85(12):1215-8.

JAYPEE BROTHERS

for detailed information on otolaryngology books, visit our website www.jaypeebrothers.com, for detailed information on otolaryngolo

ROBOTIC SURGERY IN OTOLARYNGOLOGY
HEAD & NECK SURGERY

Robotic Surgery in Otolaryngology—Head and Neck Surgery is a practical guidebook for practicing robotic surgeons as well as those surgeons in training. With the use of multiple diagrams, this book summarizes in a clear concise manner the steps in performing each type of robotic operation within the head and neck with an emphasis on transoral robotic surgery (TORS) as well as robotic thyroid surgery. This book has been divided into four sections which have been written by experts in their respective fields including a section for operations currently in the process of development.



Nilesh R Vasan MD FRACS is a Fellowship trained Head and Neck Surgeon at the University of Oklahoma Health Sciences Center, Oklahoma, USA. He was born and raised in New Zealand which is where he also completed his residency in Otolaryngology—Head and Neck Surgery, becoming a Fellow of the Royal Australasian College of Surgeons. He is the only physician in Oklahoma performing Head and Neck Robotic Surgery. Dr Vasan is active in the field of medical device innovation and has developed in conjunction with the University of Oklahoma instruments that are now commercially available.

Dr Vasan is the founder of Adroit Surgical LLC, a private company specializing in emergency airway devices that can be utilized easily in the field under adverse conditions as well as in hospitals.

Available at all medical bookstores
or buy online at www.jaypeebrothers.com

JAYPEE BROTHERS
Medical Publishers (P) Ltd.
www.jaypeebrothers.com

Join us on facebook.com/JaypeeMedicalPublishers

Shelving Recommendation
OTOLARYNGOLOGY
HEAD AND NECK SURGERY

ISBN 978-93-5152-901-9
9 789351 529019