iled information on neurology books, visit our website **www.jaypeebrothers.com,** for detailed information on neurology books, visit our website **www.jaypeebrothers.com**

Differential Diagnosis in NEUROLOGY

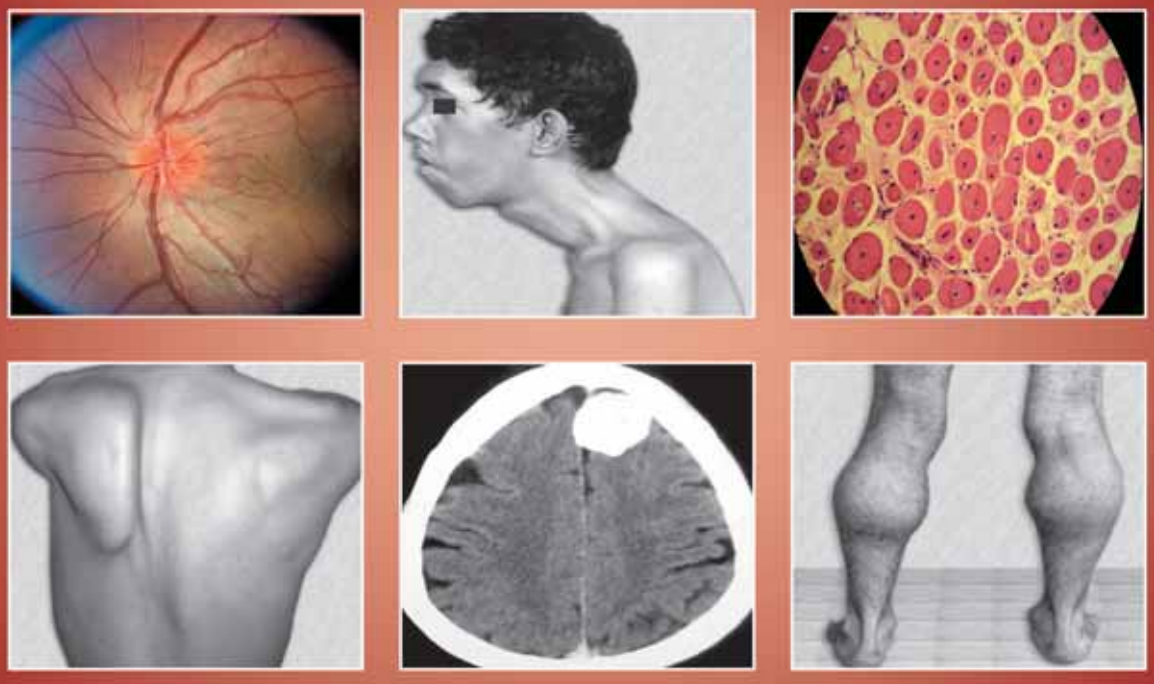

Sudesh Prabhakar
Gagandeep Singh

JAYPEE

Contents

1. **Clinical History and Neurologic Examination of Adult** 1
   Sudesh Prabhakar
2. **Historical Aspects of Neurological Examination** 14
   Kalyan B Bhattacharyya
3. **Transient Loss of Consciousness** 27
   Jagarlapudi M Murthy
4. **Approach to Patients with New Onset Seizures** 34
   Zeid Yasiry, Simon D Shorvon
5. **Approach to Intractable Epilepsy** 58
   Gagandeep Singh
6. **Psychogenic Nonepileptic Attack Disorder** 71
   Parampreet S Kharbanda
7. **Approach to Coma** 78
   Vivek Lal
8. **Delirium and Acute Confusional States** 95
   Ellajosyula Ratnavalli
9. **Approach to a Patient with Intellectual and Memory Impairment** 107
   Shyamal K Das, Sandip Pal, Malay K Ghosal
10. **Approach to Global Development Delay and Developmental Regression** 123
    Pratibha Singhi, Naveen Sankhyan
11. **Approach to a Patient with Speech and Language Disorders** 135
    Apoorva Pauranik
12. **Clinical Evaluation of Apraxia and Agnosia** 148
    Sireesha Yareeda, Archana Bethala, Suvarna Alladi
13. **Dementia: Clinical Approach** 159
    Suvarna Alladi, Pavan K Cherukuri, Divyaraj Gollahalli
14. **Approach to Disturbances of Smell and Taste** 173
    Sahil Mehta

JAYPEE BROTHERS

15. **Approach to Visual Loss** 180
Prem S Subramanian, Sarita B Dave

16. **Clinical Approach to Pupillary and Eyelid Abnormalities** 196
Wesley Chan, Fiona E Costello

17. **Approach to a Dizzy Patient** 203
Sudhir Kothari

18. **Approach to Deafness** 214
Anirban Biswas

19. **Approach to a Patient with Neurogenic Dysphagia** 226
Kiran Bala, Shaily Singh, Preeti Singla

20. **Evaluation of Acute Headache** 232
Rakesh Shukla

21. **Chronic Headache** 245
K Ravishankar, Meghna Bhatnagar

22. **Approach to Ataxia of Limbs and Gait** 251
Achal K Srivastava, Mohammed Faruq

23. **Approach to Gait Disorders** 269
Netravathi M, Pramod K Pal

24. **Approach to Falls in the Young, Middle Aged, and the Elderly** 281
Inderpal Singh

25. **Dystonia: A Clinical Approach** 287
Amit Batla, Kailash P Bhatia

26. **Myoclonus** 301
Vinay Goyal, Chanchal Goyal

27. **Hyperkinetic Movement Disorders** 308
Madhuri Behari, Awadh K Pandit

28. **Hypokinetic Disorders** 317
Chandi P Das

29. **Approach to Monoplegia and Hemiplegia** 326
Manoj Goyal, Sudesh Prabhakar

30. **Approach to Patients with Paraplegia** 344
Birinder S Paul, Gunchan Paul, Inder D Bahia

31. **An Approach to the Floppy Infant** 355
Vrajesh Udani, Sarbani S Raha

32. **Clinical Approach to a Patient with Peripheral Neuropathy** 361
Vinod Puri, Neera Chaudhry, Prashant Makhija

33. **Clinical Approach to Muscle Disease** 371
Satish V Khadilkar, Kishore V Shetty

JAYPEE BROTHERS

34. Approach to Neck and Arm Pain 397
Vinay Goyal, Abhishek Pathak, Chanchal Goyal

35. Lower Backache and Lower Limb Pain 403
Usha K Misra, Jayantee Kalita, Sanjeev K Bhoi

36. Suspected Spinal Cord Syndromes: A Clinical Approach 418
Rohit Bhatia, Rima M Chaudhari

37. Craniovertebral Junction Anomalies—Diagnosis and Changing Trends in Management 440
Poodipedi S Chandra

38. Approach to Bladder, Bowel, and Sexual Dysfunction 450
Netravathi M, Pramod K Pal, P Satishchandra

39. Excessive Daytime Sleepiness 465
Suresh Kumar, Ayyar SSK, Sheetal Suresh

40. Differential Diagnosis of the Parasomnias 472
Garima Shukla, Bhavna Kaul

41. Diagnosis of Spontaneous Intracerebral Hemorrhage and Its Complications 480
Craig S Anderson, Jie Yang

42. Approach to a Patient with Subarachnoid Hemorrhage 487
Shakir Husain, PR Srijithesh

43. Approach to Stroke in Young 494
Dheeraj Khurana, Anu Gupta

44. Spinal Cord Vascular Diseases 509
Jeyaraj D Pandian, Paulin Sudhan

45. Approach to Nonarterial Ischemic Strokes—Central Nervous System Vasculitis 519
Manish Modi, Venugopalan Y Vishnu

46. Approach to a Patient with Acute Ischemic Stroke within Four Hours of Onset 525
Madakasira V Padma, Deepa Dash

Appendices

Appendix 1: Glossary of Cognitive Neuropsychology and Linguistics 529
Apoorva Pauranik

Appendix 2: Hindi Words, Phrases, and Nonwords 534
Apoorva Pauranik

Appendix 3: Picture Cards 535
Apoorva Pauranik

Appendix 4: Criteria for Diagnosis of Dementia Subtypes 538
Suvarna Alladi, Pavankumar Cherukuri, Divyaraj Gollahalli

JAYPEE BROTHERS

Appendix 5: Geriatric Assessment Tool Kit
Tinetti Performance Oriented Mobility Assessment **544**
M Netravathi, Pramod K Pal

Appendix 6: Berg Balance Scale **546**
M Netravathi, Pramod K Pal

Appendix 7: Balance Evaluation Systems Test **546**
M Netravathi, Pramod K Pal

Index **557**

JAYPEE BROTHERS

Chapter 28

Hypokinetic Disorders

Chandi P Das

JAYPEE BROTHERS

INTRODUCTION

Despite modern investigative tools, Parkinson's disease (PD) remains essentially a clinical diagnosis. Parkinson's disease requires the presence of bradykinesia with at least one of the following: tremor, rigidity, gait disturbance/postural instability, with asymmetrical onset of symptoms. Brain imaging and response to levodopa/dopamine agonist (DA) are supportive criteria. However, accuracy in clinical diagnosis may be incorrect in one quarter of patients seen by neurologists. Patients with various causes of hypokinesia get referred to a neurologist (Box 28.1). Studies performed at the London Brain Bank found that of the 100 consecutive cases of diagnosed PD in life, 24% could not be confirmed at autopsy.[1] Error rates of up to 8% have been reported when differentiating between PD and parkinsonian syndromes even in expert movement disorder clinics.[2] All patients with PD do not necessarily manifest all the cardinal features. Tremor is the commonest symptom in PD seen in around 80% cases. However, the commonest cause of tremor is not PD but essential tremor (ET), which is seen in 2–3% of the population.[3] As the prevalence of PD is around 0.2%, only a tenth of patients with tremor have PD.[4]

The diagnosis of PD can also be difficult when all the features of tremor, rigidity, akinesia (bradykinesia), and postural instability (TRAP) are present in a patient seen after a few years of symptom onset. Quite a few of the parkinsonian syndromes may mimic PD in this regard, but these have other features in addition, which are normally not seen in PD (Table 28.1). It is imperative that the chronology of onset of various symptoms be enquired as the pattern of progression is variable in different syndromes. As an analogy, patients seen late in the course of what appears to be peripheral neuropathy may, in fact, have started with a mononeuritis, evolved to mononeuritis multiplex, and finally present with diffuse involvement of the peripheral nerves. Since, some of the PD mimics can be partially responsive to L-dopa and DA, all cases of labeled PD (by another clinician), when first seen should have a review of diagnosis, especially when the symptoms are worsening to avoid unnecessary increments in dopaminergic therapy and institution of more invasive intervention, e.g., apomorphine, duodopa, or deep brain stimulation. Patients with various causes of hypokinesia may get referred to a neurologist (Box 28.1).

Box 28.1: Causes of hypokinesia (slowness of movement)

Nonneurological

- Poor eyesight
- Joint problems
- Depression, catatonia
- Chronic diseases (cardiac, respiratory)

Neurological

- Spasticity
- Cerebellar disorders
- Peripheral neuropathy
- Neuromuscular disorders
- Muscle diseases

Basal ganglia

- Parkinson's disease
- Parkinson mimics

TABLE 28.1: Clinical characters in PD and parkinsonian syndromes (PD mimics)

	PD	MSA	CBD	PSP	DLB
Tremor	+				+
Rigidity	+	+	+	+	+
Bradykinesia	+	+	+	+	+
Gait disorder		+	+	+	+
Early falls			+	+	+
Dysarthria		+	+	+	+
Dysphagia				+	+
Dysautonomia		+			
Apraxia			+		
Gaze palsy				+	
Dementia					+

PD, Parkinson's disease; DLB, dementia with Lewy bodies; MSA, multisystem atrophy; PSP, progressive supranuclear palsy; CBD, corticobasal degeneration. + denotes features present in >70% of patients in postmortem series.

SPECIALIZED INVESTIGATIONS

Neuroimaging studies can occasionally be helpful in making a diagnosis of PD but are generally not required. Besides they are expensive and available only in select centers. Positron emission tomography (PET) and single photon emission tomography (SPECT) can be used to provide an index of the integrity of the nigrostriatal dopamine system.[5,6] Striatal uptake of [18F]-fluorodopa (FD), ligands that bind to the dopamine transporter, such as beta-carbomethoxy-3 beta-(4-iodophenyl) tropane (β-CIT), can each be used to estimate the number of remaining dopamine terminals and nigral neurons. With each of these techniques, patients with PD demonstrate a significant and asymmetric reduction of tracer uptake in the striatum, particularly in the posterior portion of the putamen. It is also reduced in those with Parkinson's disease with dementia and parkinsonian syndromes. Uptake is normal in controls and in patients with ET, neuroleptic-induced parkinsonism, and psychogenic parkinsonism.

Parkinson's disease is thought to result from a complex interaction between multiple predisposing genes and environmental effects, although these interactions are still poorly understood.[7,8] An increasing number of loci linked to familial parkinsonism have been found (*PARK1–PARK16*). Of these, some cause autosomal dominant (AD) parkinsonism (*PARK1, 3, 4, 5, 8, 11, 13,* possibly *16*) and some have autosomal recessive transmission (*PARK2, 6, 7, 9, 10, 14, 15*), with *PARK12* being X-linked recessive. Although important for insight into the molecular pathogenesis of the disease, and differing phenotypes of presentation, genetic testing is so far of little therapeutic relevance. Genetic testing for parkin mutations can be offered in young-onset cases. However, the chance of identifying parkin (*PARK2*) mutations is <5% in sporadic cases with onset at <45 years.[9] This probability is much greater in those with onset <30 years and in those with an affected sibling.[9] Confirmation of this recessive form of disease might be helpful in genetic counseling because it renders transmission to the subsequent generation quite unlikely. Genetic testing for α-synuclein gene (*PARK1*) multiplications is rarely warranted in patients with AD pedigrees. Duplications seem to cause a classic phenotype, whereas more progressive disease, including dementia with Lewy bodies, occurs in cases with triplications. Overall, however, α-synuclein gene multiplication is not a common cause of PD or dementia with Lewy bodies. Another form of AD PD *PARK8* has been identified. Different point mutations in the gene encoding a leucine-rich repeat kinase (*LRRK2*) have been found in several families with AD parkinsonism. Mutations in the *LRRK2* gene have subsequently been identified in 5–6% of patients with AD disease, and screening for a single common LRRK2 mutation yielded positive results in 1.6% of patients with apparently sporadic disease.[10] The screening for LRRK2 mutations is important in the diagnostic workup and counseling of patients with PD. Currently, access to molecular genetic testing for the 2 most common mutations (parkin [PARK2] and LRRK2 [PARK8]) is still restricted to research centers and costs are high.

Clinical Presentation

Bradykinesia, or slowness of movements, is the most characteristic and disabling motor feature in Parkinson's disease, causing difficulties in performing daily activities, such as writing and personal hygiene. Other manifestations of bradykinesia are, "mask face", reduced arm-swing during gait, and loss of spontaneous movements. This may also be influenced by apathy and depression (nonmotor manifestations). Although, amplitude and speed are both affected, the former is disproportionately more affected (decrements in finger taps and fractionating finger movements) compared to other PD mimics or parkinsonian syndromes.[11]

Resting tremor is present in most patients and usually begins unilaterally; it is almost always prominent in

JAYPEE BROTHERS

the distal part of the extremity. In early stages, it may disappear on activity. As the disease worsens, the tremor becomes bilateral. PD tremor frequency is in the 4–6 Hz range and described as supination–pronation ("pill-rolling") type. This clinical feature assists the clinicians to differentiate it from ET, which usually has a higher frequency and is a flexion–extension form of movement.[12] An estimated 30% of patients with PD do not have resting tremor. Patients with a tremor-dominant form of PD tend to have a relatively benign course, whereas those who present with an akinetic-rigid form of the disease have more rapid progression, and are likely to be diagnosed as having atypical parkinsonism.[13]

Essential tremor is a common differential diagnosis for tremor in PD and is characterized by the presence of bilateral, largely symmetrical, postural, or kinetic tremor that affects the hands and forearms and is visible and persistent. Around 20% of patients with ET are misdiagnosed with PD and vice versa.[14] Bradykinesia, rigidity, and postural instability are not part of ET, but it has a postural component, which is apparent immediately as the arms are outstretched. However, a re-emergent tremor that appears when outstretching the arms after some latency is more characteristic of PD.[15] Particularly, difficult diagnostic situations arise when an otherwise typical case of ET is associated with rest tremor (10% of cases) or when the tremor is unilateral, which can occur during the initial years of ET.[16,17] The presence of head tremor, voice tremor, and sensitivity to alcohol strongly favors ET. A family history of a similar tremor could also be indicative of ET because it is an AD disorder in many cases.

One must also consider psychogenic forms of parkinsonian tremor.[18] Such cases may represent as many as 5% of patients seen in the practice of a movement disorder specialist and may be difficult to diagnose. It is characterized by variable frequency (tremor with multiple frequencies), and distractibility (tremor is more prominent when the patient focuses on the tremor and diminishes or disappears when the patient is distracted, whereas the opposite is true with organic tremor). Entrainment is another feature; patient is asked to mimic a varying tremor pattern (in the unaffected limb), demonstrated by the examiner. Then the tremor frequency in the affected limb changes to match or entrain with a series the different frequencies in the mimicking limb. In genuine/organic cases the tremor in the affected limb should not change. These features can often be recognized at the bedside and documented with accelerometry.[19]

Rigidity, which occurs in neck, shoulders, wrist, and ankles, leads to the characteristic stooped posture, anteroflexed head, and flexed knees and elbows in patients who have PD. However, if there is a disproportionately greater "axial" than "appendicular" rigidity, then the possibility of a PD mimic is higher. Those patients may have sustained antecollis" or flexion of neck when lying down ("pillow sign"), with a lesser rigidity in the limbs. Upper limb rigidity may precede (greater) or equal lower-limb rigidity in PD, whereas markedly more rigidity in lower compared to upper limbs, especially in the presence of cerebrovascular risk factors, which may point toward vascular parkinsonism (VP). Postural instability usually presents later in the course of PD >3 years. The pull test, during which the patient is quickly pulled backward or forward by the shoulders, is used to assess retropulsion or propulsion. Taking more than two steps indicates an abnormal postural response.

Although, the motor symptoms of PD are well-defined, the nonmotor features of this disorder are under recognized and, consequently, undertreated. Results from a recent international survey show that up to 62% of nonmotor symptoms of PD, such as apathy, pain, sexual difficulties, bowel incontinence, and sleep disorders, might remain undeclared to healthcare professionals because patients are either embarrassed or unaware that the symptoms are linked to PD.[20] A large range of symptoms comprise the nonmotor symptom complex of PD (Table 28.2) and several reviews have focused on these symptoms and the efforts made to quantify and manage them.[21] Nonmotor symptoms of PD occur not only in advanced disease but also in early stages, and some symptoms such as olfactory deficit, constipation, rapid-eye movement sleep behavior disorder (RBD), and depression might precede the expression of motor symptoms by more than a decade.[22]

Clinicopathologic Correlation

Pathologic studies by Braak et al., based on autopsies performed on a large series of individuals, suggest that α-synuclein accumulation in the substantia nigra pars compacta (SNc) is a relatively late pathologic development in the course of PD, occurring only after changes have already developed in the lower brainstem and olfactory regions.[23] Clinical studies similarly suggest that olfactory changes, constipation, and RBD are risk factors for the emergence of the more classic motor features of the disease.[24] For example, the prospective longitudinal

JAYPEE BROTHERS

TABLE 28.2: Nonmotor symptoms in PD and response to Rx

Nature of symptoms	Response to L-dopa
Neuropsychiatric symptoms	
Depression, apathy	Yes
Anhedonia	Yes
Cognitive dysfunction	00
Hallucinations, illusions, delusions	00
Confusion	00
Panic attacks, anxiety	Yes (when related to "off" period)
Sleep disorders	
Restless legs and periodic limb movements	Yes
Rapid-eye movement sleep behavior disorder	Yes?
Excessive daytime somnolence	00
Vivid dreaming	00
Insomnia	00
Sleep-disordered breathing	00
Autonomic symptoms	
Bladder disturbances	00
Urgency	Yes (detrusor overactivity)
Nocturia	Yes
Frequency	00
Sweating	00
Orthostatic hypotension	00
Erectile impotence	Yes
Gastrointestinal symptoms	
Dribbling of saliva	Yes?
Ageusia	00
Dysphagia, choking	00
Reflux, vomiting	00
Constipation	Yes
Sensory symptoms	
Primary pain related to Parkinson's disease (central pain)	Yes
Fluctuation-related pain (wearing off, dyskinesias)	Yes
Paresthesia	00
Olfactory disturbance	00
Visual dysfunction (contrast sensitivity, color vision)	00
Fatigue	Yes

Honolulu Heart Study showed that constipation increased the risk of developing PD by as much as 4.5-fold. RBD is frequently associated with dopaminergic changes on PET imaging even when patients have no parkinsonian features, and as many as 50% of patients with RBD go on to develop PD.[25] The anterior olfactory region is a common early site of pathology in PD, and anosmia is frequently found in patients with PD in all stages of the disease. A prospective study showed that 10% of hyposmic first-degree family members and almost half of the asymptomatic relatives of patients with PD who had hyposmia and an abnormal dopaminergic scan developed PD within 2 years, whereas PD did not develop in any of the relatives without anosmia during this same time period.[26] Indeed, it has been proposed that these features may represent more than risk factors. Their frequent appearance in patients who later develop the classic motor features of PD coupled with corresponding pathologic changes, which seem to antedate degeneration of dopamine neurons, raises the possibility that they may actually represent an early phase of the disease process itself.

Parkinsonian Syndrome (Parkinson Mimics)

Clinical diagnostic accuracy is less precise for patients with atypical parkinsonian sydrome (Parkinson mimics) than for those with PD. Although, it is usually possible to identify that a patient who is a Parkinson mimic, it may be difficult to diagnose the precise subtype. The various subtypes are categorized in Box 28.2. Features favoring a Parkinson mimic would include, early onset of prominent speech, and gait dysfunction, postural instability, and freezing in the first 3 years, hallucinations not related to levodopa in the first 3 years, dementia preceding motor symptoms, axial rigidity greater than appendicular rigidity, absence of resting tremor, prominent autonomic

Box 28.2: Parkinsonian syndromes (Parkinson's mimics)

Neurodegenerative

- Multiple system atrophy
- Corticobasal-ganglionic degeneration
- Progressive supranuclear palsy
- Diffuse Lewy body disease

Nondegenerative

- Normal pressure hydrocephalous
- Drug-induced parkinsonism
- Vascular parkinsonism
- Trauma/subdural hematoma

JAYPEE BROTHERS

dysfunction, and poor or unsustained response to levodopa.

Multiple System Atrophy (MSA)

The disorder can be reliably diagnosed only if prominent signs of autonomic failure, such as impotence or postural hypotension, develop early in the course of the disease. Although, features may overlap, recent nomenclature favors dividing MSA into those with predominant parkinsonian (MSA-P) or those with predominant cerebellar (MSA-C) features.[27] Clinical characteristics that can help differentiate MSA-P from PD are nocturnal stridor, rapid course, early instability, and falls, stimulus-sensitive myoclonus, pyramidal tract signs, severe dysarthria, and insufficient or only transient response to levodopa (including dyskinesia, which are frequently restricted to the orofacial, and cervical musculature).

Rapid-eye-movement sleep behavioral disorder is found, through history in a large member of patients who have MSA, and in almost all through polysomnography. Additional clinical findings reported in MSA include extensor plantar reflexes and hyperreflexia, but limb weakness and spasticity are uncommon. Less frequent features include upgaze palsy, emotional lability, truncal dystonia with a tendency to lean laterally while seated, antecollis, myoclonus, stridor, polyneuropathy, distal limb cyanosis, postprandial hypotension, poor lacrimation, and salivation, and Raynaud's phenomenon.

The diagnosis is based on consensus criteria.[28] Purely based on clinical examination, the criteria include four domains: autonomic/urinary dysfunction, parkinsonism, cerebellar ataxia, and corticospinal dysfunction. The criteria were developed to define the relative importance of these features. The diagnosis of possible MSA requires the presence of one criterion plus two features from separate domains. The diagnosis of probable MSA requires the presence of autonomic failure/urinary dysfunction plus poorly levodopa-responsive parkinsonism or cerebellar ataxia. The diagnosis of definite MSA requires pathologic confirmation. The exclusion criteria include onset before the age of 30 years, family history, hallucinations unrelated to medication, dementia, vertical supranuclear gaze dysfunction, focal cortical dysfunction, and clinical or radiographic evidence for alternate diagnoses.

Corticobasal-Ganglionic Degeneration (CBD)

Corticobasal-ganglionic degeneration begins generally with asymmetric parkinsonian symptoms (except tremor), or cognitive decline. When motor dysfunction appears initially, the symptoms include rigidity, akinesia, and gait disorder, coupled with marked difficulty using the involved side of the body because of limb apraxia. Up to 50% patients exhibit the ''alien limb'' phenomenon in which the affected limb, usually an arm, moves involuntarily, appears to float in space without the individual's awareness.[29] Hemispatial neglect can be a feature, along with disinhibition and dysphasia. Once the disorder has become established, rigidity, bradykinesia, gait disorder, or tremor affects all subjects; myoclonus or dystonia and cognitive dysfunction are seen in around 90% of patients. Multiple oculomotor abnormalities may be seen, including oculomotor apraxia, optic ataxia, and supranuclear gaze palsy. The disorder progresses relentlessly to become bilateral and produces severe disability within 2–7 years.

Differential diagnoses depend on the nature of symptom progression and include primary progressive aphasia, frontal lobe dementia, progressive apraxia, and progressive supranuclear palsy (PSP). Unlike PD with deposits of α-synuclein, the neuropathologic features of CBD consist of ballooned neurons, cortical and striatal tau-containing neuronal and glial inclusions, astrocytic plaques and thread-like lesions in the substantia nigra, cerebral cortex, and cervical spinal cord. The pathology is similar to that seen in PSP, and the clinical picture of both diseases has considerable overlap, especially in the late stages. The general site of spread in CBD is cortical to subcortical, and reverse in PSP, which possibly explains the clinical differences in the initial stages.

Progressive Supranuclear Palsy

Progressive supranuclear palsy is characterized by features of an atypical parkinsonism, with impairment in vertical eye movements, particularly down-gaze, hyperextension of the neck, and early falls within the first year.[30] Slowing of vertical saccades or the presence of a prominent stare with marked reduction in blink rate is the early feature and should raise suspicion that a patient with atypical parkinsonism might have PSP. Dissociation between impaired voluntary and pursuit gaze and preservation of oculocephalic reflexes show the supranuclear origin of the oculomotor disorder. Associated oculomotor abnormalities include square-wave jerks, convergence insufficiency, reduced blink rate, eyelid apraxia (difficulty opening the closed eyelids) accompanied by compensatory eyebrow elevation with frontalis overactivity, and blepharospasm. Axial (neck and trunk) symptoms predominate and rest tremor is

JAYPEE BROTHERS

uncommon. Bradykinesia is symmetrical and can be severe. Postural instability and falls commonly occur in the first year of the disease. Gait is more broad based and unsteady, unlike the typical small-stepped shuffling gait with propulsion of PD.

Some patients with PSP may strongly resemble patients with PD in the early stages of their illness and have a positive response to levodopa. PSP is also associated with personality changes, frequently apathy and depression, and mild dementia characterized principally by executive dysfunction. Sleep disturbances, notably insomnia, shorter sleep latency, and increased number of awakenings, which all become more severe with increased motor impairment, worsen the quality of life. Pathologically, PSP is characterized by degeneration in the SNc, other brainstem regions, and the pallidum, coupled with prominent tau-positive neurofibrillary tangles, quite similar to CBD. The early cortical pathology in CBD and later affliction in PSP may explain the differences in the phenotype at presentation and the similarities of clinical features of both diseases at a later stage.

Diffuse Lewy Body Disease

It is clinically defined as a progressive dementia syndrome with attentional and visuospatial deficits, fluctuations in attention, and cognition, visual hallucinations, and parkinsonism. Up to 40% of patients with idiopathic PD will also develop dementia according to population-based studies, which mostly occurs after 2 years of disease onset.[31] Clinical studies have not identified consistent clinical differences between patients with PD, dementia, and dementia with Lewy bodies, including fluctuations in attention, and cognition. Neuroleptic sensitivity with substantial motor worsening and changes in mental status has also been claimed as a distinctive feature of dementia with Lewy bodies.

Neuropathology shows widespread neocortical and limbic Lewy body degeneration in addition to brainstem Lewy body disease. Consistent with clinical overlap, neuropathological findings in patients fulfilling clinical criteria for either disease also seem indistinguishable, apart from a more pronounced temporal lobe Lewy body formation in dementia with Lewy bodies. Although, this characteristic has been suggested to separate the 2 disorders on the basis of dementia onset relative to parkinsonism, and to restrict the term PD dementia to patients in whom dementia begins at least 12 months after the motor manifestations of the disease, the 2 forms of dementia are, probably, 2 clinical manifestations within a spectrum of Lewy body diseases.[32] This notion is also corroborated by recent genetic findings, where triplication of the α-synuclein gene was associated with a clinical phenotype of PD dementia or dementia with Lewy bodies, whereas duplication of the same gene caused PD without dementia.[33]

Vascular Parkinsonism

Vascular parkinsonism, also termed as arteriosclerotic parkinsonism, affects people in the 7–8 decade of life and is characterized by the parkinsonian signs of bradykinesia, rigidity, and gait disorder resulting from multiple bilateral lacunar infarctions in the basal ganglia and subcortical white matter. Vascular parkinsonism differs clinically from idiopathic parkinson's disease in showing plastic (lead-pipe) rigidity rather than cogwheel rigidity, symmetric rather than asymmetric symptoms, absence of tremor, and poor or no response to dopaminergic medications. Vascular parkinsonism frequently affects the lower body more than the upper and is often associated with pseudobulbar palsy (dysarthria, dysphagia, and emotional lability), pyramidal tract signs, impaired cognition, and dementia (frontal release signs). Balance is poor, and the gait consists of small, short steps, often with a "glued to the floor" quality.

The disorder can be differentiated from MSA by the absence of autonomic impairment, from PSP by the absence of oculomotor disorders, and from CBD by the symmetric presentation, and absence of focal dystonias and apraxias. The symptoms often exhibit stepwise progression; however, gradual slow progression, and sudden onset, followed by improvement are also described.[34] Magnetic resonance imaging (MRI) shows multiple lacunae or larger infarctions in the deep white matter bilaterally and within the basal ganglia (Fig. 28.1). Studies using [123I] FP-CIT SPECT, have tried to determine whether VP patients have presynaptic dopaminergic function similar to PD patients. The presence of a symmetrical FP-CIT uptake in the basal ganglia may help distinguish VP from PD and could, therefore, be used as a criterion for the diagnosis of VP.[35]

Drug-Induced Parkinsonism

The most common of nondegenerative PD mimics is drug-induced parkinsonism. Various antidopaminergic drugs can induce parkinsonism; the most common being the neuroleptics and the antiemetics. The older generation antipsychotics block all subtypes of dopamine

JAYPEE BROTHERS

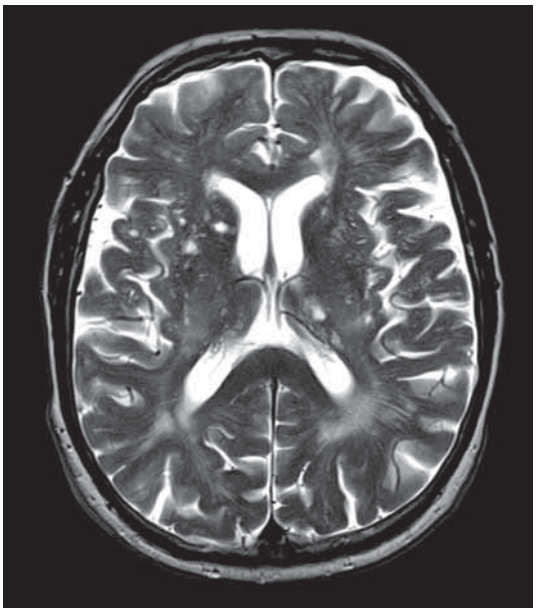

Fig. 28.1: Vascular parkinsonism.

receptors (D1–D5). These agents' primary target for psychosis are D3–D5 receptors, primarily found in nucleus accumbens, frontal cortex, and hippocampus, respectively, but collaterally block the D1 and D2 receptors in the striatum giving rise to parkinsonian manifestations. The newer generation atypical antipsychotics have limited effect on D1 and D2 receptors; the least being clozapine, followed by quetiapine, olanzapine, and then risperidone. Some neuroleptic agents are used primarily to treat nonpsychiatric problems, such as emesis (e.g., prochlorperazine and promethazine) and other gastrointestinal disorders (e.g., metoclopramide).

The presence of orofacial dyskinesias or akathisia (movement disorders associated with chronic neuroleptics) is helpful for diagnosis. The symptoms and signs of drug-induced parkinsonism can be identical to those of PD, including asymmetric presentation with rest tremor. The diagnosis of drug-induced parkinsonism is especially difficult in patients in whom a drug history is unclear, in those taking small amounts of antidopaminergic drugs, and in those in whom withdrawal of the offending drugs is not followed by regression of parkinsonism, which suggests that PD might underlie the drug-induced state. Other drugs that have been reported to induce or worsen parkinsonism include dopamine-uptake inhibitors such as reserpine or tetrabenazine, selective serotonin-reuptake inhibitors, lithium, valproic acid, calcium channel blockers such as cinnarizine, and flunarizine, antiarrhythmics such as amiodarone, cholinergics, chemotherapeutics, amphotericin B, and estrogens.

IMAGING

Structural brain imaging with cranial computed tomography (CT) is normal in uncomplicated PD. There may be age-associated abnormal changes, such as mild-to-moderate degrees of cortical and subcortical atrophy or signs of cerebrovascular disease with lacunar white matter lesions. These latter pathologies may raise diagnostic issues when they are deemed substantial enough to cause VP, or when parkinsonian signs have developed contralaterally to a basal ganglia infarct. Cranial CT is also useful in the detection of normal pressure hydrocephalus in patients with lower body parkinsonism who present with small-stepped gait, freezing, and instability but has limited sensitivity to detect cerebellar or pontine atrophy in multisystem atrophy, and midbrain atrophy in PSP.

Magnetic resonance imaging has substantially greater differential diagnostic potential in degenerative parkinsonian disorders (Box 28.3). Although, signal void in the substantia nigra with high-field MRI has been reported in PD, no specific MRI marker for the disease has been identified. The true value of MRI in parkinsonian disorders is in the differentiation of PD and atypical parkinsonism. Several structural MRI changes have been described for multisystem atrophy (Fig. 28.2), PSP (Fig. 28.3), or CBD, and some of these changes have

Box 28.3: Routine MRI findings in degenerative parkinsonism

- Parkinson's disease
  - Substantia nigra signal void on high-field MRI
- Multisystem atrophy
  - Infratentorial pathology
    - Medullary and pontine atrophy
    - Cerebellar and dentate atrophy
    - Hyperintensity of middle cerebellar peduncle, inferior olives, pons (hot-cross bun sign)
    - Dilated fourth ventricle
  - Supratentorial pathology
    - Putaminal atrophy and/or hypointensity
    - Putaminal lateral hyperintensity (slit sign)
- Progressive supranuclear palsy
  - Dilated 3rd ventricle
  - Dorsal midbrain atrophy (humming bird sign)
  - Frontotemporal cortical atrophy
  - Globus pallidus hyperintensity
  - Red nucleus hyperintensity
- Corticobasal degeneration
  - Asymmetric parietal cortical atrophy

MRI, magnetic resonance imaging.

JAYPEE BROTHERS



Fig. 28.2: MSA with 'hot cross bun sign'.

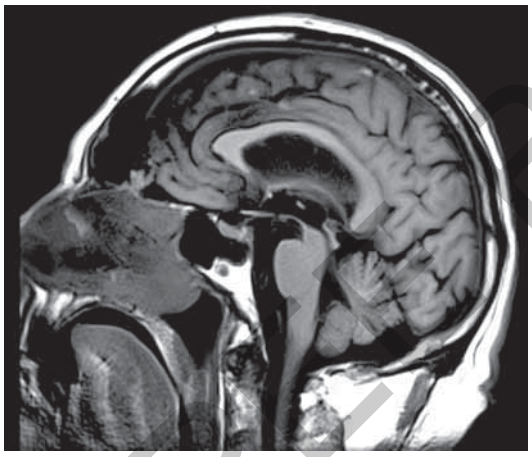

Fig. 28.3: PSP with humming bird sign.

high specificity and positive predictive values. However, sensitivity is generally around 60–80% or less.[36,37] Sensitivity to detect changes of striatal signal intensity in the parkinsonian variant of multisystem atrophy can be increased above 80% with 3–5 mm slice thickness.[38]

More recently, diffusion-weighted MRI has been used to differentiate between the disorders on the basis of changes of diffusivity of water molecules along fiber tracts, which were postulated to occur with striatal pathology in atypical parkinsonian disorders but not in the intact striatum of PD.[39] Initial studies have yielded nearly 100% sensitivity and specificity for differentiation of these disorders on the basis of increases in regional diffusion coefficients in the putamen. Three dimensional diffusivity measurements with tensor MRI could further enhance this type of differentiation between PD and other types of degenerative parkinsonism.

REFERENCES

1. Hughes AJ, Daniel SE, Kilford L, et al. Accuracy of clinical diagnosis of idiopathic Parkinson's disease: a clinico-pathological study of 100 cases. J Neurol Neurosurg Psychiatry. 1992;55:181-4.
2. Hughes AJ, Daniel SE, Ben-Shlomo Y, et al. The accuracy of diagnosis of parkinsonian syndromes in a specialist movement disorder service. Brain. 2002;125:861-70.
3. Koller WC, Busenbark KL. Essential tremor. In: Watts RL, Koller WC (Eds). Movement Disorders. New York: McGraw-Hill; 1997. pp. 365-85.
4. Ben-Shlomo Y. The epidemiology of Parkinson's disease. In: Quinn NP (Ed). Parkinsonism. London: Bailliere-Tindall; 1997. pp. 55-68.
5. Vingerhoets FJ, Snow BJ, Lee CS, et al. Longitudinal fluorodopa positron emission tomographic studies of the evolution of idiopathic parkinsonism. Ann Neurol. 1994;36:759-64.
6. Seibyl JP, Marek K, Sheff K, et al. Iodine-123-CIT and iodine-123-FPCIT SPECT measurement of dopamine transporters in healthy subjects and Parkinson patients. J Nucl Med. 1998;39:1500-8.
7. Satake W, Nakabayashi Y, Mizuta I, et al. Genome-wide association study identifies common variants at four loci as genetic risk factors for Parkinson's disease. Nat Genet. 2009;41:1303-7.
8. Simon-Sanchez J, Schulte C, Bras JM, et al. Genome-wide association study reveals genetic risk underlying Parkinson's disease. Nat Genet. 2009;41:1308-12.
9. Lücking CB, Durr A, Bonifati V, et al. Association between early onset Parkinson's disease and mutations in the parkin gene. N Engl J Med. 2000;342:1560-7.
10. Gilks WP, Abou-Sleiman PM, Gandhi S, et al. A common LRRK2 mutation in idiopathic Parkinson's disease. Lancet. 2005;365:415-6.
11. Epsay AJ, Beaton DE, Morgante F, et al. Impairments of speed and amplitude of movement in Parkinson's disease: a pilot study. Mov Disord. 2009;24:635-46.
12. Alvarez MV, Evidente VG, Driver-Dunckley ED. Differentiating Parkinson's disease from other parkinsonian disorders. Semin Neurol. 2007;27(4):356-62.
13. Jankovic J, McDermott M, Carter J, et al. Variable expression of Parkinson's disease: a base-line analysis of the DATATOP cohort. Neurology. 1990;40:1529-34.
14. Louis ED, Levy G, Cote LJ, et al. Clinical correlates of action tremor in Parkinson disease. Arch Neurol. 2001;58:1630-4.
15. Jankovic J, Schwartz KS, Ondo W. Re-emergent tremor of Parkinson's disease. J Neurol Neurosurg Psychiatry. 1999;67:646-50.
16. Cohen O, Pullman S, Jurewicz E, et al. Rest tremor in patients with essential tremor: prevalence, clinical correlates, and electrophysiologic characteristics. Arch Neurol. 2003;60:405-10.
17. Chaudhuri KR, Buxton-Thomas M, Dhawan V, et al. Long duration asymmetrical postural tremor is likely to predict development of Parkinson's disease and not essential tremor: clinical follow up study of 13 cases. J Neurol Neurosurg Psychiatry. 2005;76:115-7.
18. Lang AE, Koller WC, Fahn S. Psychogenic parkinsonism. Arch Neurol. 1995;52:802-10.
19. Zeuner KE, Shoge RO, Goldstein SR, et al. Accelerometry to distinguish psychogenic from essential or parkinsonian tremor. Neurology. 2003;26: 548-50.
20. Mitra T, Naidu Y, Martinez-Martin P, et al. The non declaration of non motor symptoms of Parkinson's disease to healthcare professionals. An international survey using the NMSQuest. 6th International Congress on

JAYPEE BROTHERS

Mental Dysfunctions and other Non-motor Features in Parkinson's disease and Related Disorders. Dresden October, 2008. Park Related Disorders. P0II: 161.
21. Chaudhuri KR, Martinez-Martin P. Quantitation of non-motor symptoms in Parkinson's disease. Eur J Neurol. 2008;15:2-7.
22. Naidu Y, Chaudhuri KR. Early Parkinson's disease and non motor issues. J Neurol. 2008;255:33-8.
23. Braak H, Del Tredici K, Rub U, et al. Staging of brain pathology related to sporadic Parkinson's disease. Neurobiol Aging. 2003;24:197-211.
24. Langston JW. The Parkinson's complex: parkinsonism is just the tip of the iceberg. Ann Neurol. 2006;59:591-6.
25. Albin RL, Koeppe RA, Chervin RD. Decreased striatal dopaminergic innervation in REM sleep behavior disorder. Neurology. 2000;55:1410-2.
26. Ponsen MM, Stoffers D, Booij J, et al. Idiopathic hyposmia as a preclinical sign of Parkinson's disease. Ann Neurol. 2004;56:173-81.
27. Wenning GK, Ben-Shlomo Y, Hughes A, et al. What clinical features are most useful to distinguish definite multiple system atrophy from Parkinson's disease? J Neurol Neurosurg Psychiatry. 2000;68:434-40.
28. Gilman S, Low PA, Quinn N, et al. Consensus statement on the diagnosis of multiple system atrophy. J Neurol Sci. 1999;163(1):94-8.
29. Hanna PA, Doody RS. Alien limb sign. Adv Neurol. 2000;82:135-45.
30. Litvan I, Agid Y, Calne D, et al. Clinical research criteria for the diagnosis of progressive supranuclear palsy (Steele-Richardson-Olszewski syndrome): report of the NINDS-SPSP international workshop. Neurology. 1996;47:1-9.
31. Aarsland D, Andersen K, Larsen JP, et al. Risk of dementia in Parkinson's disease: a community-based, prospective study. Neurology. 2001;56:730-36.
32. McKeith I, Mintzer J, Aarsland D, et al. Dementia with Lewy bodies. Lancet Neurol. 2004;3:19-28.
33. Zarranz JJ, Alegre J, Gómez-Esteban JC, et al. The new mutation, E46K, of α-synuclein causes Parkinson and Lewy body dementia. Ann Neurol. 2004;55:164-73.
34. Yamanouchi H, Nagura H. Neurological signs and frontal white matter lesions in vascular parkinsonism. A clinicopathologic study. Stroke. 1997;28(5):965-59.
35. Zijlmans J, Evans A, Fontes F, et al. [123I] FP-CIT spect study in vascular parkinsonism and Parkinson's disease. Mov Dis. 2007;22:1278-85.
36. Schrag A, Good CD, Miszkiel K, et al. Differentiation of atypical parkinsonian syndromes with routine MRI. Neurology. 2000;54:697-702.
37. Warmuth-Metz M, Naumann M, Csoti I, et al. Measurement of the midbrain diameter on routine magnetic resonance imaging: a simple and accurate method of differentiating between Parkinson disease and progressive supranuclear palsy. Arch Neurol. 2001;58:1076-9.
38. Kraft E, Trenkwalder C, Auer DP. T2-weighted MRI differentiates multiple system atrophy from Parkinson's disease. Neurology. 2002;59:1265-7.
39. Seppi K, Schocke MF, Esterhammer R, et al. Diffusion weighted imaging discriminates progressive supranuclear palsy from PD, but not from the Parkinson variant of multiple system atrophy. Neurology. 2003;60:922-7.

JAYPEE BROTHERS

for detailed information on neurology books, visit our website **www.jaypeebrothers.com,** for detailed information on neurology books, visit our website **www.jaype**

Differential Diagnosis in NEUROLOGY

Salient Features

- This book provides a practical approach to the diagnosis of neurological disorders
- Provides the reader with in-depth understanding of neurological examination and management of a patient with a practical how-to-do approach
- Covers all aspects of neurology from clinical history taking and examination to management of common as well as rare neurological conditions and their complications
- Numerous line drawings elaborate upon the brain anatomy and pathology in a simplified, reader-friendly manner
- With more than 350 images and 250 tables, the content adds up to make the book comprehensive and reader-friendly.

Sudesh Prabhakar MD DM FAMS FIAN
Director Neurology, Fortis Hospital
Mohali, Punjab, India
Former Professor and Head
Department of Neurology
Postgraduate Institute of Medical Education and Research
Chandigarh, Punjab, India



Gagandeep Singh MD DM
Professor and Head
Department of Neurology
Dayanand Medical College and Hospital
Ludhiana, Punjab, India



Available at all medical bookstores
or buy online at www.jaypeebrothers.com

JAYPEE BROTHERS
Medical Publishers (P) Ltd.
www.jaypeebrothers.com

Join us on facebook.com/JaypeeMedicalPublishers

Shelving Recommendation
NEUROLOGY

ISBN 978-93-5152-902-6