ophthalmology books, visit our website **www.jaypeebrothers.com,** for detailed information on ophthalmology books

Clinical Methods in
OPHTHALMOLOGY

A Practical Manual for Medical Students

Dadapeer K









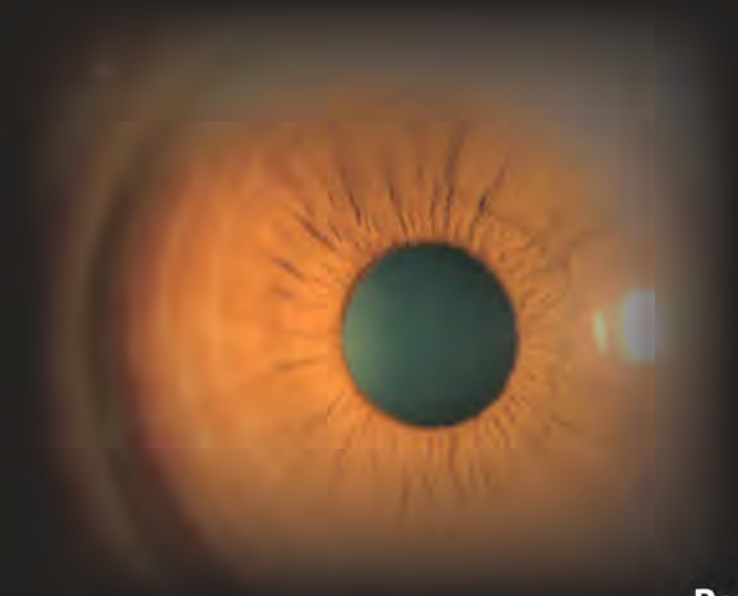

Forewords
Ravikumar BC
Jyothri Swarup

JAYPEE

SECOND EDITION

Contents

1. Symptomatology in Ophthalmology 1
Symptoms Related to Vision 1
Symptoms Not Related to Vision 5
Symptoms due to Adnexa of Eye 6

2. Ocular Examination 7
Head Posture 7
Facial Symmetry 8
Abnormal Facial Symmetry 8
Visual Acuity 9
Eyebrows 12
Eyelids 13
Eyelashes 15
Lacrimal Apparatus 16
Eyeball 17
Conjunctiva 21
Cornea 26
Sclera 30
Anterior Chamber 30
Iris 33
Pupil 37
Lens 41
Fundus: Vitreous and Retina 42

3. Case Proforma 45
History 45
General Physical Examination 45
Relevant Systemic Examination 45
Differential Diagnosis 46
Provisional Diagnosis 46
Investigations 46
Treatment 46

4. Case Presentation 47
Cataract 47
Pseudophakia 66
Aphakia 73
Corneal Opacity 77
Adult Dacryocystitis 85
Chalazion 93

Pterygium 97
Corneal Ulcer 104
Ptosis 113

5. Diagnostic Tests in Ophthalmology 118
Tonometry 118
Slit-lamp Examination 120
Ophthalmoscopy 121
Keratometry 123
Retinoscopy 124
Gonioscopy 127
Perimetry 128
Ultrasonography 129
Ultrasound Biomicroscopy 130
Vital Stains 130
Specular Microscopy 131
Fundus Fluorescein Angiography 132
Indocyanine Green Angiography 133
Optical Coherence Tomography 133
Heidelberg Retinal Tomography 133
Corneal Topography 133
Electrophysiological Tests 133
Retinal Function Tests 134
Macular Function Tests 134
Tests for Evaluation of a Case of Watering Eye 134
Tests for Evaluation of a Case of Squint 134
Tests for Evaluation of Tear Film 138

6. Ophthalmic Instruments 139
Lid Speculum 139
Needle Holder 139
Forceps 140
Scissors 143
Knives (Blades) 145
Instruments for Incision and Curettage of Chalazion 148
Instruments for Lens Removal 149
Instruments for Irrigation and Aspiration of Cortical Matter During Cataract Surgery 149
Instruments for Enucleation 150
Instruments for Evisceration 150
Instruments for Lacrimal Sac Surgery 151
Hooks and Retractors 152
Castroviejo Calipers 153
Iris Repositor 154
Thermal Ball Point Cautery 154
Cystitome or Capsulotome 154

7. Ophthalmic Lenses 155
Lens 155
Pinhole 157
Stenopaic Slit 157
Priestley Smith's Retinoscope Mirror 158
Jackson Cross Cylinder 158
Maddox Rod 158
20 D Lens 159
+78 D Lens 159

8. Drugs Used in Ophthalmology 160
Antiglaucoma Drugs 160
Mydriatics and Cycloplegics 162
Corticosteroids 163
Antibacterial Drugs 163
Antiviral Drugs 164
Antifungal Drugs 164
Nonsteroidal Anti-inflammatory Drugs 165
Local Anesthetic Drugs 165
Hyaluronidase Injection 165
Viscoelastics 165
Artificial Tears 166
Sutures 166
Dyes 166
Antiallergic Drugs 166

9. Common Ophthalmic Surgeries 167
Anesthesia 167
Cataract Surgery 169
Trabeculectomy 175
Evisceration 175
Enucleation 176
Other Surgeries 176

10. An Approach to a Patient with Red Eye 177
Acute Red Eye 177
Subconjunctival Hemorrhage 177
Blepharitis 178
Conjunctivitis 178
Inflamed Pterygium 179
Episcleritis 179
Scleritis 179
Corneal Abrasion 179
Infective and Noninfective Keratitis 180
Endophthalmitis 180

Panophthalmitis 180
Orbital Cellulitis 180
Acute Iridocyclitis 181
Acute Congestive Glaucoma 181

11. Examination of Retina 183
Fundus Examination 183
Hypertensive Retinopathy 187
Diabetic Retinopathy 188
Central Retinal Artery Occlusion 190
Branch Retinal Vein Occlusion 191
Central Retinal Vein Occlusion 192
Retinitis Pigmentosa 194
Central Serous Retinopathy 194
Cystoid Macular Edema 194
Myopia 195
Papilledema 196
Optic Neuritis 197
Optic Disk Changes in Glaucoma 198
Primary Optic Atrophy 199
Secondary Optic Atrophy 200
Consecutive Optic Atrophy 200

12. Community Ophthalmology 201
Community Ophthalmology 201
Blindness and Low Vision 201
Blindness Statistics 202
National Program for Control of Blindness 202
Vision 2020: The Right to Sight 203
District Blindness Control Society/District Health Society 203
National Trachoma Control Program 203
Xerophthalmia 203
Important Dates in Ophthalmology 204

Bibliography 207
Index 209

Chapter 4

Case Presentation

Chapter Outline

- Cataract
- Pseudophakia
- Aphakia
- Corneal Opacity
- Adult Dacryocystitis
- Chalazion
- Pterygium
- Corneal Ulcer
- Ptosis

CATARACT

Cataract is the most common cause for blindness in India accounting for 62.6% of the blindness.

Refractive error 19.7%, corneal opacity 0.9%, glaucoma 5.8% are the other leading causes in India.

Cataract is defined as opacification of lens and/or its capsule, congenital or acquired, progressive or stationary, partial or complete, with or without visual impairment.

The word cataract literally means waterfalls. The word cataract is derived from a Latin word 'cataracta' meaning waterfalls. It implies that vision of a patient with cataract is foggy as if he/she is seeing through a glass covered with water droplets and it also indicates the color of the lens in total cataract (mature cataract) is white as that of waterfalls.

Cataract is the commonest cause for avoidable blindness worldwide and in India. Cataract is responsible for 51% of worldwide blindness.

CASE PROFORMA (Box 4.1)

Box 4.1: Proforma for cataract

Biodata

Here is a male/female patient aged about.....years,.....by occupation, hailing from.....

Important Facts

Age

- Congenital cataract onset at birth
- Developmental cataract onset after birth to puberty

Contd...

JAYPEE BROTHERS

Contd...

- Presenile cataract onset after puberty before 50 years of age
- Senile cataract onset after 50 years of age.

Occupation

Total amount of annual exposure to sunlight has a direct relation to high incidence of senile cataract seen in the hot and dry areas of the world. Cataract is more common in people of rural origin.

Presenting Complaints

His presenting complaints are:

- Diminution of vision in right eye (RE)/left eye (LE)/both eyes (BE) since.....months/years
- .....

History of Presenting Illness

He/She was apparently normal.....months/years back. He/She noticed diminution of vision insidious in onset, gradually progressive in nature. Initially he/she was able to see things at.....meters, now he/she can see things at.....meters.

- Diminution of vision is (choose one among three):
  - Same for both near and distance vision
  - More for near vision
  - More for distance vision.
- Diminution of vision is (choose one among three):
  - Same in dim light and bright light
  - More in dim light
  - More in bright light.
- Diminution of vision is associated with:
  - Glare
  - Pain
  - Redness
  - Watering
  - Discharge
  - Brow ache
  - Headache.

Important Facts

Cuneiform cataract: As the cataract starts at periphery, visual disturbances are noted at a comparatively late stage. As the pupil dilates (Fig. 4.1) in dim light these patients experience more diminution of vision in dim light.

Cupuliform cataract: As the cataract starts in the center, visual disturbances are noticed at early stage. As the pupil is constricted (Fig. 4.2) in bright light, these patients experience more diminution of vision in bright or day light.

Nuclear cataract: In nuclear sclerosis, distant vision decreases and near vision improves due to index myopia. Hence such persons will be able to read without presbyopic glasses. This improvement in near vision is called second sight.

Symptoms: Glare is one of the earliest symptoms of cataract and is due to diffraction of light by lenticular opacity. Other earliest symptoms of cataract are colored halos and uniocular polyopia. Pain, redness, watering, discharge are seen in:

- Complications associated with cataract such as phacoanaphylactic uveitis, phacomorphic glaucoma and phacolytic glaucoma, etc.
- Other ocular diseases such as acute dacryocystitis and conjunctivitis, etc. when present along with cataract.

Contd...

JAYPEE BROTHERS

Contd...

Ocular History
- He/She is/was wearing spectacles for (choose one among three):
  - Near vision
  - Distance vision
  - Both.
- He/She give history of surgery/no history of surgery to RE/LE/BE
- He/She give history of trauma/no history of trauma to RE/LE/BE
- He/She history of using eyedrops for long duration/no history of using eyedrops to RE/LE/BE.

Important Facts
- Posterior subcapsular cataracts are associated with prolonged use of steroids
- Anterior subcapsular cataracts are associated with long-term use of miotics such as echothiophate and demecarium chloride
- Amiodarone, chlorpromazine and busulfan are some other drugs associated with development of cataract.

Trauma is associated with:
- Vossius ring
- Conclusion cataract
- Rosette cataract (Fig. 4.3)
- Subluxation of lens
- Dislocation of the lens.

Past History
- He/She is a known diabetic on treatment/not a known diabetic
- He/She is a known hypertensive on treatment/not a known hypertensive
- He/She is a known patient of chronic obstructive pulmonary disease (COPD), asthma, ischemic heart disease on treatment/not a known patient of COPD, asthma, ischemic heart disease
- He/She give past history of tuberculosis/no past history of tuberculosis.

Important Facts

Diabetes and Cataract

Diabetes is associated with early onset of senile cataract or with true diabetic cataract. True diabetic cataract is called snow flake cataract or snow storm cataract. When blood sugar levels are elevated above 200 mg/mL, the enzyme hexokinase is saturated and remaining glucose is converted by aldose reductase to sorbitol, which accumulates in the lens fibers and causes cataract by osmotic stress.

Other Ocular Signs in Diabetes
- Transient variation in refraction as hyperglycemia causes increased refractive index of the lens causing myopic shift and hypoglycemia causes decreased refractive index of the lens causing hypermetropic shift
- Increased incidence of:
  - Extraocular muscle paresis/paralysis
  - Stye and internal hordeolum
  - Infective keratitis
  - Vitreous hemorrhage, central retinal vein occlusion, primary open angle glaucoma and neovascular glaucoma.
- Diabetic retinopathy
- Delayed epithelial healing due to abnormality in epithelial basement membrane.

Family History
- Significant/Not significant
- His/Her father/mother/both had history of cataract/cataract surgery
- His/Her brothers/sisters had history of cataract/cataract surgery.

Contd...

JAYPEE BROTHERS

Contd...

Important Facts
- Heredity plays an important role in age of onset and maturation of senile cataract.

Personal History
- Diet
- Appetite
- Habits.

Important Facts
Deficiency of proteins, calcium, essential elements such as copper, selenium and zinc has been postulated in the development of cataract. Vitamins E and C, and riboflavin are involved in lens metabolism, by acting as antioxidants they prevent cataract formation.

Socioeconomic History
He/She belongs to:
- Upper class
- Middle class
- Lower class.

Important Facts
Cataract is more common in people of poor socioeconomic status. For management socioeconomic status plays an important role in advising the type of surgery and type of intraocular lens (IOL) considering the affordability of the patient. Surgeries in camp set-up are done free of cost. Cataract surgeries with multifocal IOL cost around ₹50,000.

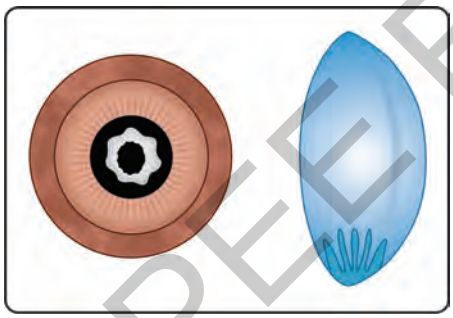

Fig. 4.1: Cuneiform cataract

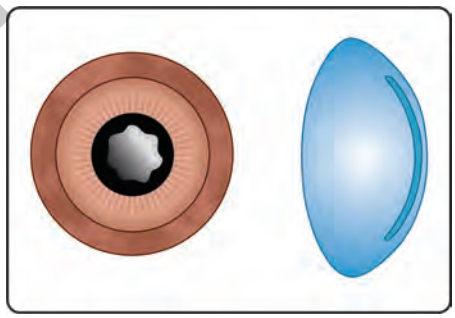

Fig. 4.2: Cupuliform cataract

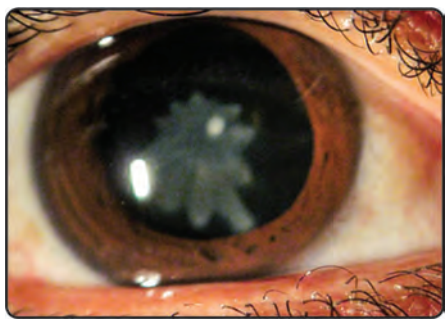

Fig. 4.3: Rosette cataract seen after blunt trauma

JAYPEE BROTHERS

CASE DISCUSSION

1. How the cataract is diagnosed?

History: Painless diminution of vision insidious in onset and gradually progressive.

On examination: Visual acuity decreased.

Immature cataract: 6/6p (p indicates person can read only a part of the 6/6) to counting fingers close to face.

Mature cataract: Hand movements, perception of light and projection of rays present.

Hypermature cataract: Perception of light and projection of rays present.

2. What are the significant features of lens in cataract?

Lens opacity

Immature cataract

- Grayish white color of the lens (Fig. 4.4)
- Iris shadow present (Fig. 4.5)
- Purkinje images—all 4 are present.

Mature cataract

- Pearly white color of the lens (Figs 4.6A and B)
- Iris shadow absent
- Purkinje images—first 3 are present.

Hypermature cataract

- Milky white color of the lens
- Iris shadow absent
- Purkinje images—first 3 are present.

Complete loss of vision, i.e. perception of light (PL) negative can never be caused by cataract. Diseases of lens or cornea can never cause PL negative unless there is a problem in retina and/or in optic nerve.

Lens anatomy

- Transparent biconvex crystalline structure
- Anterior surface—radius of curvature is 10 mm
- Posterior surface—radius of curvature is 6 mm
- Refractive index—1.39
- Total power—16 D
- Accommodation:
  - 14–16 D (at birth)
  - 7–8 D (at 25 year)
  - 1–2 D (at 50 year).

Lens transparency

Lens is transparent due to:

- Regular arrangement of lens fibers
- Presence of protective factors such as glutathione in high concentration, which protect the lens against oxidative damage
- Avascularity of lens
- Pump mechanism of lens, which maintains it in a state of relative dehydration.

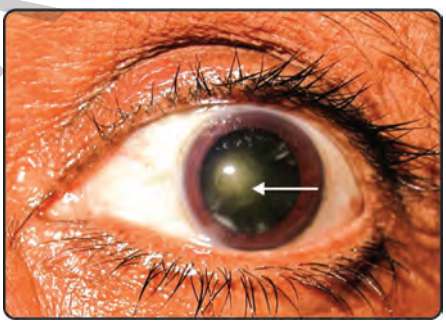

Fig. 4.4: Immature cataract (subtype—posterior subcapsular cataract, e.g. cupuliform cataract) (*Note:* Grayish white color of the lens).

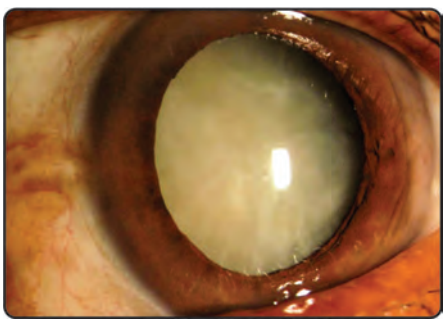

Fig. 4.5: Immature cataract (*Note:* Presence of iris shadow)

JAYPEE BROTHERS

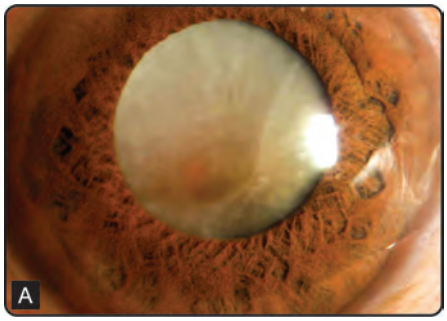

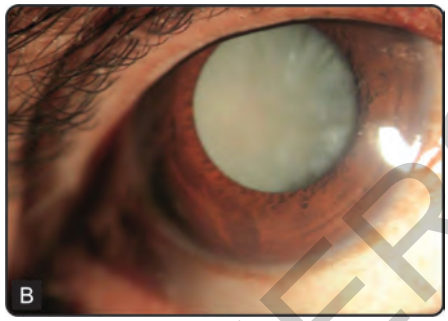

Figs 4.6A and B: Mature cataract (*Note*: Pearly white color of the lens)

3. Classify cataract.

Etiological classification

Broadly classified as congenital or developmental cataract and acquired cataract, which is again classified into:

- Senile cataract
- Metabolic cataract
- Complicated cataract
- Traumatic cataract
- Electric cataract
- Radiational cataract
- Toxic cataract
- Cataract associated with skin diseases
- Cataract associated with syndromes.

Morphological classification (Fig. 4.7)

- Capsular cataract—anterior capsular (Fig. 4.8) and posterior capsular cataract
- Subcapsular cataract—anterior subcapsular and posterior subcapsular cataract.
- Cortical cataract
- Supranuclear cataract
- Nuclear cataract
- Polar cataract—anterior polar and posterior polar cataract (Fig. 4.9).

With respect to maturity

- Incipient cataract
- Immature cataract (Figs 4.10A and B)
- Mature cataract
- Hypermature cataract.

With respect to age of onset

- Congenital cataract
- Infantile cataract
- Juvenile cataract
- Presenile cataract
- Senile cataract.

4. Define senile cataract.

Senile cataract is defined as opacification of lens because of age-related changes and characterized by absence of congenital, secondary or other specific causes.

5. Mention the stages of maturation of cataract.

- Stage of lamellar separation
- Stage of incipient cataract
- Immature cataract
- Mature cataract
- Hypermature cataract.

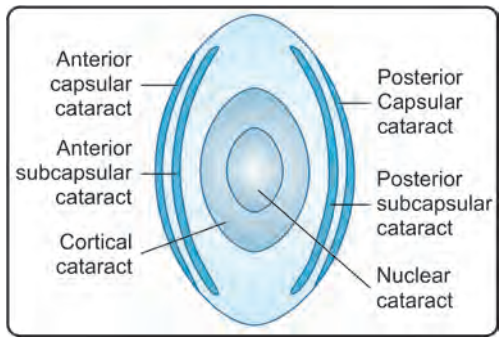

Fig. 4.7: Morphological types of cataract

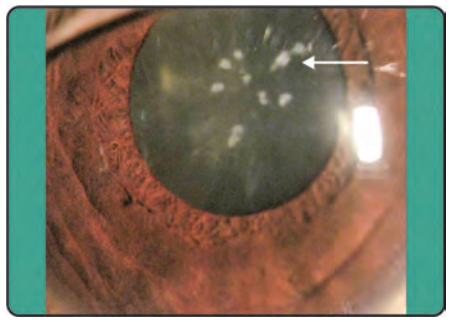

Fig. 4.8: Anterior capsular cataract (*Note:* Presence of anterior capsular opacities)

JAYPEE BROTHERS



Fig. 4.9: Posterior polar cataract (*Note:* Presence of lens opacity in the center of lens at posterior pole

6. What is intumescent cataract?

Increased hydration of lens causing the lens to become swollen is called intumescent cataract. It can occur in immature stage or in mature cataract stage.

7. What is morgagnian cataract?

A type of hypermature cataract where the cortex is liquefied and the brownish nucleus settles at the bottom.

8. What are the types of hypermature cataract?

- Morgagnian cataract (as described above)
- Sclerotic cataract in which the lens becomes shrunken due to dehydration and anterior capsule is wrinkled and thickened (Figs 4.11A and B).

9. What is complicated cataract?

Cataract, which develops secondary to intraocular disease is called complicated cataract. The causes for complicated cataract are:

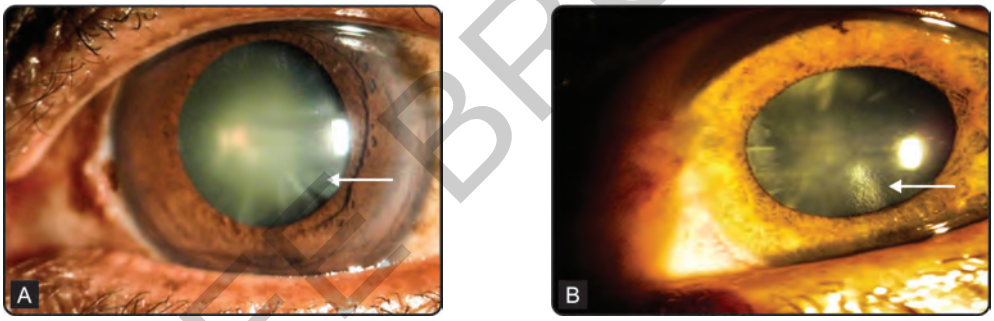

Figs 4.10A and B: **A.** Early immature cataract (subtype—cuneiform cataract); **B.** Advanced immature cataract (subtype—cuneiform cataract) (*Note:* Grayish white wedge-shaped opacities present in the periphery).

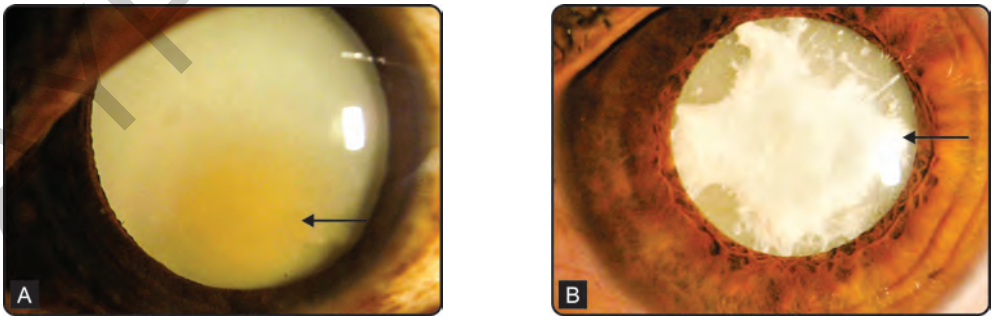

Figs 4.11A and B: Hypermature cataract. **A.** Subtype—morgagnian cataract (*Note:* Presence of milky white color of the lens with nucleus sinking at the bottom of the capsular bag of lens as indicated by brown tinge inferiorly; **B.** Subtype—sclerotic hypermature cataract (*Note:* Milky white color of the lens with calcification of anterior capsule.

JAYPEE BROTHERS

a. Inflammatory conditions of the eye such as uveitis including iridocyclitis, intermediate uveitis, choroiditis, endophthalmitis and keratitis.
b. Diseases of the retina such as long-standing retinal detachment, retinitis pigmentosa, gyrate atrophy, Leber's congenital amaurosis.
c. Glaucoma, including primary and secondary glaucomas.
d. Pathological myopia.
e. Intraocular tumors including primary tumors such as retinoblastoma, malignant melanoma and metastatic tumors.

10. What are the characteristic features of complicated cataract?

a. Complicated cataract usually begins in the posterior cortex as posterior subcapsular opacity (Fig. 4.12).
b. Breadcrumb appearance and polychromatic luster are the characteristic features of complicated cataract (Figs 4.13A and B).

11. Classify congenital cataract.

- Lamellar cataract
- Cataracta centralis pulverulenta
- Sutural cataract
- Blue dot cataract
- Anterior polar cataract
- Posterior polar cataract
- Total congenital cataract.

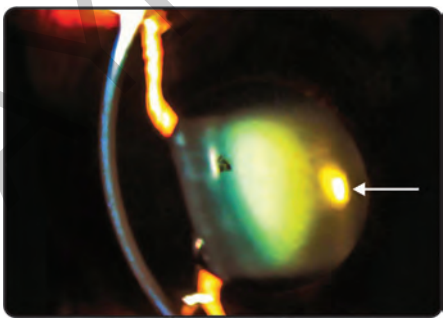

Fig. 4.12: Complicated cataract (*Note:* Presence of opacity in the center of the posterior cortex as shown in the slit-lamp section of lens.

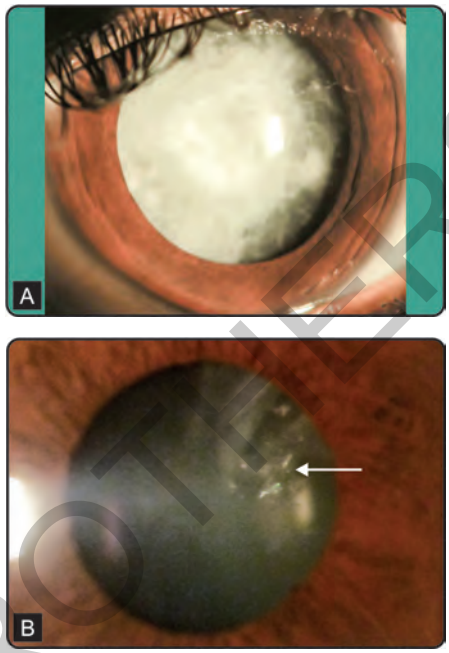

Figs 4.13A and B: Complicated cataract. **A.** Presence of yellowish, dirty, chalky white color of the lens; **B.** Polychromatic luster in a patient with complicated cataract.

12. What is the mechanism of formation of cataract?

Cortical cataract: Decreased level of proteins and amino acids with increasing age leading to increase in the permeability of lens capsule resulting in increased levels of sodium causing increased hydration. Increased hydration of the lens leads to opacification of lens fibers. The cortical cataract is because of overhydration and the cortical cataract is called soft cataract.

Nuclear cataract: Nuclear cataract is because of dehydration and it is called hard cataract. The mechanism of formation of nuclear cataract is from dehydration leading to increase in water-insoluble proteins and compaction of nucleus. Nuclear cataract may be associated with deposition of urochrome or melanin derived from the amino acids.

JAYPEE BROTHERS

13. What is nuclear cataract?

Cataract, which occurs as a result of age-related sclerosis is called nuclear cataract. Nuclear cataract can be:

- Cataracta brunescens (brown cataract)
- Cataracta rubra (red cataract)
- Cataracta nigra (black cataract).

14. What is nuclear sclerosis?

Nuclear sclerosis is the hardness of the nucleus. It is found in both cortical and nuclear cataracts and in immature or mature cataract. Nuclear sclerosis can be graded by examining the color and size of the lens after dilatation of the pupil.

15. How do you grade nuclear sclerosis (Figs 4.14A to C)?

- Grade I—grayish yellow
- Grade II—grayish orange
- Grade III—grayish brown
- Grade IV—black.

16. What is second sight?

Improvement in near vision in patients with nuclear sclerosis due to progressive index myopia is called second sight. This is because of neutralization of the 'plus' power of presbyopia by the 'minus' power of myopia, which is because of index myopia as a result of increase in the refractive index of the lens caused by nuclear sclerosis.

17. What is Iris shadow?

Crescenteric shadow of pupillary margin of iris formed on the grayish opacity of the lens when an oblique beam of light is thrown on the pupil is called iris shadow. When lens is completely transparent or opaque, no iris shadow is formed. Hence, iris shadow is a sign of immature cataract (Figs 4.15A and B).

18. Why Iris shadow is seen?

For shadow to form this requirement is the transparent media, which allows light and opaque media, which acts as a screen on which the image is formed. This requirement is fulfilled only in immature cataract.

In immature cataract, there is a clear lens between the iris and the lens opacity, thus iris shadow is formed in immature cataract.

Normally, lens is completely transparent in mature and the hypermature cataract lens is completely opaque. Hence, iris shadow is not seen in these two conditions and seen only in immature cataract in which lens is partly transparent and partly opaque.

19. Name retinal and macular function tests.

Retinal function tests

Projection of rays

The patient is asked to identify the direction of light from which light is coming while projecting light from various directions. Each

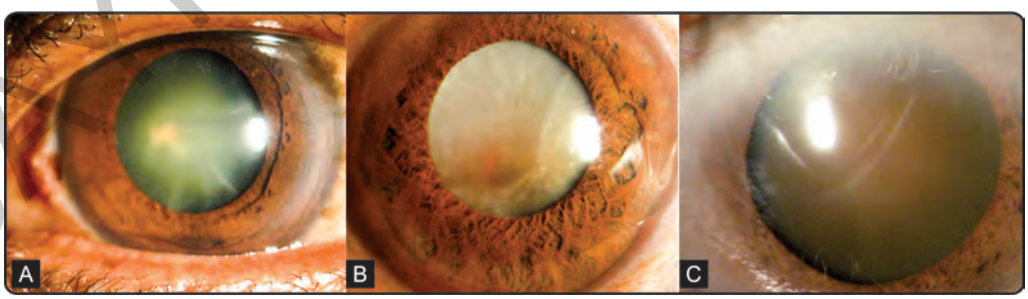

Figs 4.14A to C: Grading of nuclear sclerosis. **A.** Yellowish color in the center (in nucleus)—grade I nuclear sclerosis; **B.** Orange color in the center (in nucleus)—grade II nuclear sclerosis; **C.** Brown color in the center (in nucleus)—grade III nuclear sclerosis (cataracta brunescens).

JAYPEE BROTHERS

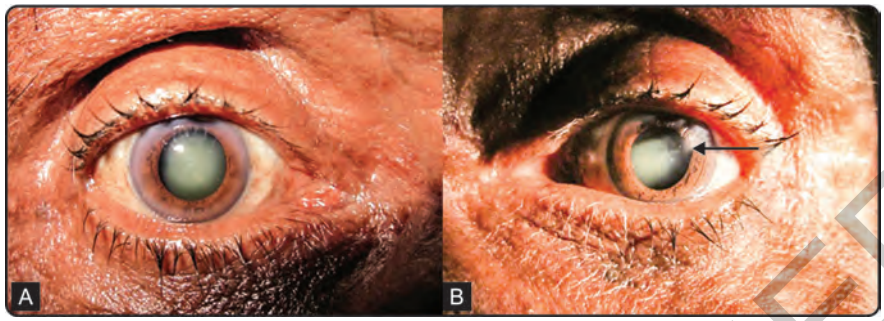

Figs 4.15A and B: Demonstration of iris shadow. **A.** Front view; **B.** Presence of crescentic shadow of the iris on the temporal side when light is directed on the eye from temporal side.

eye is tested separately with the other eye being closed. If the patient can identify the direction from which the light is coming, it indicates good retinal function. Usually projection of rays is tested in the four quadrants to check for the retinal function in the four quadrants of retina:

a. Entoptic visualization: It is done by placing a point source of light against the closed eyelids and asking the patient if he/she can perceive the retinal vascular pattern. The presence of entoptic visualization indicates good retinal function.
b. Test for Marcus Gunn pupillary response, presence of Marcus Gunn pupil indicates afferent pathway defect.
c. B-scan: To detect anatomical state of retina and vitreous.
d. Electroretinogram.
e. Electrooculogram.
f. Visual evoked potential.

Macular function tests

a. Cardboard test (two point discrimination test): Patient is asked to see through a cardboard with two holes close to each other with light behind the holes if two lights are appreciated. It indicates good macular function.
b. Maddox rod test: Patient is asked to look through a maddox rod at a bright light. If the patient sees continuous, unbroken and undistorted red line it indicates that the macula is normal; if the line is broken, it indicates diseases of macula.
c. Amsler grid test: It can be used in eyes with better vision. Patient is asked to close one eye and to see at Amsler chart with the other eye holding at normal reading distance. Patient is asked to look for any distortion in the grid while looking at the central fixing dot; when present, distortion indicates macular pathology. The test is repeated with the other eye.
d. Laser interferometry: It is done by laser interferometer—an instrument used to detect visual acuity in the presence of opaque media.
e. Potential acuity meter: It is done by projecting a slit-lamp miniature Snellen's chart into the eye and the macular function can be judged by lines read by the patient.

20. How do you calculate IOL power?

Calculation of IOL power

Without biometry

a. Using standard power +19 D.
b. Based on basic refraction (refractive error present prior to the onset of cataract):

$$P = +19\ D + (1.25\ R)$$

where,

P = Implant power
R = Basic refractive error.

Contd...

JAYPEE BROTHERS

Contd...

With biometry

a. Using regression formulae:
   - SRK-I, SRK-II, SRK-T, modified SRK-II, holladay, etc. [*Note:* SRK formulae are most commonly used (SRK stands for 'Sanders-Retzlaff-Kraff')]:
     P = A – 2.5L – 0.9K

   where,
   P = Implant power
   A = Constant
   L = axial length
   K = corneal power in diopters (D).
   - Value of A:
     - For posterior chamber IOL: 118.2 (value of constant varies with the type of lens)
     - For anterior chamber IOL: 114.

21. What is presenile cataract?

Cataract formation because of age-related changes in people aged less than 50 years is called presenile cataract. In all cases of presenile cataract, other causes for cataract have to be ruled out, i.e. trauma, metabolic diseases such as diabetes, intraocular diseases causing complicated cataract, drug intake such as corticosteroids and other drugs causing cataract and skin diseases causing cataract (Table 4.1).

Table 4.1: Some specific type of cataracts and their causes

Types	Causes
Snowflake cataract	Diabetic cataract
Oil droplet cataract	Galactosemic cataract
Sunflower cataract	Inborn errors of copper metabolism, e.g. Wilson's disease
Glass-blower's cataract	Prolonged exposure to heat
Toxic cataract	Long-term use of steroids and miotics such as echothiophate and demecarium bromide
Syndermatotic cataract	Cataract with skin diseases

22. What is the work up for a patient with cataract posted for cataract surgery?

Diagnosis of cataract

History: Diminution of vision insidious in onset and gradually progressive.

On examination

Decrease in visual acuity varying according to the stage of cataract:

a. In immature cataract—6/6 parts to counting fingers close to face (6/6 parts—cannot read complete letters in 6/6, can read only a part of it.
b. In mature cataract—hand movements, perception of light and projection of rays.
c. In hypermature cataract—perception of light and projection of rays.

Presence of lens opacity

a. Grayish white opacity and iris shadow present—immature cataract.
b. Pearly white opacity—mature cataract.
c. Milky white opacity—hypermature cataract.

Eye has got two refractive structures—cornea and lens, which project light rays onto the retina, which travel via optic nerve to the visual sensory area in the occipital lobe.

Diminution of vision should have problem in one of these structures or there can be a problem in all three or two structures at the same time.

Confirm diagnosis and exclude other associated causes for diminution of vision. Slit-lamp examination/anterior segment examination to rule out corneal disorders such as dystrophies and degenerations; pterygium encroaching the pupillary area.

Retinoscopy to rule out refractive error

Ophthalmoscopic examination of retina (fundoscopy), to look for retinal pathologies such as age-related macular degeneration, chorioretinal degeneration and optic atrophy.

JAYPEE BROTHERS

Systemic investigations to confirm fitness of the patient for surgery

a. Urine sugar/random blood sugar (RBS) to rule out diabetes mellitus. If the patient is known diabetic, fasting and postprandial blood sugar (FBS and PPBS) has to be done.
b. Blood pressure measurement to rule out hypertension.
c. Electrocardiography (ECG) to know the cardiac status.
d. If the patient is known to have chronic disorders such as COPD and IHD, they have to be controlled before posting the patient for surgery.
e. HIV and HBsAg to take safety precautions if the patient is seropositive.
f. Rule out any potential source of infection such as infected abscess and open infected wound, which may act as a foci for development of endophthalmitis.

Ocular investigations

a. Rule out any ocular infections/inflammatory diseases such as conjunctivitis, stye, chronic dacryocystitis/active uveitis.
b. Lacrimal syringing to rule out chronic dacryocystitis.
c. Retinal and macular function tests to know visual prognosis.
d. Biometry for calculation of IOL power, which includes keratometry and A-scan.
e. Xylocaine test dose to rule out hypersensitivity to xylocaine.

To summarize

Systemic

- Urine sugar/RBS
- Blood pressure
- Electrocardiography
- Human immunodeficiency virus
- Hepatitis B surface antigen
- Evaluation of any chronic disorder and treating it appropriately
- Rule out any septic foci of infection anywhere in the body.

Ocular

- Measurement of intraocular tension
- Lacrimal syringing
- Retinal and macular function tests
- Biometry.

23. What are the differential diagnoses for immature cataract?

Immature cataract has to be differentiated from nuclear sclerosis (Table 4.2).

24. What are the differential diagnoses of mature cataract and hypermature cataract?

Mature and hypermature cataracts have to be differentiated by pseudoglioma (Table 4.3).

Table 4.2: Differences between immature cataract and nuclear sclerosis

Clinical features	Immature cataract	Nuclear sclerosis
Vision	Diminution of vision, painless and progressive in nature No improvement with pinhole	Diminution of vision, painless and progressive in nature Improvement with pinhole
Anterior segment examination	Grayish white color of the lens, iris shadow present	Grayish color of the lens (color varies according to the grade of nuclear sclerosis), iris shadow absent
Distant direct ophthalmoscopy	Black spots against red background	Only red glow is seen

JAYPEE BROTHERS

for detailed information on ophthalmology books, visit our website **www.jaypeebrothers.com**, for detailed inform

Clinical Methods in OPHTHALMOLOGY

A Practical Manual for Medical Students

Salient Features

- Comprehensive review for undergraduates and quick review for postgraduates.
- History taking with clinically structured questionnaire for each case.
- Detailed case discussion with explanation of clinical problems.
- Comprehensive coverage with emphasis on clinical application.
- A straightforward and easy-to-use guide for the students of Ophthalmology course to grasp key information quickly and prepare for examinations effectively.



Dadapeer K MS DNB (Ophthalmology) is Associate Professor, Department of Ophthalmology, Hassan Institute of Medical Sciences, Hassan, Karnataka, India. He completed his basic education from Sri Vasavi Vidya Samsthe and Government Science College, Chitradurga, Karnataka, MBBS from Sri Siddhartha Medical College, Tumakuru, Karnataka (1998-2003), MS (Ophthalmology) from Minto Ophthalmic Hospital, Regional Institute of Ophthalmology, Bangalore Medical College and Research Institute, Bengaluru, Karnataka (2004-2007) and DNB (Ophthalmology) in May 2008. He has done training in keratoplasty and corneal transplantation, and in oculoplasty surgeries. He has undergone short-term fellowships in Small Incision Cataract Surgery, Phacoemulsification Cataract Surgery and also in Medical Retina and Lasers in Diabetic Retinopathy.

Dadapeer has worked as Assistant Professor, Department of Ophthalmology, PES Institute of Medical Sciences and Research, Chittoor, Andhra Pradesh, India, and Consultant in Ophthalmology at The Eye Foundation, Coimbatore and Tiruppur, Tamil Nadu, India. He is a Life Member of Karnataka Ophthalmic Society and All India Ophthalmic Society. He has presented five papers/posters in state/national/international conferences, and has seven original articles/publications in state/national journals. He is honored with Dr TK Ramesh Award for Best Poster at Karnataka Ophthalmic Society 23rd State Conference at Ballari, Karnataka, India.

Available at all medical bookstores
or buy online at www.jaypeebrothers.com



JAYPEE BROTHERS
Medical Publishers (P) Ltd.
www.jaypeebrothers.com

Join us on facebook.com/JaypeeMedicalPublishers

Shelving Recommendation
OPHTHALMOLOGY

