rothers.com, for detailed information of dermatology books, visit our website www.jaypeebrothers.com, for detailed information of dermatology boo



Aesthetic Series

Aesthetic Series

HAIR TRANSPLANTATION

Editors
Nicole Rogers
Meena K Singh
Shannon Watkins

Series Editor
Marc R Avram

JAYPEE

Contents

1. The Consult **1**
Meena K Singh
- Candidate Selection *1*

2. Preoperative and Postoperative Instructions for Hair Transplant Surgery **9**
Shannon Watkins, Marc R Avram
- Preoperative Workup *9*
- Anticoagulants *9*
- Prophylactic Antibiotics *10*
- Preoperative Instructions for Hair Transplant Surgery *11*
- Postoperative Instructions for Hair Transplant Surgery *12*
- Postoperative Wound Care *14*

3. Donor Harvesting in Hair Transplantation **15**
Shannon Watkins
- A Brief History of Donor Harvesting *15*
- Ideal Location for Donor Harvesting *15*
- Preparation for Donor Harvesting *16*
- Anesthesia for Donor Harvesting *16*
- Elliptical Donor Strip Harvesting *17*
- Processing of the Ellipse into Follicular Units *19*
- Follicular Unit Extraction *19*
- Manual FUE *19*
- Robotic System *21*
- Wound Care after Donor Harvesting *22*

4. Hairline Design/Holding Solutions/Graft Creation **24**
Francisco Jimenez-Acosta
- Hairline Design *24*
- Holding Solutions *27*
- Graft Creation *29*

5. Anesthesia and Instrumentation **31**
Shannon Watkins
- Systemic Anesthetics and General Considerations *31*
- Anesthesia for Hair Transplantation *31*
- Instrumentation for Hair Transplant Surgery *36*

6. Female Hair Transplant Surgery **44**
Robin Unger
- Consultation *44*
- Surgical Plan *45*
- Preoperative Directions and Lab Tests *48*
- Anesthesia *48*
- Donor Harvest *49*
- Recipient Site Creation and Graft Sizes *50*
- Special Considerations and Techniques *52*
- Postoperative Care *53*

7. Corrective Hair Transplantation **56**
Nicole Rogers, Craig Ziering
- History *56*
- Consultation *56*
- Correction of Recipient Area Grafting *57*
- Correction of Donor Area *60*

8. Hair Transplant for the Treatment of Scarring Alopecias **63**
Meena K Singh
- Background *63*
- Initial Evaluation *63*
- Histopathologic Examination *64*
- Primary Cicatricial (Scarring) Alopecia *65*
- Classification of the Primary Cicatricial Alopecias *65*
- Lymphocytic Perifollicular Inflammation *65*
- Central Centrifugal Cicatricial Alopecia (Further Discussed in HT in Blacks Chapter 9) *65*
- Neutrophilic Perifollicular Infiltrates *67*
- Mixed Neutrophilic and Lymphocytic Perifollicular Inflammation *68*
- Secondary Cicatricial Alopecias *68*
- Postsurgical Alopecia *68*
- Technical Considerations for Hair Transplantation in Cicatricial Alopecia *69*
- Donor Area *70*
- Donor Harvesting *71*
- Recipient Area *71*
- Scalp Thickness and Fibrosis *71*
- Other Considerations *71*

9. Hair Transplantation in Blacks **74**
Duane Dilworth, Meena K Singh
- Candidate Selection *74*
- Donor Area *77*
- Hairline Design *77*
- Key Concepts for Hair Transplantation in Blacks *77*

10. Medications Used in Hair Transplantation **80**
Duane Dilworth, Meena K Singh
- Minoxidil *80*
- Finasteride *80*
- Dutasteride *81*
- Ketoconazole *81*
- Spironolactone *81*
- Platelet-Rich Plasma *81*
- Low-Level Light Laser Therapy *82*

11. Future Trends in Hair Transplant Surgery **83**
Carlos K Wesley
- Low-Level Light Therapy *83*
- Bioenhanced Hair Restoration: Scalp Mesotherapy *85*
- Robotic Technology *88*
- Holding Solutions *91*
- Piloscopy *91*
- Cell Therapy/Cloning *94*

Index *99*

CHAPTER

3

Donor Harvesting in Hair Transplantation

Shannon Watkins

JAYPEE BROTHERS

The quantity of donor hair is the limiting factor in hair transplantation surgery. This will likely remain true until hair can be cloned. Therefore, efficiency in donor harvesting is essential to avoid wasting a limited donor supply.

Hair transplantation is based on the concept of donor dominance suggested by Orentreich in 1959, which is the concept that hair retains the genetic makeup of the donor site, even after being transplanted.[1,2] This is important because in male- and female pattern hair loss, hair tends to be lost primarily from the top of the scalp (frontal, parietal, and vertex scalp) and retained in the posterior scalp. Donor dominance allows for hairs to be taken from the posterior scalp, where hairs will often remain for the duration of a patient's life, and placed on the top of scalp where they will last for many years. If a patient's posterior scalp hair is genetically determined to thin over time, it will thin whether it is in the posterior scalp or transplanted to the frontal scalp.[3]

There are many important aspects of donor harvesting in hair transplantation surgery. We discuss the various methods and techniques of donor harvesting in following sections.

A BRIEF HISTORY OF DONOR HARVESTING

From the 1960s to the mid-1990s, 3–4 mm punch biopsies were the standard method utilized to harvest hairs for transplantation. This technique was inefficient and labor intensive and created extensive scarring.[4] In the 1990s, elliptical donor strip harvesting became the standard method for harvesting hair from the posterior scalp and is still a popular method of donor harvesting today.[4,5] Starting in the early 2000s, follicular unit extraction (FUE) gained popularity as a method of harvesting hairs in their natural groupings of one to three hairs for use in hair transplantation. Follicular unit extraction is minimally invasive and offers the advantage of avoiding a linear scar on the posterior scalp, which is inevitable with elliptical donor harvesting. We will review in further detail elliptical donor strip harvesting and FUE, as these are the primary methods used for donor harvesting today.

IDEAL LOCATION FOR DONOR HARVESTING

One of the most important factors in hair transplantation is harvesting donor hair from a site that will not fall prey to ongoing hair loss. A safe donor area is one that is expected to be covered with hair for the lifetime of an individual, and therefore provide lasting coverage when transplanted.[2]

The "safe" donor area has three significant boundaries. The anterior boundary is thought to be vertically superior to the external acoustic meatus (Fig. 3.1A). The superior boundary is located 1–2 cm above the horizontal plane connecting the upper border of the helical rims. The inferior border is the occipital protuberance; as the inferior margin of the hairline may move upward with the progression of male and female hair loss (Fig. 3.1B).[2,3,6,7] One article by Park et al. suggests that the location of the parietal whorl may also be used to estimate the eventual progression of vertex alopecia. Based on a survey of 1,008 Korean males, they estimate that alopecia mostly progresses within 6 cm of the parietal whorl on the

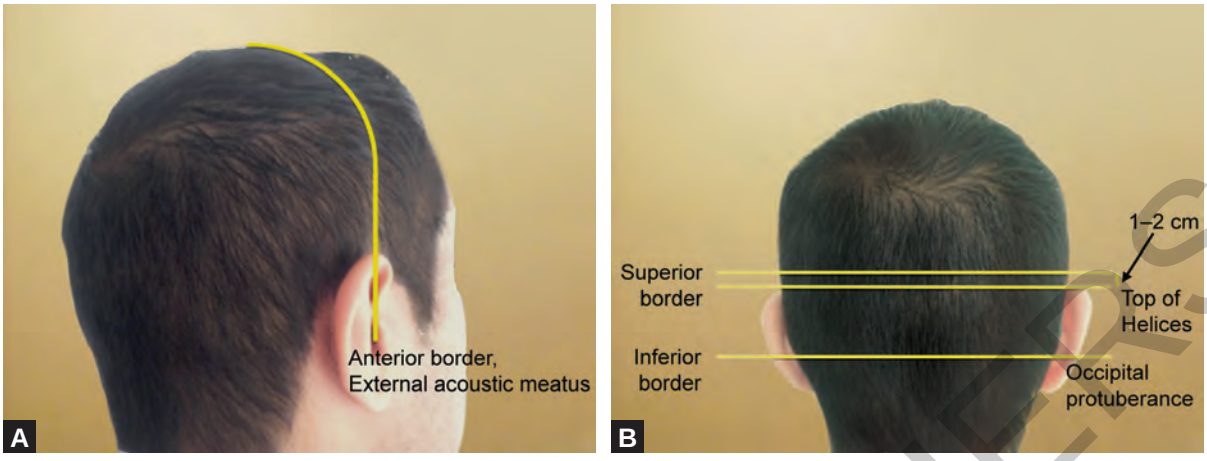

Figs. 3.1A and B: (A) Safe donor area, anterior border. Determined by line drawn vertically from external acoustic meatus. (B) Safe donor area, superior and inferior border. Inferior border determined by location of the occipital protuberance. Superior border is 1–2 cm above a horizontal line drawn from the top of the ear helices.

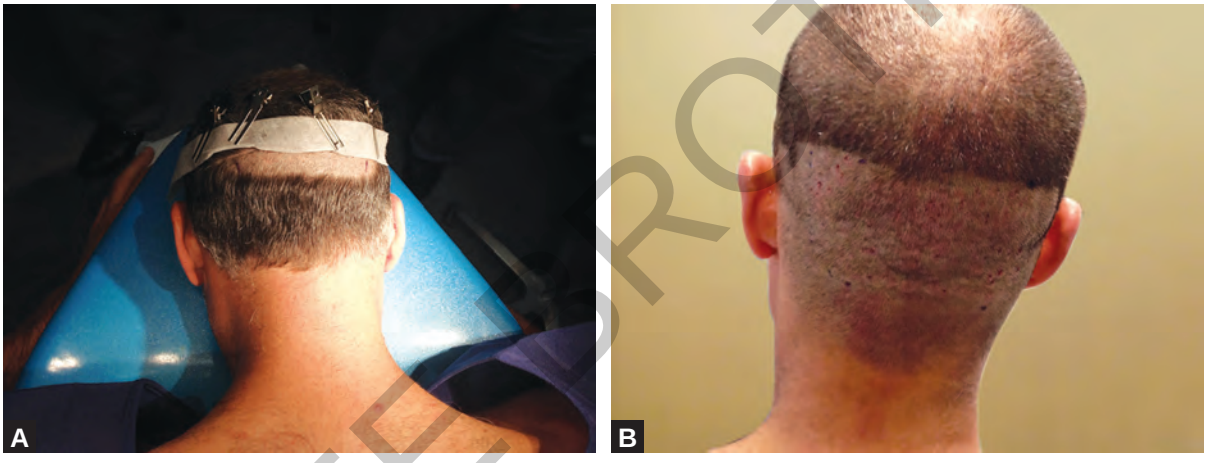

Figs. 3.2A and B: (A) Donor site for strip harvesting. (A) Donor site for follicular unit extraction (FUE) harvesting. Note the larger shaved area necessary for FUE harvesting.

occipital side. Therefore, the safe zone for donor harvesting may vary based on the location of a patient's parietal whorl. This 6 cm measurement may vary in Caucasians and other races, given their different facial structure; so before this becomes a clinical tool, further studies are needed.[2]

PREPARATION FOR DONOR HARVESTING

For patients undergoing elliptical donor strip harvesting, we recommend they wear their hair at least 2–3 cm long on the posterior scalp so that their hair will camouflage the sutures or staples placed during the procedure. The donor region is trimmed 2–3 mm long with a moustache trimmer (Fig. 3.2A).

For patients undergoing FUE, we encourage them to shave the hair on their posterior scalp short. The day of the procedure, a mustache trimmer is used to trim a larger donor area on the posterior scalp to a length of 1 mm (Fig. 3.2B). This area is typically too large to be concealed by longer hairs as with the elliptical donor strip harvesting. A few days after the procedure, once surgical sites have healed we instruct them to visit their barber to fade or blend the edges.

We harvest donor hair while patients are in a prone position. This allows for better visibility and stability. It also decreases the incidence of vasovagal episodes while harvesting.[3]

ANESTHESIA FOR DONOR HARVESTING

Briefly, the donor area is anesthetized with 1% lidocaine with epinephrine 1:100,000. Saline (10–30 mL) is then added for increased turgor to assist with

JAYPEE BROTHERS

anesthesia, hemostasis, and reduce hair follicle transection during harvesting. Anesthesia and instrumentation will be discussed in more detail in Chapter 5.[3]

ELLIPTICAL DONOR STRIP HARVESTING

In elliptical donor strip harvesting, a scalpel is utilized to excise a donor ellipse from the posterior scalp. This technique maximizes the amount of hair harvested while minimizing scarring. The elliptical excision can be performed using a single-blade or a double-blade knife with spacers in between (Fig. 3.3). It can also be performed utilizing the donor dissection technique, a process by which excellent hemostasis is maintained so hair follicles are directly visualized during the harvesting process, which minimizes the transection rate. A series of 50 hair transplant patients where the donor dissection technique was utilized resulted in a 1.9% transection rate during the harvesting process.[8] We utilize skin hooks on both sides of the ellipse for optimal visibility (Fig. 3.4A). The incision should be below the follicle bulbs into the subcutaneous tissue to minimize transection of hair follicles. The ellipse is removed just below the bulbs with scissors or a scalpel (Fig. 3.4B).[3]

In general, donor strips should not be >1 cm wide, as strips >1 cm in width have a greater risk of poor healing, hypertrophic scars, and widened scars. The length of the donor ellipse depends on the number of grafts needed for the surgery. In general, the average patient has 65–85 follicular groupings per square centimeter and the length of the elliptical excision can be calculated based on the average density of the donor area and number of hairs needed for the surgery.[4,9] *See* Table 3.1 for a guide to predict donor strip size based on the available donor density.[3]

Once the strip is harvested, the donor region must be repaired with staples or sutures (Fig. 3.5). A two-layered closure is typically not needed, but may be used when the site is under tension. Some transplant surgeons use a closure technique known as "trichophytic closure", where a narrow rim of epidermis on the inferior border of the ellipse is removed so the underlying hairs grow directly into and better conceal the scar. This may improve the appearance of the scar but may also result in slightly higher rates of cyst or ingrown hair formation.[3] Once the suturing or stapling is complete, a temporary dressing of Aquaphor, a nonstick dressing such as Tefla, and an elastic bandage is used to create a pressure dressing (Figs. 3.6A and B). A winter beanie or a summer scarf is then placed, and stays on the patient's head until the next day.

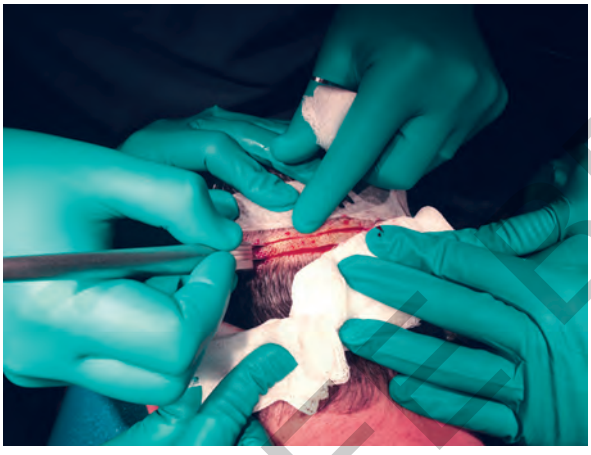

Fig. 3.3: Elliptical donor strip harvesting with a double-blade knife with spacer.

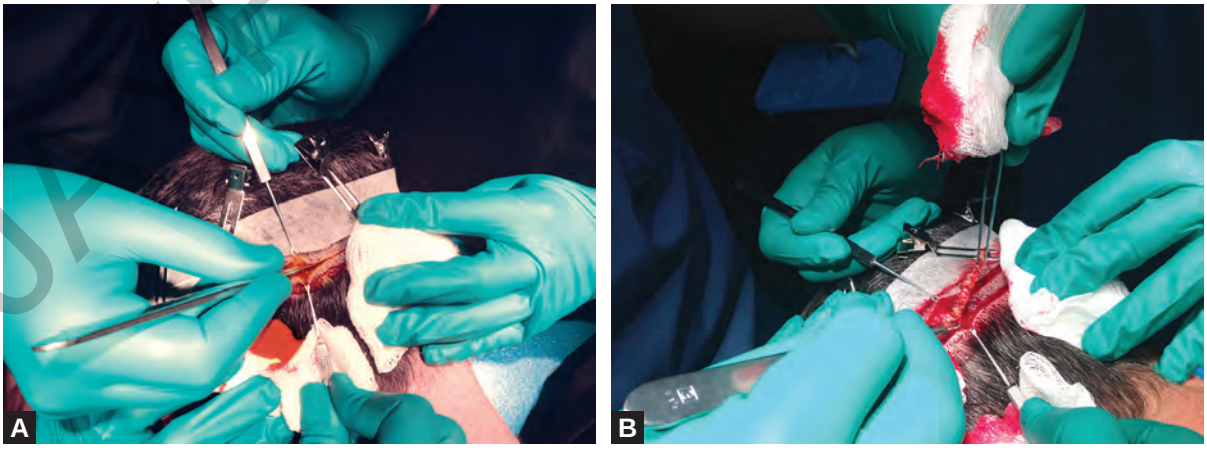

Figs. 3.4A and B: (A) Skin hooks to maximize visibility. (B) Removing ellipse just below bulbs to minimize transection.

JAYPEE BROTHERS

Key points to emphasize to the patient include: that after elliptical donor harvesting, there is no change in the perceived density of hair in the donor region, a permanent linear scar will be visible in the posterior scalp if the hair is shaved or closely cut (Fig. 3.7), there is a limited amount of donor hair, and that transplanted hair from the donor area will grow for as long as it is generically programmed to grow once transplanted (for most patients this is lifelong).[3]

Table 3.1: Predicting donor strip size based on donor density.

Donor density (follicular units per cm²)	*Strip size required to harvest 1,000 follicular units*
Above average > 85	12 × 0.8 cm
Average 65–85	15 × 0.8 cm
Below average < 50	22 × 0.8 cm

Source: Adapted from Avram M, Rogers N. Contemporary hair transplantation. Dermatol Surg. 2009;35(11):1705-19.

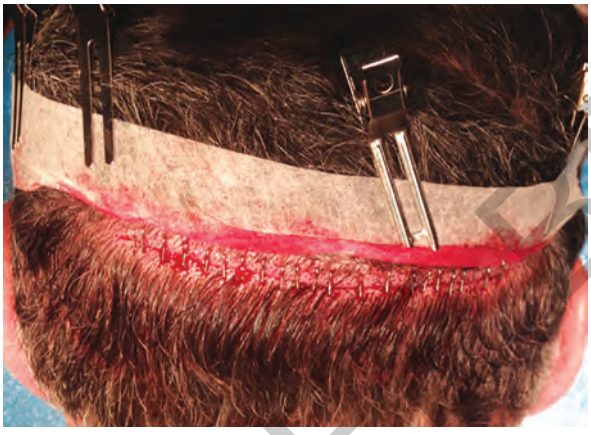

Fig. 3.5: Donor region repaired with staples.

Due to stretching of the scalp, it is thought that at least two to three elliptical separate excisions of 1 cm in width can be taken from the posterior scalp without difficulty with closure. In general, the maximum width of elliptical donor harvesting is determined by the amount of scalp laxity present in a patient. Depending on donor laxity, a safe strip width is generally 10–25 mm.[10] There are many ways to predict donor site laxity. One method is to squeeze the scalp between your fingers. This is a subjective test and relies on experience, but for an experienced surgeon, it is often quite reliable.[10] In general, lateral donor areas have less laxity, afford less camouflage, and yield few grafts.

There is also formula developed by Mayer and Pauls that can be used to determine scalp elasticity. With this method, a 50 mm line is marked on the occipital donor area, and the borders are squeezed together along the horizontal axis. The formula is:

Scalp elasticity = (50 mm – x) (100%)/50 mm, where x is the length of the compressed skin segment in millimeter.

Mayer and Pauls[11] used this formula to determine scalp elasticity in 400 patients. They found the range of scalp elasticity in these patients was between 10% and 45%, with an average of 24%. They concluded that a 10% elasticity represented a tight scalp and a 45% elasticity represented a very elastic scalp. They suggested that scalps with low elasticity (10% elasticity) may yield a 5 mm strip, a scalp with average elasticity (24%) may yield a 12 mm strip, and a very loose scalp (45% elasticity) may yield a 22.5 mm strip.[10,11]



Figs. 3.6A and B: Pressure bandage. (A) Aquaphor and Telfa covering donor site. (B) Elastic pressure bandage.

JAYPEE BROTHERS



Fig. 3.7: Linear scar after elliptical donor harvesting.



Fig. 3.8: Slivering of the strip.

Some hair transplant surgeons also feel that preoperative scalp massage can be used to increase scalp laxity. The results vary, but patients can be instructed to massage the scalp in a vertical fashion for 3–5 minutes multiple time during the day for 2–4 weeks prior to the procedure.[10]

PROCESSING OF THE ELLIPSE INTO FOLLICULAR UNITS

After the donor strip is removed, it takes about 45–60 minutes for three to four experienced assistants to process the strip into 1,000–1,5000 follicular units.[4] First, the strip is divided into slivers, much like slicing a loaf of bread (Fig. 3.8). Then, each sliver is divided into individual follicular units of one to four hair grafts, depending on their natural groupings in the scalp (Fig. 3.9). Microscopes are often used for increased precision. The technique of donor dissection with direct visualization of hair follicles is also often used to decrease transection rates during the graft cutting process. A paper by Pathomvanich reports the transection rate during graft cutting was reduced to 1.2% using the donor dissection technique.[8]

FOLLICULAR UNIT EXTRACTION

The concept of FUE was introduced in the early 21st century and has been refined over the past decade. There are many devices designed for FUE. They range from manual to powered, sharp and dull devices. We will briefly review some of the more common devices used for FUE in the following section.

The main advantage of over traditional elliptical excision is the absence of a linear scar. Follicular unit extraction is also less invasive than traditional donor strip excision, and has less downtime involved in the recovery process. If the donor area is overharvested by FUE, however, it is possible that the donor site can have a moth-eaten or pseudosyphilitic appearance. *See* Table 3.2 for a comparison of standard ellipse versus FUE donor harvesting.[3,12]

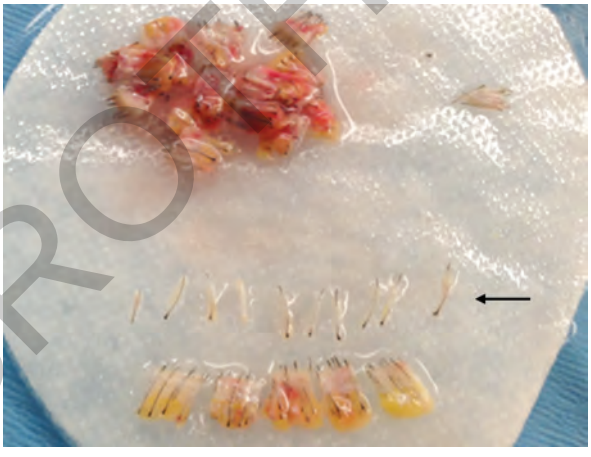

Fig. 3.9: Follicular units obtained via elliptical donor harvesting (arrow). Above and below, the slivers are pictured.

MANUAL FUE

Rassman et al. described a technique of manual FUE known as the Fox Procedure, utilizing a 1 mm punch biopsy placed directly over an individual follicular unit, following the angle of emerging hairs, until the punch is passed partially through the dermis. Once the initial advancement is made, the bulk of the follicle is pulled with forceps, extracting the follicular unit from the scalp. They also describe the Fox Test, which can be used to determine which patients are good

JAYPEE BROTHERS

Table 3.2: A comparison of standard ellipse to FUE harvesting.

	Standard ellipse	*Follicular unit extraction*
Scarring	Linear scar	No linear scar
Time to harvest grafts	10–20 minutes for 300–2,000	Manual FUE 1 hour: 100–200 grafts (operator dependent) Powered FUE: Operator and device dependent ARTAS robotic FUE 45–60 minutes: 300–600 grafts 60–120 minutes: 600–1,200 grafts
Healing time	7–10 days	3–5 days
Cost	Minimal	Manual FUE: Minimal Powered FUE: Device dependent ARTAS robotic FUE: Significant to purchase machine and per surgery fee
Transection rate	Low with experienced team Widely variable with inexperienced team	Manual FUE: Operator dependent Powered FUE: Operator dependent ARTAS robotic FUE: Low to low-moderate
Physician skill	Standard skin excision techniques	Manual and powered FUE: Technically demanding, operator dependent ARTAS robotic FUE: Knowledge of software program and robot
Technician skill	Skilled technician mandatory to create follicular units with low transection	Skilled technician needed to remove grafts from scalp and assess quality under magnification before placing in recipient site
Reliability	Technician + physician dependent	Manual FUE: Technician + physician dependent Powered and ARTAS robotic FUE: Technician + physician + robot dependent
Area of donor site shaved	1.5 cm × 8–10 cm	4–8 cm × 10–20 cm

(FUE: Follicular unit extraction).
Source: Adapted from Avram MR, Watkins SA. Robotic follicular unit extraction in hair transplantation. Dermatol Surg. 2014;4(12):1319-27.

candidates for the procedure. In the Fox Test, at least five follicular units are extracted from the back of the scalp using the FOX Procedure. The extracted grafts are examined under a microscope for their integrity and/or sent for histologic examination. Then a score of 1–5 is given to the patient that predicts whether or not the patient is a good candidate for manual FUE. A score of 1 was assigned if all the follicular units extracted were intact, a score of 2 was assigned to those patients who had all grafts with most of the anatomy intact, but a loss of fat around the lower part of the follicle or some degree of amputation in <20% of the follicular units, and a score of 4 was given when most of the surrounding fat was avulsed with a significant number of follicles amputated, a score of 5 reflected significant damage in all of the grafts. Patients who scored a 1 or 2 in the Fox Test were considered good candidates for the procedure, class 3 were neutral, and class 4 or 5 were not considered candidates for the Fox Procedure.[13] Figure 3.10 shows an example of a manual and a motorized FUE device.

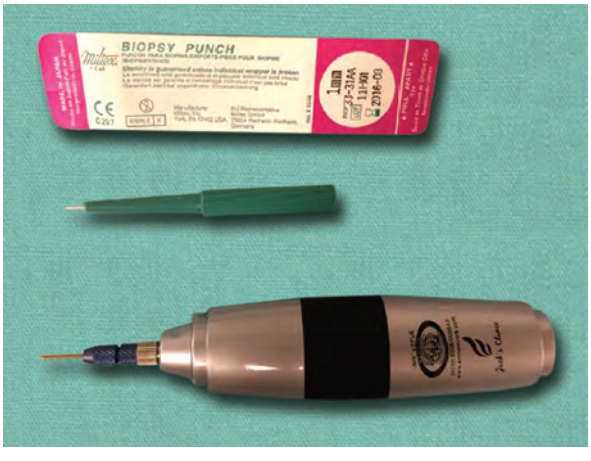

Fig. 3.10: A manual and motorized follicular unit extraction (FUE) device. Motorized FUE device pictured at bottom.

Powered Manual FUE Devices

There are several motorized FUE devices on the market. We will discuss two of the most well-known devices below, the SAFE system and the Neograft.

JAYPEE BROTHERS

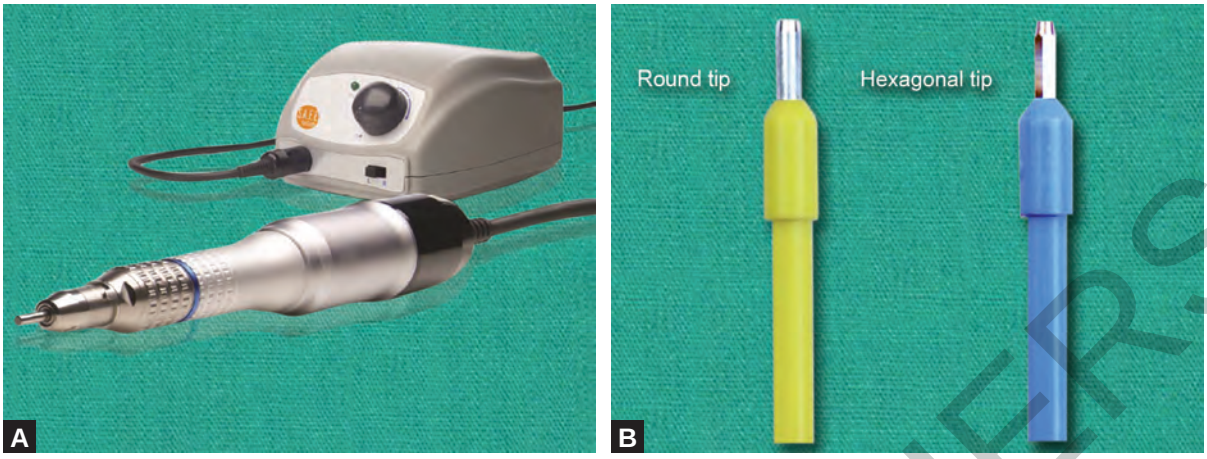

Figs. 3.11A and B: (A) The SAFE system. Image courtesy of Dr. James Harris. www.hsccolorado.com. (B) Standard Round and Hexagonal tips used with the SAFE system.

SAFE System

The surgically advanced follicular extraction (SAFE) system (Fig. 3.11A) is a powered FUE device invented by James Harris. It is a motorized device that uses either cylindrical ("round") or hexagonal ("Hex") blunt tip punches for graft dissection (Fig. 3.11B). The punches come in .8, .9, 1.0, and 1.2 mm sizes. The principle advantage of the blunt punch dissection technique is the ability to dissect to the depth of 4mm with minimal transection of follicles. The average depth of dissection for sharp punch systems is 2–2.5 mm. Harris reports that a deeper depth of dissection means less force is required to remove the graft from the skin, and therefore less trauma to the grafts. The latest innovation, the hexagonal tip, induces a small amount of vibration which helps separate the surrounding tissue from follicular units further, leading to even lower transection rates. The isolated follicular units are then removed with forceps and evaluated for integrity prior to transplantation.

James Harris reports the SAFE system has expanded patient candidacy to include blacks and some of the patients who are classified as not eligible for FUE by the Fox Test proposed by Rassman and colleagues.[13,14] Based on a series of 59 patients from whom 6,947 grafts were harvested, Harris reports an average of 6.14% transection rate (range 1.7–15%) with the SAFE system. The only adverse reactions reported were two buried grafts resulting in inflammatory subcutaneous cysts requiring excision. He concludes that the SAFE system provides methodology and instrumentation that can enhance FUE techniques and expand patient candidacy.[14] Like manual FUE, however, this method of FUE is user dependent as it requires technical skill to perform with speed and accuracy.

Neograft

The Neograft machine is a powered, handheld surgical device that utilizes a sharp punch biopsy to extract individual follicular units from the donor area. It is operator dependent, as an operator guides and selects which hair follicles are to be harvested. It then uses a controlled pneumatic pressure system to remove the graft from the donor area and stores grafts in a saline filled canister until the grafts are ready for implantation in the recipient site. Compared with the ARTAS robotic system, the Neograft relies on operator skill and experience to determine which grafts and at which angle grafts should be harvested, while the ARTAS robotic system relies on computerized digital imaging to concisely harvest grafts.[15,16]

ROBOTIC SYSTEM

ARTAS Robotic System

The ARTAS robotic system (Restoration Robotics, Inc, San Jose, CA) is the only truly robotic system for FUE on the market to date (Fig. 3.12). It was Food and Drug Administration approved for hair transplantation in 2011. A 1 mm punch is attached to the robotic arm consisting of a "needle-within-needle," where the sharp inner punch is surrounded by a blunt outer punch. The sharp inner punch creates a shallow 1 mm incision and the blunt outer punch spinning at 400–800 rpm subsequently dissects deeper and

JAYPEE BROTHERS



Fig. 3.12: ARTAS robotic system.



Fig. 3.13: Grid for harvesting with ARTAS device.

separates the follicular unit from the surrounding tissue. A suction system then elevates the follicular unit from surrounding skin, making it easier to manually extract the graft. A combination of stereoscopic cameras managed by image processing software allows the sharp and blunt punches to identify the precise angle and direction of hair growth. This continuous imaging feedback allows the robot to accurately harvest each follicular grouping. The sensors work by detecting the pigment in hair follicles, so if a patient has white or blonde hair, the donor hair must be dyed brown or black prior to harvesting. This is typically done with a temporary hair dye immediately prior to the procedure. Hairs must also be trimmed to 1–2 mm in length for the digital imaging system to function properly, and a plastic grid with fiducials (appear like dominos) to calibrate the system must be placed and moved on the scalp to facilitate donor harvesting (Fig. 3.13). Due to the high level of automation, the robot can remove 400–600 grafts per hour. There is a minimum distance of 1.6 mm between extracted follicular groupings to minimize the risk of overharvesting the donor area. Once the follicular units are harvested, they are inspected by experienced technicians who trim excess tissue off the grafts prior to implantation of the hairs in the recipient site.[17] Figure 3.14 for an example of typical grafts harvested by the ARTS robotic device.

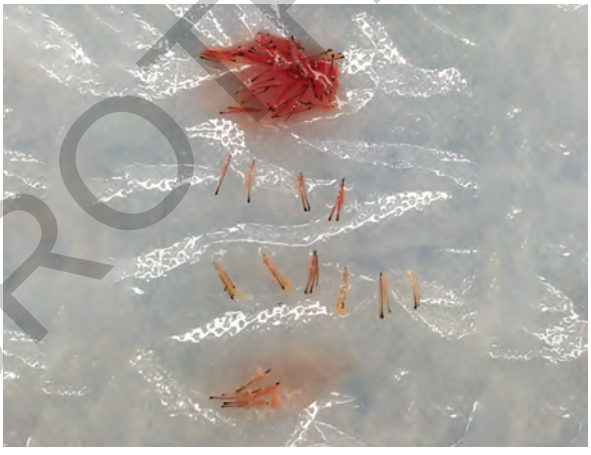

Fig. 3.14: Typical follicular unit extraction grafts harvested with ARTAS device.

WOUND CARE AFTER DONOR HARVESTING

After the hair transplant procedure is complete whether donor harvesting is done via an FUE or elliptical excision, a pressure bandage is placed on the scalp as described above. We recommend the patient keep the pressure bandage in place until the day after the procedure. Beginning postoperative day 1, we recommend the patient wash the donor site with soap and water and apply Aquaphor ointment twice daily for the next 7 days. Wound care is the same for both FUE and elliptical donor harvesting. Typically, the FUE donor sites heal within 3–5 days and patients can resume their regular activities. With elliptical donor harvesting, however, we remove the sutures at day 7 and ask patients to avoid heavy exercise at least until the sutures are removed.

If the patient is diabetic and at an increased risk of infection, we typically prescribe Bactroban (mupirocin) ointment to be applied twice daily to the donor site instead of the usual Aquaphor. Oral antibiotics are not routinely given.

JAYPEE BROTHERS

REFERENCES

1. Orentreich N. Autografts in alopecias and other selected dermatological conditions. Ann NY Acad Sci. 1959;83:463-79.
2. Park JH, Na YC, Moh JS, et al. Predicting the permanent safe donor area for hair transplantation in Koreans with male pattern baldness according to the position of the parietal whorl. Arch Plast Surg. 2014;41(3):277-84.
3. Avram M, Rogers N. Contemporary hair transplantation. Dermatol Surg. 2009;35(11):1705-19.
4. Avram MR. Hair transplantation: new concepts in 2005. J Cosmet Laser Ther. 2005;7(2):77-80.
5. Bisaccia E, Scarborough D. Hair transplant by incisional strip harvesting. J Dermatol Surg Oncol. 1994; 20(7):443-8.
6. Knudsen RG. The donor area. Facial Plast Surg Clin North Am. 2004;12(2):233-40.
7. Rassman WR, Carson S. Micrografting in extensive quantities. The ideal hair restoration procedure. Dermatol Surg. 1995;21(4):306-11.
8. Pathomvanich D. Donor harvesting: a new approach to minimize transection of hair follicles. Dermatol Surg. 2000;26(4):345-8.
9. Jimenez F, Ruifernandez JM. Distribution of human hair in follicular units. A mathematical model for estimating the donor size in follicular unit transplantation. Dermatol Surg. 1999;25(4):294-8.
10. Buchwach KA. Graft harvesting and management of the donor site. Facial Plast Surg Clin North Am. 2013;21(3):363-74.
11. Mayer M, Pauls T. Scalp elasticity scale. Hair Transplant Forum Intl. 2005;15:122-23.
12. Avram MR, Watkins SA. Robotic follicular unit extraction in hair transplantation. Dermatol Surg. 2014;40(12):1319-27.
13. Rassman WR, Bernstein RM, McClellan R, et al. Follicular unit extraction: minimally invasive surgery for hair transplantation. Dermatol Surg. 2002;28(8): 720-28.
14. Harris JA. New methodology and instrumentation for follicular unit extraction: lower follicle transection rates and expanded patient candidacy. Dermatol Surg. 2006;32(1):56-61; discussion 61-2.
15. Available from www.neograft.com.
16. Available from www.restorationrobotics.com.
17. Rose PT, Nusbaum B. Robotic hair restoration. Dermatol Clin. 2014;32(1):97-107.

JAYPEE BROTHERS

or detailed information of dermatology books, visit our website **www.jaypeebrothers.com,** for detailed information of dermatology books, visit our web

Aesthetic Series

HAIR TRANSPLANTATION

Salient Features

- Candidate selection
- Donor harvesting techniques
- Follicular unit extraction (FUE) vs ellipse
- Instrumentation
- The role of medications with hair transplantation
- Future trends in hair transplantation



Nicole Rogers MD FAAD is Clinical Assistant Professor of Dermatology at Tulane University School of Medicine in New Orleans, Louisiana, USA, and also in private practice in Metairie, Louisiana USA. She completed her fellowship in hair transplantation with Dr. Marc R Avram shortly after finishing residency at Tulane. Since then, she has written and spoken extensively on the medical and surgical treatment of hair loss, both in men and women, and has featured in many media appearances.



Meena K Singh MD is board-certified Dermatologist and Dermatologic Surgeon at KMC Hair Center. She attended Harvard Medical School, trained at the Mayo Clinic, and completed surgical fellowship in New York City, in which she became trained in Mohs Micrographic Surgery, as well as cosmetic dermatology procedures, such as Botox, Lasers and Fillers. She also completed her fellowship with the International Society for Hair Restoration Surgery, and was trained in all hair transplantation techniques, including strip excision and manual/motorized/ robotic follicular unit extraction, as well as transplanting into scarring alopecias. She also specializes in medical treatments for hair loss of all types. Dr Singh has performed clinical trials in laser hair stimulation, as well as studies in hair transplantation for scarring and non-scarring forms of hair loss. She has also performed investigative studies on skin cancer in transplant recipients, as well as tissue engineering. She has numerous publications in many peer-reviewed dermatology journals, and book chapters including the New England Journal of Medicine. She is also one of the reviewer for the Journal of Cosmetic Dermatology and the Dermatologic Surgery journal. Dr. Singh has also been featured on the cover of New York Times.



Shannon Watkins MD is board-certified Dermatologist and Hair loss specialist practicing in the New York area. She has co-authored multiple publications on medical and surgical therapies for hair loss. She completed her Dermatology residency at New York Presbyterian—Weill Cornell Medical College, followed by a hair transplant and laser fellowship in New York City with Dr Marc R Avram. She is a Voluntary Clinical Professor at the Mount Sinai Department of Dermatology. Her speciality interests include the medical and surgical treatment of hair disorders, medical and cosmetic dermatology. Dr Watkins grew up in Hawaii and now lives in New York City with her husband who is also a physician.



Marc R Avram MD is Clinical Professor of Dermatology, Department of Dermatology, Weill Cornell Medical College and Presbyterian Hospital, New York, NY, USA and Fellow of the American Academy of Dermatology (AAD) since 1994. He is a Member of the International Society of Hair Restoration Surgeons (ISHRS) since 1994 and Fellow of the ASLMS since 1998. He is also Fellow of the American Society of Dermatologic Surgery (ASDS) since 1997 and Member of the Dermatologic Society of Greater New York since 1994.

Dr Avram is Senior Editor of textbooks, such as Hair Transplantation, published by Cambridge University Press and The Color Atlas of Cosmetic Dermatology published by McGraw-Hill Publishing. He is also the Series editor for Laser and Light Source Treatment for the Skin published by Jaypee Brothers. Besides, he is also Editor of the Color Atlas of Cosmetic Dermatology, Second Edition, published by McGraw-Hill Publishing. He has published numerous papers in several journals as well as contributed many chapters in leading textbooks. Dr Avram has also given 400 to 500 invited lectures in the United States and worldwide. He serves on the editorial board of several peer reviewed journals.

Available at all medical bookstores or buy online at www.jaypeebrothers.com

JAYPEE BROTHERS
Medical Publishers (P) Ltd.
www.jaypeebrothers.com

Join us on facebook.com/JaypeeMedicalPublishers

Shelving Recommendation
DERMATOLOGY

ISBN 978-93-5152-932-3