rothers.com, for detailed information on gastroenterology books, visit our website www.jaypeebrothers.com, for detailed information on gastroenterology books

Get Full Access
with added features at
emedicine360.com

Evidence-Based Practices in GASTROINTESTINAL, COLORECTAL AND HEPATOBILIARY SURGERY

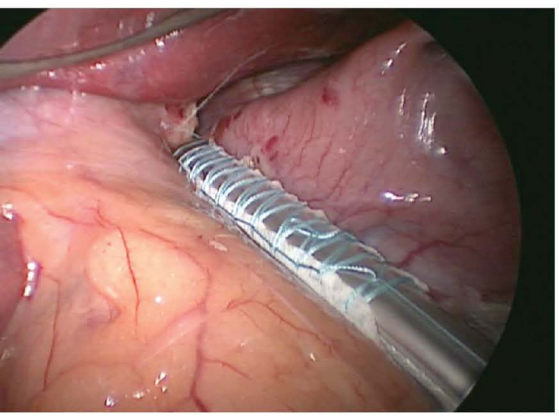
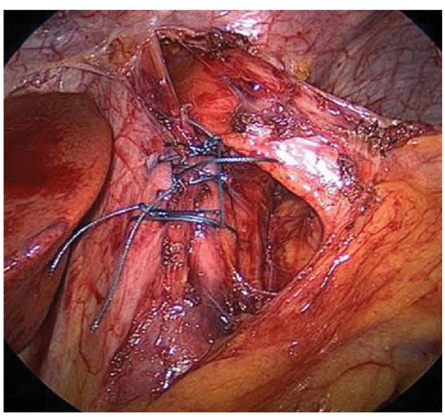
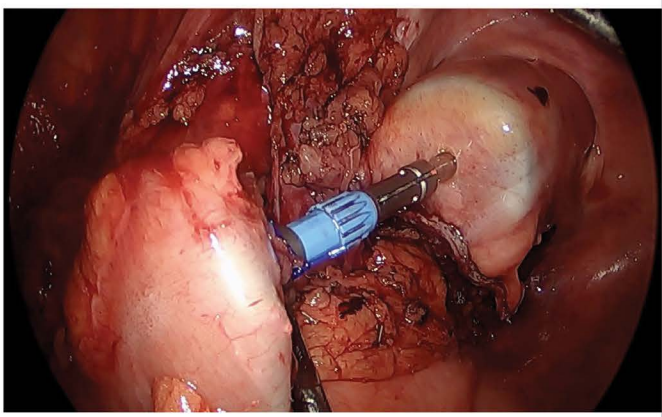

Govind Nandakumar

Forewords
Jeffrey W Milsom
Fabrizio Michelassi
Nandakumar Jairam

JAYPEE

Contents

Section 1: General Chapters

1. **Topics in Intraoperative Gastrointestinal Pathology for Practicing Surgeons** 3
   Nicole C Panarelli, Debra Beneck
   - Review *3*

2. **Hepatic, Biliary, and Pancreatic Imaging** 14
   Allen Sanchez, Gayle Rudofsky Salama, Douglas Brylka
   - Imaging of the Liver *14*
   - Lesions of the Liver *19*
   - Metastases *30*
   - Imaging of the Biliary System *32*
   - Imaging of the Pancreas *43*

3. **Interventional Radiology Techniques** 69
   Jessica A Rotman, Adam D Talenfeld

   Part I: Percutaneous Treatment of Benign Liver Disease 69
   - Portal Hypertension *69*
   - Biliary Obstruction *73*

   Part II: Percutaneous Treatment of Primary and Metastatic Hepatic Malignancy 77
   - Percutaneous Tumor Ablation *77*
   - Transarterial Interventions *81*

4. **Radiotherapy for Gastrointestinal and Liver Pathology** 102
   John Ng, Baoqing Li, Tony JC Wang, David P Horowitz
   - Evidence-Based Review *103*
   - Landmark Trials *107*
   - Conclusion and Future Directions *107*

5. **Novel Techniques in Advanced Endoscopy** 110
   Christine Boumitri, Nikhil Kumta, Prashant Kedia, Michel Kahaleh
   - Interventional Endoscopic Ultrasound *110*

6. **Pediatric Gastrointestinal and Hepatobiliary Surgery** 136
   Oliver J Muensterer, Samir Pandya
   - General Aspects of Surgery in Children *136*
   - Pediatric Foregut Surgery *136*
   - Midgut and Hindgut Pediatric Surgery *143*
   - Hepatobiliary Surgery in Children *152*
   - Conclusion and Future Directions *159*

7. Early Recovery after Gastrointestinal Surgery **162**
Benjamin Perakath, Rohin Mittal
- Aim and Rationale of the ERAS Pathway *162*
- Components of ERAS *162*
- Preoperative Interventions *162*
- Perioperative Interventions *164*
- Postoperative Interventions *165*
- Audit *166*
- Outcomes of the ERAS Pathway *166*

8. Nutrition for the Gastrointestinal and Hepatobiliary Surgery Patient **169**
Alissa J Ritter Lupu
- Preoperative Nutrition Optimization *169*
- Enteral and Parenteral Nutrition Support *173*
- Selection of EN Formula *174*
- Oral Diet Advancement *175*
- Postoperative Medical Nutrition Therapy Guidelines *175*
- Medical Nutrition Therapy for Specific Surgeries *178*

9. Stoma Care **182**
Kelly Hicks, Nora Sammon, Danielle Hunton
- Preoperative Considerations *182*
- Stomal Complications *182*
- Peristomal Skin Complications *184*
- Other Skin Complications *189*
- Psychological Impact *189*

10. Genetic Counseling and Genetic Testing for Colorectal Cancer Risk—A Case-based Review **192**
Francesca Tubito, Diana Moglia Tully, Michelle E Ernst
- Genetic Counseling *192*
- Introduction to Hereditary Colorectal Cancer Syndromes *197*
- Hereditary Colorectal Cancer Syndromes without Significant Polyposis *199*
- Adenomatous Polyposis Syndromes *210*
- Hamartomatous Polyposis Syndromes *225*
- Other Polyposis Syndromes *231*
- Other Hereditary Syndromes with GI Findings *232*
- Types of Genetic Tests and Technologies *232*

Section 2: Esophagus
Section Editor—*Subroto Paul*

11. Benign Disorders of the Esophagus **245**
Subroto Paul
- Overview *245*

12. Gastroesophageal Reflux Disease 246
Stefan S Kachala, Brendan M Finnerty, Rasa Zarnegar
- Review of Landmark Studies *246*
- Minimally Invasive Gastric Fundoplication *247*
- Operative Tips *251*

13. Surgical Options for Achalasia 253
Jon Wee, Nestor Villamizar
- Laparoscopic Heller Myotomy *253*
- Peroral Endoscopic Myotomy (POEM) *260*
- Conclusion and Future Directions *263*

14. Surgical Treatment of Esophageal Diverticula 265
Desmond M D'Souza, Siva Raja
- Zenker's Diverticulum *265*
- Diverticulectomy and Myotomy *265*
- Thoracic Diverticula *267*
- Conclusion and Future Directions *269*

15. Endoscopic Treatment for Achalsia: Peroral Endoscopic Myotomy 271
Nikhil Kumta, Christine Boumitri, Michel Kahaleh
- Evidence-Based Review *271*
- Procedure *271*
- Outcomes *274*
- Conclusion and Future Directions *275*

16. Barrett's Esophagus 277
Amir Soumekh, Felice Schnoll-Sussman
- Preoperative Planning *280*
- Surgical Anatomy *280*
- Step-by-Step Illustration of Procedure *280*
- Operative Tips *280*
- Complications *280*
- Outcomes *280*
- Conclusion and Future Directions *281*

17. Malignant Disorders of the Esophagus 283
Subroto Paul
- Overview *283*

18. Short- and Long-Term Outcomes in Esophageal Cancer 284
Subroto Paul
- Postoperative and Short-Term Outcomes *284*
- Long-Term Survival *286*

19. Esophagectomy 291
Elliot Servais
- Overview *291*

- Preoperative Evaluation *292*
- Open Esophagectomy *292*
- Minimally Invasive Esophagectomy *294*
- Future Directions *296*

20. Robotically Assisted Minimally Invasive Ivor Lewis Esophagectomy **299**
R Taylor Ripley, Inderpal S Sarkaria
- Evidence-Based Review *299*
- Preoperative Planning *299*
- Anesthetic Considerations *300*
- Procedure and Surgical Anatomy *300*
- Postoperative Care *303*
- Illustrations *303*
- Complications *303*
- Outcomes (Literature Review) *303*
- Conclusion and Future Directions *308*

Section 3: Stomach

21. Gastric Bypass and Biliopancreatic Diversion **313**
Adam Levy, Katherine D Gray, Gregory Dakin
- Evidence-Based Review: Indications *313*
- Evidence-Based Review: Physiology *314*
- Landmark Trials *315*
- Procedures *315*
- Operative Tips *319*
- Complications *319*
- Outcomes in Bariatric Surgery *321*

22. Laparoscopic Adjustable Gastric Banding and Sleeve Gastrectomy **325**
Nabeel R Obeid, Christine J Ren-Fielding, Manish Parikh
- Evidence-Based Review *325*
- Landmark Trials *326*
- Preoperative Planning *327*
- Surgical Anatomy *327*
- Procedure: Laparoscopic AGB *328*
- Procedure: Laparoscopic SG *334*
- Conclusion and Future Directions *340*

23. Role of Surgery in Developing Economies **342**
HV Shivaram, Natarajan A
- Synergism of Growing Economies and Illnesses *342*
- Evidence-Based Review *343*

- Landmark Trials *360*
- Procedures *361*
- Surgical Anatomy and Operative Technique *363*
- Conclusion and Future Directions *371*

24. Metabolic Surgery **378**
Alpana P Shukla, Alfons Pomp
- Mechanisms of Glycemic Control after Metabolic Surgery *378*
- Outcomes of Metabolic Surgery *379*
- Patient Selection and Surgical Options for the Obese Patient with T2DM *380*

25. Gastric Cancer **384**
Savio George Barreto, Ankesh Rawat, Parul J Shukla
- Etiology *384*
- Classification of Gastric Cancer *384*
- Signs and Symptoms of Gastric Cancer *384*
- Diagnosis and Staging of Gastric Carcinoma *386*
- Treatment of Gastric Cancer *387*

Section 4: Liver

26. Anatomic Resections of the Liver **399**
Neel P Chudgar, Govind Nandakumar
- Anatomy *399*
- Preoperative Planning *404*
- Procedures *405*
- Postoperative Care *412*
- Operative Tips *413*
- Outcomes *414*
- Conclusion and Future Directions *414*

27. Benign Tumors of the Liver **416**
Ashwin Rammohan, Sanjay Govil
- Introduction and Classification *416*
- Incidental Liver Tumors *416*
- Cavernous Hemangioma *418*
- Focal Nodular Hyperplasia *420*
- Hepatocellular Adenoma *421*
- Benign Cystic Tumors *423*
- Hepatobiliary Cystadenoma with OS *424*
- Hepatobiliary Cystadenoma without OS *425*
- Intraductal Papillary Mucinous Neoplasm of the Bile Duct *426*

28. Hepatocellular Carcinoma **429**
Teo Jin Yao, Lee Ser Yee, Chan Chung Yip, Chung Yaw-Fui Alexander
- Risk Factors *429*

- Evidence-Based Review *429*
- Landmark Trials *433*
- Procedure *434*
- Surgical Anatomy *436*
- Step-by-Step Illustration of Procedure *439*
- Parenchymal Transection *447*
- Laparoscopic Resections *447*
- Robotic Liver Surgery *450*
- Operative Tips *451*
- Postoperative Complications *452*
- Outcomes *453*
- Conclusion and Future Directions *456*

29. Intrahepatic and Perihilar Cholangiocarcinoma: Surgical Management **459**
Kayvan Roayaie, Sasan Roayaie
- Epidemiology *459*
- Risk Factors *460*
- Intrahepatic Cholangiocarcinoma *460*
- Perihilar Cholangiocarcinoma *463*
- Liver Transplantation for PCCA *466*

30. Colorectal Liver Metastasis **468**
Ramraj Vemala Nagendra Gupta, Govind Nandakumar
- Surgical Anatomy *469*
- Diagnosis *469*
- Management *471*
- Landmark Trials *473*
- Operative Tips *474*
- Outcome and Surveillance *475*
- Future *475*

31. Gallbladder Cancer **478**
Pankaj Kumar Garg, Rambha Pandey, Durgatosh Pandey
- Evidence-Based Review of Different Aspects of Surgical Management of GBC *480*
- Radical Cholecystectomy *482*
- Conclusion and Future Directions *486*

32. Ex Vivo Resection of Complex Abdominal Masses **489**
Abhishek Mathur, Tomoaki Kato
- Ex Vivo Surgery in Liver Pathology *489*
- Ex Vivo in Cholangiocarcinomas and Klatskin Tumors *489*
- Ex Vivo in HCC *491*
- Ex Vivo and Colorectal Metastases *492*
- Ex Vivo for Benign Liver Lesions or Lesions with Low Malignant Potential *492*
- Ex Vivo and Pancreatic Adenocarcinoma *496*

- Ex Vivo for Pancreatic Lesions with Low Malignant Potential *497*
- Ex Vivo for Lesions at the Root of the Mesentery *500*

33. Operative Techniques for Liver Transplantation **506**
Pejman Radkani, Vikram Wadhera, Sander Florman
- History *506*
- Preoperative Planning *506*
- Operative Techniques *507*

34. Perioperative Management of Liver Transplantation **513**
Parissa Tabrizian, Josep Marti-Sanchez, Antonios Arvelakis, Sander Florman
- Pathophysiology and Preoperative Evaluation *513*
- Intraoperative Monitoring *514*
- Surgical Techniques *516*
- Challenges Associated with Transplantation *516*
- Postoperative Care after Liver Transplantation *517*
- Complications *518*

35. Indications and Contraindications for Liver Transplantation **522**
Parissa Tabrizian, Sander Florman
- Allocation Systems *522*
- Preoperative Evaluation *523*
- Indications *523*
- Contraindications *527*
- Living Donor Liver Transplantation *528*

Section 5: Pancreas

36. Management of Acute and Chronic Pancreatitis: Focus on Surgical Management **533**
Beth Schrope
- Acute Pancreatitis *533*
- Chronic Pancreatitis *543*
- Conclusion and Future Directions *563*

37. Pancreatic Cancer **566**
Jumana Jaloudi, Michael D Kluger
- Diagnostic Approach *568*
- Surgical Management *570*
- Other Procedures *581*
- Outcomes and Considerations *585*
- Landmark Trials *585*

38. Borderline Resectable Pancreatic Cancer **589**
Abhishek Mitra, Bhawna Sirohi, Mahesh Goel, Shailesh V Shrikhande
- Evidence-Based Review *589*
- Landmark Trials *593*
- Preoperative Planning *594*

- Surgical Anatomy *594*
- Operative Tips for Vein Resection *596*
- Postoperative Management and Complications *598*
- Outcomes *599*
- Future Trends *599*

39. Endocrine Tumors of the Pancreas **603**
Kareem Ibrahim, Hasan Aldailami, Thomas J Fahey III
- Anatomy and Physiology of the Pancreas *603*
- Diagnosis *605*
- Insulinoma *606*
- Gastrinoma *609*
- Glucagonoma *612*
- Somatostatinoma *613*
- Incidentaloma *613*
- Operative Strategies *614*

40. Pancreas Transplantation **619**
Samuel Sultan, Anthony Watkins
- Evidence-Based Review *619*
- Landmark Trials *621*
- Donor Procurement *622*
- Pancreas Transplantation *624*
- Operative Tips *628*
- Complications *631*
- Outcomes *632*
- Conclusion and Future Directions *632*

Section 6: Small Bowel and Abdomen

41. Crohn's Disease of the Small Bowel **637**
Daniele Scoglio, Alessandro Fichera
- Preoperative Planning *637*
- Surgical Procedure *638*
- Operative Technique: Gastrojejunostomy *638*
- Operative Technique: Strictureplasty *640*
- Operative Technique: Laparoscopic Ileocolic Resection *644*

42. Gastrointestinal Stromal Tumors **652**
John Creasy, Benjamin Golas, Melanie Ongchin
- Pathology *652*
- Prognostic Features and Risk Stratification *654*
- Clinical Presentation *654*

- Diagnosis *654*
- Treatment and Prognosis *657*
- Future Directions *664*

43. Carcinoid Tumors of the Gastrointestinal Tract **667**
Tushar Samdani, Vanessa Hui, Rashmi S, Govind Nandakumar
- Clinical Presentations and Symptoms *667*
- Pathological Diagnosis and Reporting of NET *669*
- Management of Locoregional Unresectable or Metastatic Carcinoid Tumors *671*
- Landmark Trials *672*
- Outcomes *674*
- Conclusion and Future Directions *675*

44. Trauma of the Gastrointestinal Tract **678**
Soumitra R Eachempati, Philip S Barie
- Initial Diagnosis of Abdominal Injuries *678*
- Management of Hollow Viscus Injuries *678*
- Injuries to the Stomach *679*
- Duodenal Injuries *680*
- Small and Large Bowel Injuries *680*
- Rectal Injuries *681*
- Injuries to the Spleen *682*
- Liver Injuries *684*
- Injuries to the Pancreas *687*

Section 7: Colon

45. Volvulus **693**
Evan N Feldman
- Sigmoid Volvulus *693*
- Cecal Volvulus *695*
- Ileosigmoid Knotting *695*
- Volvulus of the Transverse Colon or Splenic Flexure *695*
- Colonic Volvulus in Pregnant Women *696*

46. Diverticulitis **697**
Gregory Charak, Chukwuma Apakama, Steven Lee-Kong
- Evidence-Based Review *697*
- Trials *699*
- Rationale for Minimally Invasive Approach *699*
- Conclusion and Future Directions *704*

47. Surgical Management of Constipation **705**
Christopher T Aquina, Christian P Probst, Kristin N Kelly, Christina Cellini
- Prevalence *705*

- Etiology and Risk Factors *705*
- Classification *705*
- Diagnosis and Workup of Constipation *705*
- History and Physical Exam *706*
- Overview of Diagnostic Schema *708*
- Disordered Defecation Studies *708*
- Colonic Transit Studies *709*
- Lifestyle Modification *710*
- Medication Therapy *710*
- Biofeedback *712*
- Surgical Options for Slow Transit Constipation *712*
- Surgical Options for Defecatory Disorders *715*

48. Surgical Management of Ulcerative Colitis **719**
Vitaliy Y Poylin, Thomas Cataldo
- Preoperative Planning *722*

49. Surgical Management of Crohn's Colitis **732**
Mukta K Krane
- Clinical Presentation *732*
- Indications for Surgery *732*
- Failure of Medical Management *733*
- Procedures *733*

50. Hereditary Nonpolyposis Colorectal Cancer Syndromes **739**
Joongho Shin
- Hereditary Nonpolyposis Colorectal Cancer Syndromes (Lynch Syndrome, LC) *739*
- Hamartomatous Tumor Syndrome *739*
- Conclusion and Future Directions *743*

51. Inherited Polyposis Syndromes **745**
Maria Ximena Traa Kiely, Lilian Chen, James Yoo
- Investigation of Polyposis Syndromes *748*
- Management *748*
- Prevention *756*
- Conclusion and Future Directions *756*

52. Difficult Polypectomy **760**
Erman Aytac, Emre Gorgun
- Endoscopic Mucosal Resection *761*
- Endoscopic Submucosal Dissection *762*
- Combined Endoscopic and Laparoscopic Surgery *769*

53. Laparoscopy for Colon Cancer **773**
Jared Wong, James Fleshman
- Colon Cancer *773*

- Right Colectomy *775*
- Hepatic Flexure Mobilization *777*
- Splenic Flexure Mobilization *781*

54. Cytoreductive Surgery and Intraperitoneal Chemotherapy **787**
Michael Polcino, Leandro Feo, Garrett M Nash
- Technique *787*
- Evidence-Based Review and Outcomes *791*

Section 8: Rectum

55. Rectal Prolapse **803**
Azah A Althumairi, Bashar Safar
- Clinical Presentation and Patient Evaluation *803*
- Evidence-Based Review and Landmark Trials *803*
- Surgical Procedures *805*
- Outcomes *808*
- Conclusion and Future Directions *809*

56. Transanal Endoscopic Microsurgery **811**
Joshua A Tyler, Steven R Hunt
- Clinical Anatomy *811*
- Preoperative Evaluation *811*
- Operative Steps *812*
- Postoperative Care *815*
- Clinical Tips and Pitfalls *815*

57. Rectal Cancer **816**
Usmaan Hameed, Anand Govindarajan
- Evidence-Based Review and Landmark Trials *816*
- Procedures *819*
- Complications *821*
- Conclusion and Future Directions *821*

58. Management of Recurrent Rectal Cancer **823**
Paul RA O'Mahoney, Govind Nandakumar, Heather Yeo
- Risk Factors for Recurrence *823*
- Classification of Local Recurrence *823*
- Presentation and Incidence *825*
- Patient Selection *826*
- Preoperative Planning *826*
- Anatomic Considerations and Consultants *826*
- Imaging *826*
- Operative Technique *827*
- Intraoperative Radiation Therapy *828*

- Postoperative Care *829*
- Complications *829*
- Palliative Treatment *830*
- Future Directions *830*

59. Laparoscopic Proctectomy **833**
Alexis L Grucela, John-Paul Bellistri, Aida Taye
- Evidence-Based Review *833*
- Preoperative Preparation and Prevention *834*
- Surgical Anatomy *837*
- Step-by-Step: Laparoscopic Low Anterior Resection *839*
- Operative Tips *846*
- Outcomes and Complications *847*
- Future Directions *850*
- Landmark Trials and Key Studies *850*

60. Robotic Proctectomy **855**
Carrie Y Peterson, Govind Nandakumar
- Indications *855*

61. Acute and Chronic Pouch Complication **867**
Lilian Chen, Joseph Batac, Todd D Francone
- Acute Complications *867*
- Chronic Complications of IPAA *872*
- Pouch Dysfunction *876*

62. Retrorectal Tumors **887**
Rebecca A Levine, Rahul Narang
- Evidence-Based Review *887*
- Procedure *893*
- Complications *896*
- Outcomes *896*
- Future Directions *897*

Section 9: Anus

63. Hemorrhoids **903**
Ziad N Kronfol, Melissa M Alvarez-Downing
- Surgical Anatomy *903*
- Preoperative Planning *905*
- Closed Hemorrhoidectomy (Ferguson) *905*
- Open Hemorrhoidectomy (Milligan-Morgan) *907*
- Stapled Hemorrhoidopexy (Procedure for Prolapse and Hemorrhoids, PPH) *908*

- Ligasure Emorrhoidectomy *910*
- Transanal Hemorrhoidal Devascularization or Hemorrhoidal Artery Ligation *911*

64. Surgical Therapy for Fecal Incontinence **915**
Kelly A Garrett
- Etiology *915*
- Assessment *917*
- Physiologic Testing *917*
- Treatment *919*

65. Perianal Crohn's Disease **929**
Emily Steinhagen, Randolph M Steinhagen
- Evaluation *929*
- Treatment *929*
- Skin Tags *930*
- Anal Fissure and Ulceration *930*
- Stricture *931*
- Abscess and Fistula *931*
- Carcinoma *934*

66. Anorectal Sexually Transmitted Diseases **937**
Maria Camilla Ramirez, Lester Gottesman
- Bacterial STD *937*

67. Anal Cancer and Anal Intraepithelial Neoplasia **943**
Jason R Bingham, Amit K Agarwal, Scott R Steele
- Evidence-Based Review *945*
- Landmark Trials *951*
- Preoperative Planning *952*
- Surgical Anatomy *952*
- Abdominoperineal Resection *954*
- Technique for AIN *963*
- Conclusion and Future Directions *965*

Index *971*

4 Radiotherapy for Gastrointestinal and Liver Pathology

John Ng, Baoqing Li, Tony JC Wang, David P Horowitz

BACKGROUND

Radiation therapy is a central modality in the standard treatment for nearly every type of gastrointestinal malignancy. Radiotherapy's utility and effectiveness is based on its fundamental biologic properties, preferentially killing malignant cells and tumors while enabling the normal tissue to repair over a short interval of time. The four R's of radiotherapy—Repair, Reassortment, Repopulation, and Reoxygenation—enable for versatility and efficacy, while everimproving technologies enable radiation to be delivered with precise spatial and anatomic localization to widen the therapeutic window. When integrated with surgery and chemotherapy in multimodality treatment, radiation therapy can lead to curative treatments for many cancer patients.

This textbook chapter will focus on the emerging role of radiation treatment in liver malignancies—whether with primary hepatocellular or hepatobiliary carcinoma or with liver metastases. The chapter will bypass the central importance of radiotherapy in the management of the other gastrointestinal malignancies, such as esophageal, pancreatic, colorectal, and anal cancers. Those topics are broad and are covered well by several introductory radiation oncology textbooks.[1-3] We will discuss the basis of hepatobiliary radiotherapy and the advances in imaging and treatment delivery that allow for improvements in toxicities and patient outcomes. We will also focus on the growing body of clinical literature that is establishing the role of radiotherapy in liver cancer management.

Liver tumors are sensitive to the effects of radiation. Historically, the role of radiotherapy was limited due to the sensitivity of the liver to radiation injury. Older radiation techniques often led to unacceptable doses of radiation to healthy hepatic parenchyma and nearby organs with subsequent side effects. One of the major advances of modern radiotherapy has been the enhanced ability to deliver to tumor regions sufficient radiation dose to achieve reasonable local control without causing unacceptable toxicities.[4,5]

The classic radiation associated liver toxicity is radiation induced liver disease (RILD).

This condition typically occurs 4–6 months following hepatic radiation therapy, and the clinical presentation usually includes fatigue, weight gain, increased abdominal girth, hepatomegaly, anicteric ascites, and alkaline phosphatase elevation out of proportion to the other liver enzymes. The characteristic initial laboratory findings include relatively normal liver function tests and normal bilirubin and ammonia levels.[6] On histopathology, RILD often will show features of veno-occlusive disease and have been described in the normal liver tissues following radiation therapy.[7]

Those patients with severe underlying liver disease at baseline are at a higher risk for radiation induced liver toxicity, similar to their risks with other liver treatment modalities. From classic animal model work and epidemiologic studies, it is believed that as long as radiation treatment planning can keep whole liver mean radiation doses below 30 Gray (Gy) in 2 Gy fractions, there should be less than a 5% risk of radiation-induced liver failure. These risk estimates have been largely concordant with observed results from clinical trials.[8] In the modern era, where the radiation treatments are often given in 5 or fewer fractions, another widely used dose constraint parameter is 700 cc of normal liver volume receiving less than 15 Gy.[9]

Management of radiation induced liver disease is difficult. There are not any established agents which can reverse RILD. The condition is managed with supportive care measures such as diuretics, pain management, steroids, and glutathione. There is promise that cell-based or transplant-based strategies may demonstrate effectiveness in treating RILD in the future, but they are not yet widely applicable in the clinic.[6]

The ability to keep the radiation dose to acceptable levels to normal liver was more widely achievable with improved radiotherapy technologies. In the last two decades, 3D conformal treatment planning (3D-CRT)

JAYPEE BROTHERS

and intensity modulated radiation therapy (IMRT) have become increasingly utilized in clinical radiation oncology, and these techniques were applied to liver radiotherapy successfully. The most recent technologic advance has been the emergence of stereotactic body radiotherapy (SBRT), often utilized in brain tumor and lung cancer management, towards treatment of liver tumors.

The SBRT technique involves using high ablative doses of radiation, often delivered in five or fewer high-dose fractions. Highly conformal treatment planning is achieved by the use of multiple radiation beams or arcs, while a steep dose gradient with rapid dose fall off outside of the target minimizes dose to adjacent normal tissues. Due to the dose gradient and the high ablative radiation doses, treatment must be delivered with high geometric precision and accuracy. This accuracy has been improved through the use of image guidance technologies and other strategies to account for or mitigate for hepatic motion during the respiratory cycle. Immobilization techniques have been substantially improved to minimize setup uncertainty. An example of stereotactic treatment planning in liver radiation treatment is given in Figures 1 A and B.

EVIDENCE-BASED REVIEW

Hepatocellular Carcinoma

The earliest radiotherapy trials in hepatocellular carcinoma (HCC) in the era of modern diagnostic imaging and conformal radiotherapy techniques were conducted at the University of Michigan, in France, and in Korea.[10-12] The University of Michigan experience utilized a risk-stratified, individualized dose approach towards HCC patients and reported a favorable local control rate of 81% at 1 year. From this study, there was evidence of a dose-response relationship[10]. Tumor size, lymph node status, and Childs-Pugh class were all noted to be predictive of improved survival on multivariate analysis. Meanwhile, the French group reported a grade 4 toxicity rate of 22% among Childs-Pugh B patients compared with no cases of grade 4 toxicity seen in the Childs-Pugh A group. These results emphasized the importance of underlying healthy liver reserve.[11] The results from these early pioneering studies provided the evidence that 3D conformal and IMRT techniques would enable improved therapeutic

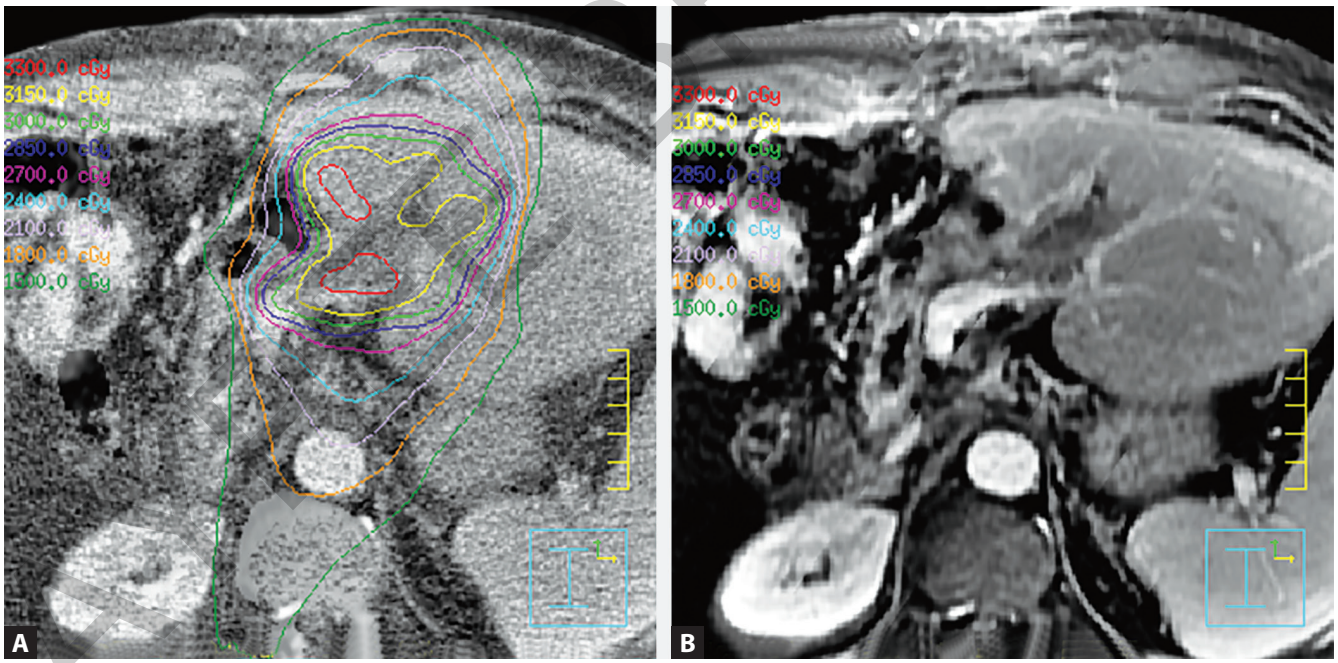

Figs. 1A and B: A stereotactic body radiotherapy (SBRT) treatment plan for liver radiotherapy, demonstrating the high conformality of radiation dose with the stereotactic technique. The patient's pathology showed hepatocellular carcinoma with portal vein invasion, and the patient's tumor subsequently recurred with portal vein tumor thrombus. The patient was treated with liver SBRT to the recurrent disease. (A) The image shows the planning SBRT computed tomography scan with intravenous (IV) contrast. (B) The image shows a magnetic resonance imaging with IV contrast in the portal phase demonstrating a tumor thrombus.
The multiple lines of color—red, yellow, green, blue, etc.—represent different radiation isodose lines. The green line represents the isodose line of the therapeutic dose.

JAYPEE BROTHERS

Table 1: SBRT prospective trials for primary liver.

Study	*Year*	*Number of patients*	*Median follow-up*	*Dose fractionations*	*Local control*	*Overall survival*
Mendez Romero et al.	2006	25 (8 with HCC)	12.9 months	30 Gy in three fractions, 37.5 Gy in three fractions, 25 Gy in five fractions	1-year (75%)	1-year (74%)
Tse et al.	2008	41 (31 HCC)	17.6 months	24–54 Gy in six fractions	1-year (65%)	1-year (48%)
Bujold et al.	2013	102	31.4 months	39–54 Gy in six fractions	1-year (87%)	1-year (55%)
Culleton et al.	2014	29 (with Child-Pugh B or C)	NA	Median 30 Gy in six fractions	NA	1-year (32.3%)

(SBRT: Stereotactic body radiotherapy; HCC: Hepatocellular carcinoma; NA: Not available).

opportunities for radiotherapy in the setting of unresectable hepatocellular cancer.

After the acceptance of 3 D conformal radiotherapy and IMRT as liver radiotherapy techniques, the results from clinical trials incorporating (SBRT) to the liver showed even greater clinical promise. To date, there are numerous single institutional studies supporting the role of SBRT in the management of HCC.[13-16] The data and results are summarized in Table 1. In patients with early stage primary disease unsuitable for surgery or transplantation, SBRT appears to be safe and effective with reported local control rates ranging from 72% to 96% and 1-year overall survival of 69–93%. The rates of grade 3 or higher toxicity were from 0% to 6%.[17] Comparisons of patient subsets within these trials and across the prospective trials further support the paradigm of a dose-response relationship with improved locoregional control with increasing radiation doses.

An important clinical trial from the Princess Margaret Hospital has reported good efficacy and safety of liver SBRT in patients with locally advanced hepatocellular carcinoma.[15] This institutional prospective trial enrolled 102 patients who were treated with a six fraction regimen with the dose dependent on the volume of normal liver being irradiated. The enrolled patient population had conditions rendering them unsuitable for most other local therapies, including transarterial chemoembolization (TACE). The most common contraindication was tumor thrombosis. Despite enrolling a patient population with significant co-morbidities and tumor burden (55% with tumour thrombosis, 12% extra-hepatic disease, 60% multifocal disease), the 1 year local control rate was 87% and the overall survival was 47%. These results compared favorably to sorafenib therapy with significantly less toxicity.

Another recent clinical trial recently evaluated the role of liver SBRT in locally advanced patients who progressed after TACE.[18] An aggressive approach of treating the tumor to 60 Gy in 3 fractions was used if normal tissue constraints could be met.The toxicity was acceptable with 7% grade 3 or 4 gastrointestinal toxicity. 15% of patients showed deterioration in Childs-Pugh class after treatment. Most importantly, the two year local control and overall survival rates were impressive at 95% and 69% respectively.

The clinical trials for liver SBRT for early stage and advanced HCC have established its safety and effectiveness. Further prospective trials will be necessary to evaluate the technique in comparison with other local therapies. For patients unsuitable for surgery and favorable Child-Pugh status, ablative radiotherapy may provide a good therapeutic option. Stereotactic body radiotherapy may also serve a key role in patients with locally advanced disease or portal vein thrombosis where other local therapies are contraindicated. The recently opened RTOG 1112, a cooperative group phase III clinical trial evaluating the role of stereotactic radiotherapy in unresectable hepatocellular cancer management, may provide more insight into the role of liver radiotherapy in patients with unresectable hepatocellular carcinoma.

Intrahepatic Cholangiocarcinoma

Intrahepatic cholangiocarcinoma is a rare but aggressive hepatobiliary malignancy for which surgical resection is the only curative treatment modality. Although less than one-third of newly diagnosed patients will present with resectable disease, locoregional recurrence is the most common pattern of relapse in resected patients, leading to the frequent use of radiotherapy as an adjuvant

JAYPEE BROTHERS

treatment option.[19,20] There have not been any conclusive results from prospective clinical trials. However, single institutional retrospective reviews have highlighted patients who may benefit from adjuvant radiotherapy, in particular those with better performance status or with more unfavorable tumor, stage, or margin status. Two large Surveillance, Epidemiology, and End Results (SEER) database overviews have provided conflicting results on the role of adjuvant radiotherapy in this disease.[21,22] In patients with localized cholangiocarcinoma unsuitable for curative resection, the most common indication of radiation therapy for cholangiocarcinoma is palliation, with goals to either alleviate pain or to restore the obstructed biliary drainage. Although less well-defined, radiotherapy may also be given as single modality therapy, concurrently with chemotherapy, or utilizing stereotactic technology, to potentially improve local control and survival for patients with unresectable disease. Similar to the results from the HCC and liver metastases literature, there appears to be evidence of a dose-response relationship. However, despite the use of escalated radiation doses near normal tissue tolerances, many patients will ultimately fail within the irradiated area

As a method for dose-escalation, SBRT has been increasingly applied toward the patient with unresectable cholangiocarcinoma to improve locoregional control, to shorten treatment times, as well as to potentially reduce toxicities. The results of the prospective clinical trials to date are summarized in Table 2.[10,14,23-27] In a phase II trial of radiation therapy with concurrent hepatic artery floxuridine for unresectable intrahepatic malignancies, conformal high-dose radiation therapy with a mean dose of 60 Gy (1.5 Gy per fraction, bid) was shown to have a median survival of 13.3 months, significantly improved compared with historical controls.[10] Also notable is a Mayo Clinic study that reported impressive rates of 1-year local control and survival of 100% and 73% respectively on 10 patients with unresectable or recurrent cholangiocarcinoma receiving a median dose of 55 Gy in three to five fractions.[24] Finally, the strongest evidence to date supporting the role of radiotherapy and radiation dose escalation in unresectable cholangiocarcinoma comes from a Massachusetts General Hospital/MD Anderson Phase II trial using protons. In the MGH/MDACC study, 37 patients with intrahepatic cholangiocarcinoma have been enrolled, and with a median follow-up of 19.5 months among surviving patients, the median PFS and the median OS is 13.9 months and 49.9 months respectively. In summary, higher local control rates for cholangiocarcinoma have been seen with hypofractionated radiotherapy and with SBRT in comparison with older conformal radiotherapy techniques. Dose escalation in radiotherapy may be a promising area for emerging technologies to improve clinical outcomes for the cholangiocarcinoma patient population. An example of a stereotactic cholangiocarcinoma treatment plan is given in Figure 2.

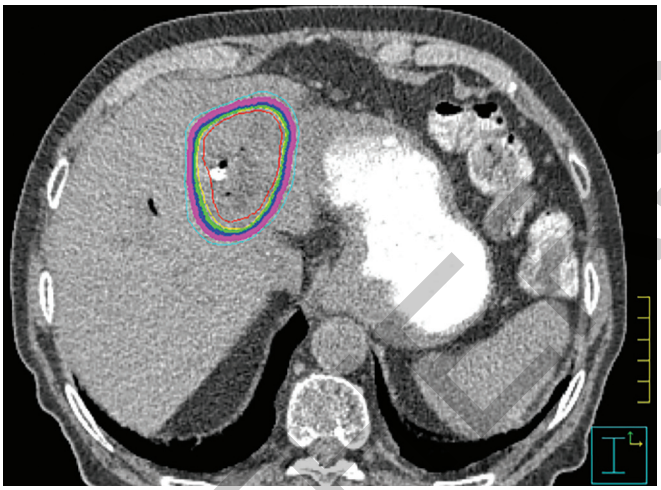

Fig. 2: A stereotactic body radiotherapy (SBRT) treatment plan for a cholangiocarcinoma patient, demonstrating the high conformality of radiation dose with the stereotactic technique. The patient was not an operative candidate. The image is a computed tomography scan with oral contrast used for SBRT radiation treatment planning.
The multiple lines of color—red, yellow, green, blue, etc.—represent different radiation isodose lines. The green line represents the isodose line of the therapeutic dose.

Metastases to Liver

The role of SBRT for liver metastases has been a rapidly emerging field with numerous clinical studies having been reported over the past decade.[28-42] A particularly notable population are those patients with primary colorectal cancer and liver metastases. Colorectal cancer patients who have undergone surgical resection for limited liver metastatic disease may have long term survival. This oligometastatic population may derive significant benefit from aggressive treatments of both their primary and metastatic disease sites, and an emerging paradigm in the metastatic disease setting is the potentially curative approach towards patients with limited metastatic tumor burden. In this setting, liver SBRT may hold promise as an approach to eradicate metastatic liver disease. The results from prospective clinical trials have reported promising results and are summarized in Table 3. To date, no randomized phase III data have been reported.

JAYPEE BROTHERS

Table 2: SBRT prospective trials for intrahepatic cholangiocarcinoma.

Study	*Year*	*Number of patients*	*Median follow-up*	*Dose fractionations*	*Local control*	*1-year overall survival*
Ben-Josef et al.	2005	46	16 months	60.75 Gy (40–90) in 1.5 Gy/fx, b.i.d.	70%	13.3 months
Goodman et al.	2010	5	17 months	18–30 Gy in one fraction	77%	71%
Tse et al.	2008	10	17.6 months	32.5 Gy (28.2–48) in six fractions	65%	58%
Ibarra et al.	2012	11	12.9 months	30 Gy (22–50), one to ten fractions	50%	45%
Barney et al.	2012	10	10 months	55 Gy (45–60) in three to five fractions	100%	73%
Dewas et al.	2012	6	15 months	39–45 Gy in three to four fractions	100%	100%
Goyal et al.	2010	3	8 months	34 Gy (24–45) in one to three fractions	67%	0%
Blomgren et al.	1995	1	NA	63 Gy in three fractions	NA	14 months

(SBRT: Stereotactic body radiotherapy; NA: Not available).

Table 3: SBRT prospective trials for liver metastases.

Study	*Year*	*Number of patients*	*Primary disease*	*Median follow-up*	*Dose fraction-ations*	*Local control*	*Median overall survival*
Herfarth et al.	2004	37 (33 with liver metastases)	18 CRC, 10 breast, and 5 other	15.1 months (mean)	14–26 Gy in one fraction	18-month 68%	25 months
Hoyer et al.	2006	64 (44 with liver metastases)	44 CRC	4.3 years	45 Gy in three fractions	2-year 86% by tumor; 2-year 63% by patient	1.6 years
Rusthoven et al.	2009	47	15 CRC, 10 lung, 4 breast, 3 ovarian, 3 esophageal, 2 HCC, 10 other	16 months	36–60 Gy in three fractions	1-year 95%, 2-year 92%	20.5 months
Lee et al.	2009	68	40 CRC, 12 breast, 16 other	10.8 months	27.7–60 Gy in six fractions	1-year 71%	17.6 months
Ambrosino et al.	2009	27	11 CRC, 16 other	13 months	25–60 Gy in three fractions	1-year 74%	NA
Van der Pool et al.	2010	20	20 CRC	26 months	37.5–45 Gy in three fractions	2-year 74%	34 months
Goodman et al.	2010	26 (19 with liver metastases)	6 CRC, 3 pancreatic, 2 gastric, 2 ovarian, 1 breast, 5 other	17.3 months	18–30 Gy in one fraction	1-year 77%	28.6 monhts
Rule et al.	2011	27	12 CRC, 3 carcinoid, 2 melanoma, 2 pancreas, 8 other	20 months	30 Gy in three fractions, 50 Gy in five fractions, 60 Gy in five fractions	2-year 56%, 89%, and 100%	37 months
Scorsetti et al.	2014	42	42 CRC	24 months	75 Gy in three fractions	2-year 91%	29.2 months

(SBRT: Stereotactic body radiotherapy; HCC: Hepatocellular carcinoma: CRC: Colorectal cancer; NA: Not available).

JAYPEE BROTHERS

The interpretation of the results from many of the SBRT trials in the metastatic liver setting have been confounded by the wide heterogeneity of the enrolled patients. These factors include heavy pretreatment with systemic therapy, variation in primary tumor histology, volume of metastases, and radiotherapy dose and fractionation. Despite these confounding variables, the literature generally reports a local control rate in the range of 70–100% at 1 year and 60–90% at 2 years.[37]

As with primary liver and biliary disease, there appears to be a dose-response relationship for local control. Other factors which appear to correlate with better outcomes include smaller tumor volumes, longer disease free intervals, adenocarcinoma histology, and metachronous disease presentation[38]. A recent meta-analysis concluded that a dose of 46–52 Gy in three fractions or higher is required to achieve 90% local control at 1 year for the treatment of colorectal liver metastases (equivalent to a biologically equivalent dose > 117)[39]. Other recent studies have pursued aggressive dose escalation up to 75 Gy in three fractions, reporting local control rates of 94% at 1 year[40].

For patients with larger tumors (>6 cm), dose escalation is challenging due to dose heterogeneity and normal tissues tolerances. In such cases, six to ten fraction regimens have been utilized and have reported 1-year local control rates ranging from 65–71%[41,42]. Even in the patient populations with significant disease burden and relatively poorer prognosis, fractionated liver radiotherapy has been demonstrated to be safe and can serve as a beneficial treatment option.

LANDMARK TRIALS

See Tables 1–3 for landmark trials.

CONCLUSION AND FUTURE DIRECTIONS

Liver radiotherapy historically has been a challenging area for clinical radiation oncologists due to concerns for radiation toxicity to the liver and nearby organs. Improved conformal technologies have created a rapidly expanding role for radiotherapy in treating patients with liver cancers, particularly with the advent of liver SBRT. The results of recent prospective clinical trials have confirmed this improved therapeutic window, and an enlarging body of literature indicate improved patient outcomes and perhaps long-term disease control when these newer techniques are used.[38,39,43,44] Randomized Phase III trials recently have opened and should further establish and define the role of liver radiotherapy in the management of liver cancers in the primary or metastatic setting.

In summary, liver radiotherapy, particularly with liver SBRT, appears to be safe and effective in hepatobiliary cancer management. In the setting of hepatocellular carcinoma, SBRT may serve a valuable role for low tumor burden patients unsuitable for surgery and favorable Child-Pugh status or for locally advanced disease patients with portal vein thrombosis or comorbidities where other local therapies are contraindicated. In patients with resected or unresectable cholangiocarcinoma, studies show promise that radiotherapy, whether utilizing SBRT or dose escalation, improve locoregional control. Finally, for selected patients with limited metastatic liver disease, liver SBRT may provide an ablative therapeutic option leading to long-term survival. The evidence for the role of liver radiotherapy has been rapidly accruing, ushering in an exciting era where it may be integrated with other treatment modalities to provide improved outcomes and perhaps even curative treatment options for many patients.

REFERENCES

1. Gunderson LL, Tepper J. Clinical Radiation Oncology, 3rd edition. Philadelphia: Elsevier/Saunders; 2011.
2. Halperin EC, Perez CA, Brady LW (Eds.). Principles and Practice of Radiation Oncology, 5th edition. Philadelphia, Pa: Lippincott Williams & Wilkins; 2008.
3. Phillips TL, Hoppe R, Roach M, et al. Textbook of Radiation Oncology, 6th edition. Philadelphia: Elsevier/Saunders; 2010.
4. Ingold JA, Reed GB, Kaplan HS, et al. Radiation hepatitis. Am J Roentgenol Radium Ther Nucl Med. 1965;93:200-10.
5. Reed GB Jr, Cox AJ Jr. The human liver after radiation injury. A form of veno-occlusive disease. Am J Pathol. 1966;48(4):597-611.
6. Guha C, Kavanagh BD. Hepatic radiation toxicity: avoidance and amelioration. Semin Radiat Oncol. 2011;21(4):256-63.
7. Lawrence TS, Robertson JM, Anscher MS, et al. Hepatic toxicity resulting from cancer treatment. Int J Radiat Oncol Biol Phys.1995;31(5):1237-48.
8. Emami B, Lyman J, Brown A, et al. Tolerance of normal tissue to therapeutic irradiation. Int J Radiat Oncol Biol Phys.1991;21(1):109-22.
9. Schefter TE, Kavanagh BD, Timmerman RD, et al. A phase I trial of stereotactic body radiation therapy (SBRT) for liver metastases. Int J Radiat Oncol Biol Phys. 2005;62(5):1371-8.

JAYPEE BROTHERS

10. Ben-Josef E, Normolle D, Ensminger WD, et al. Phase II trial of high-dose conformal radiation therapy with concurrent hepatic artery floxuridine for unresectable intrahepatic malignancies. J Clin Oncol. 2005;23:8739-47.
11. Mornex F, Girard N, Beziat C, et al. Feasibility and efficacy of high-dose three-dimensional-conformal radiotherapy in cirrhotic patients with small-size hepatocellular carcinoma non-eligible for curative therapies—mature results of the French Phase II RTF-1 trial. Int J Radiat Oncol Biol Phys. 2006;66:1152-8.
12. Kim TH, Kim DY, Park JW, et al. Three-dimensional conformal radiotherapy of unresectable hepatocellular carcinoma patients for whom transcatheter arterial chemoembolization was ineffective or unsuitable. Am J Clin Oncol. 2006;29: 568-57. Stereotactic radiation therapy of liver metastases: update of the initial phase-I/II trial.5.
13. Méndez Romero A, Wunderink W, Hussain SM. Stereotactic body radiation therapy for primary and metastatic liver tumors: a single institution phase i-ii study. Acta Oncol. 2006;45(7):831-7.
14. Tse RV, Hawkins M, Lockwood G. Phase I study of individualized stereotactic body radiotherapy for hepatocellular carcinoma and intrahepatic cholangiocarcinoma. J Clin Oncol. 2008;26(4):657-64.
15. Bujold A, Massey CA, Kim JJ. Sequential phase I and II trials of stereotactic body radiotherapy for locally advanced hepatocellular carcinoma. J Clin Oncol. 2013;31(13):1631-9.
16. Culleton S, Jiang H, Haddad CR. Outcomes following definitive stereotactic body radiotherapy for patients with Child-Pugh B or C hepatocellular carcinoma. Radiother Oncol. 2014;111(3):412-7.
17. Aitken KL, Hawkins MA. The role of radiotherapy and chemoradiation in the management of primary liver tumours. Clin Oncol (R Coll Radiol). 2014;26(9):569-80.
18. Kang JK, Kim MS, Cho CK, et al. Stereotactic body radiation therapy for inoperable hepatocellular carcinoma as a local salvage treatment after incomplete transarterial chemoembolization. Cancer. 2012;118:5424-31.
19. Khan SA, Davidson BR, Goldin RD, et al. Guidelines for the diagnosis and treatment of cholangiocarcinoma: an update. Gut. 2012;61:1657-69.
20. Jarnagin WR, Ruo L, Little SA, et al. Patterns of initial disease recurrence after resection of gallbladder carcinoma and hilar cholangiocarcinoma: implications for adjuvant therapeutic strategies. Cancer. 2003;98:1689-700.
21. Vern-Gross TZ, Shivnani AT, Chen K, et al. Survival outcomes in resected extrahepatic cholangiocarcinoma: effect of adjuvant radiotherapy in a surveillance, epidemiology, and end results analysis. Int J Radiat Oncol Biol Phys. 2011;81:189-98.
22. Shinohara ET, Mitra N, Guo M, et al. Radiotherapy is associated with improved survival in adjuvant and palliative treatment of extrahepatic cholangiocarcinomas. Int J Radiat Oncol Biol Phys. 2009;74:1191-8.
23. Cardenes HR, Price TR, Perkins SM, et al. Phase I feasibility trial of stereotactic body radiation therapy for primary hepatocellular carcinoma. Clin Transl Oncol. 2010;12: 218-25.
24. Barney BM, Olivier KR, Miller RC, et al. Clinical outcomes and toxicity using stereotactic body radiotherapy (SBRT) for advanced cholangiocarcinoma. Radiat Oncol. 2012;7:67.
25. Dewas S, Bibault JE, Mirabel X, et al. Prognostic factors affecting local control of hepatic tumors treated by stereotactic body radiation therapy. Radiat Oncol. 2012;7:166.
26. Goyal K, Einstein D, Yao M, et al. Cyberknife stereotactic body radiation therapy for nonresectable tumors of the liver: Preliminary results. HPB Surg. 2010;2010.
27. Blomgren H, Lax I, Naslund I, et al. Stereotactic high dose fraction radiation therapy of extracranial tumors using an accelerator. Clinical experience of the first thirty-one patients. Acta Oncol. 1995;34:861-70.
28. Herfarth KK, Debus J, Wannenmacher M. Stereotactic radiation therapy of liver metastases: update of the initial phase-I/II trial. Front Radiat Ther Oncol. 2004;38:100-5.
29. Hoyer M, Roed H, Traberg Hansen A. Phase II study on stereotactic body radiotherapy of colorectal metastases. Acta Oncol. 2006;45(7):823-30.
30. Wulf J, Guckenberger M, Haedinger U. Stereotactic radiotherapy of primary liver cancer and hepatic metastases. Acta Oncol. 2006;45(7):838-47.
31. Rusthoven KE, Kavanagh BD, Cardenes H. Multi-institutional phase I/II trial of stereotactic body radiation therapy for liver metastases. J Clin Oncol. 2009;27(10):1572-8.
32. Van der Pool AE, Méndez Romero A, Wunderink W. Stereotactic body radiation therapy for colorectal liver metastases. Br J Surg. 2010;97(3):377-82.
33. Goodman KA, Wiegner EA, Maturen KE. Dose-escalation study of single-fraction stereotactic body radiotherapy for liver malignancies. Int J Radiat Oncol Biol Phys. 2010;78(2):486-93.
34. Rule W, Timmerman R, Tong L. Phase I dose-escalation study of stereotactic body radiotherapy in patients with hepatic metastases. Ann Surg Oncol. 2011;18(4):1081-7.
35. Ambrosino G, Polistina F, Costantin G. Image-guided robotic stereotactic radiosurgery for unresectable liver metastases: preliminary results. Anticancer Res. 2009;29(8):3381-4.
36. Scorsetti M, Comito T, Tozzi A. Final results of a phase II trial for stereotactic body radiation therapy for patients with inoperable liver metastases from colorectal cancer. J Cancer Res Clin Oncol. 2015;141(3):543-53.
37. Hoyer M, Swaminath A, Bydder S, et al. Radiotherapy for liver metastases: a review of evidence. Int J Radiat Oncol Biol Phys. 2012;82(3):1047-57.
38. De Vin T, Engels B, Gevaert T, et al. Stereotactic radiotherapy for oligometastatic cancer: a prognostic model for survival. Ann Oncol. 2014;25(2):467-71.
39. Chang DT, Swaminath A, Kozak M, et al. Stereotactic body radiotherapy for colorectal liver metastases: a pooled analysis. Cancer. 2011;117(17):4060-9.

JAYPEE BROTHERS

40. Scorsetti M, Arcangeli S, Tozzi A, et al. Is stereotactic body radiation therapy an attractive option for unresectable liver metastases? A preliminary report from a phase 2 trial. Int Radiat Oncol Biol Phys. 2013;86(2):336-42.
41. Aitken KL, Tait DM, Nutting CM, et al. Risk adapted strategy partial liver irradiation for the treatment of large volume metastatic liver disease. Acta Oncol. 2014;53(5): 702-6.
42. Lee MT, Kim JJ, Dinniwell R. Phase I study of individualized stereotactic body radiotherapy of liver metastases. J Clin Oncol. 2009;27(10):1585-91.
43. Aitken KL, Hawkins MA. Stereotactic body radiotherapy for liver metastases. Clin Oncol (R Coll Radiol). 2015;27(5):307-15.
44. Klein J, Dawson LA. Hepatocellular carcinoma radiation therapy: review of evidence and future opportunities. Int J Radiat Oncol Biol Phys. 2013;87:22-32.

JAYPEE BROTHERS

for detailed information on gastroenterology books, visit our website **www.jaypeebrothers.com**, for detailed information on gastroenterology books, visit our webs

Evidence-Based Practices in GASTROINTESTINAL, COLORECTAL AND HEPATOBILIARY SURGERY

Evidence-based Practices in Gastrointestinal, Colorectal and Hepatobiliary Surgery is meant to be a practical guide for the young gastrointestinal surgeon or trainee. The book has a global authorship and is focused on evidence-based care and multidisciplinary care of the complex gastrointestinal or liver patient. The chapters are succinct yet comprehensive making it an efficient read. The practical approach of the book will make it a good adjunct to textbooks that address the pathophysiology and basic science of disease processes.



Govind Nandakumar MD FACS FASCRS completed his medical school at Mount Sinai School of Medicine, and completed his basic surgical training at Weill Cornell Medical College, and Memorial Sloan Kettering Cancer Center, New York, USA. He completed his advanced Colorectal Fellowship at Washington University in St. Louis and his upper gastrointestinal and hepatobiliary training at Weill Cornell Medical College, New York, USA. Subsequently, he was recruited to the division of Gastrointestinal Surgery at Weill Cornell Medical College and continues to maintain his faculty appointment at Weill Cornell Medical College. In 2015, he was recruited to Columbia Asia Referral Hospital, Bengaluru, Karnataka, India to build a state-of-the-art integrated gastrointestinal and liver center.

He has an interest in developing innovative and endoluminal approaches to gastrointestinal surgery. He also has a special interest in evidence-based, multidisciplinary and integrated care for gastrointestinal and liver diseases. He has written several articles and book chapters in leading surgical textbooks on topics within gastrointestinal surgery. He is a reputed teacher and has received several teaching and training awards from students, residents and fellows. He is an active member of the SSAT, ASCRS, ACS, SAGES, IHPBA, SSO, IASG and the ASI.

Reviews

"Dr. Govind Nandakumar used his experience at the Center for Advanced Digestive Care (CADC) at the New York Presbyterian Hospital and is in the process of developing a similar center called the Integrated Digestive Liver and Cancer Centre (IDLCC) at Columbia Asia Hospitals, Bangalore".

—Jeffrey W Milsom MD

"Dr. Govind Nandakumar, an experienced gastrointestinal surgeon, has edited a very comprehensive book on the topic with contributions from an outstanding group of authors. The evidence based approach and the section on "Landmark Trials" gives the necessary background information and yet encourage the reader to constantly review and update the ever changing literature".

—Fabrizio Michelassi, MD

"Dr. Govind Nandakumar has chosen a topic and author list to dissipate knowledge in the field of surgical gastroenterology in an evidence-based, comprehensive and yet concise manner. Global authorship, well-defined chapters that address topics of relevance and importance are delivered with clarity".

—Nandakumar Jairam MBBS MS

Available at all medical bookstores or buy online at www.jaypeebrothers.com

JAYPEE BROTHERS
Medical Publishers (P) Ltd.
www.jaypeebrothers.com

Join us on facebook.com/JaypeeMedicalPublishers

Shelving Recommendations
SURGERY, GASTROINTESTINAL, ONCOLOGY, COLORECTAL AND HEPATOBILIARY

ISBN 978-93-5152-939-2
9 789351 529392