thers.com, for detailed information on dermatology books, visit our website www.jaypeebrothers.com, for detailed information on dermatology books

RECONSTRUCTIVE DERMATOLOGIC SURGERY



S Brian Jiang
Arisa E Ortiz

JAYPEE

Contents

1. Surgical Space and Equipment **1**

Lee M Miller, Vineet Mishra

- Types of Facilities *1*
- Accreditation *2*
- Laboratory Certification *2*
- Understanding the Market *2*
- Clinical Space *3*
- Leasing versus Owning *3*
- Equipment *4*
- Surgical Beds *4*
- Lighting *4*
- Smoke Management *4*
- Sterilization *6*
- Personnel *7*

2. Surgical Instruments **9**

Ashley G Rubin, Arisa E Ortiz, S Brian Jiang

- Scalpel Handles *9*
- Scalpel Blades *9*
- Needle Holders *10*
- Forceps *12*
- Scissors *13*
- Other Instruments *16*
- Nail Surgery Instruments *17*
- Surgical Tray *18*
- Safety *19*

3. Facial Anatomy **21**

Thomas D Griffin Jr, Mary Larijani, Ezra Hazan, Nazanin Saedi

- Surface Anatomy of the Face *21*
- Facial Innervation *27*

4. Preoperative Considerations **32**

Margaret W Mann, Megan Morrison, Scott Santilli, Aleta Simmons

- Anesthesia in Dermatologic Surgery *32*
- Antibiotic Prophylaxis in Dermatologic Surgery *40*
- Anticoagulation Management in Dermatologic Surgery *44*

5. Postoperative Considerations **52**
Anne Zhuang, S Brian Jiang
- Bandaging *52*
- Dressings and Bandages *53*

6. Suturing Techniques **59**
Robert Edwin Eilers Jr, Arisa E Ortiz, S Brian Jiang
- Loading the Needle *59*
- Handling the Needle and Suture *59*
- Handling the Tissue *59*
- The Simple Instrument Tie *59*
- Preoperative Considerations *60*
- Suture Techniques *62*

7. Flap Classification and Design/Biomechanics of Skin **72**
Andrew Breithaupt, Patrick K Lee
- Biomechanics of Skin Flaps *80*
- Flap Physiology *82*

8. Advancement Flaps **86**
Laura Kruter, Thomas Rohrer
- Flap Design and Considerations *86*
- Applications *94*

9. Rotation Flaps **96**
Tushar Dabade, Bichchau Michelle Nguyen
- Unilateral Rotation Flaps *96*
- Bilateral Rotation Flaps *100*

10. Transposition Flaps **104**
Jennifer Herrmann, Michelle Levender, Sarah Tuttleton Arron
- Types *104*
- Applications *110*

11. Staged Flaps **119**
Jesse M Lewin, John A Carucci

12. Skin, Cartilage, and Composite Grafts **147**
Syril Keena T Que, Omar A Ibrahimi
- Graft Types *147*

13. Combination Repairs **159**
Sailesh Konda, Swati Kannan, Suneel Chilukuri
- Nasofacial Sulcus *160*
- Cheek *161*
- Nose *162*
- Forehead *165*
- Ear *169*
- Chin *172*

14. Reconstruction of the Nose 174
Bassel H Mahmoud, Suzanne M Olbricht
- Instrumentation *176*
- Nasal Repair Options *176*
- Flap Reconstruction *181*
- Complications *188*

15. Eyelid and Periorbital Reconstruction 191
Ian A Maher, Joseph Kallini, Jeremy S Bordeaux
- Anatomy *191*
- Assessment of the Wound *193*
- Reconstruction of Anterior Lamellar Defects *193*
- Reconstruction of Full-Thickness Eyelid Defects *202*

16. Reconstruction of the Lip/Perioral 207
G Richard Nichols, T Minsue Chen, J Ramsey Mellette
- Reconstruction Planning *208*
- Location *209*

17. Reconstruction of the Cheek 251
Daniel Y Sugai, Daihung V Do
- Anatomy of the Cheek *251*

18. Forehead Reconstruction 269
Jennifer Herrmann, Consuelo V David, Lisa Chipps
- Reconstructive Planning *270*
- Reconstruction by Location *273*

19. Reconstruction of the Ear 287
Robert Egbers Jr, Sarah M Sung, Timothy Wang
- Auricular Architecture *288*
- Ear Reconstruction *289*

20. Reconstruction of the Scalp 295
Brian Hibler, Anthony M Rossi, Kishwer S Nehal
- Anatomy *295*
- Reconstruction Planning: Basic Tenets *297*
- Reconstruction Planning: Methods of Closure *299*
- Complications and Postoperative Care *314*

21. Reconstruction of the Hand/Nail 317
Joseph F Sobanko, Christopher J Miller
- Anatomy Overview *317*
- Planning Reconstruction *323*
- Digital Reconstruction *332*
- Postoperative Wound Care *341*

22. Scar Revision 344
Steven Chow, Richard G Bennett
- Scar Assessment *344*

- Time to Revise a Scar *344*
- Fusiform Excision *344*
- Trapdoor Deformity Repair *345*
- Z-Plasty *346*
- Running W-Plasty *348*
- V-to-Y Advancement Flap *350*

23. Scar Refinement **353**

Anne Marie Tremaine, Arisa E Ortiz, Mathew M Avram

- Prevention *353*
- Laser Treatments *354*
- Dermabrasion *358*
- Subcision *359*
- Intralesional Injections *359*
- Pressure *359*
- Radiation *359*
- Re-Excision *360*
- Other Modalities *360*

24. Complications **363**

Brienne Cressey, Murad Alam, Kira Minkis

- Complications of Local Anesthesia: Lidocaine Toxicity *363*
- Bleeding/Hemorrhage Complications *364*
- Infectious Complications *366*
- Wound Failure and Tissue Ischemia Complications *372*
- Complications by Anatomic Location *375*
- Emergencies in Dermatologic Surgery *375*
- Motor Nerve Transection *376*

Index *381*

CHAPTER

3

Facial Anatomy

Thomas D Griffin Jr, Mary Larijani, Ezra Hazan, Nazanin Saedi

JAYPEE BROTHERS

INTRODUCTION

A thorough understanding of facial anatomy is crucial for dermatologic surgery. Fundamental components of this knowledge include the location and function of individual skeletal bones, muscles, nerves, and vessels. Herein, we review these components as well as discuss other structures and danger zones relevant in dermatologic surgery.

SURFACE ANATOMY OF THE FACE

The bony architecture of the face determines the facial appearance of an individual and creates anatomic landmarks for structures underlying the skin. The face is composed of the frontal bone, mandible, and the midface.[1] The midface bones consist of the maxillae, palatine bones, nasal bones, lacrimal bones, ethmoid bones, turbinates, zygomatic bones, and zygomatic processes of temporal bones.[1] Many of these bones serve as attachments for overlying muscles—muscles of facial expression and muscles of mastication. Anatomic locations can be seen in Figures 3.1 and 3.2.

From the hairline of the scalp to the chin there are numerous anatomical features that are consistent between individuals. Eyebrows are curvilinear growths of hair overlying the supraorbital ridges formed by the frontal bone.[1] Between the eyebrows is a hairless region that is termed the glabella.[2] Above the eyebrows and extending laterally are the supraciliary arches. The eyelids are mobile folds that overlie the orbit.[3] The medial and lateral canthi are the points at which the superior and inferior eyelids join together. The depressions superior and inferior to the eyelids are called the supra- and infrapalpebral sulci, respectively.[3]

Below the glabella is the beginning of the surface of the nose. The most superior aspect of the nose is termed the root.[1] The root is an indentation where the nasal

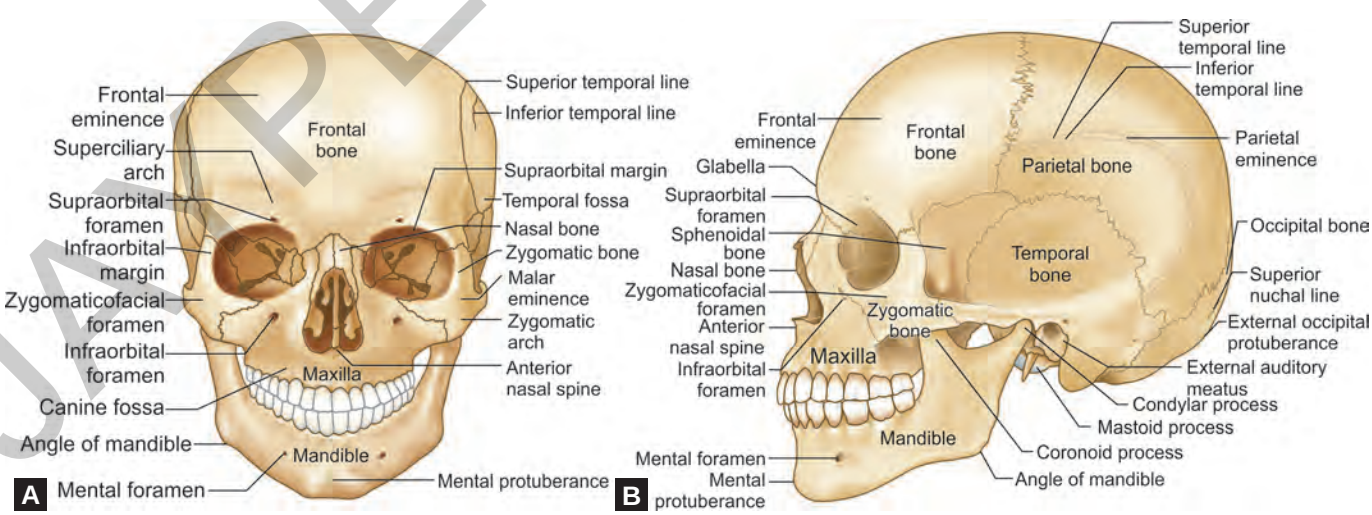

Figs. 3.1A and B: Bony landmarks of the skull: (A) anterior view; (B) lateral view.

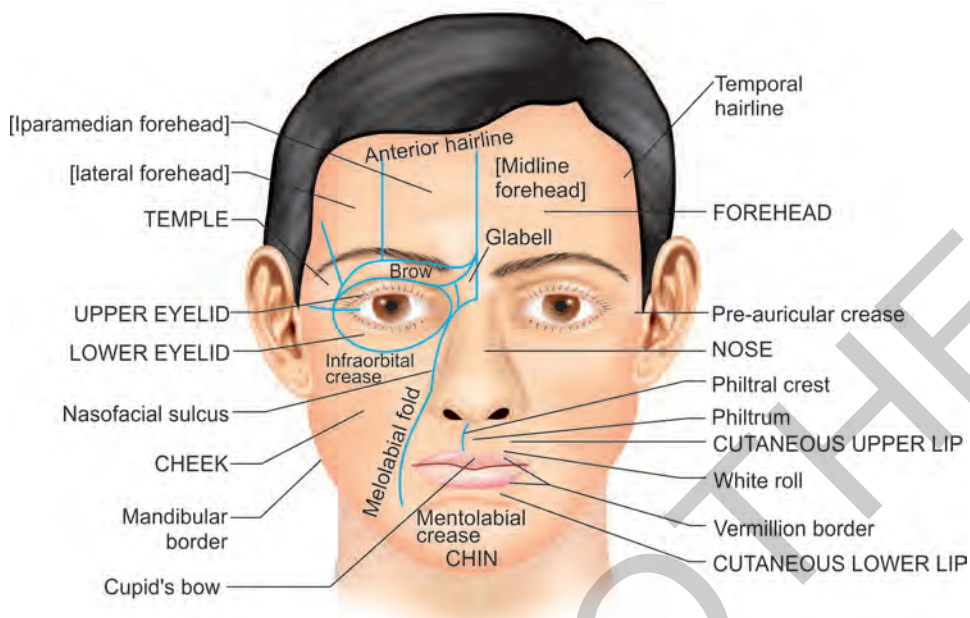

Fig. 3.2: Facial cosmetic units (capital letters), forehead subunits [brackets], and junction lines.

bone and frontal bone intersect.[1] The dorsum of the nose connects the root to the nasal tip. Lateral to the nasal dorsum and continuous with the cheeks is the nasal sidewall. The openings of the nose are termed the nares, and they are divided by the columella.[4] The soft triangles are on the underside of the nose anterior to the nares and lateral to the columella.[4] The nasal ala is superior to the nares and lateral to the nasal tip.

The oral fissure is the opening of the mouth. The vermilion border is the transition between the pink mucosa of the lip and the cutaneous lip.[4] The upper and lower lips come together at the corner of the mouth to form the lateral commissure.[4] The philtrum is a vertical groove superior to the upper lip.[4]

The nasolabial fold is a sulcus that extends obliquely between the ala of the nose and the angle of the mouth. It divides the cheeks laterally from the lips medially.[4] The mentolabial crease is a sulcus that divides the mental protuberance from the inferior lip (Fig. 3.2).

Cosmetic Units and Subunits

Variations in color, texture, thickness, elasticity, pore density and size, hairiness, and amount of sebaceous glands delineate various subunits of skin on the face.[5] These units are referred to as cosmetic units. Major cosmetic units include the forehead, temples, cheeks, eyelids, nose, upper and lower lips, chin, and ears.[5-7] Cosmetic subunits can be appreciated by locating contour or junction lines, which separate various subunits.[5] These include the nasofacial sulcus, melolabial fold, preauricular crease, and mentolabial crease (Figs. 3.2 and 3.3).

Each cosmetic subunit has distinct topical anatomical features that are important for facial reconstructive surgery, as they assist in guiding incisions as well as demarcating the underlying musculature. Additionally, care is taken to ensure that defects generated during facial surgery are reconstructed with tissue from the same cosmetic subunit to optimize tissue match.

Skin Tension Lines

Facial lines are superficial anatomic features that can enhance the cosmetic appearance of postsurgical scars through camouflaging surgical incisions in the natural contours and lines of the skin.[5,8,9] These include junction lines and skin tension lines. Additional facial lines include wrinkles and lines of facial expression, which are created from the contraction of the underling muscles.[10]

Junction lines demarcate the cosmetic units of the face. These lines are depicted in Figs. 3.2 and 3.3.[5] The junction lines of the upper face include the frontal and temporal hairlines, eyebrows, and glabellar creases. The midface includes the melolabial folds, alar grooves, nasofacial

JAYPEE BROTHERS

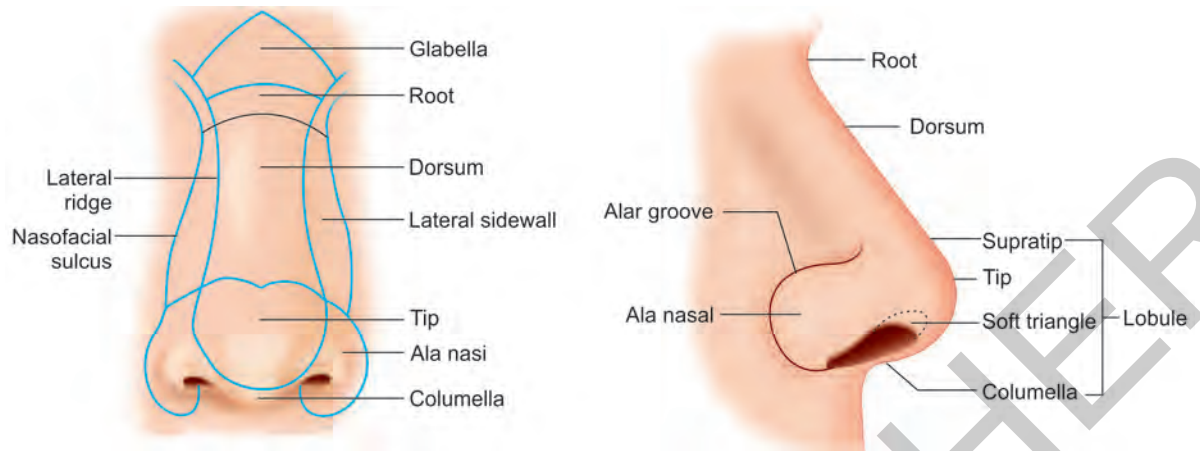

Fig. 3.3: Nasal cosmetic subunits and junction lines.



Fig. 3.4: Skin tension lines (left) and underlying facial muscles (right).

sulcus, and infraorbital crease.[5,8,9] The lower face includes the philtrum, vermillion-cutaneous junction, and mentolabial crease.[5] Laterally, the preauricular crease acts as an additional junction line for defects in this area[5] (Figs. 3.2 and 3.3).

Unlike junction lines, no single pattern has been described for skin tension lines. The depiction of skin tension lines described by Borges and Alexander in 1962[10] is one that has been commonly used.[5] Borges and Alexander described relaxed skin tension lines as a reflection of underlying tension created by a tenting effect of skin over underlying bony, cartilaginous, and soft tissue structures.[5,10] Skin tension lines run perpendicular to the underlying facial muscles, as is seen in Fig. 3.4,[5] with a more horizontal directionality at the midline and more vertical directionality at the lateral border.[11] In order to find skin tension lines, which are not as clearly visible, one can pinch the skin to detect the natural direction of skin lines[5,8,9] (Fig. 3.3).

Superficial Musculoaponeurotic System

The superficial musculoaponeurotic system (SMAS) is a fibrous network of collagen fibers, elastic fibers, fat cells, and muscle fibers that serves to connect the facial muscles to the dermis.[12,13] A continuous and organized three-dimensional structure, the SMAS extends from the platysma into the face, temporal area, and onto the forehead as the galea aponeurotica.[12] This facial layer serves a functional role in the coordination of facial expression and contributes to organize facial movement, facial symmetry, and skin tension lines.[14] For the surgeon, the SMAS serves as a convenient and relatively avascular dissection plane and protection for important underlying structures. The SMAS is also an important structure for facelift and rejuvenation procedures where it is utilized for tissue mobilization.[15]

Ghassemi et al. describe two different architectural models for the SMAS. Type 1 is located in the forehead, parotid, zygomatic, and infraorbital areas.[12] It is a meshwork of fibrous septa that envelops fat cells. These septae project perpendicularly between fat lobules and connect to facial muscles or periosteum deep and the dermis

JAYPEE BROTHERS

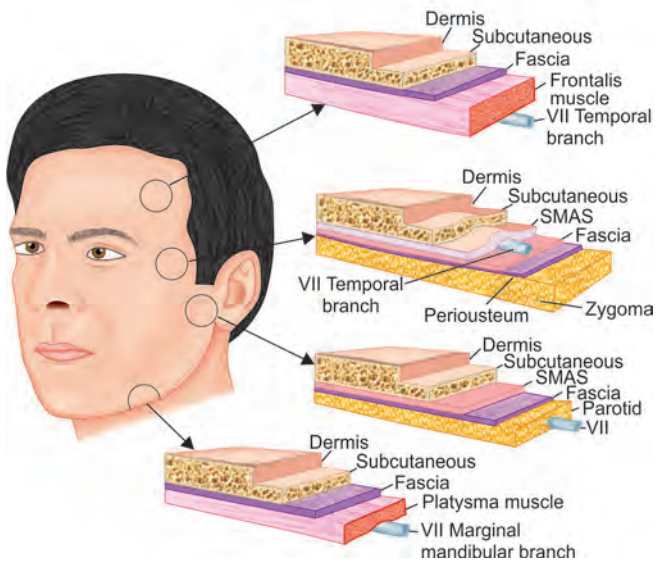

Fig. 3.5: Cross-sectional anatomy of facial soft-tissue layers of high-risk areas susceptible to damage during dermatologic surgery in relation to the facial nerve. SMAS, superficial musculoaponeurotic system.

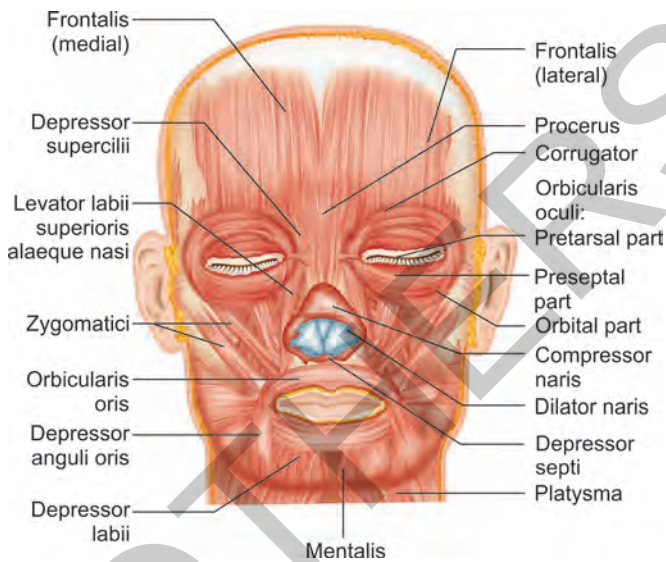

Fig. 3.6: Mimetic facial muscles.

superficially. Type II SMAS is found medial to the melolabial fold and in the upper and lower lips.[12] Here, the SMAS is thin and the dense meshwork of collagen, and elastic fibers are entwined with muscle and nerves to help transmit the complex movements of the mouth.

Although the SMAS is considered to be one continuous facial plane, the SMAS of the upper face is discontinuous with the SMAS below the zygoma. There is also considerable regional variation in the thickness and composition of the SMAS.[12] Whereas the SMAS near the mouth is thin, in the temporal area and forehead, where the facial muscles are absent, the SMAS is a thick, inelastic membrane.[12] Over the parotid gland, the SMAS is particularly thick to cover the parotid gland and the facial nerve.[15]

The SMAS lies in a facial plane that divides the subcutaneous fat from the facial muscles. In general, large sensory nerves and axial blood vessels supply the face branch within the SMAS and run in the subcutaneous fat superficial to the SMAS[14] (Fig. 3.5). Motor nerves, on the other hand run deep to the SMAS.[14] Although sensory nerves can be injured, undermining in the subcutaneous fat above the level of the SMAS allows for a safe and relatively avascular dissection plane.[14] However, there are exceptions to this rule. The supraorbital and supratrochlear neurovascular bundles can be injured in the forehead when dissecting to the galea. The superficial temporal vessels and auriculotemporal nerve lie within and above the fascia above the zygomatic arch.[12] Also, the buccal and zygomatic branches of the facial nerve can be injured in the parotid area.[12]

Facial Musculature

Mimetic Muscles

The facial musculature is composed of the mimetic muscles, also known as the muscles of facial expression, and the masticatory muscles. Mimetic muscles are characteristically thin, flat, and located in the midline of the face.[2,16] These muscles are involved in the expression of thought and feeling, as well as performing a sphincteric action for the eyes and mouth.[2,16]

Upper Face

Frontalis: The frontalis muscle originates from the anterior belly of the occipitofrontalis muscle in the epicranium.[2,16,17] It descends vertically to insert into the orbicularis oculi, corrugator supercilii muscles, and dermis over the brows.[2,16,17] The frontalis maintains the resting brow position and elevate the brows, creating horizontal forehead furrows characteristic of a surprised look (Fig. 3.6).[2,16,17]

Orbicularis oculi: The orbicularis oculi muscle is a broad muscle composed of concentric striated fibers that encircle the orbital rim.[2,3,17] It is composed of three portions: the orbital, pretarsal, and preseptal. The orbital portion originates in the nasal segment of the frontal bone, the frontal

JAYPEE BROTHERS

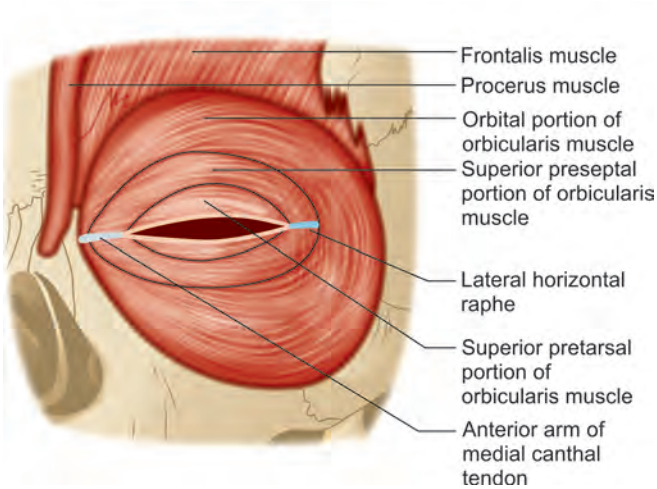

Fig. 3.7: Orbicularis oculi muscle anatomy.

process of the maxilla, and the anterior portion of the medial canthal tendon, which serves as a dense area of connective tissue.[2,3] The orbital muscle blends over the frontalis to insert subcutaneously into the lateral canthus and orbital region to cover some of the elevators of the upper lip and ala.[2,17] The orbital portion lowers the upper eyelid and depresses the brow[2] (Fig. 3.7).

The pretarsal portion originates from the upper and lower tarsal plates as well as the innermost medial canthal tendon, and it inserts into the lateral canthal tendon and palpebral raphe.[2,3] The pretarsal portion maintains the canthal angle position, secures the eyelid against the globe, and assists with the blinking reflex and lacrimal pump.[2,3,16]

The preseptal portion originates at the medial canthal tendon.[3,17] It passes over the orbital septum, a fibrous connective tissue encircling the orbit, to insert into the lateral palpebral raphe.[2] The preseptal portion functions similarly to the pretarsal, and produces characteristic "crow's feet" lines at the lateral orbital margin.[17]

Corrugator supercilii:The corrugator supercilii muscle originates from the medial end of the superciliary arch of frontal bone and the superomedial aspect of the orbital rim.[2,16] The muscle passes superolaterally to insert into the dermis of the brow deep to the frontalis and orbicularis oculi muscles.[3,16] The corrugator supercilii depresses the brows and contracts the brow medially, producing characteristic vertical lines in the glabellar region known as "frown lines".[2,16,17]

Depressor supercilii: The depressor supercilii muscle is a thin muscle that originates from the superomedial fibers of the orbital part of orbicularis oculi.[16] The muscle fibers insert into the medial brow to depress the brow.[16,17] Contraction forms vertical creases in the glabellar and lower medial forehead known as "frown lines".[17]

Procerus: The procerus muscle originates from the lower nasal bone. The muscle passes superiorly to insert into the dermis of the glabella between the corrugator muscles and fuses with the corrugator supercilii and medial portion of the orbicularis oculi muscles.[2] The muscle depresses the forehead and produces horizontal creases at the bridge of nose, also known as "glabellar lines".[2,16,17]

Eyelids

In addition to the orbicularis oculi that surrounds the orbit, there are several muscles that are distinct to the eyelid.

Levator palpebrae superioris:The levator palpebrae superioris muscle fibers blend with orbicularis oculi and insert into the lower third of the superior tarsal plate.[3] The tarsal plates serve as a semi rigid support of the eyelid fibroskeleton.[3] The levator palpebrae superioris elevates and retracts the upper eyelid. The mechanism works through anterior-posterior redirection of the levator muscle that is modulated by a fibrous sleeve of tissue intrinsic to the muscle known as the Whitnall ligament.[3]

Superior tarsal muscle or Müller's muscle:The superior tarsal muscle, also referred to as Müller's muscle, originates below the levator palpebrae superioris and inserts onto the superior tarsal plate of the upper eyelid.[3] The superior tarsal muscle contributes an extra fewmillimeters of eyelid retraction.[3]

Lower eyelid retractors: The lower eyelid retractors originate in the capsulopalpebral head, an extension of the terminal fibers and tendon of the inferior rectus and oblique muscles.[3] These muscle fibers project through the orbicularis oculi to form the transverse eyelid crease visible below the inferior tarsal plate.[3]

Midface

Nasalis: The nasalis muscle is composed of two portions, the upper transverse or compressor naris, and the lower alar portion or dilator naris. The compressor naris portion originates over the canine tooth and passes superomedially to the nasal dorsum where it decussates with fibers from the opposite side.[2,16] The compressor naris compresses the nasal aperture between the vestibule and nasal cavity.[2]

JAYPEE BROTHERS

The dilator naris originates from the maxilla, inferomedially to the compressor naris.[2] Muscle fibers insert into the alar cartilage of the nose.[2] The dilator naris muscle functions to depress the ala laterally, causing dilation of the nostrils and opening of the nasal aperture, assisting air entry during exercise or deep inspiration.[17] Excess contraction of these muscles causes the characteristic "bunny lines" on the nasal dorsum.[2]

Levator labii superioris alaeque nasi: The levator labii superioris alaeque nasi muscle originates in the frontal process of the maxilla.[2,16,17] The muscle fibers pass inferolaterally to blend with the orbicularis muscle, and insert into the lateral nasal cartilage and the upper lip.[2,16,17] The levator labii superioris alaeque nasi muscle dilates the nasal ala, and everts the upper lip.[17]

Levator labii superioris: The levator labii superioris muscle originates lateral to the levator labii superioris alaeque nasi muscle, and superior to the infraorbital foramen.[2] The muscle fibers descend deep to the orbicularis oculi to insert into the upper lip muscular slip lateral to the insertion of the levator labii superioris alaeque nasi fibers.[2,17] The levator labii superioris elevates and everts the upper lip, as well as deepens the nasolabial fold.[2,17]

Zygomaticus major: The zygomaticus major muscle originates from the zygomatic bone.[2,17] It passes inferiorly to insert into the modiolus at the corner of the mouth, where the fibers blend with the orbicularis oris and levator anguli oris muscle fibers.[2,17] The modiolus is a dense, fibromuscular interface of muscles that functions as a scaffold for muscles to pull on.[17] The zygomaticus major draws the angle of the mouth superiorly while smiling.[17]

Zygomaticus minor: The zygomaticus minor muscle originates medially to the zygomaticus major, on the lateral surface of the zygomatic bone.[17] It passes inferomedially to insert into the upper lip lateral to the levator labii superioris muscle insertion.[2] The zygomaticus minor elevates the upper lip to expose the maxillary teeth while smiling, as well as deepens the nasolabial fold.[2,17]

Levator anguli oris: The levator anguli oris originates in the canine fossa of the maxilla below the infraorbital foramen.[16,17] The muscle fibers insert into the upper lip at the modiolus.[17] The levator anguli oris functions to elevate the corners of the mouth.[16]

Buccinator: The buccinator muscle originates from the pterygomandibular raphe, the lateral alveolar process of the maxilla, and the mandible.[16] The muscle fibers move toward the modiolus and into the orbicularis oris muscle fibers.[16] The buccinator presses the cheek against the molar teeth to aid in bolus control of chewing and swallowing.[16,17]

Orbicularis oris: The orbicularis oris muscle acts as a sphincter for the mouth and is composed of both deep and superficial portions.[2,17] The deep portion, also known as pars peripheralis, connects to each oral commissure at the modiolus to bring the mouth together.[2,17] The superficial portion, also known as pars marginalis, originates deep to the vermilion border and interlaces with other facial muscles to retract the lower lip.[2] The orbicularis oris muscle contraction produces characteristic fine rhytides around the vermilion border.[17]

Risorius: The risorius muscle origin is variable, including the zygomatic arch, parotid and masseteric fascia, as well as thickening of the platysma over the lateral cheek.[2,16] The muscle fibers insert into the modiolus at the edge of the oral commissure.[2] The risorius muscle pulls the corners of the mouth laterally during laughing.[2,16]

Depressor septi: The depressor septi muscle originates in the maxilla.[2] The muscle fibers pass superiorly to attach to the inferior surface of the nasal septum cartilage to pull the nasal septum inferiorly.[2]

Lower Face and Neck

Depressor labii inferioris: The depressor labii inferioris muscle originates in the oblique line of the mandible and is found deep to the depressor anguli oris muscle and mental foramen.[2,17] The fibers pass superomedially to the skin and mucosa of the lower lip and into the fibers of the orbicularis oris muscle.[16] The depressor labii inferioris muscle depresses, laterally pulls, and everts the lower lip.[17]

Depressor anguli oris: The depressor anguli oris originates from the mental tubercle of the mandible.[16,17] The fibers pass superomedially to converge at the lateral lower lip and modiolus.[17] The depressor anguli oris muscle depresses the lateral corner of the lower lip and everts the lower lip.[2] Increased contraction of this muscle can produce characteristic radially oriented lower lip lines or "marionette lines".[17]

Mentalis: The mentalis muscle originates in the incisive fossa of the mandible and inserts into the dermis of the chin.[2,17] The mentalis pulls the chin and lip upward, causing wrinkling of the skin overlying the chin.[17] Excess

JAYPEE BROTHERS

contraction of this muscle cancause characteristic dimpling of the chin or a "peau d'orange" appearance.[16,17]

Platysma: The platysma muscle is a thin, sheet-like muscle that originates from the fascia of the upper parts of the pectoralis major and deltoid muscles.[2,16,17] The muscle fibers ascend superiorly to insert into the inferior border of the mandible, perioral muscles, modiolus, and dermis of the cheek.[16] Laterally, the fibers pass posteriorly at the angle of the mandible, and meet in the midline to form an inverted V at the lower chin region.[2,17] The platysma muscle pulls the angle of mouth laterally and inferiorly acting as a depressor of the lower lip and mandible during deep inspiration.[2]

Digastric: The digastric muscle is composed of anterior and posterior bellies. The posterior belly originates in the mastoid notch of the temporal bone.[16] Muscle fibers pass anteriorly and inferiorly to insert into the hyoid bone.[16] The anterior belly originates at the junction of the digastric and intermediate tendons and inserts into the digastric fossa of the mandible near the midline.[16] The digastric muscle depresses and retracts the mandible as well as supports the hyoid bone.[16]

Masticatory Muscles

The masticatory muscles are located on the lateral aspect of the face, deep to the fascia of the midface.[2] They include the temporalis, masseter, medial, and lateral pterygoid muscles.

Temporalis: The temporalis muscle originates from the frontal, temporal, sphenoid, and parietal bones on the lateral aspect of the cranium.[2] The muscle passes inferiorly through a gap lateral to the zygomatic arch to insert on the apex of the coronoid process.[2] The temporalis muscle elevates the mandible and retracts the mandible from protrusion.[2]

Masseter: The masseter muscle originates from the incisive fossa of the mandible.[16,17] The muscle fibers insert into the dermis of the chin.[16,17] The masseter muscle closes the jaw and retracts the mandible.[2]

Lateral pterygoid: The lateral pterygoid is composed of a superior and inferior head. The superior head originates from the infratemporal surface and crest of the greater wing of the sphenoid bone.[2] The inferior head of the lateral pterygoid muscle originates from the lateral plate of the pterygoid process.[2] Both heads insert into the neck of the mandible and capsule of the temporomandibular joint.[2] The lateral pterygoid opens the lower jaw, protrudes the mandible, and moves it from side to side.[2]

Medial pterygoid:The medial pterygoid muscle consists of both a superficial and deep head. The superficial head originates from the medial aspect of the lateral pterygoid plate, and the deep head originates from the tuberosity of the maxilla.[2] Fibers from both heads pass posterolaterally to the mandibular foramen into the medial surface of the mandibular ramus.[2] The medial pterygoid muscle elevates the mandible.[2]

FACIAL INNERVATION

Sensory Innervation

Sensory innervation to the face is mostly provided by the three trunks of the trigeminal nerve, the fifth cranial nerve (CNV).[16-18] The three trunks are the ophthalmic, maxillary, and mandibular.[4] The great auricular nerve also contributes to facial sensation. Sensory nerves generally travel between the subcutaneous fat and SMAS layers.[12]

The ophthalmic division, V1, enters the orbit through the superior orbital fissure as three branches, lacrimal, nasociliary, and frontal.[4,16,17] The lacrimal branch supplies the lateral part of the upper eyelid.[16,17] The nasociliary branch supplies the glabella, nasal dorsum, and medial part of the upper eyelid.[16,17] The frontal branch supplies the forehead, anterior scalp, and periorbital regions via the supraorbital and supratrochlear nerves, which exit the supraorbital foramen and the more medial supratrochlear notch, respectively.[16]

The maxillary division, V2, supplies the midface.[16,17] The zygomaticotemporal and zygomaticofacial branches supply the skin overlying the zygoma and lateral canthus. The maxillary nerve then travels through the infraorbital canal as it supplies the nasal floor, upper alveolar ridge, gingiva, and palate.[17] Its largest branch, the infraorbital nerve, enters the face through the infraorbital foramen and supplies the lower eyelid, ala of nose, and upper lip.[16]

The mandibular division, V3, in addition to contributing to sensation to the face, provides motor innervation to the muscles of mastication.[4] It provides sensory innervation to the buccal mucosa and cheek skin laterally via the buccal nerve.[16,17] The auriculotemporal nerve innervates the temporal region and preauricular skin. The inferior alveolar nerve passes through its canal and innervates the lower alveolar ridge before exiting the mental foramen to supply the lower lip and chin as the mental nerve.[17] The lingual

JAYPEE BROTHERS

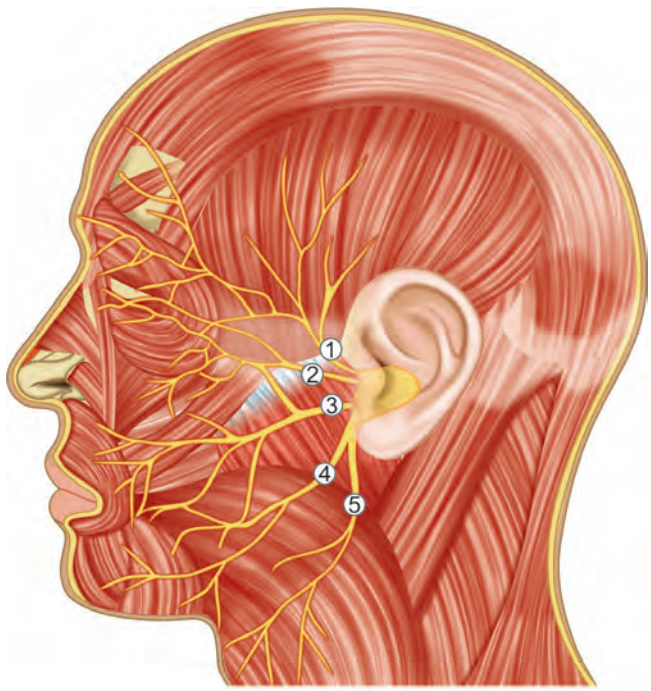

Fig. 3.8: Branches of the facial nerve. 1, temporal; 2, zygomatic; 3, buccal; 4, marginal mandibular; 5, cervical.

nerve, derived from V3, provides sensory innervation to the anterior two-thirds of the tongue.[16,17]

The greater auricular nerve, derived from the anterior rami of the second and third cervical nerves, supplies sensory innervation to the skin over the angle of the mandible and the ear.[4] The lesser occipital nerve, derived from the second and third cervical roots as well, provides sensation to the postauricular region.[17] Finally, the greater occipital nerve provides sensation to the posterior scalp.[2]

Sensory nerves, even though they travel more superficially than motor nerves, are not as much of a concern during cutaneous surgical procedures as motor nerves. Transection of sensory nerves generally results in temporary sensation impairment that can last months but usually returns to baseline.[5] Notably, the supraorbital nerve courses superiorly in the deep subcutaneous fat, which is susceptible to injury when undermining in the medial forehead.[5]

Motor Innervation

Motor innervation to the muscles of facial expression is derived from the facial nerve, the seventh cranial nerve (CNVII) (Fig. 3.8).[16-21] The facial nerve emerges from the skull at the stylomastoid foramen. After giving off three small branches, the main trunk then penetrates the substance of the parotid gland, where it divides into its five terminal branches: temporal branch, zygomatic branch, buccal branch, marginal mandibular branch, and cervical branch.[4] As these branches travel outside the parotid gland, they are protected only by the skin, a variable amount of fat and the SMAS; they enter the deep surface of the muscles they innervate (Fig. 3.5).[18]

The temporal branch leaves the parotid gland superiorly and travels superficially over the zygomatic arch to enter the frontalis muscle.[4,16,17] It also supplies the upper fibers of the orbicularis oculi and the corrugator muscles. The temporal branch is susceptible to injury as it crosses the zygomatic arch and enters the lateral aspect of the frontalis muscle. It travels within the superficial temporal fascia and is covered only by skin and minimal subcutaneous fat.[16] Transection will result in paralysis of the ipsilateral frontalis muscle, which will leave the individual unable to raise that eyebrow or wrinkle the forehead.[5]

The zygomatic branch supplies the frontalis and orbicularis oculi with its upper branch.[4,16,17] Its lower branch supplies the lower orbicularis oculi, zygomaticus major, and other lip elevators. Smaller branches continue medially to supply depressor supercilii and superomedial orbicularis oculi.[16]

The buccal branch leaves the parotid and travels anterior to the buccinator and below and parallel to the parotid duct. It supplies the zygomaticus major and minor, levator labii superioris, levator anguli oris, and the buccinators.[16]

The marginal mandibular nerve leaves the lower parotid gland, travels along the mandible, sometimes below the angle of the mandible, before coursing superiorly and superficially to innervate the orbicularis oris, depressor anguli oris, depressor labii inferioris, and mentalis muscles.[4,16,17] The variable course of the marginal mandibular branch, and the fact that it is only covered by skin, subcutaneous fat, and the thin platysma, leaves it susceptible to injury.[18] Transection will result in ipsilateral flattening, inversion, and elevation of the lip.[5]

The cervical branch travels inferiorly into the neck to supply the platysma muscle.

Transection of nerve fibers in the medial cheek is less likely to result in clinically significant paralysis since there are many anastomosing branches derived from the buccal and zygomatic nerves.[5,18]

JAYPEE BROTHERS

Arterial Supply of the Face

Thorough understanding of the blood supply to the face is important in planning reconstructive procedures and in avoiding surgical complications. Branches of the internal and external carotid arteries supply the face. Branches of the internal carotid supply areas of the scalp, central forehead, eyelids, and dorsal nose. Branches of the external carotid supply the rest of the face[2,4,16,17,22] (Fig. 3.9).

The internal carotid artery enters the skull at the carotid canal. Classically, the internal carotid artery is subdivided into seven segments, C1–C7.[4,16] It is the C6, ophthalmic, segment that gives off the ophthalmic artery that provides arterial blood to the face.[23] From its origin distal to the cavernous sinus, the ophthalmic artery courses anteriorly through the optic canal and into the orbit. Once in the orbit, it gives off multiple branches that have been conveniently grouped into those arteries that supply the eyeball, the ocular group, and those that supply the orbital structures, the orbital group.[23,24] The orbital group includes the supraorbital, supratrochlear, lacrimal, dorsal nasal, and anterior ethmoidal arteries.

Blood supply to the medial forehead is provided by the supraorbital and supratrochlear arteries.[2,4,16,17] They exit the supraorbital rim in their neurovascular bundles through the supraorbital and supratrochlear foramina, respectively.[24] The supratrochlear artery exits and courses medial to the supraorbital artery and supplies the midline forehead and nasal root.[16,24] The supraorbital artery is lateral to the supratrochlear artery and supplies the medial periorbital and scalp tissues of the forehead. The supraorbital and supratrochlear arteries both course in the deep connective tissue, deep to the frontalis muscle and have extensive anastomoses.[16,24]

The nasal dorsum is supplied by the dorsal nasal and anterior ethmoidal arteries.[2,24] The dorsal nasal artery emerges from the orbit above the medial palpebral ligament and supplies the dorsum of the nose and courses medially across the nasal root and anastomoses with the angular artery.[24] The anterior ethmoidal artery courses through the nasal cavity along the inner surface of the nasal bone. After supplying the septum and lateral nasal wall, its terminal branch exits at the interface between nasal bone and cartilage to supply the distal nasal dorsum.

The external carotid artery contributes multiple branches that supply a large portion of the face. These branches include the facial, maxillary, and superficial temporal arteries.[4,16,23,24] The facial artery branches from the external carotid in the neck and in a tortuous course, provides the major arterial supply to the face.[16] After ascending through the neck and close to the submandibular gland, it loops around the inferior and anterior borders of the mandible anterior to the masseter. Here, the facial artery is most superficial and subject to injury, lying just deep to the platysma.[24,25] After crossing the mandible, it courses medially toward the oral commissure where it passes approximately a finger breadth lateral to the angle of the mouth.[25] Here it gives off two branches, the superior and inferior labial arteries. It then courses along the nasolabial fold deep to the zygomaticus major and levator labii superioris muscles and along the side of the nose. At the nasal ala, the facial artery divides into the lateral nasal artery and its terminal branch, the angular artery, before terminating at the medial canthus of the eye. Sources vary on the point at which the facial artery becomes the angular artery, some say that this point is after the superior labial branches, others say it becomes the angular artery after the lateral nasal artery branches.[2,16,17,24]

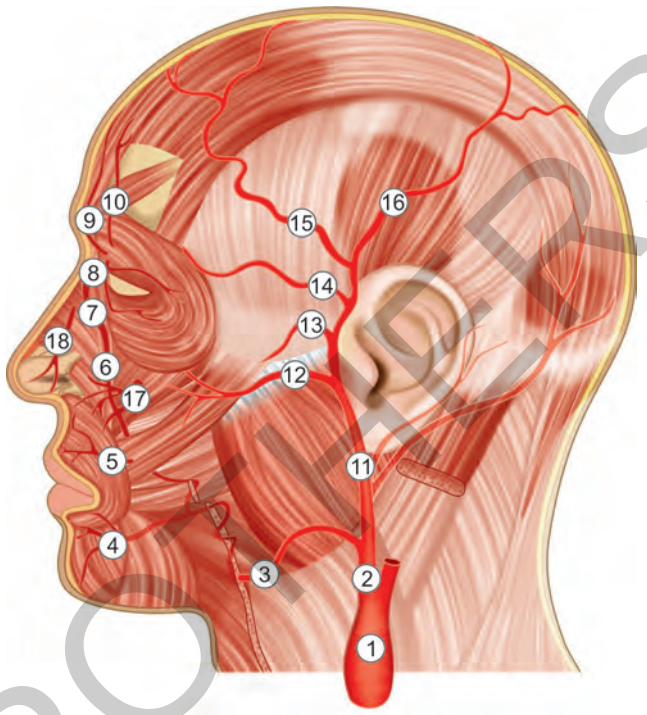

Fig. 3.9: Arteries of the face. 1, common carotid artery; 2, external carotid artery; 3, facial artery; 4, inferior labial artery; 5, superior labial artery; 6, lateral nasal artery; 7, angular artery; 8, dorsal nasal artery; 9, supratrochlear artery; 10, supraorbital artery; 11, superficial temporal artery; 12, transverse facial artery; 13, middle temporal artery; 14, zygomatico-orbital artery; 15, frontal branch of superficial temporal artery; 16, parietal branch of superficial temporal artery; 17, infraorbital artery; 18, external nasal artery.

JAYPEE BROTHERS

The branches of the facial artery include the inferior labial, superior labial lateral nasal, and angular arteries.[2,16,17,24,26] The inferior labial artery runs medially in the lower lip, deep to the lip mucosa, and supplies the lower lip and chin. The superior labial artery runs medially in the upper lip, deep to the lip mucosa, and supplies the upper lip, alar rim, columella, and membranous septum.[4] The lateral nasal artery runs medially along the alar rim and supplies the nasal dorsum and ala. The angular artery is the terminal branch of the facial artery and runs along the nasal sidewall to the medial canthus, where it anastomoses with the dorsal nasal artery. It supplies the superior medial part of the cheek, inferior eyelid, and nasal dorsum.[4]

The superficial temporal artery is a terminal branch of the external carotid artery and supplies the lateral face, scalp, and forehead.[2,4,16,17] It arises from the external carotid when it bifurcates with the maxillary artery in the parotid gland.[4] It courses superficially to the main facial nerve trunks and gives off the transverse facial artery before exiting the parotid. Running superiorly in the preauricular crease at the level of the subcutaneous fat, the superficial temporal artery crosses the zygomatic arch medial to the tragus of the ear. Here, it lies superficial to the auriculotemporal nerve and together they run superiorly above the SMAS.[12] At the top of the ear, the superficial temporal artery bifurcates into the anterior and parietal branches.

Branches of the superficial temporal artery include the transverse facial, and anterior and parietal branches.[2,4,16,17] The transverse facial artery branches from the superficial temporal artery within the parotid approximately 2 cm below the zygomatic arch and runs medially parallel to the arch.[16] It crosses the face superficial to the masseter muscle and supplies the parotid gland and duct and overlying skin before anastomosing with the facial artery.[4] The anterior and parietal branches of the superficial temporal artery originate at the upper portion of the ear and run above the SMAS to supply the parietal scalp and the anterior lateral scalp.[12] They have many anastomoses that serve to create a rich arterial network in the scalp.

The internal maxillary artery is the second terminal branch of the external carotid artery.[4,16,17,23] It courses medially in the infratemporal fossa deep to the mandibular ramus. It gives off the inferior alveolar, mental, buccal, and infraorbital branches.[4] The inferior alveolar artery runs in the body of the mandible and supplies the lower gingiva before emerging as the mental artery at the mental foramen and supplying the lower lip and chin.[24] The infraorbital branch emerges at the infraorbital foramen and supplies the lower eyelid, cheek, and lateral nose. It anastomoses with branches of the facial, ophthalmic, buccal, and facial arteries. The buccal artery begins at the second part of the maxillary artery, it runs obliquely forward superficial to the buccinator, and supplies the cheek and buccinator before anastomosing with the facial and infraorbital arteries.[24]

Venous Drainage of the Face

Most of the venous drainage of the face follows the pathways of the arterial circulation running posterior to their corresponding artery.[24] Like their arterial counterpart, veins of the face have many anastomoses creating multiple pathways of flow and possibilities for spread of disease. The supratrochlear and supraorbital veins run with their arteries and pass through the orbit before draining into the cavernous sinus. The angular vein runs parallel to the facial artery and flows into the anterior facial vein. This vein flows over the submandibular glands and into the deep facial vein. This vein ultimately drains into the internal jugular artery along with the retro mandibular vein, which parallels the superficial temporal artery.

Lymphatics of the Face

The lymphatic drainage of the face is important as it is involved in the spread of infection and malignancy. While the lymphatic drainage is highly variable, the location of individual lymph nodes is consistent between patients, and there is a general drainage pattern that is followed. Drainage is typically found inferolateral to the anatomical location. The upper lateral face including forehead, ear, and upper eyelids drain into the parotid nodes. These nodes then drain into the external or internal jugular vein or jugular nodes. The midface region including the glabella, nose, nasolabial fold, medial cheek, and upper lip drain into the submandibular nodes. These nodes connect to both the submental nodes and the superficial cervical plexus. Ultimately, these nodes drain into the internal jugular chain. The submental nodes collect the drainage from the chin and lower lip, and then drain into the internal jugular chain. The posterior scalp drains into the postauricular nodes, which subsequently drain into the superficial cervical nodes.

JAYPEE BROTHERS

SUMMARY

Dermatologic surgeons have the unique ability to combine therapeutic and cosmetic modalities in the procedures they perform. The anatomy of the affected area is the fundamental basis for these decisions. A dermatologic surgeon must have intimate knowledge of the structures of the face to achieve pleasing results and avoid complications.

REFERENCES

1. Drake RL, Drake RL, Gray H. Gray's Atlas of Anatomy, 1st edition. Philadelphia, PA: Churchill Livingstone; 2008. xvi P. 558 .
2. Marur T, Tuna Y, Demirci S. Facial anatomy. Clin Dermatol. 2014;32(1):14-23.
3. Harvey DT, Taylor RS, Itani KM, et al. Mohs micrographic surgery of the eyelid: an overview of anatomy, pathophysiology, and reconstruction options. Dermatol Surg. 2013;39(5):673-97.
4. Moore KL, Dalley AF, Agur AMA. Clinically Oriented Anatomy, 7th editon. Philadelphia, PA: Wolters Kluwer/Lippincott Williams & Wilkins Health; 2014. xxviii, P. 1134.
5. Summers BK, Siegle RJ. Facial cutaneous reconstructive surgery: general aesthetic principles. J Am Acad Dermatol. 1993;29(5 Pt 1):669-81; quiz 682-3.
6. Pepper JP, Baker SP. Local flaps: cheek and lip reconstruction. JAMA Facial Plast Surg. 2013;15(5):374-82.
7. Rapstine ED, Knaus WJ 2nd, Thornton JF. Simplifying cheek reconstruction: a review of over 400 cases. Plast Reconstr Surg. 2012;129(6):1291-9.
8. Borges AF. Relaxed skin tension lines (RSTL) versus other skin lines. Plast Reconstr Surg. 1984;73(1):144-50.
9. Borges AF. Relaxed skin tension lines. Dermatol Clin. 1989;7(1):169-77.
10. Borges AF, Alexander JE. Relaxed skin tension lines, Z-plasties on scars, and fusiform excision of lesions. Br J Plast Surg. 1962;15:242-54.
11. Summers BK, Siegle RJ. Facial cutaneous reconstructive surgery: facial flaps. J Am Acad Dermatol. 1993;29(6):917-41; quiz 942-4.
12. Ghassemi A, Prescher A, Riediger D, et al. Anatomy of the SMAS revisited. Aesthetic Plast Surg. 2003;27(4):258-64.
13. Menick FJ. Discussion: simplifying cheek reconstruction: a review of over 400 cases. Plast Reconstr Surg. 2012;129(6):1300-3.
14. Gosain AK, Yousif NJ, Madiedo G, et al. Surgical anatomy of the SMAS: a reinvestigation. Plast Reconstr Surg. 1993;92(7):1254-63; discussion 1264-5.
15. Mitz V, Peyronie M. The superficial musculo-aponeurotic system (SMAS) in the parotid and cheek area. Plast Reconstr Surg. 1976;58(1):80-8.
16. Prendergast PM. Anatomy of the face and neck. In: Giuseppe AD, Shiffman MA (Eds). Cosmetic Surgery: Art and Techniques. Berlin, NY: Springer; 2012. pp. 29-45.
17. Bentsianov B, Blitzer A. Facial anatomy. Clin Dermatol. 2004;22(1):3-13.
18. Brown SM, Oliphant T, Langtry J. Motor nerves of the head and neck that are susceptible to damage during dermatological surgery. Clin Exp Dermatol. 2014;39(6):677-82; quiz 681-2.
19. Hwang K. Surgical anatomy of the facial nerve relating to facial rejuvenation surgery. J Craniofac Surg. 2014;25(4):1476-81.
20. Carlson KC, Roenigk RK. Know your anatomy: perineural involvement of basal and squamous cell carcinoma on the face. J Dermatol Surg Oncol. 1990;16(9):827-33.
21. Moskovitz JB, Sabatino F. Regional nerve blocks of the face. Emerg Med Clin North Am. 2013;31(2):517-27.
22. Whetzel TP, Mathes SJ. Arterial anatomy of the face: an analysis of vascular territories and perforating cutaneous vessels. Plast Reconstr Surg. 1992;89(4):591-603; discussion 604-5.
23. Larrabee WF, Makielski KH. Surgical anatomy of the face. New York: Raven Press; 1993. xix, 213 p.
24. Flowers FP, Breza TS. Anatomy of the head and neck. In: Bolognia JL, Jorizzo JL, Schaffer JV (Eds). Dermatology. China: Elsevier; 2012. pp. 2327-41.
25. Pinar YA, Bilge O, Govsa F. Anatomic study of the blood supply of perioral region. Clin Anat. 2005;18(5):330-9.
26. Loukas M, Hullett J, Louis RG Jr, et al. A detailed observation of variations of the facial artery, with emphasis on the superior labial artery. Surg Radiol Anat. 2006;28(3):316-24.

JAYPEE BROTHERS

for detailed information on dermatology books, visit our website **www.jaypeebrothers.com,** for detailed information on dermatology books, visit our w

RECONSTRUCTIVE DERMATOLOGIC SURGERY

Salient Features

- Comprehensive and practical reconstruction techniques for wounds resulting from Mohs surgery
- Basic and Advanced Reconstructions illustrated in depth with detailed clinical photographs and illustrations
- Authors from various academic centers around the United States to provide a broad perspective on the different approaches to surgical repairs. Reconstruction techniques organized by flap types and by anatomical location for quicker reference.



S Brian Jiang MD is Clinical Professor in the Department of Dermatology and Director of Dermatologic and Mohs Micrographic Surgery at the University of California, San Diego (UCSD) California, USA. He is also the founding director of the Micrographic Surgery and Dermatologic Oncology Fellowship at UCSD. Prior to his appointment at UCSD, Dr Jiang was on faculty in the Department of Dermatology at Harvard Medical School where he also served as the Medical Director of the Beth Israel Deaconess Dermatology and Laser Center. He received his medical degree at New York University (NYU) School of Medicine and completed his internship at University of Pennsylvania Medical Center. He completed his residency in dermatology at NYU Medical Center where he also served as Chief Resident. At NYU Medical Center, Dr Jiang also completed a fellowship in Dermatologic and Mohs Micrographic Surgery. He has served as the President and Program Chair of the California Society of Dermatology and Dermatologic Surgery (CalDerm) as well as Program Chair for the American Society for Dermatologic Surgery (ASDS).



Arisa E Ortiz MD is Director of Laser and Cosmetic Dermatology and Assistant Clinical Professor of Dermatology at the University of California, San Diego (UCSD) California, USA. She received training in Mohs Micrographic Surgery at UCSD and also completed the prestigious cosmetic and laser fellowship at Massachusetts General Hospital, Harvard Medical School, and Wellman Center for Photomedicine. She completed her dermatology residency training at University of California, Irvine, USA. She has widely published and lectures at numerous national and international conferences. Dr Ortiz is currently the President of the San Diego Dermatologic Surgery Society. Her research interest is in laser treatment of skin cancer.

Available at all medical bookstores
or buy online at www.jaypeebrothers.com



JAYPEE BROTHERS
Medical Publishers (P) Ltd.
www.jaypeebrothers.com

Join us on facebook.com/JaypeeMedicalPublishers

Shelving Recommendations
DERMATOLOGY
RECONSTRUCTIVE SURGERY
DERMATOLOGIC SURGERY

ISBN 978-93-5152-941-5