on dermatology books, visit our website **www.jaypeebrothers.com,** for detailed information on dermatology books

Acne & Scars

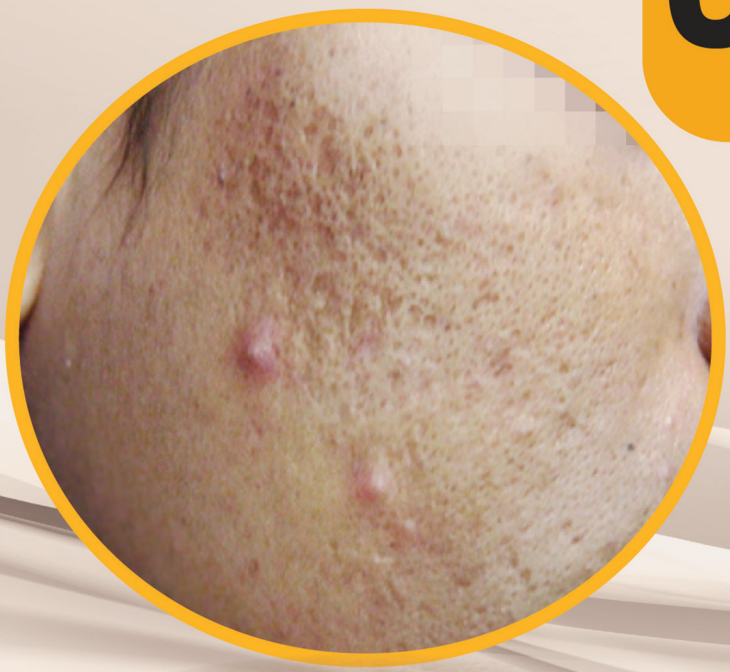

Ramanjit Singh
Nidhi Rao

JAYPEE

Contents

1. Introduction, Epidemiology and Pathogenesis of Acne **1**

Epidemiology *1*
Pathogenesis *2*

2. Clinical Features of Acne **6**

Signs and Symptoms *6*
Onset of Acne *7*
Grading Acne Severity *9*

3. Acneiform Eruption **11**

Nevus Comedonicus *11*
Eruptive Vellus Hair Cyst *12*
Steroid Acne *12*
Chloracne *13*
Acute Generalized Pustular Eruption *13*
Gram-negative Folliculitis *13*
Pityrosporum Folliculitis *13*
Rosacea *14*
Perioral Dermatitis *15*

4. Variants of Acne Vulgaris **17**

Acne Conglobata *17*
Acne Excoriee *18*
Acne Fulminans *19*
Hidradenitis Suppurativa *21*

5. Topical Treatment of Acne **27**

Topical Therapy *27*
Topical Retinoids *28*
Topical Clindamycin *29*
Azelaic Acid *30*
Dapsone 5% Gel *30*

6. Systemic Treatment of Acne **33**

Optimizing Antibiotic Therapy *34*
Isotretinoin *34*

7. Laser and Light Therapy in Acne **44**
Mechanism of Action *45*
Blue Light and Red Light *45*
Laser Therapy in Acne *46*

8. Psychological Impacts of Acne **52**
Psychological Impact *52*

9. Acne Scars and Treatment **55**
Pathogenesis *55*
Classification *56*
Treatment *58*
Atrophic Scars *58*
Hypertrophic Scars *70*

Index *79*

3

Acneiform Eruption

INTRODUCTION

Acneiform eruptions are those lesions, which are acne-like lesions and resemble acne but the distinguishing factor is absence of comedones which are present in acne and absent in acneiform eruptions.

The other distinguishing factors are as follows:

- Presence of acne outside the age of acne
- Presence of a similar monotonous morphology
- Drug history present
- Spontaneous resolution of acne after the stoppage of drug.

Acneiform eruptions can be summarized as:[1-5]

- Nevus comedonicus
- Eruptive hair cysts
- Tuberous sclerosis
- Steroid acne
- Chloracne
- Acneiform drug eruption
- Gram-negative folliculitis
- Eosinophilic pustular folliculitis
- Pityrosporum folliculitis
- Coccidioidomycosis
- Secondary syphilis
- Sporotrichosis
- Rosacea
- Perioral dermatitis.

NEVUS COMEDONICUS

It is also known as nevus acneiformis unilateralis, is an infrequent developmental anomaly manifesting as aggregated open comedones.

It consists of dilated follicular or eccrine orifices plugged with keratin. It may be solitary, congenital.

JAYPEE BROTHERS

Treatment of Nevus Comedonicus

If medical therapy is considered then topical retinoids might be of some benefit. Surgical treatment involves excision or carbon dioxide laser ablation of the involved skin.

ERUPTIVE VELLUS HAIR CYST[6]

It presents as flesh-colored papules found usually on the face, chest, neck, axillae, thighs, groin and buttocks.

It is an anomaly of the vellus hair follicles and might be hereditary.

Treatment of Eruptive Vellus Hair Cyst

There is risk of scarring with incision and drainage of the individual lesion and other modalities like CO_2 laser are difficult to use over large surface areas so treatment of the cyst is difficult. Ablations are difficult to use over large surface areas. As far as medical treatment is concerned, topical retinoids and 12% lactic acid preparations have proven useful in some instances.

STEROID ACNE (FIG. 3.1)[7,8]

Exposure to steroids, halogenated aromatic hydrocarbons, iodides, bromides and other halogens can cause acneiform eruption.

It is observed as monomorphous papulopustules located predominantly on the trunk and extremities, with less involvement of the face.

Characteristically, it appears after the administration of systemic corticosteroids, including intravenous therapy. Topical or inhaled corticosteroids may cause an acneiform eruption of the area of skin under which the topical preparation



Fig. 3.1 Steroid acne

JAYPEE BROTHERS

is applied or in around the nose or mouth in the case of inhaled steroids. The treatment of steroid acne is the usual treatment options which are used for acne and steroid acne disappears after the stoppage of particular steroid.

CHLORACNE

It is an entity which also mimics acne caused by exposure to halogenated aromatic hydrocarbon compounds, such as chlorinated dioxins and dibenzofurans. Exposure is caused by inhalation, ingestion, or direct contact of contaminated compounds or foods. Chloracne is seen as lesions similar to acne on the exposed sites. Xerosis and skin changes in the form of pigmentation might be other associated findings. These chlorinated dioxins can also be carcinogenic and might also cause changes in the nervous and hepatic systems.

Treatment of Chloracne

Treatment of chloracne can be difficult as it might persist even years after exposure has stopped.

ACUTE GENERALIZED PUSTULAR ERUPTION

It is caused mainly by antibiotic, which is mainly a drug reaction and mimics acne. Acneiform eruption can also be caused by other drugs like isoniazid, steroids, hydroxychloroquine, naproxen, mercury, itraconazole.[9-11]

Drugs like olanzapine, lithium are used in chemotherapy, also can cause acne like eruption.[12-18]

GRAM-NEGATIVE FOLLICULITIS

It is a complication of long-term of antibiotic therapy in acne or rosacea. It presents as a persistent papulopustular eruption.

Antibiotic use, such as those of the tetracycline class, can alter the normal skin flora of the skin allowing for growth of gram-negative organisms in the nares of the nose. These gram-negative organisms are typically spread to the skin of the upper lip, chin, and jawline whether they cause a folliculitis. Culture of the papulopustules grows gram-negative bacilli and gram-negative rods, including *Escherichia coli* and *Klebsiella, Enterobacter*, and *Proteus* species. Typical history is a patient with a sudden acne flare despite no change in treatment or a patient unresponsive to traditional therapies. Oral isotretinoin is considered standard of care.

PITYROSPORUM FOLLICULITIS

It is another infectious folliculitis that is presumably caused by a host reaction to the yeast *Malassezia furfur,* previously named *Pityrosporum ovale,* a normal human skin commensal organism. It appears primarily on the trunk and upper extremities of late adolescents and young adults. Unlike acne vulgaris, it is pruritic, does not contain comedones, and responds to empiric antifungal therapy rather than antibiotics. Diagnosis is typically made clinically, although the yeast and hyphae can be observed in biopsy specimens in the widened follicular ostia

JAYPEE BROTHERS

along with keratinous material, and occasionally, rupture of the follicular wall may occur. Patients may be treated with topical leave-on, wash-off, or systemic antifungal therapy.

Eosinophilic pustular folliculitis (EPF) is a disease of unclear etiology, thought to be an allergic hypersensitivity. It appears as a recurrent pruritic papulopustular eruption on the face, trunk, and extremities. Histopathology reveals a predominantly perifollicular infiltration of eosinophils with some mononuclear cells and subcorneal pustules composed of eosinophils. Three main types exist,

1. Infantile form
2. HIV associated
3. Classic Ofuji disease in immunocompetent patients, typically Japanese patients.

Patients may also demonstrate blood eosinophilia and leukocytosis. Treatment modalities and results vary greatly. Options include topical and systemic corticosteroids, oral antibiotics, dapsone, isotretinoin, and pulsed ultraviolet phototherapy (PUVA). Indomethacin is the treatment of choice for classic Ofuji disease.

Several infectious diseases may result in acneiform eruptions:

- In secondary syphilis, acne like lesions, like papulopustules and nodules, may occur on the face, trunk, and extremities. The causative agent, the spirochete *Treponema pallidum*, may be easily observed in biopsy specimens with the Warthin-Starry stain. In addition, serologic tests and the presence of spirochetes on dark field microscopy may reveal the diagnosis.
- Papules and nodules mimicking acne may occur in mycotic infections also and may ulcerate and crust.
- Sporotrichosis caused by *Sporothrix schenckii*, also causes papulonodular eruption but commonly induces a lymphocutaneous reaction. It presents as a persistent fixed localized cutaneous papulonodular eruption that may involve the face. The organism can be demonstrated histologically, by peripheral blood smear, and by fungal culture.
- Cutaneous coccidioidomycosis usually caused by inhalation and dissemination of *Coccidioides immitis*, may rarely occur by primary inoculation and appear as papulopustules, nodules, or plaques that can eventually ulcerate and crust.

ROSACEA

It is a condition which manifests mainly as facial flushing and telangeictasias but appears similarly to acne vulgaris with papulopustular lesions also (Fig. 3.2). Patients with rosacea, however, lack comedones. Four subtypes of rosacea exist:

1. Erythematotelangiectatic
2. Papulopustular
3. Phymatous
4. Ocular.

The incidence of rosacea is mostly seen in whites.

Mainly women are affected. The age group affected is mostly the third and fourth decades of life.

Rhinophyma, which is due to sebaceous hyperplasia of nose, develops mainly in men.

JAYPEE BROTHERS



Fig. 3.2 Rosacea and papulopustular lesions

Rosacea can also have eye findings also. They are blepharitis, conjunctivitis, iritis, iridocyclitis, and hypopyon. In severe cases, keratitis may also occur.

The etiology is still unclear but the factors which affect are extremes of weather, hot and spicy food and alcohol. Sometimes the mite *Demodex folliculorum* can also trigger or exacerbate rosacea.

It was also seen that taking of high dose vitamin B_6 supplement also caused rosacea.[19]

Granulomatous inflammation is seen in the histopathology. The treatment includes antibiotics like metronidazole and systemic antibiotics like oral tetracycline. Avoidance of sun exposure and use of sunscreens should be advised.

PERIORAL DERMATITIS

It is a disorder in which papulopustules with erythematous base are seen perioraly sparing the vermilion border. It might include perinasal and periorbital areas. Although the etiology is not clear, the disease is mainly seen in young and white females.

A variant known as periocular dermatitis affects the skin around the eyes. The eruption is thought to be a variant of rosacea, as biopsies show changes similar to those of rosacea.

Causative agents are theorized to be prior use of topical corticosteroids, but neither duration of use nor steroid strength have been shown to be clearly related. *Demodex* mites,[20] moisturizers, fluorinatced compounds, and contact irritants or allergens have also been implicated as causes of eruption.

Therapy typically includes cessation of topical steroids or other offending agents and topical anti-inflammatory treatments such as topical metronidazole, topical pimecrolimus cream, azelaic acid, as well as oral anti-inflammatory dose of antibiotics such as doxycycline.

JAYPEE BROTHERS

REFERENCES

1. Józwiak S, Schwartz RA, Janniger CK, Michalowicz R, Chmielik J. Skin lesions in children with tuberous sclerosis complex: their prevalence, natural course, and diagnostic significance. Int J Dermatol. 1998;37(12):911-7.
2. Song MG, Park KB, Lee ES. Resurfacing of facial angiofibromas in tuberous sclerosis patients using CO_2 laser with flash scanner. Dermatol Surg. 1999;25(12):970-3.
3. Harden D, Keeling JH. Papular and nodular lesions of the scalp, face, and neck. Secondary syphilis. Arch Dermatol. 1997;133(8):1027-30.
4. Lambert WC, Bagley MP, Khan Y, Schwartz RA. Pustular acneiform secondary syphilis. Cutis. 1986;37(1):69-70.
5. Kusuhara M, Hachisuka H, Sasai Y. Statistical survey of 150 cases with sporotrichosis. Mycopathologia. 1988;102(2):129-33.
6. Held JL, Andrew JE, Toback AC. Eruptive vellus hair cysts. Cutis. 1987;40(3):259-60.
7. Fung MA, Berger TG. A prospective study of acute-onset steroid acne associated with administration of intravenous corticosteroids. Dermatology. 2000;200(1):43-4.
8. Hurwitz RM. Steroid acne. J Am Acad Dermatol. 1989;21(6):1179-81.
9. Farella V, Sberna F, Knöpfel B, Urso C, Difonzo EM. Acne-like eruption caused by amineptine. Int J Dermatol. 1996;35(12):892-3.
10. Grimalt R, Mascaró-Galy JM, Ferrando J, Lecha M. Guess what? Macronodular iatrogenic acne due to amineptine. Eur J Dermatol. 1999;9(6):491-2.
11. Vexiau P, Gourmel B, Castot A, Husson C, Rybojad M, Julien R, et al. Severe acne due to chronic amineptine overdose. Arch Dermatol Res. 1990;282(2):103-7.
12. Schalock PC, Zug KA. Acneiform reaction to erlotinib. Dermatitis. 2007;18(4):230-1.
13. Eames T, Landthaler M, Karrer S. Severe acneiform skin reaction during therapy with erlotinib (Tarceva), an epidermal growth factor receptor (EGFR) inhibitor. Eur J Dermatol. 2007;17(6):552-3.
14. Gencoglan G, Ceylan C. Two cases of acneiform eruption induced by inhibitor of epidermal growth factor receptor. Skin Pharmacol Physiol. 2007;20(5):260-2.
15. DeWitt CA, Siroy AE, Stone SP. Acneiform eruptions associated with epidermal growth factor receptor-targeted chemotherapy. J Am Acad Dermatol. 2007;56(3):500-5.
16. Santoro F, Cozzani E, Parodi A. Cutaneous adverse effects during therapy with an epidermal growth factor receptor (EGFR) inhibitor. J Dermatolog Treat. 2006; 17(3):160-1.
17. Journagan S, Obadiah J. An acneiform eruption due to erlotinib: prognostic implications and management. J Am Acad Dermatol. 2006;54(2):358-60.
18. Myskowski PL, Halpern AC. Skin reactions to the new biologic anticancer drugs. Curr Opin Support Palliat Care. 2009;3(4):294-9.
19. Sherertz EF. Acneiform eruption due to "megadose" vitamins B_6 and B_{12}. Cutis. 1991;48(2):119-20.
20. Monk B, Cunliffe WJ, Layton AM, Rhodes DJ. Acne induced by inhaled corticosteroids. Clin Exp Dermatol. 1993;18(2):148-50.

JAYPEE BROTHERS

for detailed information on dermatology books, visit our website **www.jaypeebrothers.com,** for detailed inform

Acne & Scars

The book covers acne and scars in detail. Acne is a common problem affecting both adolescents and middle aged and most commonly encountered problem in the clinics of dermatology. The book covers acne, variants of acne, treatment and scarring, which is the most common sequela of acne.

It also covers different measures which are used to treat scarring and also includes light and laser therapy and various other surgical measures.



Ramanjit Singh is Senior Consultant Department of Dermatology at Medanta—The Medicity, Gurgaon, Haryana, India. He is also the Medical Director of Dermcos Skin Care Clinic, which is a Premier Cosmetology and Laser Center in Gurgaon. Formerly, he was Director and Head, Department of Cosmetology and Dermatology at Artemis Hospital, Gurgaon. He has done his Postgraduation from JJM Medical College, Davangere, Rajiv Gandhi University, Karnataka. He is a member of International Society of Dermatology, Cosmetology Society of India, Indian Association of Dermatology and also life member of Association of Cutaneous Surgeons of India.

He is also among the few Cosmetologists who have brought the concept of a Laser Spa in India.

His clinical focus and expertise are Acne and Acne scar surgeries, Laser therapy for Acne scars, Chemical peels, Microdermabrassion, Nonsurgical facelifts, Thread lift, Body contouring, Laser hair removal, Photo rejuvenation, Skin tightening, Vitiligo surgeries, Punch grafting, Split skin grafting, Q switch laser for removal of permanent tattoos and birth marks, Botox injections for removal of wrinkles, Dermal fillers, PRP therapy, Pediatric dermatology, Venereology to name a few. In addition to the routine clinical work, he is actively involved in various academic and research activities, such as Comparative study of Medical and Surgical Modalities in the treatment of Vitiligo, Role of Cryoslush in Acne, Psychosocial effects of Psoriasis on individuals, are some of his contributions.



Nidhi Rao is Consultant Dermatologist at Dermcos Skin Care Clinic, Gurgaon, Haryana, India, and Visiting Consultant Dermatologist in Yadav Hospital and Jain Hospital, Gurgaon. Formerly, she was Consultant Dermatologist in Artemis Hospital, Gurgaon. She is a provisional member of Indian Association of Dermatologists, Venereologists and Leprologists (IADVL) and has published two papers on Dyskeratosis Congenita and Cutaneous manifestations of type 2 Diabetes Mellitus in Oman Medical Journal and International Journal of Biological and Medical Research, respectively. She has received her MD in dermatology from Subharti University, Meerut, Uttar Pradesh, India.

Available at all medical bookstores
or buy online at www.jaypeebrothers.com

JAYPEE
JAYPEE BROTHERS
Medical Publishers (P) Ltd.
www.jaypeebrothers.com

Join us on facebook.com/JaypeeMedicalPublishers

Shelving Recommendation
DERMATOLOGY

ISBN 978-93-5152-969-9
9 789351 529699