erology books, visit our website www.jaypeebrothers.com, for detailed information on gastroenterology books, visit our website www.jaypeebrothers

2 Mishra

Volume 2

Includes Two DVD-ROMs



erology books, visit our website www.jaypeebrothers.com, for detailed information on gastroenterology books, visit our website www.jaypeebrothers.co

1 Mishra

Volume 1

Includes Two DVD-ROMs



Textbook of Surgical Gastroenterology

Textbook of Surgical Gastroenterology

Editor
PK Mishra

Foreword
Samiran Nundy

Contents

VOLUME 1

SECTION 1 General

1. **Approach to a Patient of Digestive Disease** 3
   PK Mishra
2. **Gastrointestinal Imaging** 7
   Raju Sharma, Ankur Goyal
3. **Infections and Antibiotics in Gastrointestinal Surgery** 18
   Archana Thakur
4. **Nuclear Medicine Imaging in Gastrointestinal Diseases** 37
   Rakesh Kumar, Sellam Karunanithi
5. **Radiation Therapy** 52
   Kishore Singh, Arun Kumar Rathi
6. **Chemotherapy Principles and Techniques for Gastrointestinal Cancers** 61
   Atul Sharma
7. **Nutritional Support to Hospitalized Patients** 69
   Umesh Kapil, Namrata Singh
8. **Statistics for Surgeons** 86
   Sreenivas
9. **Interventional Radiology of the Gastrointestinal Tract and Hepatobiliary System** 104
   Amar Mukund, S Rajesh

SECTION 2 Esophagus

10. **Anatomy and Physiology of the Esophagus** 133
    Nikhil Aggarwal
11. **Diagnostic Tests in Esophageal Diseases** 140
    Shobna J Bhatia, Chirag Shah
12. **Approach to a Patient with Dysphagia** 151
    Vishal Gupta
13. **Gastroesophageal Reflux Disease** 158
    V Baskaran
14. **Motility Disorders of the Esophagus** 176
    NS Balaji
15. **Esophageal Perforation: Diagnosis and Management** 184
    Rajneesh Kumar Singh, Puneet Puri
16. **Corrosive Injury of Esophagus and Stomach** 194
    N Ananthakrishnan, R Kalayarasan, Vikram Kate
17. **Benign Tumors of the Esophagus** 207
    Vivek Mangla, Manoj Gupta
18. **Carcinoma Esophagus** 216
    Kishore GS Bharathy, TK Chattopadhyay
19. **Esophageal Cancer: Operative Strategies and Lymphadenectomy** 229
    CS Pramesh, George Karimundackal, Sabita Jiwnani
20. **Multimodality Treatment in Carcinoma of the Esophagus** 237
    Shaleen Kumar, Shagun Misra, Rajneesh Kumar Singh
21. **Minimal Invasive Esophagectomy** 247
    Rajesh Bhojwani, Kapileshwar Vijay
22. **Esophageal Replacement Procedures** 257
    Sundeep Jain, Neeraj Bhateja

SECTION 3 Stomach, Duodenum, Small Intestine and Retroperitoneum

23. **Stomach and Duodenum** 269
    Neeraj Goel, PK Mishra
24. **Surgery for Peptic Ulcer Disease** 283
    Vikram Kate, R Kalayarasan, TP Elamurugan, N Ananthakrishnan
25. **Carcinoma Stomach** 300
    Durgatosh Pandey, Palaniappan Ramanathan, Pankaj Kumar Garg, Rambha Pandey
26. **Duodenal and Small Intestinal Tumors** 313
    Monika Gupta
27. **Gastric Bezoar and Gastric Volvulus** 320
    KJ Singh
28. **Intestinal Obstruction** 327
    Sanjoy Mandal
29. **Abdominal Tuberculosis** 337
    Nilesh Patil, RK Saran, Uday Somashekar
30. **Gastrointestinal Lymphomas** 348
    Anurag Mishra, AK Sarda
31. **Visceral Artery Aneurysms** 355
    RA Sastry, Venu Madhav Thumma
32. **Mesenteric Ischemia** 365
    DK Sharma
33. **Radiation Enteritis: Pathophysiology, Prevention and Management** 381
    Vineeta Goel, Pankaj Agarwal
34. **Gastrointestinal Stromal Tumor** 387
    Subodh Varshney, Ajit Sewkani
35. **Retroperitoneal Tumors** 399
    Sanjay Gupta

SECTION 4 Pancreas

36. **Pancreas: Embryology, Anatomy and Physiology** 409
Harsh Shah, Sundeep Singh Saluja

37. **Acute Pancreatitis** 417
Pramod Kumar Garg

38. **Surgery in Acute Pancreatitis** 429
Mohammad Ibrarullah, Jayanth Reddy, VK Kapoor

39. **Pseudocyst and other Complications of Pancreatitis** 437
Chintamani Godbole, Nilesh Doctor

40. **Medical Management of Chronic Pancreatitis** 449
Harpal S Dhaliwal, Saroj K Sinha, Rakesh Kochhar

41. **Surgery for Chronic Pancreatitis** 465
Vikas Gupta

42. **Pancreatic and Periampullary Cancer** 485
Savio George Barreto, Adarsh Chaudhary

43. **Pancreatic Surgery** 494
Rajesh Rajalingam, PK Mishra

44. **Cystic Neoplasms of the Pancreas** 518
Masao Tanaka

45. **Neuroendocrine Tumors of the Pancreas** 535
Vinay Gaikwad, Mahesh Goel, Bhawna Sirohi, Shailesh V Shrikhande

46. **Minimally Invasive Approach to Pancreatic Lesions** 548
C Palanivelu, P Senthilnathan

47. **Pancreaticoduodenal Injuries** 558
Satish B Dharap

48. **Pancreas and Islet Transplantation** 565
Rakesh Rai

SECTION 5 Gallbladder and Bile Ducts

49. **Gallbladder and Bile Ducts: Anatomy and Physiology** 577
Satyajit Godhi, PK Mishra

50. **Imaging of Liver and Biliary Tract** 586
Ankur Arora, Sunil Kumar Puri

51. **Endoscopic Retrograde Cholangiopancreatography in Biliary and Pancreatic Diseases** 609
Zaheer, D Nageshwar Reddy

52. **Gallstone Disease** 618
Avinash Supe, Ramkrishna Prabhu

53. **Current Management of Common Bile Duct Stones** 627
Jagdish Chander, Anubhav Vindal

54. **Cholangitis** 635
Gourdas Choudhuri, Pawan Rawal

55. **Biliary Atresia** 639
Yogesh Kumar Sarin, Sushmita Nitin Bhatnagar

56. **Choledochal Cysts** 650
Sundeep Singh Saluja, Mohammed Nayeem Vaibhav Varshneya

57. **Bile Duct Injury, Biliary Fistula and Benign Biliary Stricture** 662
Sundeep Singh Saluja, Nilesh Patil, Neeraj Goel

58. **Primary Sclerosing Cholangitis** 688
Siddharth Srivastava

59. **Recurrent Pyogenic Cholangitis** 696
Sukanta Ray

60. **Gallbladder Polyps** 701
Biju Pottakkat

61. **Carcinoma Gallbladder** 706
Asit Arora, PK Mishra

62. **Cholangiocarcinoma** 726
Rajan Saxena, Himanshu Yadav

VOLUME 2

SECTION 6 Liver

63. **Surgical Anatomy of the Liver** 743
Supriyo Ghatak, Anshuman Ray

64. **Liver Function Tests** 749
Kaushal Madan, Pankaj Tyagi

65. **Approach to a Patient with Jaundice** 757
R Surendran, Paari Vijayraghavan

66. **Liver Abscess** 762
Mihir K Mohapatra, Satya Prasad Samantaray Vedavyas Mohapatra

67. **Hydatid Disease of Liver** 766
Eppa Vimalakar Reddy, Mohan N, Ramesh Ardhnari

68. **Imaging and Intervention in Hemobilia** 784
Shivanand Gamanagatti, Prasad Thotton Veedu

69. **Hepatic Trauma** 789
Rajan Chaudhry, Anuj Sharma

70. **Approach to Space-occupying Lesion of Liver** 796
Nilesh Patil, PK Mishra

71. **Benign Liver Tumors** 814
Sudeep R Shah

72. **Malignant Neoplasms of Liver** 821
Sudhindran

73. **Liver Metastases** 830
Sanjay Govil, Ashwin Rammohan

74. **Perioperative Management in Patients with Biliary Tract and Liver Disease** 842
Ankur Garg, Sanjay Singh Negi

75. Liver Resection 852
Girish K Pande, Sujoy Pal

76. Non-Cirrhotic Portal Hypertension 878
Shivraj Bahadur Singh, Vivek Mangla, Sujoy Pal

77. Budd-Chiari and other Vascular Diseases of Liver 895
Prakash Jain, Shyamkumar N Keshava, Vinu Moses, Venkatramani Sitaram

78. Cirrhosis and its Complications 907
Cyriac Abby Philips, SK Sarin

79. Artificial Liver Support in Liver Failure 950
Rakhi Maiwall, Manoj Kumar Sharma

80. Surgery in Acute and Chronic Liver Disease 961
Shalimar, SK Acharya

SECTION 7 Spleen

81. Anatomy and Physiology of Spleen 967
AK Singh, Priya Ranjan

82. Splenic Trauma 973
JK Banerjee

83. Splenic Cysts, Tumors and Abscess 979
Hirdaya H Nag, R Kalayarasan

84. Non-Traumatic Splenectomy 984
Kamal Yadav, Deborshi Sharma

SECTION 8 Colon, Rectum and Anal Canal

85. History and Examination in Colorectal Disease 993
Nikhil Gupta, Shivendra Singh

86. Imaging in Colorectal Disease 997
Poonam Narang

87. Anal Fistula 1009
BK Jain, PK Garg

88. Rectal Prolapse 1023
Rajinder Parshad, Kamal Kataria, Saurabh Singhal, Kamlesh Kumar

89. Rectovaginal Fistula 1036
Ashok Kumar, Rakesh Kumar Singh

90. Rectourethral Fistula 1043
Nitesh Patidar, MS Ansari, Ashok Kumar

91. Fecal Incontinence 1049
Abhijit Chandra, Noushif M, Saket Kumar

92. Ulcerative Colitis 1055
Praneeth Moka, Govind K Makharia

93. Surgery for Ulcerative Colitis 1068
Rohin Mittal, Benjamin Perakath

94. Crohn's Disease 1081
Saurabh Kedia, Vineet Ahuja

95. Surgery for Crohn's Disease 1100
Benjamin Perakath

96. Colonic Polyps and Polyposis Syndromes 1107
Brundaban Nahak, Debasis Misra, Shivaram Prasad Singh

97. Colorectal Cancer: An Overview 1119
Ashok Kumar, Puneet Puri

98. Colectomy for Colon Cancer 1128
Ashok Kumar, Sunil T

99. Surgery for Carcinoma Rectum 1132
Shivendra Singh, Nikhil Gupta, Suhar Kumar

100. Recurrent Rectal Cancer and Pelvic Exenteration 1141
Sundeep Jain, Naresh Jangir

101. Minimally Invasive Colorectal Cancer Surgery 1146
Subhash Mishra, Mohd Qaleem, Purak Mishra, Deepak Govil

102. Chemotherapy for Colorectal Cancer 1154
Sunil Kumar Gupta

103. Radiotherapy for Colorectal and Anal Carcinoma 1157
Swarupa Mitra

SECTION 9 Liver Transplantation

104. History of Liver Transplantation 1169
Vinay Kumaran

105. Liver Transplantation in India 1172
Vinay Kumaran

106. Indications and Contraindications for Liver Transplantation 1175
Vibha Verma, Vinay Kumaran

107. Organ Preservation in Liver Transplant 1183
Raghavendra Raja, Vinay Kumaran

108. Anesthetic Management in Liver Transplantation 1187
Vijay Vohra

109. Immunology of Liver Transplantation 1197
Manav Wadhawan, John Joseph

110. Pediatric Liver Transplant 1205
Mohammed A Nayeem

111. Liver Transplantation in Acute Liver Failure 1215
Dronacharya Routh, CS Naidu

112. Deceased Donor Liver Transplantation 1226
Mohamed Rela, Gomathy Narasimhan

113. Living Related Liver Transplantation 1237
Subhash Gupta, Neerav Goyal, Shaleen Agarwal

114. Complications in Living Donor Liver Transplantation 1255
AS Soin, Punit Singla

SECTION 10 Miscellaneous

115. **Variceal Upper Gastrointestinal Bleeding** 1277
Patta Radhakrishna, Pavan Addala

116. **Management of Nonvariceal Hemorrhage** 1291
Patta Radhakrishna, Pavan Addala

117. **Approach to the Management of Lower Gastrointestinal Hemorrhage** 1298
Atul Sharma

118. **Bariatric and Metabolic Surgery** 1311
Mahendra Narwaria, Ahmad Jan

119. **Robotics in Gastrointestinal Surgery** 1320
Arvind Kumar, Belal Bin Asaf

120. **Tumor Markers in Gastrointestinal Malignancy** 1334
Nilesh Patil, Kunal Parasar, Sundeep Singh Saluja

121. **Chylous Ascites** 1341
Vageesh BG, PK Mishra

122. **Acute Postoperative Pain and its Management in Major Abdominal Surgeries** 1346
Baljit Singh, Indira Malik

123. **Telemedicine: Principles and the Future** 1352
Shuzi Shimizu, Ho-Seong Han, Kuriko Kudo Yoshiko Houkabe, Yasuaki Antoku, Naoki Nakashima

124. **Surgery for Portal Hypertension** 1357
Joseph George, Rajesh Panwar Sundeep Singh Saluja, Peush Sahni

125. **Ethics in Surgery** 1367
Sanjay Nagral

Appendix *1373*

Index *I-1*

CHAPTER 4

Nuclear Medicine Imaging in Gastrointestinal Diseases

Rakesh Kumar, Sellam Karunanithi

JAYPEE BROTHERS

INTRODUCTION

Gastrointestinal (GI) imaging with radionuclide agents renders quantitative diagnostic information and noninvasive functional information which could not be obtained from anatomical imaging. GI imaging for various indications with positron emission tomography or computed tomography (PET/CT) and gamma camera scintigraphy including single-photon emission computed tomography (SPECT) and hybrid single photon emission tomography or computed tomography (SPECT/CT) are discussed below.

^{99m}Tc-PERTECHNETATE MECKEL'S SCAN

Ectopic gastric mucosa in a Meckel's diverticulum can be a source of unexplained GI bleeding in pediatric patients. The indication for Meckel's scan is to localize the ectopic gastric mucosa. In the intestinal tract, gastric mucosa and the ectopic gastric mucosa shows ^{99m}Tc (Technetium-99m, $T_{1/2}$ = 6 hours)—pertechnetate uptake as the uptake is mainly localized to the mucin cell. Intravenous dose of 3.7 MBq/kg of body weight is usually given. Appearance of radioactivity in the ectopic gastric mucosa which appears at the same time as activity in the normal gastric mucosa is considered as positive study. Typical positive study occurs in gastric duplication and ectopic gastric mucosa which demonstrate simultaneous visualization with the stomach. Dynamic studies with intestinal duplication cysts show positive uptake even before the stomach is seen. Whereas delayed imaging is required in thoracic duplication cysts, as intrathoracic foregut duplication cysts show uptake on 24 hours delayed images after the gastric visualization.

^{99m}Tc-pertechnetate Meckel's scan has sensitivity and specificity of approximately 85% and 95%, respectively.[1] Priming with pentagastrin, H_2 blocker, and glucagon improves the detection rate. A subcutaneous dose of 6 mg/kg pentagastrin just before the imaging increases the metabolism of mucus producing cells. Glucagon is given at a dose of 50 mg/kg intravenously, 10 minutes after the ^{99m}Tc-pertechnetate administration. It inhibits the peristaltic dilution and washout of the radionuclide. Cimetidine is given orally for 2 days before imaging. It decreases the peptic secretion, thereby retarding the release of ^{99m}Tc-pertechnetate from the mucoid cells into the diverticulum lumen.[2,3] Intussusception, inflammatory lesions, obstructed loops of bowel, ulcers, arteriovenous malformations, and certain bowel tumors show false positive results.[4,5]

GASTROINTESTINAL BLEEDING

Nuclear medicine plays an important role in acute GI bleeding. Conventional endoscopy like gastroscopy, colonoscopy, and push-enteroscopy were used to confirm and localize hemorrhage from upper GI tract and colon. Conventional endoscopy has limited value in bleeding from the small intestine. ^{99m}Tc-labeled erythrocytes or radiolabeled sulfur colloid particles are the radionuclide agents used most commonly to detect active GI bleeding.

^{99m}Tc-labeled Autologous Erythrocyte (RBC) Scintigraphy

Red blood cells (RBCs) labeled by means of ^{99m}Tc can help to detect the source of GI bleeding in the small intestine in patients with bleeding in the lower GI tract from an uncertain source. It improves the disease management in patients presenting with obscure-overt bleeding, melena and hematochezia. Ready availability of good quality commercial kits enables rapid and reliable erythrocyte labeling. This technique is currently the most popular method as

it provides dynamic early-phase imaging followed by extended equilibrium-phase. In vitro method has superior RBC labeling efficiency (98%) as compared with the in vivo (70%) and modified in vivo (90–95%) methods. Superior labeling efficiency makes the in vitro method preferable, yet on the contrary the in vivo method is simple.

Studies demonstrating radiotracer activity outside the region of normal vascular structures with retrograde or antegrade motion of radiotracer through bowel is considered positive. Bleeding from small intestine usually demonstrates a rapid distal progression through a series of multiple small, centrally located, curvilinear segments on cinematic display of the abdomen. On the contrary, large intestine bleeding demonstrates a more elongated pattern with peripheral location within the abdomen. Steady scintigraphic activity should not be diagnosed as an active bleeding site and usually results from a fixed vascular structure like hemangioma, accessory spleen, and ectopic kidney.[6]

Detecting intermittent bleeding is the main advantage of using ^{99m}Tc-RBCs as it permits visualization of GI bleeding over the course of several hours. Importantly bleeding rates as low as 0.1–0.4 mL/min can be detected by ^{99m}Tc-RBC scintigraphy. Also, entire GI tract can be visualized in ^{99m}Tc-RBC scintigraphy. It is an effective imaging modality in localizing lower GI bleeding especially in patients for whom all other diagnostic evaluation have failed to locate the site of bleeding.

^{99m}Tc-labeled Sulfur Colloid Scintigraphy

^{99m}Tc sulfur colloid is another radiotracer used in the evaluation of GI bleeding. It acts as an early phase vascular imaging agent. ^{99m}Tc sulfur colloid is extracted to liver, spleen and bone marrow and it get rapidly cleared from the vascular space. Extravasation from a vascular source, such as that which occurs during active GI bleeding, lacks rapid clearance and is easily detected ^{99m}Tc-labeled sulfur colloid scan.[7] Active bleeding occurring within a time-window of several minutes after radiotracer administration is the main dependent factor. It yields high target to background count ratio thereby has the advantage of detecting bleeding rates as low as 0.05–0.1 mL/min. As the liver and spleen show physiological ^{99m}Tc sulfur colloid accumulation those bleeding sites in close proximity to liver and spleen can show false negative results.

Scintigraphy with ^{99m}Tc-labeled RBC and ^{99m}Tc sulfur colloid has certain advantages over contrast angiography. Scintigraphy detects sources of venous and arterial GI bleeding, whereas angiography only detects arterial sources. Also, ^{99m}Tc RBC scintigraphy for GI bleeding has the ability to predict transfusion requirements and the need for angiography and surgery.[8-10] ^{99m}Tc RBC scintigraphy has prognostic importance as a negative study is predictive of good outcome in patients presenting with acute GI bleeding who are stabilized by transfusion and supportive care. Scintigraphy study with ^{99m}Tc-labeled RBC or ^{99m}Tc sulfur colloid is highly recommended before angiography as it plays an important role in assisting both radiological and surgical interventions.[11]

Other Techniques

^{99m}Tc-labeled albumin was the earliest intravascular agent used to detect GI bleeding.[12] ^{99m}Tc-labeled heat-damaged erythrocytes also have been used. These technique showed promising results but was soon surpassed by techniques using more reliable labeling techniques. ^{111}Indium-labeled erythrocytes also have been used with the aim of using the longer ($T_{1/2}$ = 2.80 days) of ^{111}In to facilitate prolonged imaging to detect intermittent GI bleeding. The increased radiation burden and, increased cost limit the potential clinical utility of this technique.[13]

GASTROESOPHAGEAL REFLUX SCINTIGRAPHY

^{99m}Tc sulfur colloid in water or milk/formula milk is often used for the assessment of gastroesophageal reflux (GER) in children. 0.2–1 mCi of ^{99m}Tc sulfur colloid is given orally in two thirds of the expected feeding volume. In order to clear any residual activity within the oropharynx and esophagus, the remaining unlabeled one third of the feeding volume is then swallowed. The patient is burped before imaging. Acquisition for 60 minutes with short-lasting 5-s anterior images is the usual protocol (Fig. 1). In order to look for evidence of aspiration, after the dynamic imaging at the end of 60 minutes, anterior and posterior static images of the thorax will be acquired.

Detection of GER on scintigraphy was found to be useful in the assessment of the outcome of antireflux surgery and in children presenting with caustic esophageal injury.[14,15] GER scan provides additional information such as aspiration, gastric emptying data, and abnormal esophageal contraction. In order to identify pulmonary aspiration, salivagram and milk scan are the two available scintigraphic studies. Aspiration during swallowing (antegrade events) is detected by salivagram while the milk scan detects the events related to GER (retrograde events). With patient in supine position, a small drop of liquid containing ^{99m}Tc-sulfur colloid is placed on the patient's tongue for salivagram and posterior images are obtained for 1 hour although the study often ends at 10–15 minutes. Demonstration of tracheobronchial activity and/or lung activity is considered positive. The salivagram is more frequently positive than the milk scan or videofluoroscopy in the detection of pulmonary aspiration.

ESOPHAGEAL TRANSIT SCINTIGRAPHY

Down syndrome, achalasia, systemic sclerosis, diffuse esophageal spasm, esophagitis, nutcracker esophagus, tracheoesophageal fistula, and diabetes mellitus are the usual esophageal motility disorders evaluated with esophageal transit scintigraphy. The major current indication is in patients with esophageal dysmotility to evaluate esophageal emptying and reflux. At least a 3-hour overnight fasting is required for the scan. The test is performed with the patient in the supine position and having him or her swallow a 10 mL bolus of water or milk labeled with 5.55 MBq of ^{99m}Tc sulfur colloid, followed by repetitive swallows of the bolus (dry swallows may also be obtained), and images are obtained via a gamma camera while the patient is in a supine or upright position. Images are analyzed and time-activity curves (TAC) are obtained from the regions of interest (ROI) drawn around the upper, middle, and lower thirds of the esophagus and the stomach. The normal transit time through the esophagus is typically less than 10 seconds which ranges from 3.4 ± 1 s for infants to 4.6 ± 1.9 s for patients 8–16 years of age.

Noninvasive nature, low radiation burden and its ability to quantify are major advantages of esophageal scintigraphy.

JAYPEE BROTHERS



Figure 1 *Gastroesophageal reflux scintigraphic test*: Frequent reflux events are evident in this sequence (arrows), with retrograde extension of radiotracer up to the entire esophagus

Unavailability of esophageal manometry, equivocal manometry results, and negative manometry with high clinical suspicion of esophageal dysmotility are certain important indications for esophageal scintigraphy. It is also useful to monitor disease and its response to therapy.[16-18]

GASTRIC EMPTYING

Scintigraphy is the gold standard measurement of gastric emptying. It provides an objective assessment of the gastric transit abnormality preoperatively and postoperatively which guides treatment decisions.[19] Indications for scintigraphic gastric emptying include: (1) Diagnosis of dyspepsia with a normal endoscopic examination; (2) recalcitrant GER; (3) diabetics with symptoms of gastroparesis or erratic glycemic control and (4) suspected generalized motility disorders, postsurgical nausea, or vomiting.

The rate of scintigraphic gastric emptying is dependent on the nature of test meal used. Exponential clearance of activity will be noted with liquids. Solids generally demonstrate a lag period which is followed by near linear disappearance. In infants, milk or formula milk is used in assessment of gastric emptying. In older children, solid or combined solid and liquid emptying can be assessed. Idli or egg sandwich containing ^{99m}Tc-sulfur colloid is used for performing solid gastric emptying. ROI is drawn around the stomach region. Anterior images for 30 seconds are acquired for every 10 minutes. Images are acquired until 2 hours. Between image acquisitions the patient is allowed to sit upright. Simultaneous IV infusion of a prokinetic drug during gastric emptying study by scintigraphy has been used in a few nuclear medicine departments to identify patients ("responders" who have normalized gastric emptying) who are more likely to respond to chronic treatment with prokinetics.

Although scintigraphy is the accepted gold standard for diagnosis of gastroparesis[20] it has limited validation for detection of rapid gastric emptying, which has been observed in functional dyspepsia, cyclical vomiting, postgastric surgery symptoms, and diabetics with early stages of autonomic dysfunction. These patients cannot be distinguished from gastroparetics by symptoms alone. Patients should be off prokinetic or antikinetic medications for at least 48 hours before testing, and fasting blood glucose should be less than 180 mg/dL on the day of testing.

JAYPEE BROTHERS

COLON TRANSIT

Indications for colon transit include evaluation of patients in whom surgery is considered for slow transit constipation; unexplained constipation or diarrhea; and constipated patients with upper GI symptoms.[21] A methacrylate-coated capsule containing ^{111}In-labeled activated charcoal particles is ingested. The coated capsule usually dissolves in the alkaline pH of the distal ileum and releases into the colon.[22] External markers are placed over the iliac crests to localize the position of the capsule in the small bowel. At the same time, a ^{99m}Tc-labeled egg meal is used to assess gastric and small bowel transit. Anterior and posterior images are obtained at specified times (e.g., 4, 24, and 48 hours) while the patient stands erect and an area of interest is drawn around the images of the regions of the colon. Radionuclide colon transit scintigraphy, a safe and noninvasive method, has been shown to correlate with radiopaque markers. Colon transit scintigraphy provides information on regional and overall colon transit.

The use of scintigraphy to measure GI transit is an important tool for the clinician in the diagnosis and treatment of common GI diseases. Studies such as colonic transit and SPECT for measuring gastric accommodation are gaining wider acceptance and availability; however, others such as rectoanal angle, and emptying, and esophageal scintigraphy are not widely available or lack standardization of the techniques and/or interpretation of the results. Gastric emptying scintigraphy still remains the most widely used GI scintigraphic test and has been established as the gold standard for measuring gastric emptying. Scintigraphy studies are easy to perform and usually well tolerated.

BILIARY ATRESIA VERSUS NEONATAL HEPATITIS

Biliary atresia and neonatal hepatitis share similar clinical features. In order to prevent complete deterioration of the extrahepatic biliary tree and irreversible liver damage, early detection of biliary atresia before 2–3 months of age is very important. ^{99m}Tc-hepatobiliary iminodiacetic acid (HIDA) derivatives like ^{99m}Tc-diisopropyl iminodiacetic acid (DISIDA) or ^{99m}Tc-mebrofenin are used in hepatobiliary scintigraphy. Priming the neonate with phenobarbital (5 mg/kg/d divided BID for 3–5 days before scintigraphy) is important. Phenobarbital increases the bile secretion and improves the sensitivity of the scan. Rarely, ursodeoxycholic acid has also been included in the bile secretion stimulation priming regimen.

Dynamic abdominal images are acquired for 1 hour (at some centers, only 15 minutes is acquired). Visualization of bowel excludes the presence of extra hepatic biliary atresia. Non-visualization of bowel activity till 24 hours delayed images is considered positive for biliary atresia. False positive results (normal liver uptake of tracer with no excretion up to 24 hours) can occur in severe cases of neonatal hepatitis, dehydration, total parenteral nutrition (TPN) cholestasis, Alagille syndrome, sepsis, and bile plug syndrome in cystic fibrosis. Poor liver uptake and poor hepatobiliary transit with passage of tracer into the bowel occurs typically in neonatal hepatitis. Severely impaired hepatocyte radiotracer uptake with non-visualization of bowel activity is considered as indeterminate and a repeat scintigraphy after priming with phenobarbital (if previously not performed) may prove useful in these cases. With the introduction of hybrid SPECT/CT accurate anatomical localization of questionable activity to bowel lumen versus genitourinary tract, liver, spleen, or elsewhere in equivocal cases can be performed.[23]

CHOLEDOCHAL CYST

A choledochal cyst is a congenital focal cystic or fusiform dilatation of the common bile duct (CBD) with or without associated proximal intrahepatic ductal dilatation. Patients with choledochal cysts usually present prior to the age of 10 years and females are affected more than males (4:1). Symptoms include pain (90%), intermittent jaundice (33%), right upper quadrant (RUQ) mass (25%), choledocholithiasis (50%), pancreatitis (33%), and cholangitis. Affected patients are at an increased risk of developing cholangiocarcinoma (10% of patients). Treatment consists of early surgical excision or anastomosis to the intestine in order to prevent biliary cirrhosis. Complications include: Cholangitis, pancreatitis, stone formation, and cholangiocarcinoma (20x's general population risk). Choledochal cysts may be sub-classified into five types (Type I–V).

HIDA scintigraphy with ^{99m}Tc-mebrofenin: A variety of appearances can be seen on the scintigraphic exam. Uptake of the radiotracer by the liver is usually normal. Initially the bile filled cyst may appear as a photopenic area, but on delayed images the cyst will fill with tracer and appear as a hot spot (Figs 2A to H). If the cyst is obstructive, there may be non-visualization of the CBD and bowel activity may not be identified.

BILIARY OBSTRUCTION AND CHOLECYSTITIS

Hepatobiliary scintigraphy is useful in the assessment of patients with right upper quadrant pain. Acute cholecystitis is associated with nonvisualization of the gallbladder on HIDA scintigraphy with ^{99m}Tc mebrofenin. A specificity of 100% and a diagnostic accuracy of 98% are documented in adult population.[24] However, in children, gallbladder visualization, though infrequent, is possible in acalculous cholecystitis. So visualization of the gallbladder in children does not exclude cholecystitis. Further assessment with 0.02 mg/kg sincalide infusion is advised if the gallbladder is visualized. Partial cystic duct obstruction, acalculous cholecystitis or chronic cholecystitis can cause poor contraction of the gallbladder following sincalide administration. A gallbladder ejection fraction (EF) of approximately less than 35% can be noted in patients with chronic cholecystitis. Also, chronic cholecystitis shows a delay in gallbladder filling in the absence of hepatic dysfunction. In scintigraphic evaluation for acute cholecystitis, morphine augmentation may help to reduce the number of false positive studies and decrease scanning time.[25]

BILIARY LEAK

Trauma and surgery are the common causes for biliary leak. In surgical cases, bile leaks occur most commonly at the cystic duct (70–75%). Intervention is required in large biliary leaks whereas small biliary leaks are allowed to heal spontaneously. Hepatobiliary scintigraphy is usually performed in such cases to identify biliary leak and to localize the site of leak. Also, scintigraphy provides a qualitative assessment of the severity of the leak. Hepatobiliary

JAYPEE BROTHERS



Figures 2A to H Hepatobiliary iminodiacetic acid (HIDA) scan with ^{99m}Tc-mebrofenin. Serial images reveal an initial photopenic area which as time progresses shows progressive accumulation of radiotracer (thick arrows). Also, appreciated are the right and left hepatic ducts (C; thin arrows) and gallbladder (E; thin arrows) with abdomen showing bowel activity in delayed images. These features are suggestive of non-obstructive choledochal cyst

scintigraphy is a sensitive, noninvasive and inexpensive test in this clinical setting. Positive scan reveal the presence of radiotracer within the peritoneal cavity (either adjacent to the liver or within the hepatic capsule) (Fig. 3). Infrequently, free bile ascites can be noted. Scintigraphy has better sensitivity and specificity in biliary leak detection as it can establish an active hepatobiliary component in fluid collection, whereas CT or ultrasonography (USG) can demonstrate only the presence of a fluid collection.[26] With the introduction of hybrid SPECT/CT accurate anatomical localization of bile leak can be documented which improves the patient management.

SPLENIC SCINTIGRAPHY

^{99m}Tc-denatured RBC is the ideal tracer for splenic scintigraphy. Denaturation of RBC improves the localization of spleen. Images are acquired at least 15 minutes after intravenous injection of ^{99m}Tc-labeled, denatured RBCs. Splenic scintigraphy alternatively can be performed by using ^{99m}Tc sulfur colloid. The tracer usually clears with a half-time of 2.5 minutes. Anatomic imaging may give the spleen a false appearance of abdominal tumor in patients with increased ligamentous laxity as they allow the spleen to become mobile within the abdomen. ^{99m}Tc-sulfur colloid or denatured RBC scan can distinguish the "wandering spleen" from abdominal tumor in these cases.[27]

Failure of early embryologic fusion of multiple buds of splenic tissue can result in accessory spleens or splenules which occurs in 40% of patients. Splenic hilum is the most common site. In patients with accessory spleens or splenules, after splenectomy hypertrophy of these residual buds occurs and can create an appearance of hypersplenism. Splenic scintigraphy with ^{99m}Tc-sulfur colloid or denatured RBC is helpful for establishing the presence of splenic tissue versus neoplastic proliferation. It is also useful in patients with splenic trauma where splenosis can occur with fragmentation of the spleen with subsequent auto-transplantation of splenic tissue. Associated rupture of diaphragm can result in thoracic splenosis. Splenic scintigraphy with ^{99m}Tc sulfur colloid or ^{99m}Tc denatured RBCs can be utilized in distincting thoracic splenosis from thoracic neoplasm in patient presenting with thoracic mass and a previous history of splenic trauma.[28] SPECT imaging gives a

JAYPEE BROTHERS



Figure 3 Hepatobiliary iminodiacetic acid (HIDA) scan with ^{99m}Tc-mebrofenin. Serial images reveal progressive accumulation of radiotracer in gallbladder fossa suggestive of bile leak (arrows) consequent to blunt injury to abdomen in a road traffic accident

three dimensional view which gives a better information regarding distribution and presence of splenic tissue. Hybrid SPECT/CT imaging provides precise anatomical correlation of splenic scintigraphic foci with its corresponding anatomical region.

PROTEIN-LOSING ENTEROPATHY

Protein-losing enteropathy refers to GI disorders associated with excessive plasma protein loss into the lumen of the gut. It is caused by loss of integrity of the cell membranes of enterocytes mucosal erosion or ulceration.[29,30] Patients can become edematous due to albumin loss and decreased plasma oncotic pressure. Scintigraphy for diagnosing protein losing enteropathy was initially performed using ^{131}I-polyvinylpyrrolidone, ^{131}I-albumin,[31] ^{51}Cr-albumin[29] and ^{99m}Tc-albumin. Imaging with ^{99m}Tc-albumin allows imaging of the GI tract thereby localizing the site of protein loss. It is useful in directing resection for surgically correctable causes. ^{99m}Tc-HSA (human serum albumin) scans were more likely positive in patients with higher rates of protein loss.[32,33] ^{99m}Tc-dextran and ^{111}In-transferrin are the other radiotracer available for diagnosing protein losing enteropathy. ^{99m}Tc-dextran when compared to ^{99m}Tc-HSA has faster background clearance and better in vivo stability. ^{111}In-transferrin has the ability to identify and quantify the protein loss in single examination.[34]

INFLAMMATORY BOWEL DISEASES

Localizing and quantifying the inflammation in inflammatory bowel diseases (IBDs) are very crucial in determining the diagnosis, prognosis, and optimal therapy. Evaluation with endoscopy is invasive and usually requires sedation. Limited segment of colon and the small intestine are particularly the sites that are inaccessible to evaluation. ^{99m}Tc-WBC imaging is noninvasive and has demonstrated less perceived discomfort and embarrassment when compared with barium enema and colonoscopy.[35]

Evaluation with ^{99m}Tc-WBC

The labeling of leukocytes with ^{99m}Tc with 20–45 mL of venous blood is done. Imaging is performed with a large field of view gamma camera and images are obtained at 0.5 hour and 2–3 hours after the injection of ^{99m}Tc-WBC. The patient voids before each imaging. Additional anterior chest images may be acquired in patients with suspicion of Crohn's disease (CD), to evaluate for

JAYPEE BROTHERS

esophageal and gastric activity. Static anterior supine view of the abdomen and pelvis are obtained followed by SPECT imaging.

Scintigraphy with ^{99m}Tc-WBC has been reported to be sensitive for the detection of inflammation in adults.[36] The agreement between colonoscopy and ^{99m}Tc-WBC imaging for the localization and evaluation of the extent of inflammation is excellent. Noninvasiveness, evaluation of the entire bowel in single study, and less radiation exposure compared with barium radiograph are the merits of ^{99m}Tc-WBC scan.[37] The ^{99m}Tc-WBC scan plays important role in the initial evaluation, and follow-up of patients with IBD.

^{99m}Tc-WBC scan has limitations in defining anatomic details such as prestenotic dilations, fistulas, or strictures which are best identifies with barium radiographic scans. The ^{99m}Tc-WBC scan is safe even in acutely ill patients who may not tolerate an endoscopic or radiological study. ^{99m}Tc-WBC scan is complementary to endoscopic or radiological studies in most patients.

Evaluation with Fluorodeoxyglucose (FDG) PET/CT

Positron emission tomography enabled researchers to correctly identify active IBD in 80% of children with IBD and showed no evidence of inflammation in children without IBD but present with recurrent abdominal pain.[38] Recently we evaluated the role of PET/CT enteroclysis and PET/CT colonography in IBDs. PET/CT enteroclysis in a single investigation detects a significantly higher number of lesions both in the small and large intestine in comparison to that detected by conventional barium and colonoscopy combined together.[39] PET/CT colonography is a novel noninvasive technique for the assessment of extent and activity of the disease in patients with ulcerative colitis (UC).[40]

FDG PET/CT IN GI MALIGNANCY

^{18}F-Fluorodeoxyglucose PET imaging has been used in clinical oncology since late 1980s. Large scientific data from 1990s consolidated the utility of PET in clinical oncology especially in lung malignancy, colorectal malignancy, lymphoma, and melanoma. FDG uptake is considered as a surrogate for the metabolic activity of a malignancy, specifically linked to glucose metabolism in malignant cells. The role of FDG-PET imaging, in fact, may be related to the Warburg effect-the observation made by Otto Warburg in 1924 that suggested that cancer cells metabolize glucose differently from normal nonmalignant cells. Glucose uptake by malignant cells is largely mediated by the glucose transporter 1 (GLUT-1) transporter. It has been correlated that the standardized uptake value (SUV) in FDG-PET correlate with the expression of GLUT-1 and the Ki-67 proliferative marker, indicating an association with tumor aggressiveness. PET combined with CT in the form of hybrid PET/CT allows accurate localization of lesions with improved spatial resolution.

Certain basic principles to be noted before advising FDG PET/CT:

- FDG-PET should be performed only after 4–6 weeks post-chemotherapy, 6–8 weeks post-radiotherapy and 8–12 weeks post-surgery as there are possibilities for false positive uptake during or early after therapy due to inflammation.
- Metabolic information is especially advantageous in detection of recurrent disease when sensitive serum markers such as carcinoembryonic antigen (CEA) are abnormal and anatomic imaging is unrevealing.

Colorectal Cancer

The primary indications for FDG-PET in colorectal carcinoma are for staging, restaging and detection of recurrence. Elevated serum CEA levels with unrevealing conventional diagnostic imaging findings is the scenario where FDG-PET is especially useful in the evaluation of recurrent colorectal cancer. FDG-PET is well established as the most accurate imaging modality for staging, restaging and evaluation of colorectal recurrence (Figs 4A to E).

FDG-PET imaging is useful in the detection of primary and premalignant lesions of the colon.[41-44] Size of the lesion and grade of dysplasia are the dependent factors that affect the sensitivity. Tumor larger than 1 cm has higher sensitivity (72%), FDG-PET has a sensitivity ranging from 33% in low-grade lesions up to 76% in high-grade lesions.[44] False positive uptake can be noted in IBDs and diverticulitis. Also, physiologic uptake in colonic mucosa, lymphoid tissue, and smooth muscle should be carefully analyzed which usually shows diffuse uptake. So the focal nature of hypermetabolism is important to differentiate between benign and malignant lesions. IBDs and physiologic uptake tend to be diffuse or segmental, whereas the accumulations of FDG in premalignant and malignant lesions are focal and intense. Focal uptake in the colon should lead to further invasive investigation.

In patients with rectal carcinoma main indications for FDG-PET are therapy monitoring and diagnosis of relapses, especially the differentiation between tumor and scar and also the localization of tumor manifestations in cases with increasing tumor markers. FDG-PET is very efficient in the imaging of pulmonic and hepatic metastases of colorectal cancer but not in lymph node staging. For patients who present with advanced stage disease FDG-PET imaging can serve as a baseline scan before the start of chemotherapy. Because the degree of FDG uptake before starting with assessment of the overall tumor burden can serve as a powerful tool to determine appropriate response to treatment on follow-up scans. Most recurrences after surgical resection for colorectal cancer occur within the first 4 years for which FDG-PET is very useful. FDG-PET imaging can be particularly useful in monitoring response to therapy with neoadjuvant chemoradiotherapy. FDG-PET can differentiate benign from malignant lesions based on their metabolic activity and its biological aggressiveness can be assessed which allows early assessment of response to treatment. Metabolically active tumors can be detected even before a morphologic change is noted on anatomical imaging. Meta-analysis studies[45] showed an overall sensitivity of 97% and specificity of 76% for FDG-PET in detecting recurrent colorectal cancer. FDG PET/CT is also found to be useful in malignant melanoma of anal canal, rectum and colon.

Minimally Invasive Radionuclide Interventional Therapies

In patients with unresectable liver metastases radiofrequency (RF) ablation and Yttrium-90 (^{90}Y) microspheres radioembolization are increasingly becoming the interventional techniques of choice. FDG-PET appears to have great potential in identifying residual tumor soon after RF ablation. Liver metastases depend primarily on the hepatic arteries for their nutrition and growth. The principle of radioembolization is similar to chemoembolization. Patients with liver-lung shunt fractions greater than 20% is a contraindication for radioembolization with ^{90}Y microspheres.

JAYPEE BROTHERS

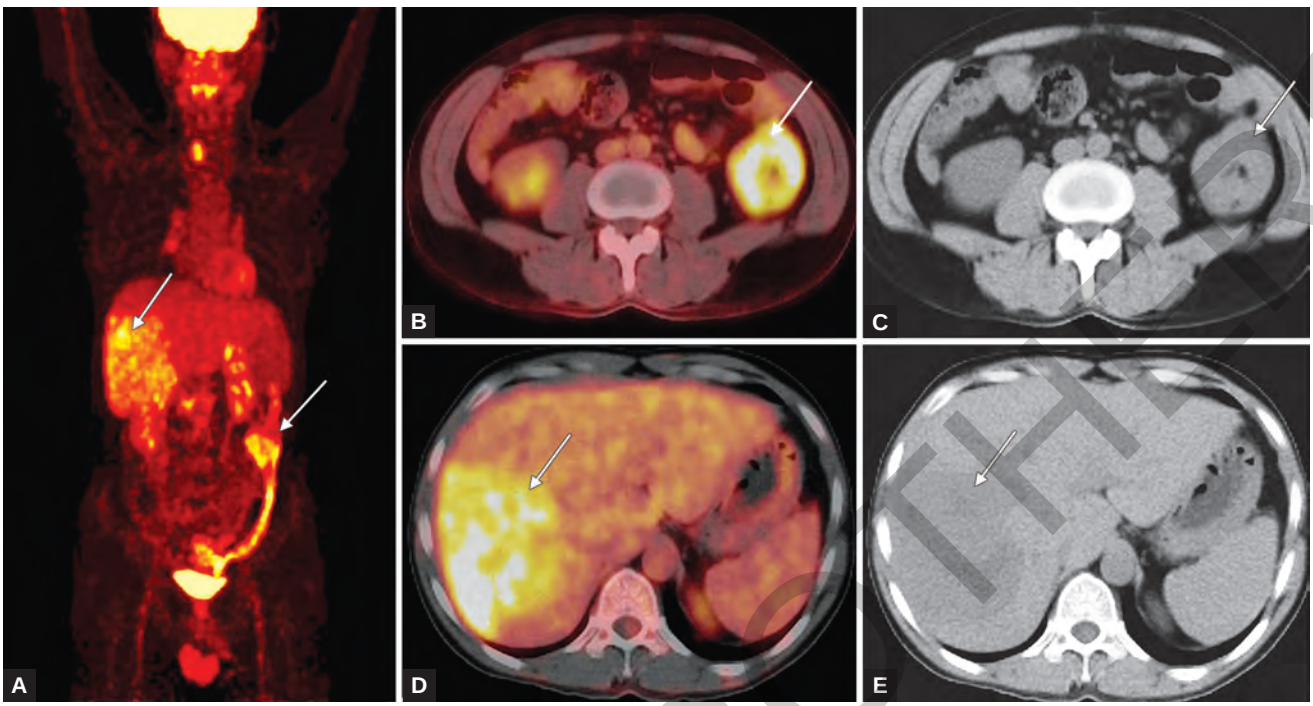

Figures 4A to E A 37-year-old male with colon carcinoma who underwent right hemicolectomy 8 years ago now presented with raising carcinoembryonic antigen (CEA) levels. He underwent ^{18}F-FDG PET/CT. Maximum intensity projection positron emission tomography (PET) image (A) and trans-axial PET/CT images (B to D) revealed recurrence in descending colon with hepatic metastatic lesions (arrows)

Esophageal Cancer

The sensitivity of detecting primary esophageal cancer with FDG-PET is high (90–100%).[46,47] It has superior sensitivity compared to CT alone. Esophagitis or other inflammation involving the esophagus can cause false positive uptake, which usually show mild linear diffuse uptake. Small or flat mucosal lesions and adenocarcinoma at or near the gastroesophageal junction can show false negative results with FDG-PET. Also, diffuse growth pattern and/or mucinous histopathology may show false negative results.[48,49]

Staging PET is limited in its ability to determine depth of tumor invasion. PET is complementary to CT for initial locoregional staging. The accuracy for distant metastasis was much higher than for CT-endoscopic ultrasound (CT-EUS). However, FDG-PET has lower accuracy for N staging when compared to CT-EUS. The lymph nodes adjacent to primary tumor usually show poor conspicuity due to intense primary tumor uptake. PET is also used in restaging, recurrence detection and in response evaluation to therapy (Figs 5A to D). FDG-PET is established as modality of highest sensitivity and accuracy for identifying distant metastatic disease in esophageal carcinoma. Also, response assessment to neoadjuvant therapy can be best performed with FDG PET/CT.

Gastric Carcinomas

The sensitivity of FDG-PET to detect locally advanced gastric carcinomas is dependent on the microscopic growth type of the tumor. Due to variable intense physiologic uptake of FDG within the gastric wall primary tumor of the stomach is difficult to identify with usual protocol FDG PET/CT. Distending the stomach with water improves the accuracy of detection of gastric lesions both preoperatively and in the postoperative remnant stomach. False positive FDG uptake can occur in acute inflammatory conditions such as superficial or erosive gastritis. The sensitivity of PET is low for the detection of metastatic lymph nodes, if size of the node is less than 6 mm as the spatial resolution is low for less than 6mm lesions.

Histologic subtype of the tumor is a strong dependent factor for FDG uptake and inversely correlates with the content of mucus.[50-52] The nonintestinal cell type, in the signet ring or mucinous cell types show low FDG uptake. If the primary tumor show FDG uptake, preliminary studies show a change in post-therapy uptake can serve as a good predictor of response to therapy and survival.

In response evaluation, the FDG-PET has advantage over CT. FDG-PET can demonstrate a decrease in FDG uptake at an earlier stage than could be demonstrated by CT and other conventional imaging methods. Also, CT response by RECIST (Response Evaluation Criteria in Solid Tumors) is measured by the change in size which may be a late manifestation of a response. FDG-PET has higher specificity (70–100%) for the detection of recurrent disease.

Gastrointestinal Stromal Tumors

Gastrointestinal stromal tumors (GIST) are considered as uncommon tumors of the GI tract and are now believed to be not sarcomas and to be arising from interstitial cells of Cajal or primitive

JAYPEE BROTHERS

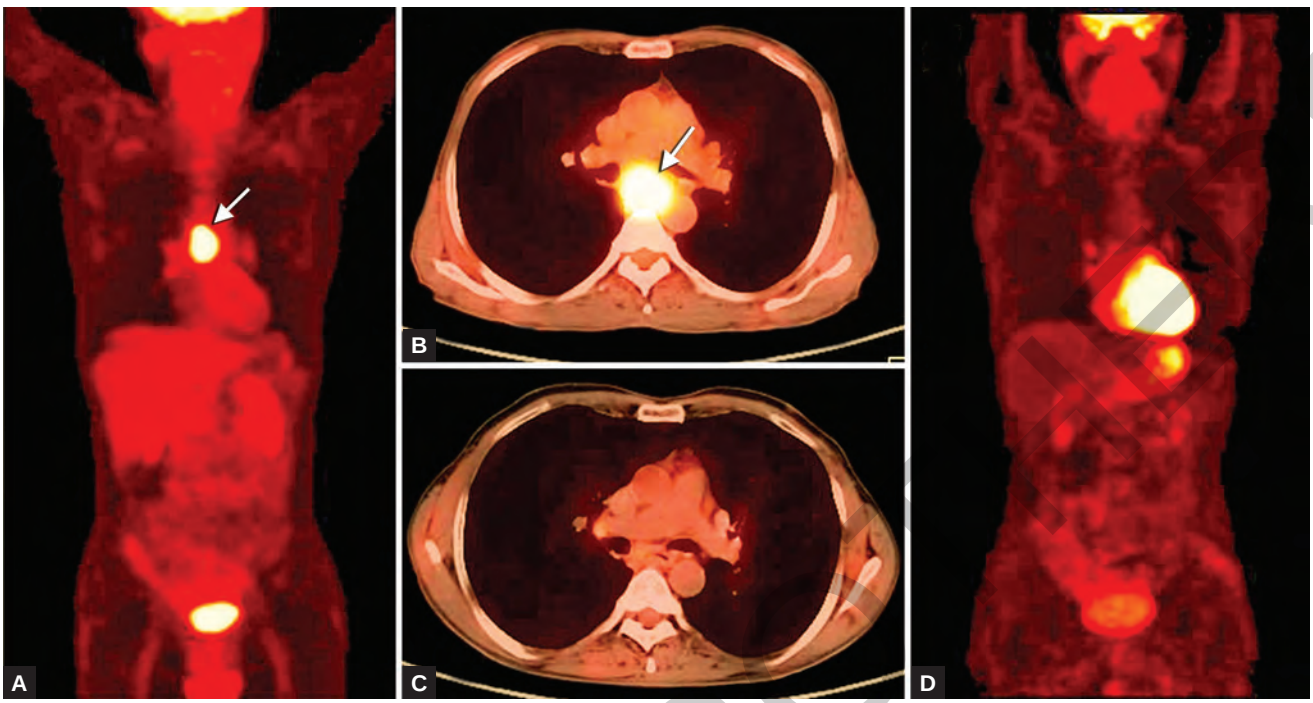

Figures 5A to D A 55-year-old male with esophageal carcinoma underwent ^{18}F-FDG PET/CT as a baseline study and as a response evaluation study. His baseline staging study revealed a mass lesion in lower esophagus (A, B; arrows) with no distant metastasis. His response evaluation study after three cycles of neoadjuvant chemotherapy (C and D) revealed complete resolution of the disease implying significant response to chemotherapy

cells in the GI tract. The prognostic information was better seen in FDG-PET images than in CT findings.[53] FDG-PET is useful for the recurrence detection (Figs 6A to G), monitoring of therapy and also in initial staging. GIST show highly variable uptake on FDG-PET. FDG-PET appears to be useful in assessing response to imatinib mesylate (Gleevec) therapy and prognosis if the tumor lesion show high uptake on the initial FDG scan.[54,55]

Hepatocellular Carcinoma

Hepatocellular carcinoma (HCC) is potentially curable by surgical resection, but surgery is the treatment of choice for only a small fraction of patients with localized disease. HCC has lower FDG accumulation in well-differentiated and low-grade tumors than in high-grade tumors (Figs 7A to F), as the much needed GLUT-1 concentration which is necessary for FDG uptake is low in well differentiated HCC.[56] Recently ^{11}C-acetate PET showed a good sensitivity of 87% compared with that of 47% with FDG-PET in HCC detection.[57] Hence the importance of ^{18}F-FDG-PET in the management of HCC is mainly in detecting extrahepatic spread. FDG-PET/CT may be helpful in surveillance after therapy and detection of local recurrence or occult metastatic disease in patients with unexplained serum alpha fetoprotein (AFP) elevation after interventional treatment (e.g., transarterial chemoembolization or RF ablation) and negative conventional imaging.[58] FDG-PET/CT sensitivity for detection of HCC depends on the underlying tumor grade. However, when assessed from the point of view of tumor characterization and prognosis, HCCs with low FDG uptake tend to be low grade and associated with improved patient outcome. High tumor FDG uptake in patients who are candidates for liver transplantation is associated with higher risk of tumor recurrence postoperatively (Figs 7A to F). Radiotracers of lipogenesis appear to be complementary to FDG. In particular, radiolabeled acetate and choline are useful in the imaging evaluation of well-differentiated tumors that do not sufficiently accumulate FDG.

Cholangiocarcinoma and Gallbladder Cancer

Limited data regarding use of FDG-PET, but evidence supports good sensitivity with potential false negative results in mucinous adenocarcinomas. Also, granulomatous disease, sclerosing cholangitis and stents can show FDG uptake and mimic malignancy.[59] Currently FDG PET/CT is used to detect distant metastasis, recurrence detection and in response evaluation (Figs 8A to H). Recently we evaluated the role of FDG PET/CT in recurrent gallbladder cancer (GBC).We found that FDG PET/CT can detect recurrence in GBC with high sensitivity and specificity and its routine use in these patients will detect recurrence early and change the subsequent management.[60]

Pancreatic Cancer

In diagnostic procedures for pancreatic carcinoma, FDG-PET can be recommended to explore the dignity of pancreatic lesions and in the imaging of tumor relapses. In order to stage the depth of invasion or to determine the invasion of local-regional structures

JAYPEE BROTHERS

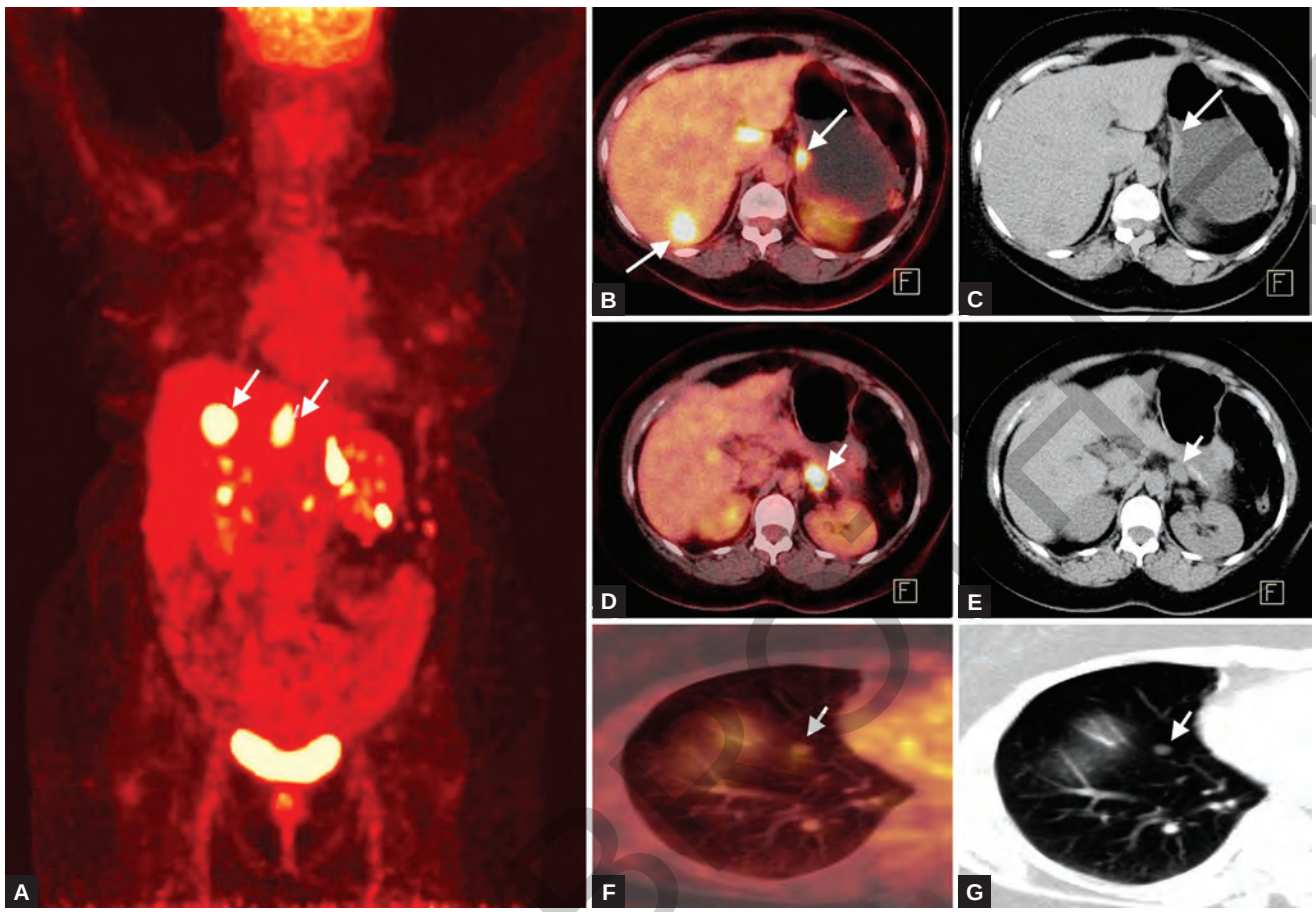

Figures 6A to G A 45-year-old female who was a known case of gastric gastrointestinal stromal tumor (GIST) underwent surgical resection now referred for PET/CT to rule out recurrence. She underwent ^{18}F-FDG PET/CT. Maximum intensity projection PET image (A) and transaxial PET/CT images (B to G) revealed recurrence in stomach with hepatic, perigastric lymph node and lung metastatic lesions (arrows)

by the primary tumor, thin slice CT or EUS are generally preferred. FDG-PET has limited role in delineating the anatomical boundaries of the primary tumor for respectability decision. Also, FDG-PET is poorly sensitive for the locoregional lymph node metastases detection, which may be due to their proximity to the primary lesion. FDG-PET is sensitive for the detection of metastatic disease to the liver and bone (Figs 9A to E).

The sensitivity of PET in detecting pancreatic cancer is similar to that of CT, but PET seems to be more specific. Sperti et al. found a sensitivity of 94% for both modalities, but PET was significantly more accurate in identifying malignancy.[61] FDG-PET is superior for detection of a treatment response to chemoradiotherapy. PET was superior to the combination of CT and MRI in the detection of recurrence (96% versus 39%). PET may be superior in the detection of recurrence within the tumor bed, but CT/MRI may have better discriminatory power within the hepatic parenchyma. PET may also complement the use of tumor markers or CT for the detection of recurrent disease when CT findings are equivocal. FDG-PET certainly plays a role in the detection of nonlocoregional and extra-abdominal metastases, but the role of FDG-PET in the initial diagnosis is questionable.

Carcinoma of Unknown Primary

For carcinoma of unknown primary (CUP), FDG-PET has shown overall modest sensitivity. The majority of these tumors prove to be from head and neck and lung carcinomas, but occult GI tumors are sometimes detected (< 10% incidence).[62,63]

In short, ^{18}F-FDG PET/CT imaging is highly accurate in restaging colorectal cancer, esophageal cancer and GISTs. Also, it has great potential in predicting treatment response early in the course of therapy. Initial staging with FDG-PET is usually restricted to patients with locally advanced disease who may benefit from curative resection if distant metastases are not found. For each GI malignancy, depth of invasion and nodal status are not well evaluated by FDG-PET scans. However, for locally-advanced malignancies, an FDG-PET scan may be used to identify occult metastatic disease which may then significantly change the treatment plan.

NEUROENDOCRINE TUMORS

Fluorodeoxyglucose PET/CT has revolutionized the imaging evaluation of patients with cancer. However, some cancers

JAYPEE BROTHERS

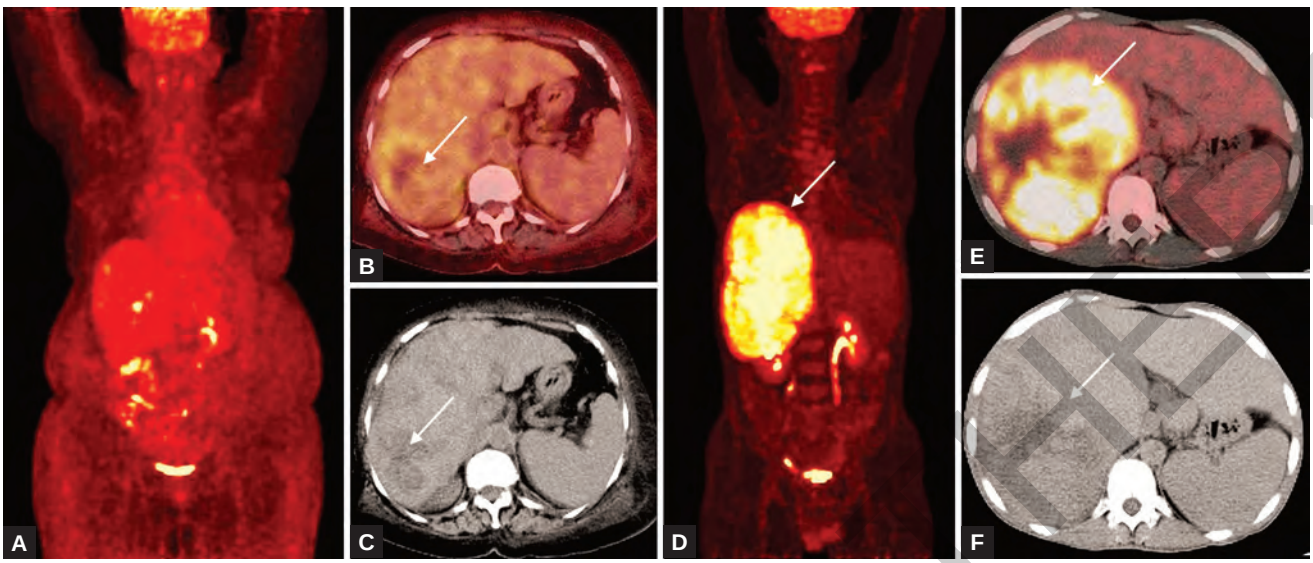

Figures 7A to F ^{18}F-FDG PET/CT studies in hepatocellular carcinoma (HCC) in two different scenarios. Well differentiated low grade HCC are often less fluorodeoxyglucose (FDG) avid lesions as depicted in maximum intensity projection positron emission tomography (PET) image (A) and trans-axial PET/CT images (B, C; arrows) where there is a hypodense lesion with less FDG avidity. High grade and poorly differentiated HCC are intense FDG avid lesions as depicted in maximum intensity projection PET image (D; arrows) and transaxial PET/CT images (E, F; arrows)

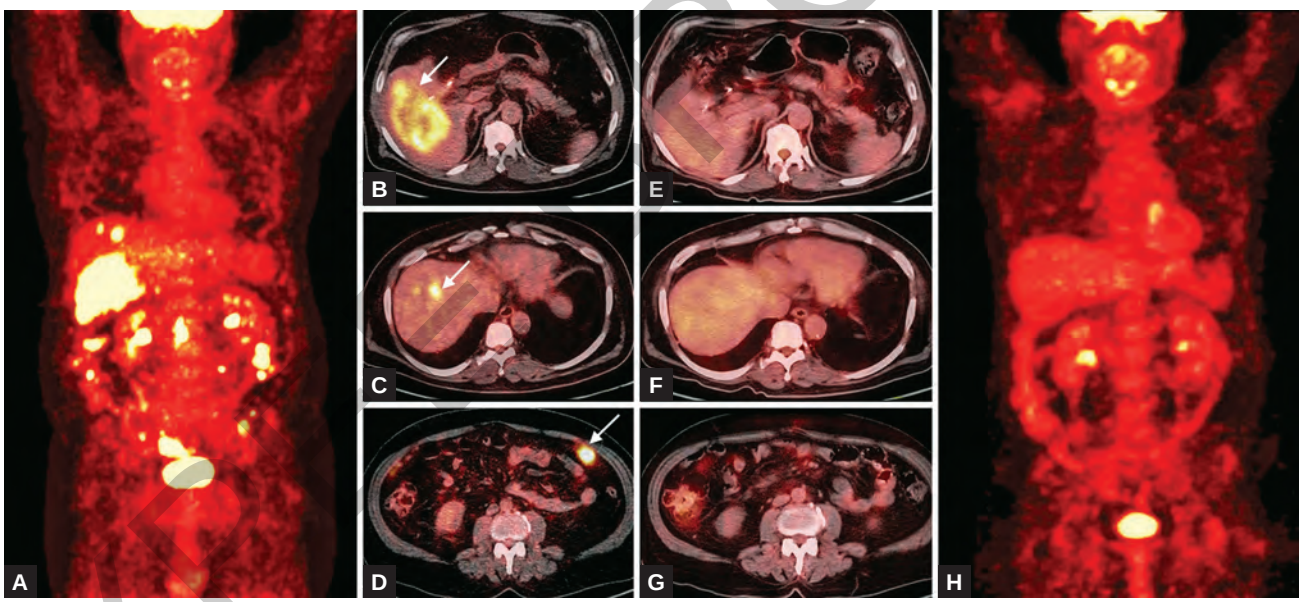

Figures 8A to H A 56-year-old male with gallbladder carcinoma underwent ^{18}F-Fluorodeoxyglucose positron emission tomography/computed tomography (^{18}F-FDG PET/CT) as a baseline study and as a response evaluation study. His baseline staging study revealed a mass lesion in gallbladder with adjacent hepatic involvement with hepatic and mesenteric lymph node metastasis (A to D; arrows). His response evaluation study after chemotherapy (E to H) revealed complete resolution of the disease implying significant response to chemotherapy

demonstrate low FDG avidity. It has been argued that although a negative FDG-PET scan may be interpreted as false-negative in terms of detectability of a tumor of sufficient size above the spatial resolution of PET, it should be considered true-negative with regard to tumor aggressiveness.[64] Other potentially useful PET radiotracers have been developed for tumors of hepatic, pancreatic, and GI origin, which may demonstrate low FDG uptake.

Neuroendocrine tumors (NETs) are a heterogeneous, generally indolent group of tumors that stem from the neural crest with main localization in the gastroenteropancreatic tract (e.g. carcinoids, insulinoma, glucagonoma, VIPoma, gastrinoma, somatostatinoma). A functioning NET, for instance in the pancreas, may be very small and yet give rise to severe endocrine symptoms whereas a patient with a small bowel tumor may present with diffuse symptoms and

JAYPEE BROTHERS

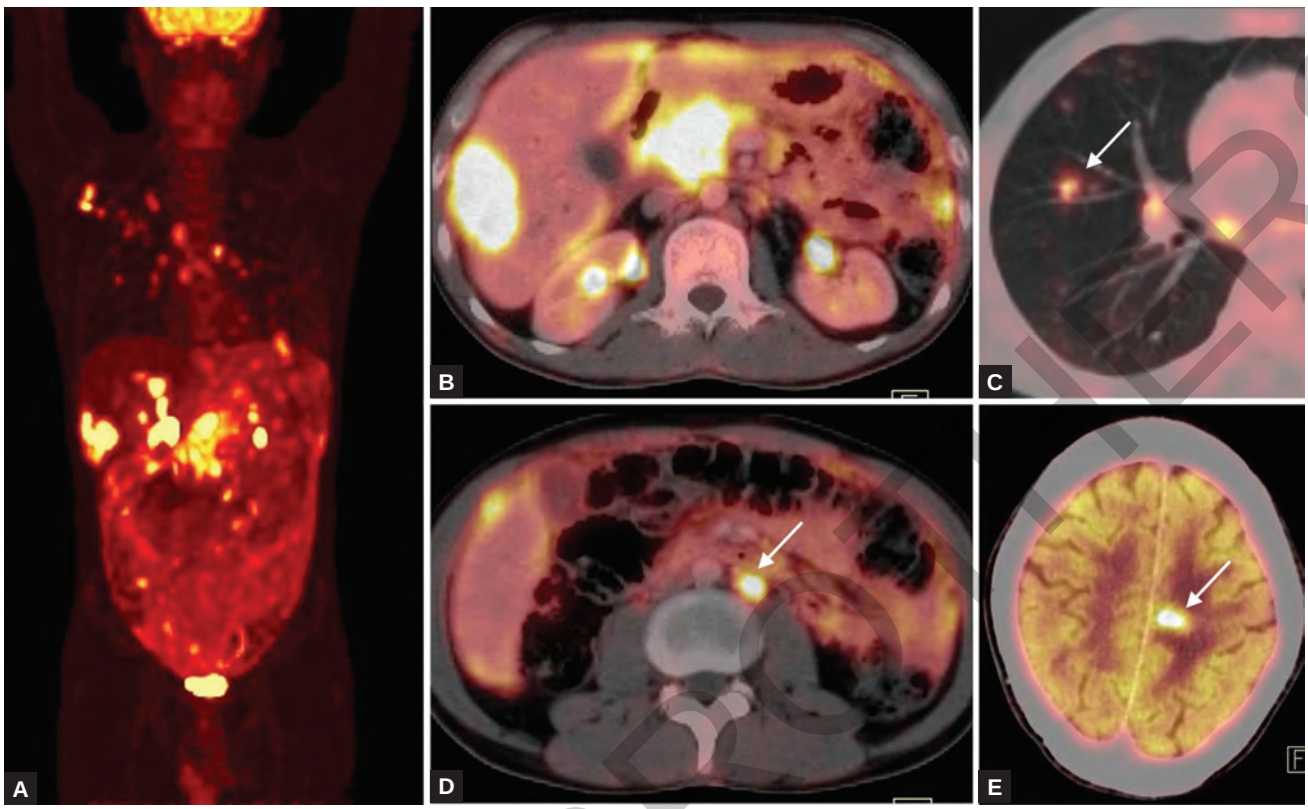

Figures 9A to E ^{18}F-Fluorodeoxyglucose positron emission tomography/computed tomography (^{18}F-FDG PET/CT) baseline staging study in a 57-year-old male with pancreatic cancer with raised cancer antigen (CA) 19.9 levels. Maximum intensity projection PET image (A) and trans-axial PET/CT images (B to E) revealed primary mass in pancreatic head with lung, para-aortic lymph node and brain metastatic lesions (arrows)

disseminated disease with a palpable bulky liver. The liver is a major site for metastases.

Imaging of NETs is therefore challenging and the imaging needs in the various patients are diverse. Imaging evaluation of NETs with PET has evolved rapidly in the recent years. The basic modalities for NET imaging are CT or MRI in combination with somatostatin receptor scintigraphy (SRS) with ^{111}In-labeled octreotide (OctreoScan) or more recently by PET with ^{68}Ga-labeled somatostatin analogues. Most of the NETs are well differentiated and low grade tumors which are less likely to be positive with FDG-PET. NETs express somatostatin tumor receptor (SSTR) which forms the basis for imaging with SRS. For SSTR imaging of the NET and its metastases, previously scintigraphy with somatostatin analogue pentetreotide radiolabeled SPECT agents by means of ^{111}In ($T_{1/2}$ = 2.8 days) or ^{99m}Tc-hydrazinonicotinyl (HYNIC)-Tyr3-octreotide were used.

Presently, PET tracer with somatostatin analogues as *68Ga-DOTA-NOC* ($T_{1/2}$= 68 min; ^{68}Ga-DOTA-1-NaI3-octreotide) that bind to the SSTR using the chelator 1,4,7,10-tetraazacyclododecane-*N,N=,N_,N_=*-tetraacetic acid (DOTA) is widely used and commonly performed (Figs 10A to F). ^{68}Ga-DOTA-peptides are generator produced unlike ^{18}F-FDG which is cyclotron produced. ^{68}Ga-DOTA-NOC uptake in gastroenteropancreatic NET correlates strongly with the tumor-associated overexpression of SSRT (subtypes 2A and 5).[65] Other current relevant tracers include the ^{68}Ga-DOTA-peptides (^{68}Ga-DOTAd- Phe1-Tyr3-octreotide, abbreviated as ^{68}Ga-DOTATOC; and ^{68}Ga-DOTA-DPhe1, Tyr3-octreotate, abbreviated as ^{68}Ga-DOTA-TATE).[65,66] First introduced in clinical application in 2005, ^{68}Ga-DOTATOC was reported to present a high tumor to non-tumor contrast and a higher sensitivity compared to SRS.[67,68] ^{68}Ga-DOTANOC has revealed promising results in preliminary studies for the main clinical indications: staging NET; suspected NET of unknown primary; follow-up, restaging and, finally for pre- and post-treatment evaluation of receptor radionuclide therapies.

In patients with inoperable or metastasized NETs, radiolabeled somatostatin analogues is a promising new tool in the treatment management. ^{111}In, ^{90}Y and ^{177}Lu labeled somatostatin analogues have been used for peptide receptor radionuclide therapy (PRRT). Symptomatic relief and tumor regression has been documented with [^{90}Y-DOTA0, Tyr3] octreotide and ^{177}Lu-DOTA-TATE therapy. Kidney protective agents are used to neutralize the side effects of this therapy. The patients' self-assessed quality of life increases significantly after ^{177}Lu-DOTA-TATE therapy. In our department we use ^{177}Lu-DOTA-TATE routinely for inoperable or metastasized NETs.

^{18}F-FDOPA ($T_{1/2}$ = 109 minutes; fluoro-3,4-dihydroxyphenylalanine)[69] is an another promising PET tracer recently being evaluated for NETs. ^{18}F-FDOPA uptake mechanism is different from SRS and ^{68}Ga-DOTA-NOC uptake mechanism.

JAYPEE BROTHERS

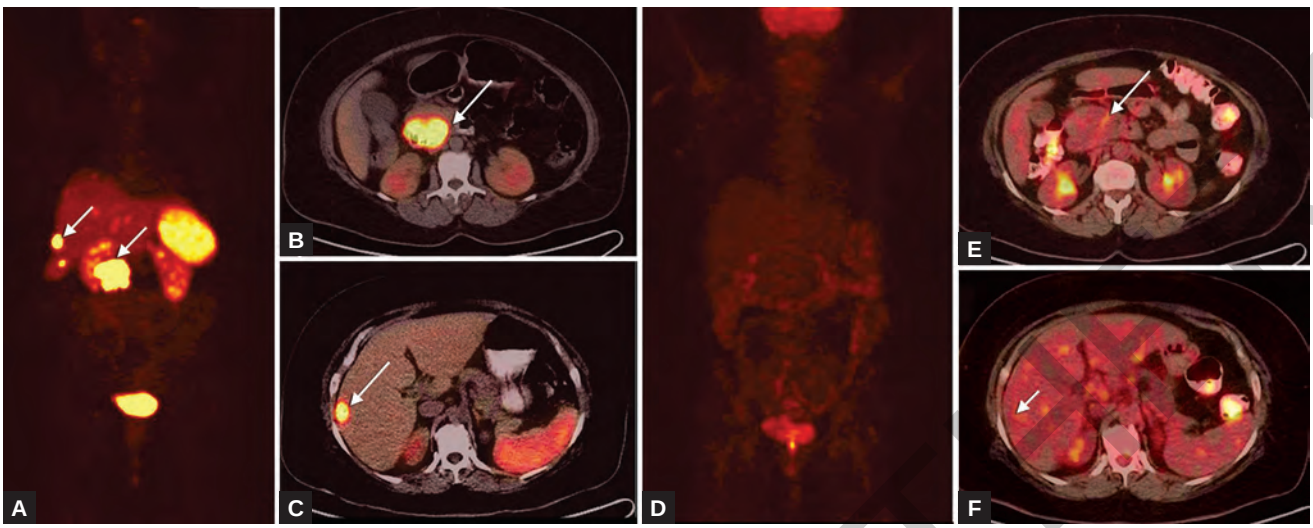

Figures 10A to F ^{68}Ga-DOTONOC positron emission tomography/computed tomography (PET/CT) and ^{18}F-FDG PET/CT studies in a case of pancreatic neuroendocrine tumor (NET). ^{68}Ga-DOTONOC PET/CT maximum intensity projection PET image (A) and trans-axial PET/CT images (B and C) revealed a DOTONOC avid primary pancreatic NET with hepatic metastasis (arrows). The same patient was false negative on ^{18}F-FDG PET/CT study as the corresponding lesions revealed no abnormal uptake (D to F; arrows)

^{18}F-FDOPA is concentrated by NETs through a large neutral amino acid transporter (LAT1)[70] that are upregulated and highly active in the cells of these tumors. Hybrid PET/CT allows for three-dimensional (3D) image acquisition and display as well as improved image interpretation.

In a recent investigation from our institution, we compared ^{68}Ga-DOTA-TOC PET/CT with FDG-PET/CT and contrast-enhanced CT to assess 20 patients with clinically suspected or known pancreatic NET.[71] The primary tumor was correctly localized in all 20 patients using ^{68}Ga-DOTA-TOC PET/CT, whereas contrast-enhanced CT correctly identified the tumors in 15 patients, and FDG-PET/CT, performing poorly with correct detection, identified the tumors in only two patients. Similar comparative findings were also noted for detection of metastatic disease.

Also, in another single-center study from our institution, 109 patients with gastroenteropancreatic NETs were evaluated with ^{68}Ga-DOTA-NOC PET/CT.[72] It performed significantly better than conventional imaging, with sensitivity and specificity of 78.3% and 92.5%, respectively, for detection of primary tumor and 97.4% and 100%, respectively, for identification of metastases. ^{68}Ga-DOTA-NOC PET/CT impacted the clinical management in 19% of patients. A potential confounding factor for PET tracer avidity to the somatostatin receptor may be competition with therapeutic unlabeled somatostatin analogs, such as octreotide or drug induced internalization of the somatostatin subtype 2 receptors. In summary, the experience with non-FDG tracers in NET is evolving and expanding rapidly. Recently, simultaneous ^{68}Ga-DOTATOC PET/MRI acquisition was shown to have special advantages in the characterization of abdominal lesions. Thus, hybrid imaging such as PET/CT or PET/MRI will play an important role in the future. Additional studies will be expected to define the exact role of these novel tracers in the imaging evaluation of patients with NET in the next several years.

Poorly differentiated neuroendocrine carcinomas (PDNEC) are rare tumors that can originate from any site of the GI tract. They usually exhibit an overall aggressive behavior which may vary between tumors according to the degree of cellular proliferation. Locally advanced nature and/or initial metastatic presentation are common. High mitotic rate, high Ki-67 labeling index and presence of necrosis can be noted on histology signifying aggressiveness. Somatostatin receptors expression is less in PDNEC and SRS is usually negative, whereas ^{18}F-FDG PET appears to be the best method of evaluating PDNEC.

Hyperinsulinism of Infancy

Congenital hyperinsulinism induces hypoglycemia in infants and treatment is required to prevent possible neurologic complications. Focal hyperinsulinism is cured by resection of the adenoma, whereas diffuse pancreatic involvement may be treated with subtotal pancreatectomy.[73] ^{18}F-FDOPA PET/CT has been used to preoperatively classify the form of infantile hyperinsulinism.[69,73]

REFERENCES

1. Treves ST, Grand RJ. Gastrointestinal bleeding. In: Treves ST (Ed). Pediatric Nuclear Medicine, 2nd edition. New York: Springer-Verlag; 1995. pp. 453-65.
2. Rossi P, Gourtsoyiannis N, Bezzi M. "Meckel's diverticulum: imaging diagnosis," American Journal of Roentgenology; 1996. pp. 567-73.
3. Yahchouchy EK, Marano AF, Etienne JF, Fingerhut AL. "Meckel's diverticulum," Journal of the American College of Surgeons; 2001. pp. 658-62.
4. Maurer AH. Gastrointestinal bleeding. In: Ell PJ, Gambhir GG (Eds). Nuclear Medicine in Clinical Diagnosis and Treatment, 3rd edition. Sydney: Churchill Livingstone; 2004. pp. 911-17.

JAYPEE BROTHERS

5. Kumar R, Tripathi M, Chandrashekar N, Agarwala S, Kumar A, Dasan JB, et al. Diagnosis of ectopic gastric mucosa using ^{99m}Tc-pertechnetate: ^{99m}Tc-pertechnetate: spectrum of scintigraphic findings. Br J Radiol. 2005;78(932):714-20.
6. Ziessman HA, O'Malley JP, Thrall JH. Nuclear medicine. The Requisites in Radiology. Philadelphia: Elsevier, Mosby; 2006.
7. Alavi A, Ring EJ. Localization of gastrointestinal bleeding: superiority of ^{99m}Tc sulfur colloid compared with angiography. AJR Am J Roentgenol. 1981;137(4):741-8.
8. Alavi A, Worsley D, Zhuang H. Scintigraphic detection and localization of gastrointestinal bleeding sites. In: Sandler MP, Coleman RE, Patton JA (Eds). Diagnostic Nuclear Medicine, 4th edition. Philadelphia: Lippincott Williams and Wilkins; 2003. pp. 531-51.
9. Zuckier LS. Acute gastrointestinal bleeding. Semin Nucl Med. 2003;33:297-311.
10. Zettinig G, Staudenherz A, Leitha T. The importance of delayed images in gastrointestinal bleeding scintigraphy. Nuc Med Commun. 2002;23:803-8.
11. Ford PV, Bartold SP, Fink-Bennett DM, Jolles PR, Lull RJ, Maurer AH, et al. Procedure guidelines for gastrointestinal bleeding and Meckel's diverticulum scintigraphy. Society of Nuclear Medicine. J Nucl Med. 1999;40(7):1226-32.
12. Miskowiak J, Nielsen SL, Munck O, Andersen B. Abdominal scintiphotography with Tc99m technetium labelled albumin in acute gastrointestinal bleeding. Lancet. 1977;2:852-4.
13. Ferrant A, Dehasque N, Leners N, Meunier H. Scintigraphy with In-111- labeled red cells in intermittent gastrointestinal bleeding. J Nucl Med. 1980;21:844-5.
14. Ozcan Z, Ozcan C, Erinc R, Dirlik A, Mutaf O. Scintigraphy in the detection of gastro-oesophageal reflux in children with caustic oesophageal burns: a comparative study with radiography and 24-h pH monitoring. Pediatr Radiol. 2001;31:737-41.
15. Aktas A, Ciftci I, Caner B. The relationship between the degree of gasto-oesophageal reflux and the rate of gastric emptying. Nucl Med Commun. 1999;20:907-10.
16. Gainey MA. Radionuclide diagnosis. In: Walker WA, Durie PR, Hamilton JR (Eds). Pediatric Gastrointestinal Disease, 3rd edition. Canada: Decker CB; 2000. pp. 1655-75.
17. Mann MD, Wynchank S. Esophageal function (transport and motility). In: Ell PJ, Gambhir SS (Eds). Nuclear Medicine in Clinical Diagnosis and Treatment, 3rd edition. Edinburgh: Churchill Livingstone; 2004. pp. 789-803.
18. Da-Costa-Pinto EA, Dorsa TK, Altimani A, Andreollo NA, Cardoso SR, Morais DJ, et al. A functional study of caustic strictures of the esophagus in children. Braz J Med Biol Res. 2004;37:1623-30.
19. Chatterton BE. Gastric motility. In: Ell PJ, Gambhir SS (Eds). Nuclear Medicine in Clinical Diagnosis and Treatment, 3rd edition. Edinburgh: Churchill Livingstone; 2004. pp. 805-18.
20. Parkman HP, Hasler WL, Fisher RS. American Gastroenterological Association technical review on the diagnosis and treatment of gastroparesis. Gastroenterology. 2004;127:1592-1622.
21. Cook BJ, Lim E, Cook D, Hughes J, Chow CW, Stanton MP, et al. Radionuclear transit to assess sites of delay in large bowel transit in children with chronic idiopathic constipation. J Pediatr Surg. 2005;40:478-83.
22. Burton DD, Camilleri M, Mullan BP, Forstrom LA, Hung JC. Colonic transit scintigraphy labeled activated charcoal compared with ion exchange pellets. J Nucl Med. 1997;38:1807-10.
23. Kim CK, Norton KI, Shneider BL. Neonatal hyperbilirubinemia. In: Ell PJ, Gambhir SS (Eds). Nuclear Medicine in Clinical Diagnosis and Treatment, 3rd edition. Edinburgh: Churchill Livingstone; 2004. pp. 927-34.
24. Wessmann HS, Frank MS, Bernstein LH, Freeman LM. Rapid and accurate diagnosis of acute cholecystitis with ^{99m}Tc-HIDA cholescintigraphy. Am J Roentgenol. 1979;132:523-8.
25. Freitas JE. Cholescintigraphy. In: Ell PJ, Gambhir SS (Eds). Nuclear Medicine in Clinical Diagnosis and Treatment, 3rd edition. Edinburgh: Churchill Livingstone; 2004. pp. 919-26.
26. Ziessman HA, Zeman RK, Akin EA. Cholescintigraphy: correlation with other hepatobiliary imaging modalities. In: Sandler MP, Coleman RE, Patton JA (Eds). Diagnostic Nuclear Medicine, 4th edition. Philadelphia: Lippincott Williams and Wilkins; 2003. pp. 503-29.
27. Shuckett B. Cross-sectional imaging: ultrasonography, computed tomography, magnetic resonance imaging. In: Walker WA, Durie PR, Hamilton JR (Eds). Pediatric Gastrointestinal Disease, 3rd edition. Canada: Decker BC; 2000. pp. 1591-660.
28. Nadel HR. Hepatobiliary scintigraphy in children. Semin Nucl Med. 1996;26:25-42.
29. Gleason WA. Protein-losing enteropathy. In: Wyllie R, Hyams JS (Eds). Pediatric Gastrointestinal Disease, 2nd edition. Philadelphia: Saunders; 1999. Pp. 298-305.
30. Proujansky R. Protein-losing enteropathy. In: Walker WA, Durie PR, Hamilton JR (Eds). Pediatric Gastrointestinal Disease, 3rd edition. Canada: Decker CB; 2000. pp. 89-102.
31. Freeman T, Gordon AH. Measurement of albumin leak into the gastrointestinal tract using 131-I-albumin and ion exchange resins by mouth. Gut. 1964;6:155-7.
32. Shah ND, Chitkara DK, Locke GR, Meek PD, Talley NJ. Ambulatory care for constipation in the United States, 1993-2004. Am J Gastroenterol. 2008;103:1746-53.
33. Choung RS, Locke GR 3rd, Schleck CD, Zinsmeister AR, Talley NJ. Cumulative incidence of chronic constipation: a population-based study 1988-2003. Aliment Pharmacol Ther. 2007;26: 1521-8.
34. Burton DD, Camilleri M, Mullan BP, Forstrom LA, Hung JC. Colonic transit scintigraphy labeled activated charcoal compared with ion exchange pellets. J Nucl Med. 1997;38:1807-10.
35. Nelson RL, Schwartz A, Pavel D. Assessment of the usefulness of a diagnostic test: A survey of patient preference for diagnostic techniques in the evaluation of intestinal inflammation. BMC Med Res Methodol. 2001;1:5.
36. Charron M, Fernando del Rosario J, Kocoshis S. Distribution of acute bowel inflammation determined by technetium-labeled white blood cells in children with inflammatory bowel disease. Inflamm Bowel Dis. 1998;4:84-8.
37. Shields RA, Lawson RS. Effective dose equivalent. Nucl Med Commun. 1987;8:851-5.
38. Lemberg DA, Issenman RM, Cawdron R, Green T, Mernagh J, Skehan SJ, et al. Positron emission tomography in the investigation of pediatric inflammatory bowel disease. Inflamm Bowel Dis. 2005;11:733-8.
39. Das CJ, Makharia G, Kumar R, Chawla M, Goswami P, Sharma R, et al. PET-CT enteroclysis: a new technique for evaluation of inflammatory diseases of the intestine. Eur J Nucl Med Mol Imaging. 2007;34:2106-14.
40. Das CJ, Makharia GK, Kumar R, Kumar R, Tiwari RP, Sharma R, et al. PET/CT colonography: a novel non-invasive technique for assessment of extent and activity of ulcerative colitis. Eur J Nucl Med Mol Imaging. 2010;37:714-21.
41. Friedland S, Soetikno R, Carlisle M, Taur A, Kaltenbach T, Segall G, 18-Fluorodeoxyglucose positron emission tomography has limited sensitivity for colonic adenoma and early stage colon cancer. Gastrointest Endosc. 2005;61:395-400.
42. Gutman F, Alberini JL, Wartski M, Vilain D, Le Stanc E, Sarandi F, et al. Incidental colonic focal lesions detected by FDG PET/CT. AJR Am J Roentgenol. 2005;185:495-500.
43. Kamel EM, Thumshirn M, Truninger K, Schiesser M, Fried M, Padberg B, et al. Significance of incidental 18F-FDG accumulations in the gastrointestinal tract in PET/CT: correlation with endoscopic and histopathologic results. J Nucl Med. 2004;45:1804-10.

JAYPEE BROTHERS

44. Van Kouwen MC, Nagengast FM, Jansen JB, Oyen WJ, Drenth JP. 2-(18F)-fluoro-2- deoxy-D-glucose positron emission tomography detects clinical relevant adenomas of the colon: a prospective study. J Clin Oncol. 2005;23:3713-7.
45. Huebner RH, Park KC, Shepherd JE, Schwimmer J, Czernin J, Phelps ME, et al. A meta-analysis of the literature for whole-body FDG PET detection of recurrent colorectal cancer. J Nucl Med. 2000;41:1177-89.
46. Yoon YC, Lee KS, Shim YM, Kim BT, Kim K, Kim TS. Metastasis to regional lymph nodes in patients with esophageal squamous cell carcinoma: CT versus FDG PET for presurgical detection prospective study. Radiology. 2003;227:764-70.
47. Heeren PA, Jager PL, Bongaerts F, van Dullemen H, Sluiter W, Plukker JT. Detection of distant metastases in esophageal cancer with (18)F-FDG PET. J Nucl Med. 2004;45:980-7.
48. Sihvo EI, Rasanen JV, Knuuti MJ, Minn HR, Luostarinen ME, Viljanen T, et al. Adenocarcinoma of the esophagus and the esophagogastric junction: Positron emission tomography improves staging and prediction of survival in distant but not in locoregional disease. J Gastrointest Surg. 2004;8:988-96.
49. Flamen P, Lerut T, Haustermans K, Van Cutsem E, Mortelmans L. Position of positron emission tomography and other imaging diagnostic modalities in esophageal cancer. Q J Nucl Med Mol Imaging. 2004;48:96-108.
50. Ott K, Weber WA, Fink U, Helmberger H, Becker K, Stein HJ, et al. Fluorodeoxy glucose positron emission tomography in adenocarcinomas of the distal esophagus and cardia. World J Surg. 2003;27:1035-9.
51. Stahl A, Ott K, Weber WA, Becker K, Link T, Siewert JR, et al. FDG PET imaging of locally advanced gastric carcinomas: correlation with endoscopic and histopathological findings. Eur J Nucl Med Mol Imaging. 2003;30:288-95.
52. Yoshioka T, Yamaguchi K, Kubota K, Saginoya T, Yamazaki T, Ido T, et al. Evaluation of 18F-FDG PET in patients with a, metastatic, or recurrent gastric cancer. J Nucl Med. 2003;44:690-9.
53. Goerres GW, Stupp R, Barghouth G, Hany TF, Pestalozzi B, Dizendorf E, et al. The value of PET, CT and in-line PET/CT in patients with gastrointestinal stromal tumors: Long-term outcome of treatment with imatinib mesylate. Eur J Nucl Med Mol Imaging. 2005;32:153-62.
54. Goerres GW, Stupp R, Barghouth G, Hany TF, Pestalozzi B, Dizendorf E, et al. The value of PET, CT and in-line PET/CT in patients with gastrointestinal stromal tumors: long-term outcome of treatment with imatinibmesylate. Eur J Nucl Med Mol Imaging. 2005;32:153-62.
55. Antoch G, Kanja J, Bauer S, Kuehl H, Renzing-Koehler K, Schuette J, et al. Comparison of PET, CT, and dual-modality PET/CT imaging for monitoring of imatinib (STI571) therapy in patients with gastrointestinal stromal tumors. J Nucl Med 2004;45:357-65.
56. Lee JD, Yang WI, Park YN, Kim KS, Choi JS, Yun M, et al. Different glucose uptake and glycolytic mechanisms between hepatocellular carcinoma and intrahepatic mass-forming cholangiocarcinoma with increased (18)F-FDG uptake. J Nucl Med. 2005;46:1753-9.
57. Ho CL, Yu SC, Yeung DW. 11C-acetate PET imaging in hepatocellular carcinoma and other liver masses. J Nucl Med. 2003;44:213-21.
58. Shiomi S, Nishiguchi S, Ishizu H, Iwata Y, Sasaki N, Tamori A, et al. Usefulness of positron emission tomography with fluorine-18-fluorodeoxyglucose for predicting outcome in patients with hepatocellular carcinoma. Am J Gastroenterol. 2001;96: 1877-80.
59. Anderson CD, Rice MH, Pinson CW, Chapman WC, Chari RS, Delbeke D, et al. Fluorodeoxyglucose PET imaging in the evaluation of gallbladder carcinoma and cholangiocarcinoma. J Gastrointest Surg. 2004;8:90-7.
60. Kumar R, Sharma P, Kumari A, Halanaik D, Malhotra A. Role of 18F-FDG PET/CT in detecting recurrent gallbladder carcinoma. Clin Nucl Med. 2012;37:431-5.
61. Sperti C, Pasquali C, Decet G, Chierichetti F, Liessi G, Pedrazzoli S. F-18-fluorodeoxyglucose positron emission tomography in differentiating malignant from benign pancreatic cysts: a prospective study. J Gastrointest Surg. 2005;9:22-9.
62. Delgado-Bolton RC, Fernandez-Perez C, Gonzalez-Mate A, Carreras JL. Meta-analysis of the performance of 18F-FDG PET in primary tumor detection in unknown primary tumors. J Nucl Med. 2003;44:1301-14.
63. Gutzeit A, Antoch G, Kuhl H, Egelhof T, Fischer M, Hauth E, et al. Unknown primary tumors: detection with dual-modality PET/CT—initial experience. Radiology. 2005;234:227-34.
64. Kwee TC, Basu S, Saboury B, Ambrosini V, Torigian DA, Alavi A. A new dimension of FDG-PET interpretation: Assessment of tumor biology. Eur J Nucl Med Mol Imaging. 2011;38:1158-70.
65. Wild D, Mäcke HR, Waser B, Reubi JC, Ginj M, Rasch H, et al. 68Ga-DOTANOC: a first compound for PET imaging with high affinity for somatostatin receptor subtypes 2 and 5. Eur J Nucl Med Mol Imaging. 2005;32:724.
66. Bushnell DL, Baum RP. Standard imaging techniques for neuroendocrine tumors. Endocrinol Metab Clin North Am. 2011;40:153-62.
67. Hofmann M, Maecke H, Borner R, Weckesser E, Schöffski P, Oei L, et al. Biokinetics and imaging with the somatostatin receptor PET radioligand (68)Ga-DOTATOC: preliminary data. Eur J Nucl Med. 2001;28:1751-7.
68. Kowalski J, Henze M, Schuhmacher J, Mäcke HR, Hofmann M, Haberkorn U. Evaluation of positron emission tomography imaging using [68Ga]-DOTA-D Phe (1)-Tyr (3)-Octreotide in comparison to [111In]-DTPAOC SPECT. First results in patients with neuroendocrine tumors. Mol Imaging Biol. 2003;5:42-8.
69. Balogova S, Talbot JN, Nataf V, Michaud L, Huchet V, Kerrou K, et al. (18)F-Fluorodihydroxyphenylalaninevs other radiopharmaceuticals for imaging neuroendocrine tumors according to their type. Eur J Nucl Med Mol Imaging. 2013;40: 943-66.
70. Jager PL, Chirakal R, Marriott CJ, Brouwers AH, Koopmans KP, Gulenchyn KY. 6-L-18F-fluorodihydroxyphenylalanine PET in neuroendocrine tumors: basic aspects and emerging clinical applications. J Nucl Med. 2008;49:573-86.
71. Kumar R, Sharma P, Garg P, Karunanithi S, Naswa N, Sharma R, et al. Role of (68)Ga-DOTATOC PET-CT in the diagnosis and staging of pancreatic neuroendocrine tumors. Eur Radiol. 2011;21:2408-16.
72. Naswa N, Sharma P, Kumar A, Nazar AH, Kumar R, Chumber S, et al. Gallium-68-DOTA-NOC PET/CT of patients with gastroenteropancreatic neuroendocrine tumors: a prospective single-center study. AJR Am J Roentgenol. 2011;197:1221-8.
73. Barthlen W, Blankenstein O, Mau H, Koch M, Höhne C, Mohnike W, et al. Evaluation of [18F]fluoro-L-DOPA positron emission tomography-computed tomography for surgery in focal congenital hyperinsulinism. J Clin Endocrinol Metab. 2008;93:869-75.

JAYPEE BROTHERS

detailed information on gastroenterology books, visit our website **www.jaypeebrothers.com,** for detailed information on gastro

Textbook of
Surgical Gastroenterology

Salient Features

- Fills a long-felt gap in the field of surgical gastroenterology
- This pioneering effort comes at a time when rapid strides are being made in technology and research
- Evidence-based medicine and experience-based medicine vie for space with each other
- Industry-driven technology push forth advancements, the results of which need to be examined closely
- Covers from basic to the advanced aspects of surgical gastroenterology
- Liver transplantation to Statistics, Cirrhosis to Robotics and from Esophagus to the Anal canal—all the topics find resonance
- This book is a "must have" in the armamentarium of all students and practitioners of surgery and gastroenterology
- Experienced authors in collaboration with the editors have come together to bring out this comprehensive volume to fulfill the needs of students and practitioners in the field of surgery, gastroenterology and surgical gastroenterology.



PK Mishra did his MBBS (1981) from Maulana Azad Medical College, New Delhi, India. He did his postgraduation in Surgery (1985-87) from Lady Hardinge Medical College and Dr Ram Manohar Lohia Hospital and has completed 30 years of his journey as a surgeon. He entered surgical gastroenterology, when this superspecialty was still in the fledgling phase and did his PhD (GI Surgery) (1996), under Professor Samiran Nundy from AIIMS, New Delhi, India. He has subsequently been in academic departments of Guru Teg Bahadur Hospital, University College of Medical Sciences and Ram Manohar Lohia Hospital (PGIMER). He has been engaged in teaching and research besides performing several advanced operations in the field of surgical gastroenterology. Many of his students are now reputed surgeons and well-placed surgical gastroenterologists. He has several international publications in the field and has traveled all over India and delivered many invited lectures.

Available at all medical bookstores
or buy online at www.jaypeebrothers.com

JAYPEE
JAYPEE BROTHERS
Medical Publishers (P) Ltd.
www.jaypeebrothers.com

Join us on facebook.com/JaypeeMedicalPublishers

Shelving Recommendations
GASTROENTEROLOGY
SURGERY

ISBN 978-93-5152-998-9
9 789351 529989